

Assessing Flexibility

Assessing Posture Assessing Range of Motion

Cervical Spine

Shoulder

Elbow

Wrist, Hand, and
Fingers

Thoracic and Lumbar
Spine

Hip

Knee

Ankle, Foot, and Toes

Summary

Not everyone has the same flexibility needs or flexibility potential. Our flexibility potential is affected by genetics, gender, age, lifestyle, medical history, occupation, and, of course, type and level of physical activity. It is therefore unwise to assume that all stretches are beneficial and safe for everyone.

For example, some individuals may have particularly tight hamstrings or pectoral muscles that deserve specific attention. These same individuals may also have a hypermobile lumbar spine that should *not* be stretched. This chapter is designed to help you construct an effective stretching program based on individual need.

As each individual has unique flexibility needs, the first step toward developing a specific flexibility program is to assess posture and available range of motion (ROM). We can then compare the available motion to the determined need to develop the most appropriate flexibility program. This chapter has been developed to help you perform this assessment. It provides a head to toe testing sequence to help determine if ROM is adequate, restricted, or excessive. Please keep in mind that these tests are meant as a guide and the ROM normative data are averages based on a healthy college age population. To determine useful ROMs at particular joints for particular athletic pursuits, the reader is encouraged to seek sources specific to that particular sport or activity. Additional sources are listed at the end of this chapter.

After a brief discussion of posture assessment (a more thorough discussion of posture is provided in Chapter 7), this chapter describes techniques for assessing movement at all major joints. A description of normal movement is followed by information on identifying the amount of motion expected. This information is provided as a guide to help determine if changes in ROM are necessary and generally to what degree. It should be used in concert with knowledge of both need and the individual's physiologic makeup. For more specific assessment, numerical data have been provided as a reference. In most cases, these numerical values are derived from the *Measurement of Joint Motion* by Norkin and White.¹ We have chosen to use this source as it was the only available source that offered ROM values throughout the body. Other sources found slightly different values for select joints; to include all of these sources would be extremely cumbersome, distracting, and of no real benefit to the intended use of this chapter, which is to provide general guidelines for ROM and how to assess it.

As Norkin and White have used a number of different references, we have chosen those values published by the American Academy of Orthopedic Surgeons (AAOS) to ensure consistency and avoid confusion with differing values. In cases where Norkin and White did not provide values (or these values were not useful for this specific application), we have chosen an alternative source. In these cases, alternative sources are listed. We have attempted to provide these ROM values in two basic forms: first

in terms of a practical measurement as described in the “test” and then, more formally, in degrees. This format allows the text to be used as both a quick reference to expected motion and as a more detailed evaluation tool. The muscles that may be causing the restriction are listed under the headings “General Stretch” and “Specific Stretches,” which identify a stretch for either the muscle group (from Chapter 5) or for each individual muscle (from Chapter 4). The techniques for performing the recommended stretches are detailed in Chapters 4 and 5.

The tests in this chapter may be used to make an initial evaluation and also to measure the progress of the prescribed stretching program. Consider recording the test “scores” obtained at the initial evaluation, and then again at regular intervals such as 6 or 12 weeks. In this way, you can track progress in particular “problem” areas.



CAUTION! Please bear in mind that the information in this chapter is intended to be used only as a guide. Individuals with painful or particularly restricted or hypermobile movements should be referred to their primary care provider. While listing every possible restriction to joint movement that you should be aware of would necessitate a chapter on its own, we have denoted a couple of situations in which injuries are frequently encountered. These are identified by the “Caution!” symbol.

ASSESSING POSTURE

For the purposes of this discussion, we will define *posture* as the position in which the upright body is held. It is typically characterized by the relationship of skeletal regions, such as the head, spinal regions, pelvis, knees, and ankles, with one another. Posture results from the interaction of a number of factors including strength, flexibility, joint ROM, age-related factors, gender, and genetics. These components may be influenced throughout an individual’s growth and development by activity level, types of physical activities pursued (including athletic pursuits, occupation, and avocation), medical history, and possibly even social factors such as self-esteem.

“Good” posture reflects a positioning of the skeleton that allows for optimal functioning of all of its individual components. It is generally described as a position in which the ear, shoulder, hip, and knee are aligned over a point just in front of the ankle joint (Fig. 3.1). In the spine, this is usually synonymous with the existence of three gentle curves—the concave cervical curvature, the convex thoracic curvature, and the concave lumbar curvature. These curves may be influenced by the amount of flexibility in the muscles that help control motion at these joints.

Posture is much more than aesthetic. Good posture allows for the optimal functioning of joints throughout the body. It also allows for the optimal function of the internal organs. In contrast, poor posture may cause excessive or abnormal stress on the vertebral column as well as on the muscles, tendons, ligaments, and connective tissues that support it. Increased pressures on intra-thoracic organs may also impair blood flow and compromise the functions of these organs.

Common postural abnormalities include forward head, rounded shoulders, increased thoracic curvature, increased lumbar curvature, and hyper-extended knees (Fig. 3.2). A flexibility program designed to help correct the components of this common “poor” posture should address the following:

- Forward head: Lower cervical and upper thoracic extensors may be overstretched. Lower cervical flexors and upper cervical extensors may need stretching.
- Forward and rounded shoulders: Spinal and thoracic extensors, scapular adductors, and shoulder external rotators may be overstretched. Spinal flexors, shoulder

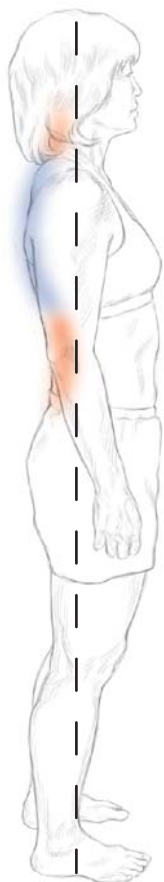


FIGURE 3.1 “Good” posture. Notice the three spinal curves: the concave cervical curvature, the convex thoracic curvature, and the concave lumbar curvature. Notice the vertical line drawn from ear, through shoulder, hip, and knee and ending just in front of the ankle.

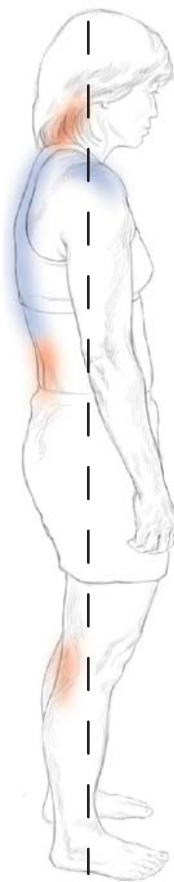


FIGURE 3.2 “Poor” posture. Notice the forward head, forward and rounded shoulders, hyper-extended lower back, and hyper-extended knees.

flexors, horizontal flexors, internal rotators, and scapular protractors may need stretching.

- Hyper-extended lower back: Abdominal muscles, lumbar joints, and anterior hip ligaments may be overstretched. Lower spinal extensors and hip flexors may need stretching.
- Hyper-extended knees: Knee joint capsule and ligaments may be overstretched. Ankle plantar flexors may need to be stretched.

ASSESSING RANGE OF MOTION

The following guide is arranged to help you easily identify possible problem areas. The movement in question is described first, followed by the quick test, average motion available, and then the stretch or stretches recommended to treat any restriction. (The muscles listed are also the possible muscular restrictions to movement.) Again, the techniques for stretching the muscle groups are listed in Chapter 5, and those for the individual muscles are listed in Chapter 4.

Please note that the tests included here are not exhaustive but should be appropriate for use with most individuals. See the end-of-chapter references for sources to consult if you need additional information on testing ROM for specific needs.

For a number of movements, “subtests” are provided to help distinguish between two or more muscles that perform the same general movement (and therefore restrict the same antagonistic movement). A few subtests address the differences between restrictions caused by multi-joint muscles (muscles that cross more than one joint) versus those caused by single-joint muscles, as these are often important distinctions to make.

Cervical Spine

Below are flexibility tests for the cervical spine.



CAUTION! Please be aware that restrictions in movement at the cervical spine that cause light-headedness, dizziness, local or referred pain, tingling, or numbness may indicate potentially hazardous injury to joint, nerve, or blood vessel. These cases should be thoroughly evaluated by a professional specializing in spinal dysfunction before continuing.

CERVICAL FLEXION: UPPER

TEST POSITION. Standing with head, shoulders, back, and heels against the wall. Both hands are placed behind the cervical curvature to maintain the curve and ensure that motion occurs above this level.

TEST. Nod the head attempting to isolate movement to the upper vertebrae. Check for 10–20 degrees of “nod” with no change in position of lower cervical vertebrae (Fig. 3.3).

AVERAGE MOTION AVAILABLE. 15 degrees (total flexion/extension at the atlanto-occipital joint)²

GENERAL STRETCH. Cervical extensors

SPECIFIC STRETCHES. Rectus capitus posterior major and minor, and obliquus capitus superior and inferior

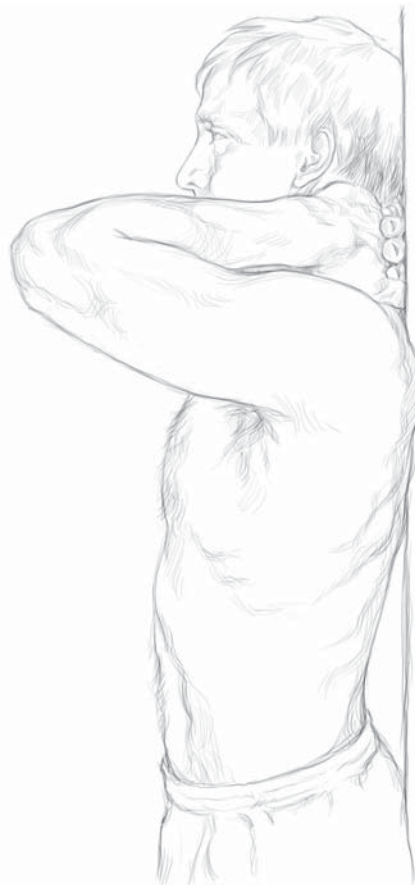

FIGURE 3.3 Test of cervical flexion: upper

CERVICAL FLEXION: LOWER

TEST POSITION. Standing with head and shoulders against the wall

TEST. Flex the head, moving chin toward chest. Chin should come within one inch of the sternum (Fig. 3.4).

AVERAGE MOTION AVAILABLE. AAOS 45 degrees

GENERAL STRETCH. Cervical extensors

SPECIFIC STRETCHES. Longissimus capitus, semispinalis capitis, and splenius capitus

CERVICAL EXTENSION

TEST POSITION. Standing, facing a wall, nose touching wall

TEST. Place the fingers of one hand just beneath the occiput. Look up toward the ceiling by lifting the chin up along the wall, encouraging a lengthening along the front of the neck while *carefully* guiding the motion up and back (Fig. 3.5). There should be 1–2 finger widths ($\frac{1}{2}$ –1 inches) between the occiput and the seventh cervical vertebra (prominent bump at the bottom of neck/upper shoulders).

AVERAGE MOTION AVAILABLE. AAOS 45 degrees

GENERAL STRETCH. Cervical flexors

SPECIFIC STRETCHES. Longus coli, sternohyoid, omohyoid, platysma

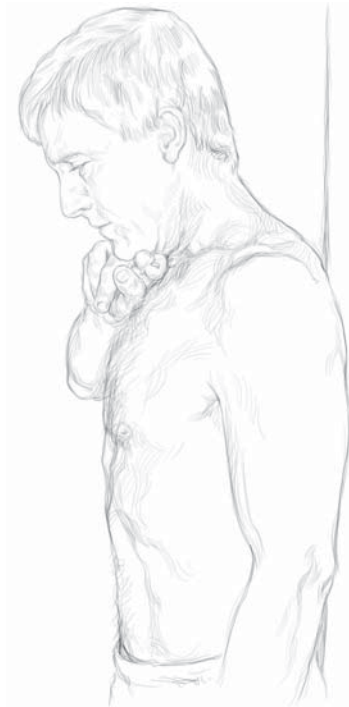

FIGURE 3.4 Test of cervical flexion: lower

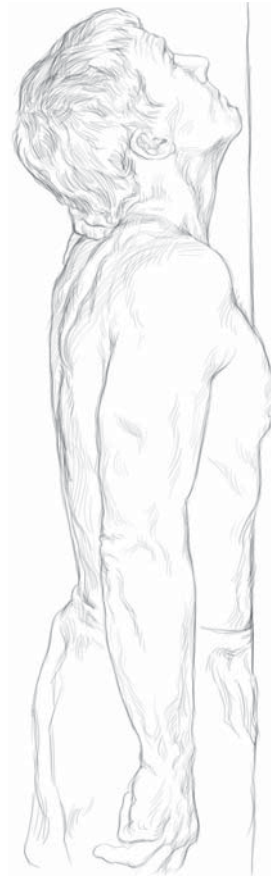

FIGURE 3.5 Test of cervical extension

CERVICAL ROTATION

TEST POSITION. Standing with back of head and shoulders against a wall

TEST. Rotate the head toward the wall, being careful not to side-bend (laterally flex) the neck (Fig. 3.6). Check for 2–3 finger widths (1–2 inches) between the cheekbone and the wall.

AVERAGE MOTION AVAILABLE. AAOS 60 degrees

GENERAL STRETCH. Cervical rotators

SPECIFIC STRETCHES. Sternocleidomastoid, upper trapezius, obliquus capitus inferior, splenius capitus

CERVICAL SIDE-BENDING

TEST POSITION. Standing with back of head and shoulders against a wall

TEST. Tilt the head directly to the left without allowing rotation (i.e., ear toward shoulder) (Fig. 3.7). Use the number of finger widths of the right hand as measurement. Three or 4 finger widths (1.5–2.0 inches) is normal.

AVERAGE MOTION AVAILABLE. AAOS 45 degrees

GENERAL STRETCH. Cervical side-benders (lateral flexors)

SPECIFIC STRETCHES. Upper trapezius, splenius capitus, longissimus capitus, obliquus capitus superior, obliquus capitus inferior

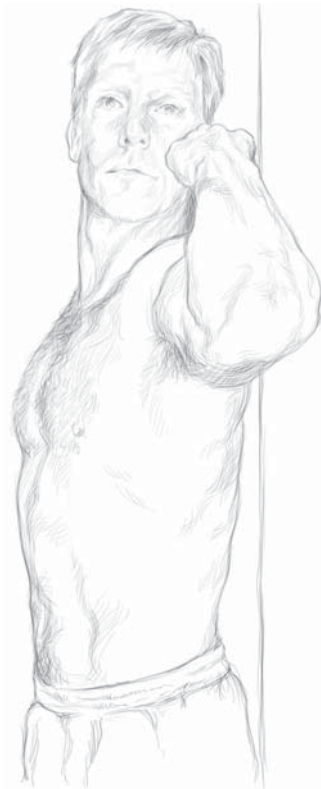

FIGURE 3.6 Test of cervical rotation




FIGURE 3.7 Test of cervical side-bending

Shoulder

Below are flexibility tests for the shoulder region.

SHOULDER FLEXION

TEST POSITION. Standing in doorway, arms overhead, palms against inside of doorway.

TEST. Keeping spine straight, move forward in doorway (Fig. 3.8). Arms should extend vertically.

AVERAGE MOTION AVAILABLE. AAOS 180 degrees

GENERAL STRETCH. Shoulder extensors

SPECIFIC STRETCHES. Posterior deltoid, latissimus dorsi, teres minor, teres major, triceps brachii-long head

SHOULDER EXTENSION

TEST POSITION. Standing, hands held together behind back

TEST. Lift hands behind back, keeping elbows straight (Fig. 3.9). Arms should extend about 12 inches behind back.

AVERAGE MOTION AVAILABLE. AAOS 60 degrees

GENERAL STRETCH. Shoulder flexors

SPECIFIC STRETCHES. Anterior deltoid, pectoralis major—clavicular portion, biceps brachii—long head, coracobrachialis



FIGURE 3.8 Test of shoulder flexion

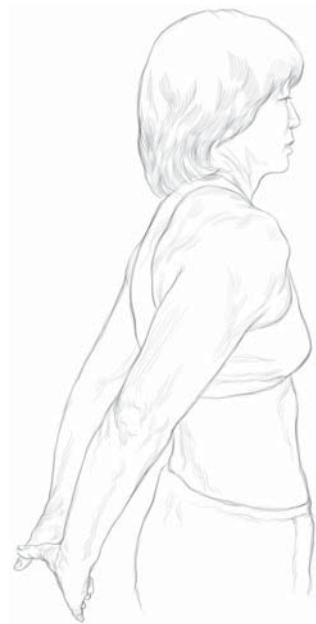

FIGURE 3.9 Test of shoulder extension

SHOULDER ABDUCTION

TEST POSITION. Standing with back against the wall, arms extended horizontally from shoulders, palms facing up

TEST. Abduct both arms, keeping them flat against the wall (Fig. 3.10). Hands should come together and upper arms should come in contact with the head.

AVERAGE MOTION AVAILABLE. AAOS 180 degrees

GENERAL STRETCH. Shoulder adductors

SPECIFIC STRETCHES. Pectoralis major, latissimus dorsi, teres major, rhomboids major and minor

SHOULDER INTERNAL ROTATION

TEST POSITION. Lying supine with left shoulder abducted to 90 degrees, left elbow bent to 90 degrees, forearm pronated

TEST. Keep the left shoulder stable by applying a firm downward pressure with the palm of the right hand while bringing the palm of the left hand toward the floor (Fig. 3.11). The left wrist should come within 4 to 6 inches of the floor. Repeat the test on the right shoulder.

AVERAGE MOTION AVAILABLE. AAOS 70 degrees

GENERAL STRETCH. Shoulder external rotators

SPECIFIC STRETCHES. Posterior deltoid, infraspinatus, teres minor



FIGURE 3.10 Test of shoulder abduction

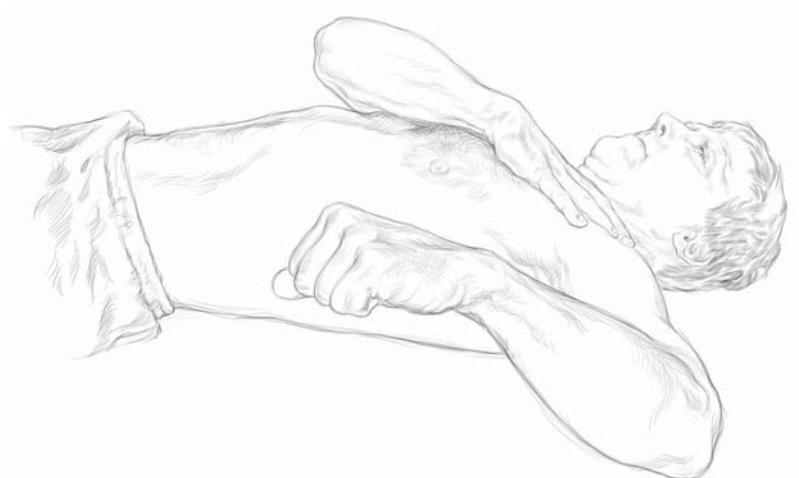


FIGURE 3.11 Test of shoulder internal rotation

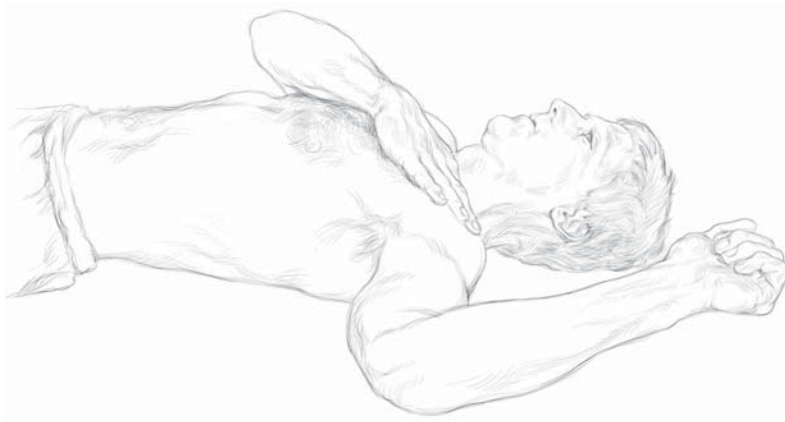

FIGURE 3.12 Test of shoulder external rotation

SHOULDER EXTERNAL ROTATION

TEST POSITION. Lying supine with left shoulder abducted to 90 degrees, left elbow bent to 90 degrees, forearm pronated

TEST. Keep the left shoulder stable by applying a firm downward pressure with the palm of the right hand while moving the left forearm and hand back toward the floor (externally or laterally rotating the shoulder) (Fig. 3.12). The back (posterior) of the left wrist should come within 1 to 2 inches of the floor. Repeat the test on the right shoulder.

AVERAGE MOTION AVAILABLE. AAOS 90 degrees

GENERAL STRETCH. Shoulder internal rotators

SPECIFIC STRETCHES. Subscapularis, pectoralis major, anterior deltoid

Elbow

Below are flexibility tests for the elbow region.

ELBOW EXTENSION

TEST POSITION. Standing, arms relaxed at sides

TEST. Straighten the elbow (Fig. 3.13). It should straighten completely. In many individuals, particularly women, the elbow hyperextends 2–5 degrees. Assess both elbows.

AVERAGE MOTION AVAILABLE. AAOS 0 degrees

GENERAL STRETCH. Elbow flexors

SPECIFIC STRETCHES. Biceps brachii—short head, brachialis, brachioradialis

SUBTEST. To test for biceps brachii—long head, keep the elbow extended and extend the shoulder back to about 30 degrees. If the elbow flexes during this shoulder extension, the long head of the biceps may be tight.

ELBOW FLEXION

TEST POSITION. Standing with arms at sides

TEST. Flex the elbow to maximum (Fig. 3.14). You should be able to touch the top of the shoulder (acromion) with your index finger. Assess both elbows.

AVERAGE MOTION AVAILABLE. AAOS 150 degrees

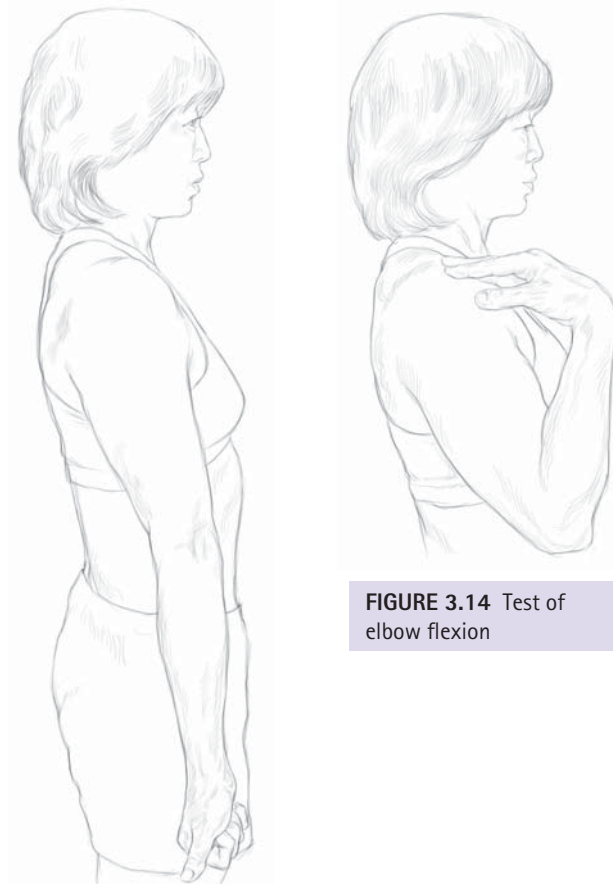


FIGURE 3.13 Test of elbow extension

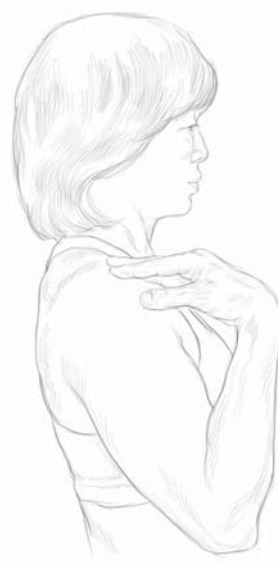

FIGURE 3.14 Test of elbow flexion

GENERAL STRETCH. Elbow extensors

SPECIFIC STRETCHES. Triceps brachii—medial and middle heads, anconeus

SUBTEST. To test for triceps brachii—long head, hold end position achieved above with index finger on acromion, and raise elbow up overhead until upper arm is vertical. If this motion is difficult, the long head of the triceps may be tight.

Wrist, Hand, and Fingers

Below are flexibility tests for the wrist, hand, and fingers.

WRIST EXTENSION

TEST POSITION. Standing facing a wall with shoulders flexed to 90 degrees and arms outstretched, hands in front of shoulders, wrists in neutral alignment, with palms facing downward

TEST. Keep elbows straight while attempting to place hands flat on the wall (Fig. 3.15). Normal ROM will allow you to place your hands flat on the wall with your elbows straight.

AVERAGE MOTION AVAILABLE. AAOS 80 degrees

GENERAL STRETCH. Wrist and finger flexors

SPECIFIC STRETCHES. Flexor carpi radialis, palmaris longus, flexor digitorum profundus and superficialis, flexor carpi ulnaris

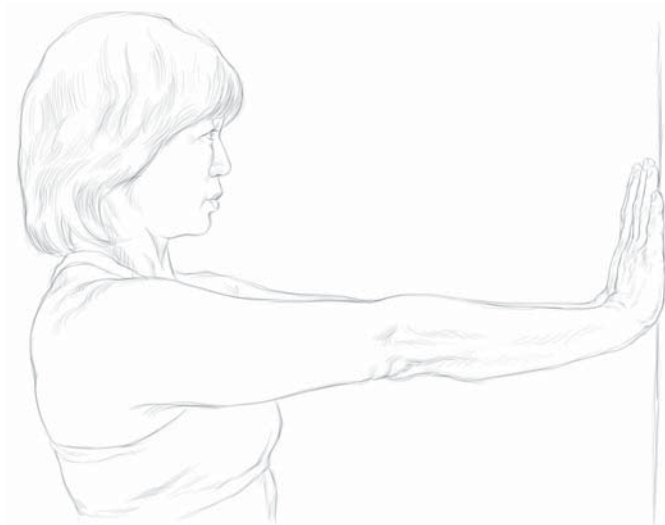

FIGURE 3.15 Test of wrist extension

WRIST FLEXION

TEST POSITION. Standing facing a wall with arms outstretched, so that hands are in front of shoulders and wrists are in neutral alignment, with palms facing downward

TEST. Keep elbows straight while attempting to place the dorsum (back) of hands flat against the wall (Fig. 3.16). You should be able to place most of the back of your hand against the wall, with the wrist coming within 1 inch.

AVERAGE MOTION AVAILABLE. AAOS 70 degrees

GENERAL STRETCH. Wrist and finger extensors.

SPECIFIC STRETCHES. Extensor carpi radialis, extensor carpi ulnaris, extensor digitorum, extensor digiti minimi, extensor indicis

FINGER FLEXION

TEST POSITION. Standing with shoulders flexed to 90 degrees (arms outstretched in front of shoulders) with palms facing downward

TEST. Attempt to make a tight fist, and then flex the wrist 30–40 degrees (Fig. 3.17). Test both hands.

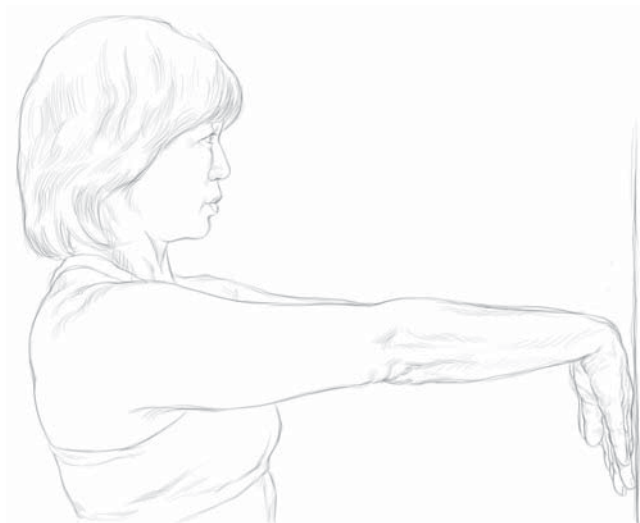


FIGURE 3.16 Test of wrist flexion

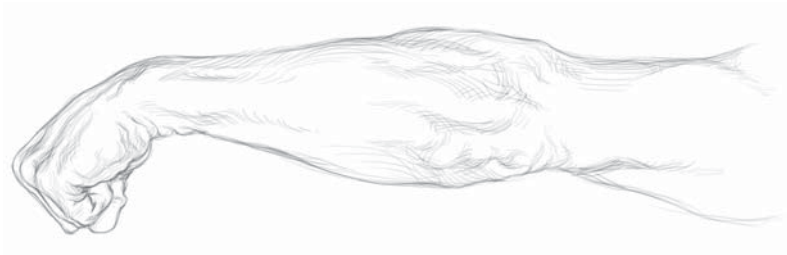


FIGURE 3.17 Test of finger flexion

AVERAGE MOTION AVAILABLE. References available are for each joint (metacarpophalangeal, interphalangeal) and beyond the scope of this text (see references in Appendix A for more information).

GENERAL STRETCH. Wrist and finger extensors

SPECIFIC STRETCHES. Extensor digitorum, extensor indicis, extensor digiti minimi

NOTE. If unable to make a fist with the wrist in neutral alignment (i.e., before flexing the wrist), a simple musculotendinous restriction is unlikely, and a joint restriction should be considered. If this restriction is significant and/or painful, consider referral to an appropriate hand specialist.

FINGER EXTENSION

TEST POSITION. Standing or seated with the elbow flexed and the forearm supinated (palm facing up)

TEST. Open the hand as wide as possible (Fig. 3.18). It should open to reveal a flat or slightly hyper-extended position. Test both hands.

AVERAGE MOTION AVAILABLE. References available are for each joint (metacarpophalangeal, interphalangeal) and beyond the scope of this text (see references in Appendix A for more information).

GENERAL STRETCH. Wrist/Hand/Finger flexors

SPECIFIC STRETCHES. Flexor pollicis brevis, abductor pollicis brevis, adductor pollicis, flexor digiti minimi, lumbricales

Thoracic and Lumbar Spine

Below are flexibility tests for the thoracic and lumbar spine regions.

THORACIC EXTENSION

TEST POSITION. Standing, back and shoulders against a wall

TEST. First, tilt the pelvis posteriorly, flattening the lower back (lumbar spine) against the wall (Fig. 3.19). Next, attempt to extend the mid/upper back (thoracic

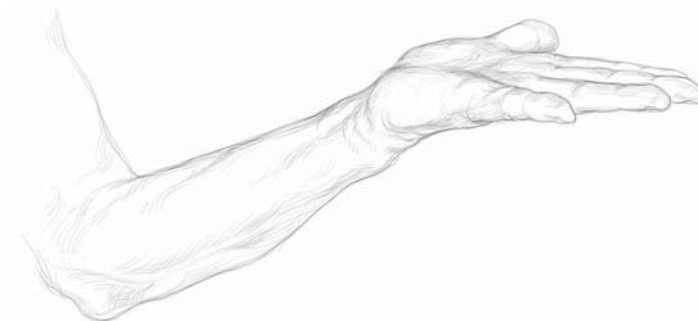


FIGURE 3.18 Test of finger extension

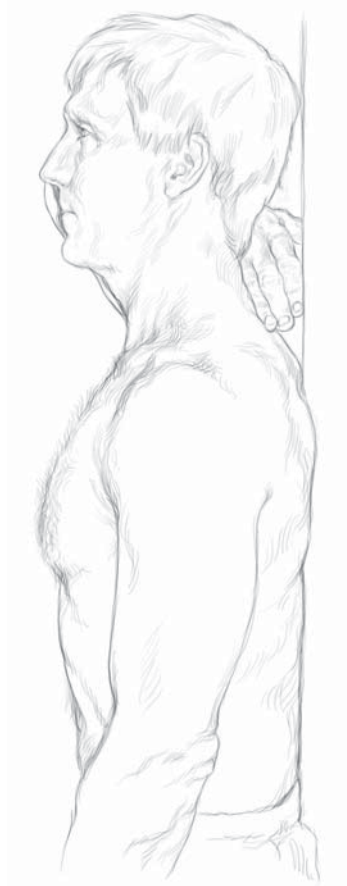

FIGURE 3.19 Test of thoracic extension

spine) and flatten it against the wall. You should observe no more than 2–3 finger widths (1.0–1.5 inches) between the spinous processes of the C7 to T1 vertebrae and the wall.

AVERAGE MOTION AVAILABLE. AAOS 25 degrees (combined motion between thoracic and lumbar spines)

GENERAL STRETCH. Lumbar and thoracic flexors

SPECIFIC STRETCHES. Rectus abdominus and, indirectly, via forward head postures: sternocleidomastoid, scalenes, platysma

NOTE. A significant lack of thoracic extension accompanied by a significantly flexed resting position is characteristic of kyphosis, a disorder that may be related to osteoporosis. Although stretching the thoracic and abdominal flexors is a useful intervention, severely restricted thoracic extension and clinical kyphosis may best be addressed with manual intervention from an osteopath, a chiropractor, or a physical therapist who specializes in spinal joint mobilization or manipulation.

THORACIC FLEXION

TEST POSITION. Standing with lower back flattened against the wall

TEST. Slowly and carefully flex the head first, and then the thoracic spine toward the feet while gliding the hands down along the front of the thighs for support (Fig. 3.20). Stop as soon as the motion reaches the lower back. You should be able to touch your knees.



FIGURE 3.20 Test of thoracic flexion

AVERAGE MOTION AVAILABLE. AAOS 80 degrees (combined motion between thoracic and lumbar spines)

GENERAL STRETCH. Spine extensors

SPECIFIC STRETCHES. Spinalis thoracis, iliocostalis thoracis, longissimus thoracis

LUMBAR FLEXION

TEST POSITION. Lying supine

TEST. Begin by using the arms and hands to pull both knees toward the chest. While keeping head, neck, shoulders, and upper back flat on the floor, continue to pull the knees up toward the chest until a gentle curve is formed by the lower back (Fig. 3.21). There should be about and 4 or 5 finger widths (3–4 inches) between your coccyx (tailbone) and the floor.

AVERAGE MOTION AVAILABLE. AAOS 80 degrees (combined motion between thoracic and lumbar spines).

GENERAL STRETCH. Spine extensors

SPECIFIC STRETCHES. Erector spinae, multifidus, quadratus lumborum



CAUTION! Severe pain, or pain, numbness, and tingling in the leg or foot, brought on by this maneuver may be indicative of lumbar pathology. This test should be modified to eliminate these symptoms or discontinued altogether. Further evaluation by a specialist may be prudent at this point.



FIGURE 3.21 Test of lumbar flexion

LUMBAR EXTENSION

TEST POSITION. Lying prone

TEST. Place both hands on the floor just in front of the shoulders (Fig. 3.22). Press the upper body up and back by extending both arms at the elbows. Keep the front of the hip bones (ASIS) in contact with the floor. Continue pressing up until a mild tension is felt in either the abdominal musculature or the lower back. *Do not* press up through lower back pain. You should be able to extend your arms comfortably.

AVERAGE MOTION AVAILABLE. AAOS 50 degrees

GENERAL STRETCH. Lumbar flexors, hip flexors

SPECIFIC STRETCHES. Rectus abdominus, internal oblique, external oblique, psoas

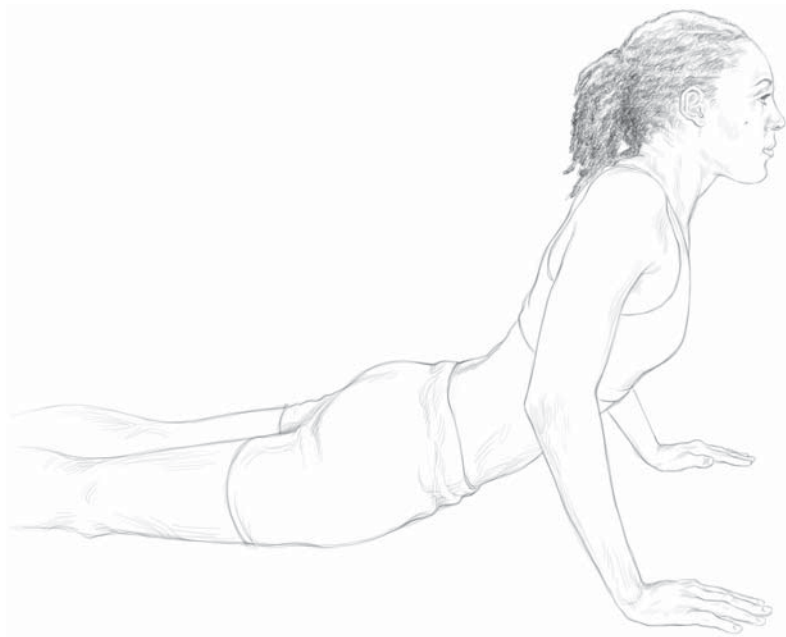


FIGURE 3.22 Test of lumbar extension



CAUTION! Severe pain, or pain, numbness, and tingling in the leg or foot, brought on by this maneuver may be indicative of lumbar pathology. This test should be modified to eliminate these symptoms or discontinued altogether. Further evaluation by a specialist may be prudent at this point. Individuals with spondylolisthesis should *not* perform this test.

Hip

Below are flexibility tests for the hip region.

HIP FLEXION

TEST POSITION. Lying supine, legs extended

TEST. Pull one knee up to the chest, allowing the hip to flex completely (Fig. 3.23). There should be contact between the thigh and abdominal area. Test hip flexion on both sides.

AVERAGE MOTION AVAILABLE. AAOS 120 degrees

GENERAL STRETCH. Hip extensors

SPECIFIC STRETCHES. Gluteus maximus, posterior fibers of gluteus medius

HIP EXTENSION

TEST POSITION. Supine with thighs and legs hanging off of plinth so that the lower back and buttocks are just supported, knees relaxed

TEST. Pull your left knee toward your chest until the lower back is flattened against the table (Fig. 3.24). The right thigh should hang below the level of the table about 20–30 degrees. Then test extension at the left hip.

AVERAGE MOTION AVAILABLE. AAOS 20 degrees

GENERAL STRETCH. Hip flexors

SPECIFIC STRETCHES. Psoas major, psoas minor, iliacus, rectus femoris

HIP ABDUCTION

TEST POSITION. Lying supine with buttocks against the wall and legs straight up, supported against the wall

TEST. Allow your legs to fall to their respective sides (abduction) while maintaining contact with the wall (Fig. 3.25). There should be at least a 90-degree angle between the legs.

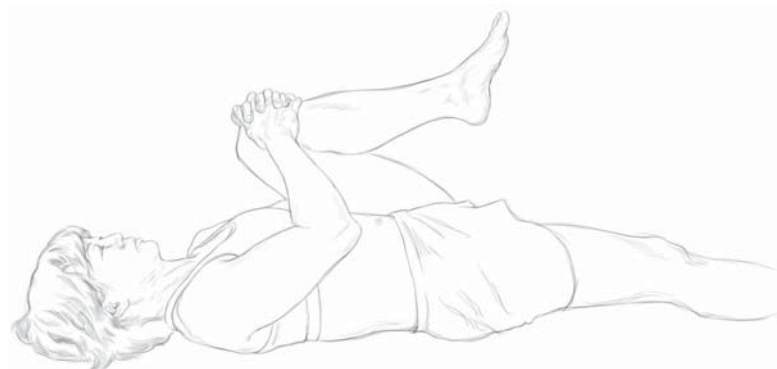

FIGURE 3.23 Test of hip flexion

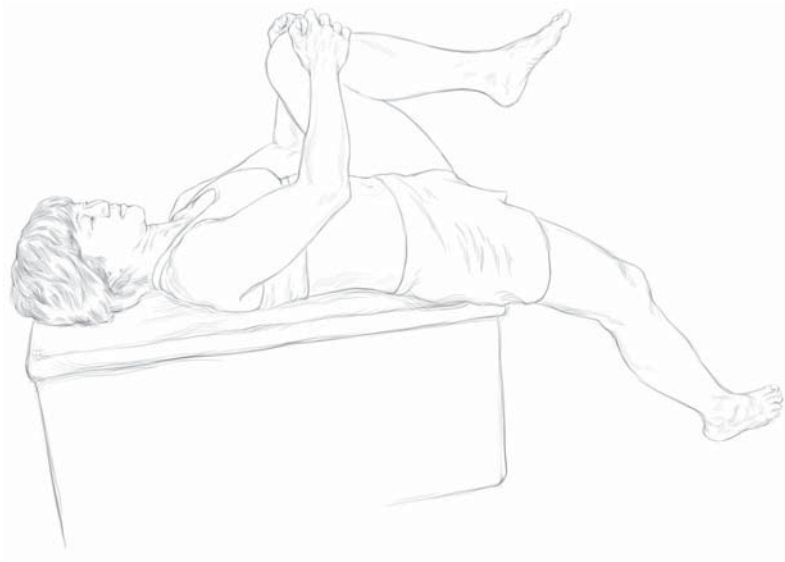

FIGURE 3.24 Test of hip extension

AVERAGE MOTION AVAILABLE. AAOS 45 degrees

GENERAL STRETCHES. Hip adductors

SPECIFIC STRETCHES. Pectineus, adductor longus, adductor brevis, adductor magnus, gracilis

HIP ADDUCTION

TEST POSITION. Lying on the left side on the plinth or other supportive surface so that the waist is supported, but the entire right leg is able to hang freely downward. Left thigh should be flexed forward, knee bent, and out of the way of the unsupported right leg.

TEST. Use your right hand to exert downward pressure on the right hip, flattening the left waist, hip, and torso against the table (Fig. 3.26). Then allow the extended right leg to hang down. The right leg should fall well below the plane of the upper body about 30 degrees. Also test adduction of left hip.

AVERAGE MOTION AVAILABLE. AAOS 30 degrees




FIGURE 3.25 Test of hip abduction

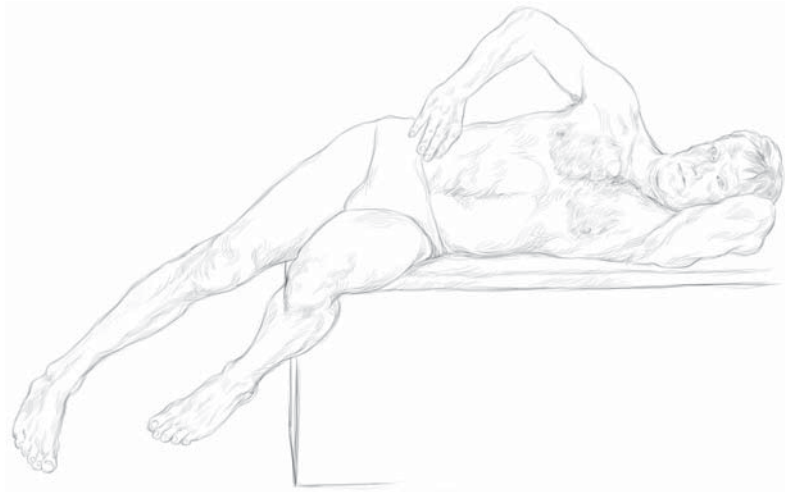


FIGURE 3.26 Test of hip adduction

GENERAL STRETCH. Hip abductors

SPECIFIC STRETCHES. Gluteus minimus, gluteus medius, tensor fascia latae

HIP INTERNAL ROTATION

TEST POSITION. Standing, with hips and knees facing directly forward. Note position of feet at start position—they will likely be pointed outward 10–20 degrees.

TEST. Keeping the knees straight, rotate one foot at a time inward as far as possible (Fig. 3.27). Forty-five degrees from the start position should be available.

AVERAGE MOTION AVAILABLE. AAOS 45 degrees

GENERAL STRETCH. Hip external rotators

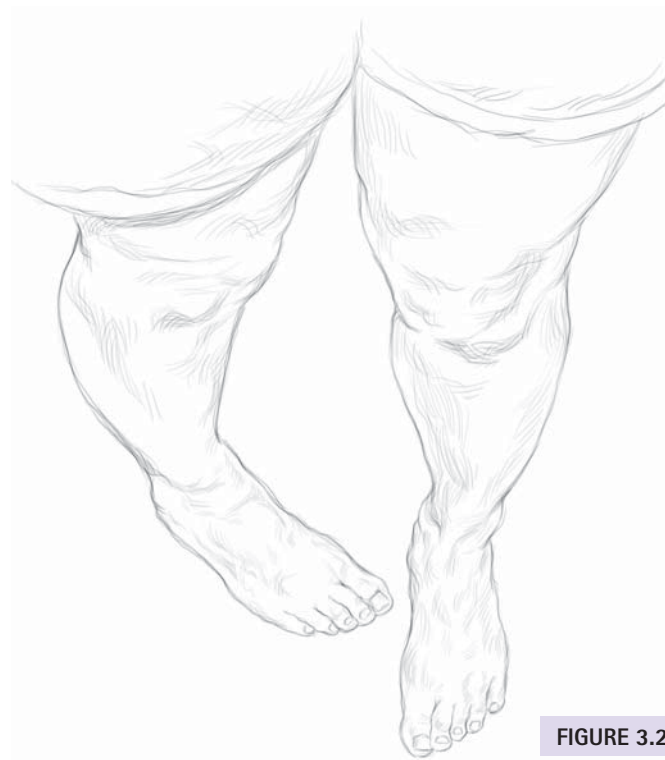

FIGURE 3.27 Test of hip internal rotation

SPECIFIC STRETCHES. Gluteus maximus, gluteus medius—posterior fibers, piriformis, gemellus superior and inferior, obturator internus and externus, quadratus femoris

HIP EXTERNAL ROTATION

TEST POSITION. Standing, with hips and knees facing directly anterior. Note position of feet at start position.

TEST. While keeping the knees locked, rotate one foot at a time outward as far as possible (Fig. 3.28). Forty-five degrees from the start position should be available.

AVERAGE MOTION AVAILABLE. AAOS 45 degrees

GENERAL STRETCH. Hip internal rotators

SPECIFIC STRETCHES. Gluteus medius—anterior fibers

Knee

Below are flexibility tests for the knee region.

KNEE EXTENSION

TEST POSITION. Lying supine, perpendicular to doorway with one leg through and the other (test leg) resting against the doorway, knee extended

TEST. Keep the knee of the test leg straight while moving the entire body as close to the doorway as possible (Fig. 3.29). This may require some assistance from the bent leg and the hands. The buttocks should come within 1 foot of the doorway for men and 6 inches for women. Test extension at both knees.

AVERAGE MOTION AVAILABLE. AAOS 10 degrees

GENERAL STRETCH. Knee flexors

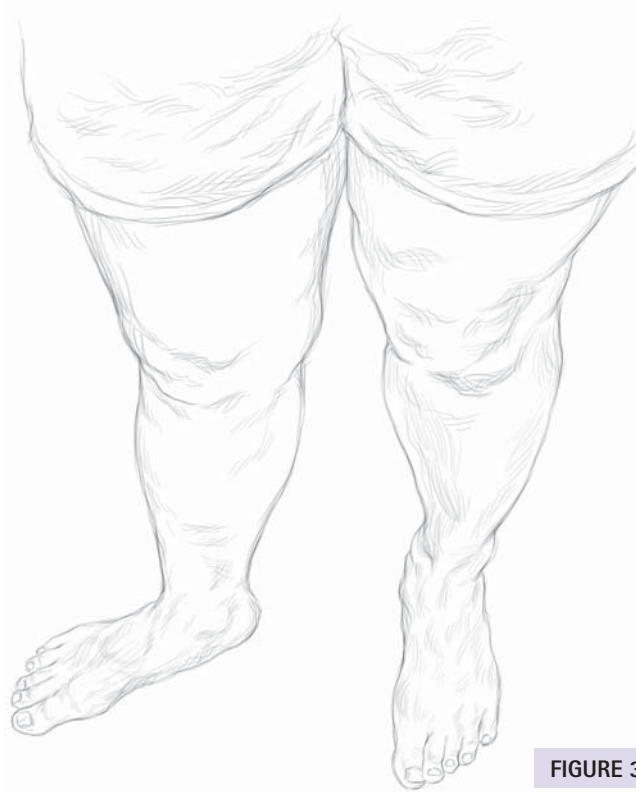

FIGURE 3.28 Test of hip external rotation



FIGURE 3.29 Test of knee extension

SPECIFIC STRETCHES. Semimembranosus, semitendinosus, biceps femoris–long head

NOTE. If the knee cannot be completely extended (i.e., straightened) even if both legs are extended on the floor, there may be a restriction in the knee joint itself. It is also possible, though uncommon, that this restriction is related to a severe shortness of the short head of biceps femoris, gastrocnemius, and popliteus.

KNEE FLEXION

TEST POSITION. Lying prone on table or mat with test leg flexed to about 90 degrees

TEST. Grasp the lower leg just proximal to the ankle and pull it toward the buttocks (Fig. 3.30). The heel should come within 2 inches of the buttocks. Test flexion of both knees.

AVERAGE MOTION AVAILABLE. AAOS 135 degrees

GENERAL STRETCH. Knee extensors

SPECIFIC STRETCHES. Rectus femoris

NOTE. If there is inappropriate knee flexion, try testing again in the supine position. Pull knee to chest and then attempt to pull heel to buttock via a firm grip on the

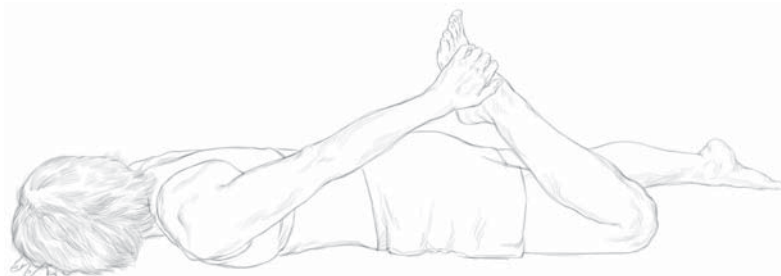

FIGURE 3.30 Test of knee flexion

lower leg, again just above the ankle. A positive test in this position may imply restriction in the other quadriceps muscles, such as the vastus lateralis, vastus medialis, and/or vastus intermedius. We must also keep in mind the possibility of a joint restriction. Referral to an orthopedic specialist is appropriate if there is any question as to the nature of the restriction, especially if the restriction is painful.

Ankle, Foot, and Toes

Below are flexibility tests for the ankle, foot, and toes.

ANKLE FLEXION (PLANTARFLEXION)

TEST POSITION. Seated on table or mat with legs supported and knees extended

TEST. Point the feet and toes as far as possible (Fig. 3.31). You should observe a relatively straight line along the shin and out onto the foot and toes. Check both sides.

AVERAGE MOTION AVAILABLE. AAOS 50 degrees

GENERAL STRETCH. Foot, ankle, and toe extensors

SPECIFIC STRETCHES. Anterior tibialis, extensor digitorum longus, extensor digitorum brevis, extensor hallucis longus, extensor hallucis brevis

ANKLE EXTENSION (DORSIFLEXION)

TEST POSITION. Lying supine with feet flat against the wall (body perpendicular to the wall)

TEST. Keep the heel in contact with the wall while attempting to pull the balls of feet and toes away from wall (Fig. 3.32). There should be a space of 1–2 inches between the ball of foot and the wall. Bear in mind that this test primarily emphasizes the gastrocnemius, while the alternative test below is more indicative of restrictions in the soleus, the other plantar flexors, and/or the ankle joint itself. Test both sides.

AVERAGE MOTION AVAILABLE. AAOS 20 degrees

ALTERNATIVE TEST. Stand facing a wall with the toes roughly 2–3 inches from the wall. Attempt to bend the knees and touch them to the wall while keeping the heels on the floor. If the knee(s) touch, move backward in increments of about half an inch until the point at which the knees can no longer touch the wall. At the last point in which the knee(s) can still touch the wall, the distance between the toes and the wall should be about 3 inches. An inability to touch the wall is a significant restriction, especially if occurring unilaterally (on one side only). As this alternative test is performed in full weight bearing, there may be considerably more than the 20 degrees of dorsiflexion suggested above.

GENERAL STRETCH. Foot, ankle, and toe flexors

SPECIFIC STRETCHES. Gastrocnemius, soleus, peroneus longus, peroneus brevis, posterior tibialis, flexor digitorum longus, flexor hallucis longus



FIGURE 3.31 Test of ankle plantarflexion

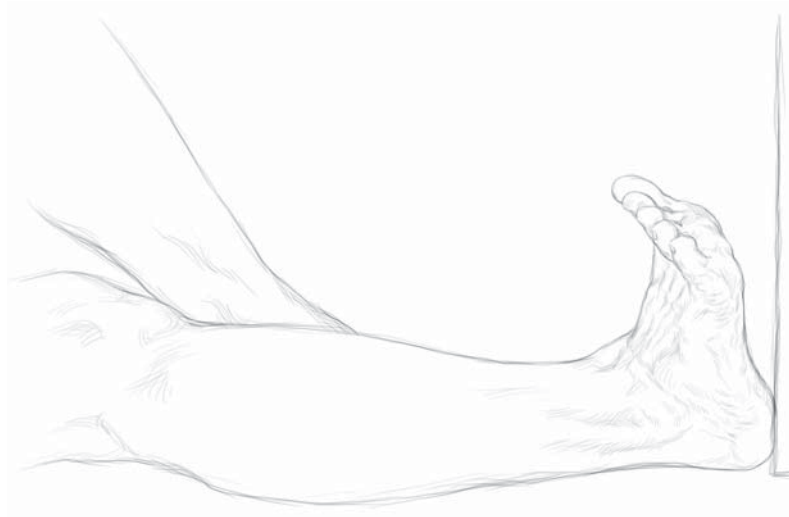


FIGURE 3.32 Test of ankle dorsiflexion

TOE FLEXION

TEST POSITION. Seated with right leg crossed over left knee

TEST. Place the left hand across the dorsum of the right foot and gently pull all of the toes toward the body (Fig. 3.33). The toes (proximal phalanges) should form a roughly 45-degree angle with the plane of the dorsal surface of the foot. Test both feet.

AVERAGE MOTION AVAILABLE. AAOS 40 degrees (45 degrees at great toe).³ Notice that these measurements are for the metatarsophalangeal (MTP) joints.

GENERAL STRETCH. Toe extensors

SPECIFIC STRETCHES. Extensor digitorum longus, extensor digitorum brevis, extensor hallucis longus, extensor hallucis brevis

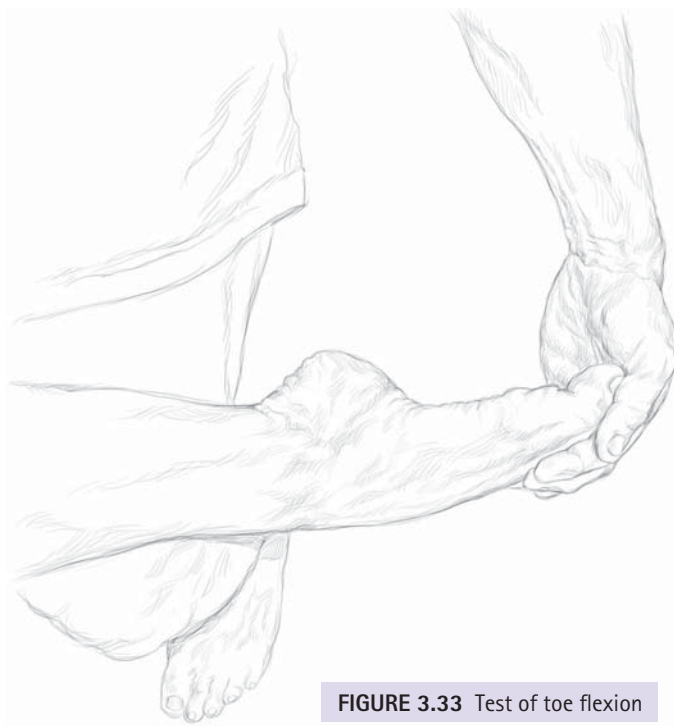


FIGURE 3.33 Test of toe flexion

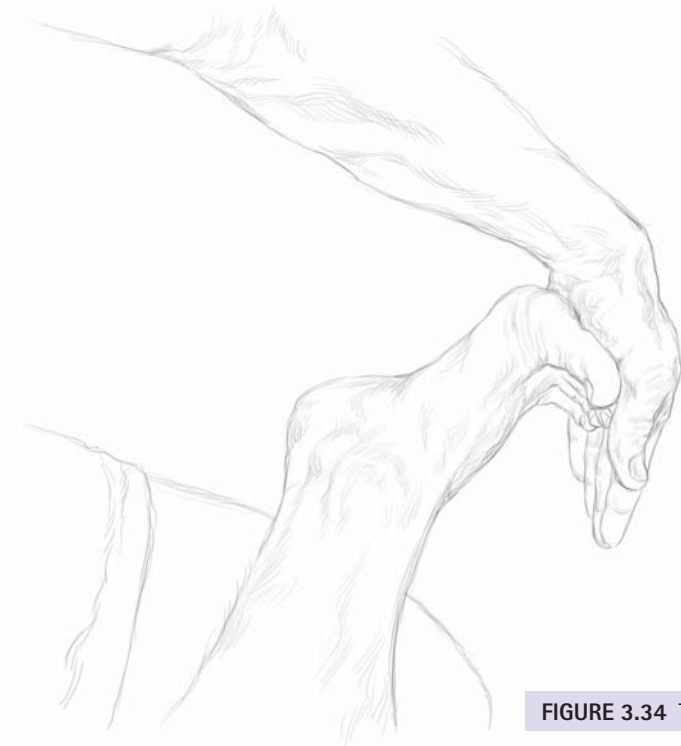


FIGURE 3.34 Test of toe extension

TOE EXTENSION

TEST POSITION. Seated, with test foot resting across opposite knee

TEST. Place the opposite left hand against the plantar surface of the right foot, so that the toes rest against the palm of the hand (Fig. 3.34). Use the palm of the left hand to push the toes into extension (toward the shin). The toes should form at least a 90-degree angle with the dorsum of the foot at the metatarsal-phalangeal joints. Test both feet.

AVERAGE MOTION AVAILABLE. AAOS 40 degrees (70 degrees at great toe) (Norkin and White, *Measurement of Joint Range of Motion*, 1st edition)

GENERAL STRETCH. Toe flexors

SPECIFIC STRETCHES. Flexor digitorum longus, flexor digitorum brevis, flexor hallucis longus, flexor hallucis brevis

SUMMARY

To develop the safest and most effective stretching program, it is necessary to be able to assess the individual's flexibility and ROM. Comparing the individual's ROM with accepted norms allows us to determine flexibility goals and focus on appropriate exercises. This chapter should help the clinician and/or the individual to quickly assess if motion is within normal limits for most useful movement patterns.

REFERENCES

1. Norkin CC, White DJ. *Measurement of Joint Motion: A Guide to Goniometry*. 3rd Ed. Philadelphia: FA Davis Company, 2003.
2. Kapandji IA. *The Physiology of the Joints*, vol 3, The Trunk and the Vertebral Column. Churchill Livingstone, 1974.

3. Norkin CC, White DJ. *Measurement of Joint Motion: A Guide to Goniometry*. 1st Ed. Philadelphia: FA Davis Company, 1985.

SUGGESTED READING

1. Palmer ML, Epler ME. *Fundamentals of Musculoskeletal Assessment Techniques*. 2nd Ed. Baltimore: Lippincott Williams and Wilkins, 1998.
2. Kendall FP, McCreary EK, Provance PG, et al. *Muscles Testing and Function with Posture and Pain*. 5th Ed. Baltimore Lippincott Williams and Wilkins, 2005.
3. Youdas YW, Garrett TR, Suman VJ, et al. Normal range of motion of the cervical spine: an initial goniometric study. *Phys Ther* 1992;72:770-780.

