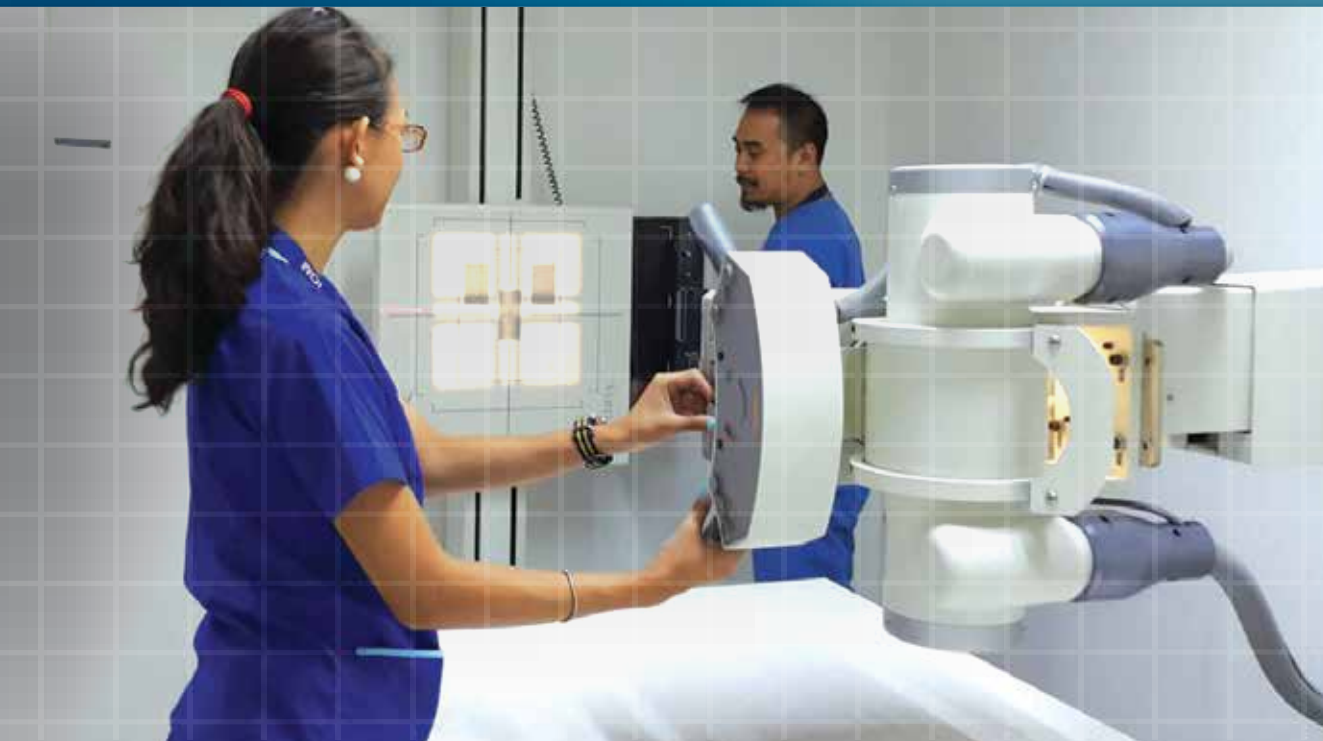

FIRST EDITION 2015

Screening Chest X-Ray Interpretations and Radiographic Techniques



IOM GUIDELINES



International Organization for Migration (IOM)

The opinions expressed in the report are those of the authors and do not necessarily reflect the views of the International Organization for Migration (IOM). The designations employed and the presentation of material throughout the report do not imply the expression of any opinion whatsoever on the part of IOM concerning the legal status of any country, territory, city or area, or of its authorities, or concerning its frontiers or boundaries.

IOM is committed to the principle that humane and orderly migration benefits migrants and society. As an intergovernmental organization, IOM acts with its partners in the international community to: assist in meeting the operational challenges of migration; advance understanding of migration issues; encourage social and economic development through migration; and uphold the human dignity and well-being of migrants.

Author Sifrash Meseret GELAW, MD
Radiologist, MPH; Global Radiology Coordinator
IOM, Manila Administrative Centre, Manila, Philippines

Major Contributor Anthony MACDERMOTT, MD
former Global HAP Quality Coordinator,
IOM, Regional Office for Asia and the Pacific, Bangkok, Thailand

Additional Contributors

Alexander KLOSOVSKY, MD, MPH
Migration Health Advisor
IOM, Washington, D.C., USA

Tesfa Semagne EGZERTEGEGNE, MD
Radiologist
IOM Kuala Lumpur, Malaysia

Reviewer Mary NAUGHTON, MD, Radiologist, MPH
Centers for Disease Control and Prevention (CDC)
Division of Global Migration and Quarantine (DGMQ) Atlanta, Georgia, USA

Publisher Global Radiology Coordination and Teleradiology Centre
Migration Health Division
International Organization for Migration (Manila Administrative Centre)
24th floor Citibank Tower, Paseo De Roxas 8741, Makati city 1226
Metro Manila, Philippines
Email: sgelaw@iom.int, teleradiology@iom.int
Tel: +632 230 1674

© 2015 International Organization for Migration (IOM)

All chest X-ray images in this guideline are images of refugees or immigrants for which Health Assessment was done under IOM. These images were saved with anonymous biodata for IOM radiology collection and teaching purposes.

All rights reserved. No part of this publication may be reproduced, stored in a retrieval system, or transmitted in any form or by any means, electronic, mechanical, photocopying, recording, or otherwise without the prior written permission of the publisher.

FIRST EDITION 2015

Screening Chest X-Ray Interpretations and Radiographic Techniques



IOM GUIDELINES



International Organization for Migration (IOM)

ACKNOWLEDGEMENTS

The authors would like to thank Dr Davide Mosca, Director of Migration Health Division (MHD), for initiating and ensuring the timely release of the Guideline, and Dr Goran Grujovic, MHD Global Health Coordinator, for his continued support.

The authors send their deepest gratitude to the governments of resettlement countries and other partners who shared their high interest, support and technical instructions, without which the radiology practice highlighted in this guideline could not have been employed.

The authors would also like to thank all refugees and immigrants who had their health assessment done at IOM, and whose chest X-rays (CXR) were included in the guideline with anonymous biodata. The authors also extend their gratitude to IOM field operations, especially IOM Nepal, from which most of the images were collected and IOM Manila Health Centre, for cooperating on taking pictures of CXR positioning.

Special thanks also goes to the IOM Manila support staff from ABLE Company, particularly Mr Rafael Fat, who agreed for his pictures to be taken for CXR positioning.

Our gratitude is extended to the Publications Team for assisting in the editing and layout of this publication, and to Ms Janice Lopez, Migration Health Assistant, for the first language editing of the guideline. The authors also acknowledge the Communications and Document Management and Intranet Teams for web dissemination and online support.

PREFACE

This guideline is prepared as one of the objectives of the IOM Global Radiology Coordination and Teleradiology Centre aiming to optimize the quality of chest X-ray (CXR) images and reporting, and standardize the approach and terminologies used in health screen programmes. This further helps in delivering a level of diagnostic accuracy and consistency as desired by the stakeholders, as well as allowing quality control (QC) at the global level. This material can be useful for staff members working CXR interpretations, mainly radiologic technologists, panel radiologists and panel physicians participating in health assessment programmes (HAPs).

The Teleradiology Centre was established in June 2012 as part of the Global Migration Health Support in Manila Administrative Centre (MAC). In August 2013, the centre grew to the Global Radiology Centre, led by the Global Radiology Coordinator, and started to be fully operational with the expansion of the capacity in its infrastructure and staff and implementation of different services.

The centre aims to optimize the quality of radiology services in HAPs through different activities including primary CXR reading, teleradiology quality control, confirmatory/second opinion CXR reading, technical guidance on different radiology-related matters (including purchasing of X-ray machines, establishing X-ray units, hiring of radiology staff and outsourcing X-ray services), as well as provide training, prepare guidelines, and participate in radiology-related research.

The centre is currently supporting several IOM field operations on primary CXRs reading using teleradiology systems and global picture archiving and communication system (PACS). It has implemented innovative global teleradiology QC services for US programmes after the necessary preparations, in addition to providing confirmatory CXR readings and different radiological technical support. In coordination with the Resource Management Office-Citizenship and Immigration Canada (RMO-CIC) Manila, the centre has implemented primary CXRs reading to non-IOM CIC panel sites in the Philippines starting in early 2015. Considering the growing demand and expectations, the centre is working on further expanding its capacity in qualified staff, infrastructure and technology, and networking to field locations, and coordinating with concerned units, particularly IOM's Migration Application Unit and Information Technology and Communications in MAC.

The PDF file of the first IOM Guideline on “Screening CXR interpretation and Radiographic Technique” was released in December 2014. This published document is the revised version. The changes made from the first PDF file released include:

- Addition of many new information and explanations;
- Inclusion of New Zealand technical instruction released in March 2015;
- Addition of new CXR images;
- Restructuring of the headings for better flow of information;
- Correction of typing errors; and
- Proper editing of the subject, language and styling.

CONTENTS

Acknowledgements.....	iii
Preface.....	v
List of acronyms and abbreviations	xi
1. Introduction	1
2. Screening chest X-ray requirements and radiographic techniques	3
2.1 Chest X-ray requirements in Immigrant Health Assessment.....	3
2.2 Use of digital radiography	4
2.3 Radiographic techniques	5
2.3.1 Radiology-related counselling	5
2.3.2 Identity checking.....	5
2.3.3 Technical parameters for good quality radiograph.....	6
2.3.4 Radiation safety measures.....	7
2.4 Chest X-ray projections	8
2.4.1 Standard CXR projection.....	8
2.4.2 Additional chest X-ray views and common indications	9
2.5 Image processing.....	15
3. Systematic chest X-ray interpretation approach	17
3.1 Identification of the image	17
3.2 Evaluation of the image quality.....	18
3.2.1 Technically good quality CXR images	18
3.2.2 Effects of poor quality image	18
3.2.3 Technical faults requiring repeat CXR	19
3.3 Systematic review of CXR for detecting abnormalities.....	20
3.4 Describing detected CXR abnormalities	20
3.5 Suggesting radiological generic or specific process explaining the abnormality	22
3.6 Suggesting further imaging modality	23
4. Requirements for proper screening CXR interpretation	25
4.1 Normal CXR radiological anatomy	25
4.2 Chest X-ray abnormalities.....	27
4.2.1 Change in appearance of normally visualized structure	27
4.2.2 Focal abnormal radio-opacity (abnormally white area).....	28
4.3 Special considerations in screening CXR interpretations	35

5. Chest X-ray signs suggestive of pulmonary tuberculosis	37
5.1 Chest X-ray signs suggestive of primary tuberculosis.....	37
5.2 Chest X-ray signs suggestive of post-primary tuberculosis.....	38
5.3 Chest X-ray signs suggestive of tuberculosis in HIV/AIDS patients	39
5.4 Chest X-ray findings suggestive of healing and previous tuberculosis	40
5.5 Misinterpretations of tuberculosis on CXR.....	41
5.5.1 Under-interpretation of tuberculosis on CXR	41
5.5.2 Over-interpretation of tuberculosis on CXR.....	42
6. Country-specific X-ray reporting forms.....	45
6.1 US X-ray reporting form	45
6.2 Australia X-ray reporting form.....	47
6.2.1 Completing the 502 chest X-ray examination part in eMedical for Australia.....	49
6.3 Canada X-ray reporting form	50
6.3.1 Things to remember when using the Canada CXR form	51
6.3.2 Completing 502 chest X-ray examination part in eMedical for Canada	53
6.4 New Zealand CXR reporting form.....	53
6.3.2 Completing the 502 chest X-ray examination part in eMedical for New Zealand	55
6.5 United Kingdom X-ray reporting form.....	55
6.6 IOM X-ray reporting form used for other resettlement countries	56
7. IOM Global Teleradiology quality control framework	57
8. Annexes	59
Annex A: DS-3030/2014 US CXR reporting form, Page 1 of 4	59
Annex B: Screenshot of 502 chest X-ray examination in Australia eMedical website	60
Annex C1: Canada paper-based CXR reporting form, page 5 of IMM 5419 (11-2012)	61
Annex C2: Canada paper-based CXR reporting form, page 6 of IMM 5419 (11-2012)	62
Annex C3: Screenshots of Canada 502 chest X-ray examinations as seen in eMedical website	63
Annex D1: Paper-based New Zealand CXR reporting form, Section C of New Zealand CXR certificate (INZ 1096)	65
Annex D2: Screenshots of New Zealand 502 chest X-ray examinations as seen in eMedical website	66
Annex E1: Screenshots of New Zealand 502 chest X-ray examinations as seen in eMedical website	67

Annex E2: UKTB CXR reporting form as it appears in UKTB global software.....	68
Annex F: IOM CXR reporting form (Form 04MH_X)	69
Annex G: IOM Global Teleradiology quality control workflow framework	70
References	71

LIST OF FIGURES AND TABLE

Fig. 1a: PA CXR position	8
Fig. 1b: PA CXR image	8
Fig. 2a: RT lateral CXR position	9
Fig. 2b: RT lateral CXR image	10
Fig. 3a: Apical lordotic CXR position	10
Fig. 3b: Apical lordotic CXR view.....	11
Fig. 4a: Lordotic CXR position	11
Fig. 4b: Lordotic CXR view.....	11
Fig. 5a: LT lateral decubitus CXR position	12
Fig. 5b: RT lateral decubitus CXR image.....	12
Fig. 6a: RT posterior oblique CXR position	13
Fig. 6b: RT posterior oblique CXR view	13
Fig. 7a: LT posterior oblique CXR position	14
Fig. 7b: LT posterior oblique CXR view.....	14
Fig. 8a: AP supine CXR position	14
Fig. 8b: AP supine CXR image	15
Fig. 9a: PA CXR showing relatively increased density underlying the medial end of the LT clavicle	21
Fig. 9b: Apical view of the same patient clarifies presence of LT apical soft tissue nodule	21
Fig. 10a: PA CXR showing relatively increased density underlying the anterior end of the RT first rib	22
Fig. 10b: Apical view of the same patient, clarifying the presence of RT apical cavitary lesion	22
Fig. 11a: PA CXR showing R T upper lung ill-defined consolidation	28
Fig. 11b: PPA C XR showing RT upper lung, non-homogenous coalescing ill-defined acinar nodular infiltrates.	28
Fig. 12a: PA CXR LT lower lobe collapse.....	29
Fig. 12b: Lateral CXR demonstrate loss of downward vertebral radiolucency	29
Fig. 13a: PA CXR showing ill-defined LT medial upper lung opacity	30
Fig. 13b: Apical view of the same patient showing LT upper lung opacity	30

Fig. 14a: PA CXR showing R T medial apical ill-defined soft tissue nodule	31
Fig. 14b: The apical view of the same case, better demonstrating the RT apical soft tissue density nodule free of the clavicle	31
Fig. 15: PA CXR showing RT upper lung cavity with relatively smooth inner wall outline and surrounding hazy infiltration	31
Fig. 16: PA CXR of another patient with RT medial apical cavitary lesion.....	32
Fig. 17: PA CXR showing LT upper lung linear opacity	32
Fig. 18: PA CXR of another patient with RT apical linear opacity.....	32
Fig. 19: PA CXR showing bilateral generalized reticulonodular interstitial infiltration	33
Fig. 20: PA CXR showing LT lateral and lower lung field homogenous opacity.....	34
Fig. 21: PA CXR of another patient with RT lateral pleural based opacity	34
Fig. 22: PA CXR showing RT mid lung field hazy opacity	34
Fig. 23: PA CXR showing RT extreme apical small pneumothorax	35
Fig. 24: PA CXR showing LT hilar enlargement (adenopathy) and adjacent LT upper lung ill-defined homogenous consolidation, suggestive of Ghon complex secondary to primary tuberculosis	38
Fig. 25: PA CXR showing RT hilar enlargement secondary to lymphadenopathy, suggestive of primary tuberculosis	38
Fig. 26: PA CXR showing bilateral upper lung, non-homogenous ill-defined infiltrations.....	39
Fig. 27: PA CXR showing LT peripheral upper lung, small, ill-defined soft tissue nodule.....	39
Fig. 28: PA CXR showing RT hilar calcified lymph node and RT mid lung field calcified nodule, commonly suggestive of Ranke complex	41
Fig. 29: PA CXR showing bilateral predominantly mid and RT upper lung, irregular linear opacities and calcific nodules more in the RT side, associated with ill-defined haziness in the LT peripheral upper/mid lung	41

LIST OF ACRONYMS AND ABBREVIATIONS

AP	anteroposterior
CDC	Centers for Disease Control and Prevention
CIC	Citizenship and Immigration Canada
CR	computed radiography
CT	computed tomography
CTR	cardiothoracic ratio
CXR	chest X-ray
C6	Cervical vertebral number 6
DICOM	Digital Imaging and Communications in Medicine
DR	digital radiography
HAP	health assessment programme
ID	identification number
IME	Immigrant medical examination
IOM	International Organization for Migration
kVp	peak kilovoltage
LAO	left anterior oblique view
LPO	left posterior oblique view
LT	left (side)
LVH	left ventricular hypertrophy
mAs	milliamperere second
MiMOSA	Migrant Management and Operational Systems Application
MP	megapixel
MTB	Mycobacterium tuberculosis
NZ	(destination country) New Zealand
NZER	abbreviation used for New Zealand reference number
NZHR	type of New Zealand case unique identifier
PA	posteroanterior
PACS	picture archiving and communication system

PDF	portable document format*
PDMS	pre-departure medical screening
QC	quality control
SOP	standard operating procedure
RAO	right anterior oblique view
RPO	right posterior oblique view
RT	right (side)
TB	tuberculosis
TLD	Thermoluminescent dosimeter
TST	Tuberculin skin test
UCI	unique client identifier
UKTBDP	United Kingdom Tuberculosis Detection Programme
UMI	unique medical identifier
UNHCR	United Nations High Commissioner for Refugees

* A file format for electronic copy of text.

I. INTRODUCTION

Plain chest radiography is the mainstay of imaging for screening pulmonary tuberculosis (TB) and monitoring response to TB treatment. Screening chest X-ray (CXR) examination is the primary method of identifying suspected pulmonary TB in Immigrant Health Assessment Programmes (HAP). Approximately, more than 95 per cent of sputum referrals at the International Organization for Migration's (IOM) HAP globally are based on chest X-ray findings. However, CXR interpretation is a challenging task due to different factors, especially in screening CXR, as early, small and subtle CXR findings in apparently normal individuals are highly prevalent.

The main aim of screening CXR in Immigrant HAPs is to correctly detect any CXR findings that can suggest tuberculosis as much as possible, while any abnormal incidental finding on the CXRs that does not suggest TB needs to be reported as well. Under-diagnosis of TB on CXR, risks travel of TB cases undetected, which increases exposure to the public in resettlement countries and creates negative implications on stakeholder relations. Chest X-ray over-diagnosis of TB on CXR, creates unnecessary delay of movement for affected clients and their families, excessive sputum referrals and laboratory demand, as well as unnecessary repeat investigations in follow-up exams, resulting in increased cost and staff resource burden with no benefits. Thus, the need to maximize CXR tuberculosis case detection without unnecessarily delaying movement and increasing cost is paramount.

This guideline will be useful for staff members working in HAPs, mainly panel radiologists, especially for newly assigned radiologists, to refresh their knowledge on chest radiology, consolidate the different resettlement country-specific radiological technical instructions, properly utilize the different country-specific CXR reporting forms and shape the radiologists' expectations on screening CXR approach and the radiological systems used. It helps the radiologic technologists to give emphasis on radiological technical CXR image quality, CXR requirements and radiation protection rules. Furthermore, the guideline assists the panel physicians to acquire knowledge and skills on systematic and standardized approach on chest X-ray review, as well as assessment of technical quality of a CXR, radiological CXR anatomy, abnormal CXR findings and CXR signs suggestive of tuberculosis.

The guideline aims to:

- Optimize the quality of CXR reporting so that diagnostic accuracy is maximized without unnecessary resource burden and delay; and
- Standardize the approach to reporting and the terminologies used.

This document is necessary in: (a) delivering efficient and ethical service to clients; (b) achieving a level of diagnostic accuracy and consistency as desired by the stakeholders; and (c) developing quality control (QC) at a global level. QC is achieved by comparing the measured with the expected, but comparisons cannot be made unless a standardized approach is used by both reporters and reviewers. These standard operating procedures (SOPs) endeavor to describe such a standardized approach.

2. SCREENING CHEST X-RAY REQUIREMENTS AND RADIOGRAPHIC TECHNIQUES

2.1 Chest X-ray requirements in Immigrant Health Assessment

Screening CXR is required as part of Immigrant Health Assessment by all resettlement countries for adults and children of a specified age range. For the United States, the specified age is 15 years and above (CDC, 2009). For all other countries, the specified age is 11 years and above (CIC, 2013; DIBP, 2014; PHE, 2013; INZ, 2015). Chest X-ray is required for all adults with permanent visa applications and in some temporary visa cases. For children under the specified age, CXR is required only in the following cases:

- If clinical indications exist (history of previous tuberculosis, sign/symptom complex of tuberculosis or contact history with tuberculosis patient) (CDC, 2009; CIC, 2013; DIBP, 2014; PHE, 2013).
- For the United States, if tuberculin skin test (TST) or interferon gamma release assay (IGRA) is positive, or if HIV positive (CDC, 2009).
- When CXR is requested by the receiving country (CIC, 2013; DIBP, 2014 INZ, 2015).

For those coming to New Zealand, chest X-ray is not required for children and pregnant women unless otherwise requested (INZ, 2004, 2015). In the US programme, if a case is diagnosed with tuberculosis, contacts to the case, both pediatric and adult, must undergo CXR if their TST results are ≥ 5 mm (CDC, 2009).

For adults, a standard posteroanterior (PA) CXR is required, though additional views can be requested as needed. When CXR is required for children, an anteroposterior (AP) or PA view is obtained, with the AP view usually required until children are old enough to cooperate with positioning. For children less than 10 years old for United States and less than 11 years for United Kingdom programmes, in addition to the PA CXR, a lateral view is also required. The additional lateral view is not a routine requirement for receiving countries other than the United States and United Kingdom but can be considered by the radiologist. In such cases, the additional benefit in comparison to the additional cost and the radiation exposure that this entails need to be considered.

All female applicants of reproductive age need to be asked about the possibility of pregnancy and the date of their last menstrual period. If the woman is pregnant or possibly pregnant, she must be counselled about the risks of radiation to the unborn child and the available options. If she agrees to have a CXR, consent must be signed, and she should be protected by double lead (both front and back) wraparound shielding during the CXR exposure (CDC, 2009; CIC, 2013; DIBP, 2014; PHE, 2013).

2.2 Use of digital radiography

Digital imaging system (digital radiography) for producing Digital Imaging and Communications in Medicine (DICOM) images has become a requirement for most resettlement countries. It is also advisable to use a picture archiving and communication system (PACS) for archiving and retrieving pictures. Since 1 October 2014, the United States requires that all persons who need a chest radiograph in their medical examination screening should be evaluated with digital imaging and that a CD, rather than film, is used for travel and archiving. Australia, Canada, and most recently New Zealand, receive the digital images through eMedical system. Other countries such as the United Kingdom are also in the same line of interest, with plans to receive images through teleradiology system.

Digital imaging system, besides being filmless, has many advantages over the conventional film-based imaging system. Its advantages include:

- Time efficiency, with quicker image retrieval, and images are less likely to get lost;
- Attains consistent and higher image quality, with increased latitude and dynamic range;
- Reduces artifacts related to film and film processing;
- The direct and integrated digital radiography systems avoids manual handling of cassettes;
- Provides easy image archiving, with ability to use digital image archives instead of film library;
- Provides ability to manipulate the digital image (post-process images) on the CR/DR monitor for adjusting some image-quality problems;
- Reduces radiation dose to patients;
- Potentially lower running costs, with time efficiency, and avoids the use of hard films and processing chemicals;
- Allows image viewing at multiple sites, with ability to access the images simultaneously from multiple viewing stations set up in different locations;
- Creates ability of electronic reporting of CXRs;
- Provides easier side-to-side reviewing of CXRs taken at different time and comparison of findings; and

- Digital image and PACS image archiving system also create accessibility for remote networking across countries, such as using teleradiology system for quality control, and remote primary CXR readings support as needed.

2.3 Radiographic techniques

The use of proper radiographic techniques is crucial for producing good quality CXRs. The radiographic techniques should start with correct identification of the individual, followed by counselling and guiding the individual in preparation for the CXR, correct positioning and instruction, and use of correct X-ray parameters and radiation protection measures.

2.3.1 Radiology-related counselling

All applicants required to have CXR should have radiology-related counselling before CXR taking. The counselling includes:

- Briefing on the X-ray procedure and the benefits of cooperation, such as proper body positioning, deep inspiration technique and holding the breath while X-ray is being taken (It is advisable to demonstrate deep inspiration and check with them if they have understood).
- Instruction for changing the clothes and wearing clean X-ray gown, and avoiding metallic objects and necklace around the chest and neck. For females, additional instructions for tying up the hair on the head and removing the bra should be given.
- For clients with hearing problem, the procedure must be demonstrated symbolically and request their relatives to interpret.
- If the radiologist is reading the CXR in real time, the applicants must be advised not to leave the clinic before the X-ray reporting is completed, since additional CXR views may be needed.
- Disabled clients should be given priority; request the relatives to assist in positioning for X-ray as needed, and when assisting, the relatives should be provided with full-sized lead apron for protection.
- Applicants should be asked if they would like to have a chaperone with them.

2.3.2 Identity checking

Checking the applicant's identity with a photo and complete biodata should be the routine procedure and strictly enforced. The valid ID for immigrants is the passport; when the passport is not presented due to valid reason/s, other valid IDs such as national ID or driver's licence, can be used (CIC, 2013). For refugees, an IOM refugee

ID prepared based on the information from the Resettlement Registration Form (RRF) provided by the United Nations High Commissioner for Refugees (UNHCR) is used.

The identification on the CXR should include complete biodata including:

- Full name in English as it appears on the passport or valid document
- Gender
- Date of birth
- Identification number/s
 - Valid ID numbers include: health identifier ID for HAP (HAP ID) (for Australia); immigrant medical examination number (IME) and unique medical identifier (UMI) for upfront medical cases or unique client identifier (UCI) number (for Canada); and Immigration New Zealand reference number (NZER) or the unique medical identifiers (NZHR) (for New Zealand); other ID numbers include IOM individual ID numbers from Migrant Management and Operational Systems Application (MiMOSA) or case numbers for US programme and/or passport number or other valid IDs.
 - If MiMOSA ID is used in the individual ID field in the CR/DR screen, the other IDs need to be written in the other fields, either in accession number field or in the referring physician.
- Date and time of CXR examination
- Place of CXR (name of the X-ray institution), appended by name of location and country
- CXR view/projection and side marker labelling
- For teleradiology service, the two initials of the country of destination (the programme) need to be entered in the referring physician field with forward slash (/) before the initials – written as (/US, /AU, /CA, /UK). This is needed for the automatic selection of the corresponding X-ray reporting form, for sorting options, and for data reporting by programme.
- Gregorian calendar should be used for all dates.

2.3.3 Technical parameters for good quality radiograph

Good radiographic practice aims to result in good quality CXR at the first exposure using standard radiographic techniques, which includes (Whitley et al., 2005):

- Selecting optimum X-ray exposure factors (kVp and mAs) to attain adequate penetration.
- Taking the X-ray during deep inspiration and holding the breath to produce fully inspiratory image.

- Asking the applicant to assume the proper position during CXR taking to avoid rotation and angulations.
- Collimating the X-ray beam to the area of interest only to avoid unnecessary radiation exposure and minimize scatter radiation that reduces image quality.
- Using proper centring (X-ray beam should be centred at T5/T6 vertebral body) to have equal divergence of the X-ray beam for equal magnification effect on both upper and lower chest.
- Using constant detector to X-ray tube distance (6 ft or 180 cm is the standard) to have constant level of image magnification.
- Avoiding all possible artifacts in the image that might cover or be misinterpreted as abnormality.
- Avoid moving or breathing during CXR taking to avoid blurring.
- For smaller children, using immobilization devices is recommended to minimize motion blur.

2.3.4 Radiation safety measures

Taking good quality image at first exposure and reducing unnecessary repeat CXRs are important measures for minimizing radiation exposure in X-ray. Additionally, in order to protect the applicant, the staff and the public from unnecessary radiation, the following universal radiation safety measures should be applied during X-ray taking:

- Use as low as reasonably achievable (ALARA) radiation principle.
- Provide lead apron for all applicants and wraparound double lead (both front and back) for pregnant women.
- Avoid unnecessary repeat exposure.
- If attendants or chaperones are needed, advise them to move to the control room after the positioning is finished; but if their assistance is needed to keep applicants in position during X-ray taking, provide them with lead apron.
- The red light on the front door should be turned on during the time of X-ray.
- Make sure both X-ray room doors are closed during X-ray exposure.
- Radiology unit staff should always wear thermoluminescent dosimeter (TLD) badge and be in a protected room during X-ray exposure, and the TLD should be regularly measured for monitoring the staff radiation dose.
- X-ray rooms should be constructed and checked to make sure that there is no radiation leak to the outside.
- Appropriate radiation warning sign should be displayed in front of the CXR room in a visible place.

2.4 Chest X-ray projections

2.4.1 Standard CXR projection

PA CXR view is the standard CXR view for all adults. It is taken with the patient in upright position facing the cassette, and the patient's chin resting at the middle of the top of the bucky. The feet are placed slightly apart to keep the patient steady. The median sagittal plane is adjusted to the middle of the cassette. The shoulders are rotated forward and in contact with the cassette by placing the dorsal aspect of the hands behind and below the hips, with the elbows brought forward or allowing the arms to encircle the bucky (see Figure 1a) (Whitley et al., 2005; ARRT, 2015). A PA CXR image of a middle-age refugee woman from IOM Damak, Nepal is presented in Figure 1b. The detail of signs of good quality PA image and anatomy is included in quality of image and the radiological anatomy part.



Fig. 1a: PA CXR position: Patient is positioned upright facing the bucky, resting the chin at the centre, the arms rotated with the elbows touching the bucky and dorsal hands on the hips, and medial sagittal line lying at the middle.

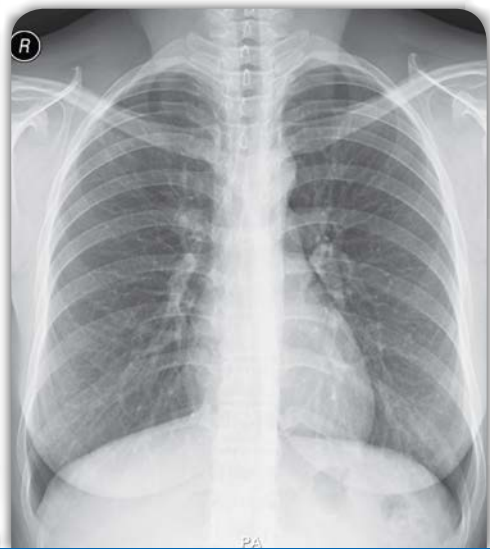


Fig. 1b: PA CXR image showing good quality image, with equidistant clavicles at level of the T4 thoracic vertebra, all the necessary areas of the chest included, the anterior 7 ribs and the posterior 10 ribs are visible above the diaphragm showing good inspiration, and has good penetration with no image blurring. There is subtle abnormal finding – RT upper lung ill-defined hazy infiltrates.

2.4.2 Additional chest X-ray views and common indications

The additional CXR views are mainly needed to confirm or exclude suspicious CXR findings or findings that are not clearly seen in the standard PA views. Repeat or additional views should be requested in such cases:

- The original image was insufficient in quality (usually repeat PA is done in this case).
- Suspected abnormalities cannot be confirmed or excluded on the basis of one view.
- Key areas of the lungs have not been adequately visualized, especially findings in hidden areas.

Due to cost and radiation safety issues, additional views should be requested only if necessary. It is not necessary to request additional views in any of the following cases:

- Minor technical quality faults are present that have not rendered the image uninterpretable and/or are correctable with digital image manipulation.
- A single image has confirmed an abnormality for which additional plain views offer no diagnostic or management advantage.



The additional CXR views and indications are as follows:

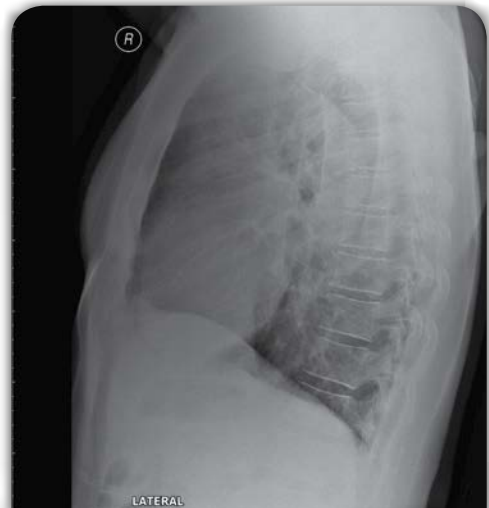(a) Lateral view (left (LT) or right (RT)) with the side of interest positioned closest to the detector during exposure)

The image is labelled according to the side of the body facing the detector/bucky. For example, if the left side is against the detector, the image should be labelled “left lateral” because the left side of the body is near the detector (see Figure 2a) (Whitley et al., 2005; ARRT, 2015).

Fig. 2a: RT lateral CXR position: The RT side is facing the chest bucky and the hands are moved up to avoid covering the areas of the chest.

Indication: Additional imaging of hilar, mediastinum, retrosternal space, retrocardiac space, thoracic cage, anterior and posterior costophrenic recesses, and upper abdomen, hidden areas, for clear visualization of the areas (see Figure 2b). Lateral images are also particularly useful for determining the AP location of findings in relation to other structures, such as the heart, mediastinum or chest wall.

Fig. 2b: RT lateral CXR image showing the structures on the lateral view, anterior and posterior chest walls and the thoracic vertebrae, the RT and LT diaphragms (RT is higher than LT). The heart shadow antero-inferiorly; trachea at the upper central chest and the hilus anterior and posterior to the lower end of the trachea (the carina), the aortic arch above the carina, and the anterior and posterior clear spaces containing air-filled lungs.



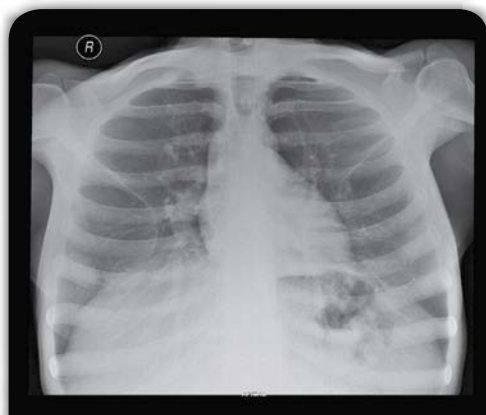
(b) Apical view (or collimated apical lordotic view) This is an angulated view (with an average of 30°) with the patient's upper posterior chest in contact with the chest bucky during exposure (see Figure 3a). This brings the ribs in longitudinal alignment with the X-ray beam and lifts the clavicles above the lungs. It provides unobstructed viewing of the lung apices and if technique and anatomy allow, a clear view between the ribs. The collimation brings the included apical and upper chest anatomy into sharper detail (Whitley et al., 2005).



Fig. 3a: Apical lordotic CXR position: Patient is seating on AP position with the upper posterior chest in contact with the chest bucky.

Indication: Additional imaging of the lung apices, particularly to clearly see the areas hidden on PA view, areas behind the clavicles, first ribs and first costochondral junctions (see Figure 3b).

Fig. 3b: Apical lordotic CXR view clearly showing the apical areas free of the clavicles, clavicles being moved above the lung fields.



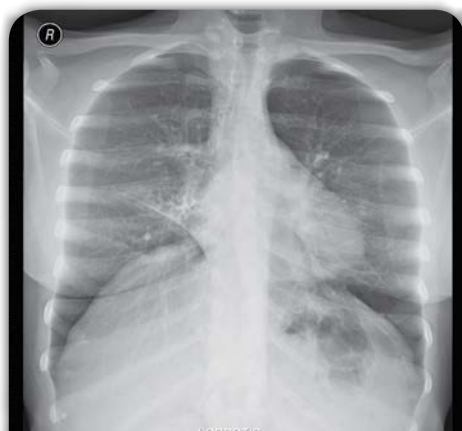
(c) Lordotic view: This is an angulated view, like apical view, taken with the patient's anterior lower chest touching the chest bucky during exposure (see Figure 4a). The degree of angulation varies with every subject depending on the specific area of interest. Generally, the angle is 30–40° (Whitley et al., 2005).



Fig. 4a: Lordotic CXR position: Patient is seating in PA position with anterior lower chest touching the bucky, bringing the middle lobe and lingular segment in close proximity to the detector.

Indication: To view the right middle lobe (see Figure 4b) or the left lingular segment and partly the lower lobes from a different angle. This view is mainly helpful to rule out RT middle lobe or LT lingular segment lesions.

Fig. 4b: Lordotic CXR view demonstrating the RT middle lobe cystic changes, with well-defined lower lateral border marked by the RT major fissure, and partially silhouetted RT heart border, suggestive of RT middle lobe bronchiectasis.



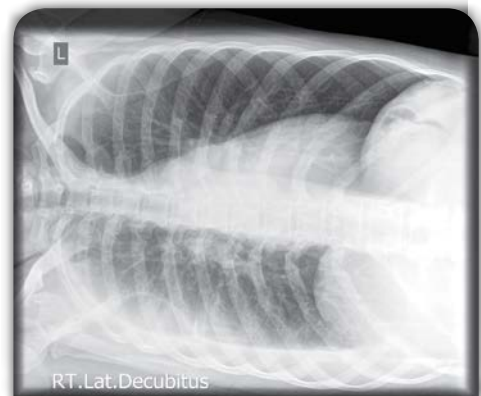
(d) Lateral decubitus view: (decubitus = lying down) This is obtained with the patient lying on one side; hence, right or left lateral decubitus views, labelled according to the side positioned inferiorly (see Figure 5a).

Fig. 5a: LT lateral decubitus CXR position: Patient is lying on the LT side (the side suspected of free pleural effusion).



Indication: Decubitus views are typically used to confirm the presence of free pleural fluid and judge whether sufficient fluid is present to allow thoracocentesis (pleural tap) but can also be used for detecting pneumothorax (for the latter, if PA CXR cannot be taken). The patient should be kept in position for at least 10 minutes to allow the fluid to shift. Free fluid (effusion) (see Figure 5b) or air (pneumothorax) in the pleural cavity will change position with the patient lying on the side from the standing position. To check for effusion, the side lying down in the decubitus position should be the side with the suspected effusion. To check for pneumothorax, the side lying down in the position should be the opposite (the suspected pneumothorax side should be up). Loculated effusion or small effusion cannot be totally ruled out by using only this view, because the loculated effusion will not “layer out” and the small effusion simply may not be visibly lining adjacent to the chest wall (Whitley et al., 2005; Ahmad, 2001; ARRT, 2015).

Fig. 5b: RT lateral decubitus CXR image showing free movement of the pleural fluid to the RT lateral pleural space, suggesting the presence of RT pleural effusion.



(e) Oblique view

There are four types of oblique projections: right anterior oblique (RAO), left anterior oblique (LAO), right posterior oblique (RPO) (see Figure 6a) and left posterior oblique (LPO) (see Figure 7a). Anterior or posterior oblique projections can be rotated either to the right or left depending on the area of interest. Oblique views can be obtained with the patient upright or supine (when patient cannot stand) and the respective side of the chest (right or left) is rotated 45° towards the bucky. Anterior oblique views are more frequently used to see the lungs and mediastinum. Posterior oblique views are mainly used for the ribs and thoracic cage, but can also be done to see areas of the lungs (Whitley et al., 2005; Ahmad, 2001; ARRT, 2015).

Indication: Oblique views are helpful in the following instances: (a) visualizing the lateral lesions near the chest wall or the costophrenic recess on the side of interest; (b) separating lateral pulmonary from the angle of the rib or medially from the mediastinal opacities from structures that overlie on PA and lateral views (Figures 6b and 7b); and (c) further evaluating lesions that are visible on PA but not in lateral view. The use of oblique views has declined since the advent of computed tomography (CT), which is more commonly employed to visualize lesions that cannot be clarified on PA and lateral views. However, plain radiographs employ much less radiation than a CT scan and sometimes obviate the need for the CT (Ahmad, 2001).



Fig. 6a: RT posterior oblique CXR position: The RT posterior side of the chest is rotated to touch the bucky.

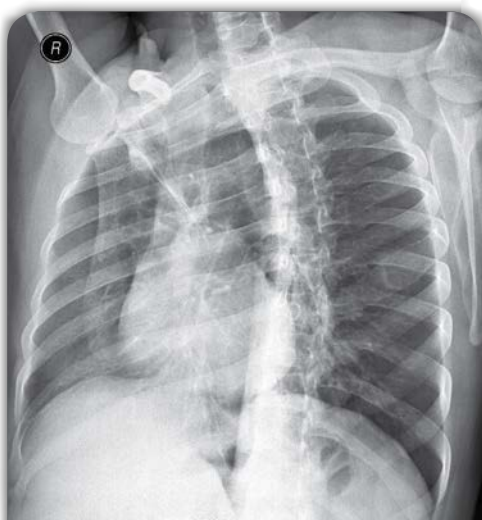


Fig. 6b: RT posterior oblique CXR view demonstrating the LT lung fields away from the lateral chest wall and the mediastinal structures, well visualizing the LT anterior 6th rib focal, expansile lytic bone lesion, which was not well seen on the PA view.



Fig. 7a: LT posterior oblique CXR position: The LT posterior chest wall is touching the bucky.

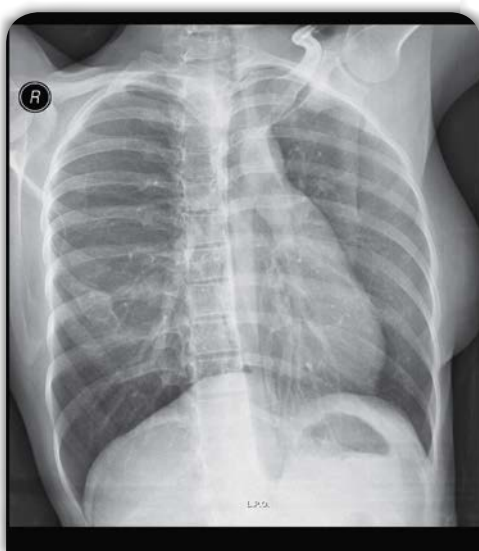


Fig. 7b: LT posterior oblique CXR view demonstrating the RT lung fields free from the lateral chest wall and away from the mediastinal structures, well visualizing the RT anterior 6th rib expansile lytic bone lesion.

(f) Anteroposterior view: The anterior aspect of the chest faces the X-ray beam. This can be taken on sitting or supine position.

Adult or older paediatric sitting or supine view: These are alternate views to the PA-erect CXR. When an adult or older pediatric patient is unable to stand, an AP sitting view is done. When the patient is unable to stand or sit, an AP semi-supine or supine view is taken with the patient lying on the back (see Figure 8a).

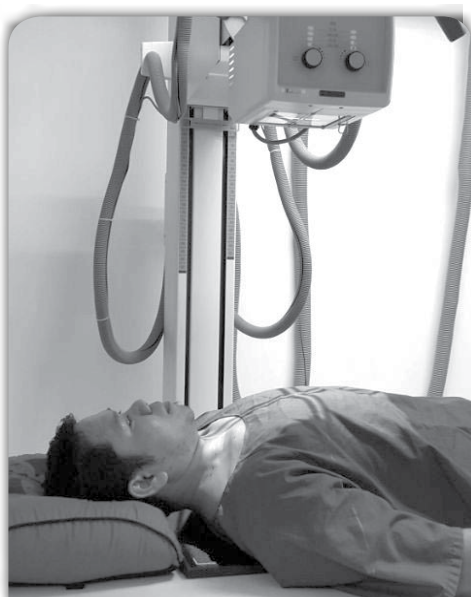

Fig. 8a: AP supine CXR position: The patient is lying on his back on the X-ray table.

(g) Anteroposterior pediatric supine view: In very young children, an AP supine chest view is usually taken unless an immobilization device that supports the child for an upright sitting view is available, or the child is old enough to stand for a PA chest exposure.

Indication: The use of AP views is the same for PA-erect CXRs. In adults, the problem with AP views is that the heart is magnified because its position is farther from the image detector. In supine AP view, the diaphragm is placed upward and the maximum lung dimension is reduced due to the absence of a gravity effect on the abdominal organs (see Figure 8b). For children, magnification is not a significant problem on AP chest views because the entire chest cavity is located close to the detector. However, the breasts receive more radiation in AP than PA views. For females, switching to PA chest views should be made as soon as possible to protect radiosensitive breast tissue.

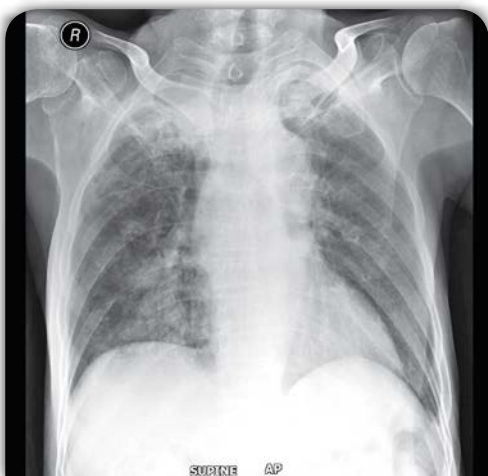


Fig. 8b: AP supine CXR image demonstrating the structures on the AP view and the effects of AP position on image quality including magnified heart and mediastinum, elevated diaphragms and scapulas overlying the lungs. The pertinent abnormal findings are RT upper and medial lower lung ill-defined infiltrations with RT upper lung linear and cystic changes to rule out cavity.

2.5 Image processing

In the digital radiography system, the traditional film-based image processing in the dark room using chemicals is replaced by checking and manipulating the digital images on a computed radiography (CR) or direct digital radiography (DR) system. The radiologic technologist is responsible for properly assigning the images to the individual biodata on the CR/DR screen, checking the quality of the images and manipulating the image for correcting some radiographic technical faults before sending it to the radiologist station or the PACS. The technologist should also be in a position to detect gross technical shortcomings, and do repeat CXR for images that are not acceptable and can not be corrected by image manipulation, before the client leaves the radiology facility. The same image processing should be done for additional views.

3. SYSTEMATIC CHEST X-RAY INTERPRETATION APPROACH

As a standard practice and as required by resettlement countries, a high resolution X-ray viewing monitor (such as EIZO and Barco with 3 MP or more) should be used for digital CXR image viewing and interpretation by radiologists. LCD computer monitor or DR/CR monitor should not be used for CXR image viewing and reporting.

For creating optimal image viewing condition, it is advisable if the room light is dimmed with no light reflections coming from the sides. The monitor's brightness should also be adjusted to most favorable.

Standard CXR interpretation requires systematic approach including the following steps:

- Checking the identification of the image;
- Evaluating the image quality;
- Systematic reviewing of the CXR for abnormalities;
- Detecting and describing the abnormalities;
- Suggesting a generic process, and whenever rarely possible, a specific process that might explain the abnormality; and
- Recommending other further imaging modalities (if needed).

3.1 Identification of the image

Standard CXR reporting technique should commence with checking the complete identification of the person. The CXR should contain all the complete biodata as mentioned above. This step is important to check if the image viewed is the right image corresponding to the same person. Comparing the age and gender of the person with the respective related findings on CXR are important in checking the correctness of the image. The radiologist also needs to check the biodata on the CXR if it matches the biodata on the reporting forms. When a series of previous CXRs are present, all the CXRs must be checked for completeness and correctness of the same biodata of the person.

3.2 Evaluation of the image quality

Review of image quality follows identification check. The radiologist is responsible for the final review of the image quality before starting the image reporting. The radiologist can review more indicators of image quality that can affect the quality of the reporting, which might not have been identified by the radiologic technologist. The radiologist should request for repeat CXR if the quality is not acceptable. Additionally, the radiologist should oversee the radiography practice and provide constant feedback to the technologist on optimizing the image quality.

3.2.1 Technically good quality CXR images

The parameters of technically good quality image include:

- **Properly collimated (Include all areas of interest):** the area from the C6 cervical vertebra to the upper abdomen with both costophrenic angles and the soft tissue chest wall on both sides should be clearly visible.
- **Well penetrated (Correctly exposed):** The vertebrae with intervertebral disc spaces are just visible behind the heart, and branching vessels should be visible through the heart's shadow.
- **Properly positioned (Not rotated or angulated):** The medial ends of the clavicles should be equidistant from the spinous process at the level of T4/T5 thoracic vertebra and not obscuring the apices. In the normal image, the mediastinum and heart should be centrally located and sharply defined.
- **Full (Deep) inspiration:** The diaphragm should be visible below the level of the 9th to 11th ribs posteriorly or the 6th to 7th anterior ribs.
- **No blurring:** Fine demarcation of the diaphragm, the borders of the heart and the lung vessels (especially those in the lower lung).
- **Scapula away from the lungs:** On the PA view, ideally, the scapula should be away from the lungs, but overlying only on one fifth of the periphery of the lungs can be acceptable if it is not covering any suspicious abnormality.
- No artifact overlying the lungs.

3.2.2 Effects of poor quality image

- **Exposure:** Problems in exposure can be either overexposure or underexposure. Overexposure risks underdiagnosis, while underexposure risks both under- and overdiagnosis. In an overexposed image, the lungs will be darker, and faint infiltrates or soft tissue lesions can be easily missed. In an underexposed image, structures will appear too white (soft image) and normal soft tissue structures can be misdiagnosed as pulmonary infiltrates increasing the risk of

overdiagnosis. In addition, normal structures such as the heart can obscure infiltrates or lesions in an underexposed image. Exposure is less of a problem in digital imaging; one reason is the equipment has image correction options, and the other is minor exposure problems of digital images can be corrected with image manipulation during image viewing. The quality of laser-printed images can also be affected by incorrectly calibrated X-ray printer. Major exposure issues that cannot be totally corrected require repeat X-ray whether the image is digital or printed.

- **Position:** Patient rotation distorts anatomical appearance, especially of the central structures (heart, mediastinum and hila), causing artificial apparent mediastinal widening, cardiac enlargement and hilar size discrepancy. Unilateral radiolucency with contralateral opacification due to rotation can also be misinterpreted as unilateral hazy infiltrates of the lungs.
- **Inspiration:** Poor inspiratory effort is more likely in overweight persons, those with restrictive lung disease, and due to failure to take deep breath, when the person didn't understand the technologist's instructions to take a deep breath due to language or other barriers and/or when the technologist didn't wait and watch through the lead window until the person took a deep breath and held it before taking the X-ray. Poor inspiratory effort produces crowding of the lung bases (which may be misinterpreted as consolidation) and/or atelectasis (which may be misinterpreted as fibrosis). Cardiac and/or hilar enlargement may also be apparent due to compression of these structures during expiration compared to an image obtained in full inspiration.
- **Others:** Scapulae excessively overlying the lung fields, the presence of artifacts or blurring of the lungs (motion artifact) may also obscure proper viewing of the lung fields or be misinterpreted as abnormalities.

If the quality of the image is unacceptable, and the technologist has not already performed a repeat and improved view, the radiologist should request a repeat CXR.

3.2.3 Technical faults requiring repeat CXR

Repeat good quality CXR is required in the following cases:

- Both lungs are not completely visualized (for example, when apices or costophrenic angles are cut off).
- Artifacts obscuring any part of the lungs.
- Over- or underexposure that is not within the range of automatic correction, rendering an unreadable image.
- Patient malpositioning (rotation) is unacceptable.
- Expiratory image (Deep inspiration is not taken).
- If the scapulae are excessively overlying the lungs.

- Blurred images due to breathing or physical movement (motion artifact) or loss of contact of the body with the bucky.

If the image quality is acceptable, the CXR can then be reviewed for possible abnormalities.

3.3 Systematic review of CXR for detecting abnormalities

Chest X-ray viewing needs consistent and systematic technique, allowing adequate time for each image. A systematic review examines all parts of the image in an orderly manner and aims to detect all possible abnormal findings on the CXR.

There is no one best standard approach, but the commonly used method is step-by-step review of the CXR, either by starting from the periphery of the chest and gradually going to the centre or starting from the central structures and going to the periphery. When viewing from the periphery to the centre, the extrapulmonary features can be evaluated first in systematic fashion, viewing the soft tissue and bony chest wall starting from one corner of the image and working around the full circle before viewing the ribs overlying the lungs, spine, diaphragms and costophrenic angles, and then the mediastinum and heart, and finally the lungs. When viewing the lungs, a similar approach can be adopted, starting at the apex or base. Always compare each region (upper, mid and lower) of the lungs from side to side. The process is continued until all areas of the image have been systematically viewed.

Additionally, hidden areas – such as apical areas underlying the clavicles, perihilar and paratracheal regions, retrocardiac and infra-diaphragmatic areas – need to be carefully examined. However, the order in which areas of the image are viewed is less important than the need to do this in a complete and consistent manner. This is especially important in images with obvious abnormalities that may catch the eye and that may prevent other more subtle abnormalities from being noticed unless the entire image is methodically evaluated.

Remember, subtle lesion might be more significant than the obvious eye-catching lesion. Ill-defined and soft tissue lesions are likely to be active TB than calcified and well-defined and visible abnormality.

3.4 Describing detected CXR abnormalities

The description of the CXR finding should include the complete characterization of the abnormal CXR finding, including size, density, location/distribution, homogeneity, number (solitary or multiple), the type of abnormality/abnormalities,

marginal clarity and contour, associated abnormality, and presence of satellite lesion and/or radiological signs of volume change. In case of cavity, wall thickness and outline and presence or absence of internal content should be described.

Every abnormality should be well characterized as much as possible. Words such as *opacity* or *density* should never be used as stand-alone terms without further characterization as these are otherwise meaningless. *Opacity* thus refers to focally increased density of any radio-opaque abnormality. When describing a lesion, it is not acceptable to simply report “opacity left upper lung”. It is, however, acceptable to define the features of opacity or opacities, for instance, “Left upper lung dense linear and nodular opacities with well-defined margins”.

Appropriate characterization of the abnormality is important for understanding the type of lesion and suggesting further radiological generic – and if possible – specific process. For example, ill-defined, soft tissue density and irregular abnormalities suggest active lesions than well-defined, dense or calcified abnormalities.

If a possible abnormality (suspicious abnormal finding) is not clearly visualized on the PA view (Figure 9a), an additional view and/or repeat PA may be required to confirm (Figure 9b) or exclude the lesion prior to finalizing the CXR report. This will help minimize the number of over- and underdiagnosis. If a detected suspicious abnormality cannot be confirmed or excluded by additional views and persists as suspicious, it is acceptable to report it as an abnormality and appropriately classify the finding. In such cases, it is preferable that the report indicate the attempt made to clarify the suspicious finding through additional view/s.

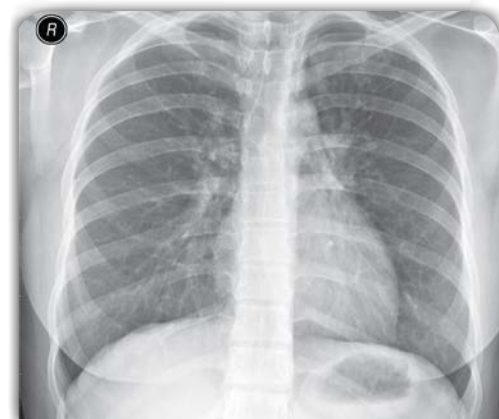


Fig. 9a: PA CXR showing relatively increased density underlying the medial end of the LT clavicle with surrounding slight haziness, indicating suspicious LT apical lung lesion.

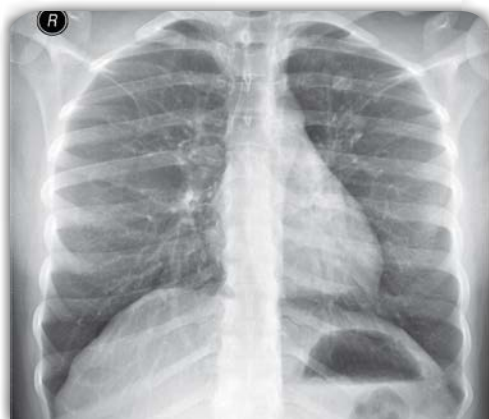


Fig. 9b: Apical view of the same patient clarifies presence of LT apical soft tissue nodule with surrounding hazy infiltrates and linear streaks.

As the presence of cavitation has an impact on tuberculosis management, it is important to additionally look for presence of cavity even in the presence of other findings suggestive of TB. If extensive infiltrates are visualized on the initial PA view, an additional CXR view may be required to further clarify the presence or absence of cavitations. In the presence of extensive lesion, it might be difficult to differentiate fibrocystic or focal bronchiectatic changes from cavity. If the suspicion remains in such cases, it is better to report cavity as a differential diagnosis and mark the corresponding checkbox in the reporting forms. Figures 10a and 10b demonstrate suspicion and confirmation of cavitary lesion in a laboratory-confirmed tuberculosis case.

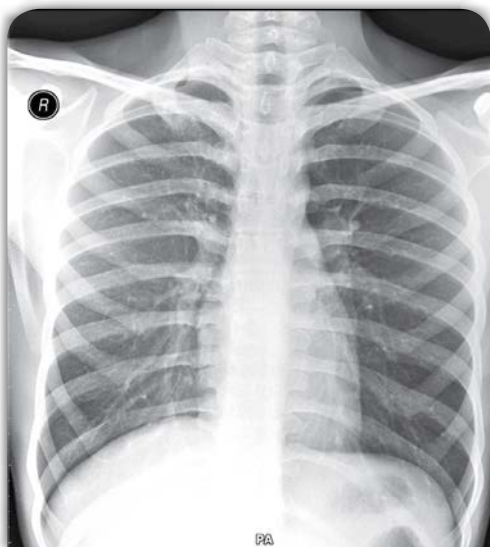

Fig. 10a: PA CXR showing relatively increased density underlying the anterior end of the RT first rib and adjacent slight haziness, indicating suspicion of underlying lung lesion.

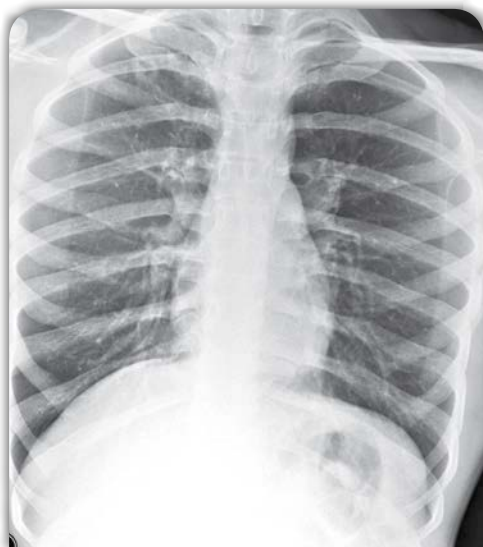


Fig. 10b: Apical view of the same patient, clarifying the presence of RT apical cavitary lesion that was hidden by the RT first rib and clavicle on PA view.

3.5 Suggesting radiological generic or specific process explaining the abnormality

Once the radiological appearance has been described, it is helpful to specify the radiological abnormal process that might explain the abnormal CXR appearance. For instance, a radiological description “RT upper lung homogenous opacity with ill-defined margins, air bronchograms and areas of linear opacity silhouetting the RT hilum” may suggest a radiological abnormal process of consolidation. Other types of common radiological abnormal processes include nodules, cavity, fibrotic lines,

interstitial/alveolar infiltrates, pleural thickening/effusion (see 4.2: Chest X-ray abnormalities).

After the abnormal radiological process, the next step is suggesting the possible differential diagnosis, or if possible, specific diagnosis explaining the process. The probability of suggesting the process in relation to possible causes can also be mentioned. For instance, the possible differential diagnosis for the consolidation described above may be stated as “suggestive of pneumonia to rule out tuberculosis”.

For non-significant findings (such as solitary calcifications or diaphragmatic tenting), although these may have possible differential diagnosis, it is not necessary to indicate additional comment. It is only recommended to suggest an explanation for findings where an association exists between those findings and a significant/worrisome condition/s.

If the abnormality suggests tuberculosis but can also be caused by other pathologies, such as lung carcinoma, both differential diagnoses should be documented and classified accordingly in the CXR reporting form, under both Findings Suggestive of Tuberculosis and Other Findings which Needs Follow-up.

Remember, a radiological process can suggest a diagnosis but doesn't usually confirm it. Plain X-rays are not usually definitively diagnostic, even though there are some conditions where radiographic appearances can be characteristic and highly suggestive. The disease process suggested by the CXR needs to be confirmed by other confirmatory examinations. For example, sputum smears and culture examinations are confirmatory examinations in tuberculosis cases.

3.6 Suggesting further imaging modality

When the CXR abnormality is suspected to be caused by other differential diagnosis with a clinical significance other than TB, recommending further imaging modality such as CT scan of the chest to further characterize the lesion can assist in narrowing the differential diagnosis or even possibly reach final diagnosis. Although the radiologist may suggest the need for further imaging, the final decision to refer the case for the procedure will be done by the panel physician, based on the requirements of the resettlement country and responses to consultations.

When mass lesion or carcinomas are suspected, CT scan is the commonly recommended imaging modality. For instance, a report that identified a soft tissue, ill-defined mass lesion and suggests carcinoma as a possible explanation of the process might add that “CT scan is recommended to further clarify the nature of the lesion”.

Other commonly used imaging modalities are: (a) ultrasound of the chest, for further examining suspected cystic lesion or rule out loculated pleural effusion; and (b) echocardiography for suspected cardiac lesion. In cases when pneumonia is suspected, recommending follow-up CXR after full antibiotic treatment may help in confirming the retrospective diagnosis.

But as previously mentioned, such findings where tuberculosis is a differential diagnosis should be classified both under tuberculosis and non-tuberculosis subcategories in the CXR report forms, and the recommendation for further imaging should not deter the required tuberculosis evaluation.

Further imaging modality should not be recommended without additional diagnostic benefit. If the CXR can give the full information of the abnormality and allow suggesting TB or non-TB process, there is no need to recommend further imaging. Likewise, if the finding is not of clinical significance, further imaging is not needed.

In hospital and clinical practice, radiologists can suggest for sputum collection or correlating the CXR tuberculosis findings with clinical presentation. However, in screening health assessment setting, this is largely dictated by the receiving country's technical instructions and accompanying forms, and as the clients are mostly apparently healthy, clinical presentation doesn't usually help. Thus, it is not necessary to make such suggestions as part of X-ray reporting. The degree of concern for active tuberculosis on the CXR should be conveyed by properly describing the CXR finding and classifying it in the reporting form.

4. REQUIREMENTS FOR PROPER SCREENING CXR INTERPRETATION

Screening CXR interpretation, in addition to the need for systematic approach, additionally requires knowledge and skill of the interpreter on the following:

- a. Knowledge on CXR radiological anatomy and normal variants
- b. Knowledge on radiological CXR abnormalities
- c. Special considerations in screening CXR interpretations
- d. Detailed knowledge on radiological signs of tuberculosis
- e. Understanding of CXR findings that can be misinterpreted
- f. Proper utilization of the different country-specific CXR reporting forms

4.1 Normal CXR radiological anatomy

Understanding of the normal radiological anatomy is important to easily identify the abnormal changes and proper description of the findings. The normal CXR radiological anatomical findings are summarized in the table below (Brant, 2007; Adam et al., 2008; Sutton, 2003).

Table 1: Summary of normal CXR radiological anatomy

Anatomy	Description
General observation	<ul style="list-style-type: none">• Symmetrical lung transradiancy on both sides (radiolucency) on PA view.• On lateral view, upper retrosternal and lower retrocardiac areas are transradiant, and vertebral radiolucency increases downward.
Soft tissue	<ul style="list-style-type: none">• Breast shadows, chest wall soft tissue and axillary folds seen equal on each side.• Areas of normal expected increased opacity are breasts, nipples and axillary folds.• Also, lower neck and upper abdomen should be checked.• No calcification or focal mass should be seen.

Bones	<ul style="list-style-type: none"> • Ribs, clavicles, scapulae, spine and sternum edges should be smooth and continuous with equal opacification on both sides and no focal lesion. • Normal variants include rib fusions, forked ribs, rib hypoplasia, cervical ribs and focally bifid spinous process.
Hemidiaphragms and upper abdomen	<ul style="list-style-type: none"> • Acute and sharp costophrenic angles and variable cardiophrenic angles due to fat pads. • RT hemidiaphragm higher than the LT. • Both diaphragms appear dome shaped with smooth and defined upper margin. • Normal variations include dromedary hump, lobulation and scalloping. • Curvature height: if <1.5 cm, shows diaphragmatic flattening. • On lateral view, RT hemidiaphragms are seen higher than the LT, LT silhouetted anteriorly by the heart, RT passes through the heart to anterior chest wall, and gastric fundal gas lies under LT hemidiaphragm.
Trachea	<ul style="list-style-type: none"> • Appears dark due to intraluminal air. • Upper part is central. • Inferiorly, it deviates slightly to the RT in adults because of aorta. • Division into RT and LT main bronchi (carina) is usually seen and should be free of filling defects.
Mediastinum	<ul style="list-style-type: none"> • Central • Sharp silhouette along most borders. • Sometimes ill-defined in cardiophrenic recesses due to fat pads, near apices and near RT hilum. • Mediastinum should be examined for abnormality of shape, position and interfaces.
Heart	<ul style="list-style-type: none"> • Positioned one third on the RT side and two thirds on the LT. • Smooth contour with marginal clarity and uniform density. • Normal cardiac size for adults is cardiothoracic ratio (CTR) <50% and can reach up to 60% for children. • The technical instructions for Australia and Canada suggest diagnosis of cardiomegaly in adults if CTR >60%.
Hila	<ul style="list-style-type: none"> • Made up of pulmonary arteries, veins and lymph nodes (on CXR, the hilar density is contributed by the vessels), normal lymph nodes are not visible. • Normally, both hila are of equal density and approximately same size. • Each has a Y shape. • RT hilum is lower than the LT by <1.5 cm.

Fissures	<ul style="list-style-type: none"> • Normal fissures are of hairline thickness. • Normal major (oblique) fissures are seen on lateral views only. • RT oblique fissure is less vertical and ends more anteriorly than the LT. • Minor fissure is seen on both PA and lateral views. • On frontal CXR, the minor fissure extends from the RT hilum to the RT lateral chest wall. • On lateral view, the minor fissure extends forward from the hilum to the posterior aspect of the sternum. • Check the fissures for position (displacement), configuration and thickness. Abnormal positioning may reflect partial collapse or consolidation. • Accessory fissures can sometimes be seen; the most common are azygous, LT minor fissure, superior accessory fissure and inferior accessory fissures. • Azygous fissure is relatively easy to diagnose, but in case of other accessory fissures, the possibility of linear opacity due to fibrosis should be considered.
Lung parenchyma and vascularity	<ul style="list-style-type: none"> • Structures normally visible in the lung on radiographs are vessels, fissures and end-on central airways (seen as thin wall ring). • The air-filled alveoli of the lungs appear dark. Vessels are clearly outlined, radiating from the hila to near lung periphery and they disappear in the peripheral 1–2 cm of lungs. Vessels going directly away from and into the X-ray beam appear as a point and called end-on vessels, and may be confused with soft tissue lung nodules. • On erect CXR, the upper lobe vessels are smaller than the lower lobe vessels.

4.2 Chest X-ray abnormalities

The expected types of CXR abnormalities on radiographs can be categorized into three (Adam, et al., 2008; Brant and Helms, 2007; Sutton, 2003):

- a. Change in appearance of normally visualized structure;
- b. Focal abnormal radio-opacity (abnormally white area), a commonly seen abnormality; and
- c. Increased radiolucency (darker area).

4.2.1 Change in appearance of normally visualized structure

Checking for changes in appearance of normally visualized structure requires looking for changes in normal anatomical structures as described above.

4.2.2 Focal abnormal radio-opacity (abnormally white area)

Radio-opacities are more common and significant compared to increased radiolucency. Abnormal radio-opacities can be caused by many different pathologies and present with different patterns.

Consolidation: This is caused by replacement of the air in distal airways and the alveoli by fluid or soft tissues. Radiologically, this is seen as opacity of any size and mostly homogenous; if non-homogenous, it has no volume loss, has the tendency to coalesce, has ill-defined margins, non-segmental distribution, irregular shape, air bronchogram (outline of air-filled distal airways seen as dark branching lines through the opacified lung), silhouettes (loss of normal lung/soft tissue interface) and adjacent structures (see Figure 11a); early lesion can present itself as coalescing acinar nodular infiltrates (see Figure 11b) or ground glass opacities. Typical consolidation is commonly caused by bacterial pneumonia but can also be found in pulmonary tuberculosis; for the latter, it is usually non-homogenous and associated with other findings.

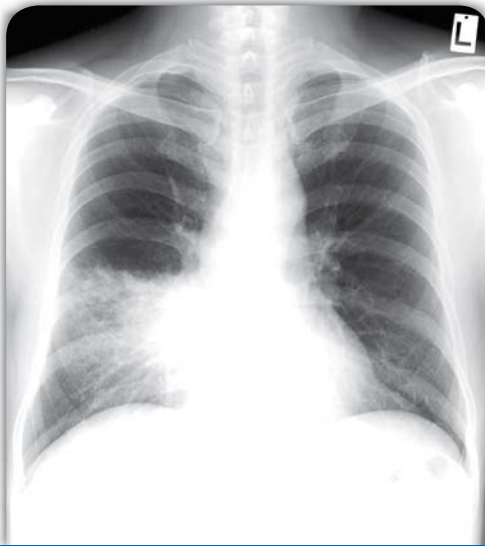

Fig. 11a: PA CXR showing RT upper lung ill-defined consolidation with air bronchogram, silhouetting the RT perihilar and cardiac border.

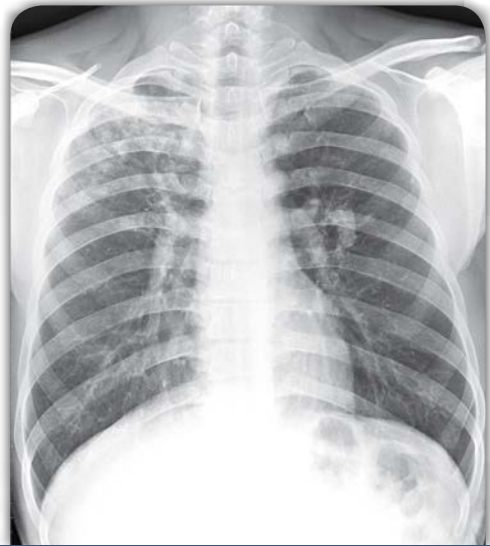


Fig. 11b: PA CXR showing RT upper lung, non-homogenous coalescing ill-defined acinar nodular infiltrates with some linear opacities, crowding of vessels and retracted RT hilum.

Collapse (atelectasis): This may affect the whole hemi-lung or sub-division of the lungs, such as the lobes (see Figures 12 and 13), segments or subsegments of the lung. Radiologically, it causes opacity and signs of volume loss (see Figures 12a and 13a). There are direct and indirect signs of volume loss. The direct signs are shift of fissures, increased opacity and crowding of vessels and airways. The indirect signs include displacement of structures towards the collapsed lung, such as mediastinal shift, elevated diaphragm, hilar shift and distortion, compensatory hyperinflation, rib crowding and shift of other structures. Tuberculosis is a common cause of collapse consolidation.

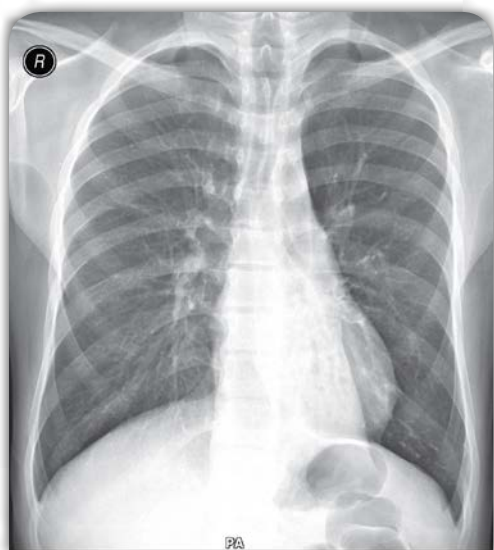


Fig. 12a: PA CXR LT lower lobe collapse seen as triangular LT retrocardiac opacity with defined lateral border.

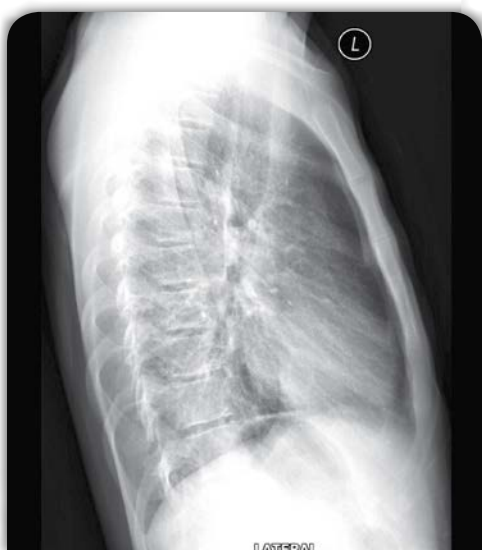


Fig. 12b: Lateral CXR demonstrate loss of downward vertebral radiolucency suggesting overlying lung opacity supporting LT lower lung collapse seen on the PA.

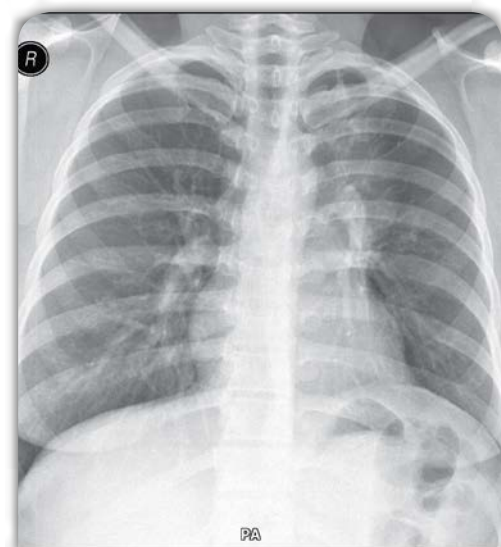


Fig. 13a: PA CXR showing ill-defined LT medial upper lung opacity with upward retracted LT hilum and hilum overlay sign suggestive of LT upper lobe collapse.

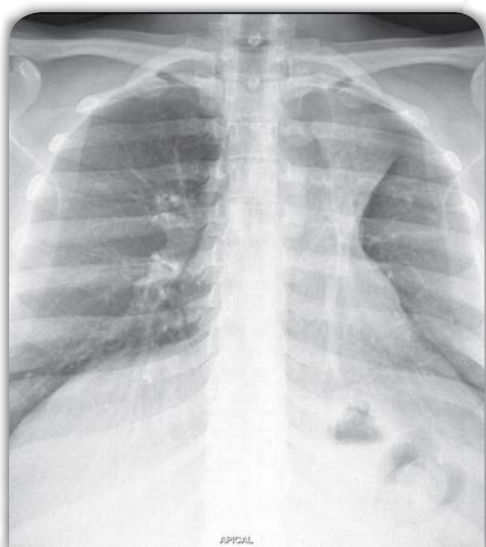


Fig. 13b: Apical view of the same patient showing LT upper lung opacity with volume loss, lateral border outlined by upward shifted fissure, mediastinal shift to the left, upward retracted LT hilum supporting evidence of LT upper lung collapse consolidation.

Nodular opacities or mass: These are rounded increased opacities that can be caused by different pathologies. Radiologically, these can be seen on any location, with sizes ranging from pinpoint to mass (it is called *mass* if >3 cm), solitary or multiple (such as miliary nodules, if multiple small nodules ≈ 2 mm in diameter), can have different shapes; and margins can be smooth, umbilicated or lobulated. The outline can be sharp, ill-defined or speculated. Density varies from soft tissue homogeneity to non-homogenous with internal calcification or cavitation or completely calcified nodule; associated satellite nodules or band shadows can be present. Figures 14a and 14b show CXR signs of nodular opacity. Secondary tuberculosis usually causes multiple acinar nodules with upper lobe predominance. Tuberculous granuloma is considered if nodules measure <4 cm. Solitary calcified nodule is mostly due to granuloma, but should not be directly called as such without description of the appearance.

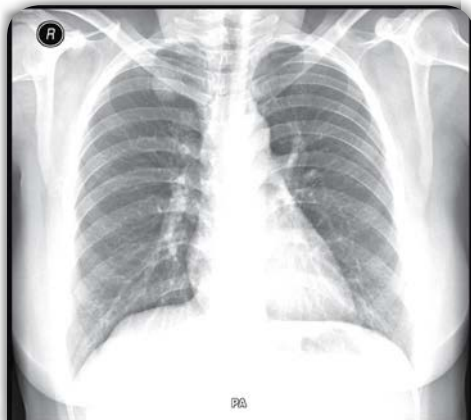


Fig. 14a: PA CXR showing RT medial apical ill-defined soft tissue nodule, partially covered by the medial clavicle and RT posterior fourth rib.

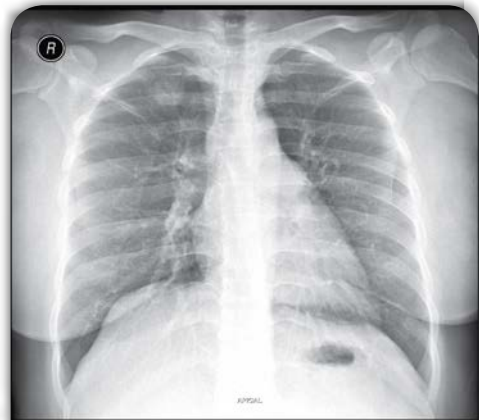


Fig. 14b: The apical view of the same case, better demonstrating the RT apical soft tissue density nodule free of the clavicle.

Ring opacities: These are annular opacities with central radiolucency usually due to cavitation of pre-existing lesion, but also can be caused by bullae, benign air cyst, loculated pneumothorax or fibrocystic changes. Radiological presentation is similar to nodules but with internal wall, inner and outer borders, varying wall thickness and wall regularity and presence or absence of fluid and intracavitary content. Cavity (see Figures 15 and 16) is one of the most important findings in post-primary tuberculosis and detecting its presence has management implications.

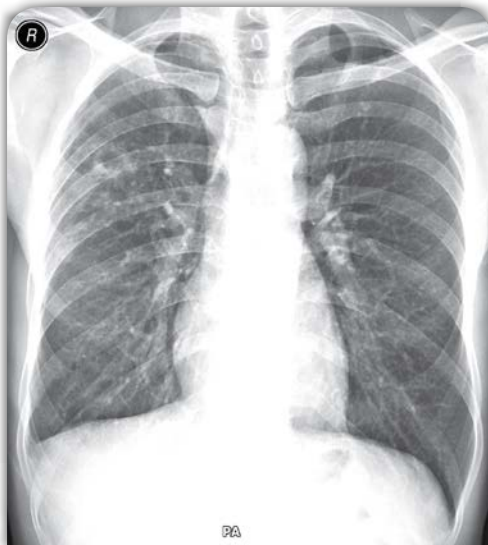


Fig. 15: PA CXR showing RT upper lung cavity with relatively smooth inner wall outline and surrounding hazy infiltration, and blunted RT costophrenic angle.

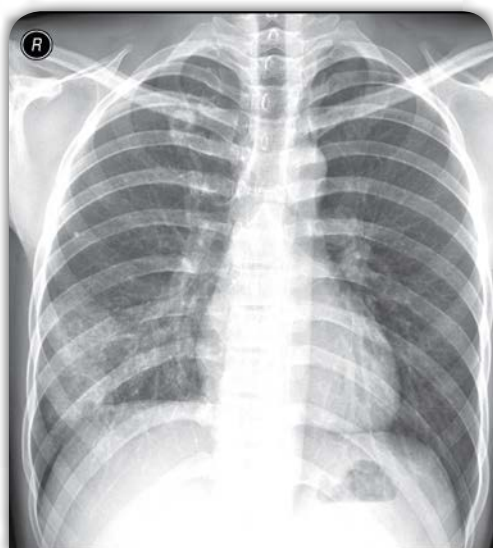


Fig. 16: PA CXR of another patient with RT medial apical cavitory lesion with relatively thick wall and smooth inner wall outline, and RT lower lung ill-defined consolidation focally silhouetting the RT mid hemi-diaphragm.

Linear opacities: These are thin or thicker (band shadow, if 5 mm or more) linear shadows. The most common abnormal linear opacity is a scar. Post-primary tuberculosis commonly heals with fibrosis presenting with irregular linear opacities and with or without volume loss. But it is mostly difficult to rule out active lesions, especially if the linear opacity is ill-defined or extensive. Figures 17 and 18 show CXR signs of linear opacities.

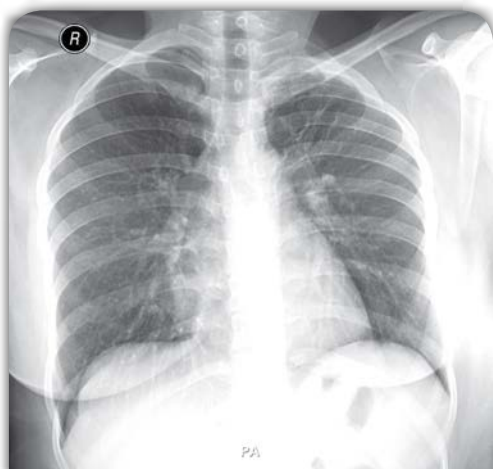


Fig. 17: PA CXR showing LT upper lung linear opacity with crowding of adjacent vessels.

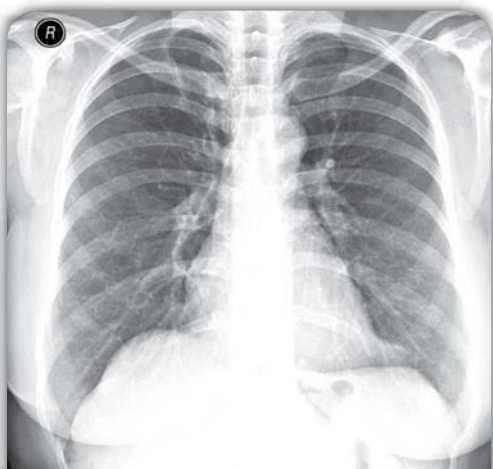


Fig. 18: PA CXR of another patient with RT apical linear opacity underlying the RT first rib and medial clavicle.

Interstitial opacities: This is the common presentation of chronic diffused interstitial lung diseases, but it can also be an atypical presentation¹ of tuberculosis especially in immuno-compromised cases. Radiologically, it can present with diffused nodular, reticular or reticulonodular shadows, or ground glass opacities with septal lines and bronchovascular and vascular changes. The distribution and types of predominant opacities are important for narrowing the possible differential diagnosis. Figure 19 shows CXR signs of interstitial opacity.

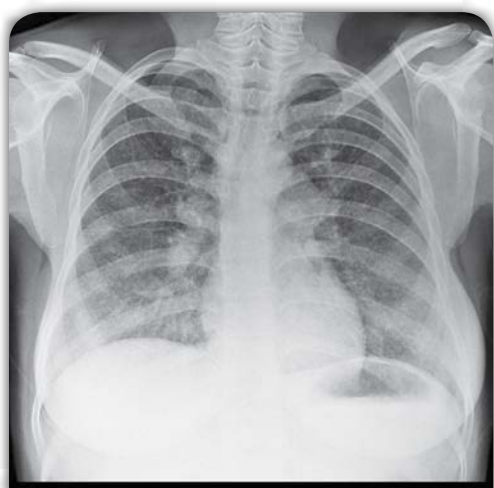


Fig. 19: PA CXR showing bilateral generalized reticulonodular interstitial infiltrations, with bilateral hilar enlargement (lymphadenopathy), minimal thickening of the minor fissure and RT upper lung linear opacity. (The case had negative sputum exam, empirical treatment for TB failed, and later was treated for sarcoidosis and responded.)

Pleural/chest wall opacities: These can be caused by pleural effusion (fluid collection in the pleural cavity) or other causes of pleural opacities, such as pleural mass lesion, pleural thickening or calcification or mass arising from soft tissue or bony chest wall (see Figure 22). Radiologically, free pleural effusion presents as lamellar lateral pleural opacity with blunted costophrenic angle, meniscus shaped medial border, and silhouettes the adjacent diaphragm or cardiac shadows (see Figure 20). Subpulmonic pleural collection presents as apparent elevated hemi-diaphragm, and the fluid lines up in the lateral side of the pleural space on ipsilateral lateral decubitus view (see Figure 5b). Fluid in the fissure appears as phantom tumor. Pleural fluid can also be loculated with irregular shape (Figure 21). Massive pleural effusions can cause opaque hemi-thorax. Pleural effusion on a patient in supine position is seen as ground glass haziness of the hemi-lung with apical capping. When pleural effusion presents associated with air in the pleura, it is known as hydro-pneumothorax. Pleural effusion and associated pleural thickening and calcifications are common presentations in tuberculosis. It is not always easy to differentiate small pleural effusion from pleural thickening; if the lateral decubitus view doesn't help and the suspicion for pleural effusion still remains on the PA view, ultrasound examination needs to be requested to rule out pleural effusion.

¹ *Atypical presentation* means the uncommon presentation.

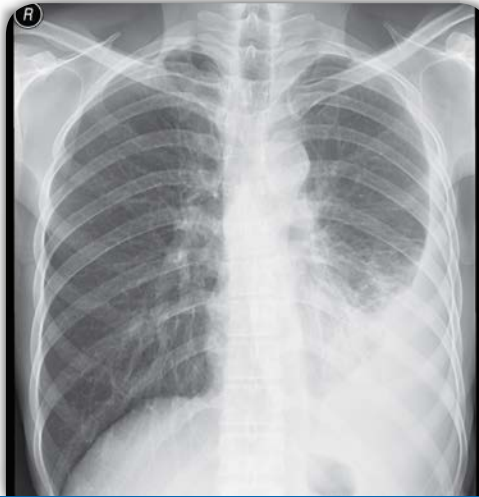


Fig. 20: PA CXR showing LT lateral and lower lung field homogenous opacity silhouetting the LT hemidiaphragm and LT lower heart border with medial meniscus sign, suggestive of LT pleural effusion.

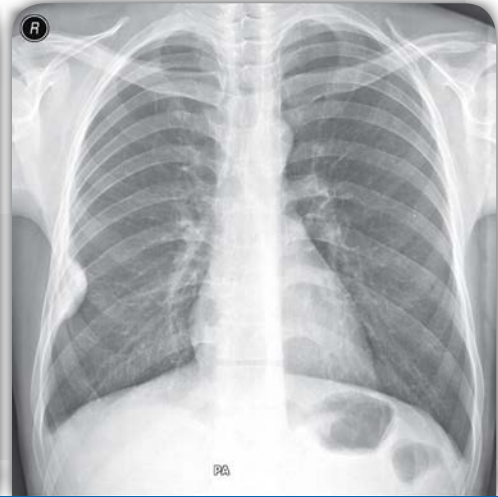


Fig. 21: PA CXR of another patient with RT lateral pleural based opacity with well-defined medial border and associated upper and lower pleural thickening and blunted RT costophrenic angle, suggestive of most likely loculated pleural effusion to rule out focal pleural mass.

Increased radiolucency (darkness)

The most common causes of increased radiolucency include pneumothorax, emphysema and airway obstruction and compensatory hyperinflation (Brant and Helms, 2007; Adam et al., 2008; Sutton, 2003). But as these abnormalities are not commonly associated findings suggestive of TB, details are not discussed here. Figure 23 shows example of CXR signs of pneumothorax.

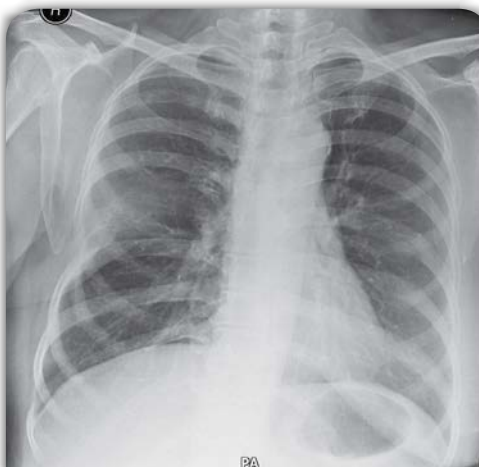
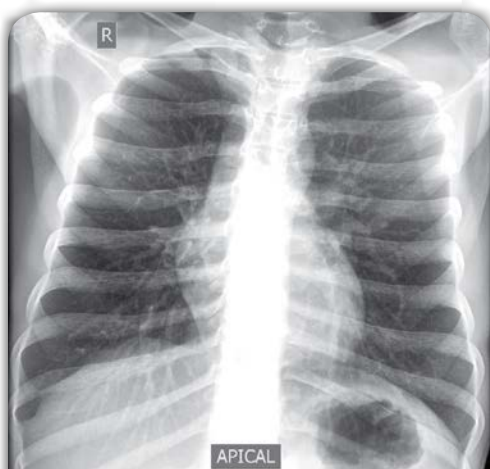


Fig. 22: PA CXR showing RT mid lung field hazy opacity extending to RT chest wall soft tissue with adjacent RT posterior 7th rib destruction and absent RT breast shadow. (This is a proven case of RT breast carcinoma, with history of RT mastectomy, presented RT chest wall mass. The CXR finding is suggestive of the focal recurrence.)

Fig. 23: PA CXR showing RT extreme apical small pneumothorax.



4.3 Special considerations in screening CXR interpretations

Immigrant health assessment is a way of active screening done on apparently healthy individuals who usually present without any clinical complaint; as a result, it is more common to see findings in the early stages. Thus, radiologists need to be extra cautious and watchful not to miss subtle lesions on CXRs especially in the hidden areas. The importance of additional views to clarify the suspicious subtle findings is paramount in such cases (Figures 9a and 9b, and 10a and 10b).

Though every abnormality detected should be properly described and reported, the main aim of screening CXR is to determine if there is any abnormality that suggests the possibility of tuberculosis. Therefore, special attention needs to be given to tuberculosis and for every abnormality on CXR. The question “Could this be tuberculosis?” should always be answered.

In addition to being acquainted with systematic CXR interpretation approach, screening CXR interpretation needs specifically detailed knowledge of radiological signs of tuberculosis (section 5). Furthermore, knowledge of the different country-specific CXR reporting forms and technical instructions is required to correctly classify the CXR findings (See Section 6).

Follow-up CXRs are commonly taken in migrant health screening process, especially in refugee programmes. The most common reasons for follow-up CXRs are: (a) follow-up CXR for tuberculosis patients to monitor response to treatment; (b) pre-departure medical screening (PDMS) to detect changes from previous CXRs; (c) retaking the medical examination if the initial exam has expired; and/or (d) other follow-up or additional CXRs are requested by the resettlement country (furtherance process) or by the panel physicians.

During screening CXR viewing, if the individual has previous images, these images should be reviewed and the findings compared to assess the change in finding with the most recent CXR, but this can also help in making sure that the same chest has been imaged, as this is a possible means of detecting rare incidents of CXR substitution.

If patient substitution is suspected while reading a CXR, the radiologic technologist should be informed and the correct image should be taken to replace the substituted image. If patient substitution is detected after the report has been delivered, it should be brought to the panel physicians' attention and a revised report based on the corrected image should be sent. In cases for Canada, Australia and New Zealand, if the substitution is detected after the image is uploaded to eMedical, the correct image should also be changed in the eMedical, and the revised report must be submitted. If detected after the report has been submitted, the eMedical authorities should be informed immediately and a request to reopen the 502 X-ray examination part should be sent, so that the wrong image will be deleted and the correct image and report will be submitted. Additionally, finding out the reason for the substitution and strengthening mechanisms to minimize such occurrences should be implemented.

For all cases with previous CXR, comparison readings should always be done and documented in the country's CXR examination report form. The report should contain the description of the current image's finding and the change should be noted comparing the findings from the previous image. In case of a series of previous images, all images should be reviewed and compared, and the dates of the CXRs on which changes were noted should be indicated in the report, with the pattern of the changes described in chronological order from oldest to the latest CXR.

5. CHEST X-RAY SIGNS SUGGESTIVE OF PULMONARY TUBERCULOSIS

Tuberculosis disease is a chronic bacterial infection caused by *Mycobacterium tuberculosis* (MTB) that can affect any part of the body, mainly the lungs. When it affects the lungs, CXR is one of the main investigation methods to suggest the diagnosis. Patterns of CXR signs suggestive of pulmonary tuberculosis depends on the type of pulmonary TB, which are:

- Primary tuberculosis;
- Post-primary (secondary) tuberculosis; and
- Tuberculosis in immuno-compromised (HIV/AIDS).

5.1 Chest X-ray signs suggestive of primary tuberculosis

Primary tuberculosis is initial infection with MTB and more common among children. CXR signs suggestive of active primary tuberculosis lesion include: (Brant and Helms, 2007; Adam et al., 2008; Sutton, 2003).

- Infiltrate or consolidation: can involve any lung segment or lobe (Ghon focus), can be minimal or more pronounced and can mimic pneumonia; multiplicity and cavitary changes are rare.
- Lymphadenopathy: the most common finding among children; usually unilateral hilar (see Figure 25), and less commonly paratracheal or mediastinal; if bilateral, it is usually asymmetrical. If hilar adenopathy occurs in the presence of a Ghon focus, it is known as Ghon complex (see Figure 24).
- Pleural effusion: usually associated with parenchymal lesions or hilar adenopathy in children. Isolated pleural effusion is more common in immuno-competent teenagers or young adults than in children or immuno-suppressed adults.
- Complications: narrowing of the central airway, collapse/consolidation or hyperinflation of a lung segment due to compression or a ball-valve phenomenon by an enlarged lymph node, endobronchial spread due to bronchial perforation that may mimic bronchopneumonia.
- Other relatively rare manifestations: pericardial effusion, minimal linear markings and/or miliary tuberculosis.

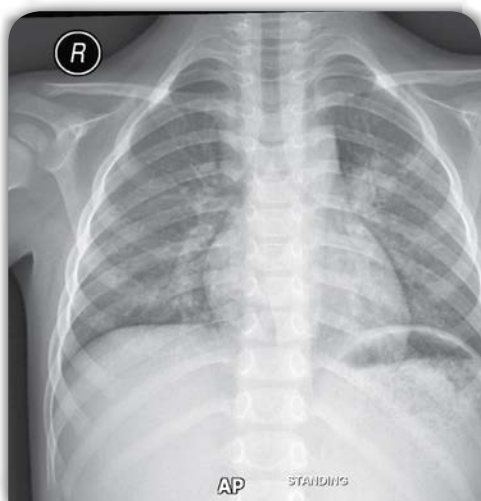


Fig. 24: PA CXR showing LT hilar enlargement (adenopathy) and adjacent LT upper lung ill-defined homogenous consolidation, suggestive of Ghon complex secondary to primary tuberculosis.

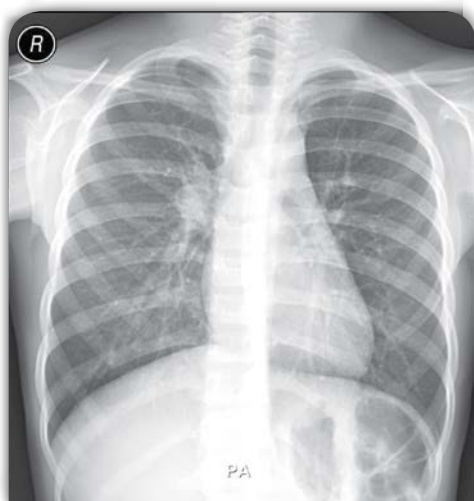


Fig. 25: PA CXR showing RT hilar enlargement secondary to lymphadenopathy, suggestive of primary tuberculosis.

5.2 Chest X-ray signs suggestive of post-primary tuberculosis

Post-primary tuberculosis, also known as secondary tuberculosis, is re-infection or reactivation of old MTB lesions and most common among adults. Major radiological findings are commonly characterized by a strong site preference. The CXR signs suggestive of active post-primary tuberculosis lesion include: (Brant and Helms, 2007; Adam et al., 2008; Sutton, 2003).

- The most preferred sites are apico-posterior segment of the upper lobes or superior segments of the lower lobes (95%). Isolated anterior segment of the upper lobe involvement is unusual for MTB.
- Non-homogenous infiltrations/consolidations are usually associated with linear opacities that may suggest fibrosis due to the long-standing process of immune response. The consolidation (see Figure 26) is usually irregular, patchy or non-homogenous and ill-defined multiple soft tissue nodular infiltrates and may be tethered to the hilum. The findings can be unilateral or bilateral and associated volume loss is common.
- Cavitation is common; the cavity can be small or large, multiple or single, and can be located inside the consolidation or nodule/mass, wall thickness varies, but internal wall outline is relatively smooth compared to malignant cavities, and fluid level is uncommon (see Figures 10, 15 and 16).

- Pleural effusions are also commonly detected among adults; usually unilateral but can be bilateral, and can be free or loculated (see Figures 20 and 21).
- Less common complications of tuberculosis seen on CXR are: (a) bronchogenic spread (diffuse acinar nodules); (b) endobronchial tuberculosis (causing collapse of the distal lung segment); (c) miliary tuberculosis; (d) tuberculoma (seen as a nodule); (e) mycetoma formation/fungal ball in a tuberculosis cavity (seen as mass in a cavity); and (f) rarely cavitary tuberculosis that can cause adjacent pulmonary arterial wall weakening and results in aneurysm, which is known as Rasmussen aneurysm, this can be life threatening if ruptures.

In early stage of tuberculosis, it is common to find small and subtle abnormal CXR findings suggestive of active tuberculosis in asymptomatic individuals (see Figure 27).

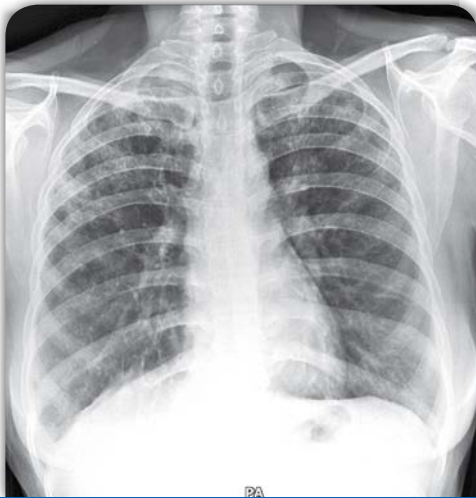


Fig. 26: PA CXR showing bilateral upper lung, non-homogenous ill-defined infiltrations, suggestive of secondary (post-primary) tuberculosis.

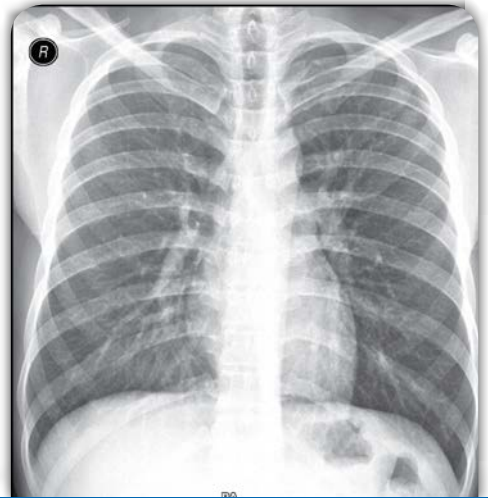


Fig. 27: PA CXR showing LT peripheral upper lung, small, ill-defined soft tissue nodule suggestive of secondary or post-primary tuberculosis.

5.3 Chest X-ray signs suggestive of tuberculosis in HIV/AIDS patients

CXR signs of pulmonary tuberculosis in HIV patients are related to the level of T-cell immunity (CD4 count) of the individual. The CXR signs change from the typical post-primary TB signs to more atypical pattern as the immunity drops; detailed descriptions are described below as follows (Brant and Helms, 2007):

- In HIV-infected individuals, with CD4 counts ≥ 200 cells/mm³, CXR signs of TB are the same as in non-HIV-infected individuals with typical post-primary CXR patterns of tuberculosis among adults.

- In HIV-infected individuals with CD4 counts 50–200 cells/mm³, the CXR usually present with signs suggestive of primary tuberculosis.
- In the later stages of HIV/AIDS with CD4 counts <50 cells/mm³, CXRs findings of tuberculosis may have an atypical pattern with bilateral predominantly lower lung, coarse, interstitial reticular-nodular infiltrates. In the later stage of the disease, concomitant atypical pneumonias and pulmonary malignancies are also more common. Thus, it is common to see CXR findings with mixed lesions that make the tuberculosis diagnosis usually difficult. In such cases, tuberculosis should always be suspected.

5.4 Chest X-ray findings suggestive of healing and previous tuberculosis

Chest X-ray signs of healing/old pulmonary TB are more common in secondary (post-primary) TB compared to primary TB. The healing signs in post-primary tuberculosis commonly start parallel with the existing active-appearing lesions, and as a result, differentiating signs of active and inactive TB on the CXR is not always easy. The common CXR signs of healing pulmonary TB are presented below (Brant, 2007; Adam et al., 2008; Sutton, 2003).

- Findings that may indicate previous primary tuberculosis disease: Usually primary tuberculosis resolves completely and the CXR can become completely normal. Sometimes, some non-specific residual findings may remain, such as calcified lymph node(s), calcified nodule (calcified granuloma), and rarely small well-defined (discrete) linear opacities and pleural thickening can rarely be seen. The presence of calcified lymph node with calcified nodule (calcified granuloma) is known as Ranke complex, which is highly suggestive of previous primary TB (see Figure 28).
- Residual findings are common in healed post-primary (secondary) tuberculosis. Healing in post-primary TB commonly result in formation of scars. Common findings include well-defined (discrete) linear opacities and calcifications (see Figure 29), often associated with signs of volume loss and pleural thickening, and sometimes cyst formation, bronchiectasis and bullas may occur due to distortion of the lung and/or bacterial super infections. Cavities usually obliterate during healing but rarely a thin walled cavity may persist.
- Due to the natural pathological process of TB that healing starts in the presence of signs of activity, especially in the presence of significant abnormality, it is not always easy to definitely indicate on the CXR if the finding is purely inactive tuberculosis. In such situations, the suspicion of active tuberculosis should remain and be reported accordingly (see Figure 29). Stability of the finding on TB follow-up CXR supports inactive tuberculosis but can not totally rule out active lesion.

The resettlement countries vary in their requirements for including CXR findings suggestive of healing/previous TB as criteria for sputum referral.

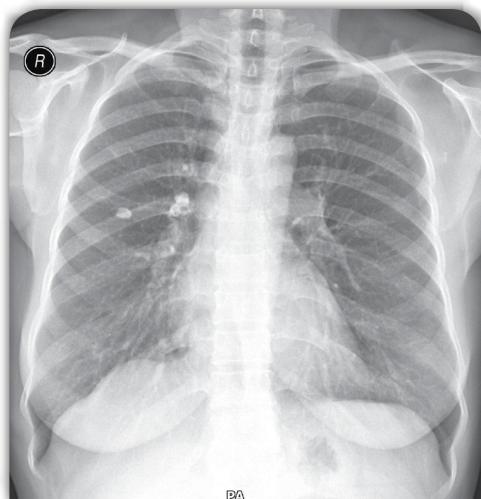


Fig. 28: PA CXR showing RT hilar calcified lymph node and RT mid lung field calcified nodule, commonly suggestive of Ranke complex secondary to old healed Ghon complex (primary tuberculosis).

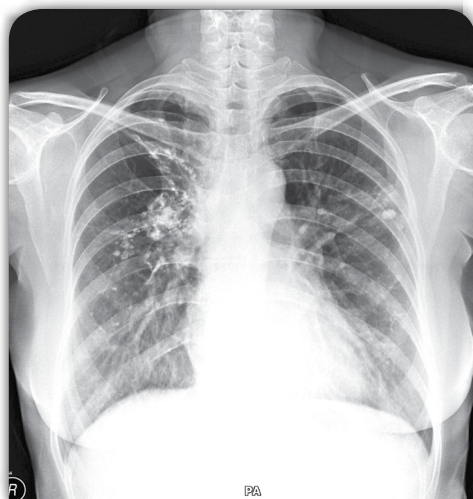


Fig. 29: PA CXR showing bilateral predominantly mid and RT upper lung, irregular linear opacities and calcific nodules more in the RT side, associated with ill-defined haziness in the LT peripheral upper/mid lung, suggestive of predominantly post-primary healing signs to rule out active TB.

5.5 Misinterpretations of tuberculosis on CXR

5.5.1 Under-interpretation of tuberculosis on CXR

It is important for an infectious disease such as tuberculosis not to be under-diagnosed for the individual client's well-being, protecting the public's health and facilitating resettlement. Under-interpretation is relatively less common compared to over-interpretations, but its consequence is more serious. It can occur with any type of lesion, but small and/or subtle lesions or lesions in the hidden areas of the lung are most likely to be overlooked. The common conditions leading to under interpretations are when:

- The image quality is not adequate;
- Image is not reviewed in a systematic manner covering all areas;
- Right viewing condition and instrument is not used;

- Adequate time is not given; and
- The person interpreting the image lacks the appropriate skill and knowledge to detect the abnormality.

Minimizing under-interpretation: Using a systematic approach (see Section 3), including reviewing the image in a systematic manner, giving adequate time for each image and using proper viewing condition and high resolution monitors, helps to minimize missing significant findings. Digital CXR images should not be viewed using LCD or CR/DR monitors for interpreting the images.

For minor image quality issue, digital correction of minor shortcomings in brightness and/or contrast should be used during image viewing whenever needed. Using image magnifying options, comparing the two sides of the lung for symmetry and paying special attention to assessment of lesions in the hidden areas (apical lungs, retrocardiac and subdiaphragmatic regions, costophrenic recesses and hilar regions) is important. For lesions not well seen on PA view, additional views should be done to clarify suspected finding in hidden areas (see Figures 9 and 10). Interpreting digital images instead of laser-printed films also helps in reducing under-interpretations or missing abnormal findings.

In addition, uncorrectable technical quality faults should trigger repeat X-ray. If previous CXR is available, comparison with previous X-ray studies is important as this may alert the viewer to changes that may be subtle on one or another view. When apical pleural thickening or apical pleural capping is visualized, it is important to check for the lower border of the apical capping for small pleural-based apical infiltrates or linear opacities.

5.5.2 Over-interpretation of tuberculosis on CXR

Significant attention is given to avoiding under-interpretation due to its impact on the public's health and the interest of the resettlement countries not to resettle untreated active TB cases. However, it is also important to minimize the over-interpretations of CXR findings suspected of tuberculosis to reduce unnecessary investigations, as this delays travel and exposes HAPs to additional costs with the use of laboratory resources and increased administrative complexity. This cost is compounded especially at follow-up exams, such as PDMS where the effects of a previously over-interpreted abnormal X-ray at health assessment stage recur.

Due to the higher prevalence of normal images over abnormal images, the nature of high expectation on screening examinations, the natural human tendency towards a safety-first approach and shifting slight suspicious findings to abnormal in the health assessment setting, over-interpretation (higher false positives) is

more frequently encountered than under-interpretation. Some CXR findings are frequently associated with over-interpretation, such as:

- Vascular shadows reported as abnormal linear opacities, fibrotic streaks or scars
- Horizontal or accessory fissures reported as linear opacities or fibrous strands
- End-on vessels reported as soft tissue or calcified nodules
- Questionable opacities (especially suspicious findings in the apices) reported as abnormal without attempt to clarify with additional views
- Lateral border of manubrium sterni reported as linear opacity
- Prominent cardiac fat pad reported as basal opacity/infiltrates
- Effect of poor inspiration reported as basal consolidation/fibrosis hilar enlargement and/or cardiomegaly
- Rotated images reported as mediastinal widening, increased translucency of one lung and/or LT ventricular emphasis or cardiomegaly
- Prominent or semi-calcified costochondral junctions, especially the first, reported as infiltrations or lung calcifications
- Nipple shadows reported as nodules.

Minimizing over-interpretation: As previously described, it is important that images are evaluated for technical quality prior to reading (section 3.2). If poor inspiratory effort or patient rotation is not recognized prior to diagnostic reading, the possibility of misinterpretation increases. The natural anatomy of the pulmonary vasculature should be remembered (section 4.1). Blood vessels are connected to a parent branch and thin out in diameter towards the periphery. As vasculature is larger in diameter near the hilum and smaller near the periphery, end-on vessels reduce in size as the view moves peripherally. If a linear or curvilinear opacity can be traced back to a parent vessel, it is likely to be a continuation of this vessel. As such, a round opacity in the lung region near the hilum with size similar to the local vasculature is more likely to be an end-on vessel than the same-sized opacity located peripherally. Additional views, such as lordotic views, can help to visualize the vessel in profile that was seen as end-on on the PA view and clarify the finding differentiating end-on vessels from nodules.

Additional views are also important for differentiating solitary lines from prominent vessels, a prominent minor fissure from adjacent abnormal linear opacity, and for clarifying questionable lesions. Additional views should be done before reporting an abnormality as “suspected” or “possible” or otherwise uncertain terminologies. Lung apices are common sites of over-interpretation due to a high index of suspicion, overlapping anatomy of neck shadow and unclear visualization of areas by the clavicles and medial ribs on the PA. Unclear visualization of the apices can be

addressed with apical lordotic view to clarify areas covered by the clavicles, upper ribs and neck shadow on the PA. If no suspicious area of concern on the lower lung, a collimated apical view cutting the lower lungs is preferred. In extreme apical lesion above the clavicles, apical view may not be helpful, as the first ribs and clavicles may cover the extreme apical areas in apical views; in such cases, repeat PA keeping the clavicles at T4/5 level is more helpful to see if the finding is genuine.

If there is a question of basal atelectasis versus small infiltrate/linear opacity due to fibrosis, and the lung volumes are noted as insufficient, the image needs to be repeated with a full inspiration. Atelectasis occurs more often among overweight individuals or in exposures obtained without full inspiration. But if suspicious infiltrations or other causes of linear opacity can not be ruled out, the possibility of TB still needs to be mentioned and classified accordingly in the reporting form.

If there is uncertainty that well-defined lower zone opacity may be a nipple shadow or a solid mass, nipple marker PA or lordotic view would provide clarification.

6. COUNTRY-SPECIFIC X-RAY REPORTING FORMS

Destination countries, such as Australia, Canada, New Zealand and the United States, have their own CXR reporting forms. The United Kingdom has adopted the specific findings part of the Canada CXR reporting form. For other countries with no specific reporting forms, IOM uses its reporting form, which is modeled from the United States' CXR reporting form. Knowledge on the different country-specific reporting forms and detailed instructions is paramount for the correct utilization of the forms and standardization of CXR reports.

6.1 US X-ray reporting form

The new US CXR reporting form, DS-3030/2014 (see Annex A), has been in use effective October 2014, and has replaced the previous form DS-3030/2007 and the older DS-3024. The US CXR reporting form uses a classification system of findings.

The first classification of findings is normal or abnormal. If the “Normal Findings” checkbox is marked, there is no need to further mark the other checkboxes. If the checkbox for “Abnormal Findings” is marked, further classification into the subcategories is required.

In the DS-3030/2014 form, there are two subcategories of CXR abnormalities: “Can Suggest Tuberculosis (Need Smears and Cultures)” and “No Sputum Specimens Required”. For each subcategory checked, the specific checkbox corresponding to the finding should be marked. If multiple findings are present, one or more boxes can be marked in each column.

Radiological signs under the “Can Suggest Tuberculosis” subcategory are: (a) infiltrate or consolidation; (b) cavitary lesion; (c) nodule(s) or mass with poorly defined margins (such as tuberculoma); (d) pleural effusion (perform lateral or decubitus radiograph or ultrasound, if needed); (e) hilar/mediastinal adenopathy; (f) miliary findings; (g) discrete linear opacity; (h) discrete nodule(s) without calcification; (i) volume loss or retraction; and (j) others.

For the “Other” checkbox under the “Can Suggest Tuberculosis (Need Smears and Cultures)” subcategory, there is no detail in the technical instruction on the findings that should be included in this checkbox. But in routine practice, less common

abnormal findings that suggest tuberculosis are included, such as bronchiectasis, clustered calcified pulmonary nodules especially in apical segments and/or irregular apical capping or significant pleural thickening >1 cm either in the apical or lateral side. When this box is checked, three smears and three cultures are required.

The second subcategory in the US CXR form is “No Sputum Specimens Required”, which is further subcategorized into “Mark as Class B Other on DS-2054” and “Do Not Mark as Class B Other on DS-2054”. In “Mark as Class B Other on DS-2054” subcategory, CXR findings brought by non-TB causes that need further investigation and/or follow-up are included. The checkboxes are ‘cardiac’, ‘musculoskeletal’, and ‘other, specify in the remarks’. Common findings included in this subcategory are cardiomegaly, significant musculoskeletal lesions, and sub-diaphragmatic abdominal lesions and thyroid calcification/mass, marked in the checkbox “Other”.

When a finding can suggest TB but at the same time can be a sign of other non-TB significant disease such as lung carcinoma, the finding should be marked both under subcategory “Can Suggest Tuberculosis” and under “No Sputum Specimens Required”, and “Mark as Class B Other on DS-2054”. The differential diagnosis should be documented in the description part, specifying the recommended imaging modality as needed, so that the investigation for both TB and the other possible differential diagnosis can proceed in parallel.

In the “Do Not Mark as Class B Other on DS-2054” subcategory, findings that may be related to tuberculosis but have such a small probability of reactivation or non-significant findings are included, such as calcified pulmonary nodule/s, solitary or scattered, calcified lymph node(s), minimal pleural thickening or apical capping (<1 cm) and diaphragmatic tenting. In such cases, no smears or cultures are required and no tuberculosis notifications for clinic follow-up are sent to the US Health Department’s tuberculosis control programmes by the Centers for Disease Control and Prevention (CDC).

For non-significant findings other than those included in the list under “Do Not Mark as Class B Other on DS-2054” subcategory, the current form does not have the option to mark them in the same category. CDC is considering updating the form in the future to include an “Other” checkbox under the subcategory. In the meantime, the workaround is to include borderline significant findings, such as prominent aortic knuckle, slight left ventricular emphasis and old rib fracture, under the “Other” checkbox under “Mark as Class B Other on DS-2054”. For normal variants, such as cervical rib, forked ribs and diaphragmatic humps, these are reported as normal and the presence of the non-significant findings (normal variants) should be documented on the description part.

Things to remember when using the US CXR form: Discrete linear opacity is under “Can Suggest Tuberculosis” on the US CXR form. There is the risk of over-interpreting this finding, commonly due to a prominent vessel misclassified as an abnormal discrete linear opacity. Additional views may help to clarify and avoid over-interpretation. There is also risk of over using this finding, when a small infiltrate containing multiple abnormal streaky markings is listed as a discrete linear opacity. If the linear opacity is ill-defined, especially in the presence of multiple linear opacities, in which tuberculous activity cannot be ruled out, the finding should be marked under “*infiltrate or consolidation*” and the detail can be described in the description as needed.

The radiologist is required to complete the US CXR reporting form. He/She should enter the detailed description of the findings in the remarks part with detailed radiological characterization of the abnormal findings (see section 3.4). The radiologist must print and sign his/her name on the DS-3030 form, and enter the date of CXR interpretation. To prevent confusion at US Health Departments, all copies of the DS-3030 form must contain an identical interpretation for the corresponding CXRs exam dates, the interpreting radiologist’s name and signature and the interpretation date. Radiologists should not dictate a radiology report that is subsequently entered onto the DS-3030 by non-radiologists (CDC, 2009). The US programme is currently not online, and chest radiographs should be copied to CDs and physically brought to the United States by the applicant.

6.2 Australia X-ray reporting form

Australia has implemented the web-based eMedical system for transferring medical documents, including CXR images and reports effective from January 2013, after replacing the e-Health system, which was used from 2011 to 2012. The paper-based Australian X-ray reporting form is called Form 160 (DAIC, 2008). The current CXR reporting form in eMedical for initial CXR exam is called 502 chest X-ray examinations (see Annex B).

The Australian technical instruction requires the panel radiologist to complete the CXR report (DIBP, 2014). The Australia CXR reporting form has seven categories; the first five sections are based on the anatomical parts (these are “Skeleton and soft tissue”, “Cardiac shadow”, “Hilar and lymphatic glands”, “Hemidiaphragms and costophrenic angles”, and “Lung fields”), with “Normal” and “Abnormal” checkboxes for each part. Each checkbox has to be marked either as normal or abnormal. For every abnormal checkbox marked, the description of the finding should be written in the adjacent Remarks part.

Checkboxes 6 (“Evidence of Tuberculosis (TB)”) and 7 (“Are there strong suspicions of active tuberculosis (TB)?”) have yes and no choices. Checkbox number 6 should be marked “Yes” if there are CXR signs of either active or old healed tuberculosis. Checkbox number 7 should be marked as “Yes” if there is highly suspicious active tuberculosis, such as infiltration or presence of cavity, and this is a decisive criterion for sputum referral for Australian cases (DIBP, 2014). In completing this part, one needs to be cautious not to miss small and subtle signs of active tuberculosis, at the same time trying not to over-diagnose signs of old tuberculosis as active. As discussed above, classifying CXR signs into active and inactive findings is not always easy (see section 5.4).

The Australian CXR form requires A/B grading of the CXR findings:

- **Grade A** includes normal CXR findings and non-significant CXR findings; and
- **Grade B** includes any abnormality indicating past or present tuberculosis and significant non-tuberculosis findings, including cardiac findings.

The following non-significant CXR findings should be graded as A, as detailed in the Australian technical instruction in Part C, section 48 (DIBP, 2014):

- Aortic calcification
- Apical cappings (smooth border)
- Azygous fissure or other accessory fissures
- Breast implants
- Cardiomegaly (CTR <60%), dextrocardia or situs inversus
- Nipple shadows
- Pectus excavatum
- Rib abnormalities (such as cervical ribs, previous rib fractures, bifid ribs) and scoliosis
- Raised hemidiaphragm

In case of raised hemidiaphragm, it is important to be cautious when ruling out significant causes, such as subpulmonic pleural effusion, diaphragmatic paralysis, sub-diaphragmatic masses and diaphragmatic hernias, before grading the finding as A.

Cardiac diseases are graded B if the CTR > 60 per cent, and/or showing signs of left atrial enlargement or pulmonary arterial hypertension. Presence of previous significant surgeries, such as cardiac valve replacement, sternal wiring and vascular stents/shunts and absent breasts should be graded B with details provided (DIBP, 2014). Though not included in the technical instruction, it is also advisable to include signs of left ventricular hypertrophy (rounded LT heart border) as grade B, even though there is no sign of cardiomegaly.

6.2.1 Completing the 502 chest X-ray examination part in eMedical for Australia

The 502 X-ray examination part in Australia eMedical has six components: Pregnancy declaration (for women), Confirm identity, Attach X-ray images (with documentation on the presence of chaperone and interpreter), Detailed radiology findings, Review exam details, and Grading and examiner declaration.

The parts of the 502 eMedical form, such as Pregnancy declaration, Confirm identity, Attach X-ray images including documenting the presence of a chaperone and interpreter should be completed by the radiologic technologist or radiology support staff. The attached CXR image should be in DICOM format with approximate size of up to 5 MB (DIBP, 2014).

Identity concerns in eMedical: If the individual's biodata in the valid ID does not match with the biodata in the eMedical, the question "Do you have identity concerns?" should be answered as "Yes" and a copy of the valid ID (passport for immigrants and RRF for refugees) should be attached. If the biodata in the ID matches with the eMedical but the biodata in the attached CXR is different, the biodata on the CXR should be corrected if it is sure that the CXR belongs to the same person. But if it cannot be confirmed that the attached CXR belongs to the same person, the CXR should be repeated and the right images should be reattached.

For Australia, the radiologist is required to complete the 502 CXR exam form with the detailed CXR findings, provide the proper grading and declaration and submit the reports directly to eMedical. The radiologist should also check the accuracy of the reports before declaration and submission, as well as ensure the reliability and quality of the CXR images and the overall radiology process (DIBP, 2014).

For non-significant CXR findings mentioned above, the required anatomical checkbox should be marked as Normal in eMedical and graded as A. If a panel radiologist wants to document such findings, the description of the finding can be included in the general comment box under the A grading. This is different from the Canada eMedical where no comment is permitted if it is graded as A.

When evidence of tuberculosis (any old or active findings of tuberculosis) is marked as present in checkbox number 6, the system will automatically grade it as B. When checkbox number 7 (highly suggestive of active tuberculosis) is marked as "Yes", in addition to being automatically graded as B, the eMedical system automatically generates requirement 603. This requirement needs further sputum examination (including culture, and when culture positive, drug sensitivity test), report from a

chest specialist² and repeat CXR at the completion of culture with the results and the image attached to the eMedical.

For Australian referral CXRs in the eMedical, such as “504 CXR examination” and others, these need to be completed by uploading the portable document format (PDF) copy of the CXR report and the CXR images.

6.3 Canada X-ray reporting form

The new medical report form of the Citizenship and Immigration Canada (CIC), including the paper-based X-ray form (IMM 5419), (see Annex C1 and C2) was released in November 2012, in parallel with the CIC eMedical rollout. At the same time, the A/B grading system similar to the Australian form has been added. It is a requirement in the Canadian CXR form to complete this grading based on the instructions provided on the technical instruction and the reporting form (CIC, 2013). The grading are:

- **Grade A:** No evidence of active TB or changes suggestive of other significant diseases identified.
- **Grade B:** Evidence of active TB or changes suggestive of other significant diseases identified.

In addition to the grading part, the Canada CXR reporting form has two parts. The first part is for detailed radiological findings with seven subparts, which is similar to the Australian X-ray form. The first five checkboxes are categorized anatomically (Skeleton and soft tissue, Cardiac shadow, Hilar and lymphatic glands, Hemi-diaphragms and costophrenic angles, and Lung fields). Each checkbox has to be marked either as normal or abnormal. If an Abnormal checkbox is selected, details of the findings need to be recorded in the adjacent “Description of Abnormal Findings” space. Checkbox 6 is for documenting evidence of active or old tuberculosis. Checkbox 7 is marked if there is evidence of suspicious active tuberculosis.

The second part of the CIC reporting form is for special findings that can be related to tuberculosis. This part has a list of findings from 1.1 to 4.7 with three subcategories, including:

1. Minor findings: 1.1, 1.2, 2.1, 2.2 and 2.3;
2. Minor findings (sometimes associated with tuberculosis infection): 3.1 to 3.5; and

² A chest specialist may also be referred to as a chest physician.

3. Findings sometimes seen in active tuberculosis or other conditions: 4.0 to 4.7.

If none of the checkboxes in the special finding list apply, the checkbox titled “NONE of the above are present” should be marked. The CXR criteria for sputum referral for CIC cases differ from region to region based on the tuberculosis burden of the countries. In the Asia-Pacific region, if one or more of the checkboxes from 4.1 to 4.7 is checked, the case requires sputum collection.

It is not necessary to report the following non-significant X-ray findings in CIC CXR form (as instructed by CIC RMO-Manila, e-mail released on 15 September 2014). The findings are:

- Breast implants
- Rib abnormalities (such as cervical ribs, previous rib fractures, bifid ribs, congenital rib fusion)
- Scoliosis
- Nipple shadows
- Dextrocardia
- Azygous fissure/lobe (or other accessory fissures)
- Pectus excavatum

Since the CIC eMedical CXR form does not allow writing a finding when the Normal checkbox is marked and graded as A, there will be no space to document these findings, unlike in the Australian eMedical form, which allows describing the insignificant findings even with an A grading in the general description part.

6.3.1 Things to remember when using the Canada CXR form

- Apical capping can be checked in two separate checkboxes in the form. If the apical capping is smooth and <1 cm thick, it is marked in 2.1; if it is irregular and/or >1 cm thick, checkbox 4.0 is marked. Here, one needs to be cautious to ensure that subtle adjacent apical infiltration or fibrosis is not misclassified, as the presence of these findings would require 4.1 classification.
- Costophrenic angle blunting can be reflected by three classifications: (a) checkbox 2.2 for blunting below the dome; (b) checkbox 3.5 at the level/above the dome; and (c) checkbox 4.5 if with pleural fibrosis/effusion. If a lateral decubitus view shows signs of free effusion with any level of costophrenic blunting, this should be classified under checkbox 4.5 (pleural effusion/fibrosis).
- Although classification 4.1 mentions only the apical segments, there is no other checkbox for fibro-nodular/calcific changes elsewhere in the lungs.

Thus, for fibrotic changes in any location that can be caused by tuberculosis, checkbox 4.1 should be used.

- In 3.1 and 3.2, the word *granuloma* is used instead of calcified nodule. Though granuloma is a generic differential diagnosis for nodule and can radiologically present as calcified or not calcified nodule, this section is used only for calcified nodule, as there are other checkboxes dedicated for soft tissue nodule (either discrete or ill-defined).
- Classification 3.1 and 3.3 are similar, as calcified nodule (calcified granulomas) can be correctly classified under either. The routine approach is to mark checkbox 3.1 for single calcified nodule <1 cm; 3.3 for multiple/single calcified nodule >1 cm; and 3.2 for calcified nodules associated with calcified lymph nodes.
- Checkbox 3.2 (“Solitary granuloma (<1 cm of any lobe) with calcified/enlarged hilar lymph nodes”) additionally mentions enlarged hilar lymph nodes, but soft tissue hilar enlargement should not be included under this checkbox as it is a clinically significant finding requiring sputum referral and can be appropriately marked under 4.3.
- Likewise, checkbox 3.3 (“Single/multiple calcified pulmonary nodules/micro-nodules with distinct borders”) though additionally mentions micro-nodules with distinct border, soft tissue nodules should not be included in this classification and should be marked under checkbox 4.2.
- Checkboxes 4.2 and 4.4 for ill-defined soft tissue nodule/nodules appear similar, but small ill-defined/soft tissue nodule or ill-defined small nodular infiltrations should be classified under checkbox 4.2 and larger nodule/s >1 cm under 4.4.
- Checkbox 4.6 contains categories “Acute pulmonary disease” and “parenchymal lung diseases”, which are not direct radiological signs. But for convenience, all CXR findings with diffused lung changes should be classified under this checkbox.
- Checkbox 4.7 is for “Any cavitating lesion OR ‘fluffy’ or ‘soft’ lesions felt likely to represent active TB”. The understanding is that the *fluffy* or *soft* lesions stand for ill-defined soft tissue consolidations or infiltrations.
- Solitary fibrotic streak is under checkbox 1.1 for the Canada CXR form, unlike in the US form, where it is classified under Can Suggest Tuberculosis (Need Smears and Cultures); one of the differences between Canada and US forms.

6.3.2 Completing 502 chest X-ray examination part in eMedical for Canada

Canada, along with Australia and most recently New Zealand, use the eMedical web-based system for transferring medical documents, including CXR images and reports. The initial CXR form in Canada eMedical is also known as 502 CXR examinations (Annex C3). The components are the same as the eMedical for Australia, except for the additional Special Findings part in the Canada form. Most instructions therefore mirror those already given for Australia.

The first parts of 502 X-ray examination forms in Canada eMedical – same as in Australia, namely “Pregnancy declaration”; “Confirm identity”; “Attach X-ray images”; and documenting the presence of chaperone and interpreter (See Annex C3) – should be completed by the radiologic technologist or radiology support staff. When there is identity concern, the same procedure mentioned in the Australia part should apply for the Canada eMedical form too.

The radiologist is expected to complete the detailed radiology finding, special findings, do the A/B grading, make the declaration and submit the CXR reports directly to eMedical. The CXR reports in the Canada eMedical form can also be copied and saved by authorized radiology support staff, but the radiologist is responsible for the accuracy of the records of the CXR findings in the system.

The radiology grading in the Canada eMedical form is automatically provided by the system based on the CXR report findings. If the system graded the finding as A, but the radiologist believes it should be B, it can be changed to B. But if the system grades it as B, it cannot be changed to A. In such cases, if the grading should be A, one should either: (a) go back to the Detailed CXR Findings part and revise the non-significant finding to normal, so that the system will automatically grade the finding as A; or (b) write the findings in the comment part below the B grading and mention that the grading is automatically graded by the system. In the Canada eMedical form, no comments are permitted if the grading is A, but comments are mandatory if the grading is B (CIC, 2013).

6.4 New Zealand CXR reporting form

New Zealand has begun implementing eMedical starting from November 2014, joining Australia and Canada. With the eMedical rollout for New Zealand, some changes are made on the New Zealand paper-based Chest X-ray Certificate (INZ 1096) (Annex D1). The latest New Zealand technical instruction containing the related changes was released in March 2015 (INZ, 2015). The New Zealand CXR part in eMedical is named 502 Chest X-ray examination (Annex D2), similar to Australia and Canada forms. The new X-ray reporting form has also included the A/B radiology

grading similar to the Australian form, the previous New Zealand form did not have part for A/B grading.

- **Grade A** is for No evidence of active TB, or old or inactive TB, or findings suggestive of other significant diseases.
- **Grade B** is for Evidence of active TB, or old or inactive TB, or findings suggestive of other significant diseases.

The other changes on the new New Zealand CXR Certificate (INZ 1096) are in Section C (Results of chest X-ray examination).

In the new form, any evidence of past or present TB must be marked under checkbox C7 (Evidence of TB), and “Evidence of highly suspicious of active TB”³ in checkbox C8. In the eMedical, checkbox C7 corresponds to question 6 of the 502 CXR exam and C8 to question 7. The part in the previous version of this form indicating “Evidence of old, healed tuberculosis (TB)” has been removed (see Annex D1 and D2).

With these new changes, the New Zealand and Australian X-ray reporting forms have become the same with the list of seven checkboxes. The first five are based on the anatomical parts with Normal and Abnormal options. For every abnormal checkbox marked, the description of the finding should be written in the adjacent Remarks part. For checkbox number 6 with present and absent options, “Present” should be checked if there is any CXR sign of either active or old (healed) tuberculosis. For checkbox number 7 with yes and no options, “Yes” should be checked if there is “Highly suspicious active tuberculosis”, and like Australia, this is a decisive criterion for sputum referral.

As stated in the new New Zealand’s technical instruction, CXR findings highly suggestive of active TB under checkbox number 7 include infiltrations and cavity, and it stresses that the finding must be convincing (INZ, 2015). According to additional criteria stated in the Guidelines for Tuberculosis Control in New Zealand 2010, developed by the New Zealand Ministry of Health (MOH), such findings include cavities, consolidations, ill-defined nodules or miliary nodules, lymphadenopathies and pleural effusion. Inactive tuberculosis signs include scarring, volume loss and calcifications, calcified nodules, calcified lymph nodes, pericardial calcification, pleural thickening and calcifications (Ministry of Health, 2010). Thus, the later findings should be marked in checkbox number 6 but not checkbox 7.

³ This is as written in the original form.

6.3.2 Completing the 502 chest X-ray examination part in eMedical for New Zealand

Completing the 502 X-ray examination in eMedical for New Zealand is almost the same as completing the eMedical for Australia.

The radiologic technologist is responsible for certifying the identity of the person, by checking the ID and completing the identity confirmation, as well as uploading the image and documenting the chaperone and interpreter. The CXR image attached should be in DICOM format and with the image size compressed approximately to 350–500 KB (INZ, 2015).

The radiologist is responsible for ensuring the correct identification and the correctness of the image attached, completing the details of the radiological finding, A/B grading and declaration, and submitting the report to eMedical.

When checkbox 6 is checked but not 7, the grading will be automatically graded as B. But answering “Yes” to checkbox 7, in addition to automatically grading it as B, will also generate requirement 603, when the case is prepared for grading. The requirement for 603 is the same as for Australian cases.

The list of non-significant CXR findings that should be graded as A in the new New Zealand technical instruction is the same as that of Australia. The same procedure also applies in documenting such findings in the eMedical (INZ, 2015).

6.5 United Kingdom X-ray reporting form

The United Kingdom tuberculosis (UKTB) Technical Instruction Version 6 (V6), released in September 2013 (PHE, 2013), has adopted Canada’s Special Findings form for documenting tuberculosis-related findings (Annex E1). IOM uses UKTB global software for reporting UKTB immigrant CXRs. The global software has incorporated the current Special Findings CXR form, with additional part for documenting non-tuberculosis incidental findings (The UKTB CXR form as seen in the UKTB global software is in Annex E2).

The UKTB Technical Instruction V6 states that “All applicants who have findings on CXR of active or old pulmonary tuberculosis are required to have sputum examination” (PHE, 2013). But the technical instruction does not specify which findings are required to be included as active or inactive tuberculosis.

According to further information from the Public Health England (PHE) through lectures and discussions, for findings from 4.0–4.7 checkboxes, sputum must be taken. For findings from 3.1–3.5, the sputum referral is decided by the panel physician. But for 1.1–2.3, sputum referral is not required. The decision for parts 3.1 to 3.5 risks inconsistency in using sputum referral criteria, where same CXR findings of two different individuals can be different. For example, calcified pulmonary nodule (calcified granuloma) classified the same way as 3.1 for two patients, one can be referred for sputum, but the other may not be referred. This may create difficulty in standardizing criteria and comparing results.

As the UKTB adopted Canada’s Special Findings part of the X-ray form, the things to remember when using the Canada special finding CXR reporting form previously mentioned (see section 6.3.1) should be noted in the UKTB CXR reporting as well.

6.5 IOM X-ray reporting form used for other resettlement countries

For other resettlement countries, such as Denmark, Germany, Netherlands, Norway and for refugee cases in the United Kingdom, the IOM CXR reporting form (Form 04MH_X) is used for the CXR findings (see Annex F). The form was developed in November 2004 modeled from the US CXR reporting form. The system of classification of CXR abnormalities is similar to the old US reporting form (DS-3024); the abnormal findings are classified into three subcategories: “Can suggest Active TB”; “Can suggest Inactive TB”; and “Other X-ray findings”.

The list under Findings suggestive of active and inactive TB is also similar to the old US form, except for the additional line “Upper lobe retraction or volume loss”, which is added as separate entity under Inactive TB. Additionally, the list under other findings doesn’t have subcategories to “Follow-up needed” and “No follow-up needed”. The IOM Global Radiology Coordination and Teleradiology Centre is planning to update the IOM CXR form in the future.

7. IOM GLOBAL TELERADIOLOGY QUALITY CONTROL FRAMEWORK

Maintaining the quality of CXR images and radiology reports requires establishing quality assurance (QA) and QC systems in the HAPs, through SOPs and training, regular internal monitoring, and internal and external QC systems, with provision of feedbacks and regular advisories.

Having analysed several CXR inter-observer studies performed in missions, IOM has designed and started implementation of a global teleradiology quality control programme led by the IOM Global Teleradiology Centre as part of its objective to optimize the quality of radiology services in immigration HAPs. The first phase has started for the US programme, and the plan is to have a step-by-step rollout for all major IOM locations and include all programmes. The QC system uses automatic image sampling system and PACS image replication, Teleradiology QC web-application for the different radiologists' roles, comparing reports and analysis of the results. The process involves many IOM and external panel radiologists participating in HAP, and therefore it is important to describe the given steps and expectations from each party in the QC framework:

1. The system will be set to randomly sample 10 per cent of CXR interpretations done by IOM's internal or external radiologists in the field operations, and replicate sampled images to Manila's central PACS. The primary CXR interpretation will be entered to MIMOSA.
2. The transferred images will be reviewed by an IOM QC radiologist in the Teleradiology Centre using teleradiology QC application system. The QC radiologist will be blinded about the initial interpretations while doing the QC reporting.
3. Cases with significant discrepancies will be available in the QC system for re-review by the radiologists in the field (the radiologist who did the primary CXR reading) who will either accept or not accept the secondary (QC) report.
4. The re-review results not accepted by the primary radiologist (non-accepted cases) will be reviewed again by the QC radiologist, and discussed with the local radiologist in the country location, upon which a final interpretation will be agreed upon by both parties.

5. If no agreement can be reached on major findings that can affect the management of a case, the receiving country (for the United States, the CDC radiologist) will be involved for a third opinion on the interpretations and classification.
6. The inter-observer agreement report with Kappa and the proportion of overall and tuberculosis-specific agreement will be generated from the teleradiology system and shared back to the originating IOM missions.
7. The result of the QC agreement analysis and the whole QC process will be regularly shared to the involved field operations. Additionally, for significant discrepancies that need immediate actions, missions will be immediately notified through e-mails.
8. Based on the results of the QC process, proper feedback and advice will be given to the missions and revision of processes will be undertaken as needed (IOM Teleradiology quality control workflow framework is included in Annex G).

Annex A: DS-3030/2014 US CXR reporting form, Page 1 of 4

DS-3030
09-2014

Annex B: Screenshot of 502 chest X-ray examination in Australia eMedical website

Components of 502 chest x-ray examination for Australia eMedical

A vertical list of components for the 502 Chest X-Ray Examination, each with a checkmark icon to its right:

- 502 Chest X-Ray Examination
- Pregnancy declaration
- Confirm identity
- Attach x-ray images
- Detailed radiology findings
- Review exam details
- Grading & Examiner Declaration

Detailed radiological findings page

The screenshot shows the 'Detailed radiology findings' page for a 502 Chest X-Ray Examination. It includes a 'Detailed question' section with a date field set to '19 Jun 2015'. Below this is a list of seven questions with radio button options for 'Normal', 'Abnormal', 'Absent', or 'Present'. The 'Attachments' section shows a table with columns for 'Delete', 'Document type', 'Details', 'Attachment type', 'Sending method', 'File name', and 'Edit'. The table is currently empty, with a message 'No documents have been attached'. Navigation buttons 'Back', 'Close', 'Save', and 'Next' are at the bottom.

502 Chest X-Ray Examination: Detailed radiology findings

Detailed question

Exam date: 19 Jun 2015

1. Skeleton and soft tissue: * ☐ Not selected ☐ Normal ☐ Abnormal

2. Cardiac shadow: * ☐ Not selected ☐ Normal ☐ Abnormal

3. Hilal and lymphatic glands: * ☐ Not selected ☐ Normal ☐ Abnormal

4. Hemidiaphragms and costophrenic angles: * ☐ Not selected ☐ Normal ☐ Abnormal

5. Lung fields: * ☐ Not selected ☐ Normal ☐ Abnormal

6. Evidence of Tuberculosis (TB): * ☐ Not selected ☐ Absent ☐ Present

7. Are there strong suspicions of active Tuberculosis (TB)? * ☐ Not selected ☐ No ☐ Yes

Attachments

Link to existing: Add New

Delete	Document type	Details	Attachment type	Sending method	File name	Edit
No documents have been attached						

Back Close Save Next

Grading and declaration page

The screenshot shows the 'Grading & Examiner Declaration' page for a 502 Chest X-Ray Examination. It includes a 'Provide Grading' section with a message: '502 Chest X-ray Examination is Required. Once you start to process the exam the 'Prepare for grading' button will become available.' Below this is an 'Examiner declaration' section with a checkbox for 'I declare that this health examination report is a true and correct record of my findings.' The 'Completed by' field is filled with 'Dr Sirrash Meseret GELAW' and the 'Date of declaration' is '19 Jun 2015'. Navigation buttons 'Back', 'Close', 'Save', and 'Submit Exam' are at the bottom.

502 Chest X-Ray Examination: Grading & Examiner Declaration

Provide Grading

502 Chest X-ray Examination is Required. Once you start to process the exam the 'Prepare for grading' button will become available.

Examiner declaration



☐ I declare that this health examination report is a true and correct record of my findings.

Completed by: Dr Sirrash Meseret GELAW

Date of declaration: 19 Jun 2015

Back Close Save Submit Exam

Annex C1: Canada paper-based CXR reporting form, page 5 of IMM 5419 (11-2012)

	Citizenship and Immigration Canada Citoyenneté et Immigration Canada	PROTECTED WHEN COMPLETED - B PAGE 5 OF 6
MEDICAL REPORT CHEST X-RAY REQUISITION AND REPORT		
UCI #: <input style="width: 100%;" type="text"/> IME #: <input style="width: 100%;" type="text"/> UMI # (if applicable): <input style="width: 100%;" type="text"/>		<div style="border: 1px solid black; padding: 10px; width: 150px; margin: auto;"> PHOTOGRAPH required for all clients. Must be taken within six months of the medical examination. </div>
Family name: <input style="width: 100%;" type="text"/>		
Given name(s): <input style="width: 100%;" type="text"/>		
Date of birth (YYYY-MM-DD): <input style="width: 100%;" type="text"/>	Country of birth: <input style="width: 100%;" type="text"/>	
Gender: <input style="width: 100%;" type="text"/>		
Routine PA (posteroanterior) chest X-ray is required.		
Date of exam: (YYYY-MM-DD) <input style="width: 100%;" type="text"/>		
TECHNICIAN/RADIOGRAPHER DECLARATION		
I have confirmed the BIODATA / Identity of the client <input type="checkbox"/> No <input type="checkbox"/> Yes I have concerns about the BIODATA / Identity of the client <input type="checkbox"/> No <input type="checkbox"/> Yes <input type="checkbox"/> If YES, please provide details:		
_____ Technician/Radiographer signature		
_____ Date (YYYY-MM-DD)		
IMMIGRATION MEDICAL RADIOLOGY GRADING		
Please consider the information you have provided about this client. You must consider if there is any evidence of TB or other significant findings. Significant means that a finding has a current or potential health impact.		
<div style="display: flex; justify-content: space-between;"> <div style="width: 45%;"> <input type="checkbox"/> A: No evidence of active TB or changes suggestive of other significant diseases identified. </div> <div style="width: 45%;"> <input type="checkbox"/> B: Evidence of active TB or changes suggestive of other significant diseases identified. </div> </div>		
Comments:		
PANEL RADIOLOGIST DECLARATION		
I confirm that this immigration radiology examination and report is a true and accurate record of my findings.		
Panel Radiologist name: <input style="width: 100%;" type="text"/>		Panel Radiologist no.: <input style="width: 100%;" type="text"/>
_____ Panel Radiologist signature		_____ Date (YYYY-MM-DD)
IMM 5419 (11-2012) E CHEST X-RAY		
		

Annex C2: Canada paper-based CXR reporting form, page 6 of IMM 5419 (11-2012)

PAGE 6 OF 6

IME #:		UMI # (if applicable):
Family name	Given name(s)	Date of birth (YYYY-MM-DD)

CHEST X-RAY REPORT

QUESTIONS/FINDINGS	RESPONSE	DESCRIPTION OF ABNORMAL FINDINGS
Is the client pregnant?	<input type="checkbox"/> No <input type="checkbox"/> Yes	
What is the expected date of delivery?	Date (YYYY-MM-DD)	
Has the pregnant woman advised that she wishes to proceed with the required x-ray examination?	<input type="checkbox"/> No <input type="checkbox"/> Yes	
Skeleton and soft tissue	<input type="checkbox"/> Normal <input type="checkbox"/> Abnormal	
Cardiac shadow	<input type="checkbox"/> Normal <input type="checkbox"/> Abnormal	
Hilar and lymphatic glands	<input type="checkbox"/> Normal <input type="checkbox"/> Abnormal	
Hemidiaphragms and costophrenic angles	<input type="checkbox"/> Normal <input type="checkbox"/> Abnormal	
Lung fields	<input type="checkbox"/> Normal <input type="checkbox"/> Abnormal	
Evidence of tuberculosis?	<input type="checkbox"/> No <input type="checkbox"/> Yes	
This chest x-ray is suspicious of Active TB	<input type="checkbox"/> No <input type="checkbox"/> Yes	

RECORD OF SPECIAL FINDINGS NOTED ON THE CLIENT'S CHEST X-RAY

FINDINGS	GRADE
Single fibrous streak/band/scar	1.1 <input type="checkbox"/>
Bony islets	1.2 <input type="checkbox"/>
Apical pleural capping with a smooth inferior border (< 1 cm thick at all points)	2.1 <input type="checkbox"/>
Unilateral or bilateral costophrenic angle blunting (below the horizontal)	2.2 <input type="checkbox"/>
Calcified nodule(s) in the hilum / mediastinum with no pulmonary granulomas	2.3 <input type="checkbox"/>
Solitary granuloma (< 1 cm and of any lobe) with an unremarkable hilum	3.1 <input type="checkbox"/>
Solitary granuloma (< 1 cm and of any lobe) with calcified / enlarged hilar lymph nodes	3.2 <input type="checkbox"/>
Single/multiple calcified pulmonary nodules/micro-nodules with distinct borders	3.3 <input type="checkbox"/>
Calcified pleural lesions	3.4 <input type="checkbox"/>
Costophrenic angle blunting (either side above the horizontal)	3.5 <input type="checkbox"/>
Notable apical pleural capping (rough or ragged inferior border and / or ≥ 1 cm thick at any point)	4.0 <input type="checkbox"/>
Apical fibronodular / fibrocalcific lesions or apical microcalcifications	4.1 <input type="checkbox"/>
Multiple / single pulmonary nodules / micro-nodules (noncalcified or poorly defined)	4.2 <input type="checkbox"/>
Isolated hilar or mediastinal mass / lymphadenopathy (noncalcified)	4.3 <input type="checkbox"/>
Single / multiple pulmonary nodules / masses ≥ 1 cm	4.4 <input type="checkbox"/>
Non-calcified pleural fibrosis and / or effusion	4.5 <input type="checkbox"/>
Interstitial fibrosis / parenchymal lung disease / acute pulmonary disease	4.6 <input type="checkbox"/>
ANY cavitating lesion OR "Fluffy" or "Soft" lesions felt likely to represent active TB	4.7 <input type="checkbox"/>
NONE of the above are present	0 <input type="checkbox"/>

IMM 5419 (11-2012) E
CHEST X-RAY

Annex C3: Screenshots of Canada 502 chest X-ray examinations as seen in eMedical website

Components of 502 chest x-ray examination for Canada eMedical

502 Chest X-Ray Examination

- Pregnancy declaration
- Confirm identity
- Attach x-ray images
- Detailed radiology findings
- Special findings
- Review exam details
- Grading & Examiner Declaration

inform
Changi
Bilal F.
09 Jun
Name
Relati
[View](#)
Clie
Prefer

Detailed radiological findings page

502 Chest X-Ray Examination: Detailed radiology findings

Detailed question

Exam date: 19 Jun 2015

1. Skeleton and soft tissue: ☒ Not selected ☐ Normal ☐ Abnormal
2. Cardiac shadow: ☒ Not selected ☐ Normal ☐ Abnormal
3. Hilar and lymphatic glands: ☒ Not selected ☐ Normal ☐ Abnormal
4. Hemidiaphragms and costophrenic angles: ☒ Not selected ☐ Normal ☐ Abnormal
5. Lung fields: ☒ Not selected ☐ Normal ☐ Abnormal
6. Evidence of Tuberculosis (TB): ☒ Not selected ☐ Absent ☐ Present
7. Are there strong suspicions of active Tuberculosis (TB)? ☒ Not selected ☐ No ☐ Yes

Attachments

Delete	Document Type	Details	Attachment type	Sending method	File name	Edit
No documents have been attached						

Special findings part for Canada eMedical

502 Chest X-Ray Examination: Special findings

Special findings

Special findings

☒ Not selected
☐ The following are present
☐ None of the following are present

The following are present

Minor findings
☐ 1.1 Single fibrous streak/band/scar (1.1)
☐ 1.2 Bony islets (1.2)
☐ 2.1 Apical pleural capping with a smooth inferior border (<1cm, thick at all points) (2.1)
☐ 2.2 Unilateral or bilateral costophrenic angle blunting (below the horizontal) (2.2)
☐ 2.3 Calcified nodule(s) in the hilum/mediastinum with no pulmonary granulomas (2.3)

Minor findings (sometimes associated with TB infection)
☐ 3.1 Solitary Granuloma (<1cm and of any lobe) with an unremarkable hilum (3.1)
☐ 3.2 Solitary Granuloma (<1cm and of any lobe) with calcified/enlarged hilar lymph nodes (3.2)
☐ 3.3 Single/Multiple calcified pulmonary nodules/micro-nodules with distinct borders (3.3)
☐ 3.4 Calcified pleural lesions (3.4)
☐ 3.5 Costophrenic angle blunting (either side above the horizontal) (3.5)

Findings sometimes seen in active TB or other conditions
☐ 4.0 Notable apical pleural capping (rough or ragged inferior border and/or greater than or equals to 1cm thick at any point) (4.0)
☐ 4.1 Apical fibro-nodular/fibrocalcific lesions or apical micro-calcifications (4.1)
☐ 4.2 Multiple/single pulmonary nodules/micro-nodules (non-calcified or poorly defined) (4.2)
☐ 4.3 Isolated hilar or mediastinal mass/lymphadenopathy (non-calcified) (4.3)
☐ 4.4 Single/multiple pulmonary nodules/masses >= 1cm (4.4)
☐ 4.5 Non-calcified pleural fibrosis and/or effusion (4.5)
☐ 4.6 Interstitial fibrosis/parenchymal lung disease/acute pulmonary disease (4.6)
☐ 4.7 Any cavitating lesion or Fluffy or Soft lesions felt likely to represent active TB (4.7)

Grading and declaration page

502 Chest X-Ray Examination: Grading & Examiner Declaration

Provide Grading

502 Chest X-ray Examination is Required. Once you start to process the exam the 'Prepare for grading' button will become available.

Examiner declaration

☐ * I declare that this health examination report is a true and correct record of my findings.

Annex D1: Paper-based New Zealand CXR reporting form, Section C of New Zealand CXR certificate (INZ 1096)

When filling in this form, please write clearly using CAPITAL LETTERS.

Passport/identification number

Radiologist/radiographer initials

Section C Results of chest X-ray examination

This section must be completed in full by the radiologist.

Where abnormalities are present, the radiologist must provide details and comments in the space provided and the X-ray film must accompany this certificate. The radiologist's report must be attached to this certificate and both returned to the examining physician or applicant.

C1 Notes to radiologist from examining physician (if applicable).

C2 Skeleton and soft tissue ☐ Normal ☐ Abnormal Give details

C3 Cardiac shadow ☐ Normal ☐ Abnormal Give details

C4 Hilar and lymphatic glands ☐ Normal ☐ Abnormal Give details

C5 Hemidiaphragms and costophrenic angles ☐ Normal ☐ Abnormal Give details

C6 Lung fields ☐ Normal ☐ Abnormal Give details

C7 Evidence of TB ☐ Absent ☐ Present Give details

C8 Evidence suspicious of active TB ☐ No ☐ Yes Give details

If abnormalities/evidence are noted in **C1** to **C8**, then include all X-ray films/plates/scans to show recent and past history of diagnosis and treatment. X-ray films/plates/scans must have a corresponding report attached.

C9 Radiologist's comments (if any).

Annex D2: Screenshots of New Zealand 502 chest X-ray examinations as seen in eMedical website

Components of 502 chest x-ray examination for NZ eMedical

☒ 502 Chest X-Ray Examination

☐ Pregnancy declaration

☐ Confirm identity

☐ Attach x-ray images

☐ Detailed radiology findings

☐ Review exam details

☐ Grading & Examiner Declaration

and Employment ("MBIE") and Changing the value or selection of it
Madinah NAKINTU
08 May 2015

Name of parent/guardian

Relationship to the client

[View client declaration](#)

Additional questions

Does the client want to receive

Detailed radiological findings page

502 Chest X-Ray Examination: Detailed radiology findings

Detailed question

Exam date

19 Jun 2015

1. Skeleton and soft tissue

☒ Not selected

☐ Normal

☐ Abnormal

2. Cardiac shadow

☒ Not selected

☐ Normal

☐ Abnormal

3. Hilar and lymphatic glands

☒ Not selected

☐ Normal

☐ Abnormal

4. Hemidiaphragms and costophrenic angles

☒ Not selected

☐ Normal

☐ Abnormal

5. Lung fields

☒ Not selected

☐ Normal

☐ Abnormal

6. Evidence of Tuberculosis (TB)

☒ Not selected

☐ Absent

☐ Present

7. Are there strong suspicions of active Tuberculosis (TB)?

☒ Not selected

☐ No

☐ Yes

Attachments

Link to existing

Add New

Delete	Document Type	Details	Attachment type	Sending method	File name	Edit
No documents have been attached						

Back

Close

Save

Next

Grading and declaration page

502 Chest X-Ray Examination: Grading & Examiner Declaration

Provide Grading

502 Chest X-ray Examination is Required. Once you start to process the exam the 'Prepare for grading' button will become available.

Examiner declaration

☐ *I declare that this health examination report is a true and correct record of my findings.

Completed by
Dr Sirash Meseret GELAW
Date of declaration
19 Jun 2015

Back

Close

Save

Submit Exam

3 Recording of radiographic findings

With acknowledgements to Citizenship and Immigration Canada

If any of the following abnormalities are present, radiologists are required to annotate their reports with the following numerical codes;

MINOR FINDINGS

- 1.1 Single fibrous streak/band/scar
- 1.2 Bony islets
- 2.1 Pleural capping with a smooth inferior border (<1cm thick at all points)
- 2.2 Unilateral or bilateral costophrenic angle blunting (below the horizontal)
- 2.3 Calcified nodule(s) in the hilum / mediastinum with no pulmonary granulomas

MINOR FINDINGS (OCCASIONALLY ASSOCIATED WITH TB INFECTION)

- 3.1 Solitary Granuloma (< 1 cm and of any lobe) with an unremarkable hilum
- 3.2 Solitary Granuloma (< 1 cm and of any lobe) with calcified / enlarged hilar lymph nodes
- 3.3 Single / Multiple calcified pulmonary nodules / micronodules with distinct borders
- 3.4 Calcified pleural lesions
- 3.5 Costophrenic Angle blunting (either side above the horizontal)

FINDINGS SOMETIMES SEEN IN ACTIVE TB (OR OTHER CONDITIONS)

- 4.0 Notable apical pleural capping (rough or ragged inferior border and/or ≥ 1 cm thick at any point)
- 4.1 Apical fibronodular / fibrocalcific lesions or apical microcalcifications
- 4.2 Multiple / single pulmonary nodules / micronodules (noncalcified or poorly defined)
- 4.3 Isolated hilar or mediastinal mass/lymphadenopathy (noncalcified)
- 4.4 Single / multiple pulmonary nodules / masses ≥ 1 cm."
- 4.5 Non-calcified pleural fibrosis and / or effusion.
- 4.6 Interstitial fibrosis/ parenchymal lung disease/ acute pulmonary disease
- 4.7 Any cavitating lesion OR "fluffy" or "Soft" lesions felt likely to represent active TB

Annex E2: UKTB CXR reporting form as it appears in UKTB global software

**UK TUBERCULOSIS
DETECTION PROGRAMME**
INTERNATIONAL ORGANIZATION FOR MIGRATION

19-Jun-2015 / 19-Jun-2015

Create a new member | Move to a family | Remove from family

NPDMK0100000706 LUMBU, Birbahadur

Back to Application List

Home

Applications

Status Tracking

Payments

CXR Assignment

Reports

Change Password

Online Help

Quick Search

706

19-Jun-2015

Application Paid

Biodata | Schedules | CXR | CXR Interpretation | Smear and Culture | History/Physical Exam | Forms & Documents

Show Biodata History

CXR Interpretation Information

Please create a new CXR interpretation

Date Interpreted * 19-Jun-2015

CXR Interpreted By

CXR Interpretation ☐ Normal ☒ Abnormal

Minor findings

☐ 1.1 Single fibrous streak/bands/cav

☐ 1.2 Bony sites

☐ 2.1 Pleural capping with a smooth inferior border (<1cm thick at all points)

☐ 2.2 Unilateral or bilateral costophrenic angle blunting (below the horizontal)

☐ 2.3 Calcified nodule(s) in the hilum / mediastinum with no pulmonary granulomas

Minor findings (occasionally associated with TB infection)

☐ 3.1 Solitary Granuloma (< 1 cm and of any lobe) with an unremarkable hilum

☐ 3.2 Solitary Granuloma (< 1 cm and of any lobe) with calcified / enlarged hilar lymph nodes

☐ 3.3 Single / Multiple calcified pulmonary nodules / micronodules with distinct borders

☐ 3.4 Calcified pleural lesions

☐ 3.5 Costophrenic Angle blunting (either side above the horizontal)

Findings sometimes seen in active TB (or other conditions)

☐ 4.0 Nodular apical pleural capping (rough or ragged inferior border and/or >= 1cm thick at any point)

☐ 4.1 Apical fibronodular / fibrocavitic lesions or apical microcalcifications

☐ 4.2 Multiple / single pulmonary nodules / micronodules (noncalcified or poorly defined)

☐ 4.3 Isolated hilar or mediastinal mass/lymphadenopathy (noncalcified)

☐ 4.4 Single / multiple pulmonary nodules / masses >= 1 cm

☐ 4.5 Non-calcified pleural fibrosis and / or effusion

☐ 4.6 Interstitial fibrosis/ parenchymal lung disease/ acute pulmonary disease

☐ 4.7 Any cavitating lesion OR "fluffy" or "soft" lesions not likely to represent active TB

Other findings (describe the abnormality in Descriptive Findings/Comments below)

☐ Skeleton and soft tissue

☐ Cardiac or major vessels

☐ Lung fields

☐ Other

Abnormality suggestive of active or old pulmonary TB? ☒ Yes (smear and culture required) ☐ No

Descriptive Findings/Comments on Abnormalities

Illustrate Findings Here

Clear

Next Step on Certify

☐ Encode Smear and Culture


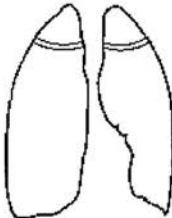
☐ Perform History/Physical Exam

☐ Schedule Smear and Culture

☐ List CXR Interpretations

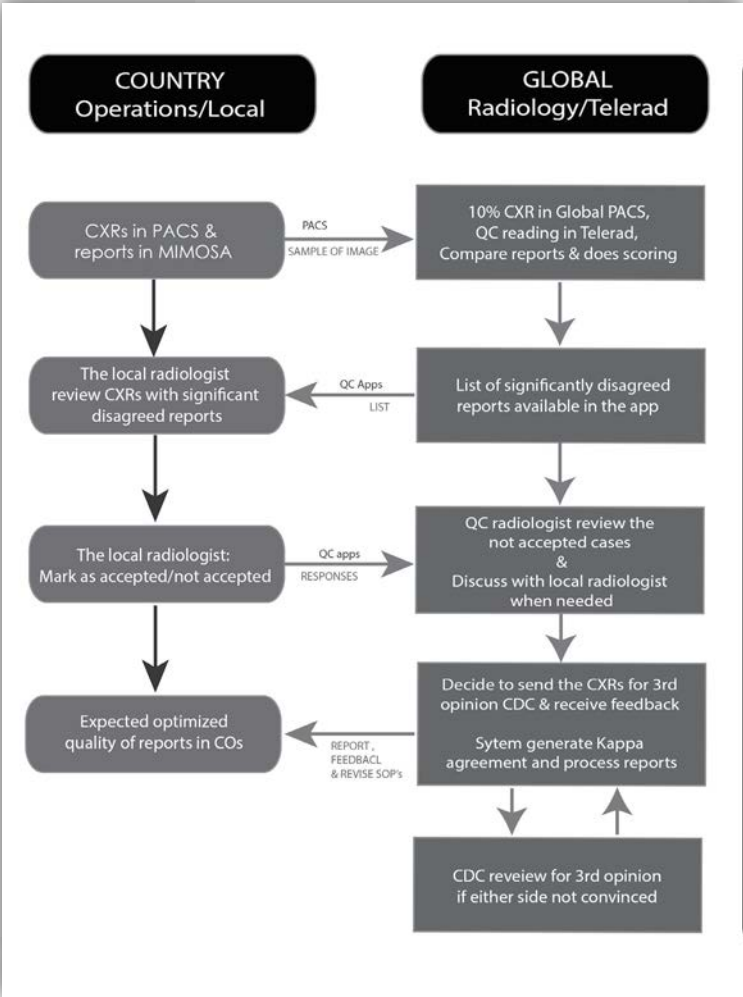
Save Certify >> List Certify >> Next Step

Annex F: IOM CXR reporting form (Form 04MH_X)

<div style="border: 1px solid black; width: 100px; height: 100px; margin: 0 auto;"></div> <p style="text-align: center; margin-top: 5px;">Photo</p>		Migration Health Assessment CHEST X-RAY REPORT Form 04MH_X	<table border="1" style="width: 100%; border-collapse: collapse;"> <tr> <td style="padding: 2px;">1. Assessment Date:</td> </tr> <tr> <td style="padding: 2px;">2. Service Provider Ref. No:</td> </tr> <tr> <td style="padding: 2px;">3. No of Films:</td> </tr> </table>	1. Assessment Date:	2. Service Provider Ref. No:	3. No of Films:																						
	1. Assessment Date:																											
2. Service Provider Ref. No:																												
3. No of Films:																												
4. Name: _____																												
<table border="1" style="width: 100%; border-collapse: collapse;"> <tr> <td style="width: 33%; padding: 2px;">5. Gender: <input type="checkbox"/> Male <input type="checkbox"/> Female</td> <td style="width: 33%; padding: 2px;">6. DOB: _____</td> <td style="width: 34%; padding: 2px;">7. Principal Applicant: No <input type="checkbox"/> Yes <input type="checkbox"/></td> </tr> <tr> <td style="padding: 2px;">8. Case No: _____</td> <td style="padding: 2px;">9. Ind.No: _____</td> <td style="padding: 2px;">10. Country/Program: _____</td> </tr> <tr> <td colspan="2" style="padding: 2px;">11. Place of Assessment: (Writing Address) _____</td> <td style="padding: 2px;">12. Doctor: _____</td> </tr> </table>				5. Gender: <input type="checkbox"/> Male <input type="checkbox"/> Female	6. DOB: _____	7. Principal Applicant: No <input type="checkbox"/> Yes <input type="checkbox"/>	8. Case No: _____	9. Ind.No: _____	10. Country/Program: _____	11. Place of Assessment: (Writing Address) _____		12. Doctor: _____																
5. Gender: <input type="checkbox"/> Male <input type="checkbox"/> Female	6. DOB: _____	7. Principal Applicant: No <input type="checkbox"/> Yes <input type="checkbox"/>																										
8. Case No: _____	9. Ind.No: _____	10. Country/Program: _____																										
11. Place of Assessment: (Writing Address) _____		12. Doctor: _____																										
<table border="1" style="width: 100%; border-collapse: collapse;"> <tr> <td style="width: 40%; padding: 2px;"> 13. CXR Not Done <input type="checkbox"/> Normal findings <input type="checkbox"/> Significant findings <input type="checkbox"/> </td> <td style="width: 40%; padding: 2px;"> b) For the reason: Age <input type="checkbox"/> Pregnancy <input type="checkbox"/> Other <input type="checkbox"/> </td> <td style="width: 20%; padding: 2px; vertical-align: top;"> <i>Comments:</i> </td> </tr> </table>				13. CXR Not Done <input type="checkbox"/> Normal findings <input type="checkbox"/> Significant findings <input type="checkbox"/>	b) For the reason: Age <input type="checkbox"/> Pregnancy <input type="checkbox"/> Other <input type="checkbox"/>	<i>Comments:</i>																						
13. CXR Not Done <input type="checkbox"/> Normal findings <input type="checkbox"/> Significant findings <input type="checkbox"/>	b) For the reason: Age <input type="checkbox"/> Pregnancy <input type="checkbox"/> Other <input type="checkbox"/>	<i>Comments:</i>																										
14. From the Medical file: a) TB signs or symptoms <input type="checkbox"/> b) Contact with TB patient <input type="checkbox"/> c) History of TB <input type="checkbox"/>																												
15. Chest X-ray Interpretation by the Radiologist																												
<table border="1" style="width: 100%; border-collapse: collapse;"> <tr> <td style="width: 33%; padding: 2px;"><input type="checkbox"/> Infiltrate or consolidation</td> <td style="width: 33%; padding: 2px;"><input type="checkbox"/> Discrete fibrotic scar or linear opacity</td> <td style="width: 34%; padding: 2px;"><input type="checkbox"/> Musculoskeletal</td> </tr> <tr> <td style="padding: 2px;"><input type="checkbox"/> Any cavity lesion</td> <td style="padding: 2px;"><input type="checkbox"/> Discrete nodule(s) without calcification</td> <td style="padding: 2px;"><input type="checkbox"/> Cardiac or major vessels</td> </tr> <tr> <td style="padding: 2px;"><input type="checkbox"/> Nodule with poorly-defined margins (such as tuberculoma)</td> <td style="padding: 2px;"><input type="checkbox"/> Discrete fibrotic scar with volume loss or retraction</td> <td style="padding: 2px;"><input type="checkbox"/> Pulmonary</td> </tr> <tr> <td style="padding: 2px;"><input type="checkbox"/> Linear, interstitial markings (children only)</td> <td style="padding: 2px;"><input type="checkbox"/> Discrete nodule(s) with volume loss or retraction</td> <td style="padding: 2px;"><input type="checkbox"/> Other</td> </tr> <tr> <td style="padding: 2px;"><input type="checkbox"/> Pleural effusion</td> <td style="padding: 2px;"><input type="checkbox"/> Upper lobe retraction or volume loss</td> <td rowspan="3" style="padding: 2px;"></td> </tr> <tr> <td style="padding: 2px;"><input type="checkbox"/> Hilar/Mediastinal adenopathy</td> <td style="padding: 2px;"><input type="checkbox"/> Other (such as bronchiectasis)</td> </tr> <tr> <td colspan="2" style="padding: 2px;"><input type="checkbox"/> Other (such as milary findings)</td> </tr> <tr> <td colspan="2" style="padding: 2px;"><input type="checkbox"/> Can suggest Active TB (need smears)</td> <td style="padding: 2px;"><input type="checkbox"/> Can suggest INACTIVE TB (need smears if symptomatic)</td> </tr> <tr> <td colspan="3" style="padding: 2px;"><input type="checkbox"/> Other X-ray findings</td> </tr> </table>				<input type="checkbox"/> Infiltrate or consolidation	<input type="checkbox"/> Discrete fibrotic scar or linear opacity	<input type="checkbox"/> Musculoskeletal	<input type="checkbox"/> Any cavity lesion	<input type="checkbox"/> Discrete nodule(s) without calcification	<input type="checkbox"/> Cardiac or major vessels	<input type="checkbox"/> Nodule with poorly-defined margins (such as tuberculoma)	<input type="checkbox"/> Discrete fibrotic scar with volume loss or retraction	<input type="checkbox"/> Pulmonary	<input type="checkbox"/> Linear, interstitial markings (children only)	<input type="checkbox"/> Discrete nodule(s) with volume loss or retraction	<input type="checkbox"/> Other	<input type="checkbox"/> Pleural effusion	<input type="checkbox"/> Upper lobe retraction or volume loss		<input type="checkbox"/> Hilar/Mediastinal adenopathy	<input type="checkbox"/> Other (such as bronchiectasis)	<input type="checkbox"/> Other (such as milary findings)		<input type="checkbox"/> Can suggest Active TB (need smears)		<input type="checkbox"/> Can suggest INACTIVE TB (need smears if symptomatic)	<input type="checkbox"/> Other X-ray findings		
<input type="checkbox"/> Infiltrate or consolidation	<input type="checkbox"/> Discrete fibrotic scar or linear opacity	<input type="checkbox"/> Musculoskeletal																										
<input type="checkbox"/> Any cavity lesion	<input type="checkbox"/> Discrete nodule(s) without calcification	<input type="checkbox"/> Cardiac or major vessels																										
<input type="checkbox"/> Nodule with poorly-defined margins (such as tuberculoma)	<input type="checkbox"/> Discrete fibrotic scar with volume loss or retraction	<input type="checkbox"/> Pulmonary																										
<input type="checkbox"/> Linear, interstitial markings (children only)	<input type="checkbox"/> Discrete nodule(s) with volume loss or retraction	<input type="checkbox"/> Other																										
<input type="checkbox"/> Pleural effusion	<input type="checkbox"/> Upper lobe retraction or volume loss																											
<input type="checkbox"/> Hilar/Mediastinal adenopathy	<input type="checkbox"/> Other (such as bronchiectasis)																											
<input type="checkbox"/> Other (such as milary findings)																												
<input type="checkbox"/> Can suggest Active TB (need smears)		<input type="checkbox"/> Can suggest INACTIVE TB (need smears if symptomatic)																										
<input type="checkbox"/> Other X-ray findings																												
16. Descriptive Findings / Comment on Abnormalities <div style="text-align: right; margin-top: 50px;">  </div>																												
17. Date: _____ (Day/Month/Year)		18. Radiologist's Signature: _____																										

IOM Health Assessment Form®, Nov 2004 (Form 04MH_X; Page 1 out of 1)

Annex G: IOM Global Teleradiology quality control workflow framework



REFERENCES

Adam, A. et al. (eds.)

- 2008 *Grainger & Allison's Diagnostic Radiology: A Textbook of Medical Imaging*, 5th edition. Churchill Livingstone, an imprint of Elsevier, Philadelphia, PA.

Ahmad, N.

- 2001 Tips and techniques for decubitus and oblique chest X-rays. AuntMinnie.com, December 21, 2001, last updated 28 April 2003. Available from www.auntminnie.com/index.aspx?sec=ser&sub=def&pag=dis&Item-ID=52402

American Registry of Radiologic Technologists (ARRT)

- 2015 *ARRT Examination Handbook for State Licensing Exams administered by ARRT in 2015*. ARRT, St Paul, Minnesota. Available from www.arrt.org/pdfs/State-Licensing/State-Licensing-Handbook.pdf

Brant, W. and C.A. Helms

- 2007 *Fundamentals of Diagnostic Radiology*, 3rd edition. Lippincott Williams & Wilkins, Philadelphia, PA

Centers for Disease Control and Prevention (CDC), U.S. Department of Health and Human Services

- 2009 CDC Immigration Requirements: Technical Instructions for Tuberculosis Screening and Treatment, Using Cultures and Directly Observed Therapy. n.p.


Citizenship and Immigration Canada (CIC), Government of Canada

- 2013 *Panel Members Handbook 2013*, chapter 4 section 9 (4.9). CIC, Health Branch, n.p. Available from www.cic.gc.ca/english/resources/publications/dmp-handbook/

Department of Immigration and Border Protection (DIBP), Government of Australia

- 2014 Australia immigration panel members' instructions. Global Health, Sydney, Australia.

- Department of Immigration and Citizenship (DAIC), Government of Australia
 2008 Radiological report on chest X-ray of an applicant for an Australian visa (Form 160). Commonwealth of Australia.
- Government of Canada
 2013 IMM 5419 Medical Report, Chest X-ray requisition and report (IMM 5419, Section E; Chest X-ray Report form), n.p.
- Immigration New Zealand (INZ), Government of New Zealand
 2004 *Handbook for Medical Examiners, Chest X-ray Referral Form (INZ 1007) Sections H, I, J, K (Chest X-ray section).*
 2013 Chest X-ray Certificate, INZ 1096. Available from www.immigration.govt.nz/NR/rdonlyres/4F0B1B69-EDAF-4BF5-B973-566D39BF52D3/0/INZ1096.pdf
 2015 *Panel Member Instructions (INZ 1216).* Available from www.immigration.govt.nz/NR/rdonlyres/26FA9CF0-982A-4B9A-A0C5-5835F7D0E398/0/NZ1216.pdf
- Ministry of Health, Government of New Zealand
 2010 *Guidelines for Tuberculosis Control in New Zealand 2010.* Ministry of Health, Wellington, Available from www.health.govt.nz/publication/guidelines-tuberculosis-control-new-zealand-2010
- Sutton, D.
 2003 *Textbook of Radiology and Imaging*, 7th edition. Churchill Livingstone, an imprint of Elsevier, Philadelphia, PA.
- U.S. Department of State
 n.d. Chest X-ray and Classification Worksheet, DS-3030/2014.
 2013 United Kingdom Visas and Immigration and Public Health England UK Tuberculosis Technical Instructions (UKTBTI) Version 6, September 2013, n.p.
- Whitley, A.S. et al.
 2005 *Clark's Positioning in Radiography*, 12th edition. Hodder Arnold Publisher, United Kingdom.



International Organization for Migration (IOM)

Global Radiology Coordination and Teleradiology Centre
Migration Health Division

International Organization for Migration (Manila Administrative Centre)
24th floor Citibank Tower, Paseo De Roxas 8741, Makati city 1226
Metro Manila, Philippines

Email: sgelaw@iom.int • teleradiology@iom.int

Tel: +632 230 1674