

CLINICAL RESEARCH STUDIES

A comparison of covered vs bare expandable stents for the treatment of aortoiliac occlusive disease

Bibombe P. Mwiapatayi, MMed (Surg), FCS (SA), FRACS,^{a,b} Shannon Thomas, MBBS (Hons),^a Jackie Wong, MPH,^a Suzanna E. L. Temple, PhD, MBA,^{a,c} Vikram Vijayan, MRCS, FRCS,^a Mark Jackson, MD, FRACS,^d and Sally A. Burrows, BMath Grad Dip Med Stat,^c on behalf of the Covered Versus Balloon Expandable Stent Trial (COBEST) Co-investigators,* Perth, Western Australia and Gold Coast, Queensland, Australia

Objective: This trial was conducted to determine if covered stents offer a patency advantage over bare-metal stents in the treatment of aortoiliac arterial occlusive disease.

Methods: The Covered Versus Balloon Expandable Stent Trial (COBEST), a prospective, multicenter, randomized controlled trial, was performed involving 168 iliac arteries in 125 patients with severe aortoiliac occlusive disease who were randomly assigned to receive a covered balloon-expandable stent or bare-metal stent. Patient demographic data, clinical signs and symptoms, TransAtlantic Inter-Society Consensus (TASC) classification, and preprocedure and postprocedure ankle-brachial index measurements were recorded. The primary end points included freedom from binary restenosis and stent occlusion of the treated area, as determined by ultrasound imaging or quantitative visual angiography, or both. Postprocedural follow-up was at 1, 6, 12, and 18 months.

Results: Aortoiliac lesions treated with a covered stent were significantly more likely to remain free from binary restenosis than those that were treated with a bare-metal stent (hazard ratio [HR], 0.35; 95% confidence interval (CI), 0.15-0.82; $P = .02$). Freedom from occlusion was also higher in lesions treated with covered stents than in those treated with a bare-metal stent (HR, 0.28; 95% CI, 0.07-1.09); however, this did not reach statistical significance ($P = .07$). Subgroup analyses demonstrated a significant difference in freedom from binary restenosis for covered stents in TASC C and D lesions compared with a bare stent (HR, 0.136; 95% CI, 0.042-0.442). This difference was not demonstrated for TASC B lesions (HR, 0.748; 95% CI, 0.235-2.386).

Conclusions: COBEST demonstrates covered and bare-metal stents produce similar and acceptable results for TASC B lesions. However, covered stents perform better for TASC C and D lesions than bare stents in longer-term patency and clinical outcome. (J Vasc Surg 2011;54:1561-70.)

Aortoiliac arterial occlusive disease is frequently encountered in the management of lower limb vascular insufficiency. Surgical reconstruction of the aortoiliac segment was initially performed using thromboendarterectomy¹;

however, advances in graft technology have made bypass procedures more commonly performed and durable. Distal aortic bypass has a reported surgical mortality of 4%, with major complications seen in up to 21% of patients.²⁻⁷

From the Department of Vascular Surgery, Royal Perth Hospital, Perth, Western Australia^a; School of Surgery, Faculty of Medicine, Dentistry and Health Sciences, University of Western Australia, Perth, Western Australia^b; Lung Institute of Western Australia and School of Medicine and Pharmacology, University of Western Australia, Perth, Western Australia^c; Department of Vascular Surgery, Gold Coast Hospital, Gold Coast, Queensland^d; and Department of Biostatistics, School of Medicine and Pharmacology, Royal Perth Hospital and University of Western Australia, Perth, Western Australia.^e

*COBEST co-investigators: Dr Marek Garbowski, Dr Glen Benveniste, Dr Michael Denton, Dr John Anderson, Dr Steve Dubenecc, Dr Michael Neale, Dr Vikram Puttaswamy, Prof John Fletcher, and Prof Geoffrey White.

Atrium Medical Corporation provided funding for the employment of a research assistant and had no role in study design, data collection, data interpretation, or writing of the report. The corresponding author had full access to all the data in the study, and the authors had final responsibility for the decision to submit for publication.

Competition of interest: Dr Mwiapatayi and Dr Jackson have received research-funding assistance from Atrium Medical Corporation.

Presented at the VIVA meeting, Las Vegas, Nev, October 19-23, 2009; the LINC meeting, Leipzig, Germany, January 25-28, 2010; C3 meeting, Baltimore, Md, June 20-24, 2010; ANZSVS Vascular Meeting, Gold Coast, State, Country, August 2-5, 2010; 10th China National Annual Congress of Vascular Surgery, Nanjing, China, September 24-26, 2010; Veith meeting, New York, NY, November 17-21, 2010; and CACVS 2011 Congress, Paris, France, January 27-29, 2011.

Additional material for this article may be found online at www.jvascsurg.org. Correspondence: Prof B. Patrice Mwiapatayi, University of Western Australia, School of Surgery, Royal Perth Hospital, Department of Vascular Surgery, Level 2, MRF Bldg, Perth, Western Australia, Australia (e-mail: bibombe@iinet.net.au; patrice.mwiapatayi@uwa.edu.au).

The editors and reviewers of this article have no relevant financial relationships to disclose per the JVS policy that requires reviewers to decline review of any manuscript for which they may have a competition of interest.

0741-5214/\$36.00

Crown Copyright © 2011 Published by Elsevier Inc. on behalf of the Society for Vascular Surgery. All rights reserved.

doi:10.1016/j.jvs.2011.06.097

Although a laparoscopic approach may decrease this mortality and morbidity, this technique has yet to become common place.⁸

Currently, the decision to perform an endovascular procedure or open surgical bypass depends on various factors, most importantly, the severity and anatomic distribution of disease. The TransAtlantic Inter-Society Consensus (TASC) I and II working group published a consensus of recommendations for management of peripheral arterial disease.^{9,10} The recommendation for patients with focal or short lesions (ie, TASC A and TASC B lesions) is endovascular intervention with an evidence basis suggesting long-term patency rates close to 80% at 2 years and 60% at 5 years.^{11,12} Lower patency rates with TASC C and D lesions led to the recommendation for an open surgical approach, except in patients deemed to be high-risk.

The use of covered stents to treat aortoiliac occlusive disease has been proposed as a method to reduce intimal hyperplasia and improve patency rates.¹³⁻¹⁵ Although the results of numerous reports are promising, present evidence is insufficient to support their widespread application. Currently, covered stent use is largely reserved for the treatment of aneurysms, ruptures, and arteriovenous fistulas.¹⁶⁻¹⁸ No published randomized controlled trials (RCTs) to date have compared the efficacy of covered stents vs bare-metal stents (BMSs) for aortoiliac occlusive disease. We hypothesized that via intimal exclusion, covered stents will provide a patency advantage and improved clinical outcome in advanced iliac occlusive disease compared with BMS.

METHODS

Study design. The Covered Versus Balloon Expandable Stent Trial (COBEST) was a prospective, multicenter, RCT (registration number: ISRCTN89458845) comparing the use of the Advanta V12 balloon-expandable covered stent (Atrium Medical Corp, Hudson, NH) with commercially available bare-metal stents (BMS) in patients with aortoiliac occlusive disease. The study was conducted between January 2006 and December 2008 with 13 physicians (11 vascular surgeons and 2 interventional radiologists) at eight major centers across Australia. The study design allowed an assessment of the safety and efficacy of covered stents vs BMSs in the treatment of hemodynamically significant aortoiliac occlusive disease. In particular, COBEST aimed to determine if the theoretical advantage of covered stents resulted in clinical improvements.

The institutional review board and ethics committees at each hospital approved the study protocol, and written informed consent was obtained from all patients before enrollment. The criterion for study entry and exclusion are listed in Table I.

Study end points. The primary study end point was the rate of binary restenosis (defined by $\geq 50\%$ reduction in lumen diameter) and freedom from stent occlusion at 18 months. These were determined by duplex ultrasound (DUS) imaging of the aortoiliac segment, computed tomography angiography (CTA), or catheter biplane digital subtraction angiography (DSA). Patients were assessed

Table I. Inclusion and exclusion criteria for the Covered Versus Balloon Expandable Stent study

Inclusion criteria

- Men and women aged ≥ 18 years
- Informed consent obtained
- Evidence of TASC B, C, or D lesions
- Hemodynamically significant dissections and recurrent stenosis after angioplasty

Exclusion criteria

- Life expectancy < 12 months (patients had to be followed up for at least 18 months)
- Uncontrolled hypertension
- TASC A lesion
- Pregnant women or women of childbearing potential who were not using an effective method of contraception
- Prior enrollment in this trial, or a patient who had had any procedure performed at the aortoiliac level
- Extensive common femoral artery disease or multiple groin procedures
- Contraindication to aspirin or clopidogrel usage
- Occluded superficial and profunda femoral arteries
- Mental condition rendering the individual unable to understand the nature, scope and possible consequences of the study, or a language barrier preventing the individual from providing informed consent
- Uncooperative attitude or potential for noncompliance with the protocol requirements, making study participation impractical

TASC, TransAtlantic Inter-Society Consensus.

clinically with an ankle-brachial index (ABI) and aortoiliac arterial DUS at intervals of 1, 6, 12, and 18 months. If the DUS scan was inconclusive, a CTA or DSA, or both, were performed using a prespecified protocol to determine if the primary end point had been achieved.

The secondary end points were determined anatomically, clinically, and hemodynamically. Anatomic end points included stent patency, as assessed by the TASC B, C, and D classification, stent integrity, and target vessel revascularization (TVR), defined as any repeat percutaneous intervention or surgical bypass of any segment of the target vessel. The target vessel was defined as the entire aortoiliac vessel proximal and distal to the target lesion. TVR was typically driven by clinical evidence of symptoms or positive stress-induced significant symptoms (treadmill exercise ABI).

The clinical end points were major amputation above the ankle and major adverse events resulting in patient hospitalization or prolongation of existing hospitalization, significant physical disability, or death. The hemodynamic end point was a change in ABI between baseline and measurements at 1, 6, 12, and 18 months.

Randomization. Eligible patients were randomized to receive a covered stent or a BMS by an online computerized randomization program (<https://io.atriummed.com/Cobest/default.aspx>). Unstratified randomization was used to randomize patients in a 1:1 ratio with a minimization algorithm to allow balanced allocation of participants across intervention groups. All randomized patients were irrevocably included in the study, regardless of eligibility or

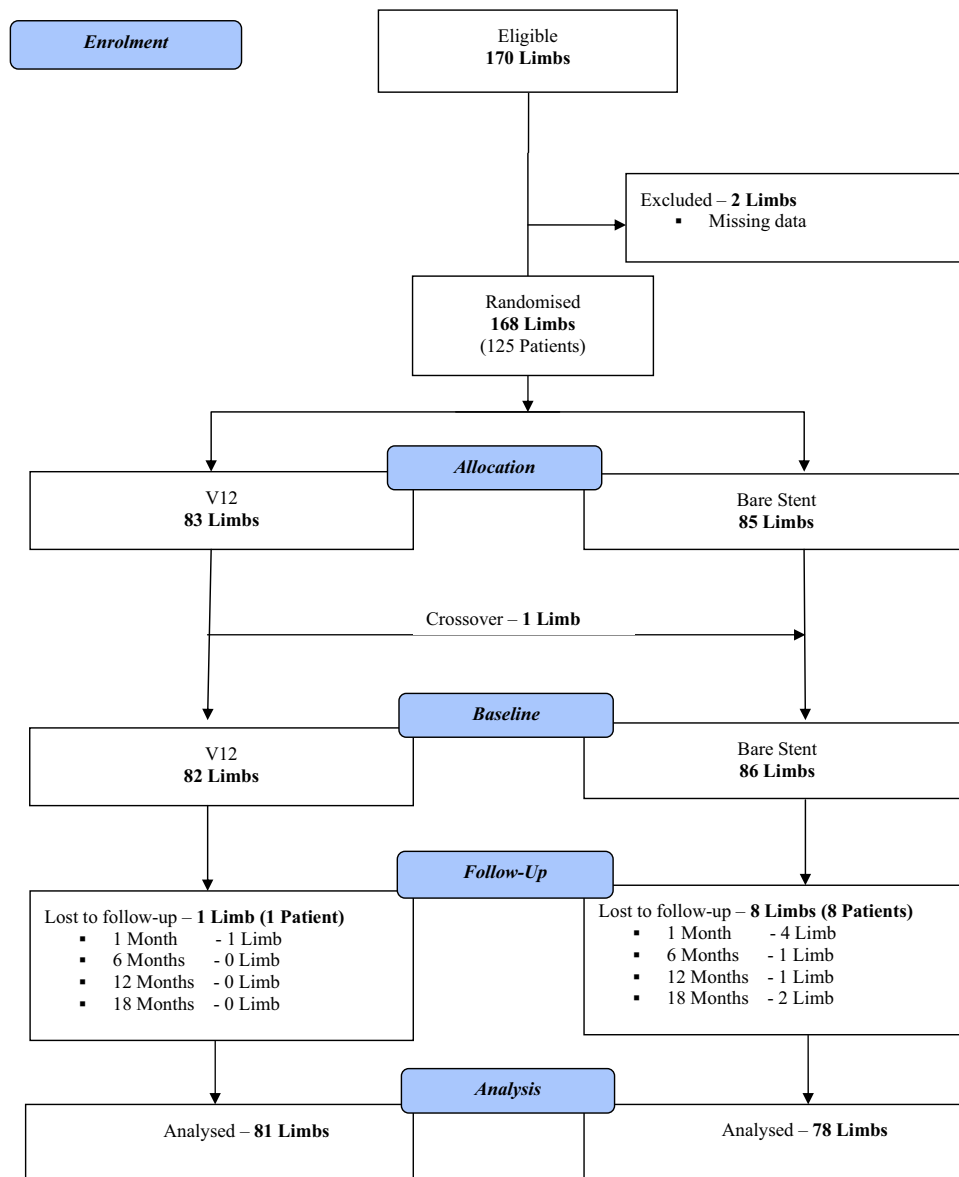


Fig 1. Flow chart shows the trial profile, including descriptions of the patients enrolled in the study and patients who were lost to follow-up.

if they received the allocated treatment, and were monitored for 18 months. A subgroup of patients had bilateral lesions and each side of the iliac artery disease (left or right) was randomized in these patients rather than the patient per se.

Stents. The investigational devices consisted of the Advanta V12 covered stent and commercially available BMSs. The Advanta V12 is encapsulated with expanded polytetrafluoroethylene (ePTFE), premounted on an Aneria noncompliant balloon (Atrium Medical Corp), and compatible with a 6F to 7F sheath. Stents were sized perioperatively, with covered and BMS oversized by 1 mm beyond the calculated diameter of the iliac artery treated.

The BMS used was chosen at the discretion of the interventionist, but Australian Therapeutic Goods Administration approval was required. The bare-metal balloon-expandable stents used included Palmaz Genesis (Cordis Corp, East Bridgewater, NJ) in 32.5%, Express LD iliac stent (Boston Scientific, Natick, Mass) in 28%, Assurant Cobalt iliac stent (Medtronic, Minneapolis, Minn) in 18.6%, Peiron (Biotronik, Berlin, Germany) in 12.8%, and AVE-Bridge (Medtronic) in 2.3%. The two self-expandable BMSs used were the Smart (Cordis Corp) in 3.5% and Edwards Life Stent (Bard Peripheral Vascular Inc, Tempe, Ariz) in 2.3%. No drug-eluting stents were used.

Table II. Characteristics of the study patients at baseline according to treatment groups

Characteristic ^a	V12 stent (n = 83)	Bare stent (n = 85)
Patients, No.	62	63
Age, years	65.34 ± 1.43	67.21 ± 1.29
Male sex	67.7	57.1
Race		
White	96.8	95.2
Aboriginal	1.6	1.6
Asian	1.6	3.2
Side of lesion		
Left	59.0	42.4
Right	39.8	56.5
Central	1.2	1.1
Rutherford-Becker		
Category 1	3.2	4.8
Category 2	27.4	30.2
Category 3	40.3	50.8
Category 4	24.2	12.7
Category 5	4.8	1.6
Risk factors		
Diabetes	24.2	28.6
Hypertension	56.5	71.4
Smoking	59.7	58.7
Hyperlipidemia	41.9	46.0
Chronic renal failure	3.2	3.2
COAD	9.7	9.5
Coronary artery disease	37.1	38.1
Hypercoagulable states	6.5	3.2
Pre-op antiplatelets		
Aspirin	88.7	93.7
Clopidogrel	87.1	84.1
	9.7	19.0

COAD, Chronic obstructive airway disease.

^aContinuous data are expressed as mean ± standard error of the mean, and categorical data as number or percentage.

Medical therapy. All patients received aspirin (100-150 mg daily) indefinitely and clopidogrel (75 mg daily) for a minimum of 1 month after the intervention. A 300-mg loading dose of clopidogrel was given during or after the intervention.

Study procedures. Access to the iliac lesion was achieved at the investigator's discretion via an antegrade approach from the contralateral femoral artery with the use of a dedicated 6F or 7F "cross-over" sheath or via a retrograde (ipsilateral) approach. A brachial approach was used at the discretion and experience of the investigator using a Shuttle sheath (Cook Medical, Bloomington, Ind). After sheath placement, a heparin bolus (3000-5000 units) was administered intravenously.

DSA was performed to assess and confirm the DUS imaging or CTA findings. The patency status of the ipsilateral femoral, popliteal, and infrapopliteal arteries was documented. After the target lesion was successfully crossed with a hydrophilic 0.018-inch or 0.035-inch wire, patients were randomized and received a covered balloon-expandable stent or a BMS.

At baseline and each follow-up, all patients were stratified by symptoms according to categories outlined previously by Rutherford et al.¹⁹ The status of the runoff vessels

Table III. Clinical and radiologic characteristics of the study patients at baseline according to treatment groups

Characteristic ^a	V12 stent (n = 83)	Bare stent (n = 85)
Preoperative assessment		
Resting ABI (side of lesion)	0.65 ± 0.03	0.63 ± 0.03
No.	75	78
Duplex scan		
Performed	62 (74.7)	65 (76.5)
>50% stenosis	87.1	81.5
Occlusion	12.9	18.5
Angiogram		
Performed	67 (80.7)	73 (85.9)
TASC B	50.7	72.6
TASC C	34.3	20.5
TASC D	14.9	6.8
CT angiogram		
Performed	32 (38.6)	36 (42.4)
TASC B	56.3	63.9
TASC C	31.3	30.6
TASC D	12.5	5.6
Runoff		
Performed	74 (89.1)	73 (85.9)
0	0	1.4
1	12.2	5.5
2	20.3	21.9
3	23.0	37.0
4	44.6	34.2

ABI, Ankle-brachial index; TASC, TransAtlantic Inter-Society Consensus.

^aData are number (%) or mean ± standard error of the mean.

was determined using an objective scoring system.¹⁹ The superficial and deep femoral arteries, which are the runoff vessels for iliac artery procedures, were evaluated by the presence of an occlusion or stenosis, or if they were patent.

Mandatory clinical evaluations combined with measurement of ABIs were performed at each postprocedural follow-up at 1, 6, 12, and 18 months. DUS imaging of the aortoiliac segment was also performed at each visit. Binary restenosis was defined by a doubling of peak systolic velocities (PSV) across a lesion or a PSV >300 cm/s with monophasic Doppler waveforms in the distal common femoral artery.²⁰⁻²² Medical events, hospitalizations, access interventions, and adverse events were documented.

Statistical analysis. Sample size was calculated using the method proposed by Armitage et al.²³ Because there has been no previous RCT comparison between groups with the two types of stent, an initial limit of noninferiority between the two groups was estimated to be 10% of the true population restenosis rate, which we assumed to be 6%. With power set at 80% and α set at 5% (on a two-sided test), the number of iliac arteries required was calculated to be 70 in each group, giving a total of 140 limbs. To compensate for patients lost to follow-up, we included an additional 14 limbs. Thus, the total target sample size was calculated to be at least 154 limbs. One patient did not receive the allocated treatment (cross-over treatment). This was a conscious decision by the surgeon because the randomized stent was not available.

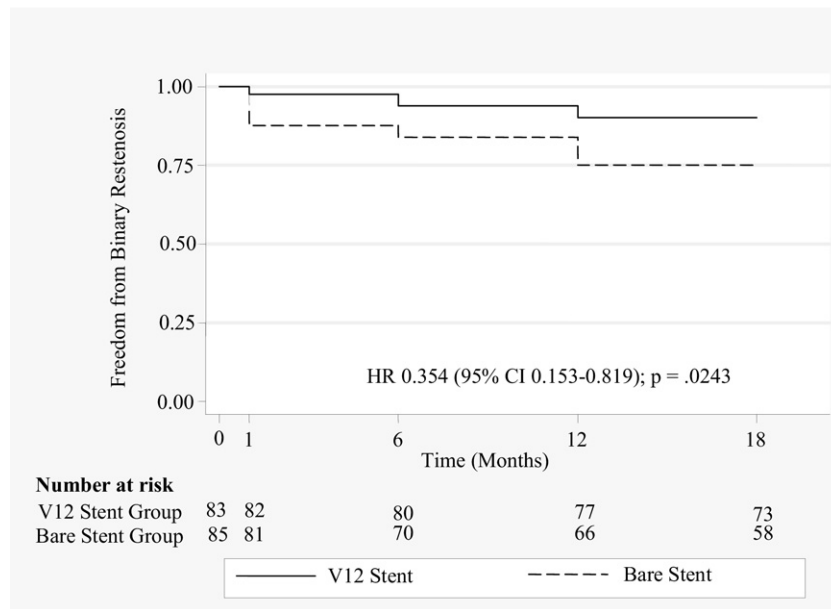


Fig 2. Kaplan-Meier curves are shown for freedom from binary restenosis for the intention-to-treat population. The sandwich variance estimate method (Lin and Wei) was used to determine the log-rank test adjusted for clustering ($P = .0243$). *CI*, Confidence interval; *HR*, hazard ratio.

Because this patient did not receive the allocated treatment, we undertook two main analyses. An intention-to-treat analysis was performed for all baseline and primary end point data for all randomized patients irrespective of whether the patient received the randomized study device or the patient's compliance with the study protocol. A per-protocol analysis was performed for all subgroup analyses and secondary end point data because the one crossover patient's data did not create any difference between the intention-to-treat analysis and the per-protocol analysis.

Baseline characteristics of the two groups were described using means and standard errors (SE) for continuous data and proportions for qualitative variables. Freedom from binary restenosis and freedom from stent occlusion at 1, 6, 12, and 18 months were analyzed with the use of Kaplan-Meier survival estimates. Cox proportional hazards models were used to determine if differences between the estimates were significant after establishing the requisite proportional hazards assumptions were met. Alternative end points, occlusion, and binary restenosis at 18 months, were analyzed using logistic regression.

Subgroup analyses of both restenosis end points were performed by testing the interaction of subgroup and randomized treatment. There were insufficient numbers of vessels with an occlusion for subgroup analysis to be performed. Logistic regression was also used to investigate the differences in proportions of patients with limb amputation between the two randomized groups. Results are reported as hazard ratios (HR) or odds ratios (OR) with 95% confidence intervals (CI).

When two iliac arteries from the same patient were randomized, it was necessary to recognize that the vessels were genetically identical and therefore the outcomes would be correlated. To adjust for the intracluster correlation, robust sandwich estimators, as proposed by Lin and Wei (1989),²⁴ were used to produce cluster adjusted SEs and P values for all logistic regression and survival analyses. Analysis of the change in ABI indexes and TVR over time was performed using a hierarchic longitudinal mixed-models analysis. The interaction between randomized treatment and time was used to determine if there were differences in the treatment slopes over time for the linear ABI model. The small number of TVR cases precluded investigation of the interaction in the logistic model.

All hypotheses tests were performed using two-sided tests, and the critical value for statistical significance was set at a value of $P < .05$. Analyses were conducted using PASW 18 (SPSS, Chicago, Ill), SAS 9.2 (SAS Institute Inc, Cary, NC), and Stata 11 (StataCorp LP, College Station, Tex) statistical software.

RESULTS

The trial recruited 125 patients (168 individual iliac arteries). Randomization assigned 83 vessels to receive a covered stent and 85 to receive a BMS (Fig 1). Patients were assessed at the prespecified intervals for 18 months. One patient in the covered-stent group and eight in the BMS group were lost to follow-up.

At baseline, demographic and clinical characteristics were similar between the two groups, with no significant differences in the frequency of atherothrombotic risk fac-

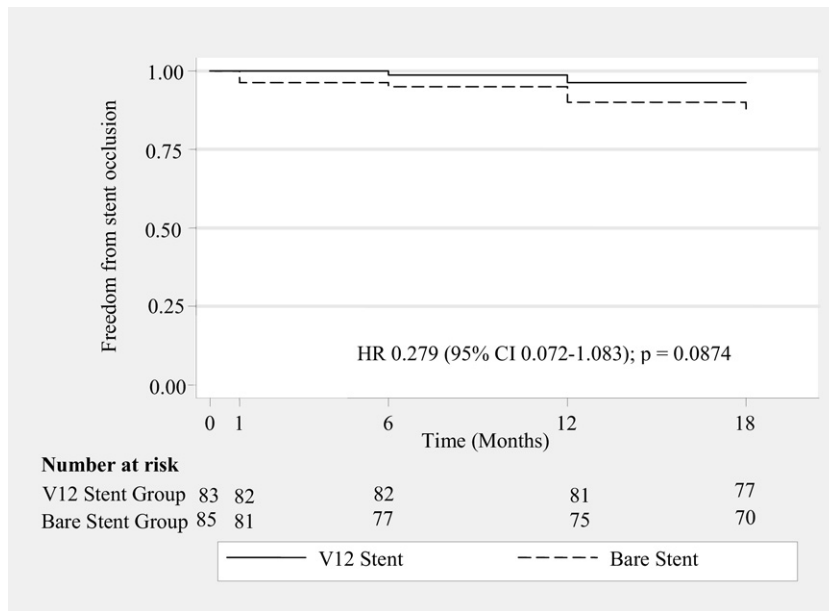


Fig 3. Kaplan-Meier curves are shown for freedom from stent occlusion for the intention-to-treat population. The sandwich variance estimate method was used to determine the log-rank test adjusted for clustering ($P = .0874$). *CI*, Confidence interval; *HR*, hazard ratio.

tors or coexisting cardiovascular conditions (Table II). Most patients in both groups were already receiving antiplatelet agents, and only three patients were taking oral anticoagulation medications (Table II). In the BMS group, Palmaz Genesis, Express LD, Assurant Cobalt, and Peiron stents were used predominantly.

Preoperative imaging demonstrated 72.6% in the BMS group had TASC B lesions vs 50.7% in the covered-stent group (Table III).

Procedural complications included hemorrhage, flow-limiting dissection, lymph leak, and seroma formation, with no statistical significance between the groups. Intravascular anticoagulation was administered to 97.6% of patients during the procedure. No conversions to open aortoiliac surgery during the perioperative period were reported. Procedural success, defined as <30% residual stenosis during the angiographic intervention, was achieved in 100% of cases in both groups.

Primary outcome. Aortoiliac lesions treated with a covered stent were significantly more likely to remain free from binary restenosis at 18 months than those that were treated with a BMS (HR, 0.35; 95% CI, 0.15-0.82; $P = .02$). Binary restenosis was documented in 8 arteries in the covered-stent group and in 20 in the BMS group (Fig 2). Complete occlusions of the stented lesion during the follow-up period occurred in 3 patients in the covered-stent group and in 10 patients in the BMS group; however, this difference was not statistically significant (HR, 0.28; 95% CI, 0.07-1.09; $P = .07$; Fig 3).

Subgroup analyses. The subgroup analysis specifically looked at freedom from binary restenosis according to the initially designated TASC lesions. A significant interaction

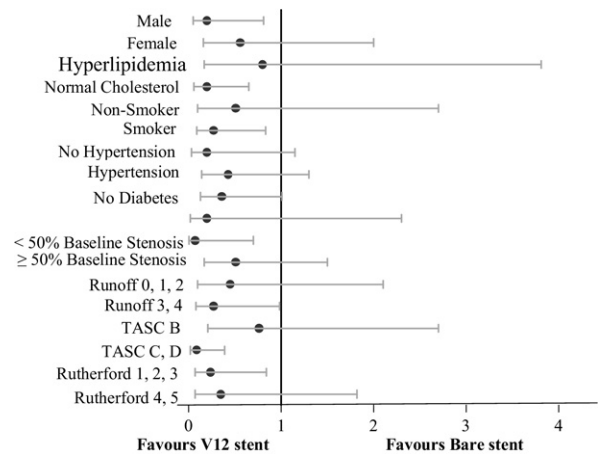


Fig 4. Odds ratios of 18-month restenosis of >50% in selected patient subgroups. For most of the variables, the 95% confidence interval crosses the line of identity, indicating lack of statistical significance. The probability values for interaction indicate that only TransAtlantic Inter-Society Consensus (TASC) variables interacted on the level of statistical significance with the treatment modality.

was found between the TASC classification and the stent type for binary restenosis at 18 months ($P = .03$). None of the factors investigated were significant (Fig 4). This study was not powered to investigate interactions; hence, further research is required to confirm these results. The Kaplan-Meier survival estimates showed a statistically significant benefit when covered stents were used in TASC C and D

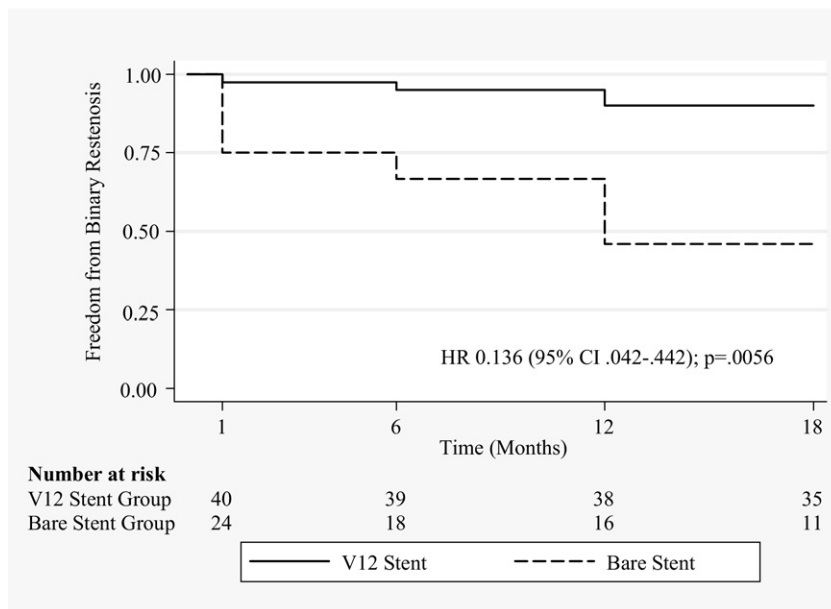


Fig 5. Kaplan-Meier curves are shown for freedom from binary restenosis for the type of stent used according to the TransAtlantic Inter-Society Consensus (TASC) C/D group. The sandwich variance estimate method was used to determine the log-rank test adjusted for clustering ($P = .0056$). *CI*, Confidence interval; *HR*, hazard ratio.

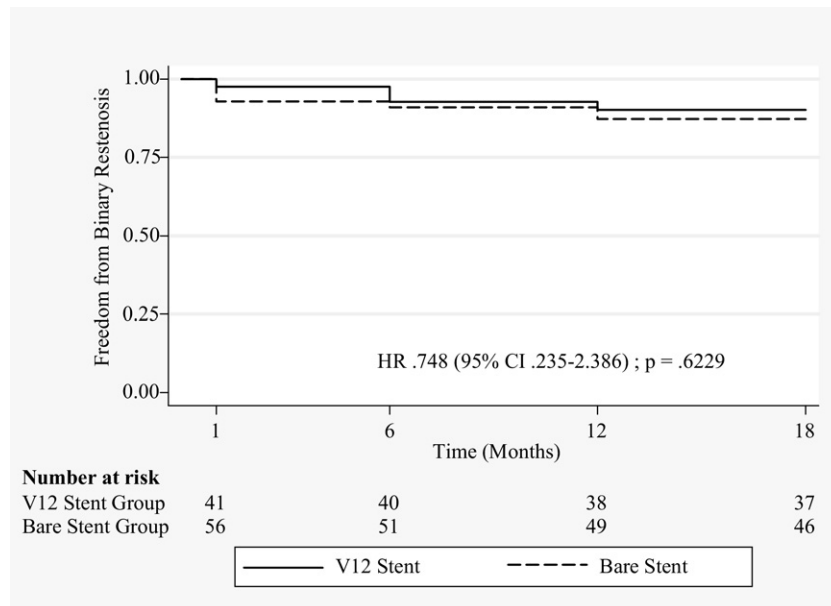


Fig 6. Kaplan-Meier curves are shown for freedom from binary restenosis for the type of stent used according to the TransAtlantic Inter-Society Consensus (TASC) B group. There is no statistical difference between the two stents in patients with TASC B lesion. *CI*, Confidence interval; *HR*, hazard ratio.

lesions compared with BMSs (HR, 0.136; 95% CI, 0.042-0.442; Fig 5; Appendix Fig, online only). However, this significant difference in freedom from binary restenosis was not demonstrated for TASC B lesions (HR, 0.748; 95% CI, 0.235-2.386; Fig 6).

The 44 patients who had bilateral iliac artery stenting were randomized to receive 43 covered stents (SE, 0.473; 95% CI, 16.399-18.252) and 45 BMSs (SE, 0.970; 95% CI, 12.304-16.106). The same stent was allocated to both limbs in 20 of the 44 patients. The overall freedom from

Table IV. Resting ankle-brachial index (ABI) on side of the lesion

Resting ABI	V12 stent		Bare stent		P
	No.	Mean \pm SEM	No.	Mean \pm SEM	
Baseline	75	.65 \pm .03	78	.63 \pm .03	.639
1 month	71	.91 \pm .03	72	.91 \pm .03	.927
6 months	73	.89 \pm .02	74	.88 \pm .03	.653
12 months	75	.94 \pm .02	79	.85 \pm .03	.014
18 months	70	.94 \pm .02	73	.86 \pm .03	.07

SEM, Standard error of the mean.

binary restenosis demonstrated that there was significantly less restenosis in covered stents compared with the BMSs (HR, 0.14; 95% CI, 0.03-0.61; $P = .009$). The interaction of TASC group and randomized stent was not significant ($P = .23$).

Secondary outcomes. ABI measurements during the follow-up period were not significantly different between the two groups at 1 and 6 months. However, the difference became statistically significant at 12 months ($P = .014$) and had marginal significance at 18 months ($P = .06$), suggesting long-term improvement in ABIs in the covered-stent group (Table IV).

TVR during the study period demonstrated that there was less reintervention in the covered-stent group compared with the BMS group (OR, 21; 95% CI, 0.07-0.64; $P = .006$). Most of the reinterventions were performed at 12 and 18 months (Fig 7). Three patients from the BMS group underwent aortobifemoral bypass grafting.

Four amputations were performed during the study period. Two patients with covered stents had below knee amputation at 18 months, which was likely related to uncontrollable diabetes mellitus and progression of infragenicular arterial disease. Two patients with BMSs had above knee amputations at 18 months due to a combination of factors. The difference between the two groups was not statistically significant (OR, 1.02; 95% CI, 0.089-11.73; $P = .984$).

A left brachial artery approach was used in 10 patients, with 1 patient requiring the use of the Outback LTD re-entry catheter (Cordis Corp), with a successful outcome. None of these patients had any major complications (no cerebral ischemic event or vessel perforation) related to the approach used. Multiple associated procedures were performed during iliac artery stenting: femoropopliteal bypass graft in five patients, common femoral artery endarterectomy in four, and superficial femoral artery stenting in four. External iliac artery stenting was performed in 14 patients, with successful outcome at 12 and 18 months.

DISCUSSION

The COBEST trial is the first RCT to compare covered stents and BMSs in the management of aortoiliac occlusive disease. Previous studies have compared different types of BMSs deployed in iliac arteries and failed to demonstrate any significant differences in technical success and

follow-up outcomes.²⁵⁻²⁷ The only published randomized study comparing primary angioplasty, followed by selective or primary stent placement in patients with iliac artery obstructive disease, is the Dutch Iliac Stent Trial (DIST). The short-term and long-term DIST results indicated that selective stent placement should be considered as the treatment of choice.¹¹

Angioplasty is a less invasive alternative treatment to open bypass surgery and proven efficacy for the treatment of patients with focal iliac artery stenosis. The procedural technical success rate has improved significantly (up to 95%), especially when adjunctive stent placement is used. Patency rates of 80% to 90% after 5 years have been reported for short iliac stenoses, which is comparable with patency results for open surgery.^{28,29} For complex, multifocal, or totally occluded atherosclerotic segments of iliac arteries (C and D lesions), TASC recommends surgery as the procedure of choice.¹⁰

Since their first applications by Dotter, endovascular metallic stent placement has been widely used for the treatment of patients with aortoiliac occlusive disease.^{30,31} Vorwerk et al^{32,33} reported 4-year patency rates of 78% and 82% for primary and secondary stenting procedures, respectively, in 100 patients. Cikrit et al³⁴ reported a 5-year patency rate of 63% in 38 limbs that were treated by Palmaz stent placement, whereas Palmaz et al²⁵ initially reported a 92% patency rate at 9 months. Primary 4-year patency rates as high as 86% were recently reported.^{25,31}

Covered stents are able to exclude plaque and endothelium, thereby potentially mitigating late luminal loss by halting migration and proliferation of vascular smooth muscle cells and inflammatory cells through open stent struts.³⁵ This may result in a reduction of restenosis caused by luminal encroachment from extracellular matrix deposition intimal hyperplasia.^{15,36} BMSs do not provide a boundary that excludes the underlying plaque from the lumen, and stent oversizing relative to the reference lumen causes an increase in neointimal growth. Covered stents may also offer the benefit of being less thrombogenic than BMSs. In the United States, no covered stents are currently approved by the U.S. Food and Drug Administration for application in the iliac arteries for occlusive disease. However, homemade covered stents, iliac limbs from modular aortic stent grafts, and commercially manufactured covered stents approved for other nonvascular indications have been placed in the iliac arteries. Because of the bulk of the additional graft material, covered stents require larger delivery systems than BMSs. This may expose the patient to a higher risk of groin complications.

The restenosis observed in the covered-stent group was predominantly located at the ends of the stent or outside the stent. We hypothesize that this may be secondary to compliance mismatch due to the use of the rigid end of the covered stent and balloon dilatation causing the increased stent-artery interface intimal hyperplasia. In addition, the stent may not cover the lesion fully, resulting in progression of the atherosclerotic process by activation from balloon inflation but with the end of the balloon inflated firstly

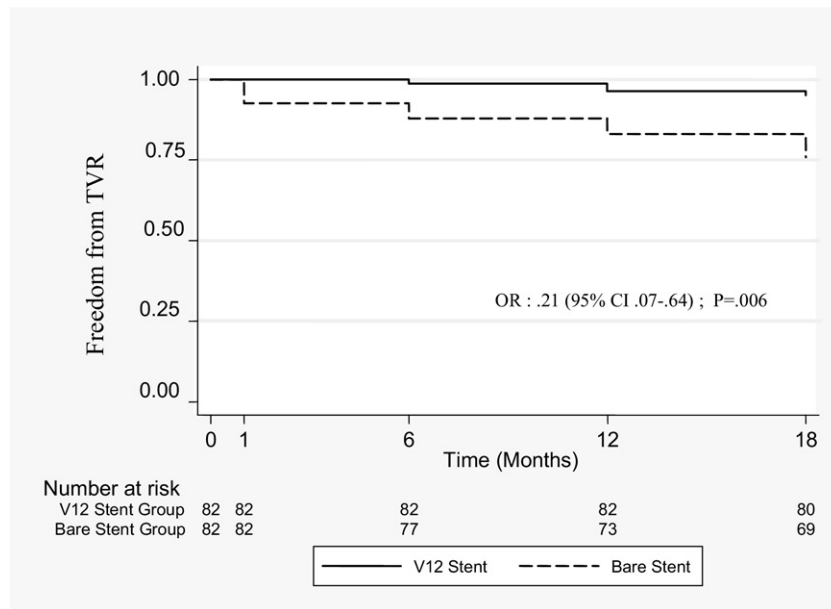


Fig 7. Kaplan-Meier curves for freedom from target vessel revascularization during the study period showed fewer reinterventions occurred in the covered-stent group ($P = .006$ at 12 months). *CI*, Confidence interval; *OR*, odds ratio; *TVR*, target vessel revascularization.

outside of the stent causing a process known as the “dog bone” effect.

We have identified three major limitations in this study: First, the different stent types used in the BMS group may have affected the results and led to bias. It was impractical in the context of a multicenter study to limit the BMS type. We suggested current practices and protocols within trial centers should continue unchanged, with the type of BMS selected left to the individual operator.

Second, the BMS group had fewer patients with a TASC D lesion (7%) compared with the covered-stent group (16.1%), which, despite the randomization, may have influenced the results.

Third, DUS was the principal imaging tool used for follow-up, which may have introduced bias because it is highly operator-dependent. We decided to use DUS imaging because we were reluctant to unnecessarily use invasive investigations if not clinically required.

CONCLUSIONS

There is increasing evidence from single-center clinical investigations that patients with complex aortoiliac lesions, including chronic iliac artery occlusions and occlusion of the aortoiliac bifurcation, can be treated safely and effectively with a covered stent. The COBEST results demonstrate that for patients with severe aortoiliac arterial occlusive disease, there is an increased freedom from restenosis and occlusion with covered stents compared with BMSs at 12 and 18 months. However, long-term durability data (5-year follow-up) is desirable.

We thank Dr Michael Phillips for his statistical advice.

AUTHOR CONTRIBUTIONS

Conception and design: BM
Analysis and interpretation: BM, JW, ST
Data collection: MJ, JW, ST
Writing the article: BM, ST, JW, ST, VV
Critical revision of the article: VV, ST,
Final approval of the article: BM, VV
Statistical analysis: BM, ST, SB
Obtained funding: BM, MJ
Overall responsibility: BM

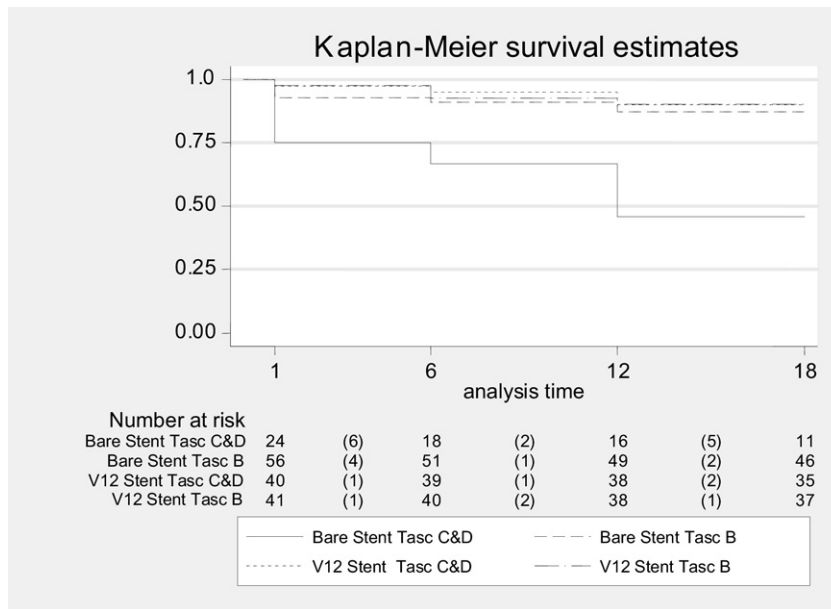
REFERENCES

1. Wylie EJ. Thromboendarterectomy for arteriosclerotic thrombosis of major arteries. *Surgery* 1952;32:275-92.
2. de Vries SO, Hunink MG. Results of aortic bifurcation grafts for aortoiliac occlusive disease: a meta-analysis. *J Vasc Surg* 1997;26:558-69.
3. Littooy FN, Steffan G, Steinam S, Saletta C, Greisler HP. An 11-year experience with aortofemoral bypass grafting. *Cardiovasc Surg* 1993;1:232-8.
4. Schneider JR, Besso SR, Walsh DB, Zwolak RM, Cronenwett JL. Femorofemoral versus aortobifemoral bypass: outcome and hemodynamic results. *J Vasc Surg* 1994;19:43-55.
5. Huber TS, Harward TR, Flynn TC, Albright JL, Seeger JM. Operative mortality rates after elective infrarenal aortic reconstructions. *J Vasc Surg* 1995;22:287-93.
6. Erdoes LS, Bernhard VM, Berman SS. Aortofemoral graft occlusion: strategy and timing of reoperation. *Cardiovasc Surg* 1995;3:277-83.
7. Passman MA, Taylor LM, Moneta GL, Edwards JM, Yeager RA, McConnell DB, et al. Comparison of axillofemoral and aortofemoral bypass for aortoiliac occlusive disease. *J Vasc Surg* 1996;23:263-9.
8. Rouers A, Meurisse N, Lavigne JP, Francart D, Quaniers J, Desiron Q, et al. Potential benefits of laparoscopic aorto-bifemoral bypass surgery. *Acta Chir Belg* 2005;105:610-5.

9. Dormandy JA, Rutherford RB. Management of peripheral arterial disease (PAD). TASC Working Group. TransAtlantic Inter-Society Consensus (TASC). *J Vasc Surg* 2000;31:S1-296.
10. Norgren L, Hiatt WR, Dormandy JA, Nehler MR, Harris KA, Fowkes FG, et al. Inter-Society Consensus for the Management of peripheral Arterial Disease (TASC II). *J Vasc Surg* 2007;45(Suppl 1):S5-67.
11. Tetteroo E, van der Graaf Y, Bosch JL, van Engelen AD, Hunink MG, Eikelboom BC, et al. Randomized comparison of primary stent placement vs primary angioplasty followed by selective stent placement in patients with iliac artery obstructive disease. *Lancet* 1998;351:1153-9.
12. Bosch JL, Hunink MG. Meta-analysis of the results of percutaneous transluminal angioplasty and stent placement for aortoiliac occlusive disease. *Radiology* 1997;204:87-96.
13. Marin ML, Veith FJ, Cynamon J, Parsons RE, Lyon RT, Suggs WD, et al. Effect of polytetrafluoroethylene covering of Palmaz stents on the development of intimal hyperplasia in human iliac arteries. *J Vasc Interv Radiol* 1996;7:651-6.
14. Palmaz J. Intravascular stents: tissue-stent interactions and design considerations. *Am J Roentgenol* 1993;160:613-8.
15. Diethrich EB. Polymeric covers and coats for metallic stents: microporous PTFE and the inhibition of intimal hyperplasia. *J Endovasc Surg* 1995;2:266-71.
16. Henry M, Amor M, Henry I, Klonaris C, Tzvetanov K, Buniet JM, et al. Percutaneous endovascular treatment of peripheral aneurysms. *J Cardiovasc Surg (Torino)* 2000;41:871-83.
17. Ohki T, Veith FJ. Five-year experience with endovascular grafts for the treatment of aneurysmal, occlusive and traumatic arterial lesions. *Cardiovasc Surg* 1998;6:552-65.
18. Wiesinger B, Beregi JP, Oliva VL, Dietrich T, Tepe G, Bosiers M, et al. PTFE-covered self-expanding nitinol stents for the treatment of severe iliac and femoral artery stenoses and occlusions: final results from a prospective study. *J Endovasc Ther* 2005;12:240-6.
19. Ahn SS, Rutherford RB, Becker GJ, Comerota AJ, Johnston KW, McClean GK, et al. Reporting standards for lower extremity arterial endovascular procedures. Society for Vascular Surgery/International Society for Cardiovascular Surgery. *J Vasc Surg* 1993;17:1103-7.
20. Zeller T, Tiefenbacher C, Steinkamp HJ, Langhoff R, Wittenberg G, Schlüter M, et al. Nitinol stent implantation in TASC A and B superficial femoral artery lesions: the Femoral Artery Conformexx Trial (FACT). *J Endovasc Ther* 2008;15:390-8.
21. Krankenberg H, Schlüter M, Steinkamp HJ, Bürgelin K, Scheinert D, Schulte KL, et al. Nitinol stent implantation versus percutaneous transluminal angioplasty in superficial femoral artery lesions up to 10 cm in length: the femoral artery stenting trial (FAST). *Circulation* 2007;116:285-92.
22. Diehm N, Pattynama PM, Jaff MR, Cremonesi A, Becker GJ, Hopkins LN, et al. Clinical endpoints in peripheral endovascular revascularization trials: a case for standardized definitions. *Eur J Vasc Endovasc Surg* 2008;36:409-19.
23. Armitage P, Berry G, Matthews J. *Statistical methods in medical research*. Oxford: Blackwell Science; 2002. p. 137-46.
24. Lin DY, Wei LJ. The robust inference for the Cox proportional hazards model. *J Am Stat Ass* 1989;84:1074-8.
25. Palmaz JC, Laborde JC, Rivera FJ, Encarnacion CE, Lutz JD, Moss JG. Stenting of the iliac arteries with the Palmaz stent: experience from a multicenter trial. *Cardiovasc Intervent Radiol* 1992;15:291-7.
26. Strecker EP, Hagen B, Liermann D, Schneider B, Wolf HR, Wambsgans J. Iliac and femoropopliteal vascular occlusive disease treated with flexible tantalum stents. *Cardiovasc Intervent Radiol* 1993;16:158-64.
27. Long AL, Sapoval MR, Beyssen BM, Auguste MC, Le Bras Y, Raynaud AC, et al. Strecker stent implantation in iliac arteries: patency and predictive factors for long-term success. *Radiology* 1995;194:739-44.
28. Motarjeme A, Keifer JW, Zuska AJ. Percutaneous transluminal angioplasty of the iliac arteries: 66 experiences. *AJR Am J Roentgenol* 1980;135:937-44.
29. Scheinert D, Schröder M, Ludwig J, Bräunlich S, Möckel M, Flachs-kampf FA, et al. Stent-supported recanalization of chronic iliac artery occlusions. *Am J Med* 2001;110:708-15.
30. Szilagyi DE, Elliott JP Jr, Smith RF, Reddy DJ, McPharlin M. A thirty-year survey of the reconstructive surgical treatment of aortoiliac occlusive disease. *J Vasc Surg* 1986;3:421-36.
31. Sacks D, Marinelli DL, Martin LG, Spies JB, Society of Interventional Radiology Technology Assessment Committee. Reporting standards for clinical evaluation of new peripheral arterial revascularization devices. *J Vasc Interv Radiol* 2003;14:S395-404.
32. Vorwerk D, Guenther RW, Schürmann K, Wendt G, Peters I. Primary stent placement for chronic iliac artery occlusions: follow-up results in 103 patients. *Radiology* 1995;194:745-9.
33. Vorwerk D, Günther RW, Schürmann K, Wendt G. Aortic and iliac stenoses: follow-up results of stent placement after insufficient balloon angioplasty in 118 cases. *Radiology* 1996;198:45-8.
34. Cikrit DF, Gustafson PA, Dalsing MC, Harris VJ, Lalka SG, Sawchuk AP, et al. Long-term follow-up of the Palmaz stent for iliac occlusive disease. *Surgery* 1995;118:608-13.
35. Farb A, Sangiorgi G, Carter AJ, Walley VM, Edwards WD, Schwartz RS, et al. Pathology of acute and chronic coronary stenting in humans. *Circulation* 1999;99:44-52.
36. Palmaz JC. Intravascular stents: tissue-stent interactions and design considerations. *Am J Roentgenol* 1993;160:613-8.

Submitted Feb 19, 2011; accepted Jun 28, 2011.

Additional material for this article may be found online at www.jvascsurg.org.



Appendix Fig (online only). Kaplan-Meier survival estimates are shown for patients with TransAtlantic Inter-Society Consensus (TASC) B, C, and D lesions undergoing placement of the bare-metal stent and the covered (V12) stent.