

TECHNIQUE

A Triceps-on Approach to Semi-Constrained Total Elbow Arthroplasty

Richard S. Boorman, MD, MSc, William T. Page, Edward J. Weldon III, MD, Steven Lippitt, MD, and Frederick A. Matsen III, MD

University of Washington

Department of Orthopaedics and Sports Medicine
Seattle, WA

Summary: Total elbow arthroplasty is often indicated in patients with fragile bone and soft tissues, such as those with rheumatoid arthritis. Some of the techniques for elbow arthroplasty involve partial or complete detachment of the triceps from the proximal ulna. In these instances, triceps failure can occur, presenting a particular problem for those who need triceps function to get out of a chair or for ambulation.

To minimize the risk of triceps failure following elbow arthroplasty, we have implemented a simple, yet extensive “triceps-on” approach to the elbow and demonstrated its application to total elbow arthroplasty.

The skin incision runs over the ulnar nerve, which is dissected free from the ulna and the medial capsule. Through this single skin incision, a complete 360-degree capsular release is performed through medial and lateral approaches. The ulna is then gently dislocated laterally with the triceps attached to the olecranon, allowing a semiconstrained total elbow prosthesis to be implanted.

HISTORICAL REVIEW

Total elbow arthroplasty (TEA) is an effective method for treating elbow arthritis, especially rheumatoid arthritis.⁴ Linked and unlinked prostheses are both commonly used, with reasonable success. Good clinical results and long-term implant survival have been reported for the Coonrad-Morrey semiconstrained total elbow arthroplasty,^{7,8} which helps manage many types of elbow pathologies, including instability. In spite of these advances, failure of the triceps insertion to the ulna continues to compromise the results in a substantial number of patients in the reported series.^{2,3,8,9} A number of factors may contribute to the risk of triceps failure: (1)

TEA demands wide exposure and dislocation of the joint; (2) the triceps tendon is often tenuous in patients undergoing TEA, many of whom have rheumatoid arthritis; (3) the skin over the posterior elbow is usually thin in patients having this surgery, leading to an increased risk of wound problems, including sloughing and infection, associated with triceps failure; (4) many patients having TEA take medications that may interfere with the strength of a triceps repair, such as corticosteroids or antimetabolites; and (5) individuals with rheumatoid arthritis often place increased demands on their triceps because of concurrent lower extremity disease requiring crutches, canes, walkers, and pushing up to rise from a chair or bed.

Approaches described for elbow arthroplasty include (1) triceps release,⁸ (2) olecranon osteotomy,¹¹ (3) triceps split and reflection,¹⁰ (4) medial to lateral triceps/anconeal flap,¹ and (5) lateral to medial triceps/anconeal flap.^{1,5} Using some of these approaches, the triceps rupture rate has been reported to be as high as 29% following TEA.

In 1982, Bryan and Morrey reported on a “triceps-sparing” approach to TEA.¹ In this approach, the triceps is peeled subperiosteally from the olecranon in continuity with the anconeus and the fascia of the forearm. The triceps tendon is not transected from the fascial tissues distal to the elbow, but instead left in a continuous sleeve. Bryan and Morrey recommended peeling the triceps-anconeal flap from medial to lateral. They also described a peel that can be performed from lateral to medial similar to an approach originally described by Kocher.^{1,5} A 0% triceps insufficiency rate was reported by the original authors using the medial to lateral peel.¹ However, other surgeons have found a higher incidence of triceps failure with this approach,^{3,9} suggesting the technical difficulty of the method, especially in patients with rheumatoid arthritis and compromised soft tissues. Hildebrand et al reported an incidence of triceps insufficiency or failure of 8% using the “triceps peel.”³

Address correspondence and reprint requests to Dr. Richard Boorman c/o Fred Westerberg, Department of Orthopaedics and Sport Medicine, University of Washington, 1959 NE Pacific Street, Seattle, WA 98195.

Pierce and Herndon⁹ have reported on ten patients in which they implanted a semiconstrained TEA without detachment of the triceps. Morrey has also described a triceps-on approach for surgical dislocation to manage elbow trauma.⁶ The approach described in the current article is similar in concept to those reported techniques. The approach can allow for gentle surgical dislocation of the elbow for the placement of a semiconstrained total elbow prosthesis. It avoids the technical challenge of triceps tendon detachment and repair to the olecranon, which is particularly difficult in patients with rheumatoid arthritis and with thin friable tissues.

■ INDICATIONS

The patient has functionally significant rheumatoid or inflammatory arthritis involving the elbow. The elbow symptoms have not responded to excellent medical management. There is no evidence of active synovitis. Other indications can include individuals with osteoarthritis who will place only low demands on their elbow and supracondylar fracture or nonunion in elderly patients with osteopenic bone.

■ PREOPERATIVE PLANNING

The elbow is evaluated clinically for range of motion (flexion, extension, supination, and pronation). Very stiff or ankylosed joints can be more technically challenging for this approach. The soft tissue envelope is examined for old surgical scars, or skin compromise secondary to corticosteroids. A very tenuous posterior soft tissue envelope is a relative contraindication for the procedure given that a large posterior skin flap must be raised. Finally, a distal neurovascular examination is carried out looking especially at preoperative ulnar nerve function.

Preoperative radiographs of the elbow include: (1) anteroposterior of the distal humerus, (2) anteroposterior of the proximal ulna, (3) lateral of the elbow in maximal flexion, and (4) lateral of the elbow in maximal extension.

■ SURGICAL TECHNIQUE

Under anesthesia, the patient is placed supine on the operating table. The entire forequarter is doubly prepped and free-draped. The drape includes a tubular stockinet over the entire arm. A sterile tourniquet is placed about the upper arm. Tourniquet inflation will only be used for the ulnar nerve dissection and for component cementation.

Using extremely gentle soft tissue technique, the elbow is approached through a straight posterior-medial incision over the course of the ulnar nerve, closer to the medial epicondyle than the olecranon (Fig. 1). The inci-

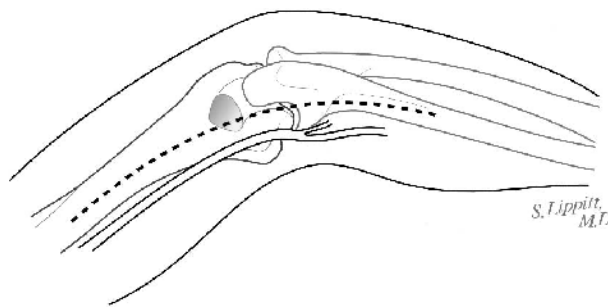


FIGURE 1. Patient is supine with arm over chest. Posterior aspect of elbow is shown. The incision is centered over the ulnar nerve.

sion extends approximately 7–10 cm proximal and distal from its bed, from the inter-muscular septum proximally, to the first motor branch to the flexor carpi ulnaris distally (Fig. 2). The nerve is often adherent to the medial aspect of the ulna and medial joint capsule, thus requiring special care in this region. A moistened quarter inch rubber drain is placed around the nerve. The tourniquet is deflated.

With the ulnar nerve under control and mobilized from its bed, the anterior, posterior, and medial aspects of the elbow joint capsule as well as the medial collateral ligament complex are released (Fig. 3). The triceps is mobilized from the distal humerus exposing the olecranon fossa. If necessary, the origin of the flexor-pronator group can be released from the medial epicondyle. Again using gentle soft tissue technique, the posterior flap, including skin, subcutaneous tissue, and bursa, is dissected from the olecranon to the lateral side of the elbow—keeping all subcutaneous tissues intact to the skin. An incision is made between the anconeus and the extensor carpi ulnaris, and this interval is developed from the lateral epicondyle to the subcutaneous border of the ulna (Fig. 4). Through this approach, the lateral capsule and

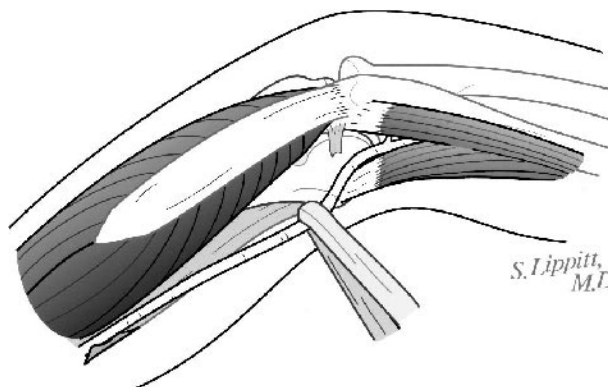


FIGURE 2. Posterior view of elbow showing triceps. Extensive mobilization of the ulnar nerve is necessary. The nerve is shown retracted with a moist Penrose drain.

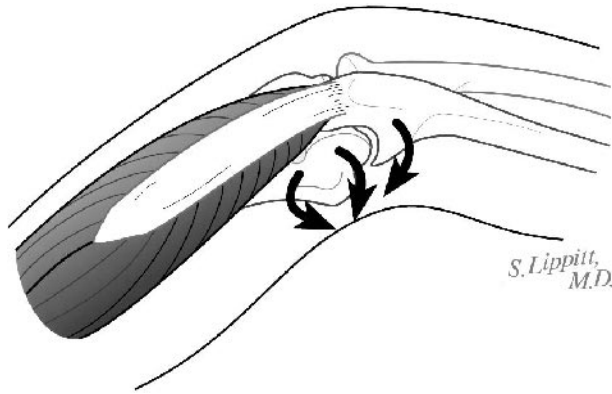


FIGURE 3. Medial capsular release is performed including MCL, medial capsul, and flexor-pronator insertion.

any remaining anterior and posterior capsule are released (Fig. 5). The triceps attachment remains entirely intact to the ulna. The triceps and the ulna in continuity are lifted from the distal humerus and gently translated laterally so that they are dislocated over the capitellum, providing complete exposure of the distal humeral surface (Fig. 6). If resistance is met, it is occasionally necessary to remove blocking osteophytes. The ulnar nerve is carefully monitored for tension during the dislocation.

Although the triceps-on technique could potentially be used with any semiconstrained total elbow prosthesis, the following description of the bony preparation is our technique for implanting the Coonrad-Morrey device (Figs. 7 and 8). This semiconstrained prosthesis allows for independent insertion of the humeral and ulnar components, and then can be linked in situ with a locking pin.

With a finger and a thumb on the distal humeral shaft for orientation, the trochlear bone overlying the extrapolated axis of the humeral medullary canal is resected with a rongeur. All resected humeral bone is saved. The medullary guide is inserted and the distal humeral cutting




FIGURE 5. Lateral and anterior capsular and ligamentous release performed through the Kocher interval.

guide attached and used for resecting the distal humerus. The distal humeral canal is broached to the correct dimensions for the humeral component, attempting to broach and seat the component in maximal extension and in neutral rotation and varus/valgus position with the posterior aspect of the distal humerus.

The greater sigmoid notch of the ulna is exposed by hyperpronating the forearm and by retracting the triceps. Tissue within the notch is debrided with a rongeur. The proximal lip of the greater sigmoid notch is resected down to the triceps insertion allowing for straight access to the ulnar canal working either through the center of the prepared distal humerus or lateral to the distal humerus. During all of these steps, the ulnar nerve is carefully protected from stretch, compression, or other injury.

The subcutaneous border of the ulna is palpated, and the junction of its extrapolated medullary canal and the distal aspect of the greater sigmoid notch are identified. A pinecone-shaped burr is used to open the medullary canal of the ulna at this point. The direction of the burr is angled approximately 45 degrees to the long axis of the ulna, angling posteriorly. The canal is opened with an awl to allow the insertion of a bulb tipped reamer guide

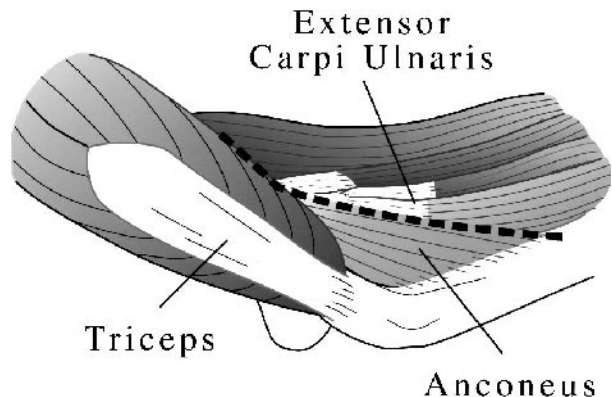


FIGURE 4. Lateral approach through interval between anconeus and extensor carpi ulnaris.

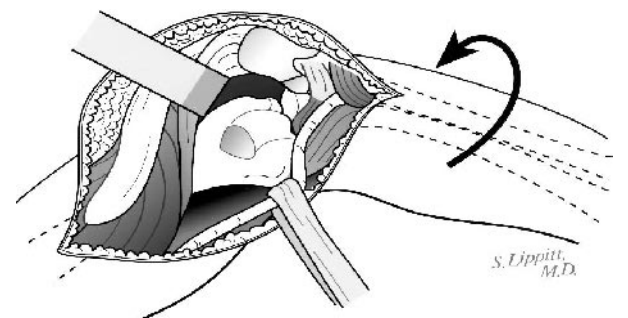


FIGURE 6. Gentle dislocation of the elbow with the triceps left completely attached to the ulna. The ulnar nerve must be carefully protected during dislocation. The ulna is shown hyperpronated and dislocated laterally.

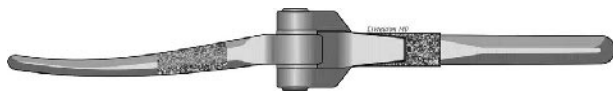

FIGURE 7. Anterior view of the Coonrad-Morrey semi-constrained elbow prosthesis.

down the medullary canal of the ulna. Flexible cannulated reamers are passed over this guide, enlarging the canal sufficiently to receive the stem of the ulnar prosthesis. In preparing the ulna to receive its component, attention is directed at assuring that the flexion axis of the elbow defined by the ulnar component will be centered in the greater sigmoid notch—proximal/distally and anterior/posteriorly—and that this axis is parallel to the posterior surface of the ulna.

Trial humeral and ulnar components are inserted; the elbow is reduced and temporarily linked while the range of motion is examined. In maximal flexion, any bone of the coronoid process abutting against the anterior flange of the prosthesis is resected, and any radial head abutting against the distal humerus is resected. In maximal extension, any bone of the olecranon abutting against the back of the humerus is resected.

Once the definitive size and fit is determined, the trial components are removed. The tourniquet is inflated. The medullary canal of the humerus is thoroughly irrigated. A cancellous bone plug from the resected bone is shaped to fit in the humeral canal and tamped into position so that it lies just proximal to the tip of the stem of the fully inserted 4-inch humeral trial. Use of a longer humeral

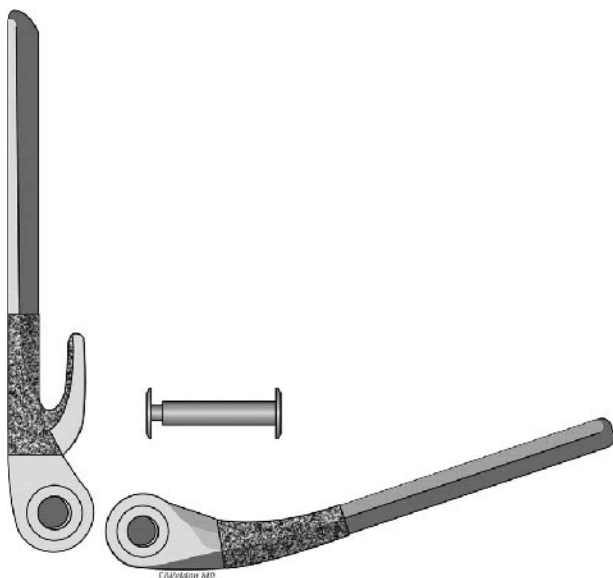


FIGURE 8. Lateral view of Coonrad-Morrey prosthesis showing anterior flange. Implant shown unlinked with locking pin and bushing.

stem may compromise the availability of the canal for future shoulder arthroplasty. Also, if the tip of the humeral stem extends beyond the isthmus, it may be difficult to achieve a press fit of the plug. The canal is brushed, irrigated, and packed with dry gauze. Using a cement gun with a small stem, the distal humeral canal is filled with high-viscosity cement in a retrograde fashion. The humeral component is then inserted, holding it in maximal extension until the cement is hardened. We do not use anterior bone graft as we have found that it can lead to excessive flexion of the humeral component, increasing the risk for coronoid abutment. Exposed cement is removed from around the prosthesis and humerus.

Similarly, the ulnar canal is cleaned, grafted distally with cancellous bone at a level that allows full insertion of the trial component. After drying the canal, cement is inserted using a cement gun with a small tip, and the ulnar component is inserted. The elbow is promptly reduced, the components temporarily linked and the elbow held in full extension while the cement is setting. This helps ensure appropriate rotation of the ulnar component. After the cement is set and cool, the elbow linkage is dissociated to allow for inspection of the joint surfaces for extraneous cement and bone, which is removed.

The wound is thoroughly irrigated and the elbow reduced. Bone is resected from the anterior humeral epicondyles as necessary to allow insertion of the locking pins, which are then inserted and locked. The tourniquet is deflated. The completeness of the range of motion is verified. Hemostasis is achieved. The ulnar nerve is placed anterior to the medial epicondyle.

The flexor-pronator group is reattached to the medial epicondyle with no. 2 nonabsorbable sutures passed through bone holes. No triceps repair is necessary as the insertion to the olecranon is left completely intact (Fig. 9). The wound is closed in layers over a suction drain, using an interrupted closure on the skin to allow additional drainage.

Dry sterile dressings are applied followed by a bulky cotton dressing to protect the elbow in a position of comfortable flexion. The dressings will be removed on the second postoperative day and motion started if the wound is dry. Otherwise, motion will be held until the drainage has ceased.

■ POSTOPERATIVE MANAGEMENT

The elbow is maintained in approximately 30 degrees flexion in the loose, bulky, cotton dressing for 2 days. The dressing is then removed and the drain is pulled. The wound is inspected for excessive swelling, quality of wound apposition, and skin health. If there is any concern, motion is held, and the elbow is maintained in comfortable extension to minimize posterior skin tension

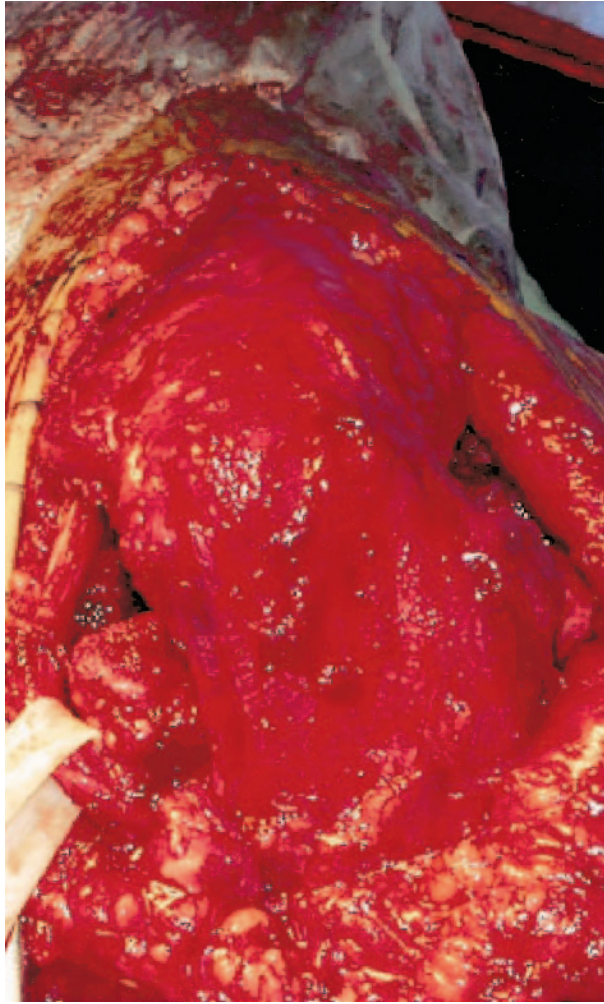


FIGURE 9. Posterior view of the flexed elbow following implantation of a semiconstrained total elbow arthroplasty. The triceps attachment remains completely intact.

from elbow flexion. Otherwise, active-assisted elbow flexion, extension, pronation, and supination are commenced on the second postoperative day. Active exercises are progressed after skin healing since the triceps mechanism has not been violated.

■ RESULTS

We have performed 40 total elbow replacements in 33 patients (seven bilateral surgeries) since 1992. Twenty-two patients were female, and 11 patients were male. The diagnosis was rheumatoid arthritis in 25 patients and posttraumatic arthritis in eight patients. The average age at the time of surgery was 55 years.

There were no postoperative triceps insufficiencies or failures in this series of patients. We had no infections and no permanent ulnar nerve deficits. Some patients

were found to have transient ulnar nerve sensory deficits, but there were no ulnar nerve motor deficits in this series.

We have collected preoperative and greater than 2-year postoperative functional inventory questionnaires from 14 patients with rheumatoid arthritis. Over 90% of patients reported that they could push to rise from a chair postoperatively, suggesting good triceps function.

■ COMPLICATIONS

Two patients had self-limiting wound healing complications. Both of these patients had a small region (approximately 2 × 2 cm) of skin necrosis posteriorly over the olecranon. Neither of these patients required special treatment or surgery, and both had complete healing of the compromised region of skin. Five patients required repeat surgery: one patient for a persistent draining hematoma, two patients for early ulnar component loosening, one patient for excessive stiffness secondary to heterotopic ossification, and one patient for dissociation of components.

■ POSSIBLE CONCERNS AND FUTURE CONSIDERATIONS

We have used this “triceps-on” approach for routine use in semiconstrained TEA using the Coonrad-Morrey total elbow prosthesis with excellent clinical success. This technique allows for the gentle dislocation of the elbow without detaching the triceps from the olecranon, thus avoiding the potential serious complication of triceps insufficiency or failure. Extreme care must be exercised when handling the posterior soft tissues, as posterior wound-healing problems are of concern. The ulnar nerve must also be adequately mobilized and carefully handled to avoid permanent ulnar nerve deficits. Finally, ulnar component placement is made slightly more difficult with this technique, thus requiring special attention. Future studies need to better delineate whether postoperative function can be more significantly improved following TEA using this triceps-on technique.

■ REFERENCES

- 1) Bryan RS, Morrey BF. Extensive posterior exposure of the elbow: a triceps-sparing approach. *Clin Orthop.* 1982;166: 188–192.
- 2) Gill DR, Morrey BF. The Coonrad-Morrey total elbow arthroplasty in patients who have rheumatoid arthritis. A ten to fifteen-year follow-up study. *J Bone Joint Surg Am.* 1998;80:1327–1335.
- 3) Hildebrand KA, Patterson SD, Regan WD, et al. Functional outcome of semiconstrained total elbow arthroplasty. *J Bone Joint Surg Am.* 2000;82-A:1379–1386.

- 4) Inglis AE, Pellicci PM. Total elbow replacement. *J Bone Joint Surg Am.* 1980;62:1252–1258.
- 5) Kocher T. *Textbook of Operative Surgery.* 3rd ed. London, England: A and C Black; 1911.
- 6) Morrey BF. Surgical exposures of the elbow. In: Morrey BF, ed. *The Elbow and its Disorders.* Philadelphia, PA: WB Saunders; 1993: 139–166.
- 7) Morrey BF, Adams RA. Semiconstrained arthroplasty for the treatment of rheumatoid arthritis of the elbow. *J Bone Joint Surg Am.* 1992;74:479–490.
- 8) Morrey BF, Bryan RS, Dobyns JH, et al. Total elbow arthroplasty. A five-year experience at the Mayo Clinic. *J Bone Joint Surg Am.* 1981;63:1050–1063.
- 9) Pierce TD, Herndon JH. The triceps preserving approach to total elbow arthroplasty. *Clin Orthop.* 1998;354:144–152.
- 10) Shahane SA, Stanley D. A posterior approach to the elbow joint. *J Bone Joint Surg Br.* 1999;81:1020–1022.
- 11) Wolfe SW, Ranawat CS. The osteo-anconeus flap. An approach for total elbow arthroplasty. *J Bone Joint Surg Am.* 1990;72:684–688.