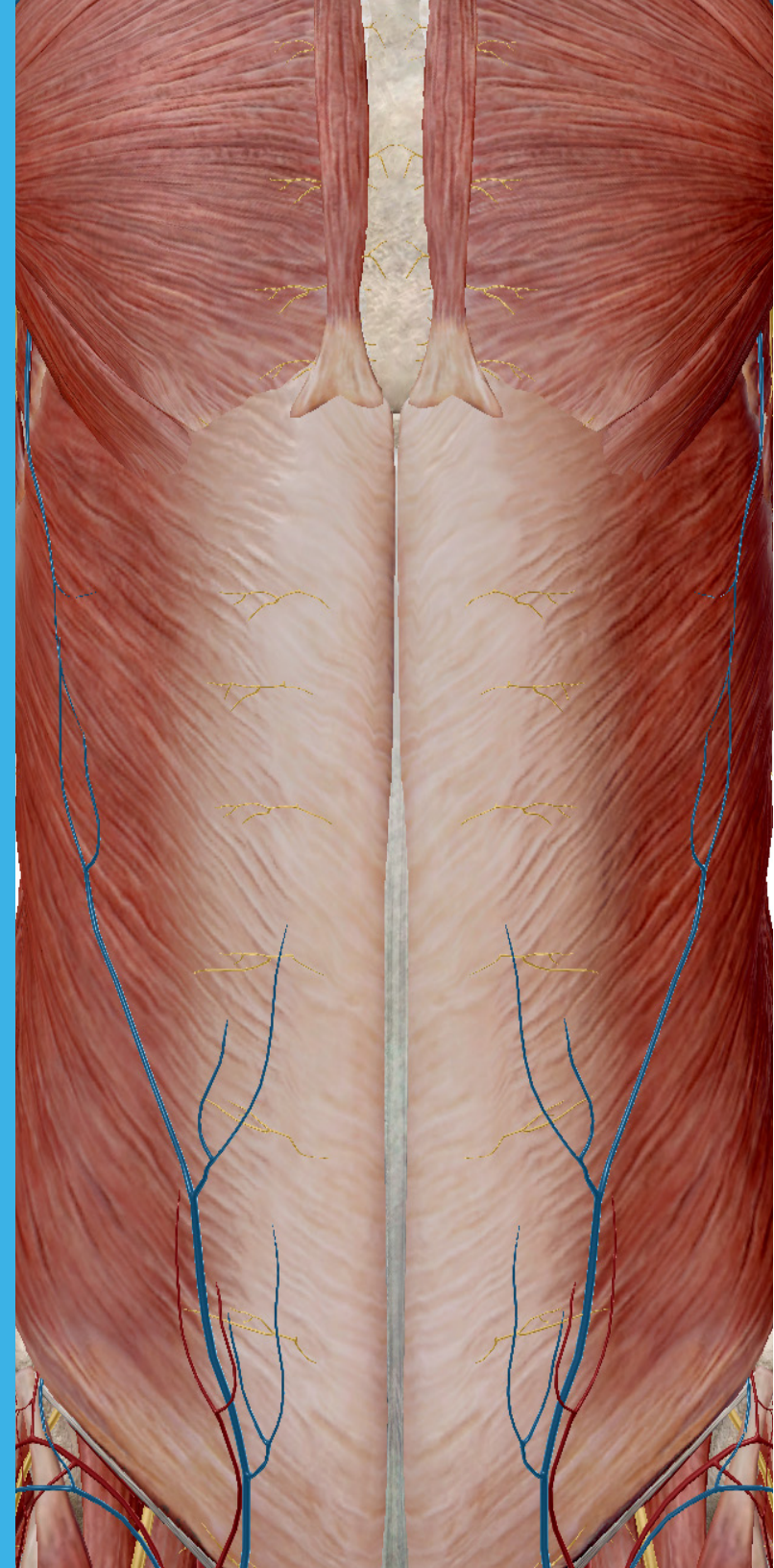


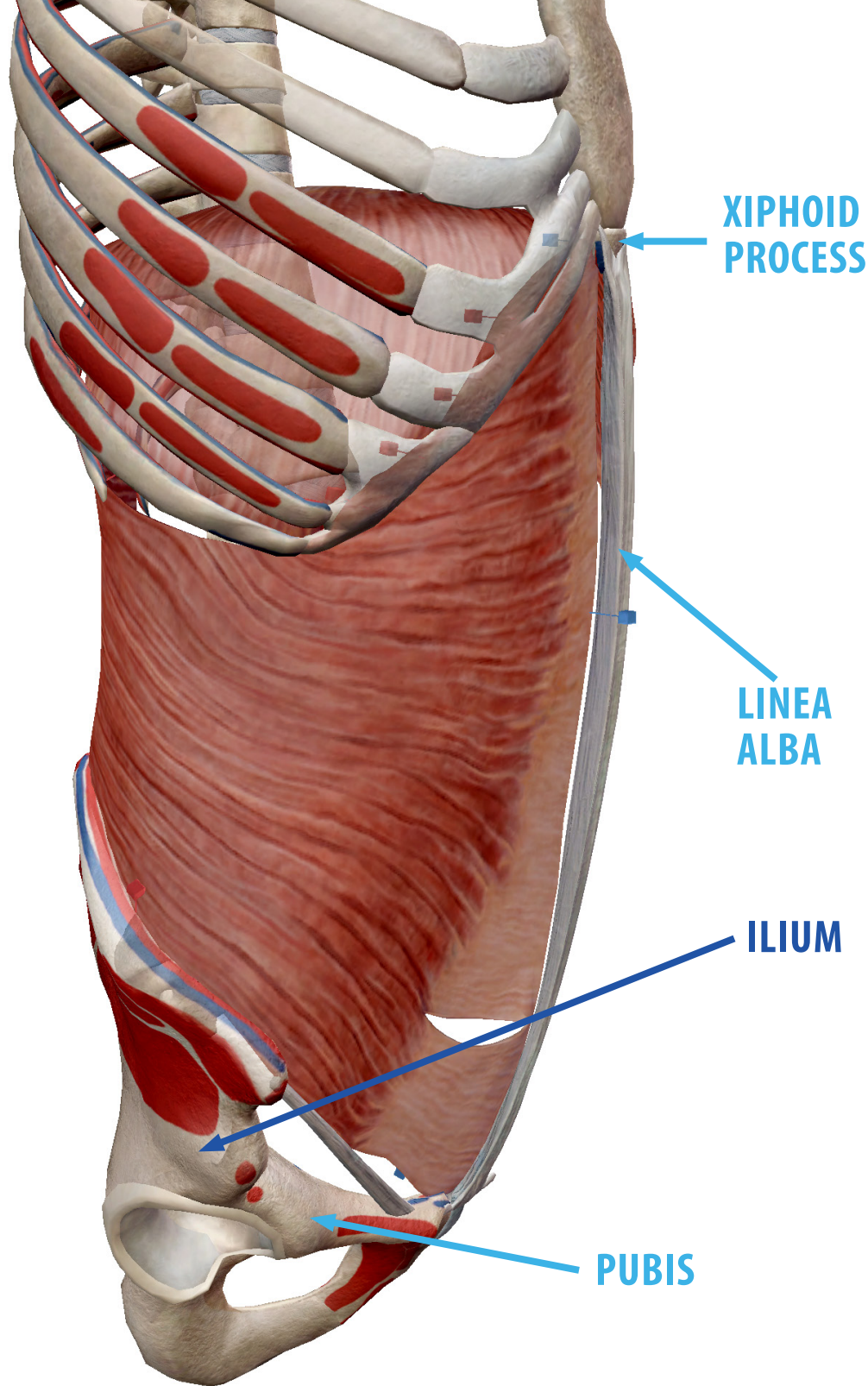
# ABDOMINAL MUSCLES

*The abdominal muscles provide support and movement to the trunk and spine. They also help maintain the internal pressure of your abdomen, holding the internal organs there in place.*

Ready to learn more? Consider this your official Ab Manual.

VISIBLE  BODY®





# TRANSVERSUS ABDOMINIS

The transversus abdominis is the deepest of the abdominal muscles.

It has multiple origins, including the lower six ribs, iliac crest, and thoracolumbar fascia.

It ends in an aponeurosis (a type of connective tissue), part of which attaches to the pubis. Other insertion points include the xiphoid process and the linea alba, a band of connective tissue that runs vertically down the front of the abdomen.

# TRANSVERSUS ABDOMINIS

The transversus abdominis compresses the abdominal viscera and tenses the abdominal wall. It also helps stabilize the lumbar spine and pelvis.

Spinal nerves T07-T12 and the iliohypogastric and ilioinguinal nerves (branches of L01) innervate this muscle. Its blood supply comes from the subcostal arteries, which branch off from the descending abdominal portion of the aorta.



**SUBCOSTAL  
ARTERY**

# RECTUS ABDOMINIS

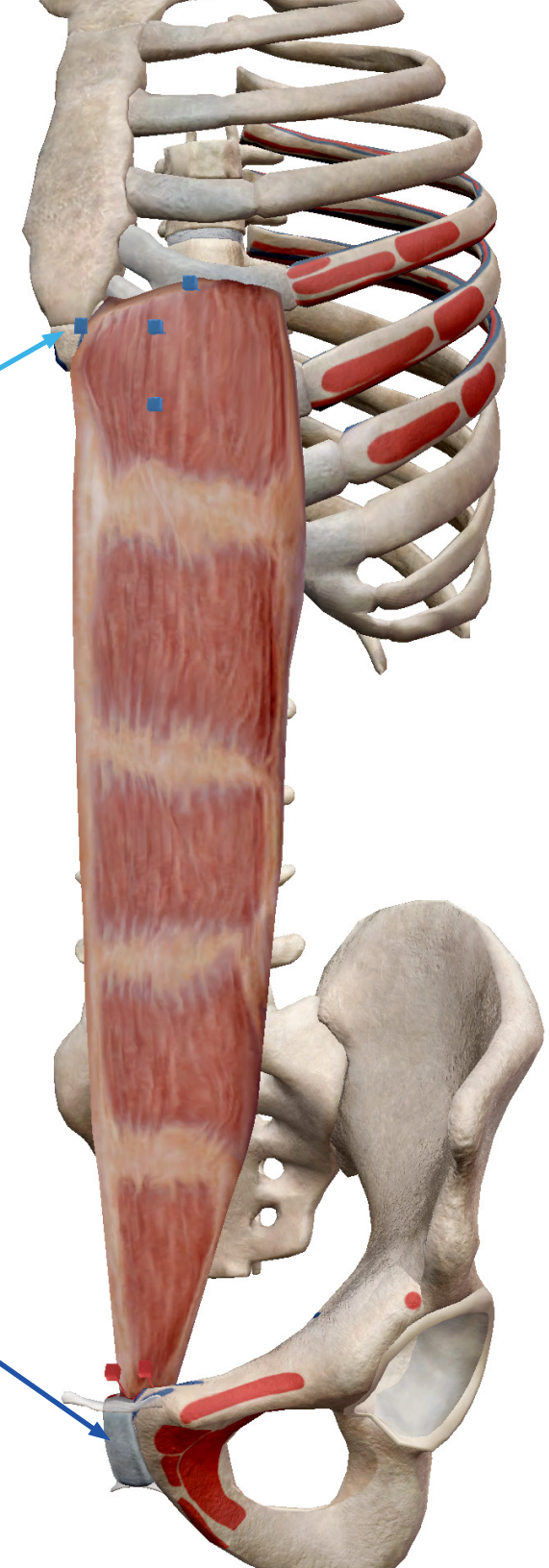
The rectus abdominis is a long muscle originating from the pubis and pubic symphysis and inserting at the xiphoid process and the fifth, sixth, and seventh ribs.

## Factoid!

The rectus abdominis is what gives the appearance of a “six pack”. The linea alba separates the right and left rectus abdominis muscles, and bands of connective tissue separate each into multiple distinct segments.

XIPHOID  
PROCESS

PUBIC  
SYMPHYSIS



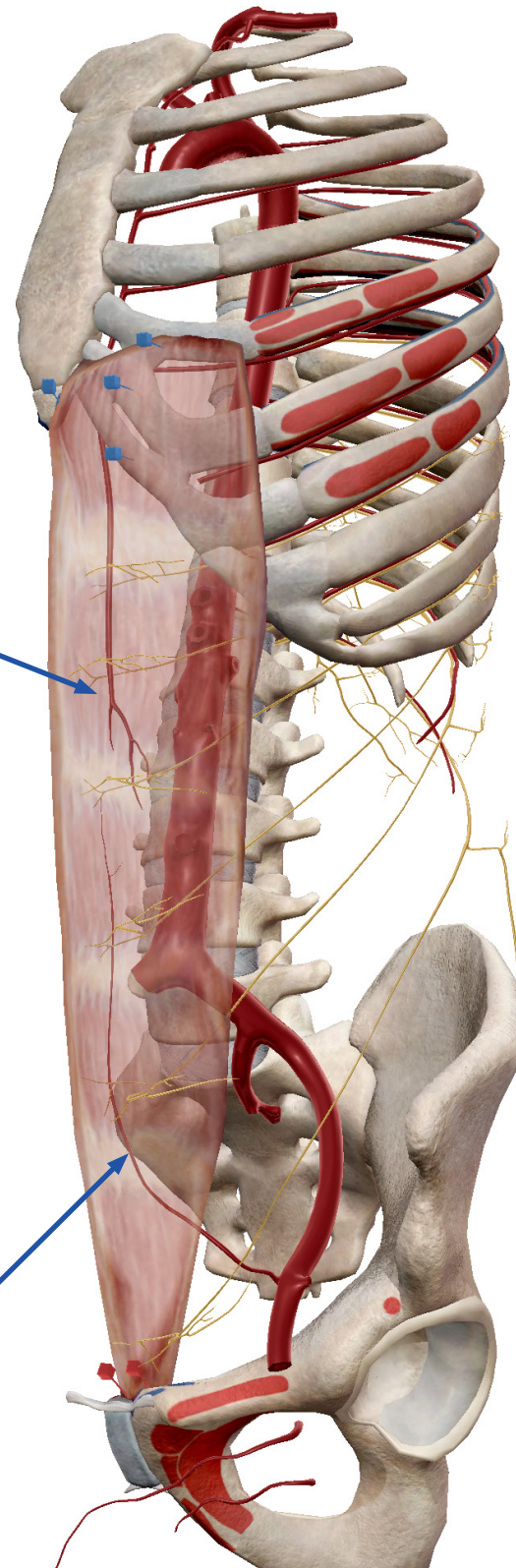
# RECTUS ABDOMINIS

The rectus abdominis helps flex the vertebral column, sending the pelvis forward. Like the transversus abdominis, it also compresses the viscera and tenses the abdominal wall.

It is innervated by T07-T12 and receives its blood supply from the superior and inferior epigastric arteries.

**SUPERIOR  
EPIGASTRIC  
ARTERY**

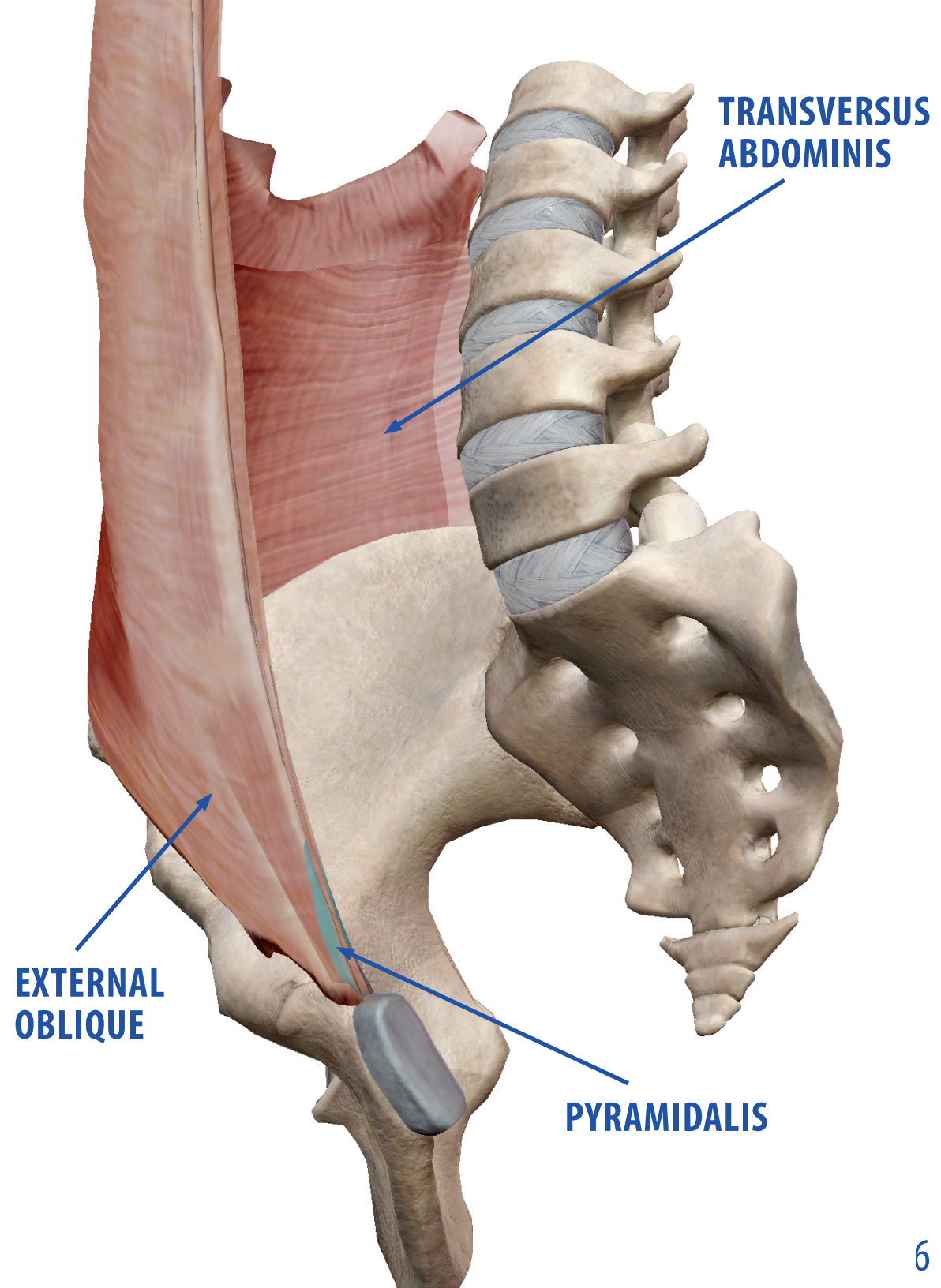
**INFERIOR  
EPIGASTRIC  
ARTERY**

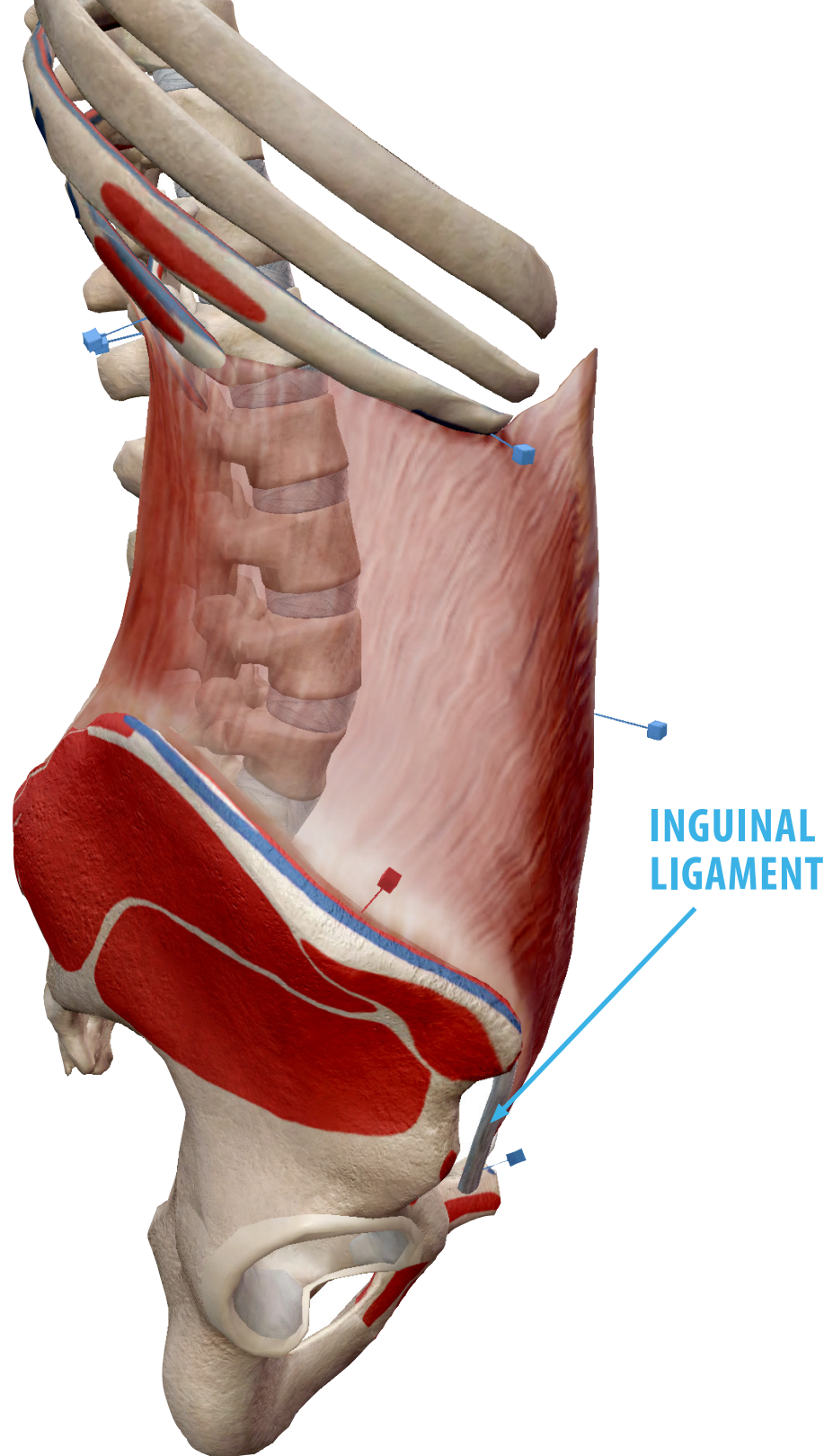


# RECTUS SHEATH

The rectus sheath (aka the rectus fascia) is formed by the aponeuroses of the transversus abdominis and the internal and external obliques. The pyramidalis is located inside the rectus sheath.

This image shows how the main abdominal muscles layer with one another: the transversus abdominis is the deepest, then the internal obliques and rectus abdominis, followed by the external obliques.

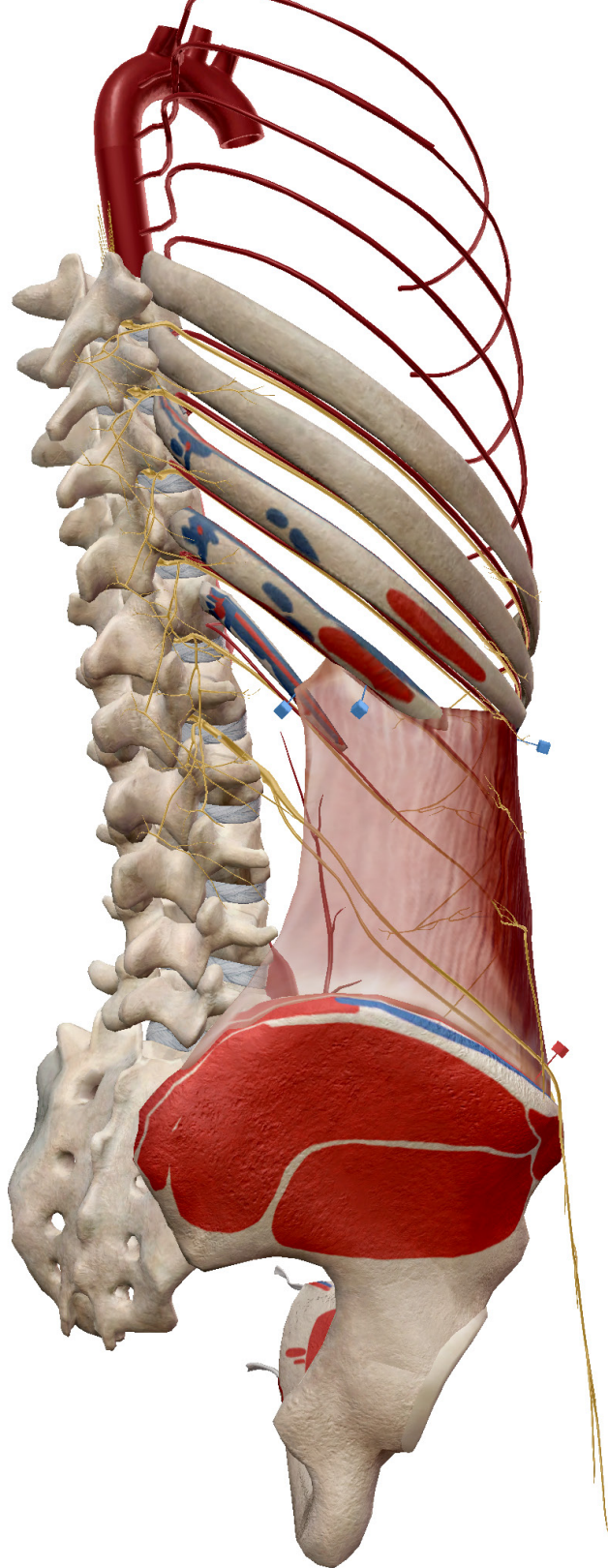




# INTERNAL OBLIQUES

As the name implies, the internal obliques sit just under the external obliques.

The internal oblique muscle on each side of the body originates at the thoracolumbar fascia, the iliac crest, and the inguinal ligament. Their insertion points include the three lowest ribs, the xiphoid process, the linea alba, and the pubic symphysis.



# INTERNAL OBLIQUES

When both internal obliques contract, they compress the viscera and flex the spine. Individually, the internal obliques play a role in lateral spine flexion and, in concert with the opposite external oblique, spinal rotation.

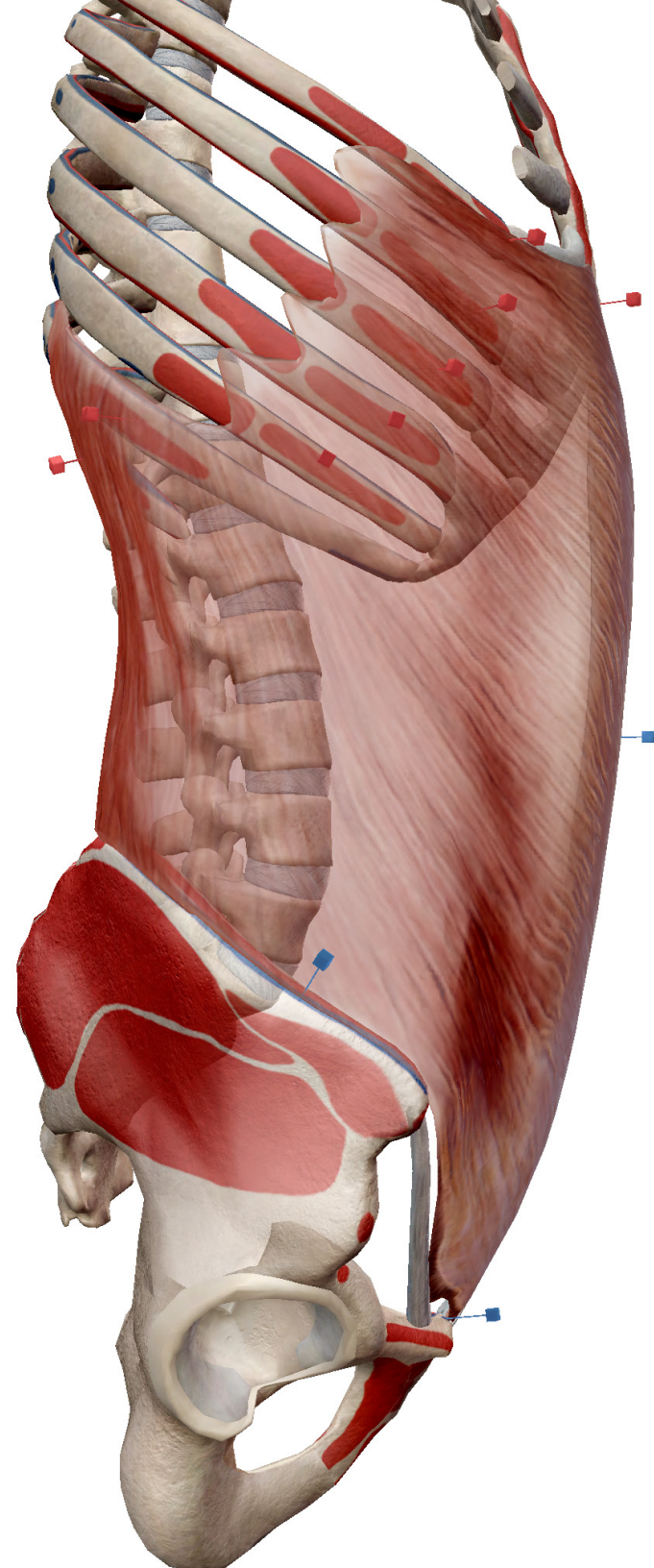
The internal obliques are innervated by T08-T12 and the branches of L01. It receives its blood supply from the intercostal and subcostal arteries.



# EXTERNAL OBLIQUES

The external obliques are the outermost abdominal muscles, covering the sides and front of the abdomen.

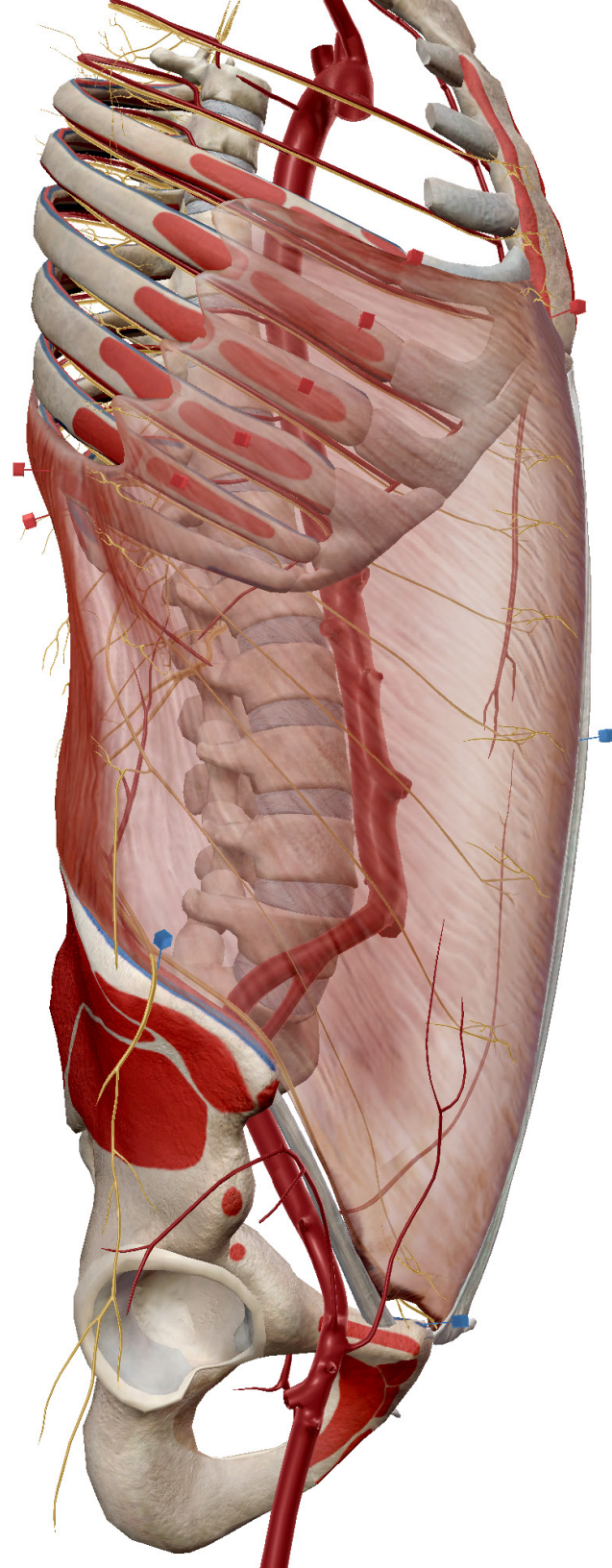
The lowest eight ribs are their origins, and they insert at the iliac crest. They also form an aponeurosis which inserts at the linea alba and pubis.

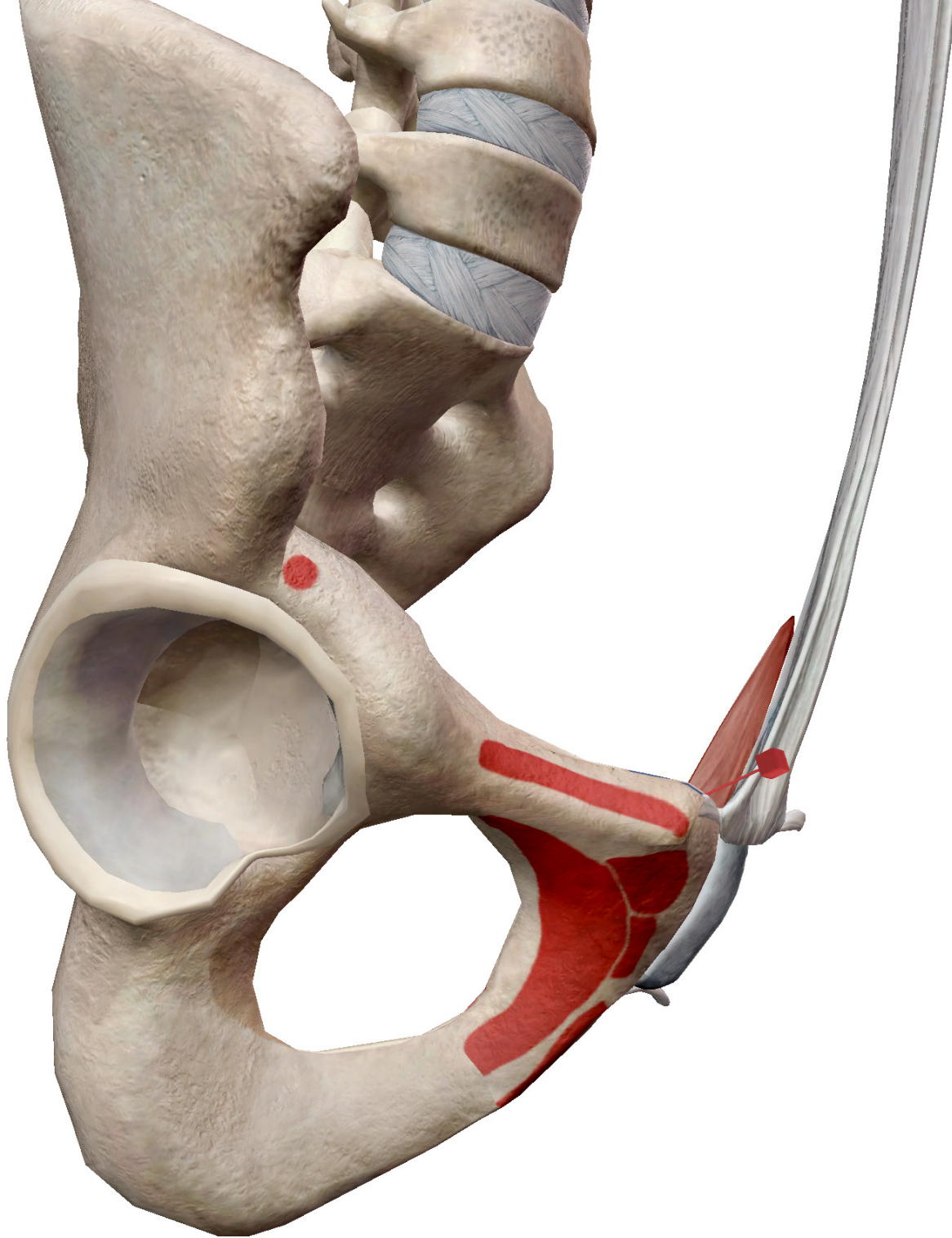


# EXTERNAL OBLIQUES

When acting together, the external obliques contribute to **spinal flexion**. Along with the internal obliques, they also play a role in lateral flexion and rotation of the spine.

They are innervated by T07-T12 and the branches of L01 and receive their blood supply from the **intercostal, subcostal, and deep circumflex iliac arteries**.



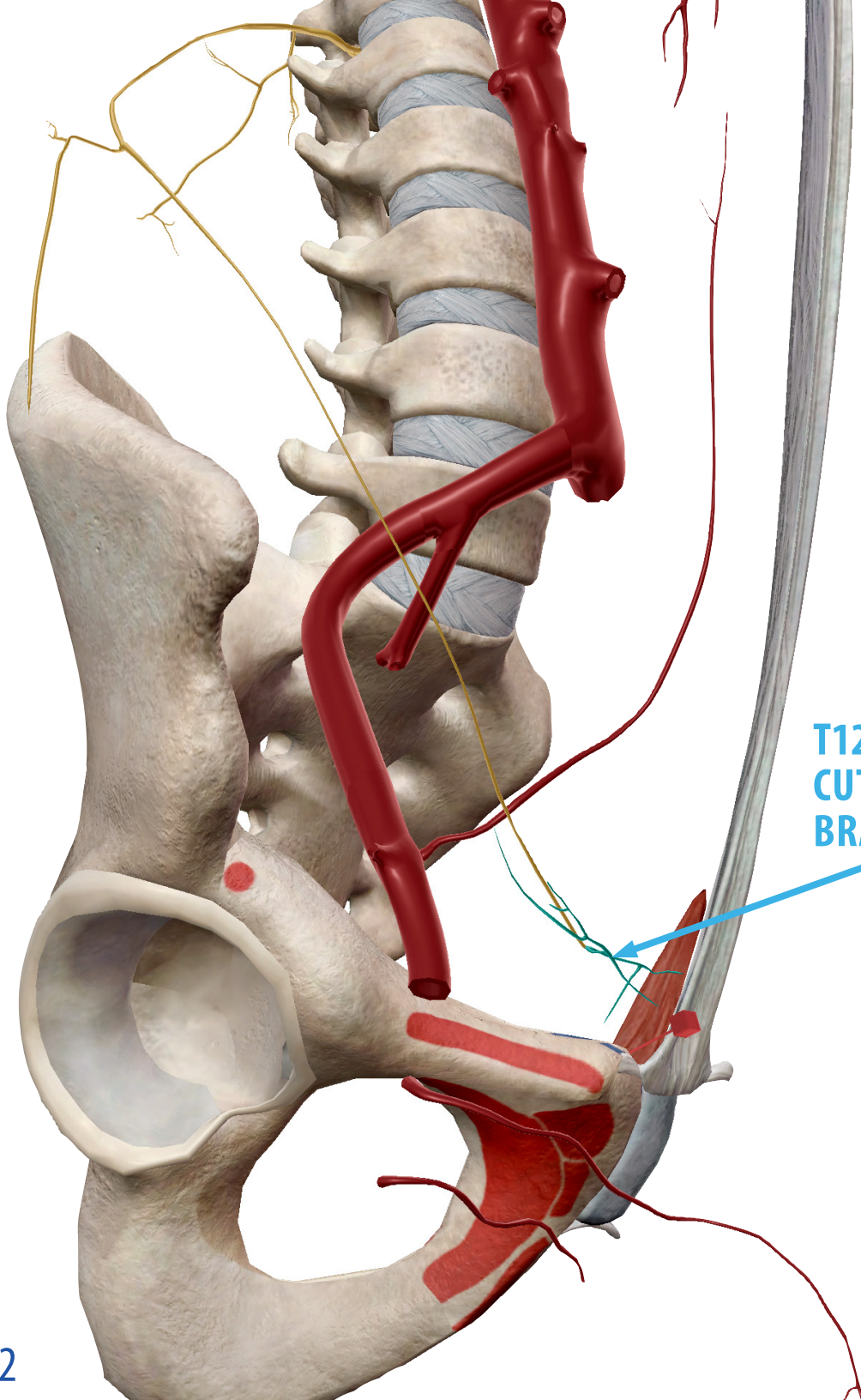


# PYRAMIDALIS

The pyramidalis is a tiny muscle located in the rectus sheath. It originates from the anterior pubis and pubic symphysis and inserts into the linea alba.

## **Factoid!**

About 20% of people don't have any pyramidalis muscles! The other 80% have either one or both.



# PYRAMIDALIS

The pyramidalis assists the other abdominal muscles in compressing the abdominal cavity. It does this by tensing the linea alba.

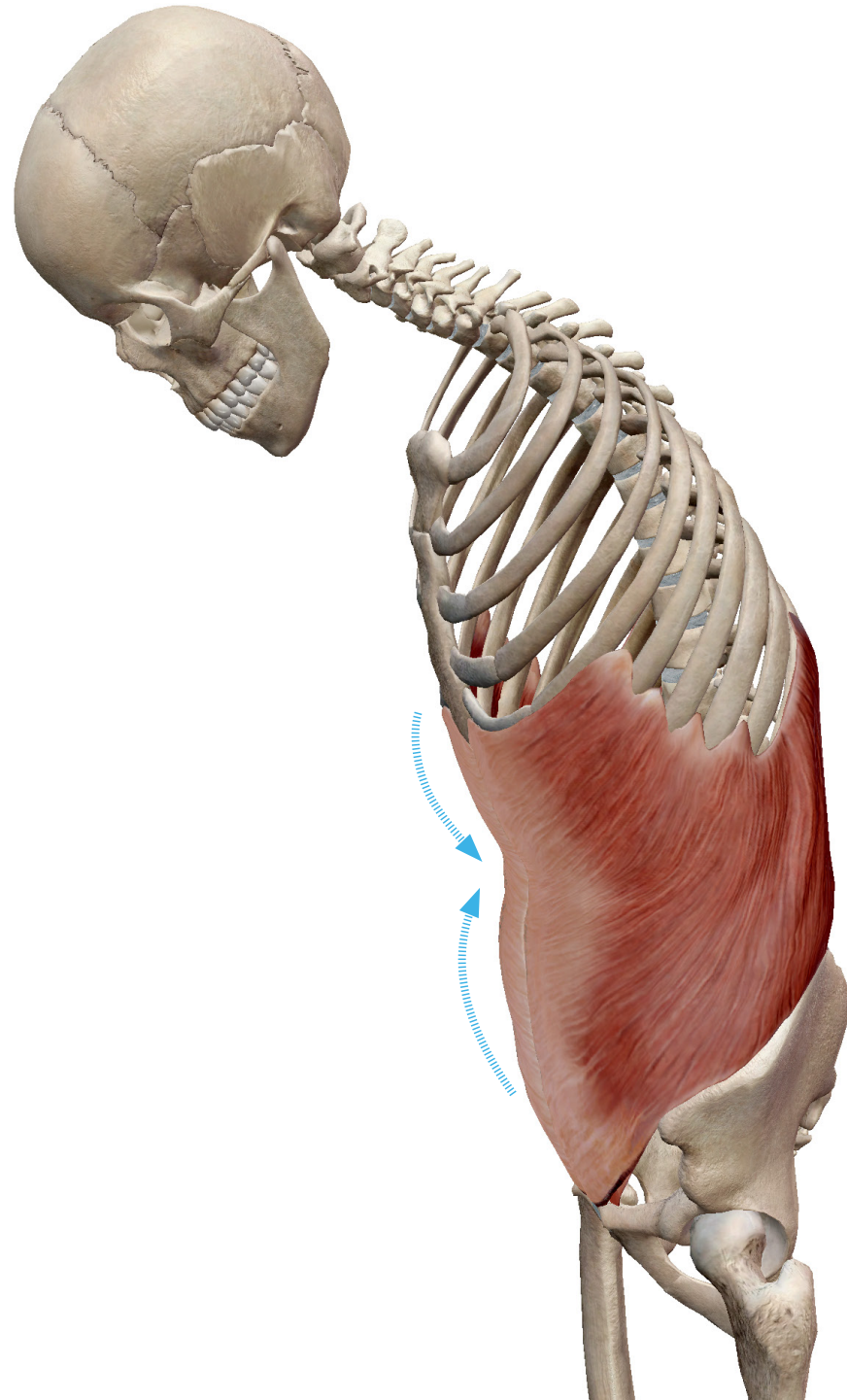
It is innervated by the cutaneous branches of T12 and receives its blood supply from the superior and inferior epigastric arteries.

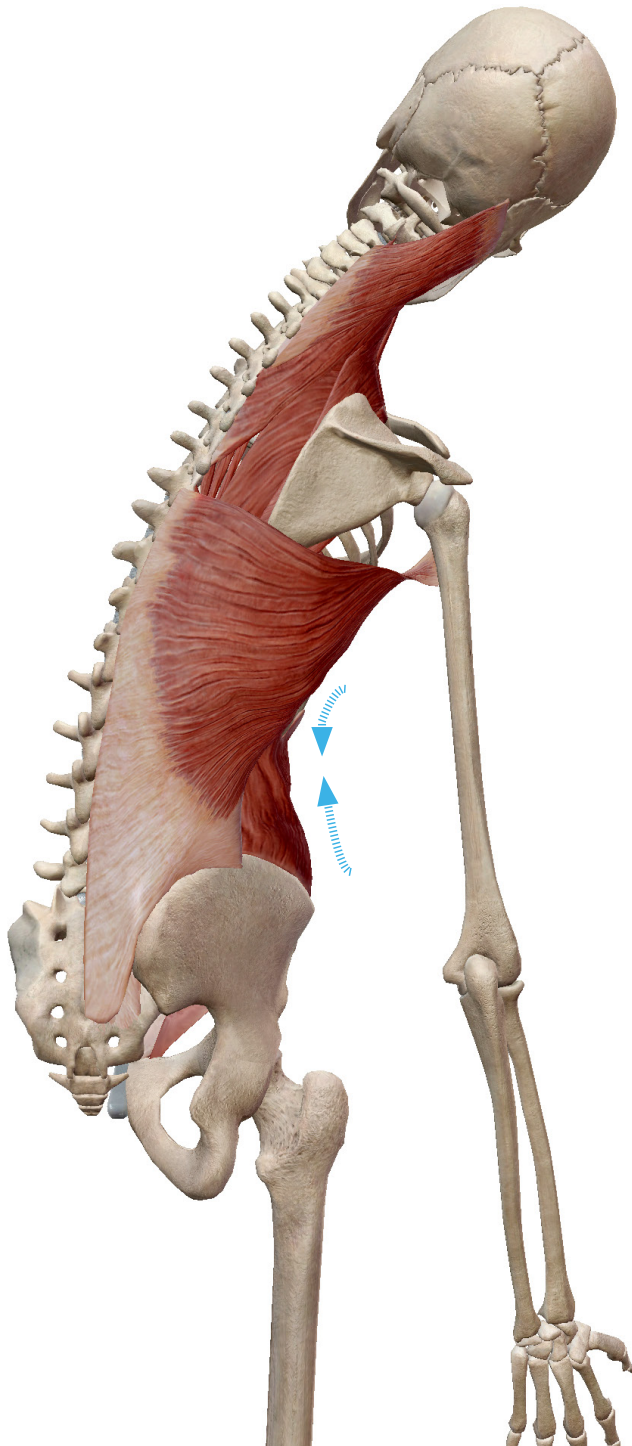
# SPINE FLEXION

The abdominal muscles are involved in many movements we typically associate with the spine.

Spine flexion is the basic movement we do when we bend forward.

The prime movers of this action are the rectus abdominis and internal and external obliques. When these muscles contract, they bring the pelvis and ribs closer together, bending the spine forward.





# SPINE LATERAL FLEXION

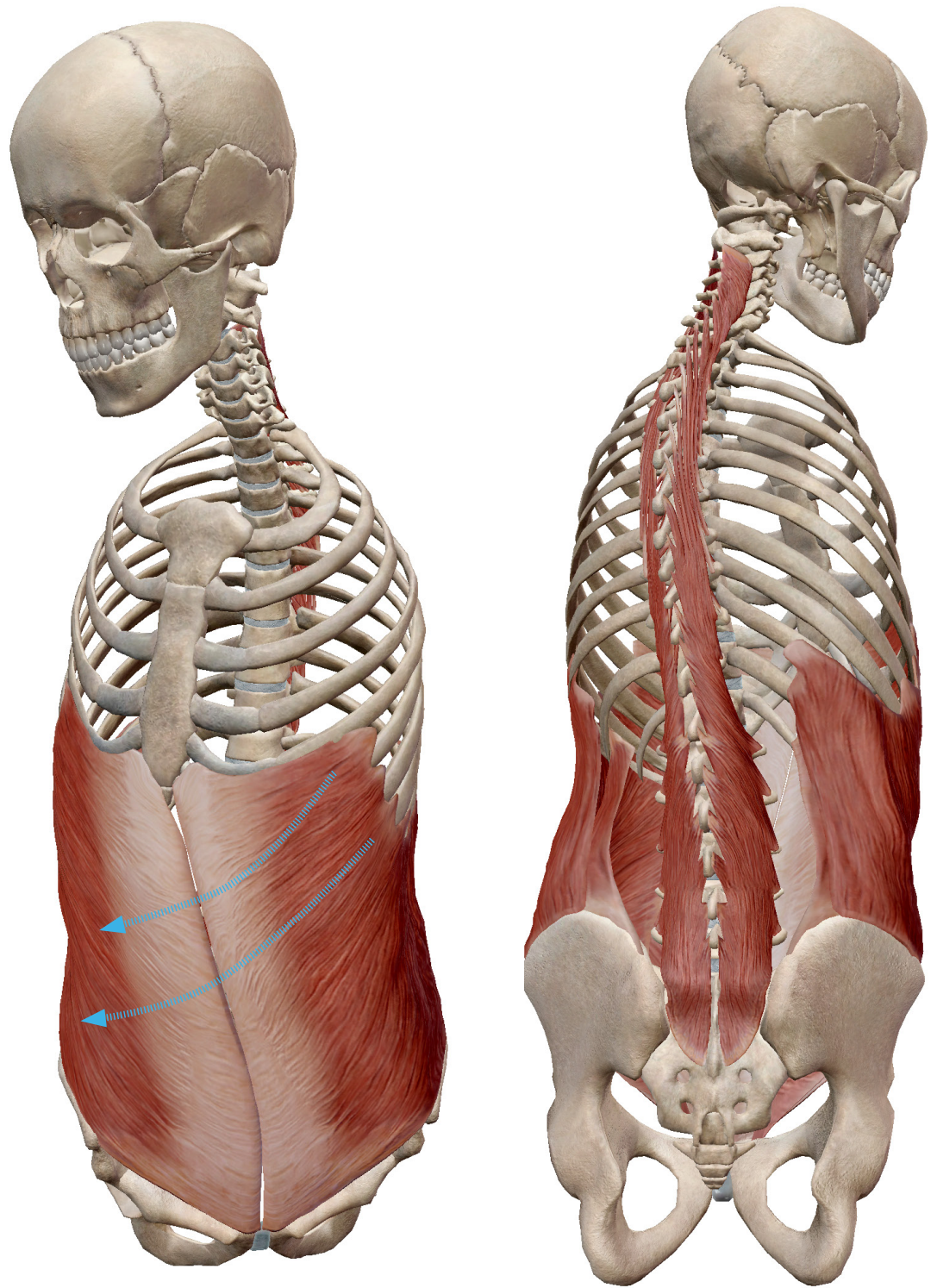
Lateral flexion of the spine happens when we bend to the side. If you do yoga, think of a standing side bend and you'll know what lateral spine flexion feels like.

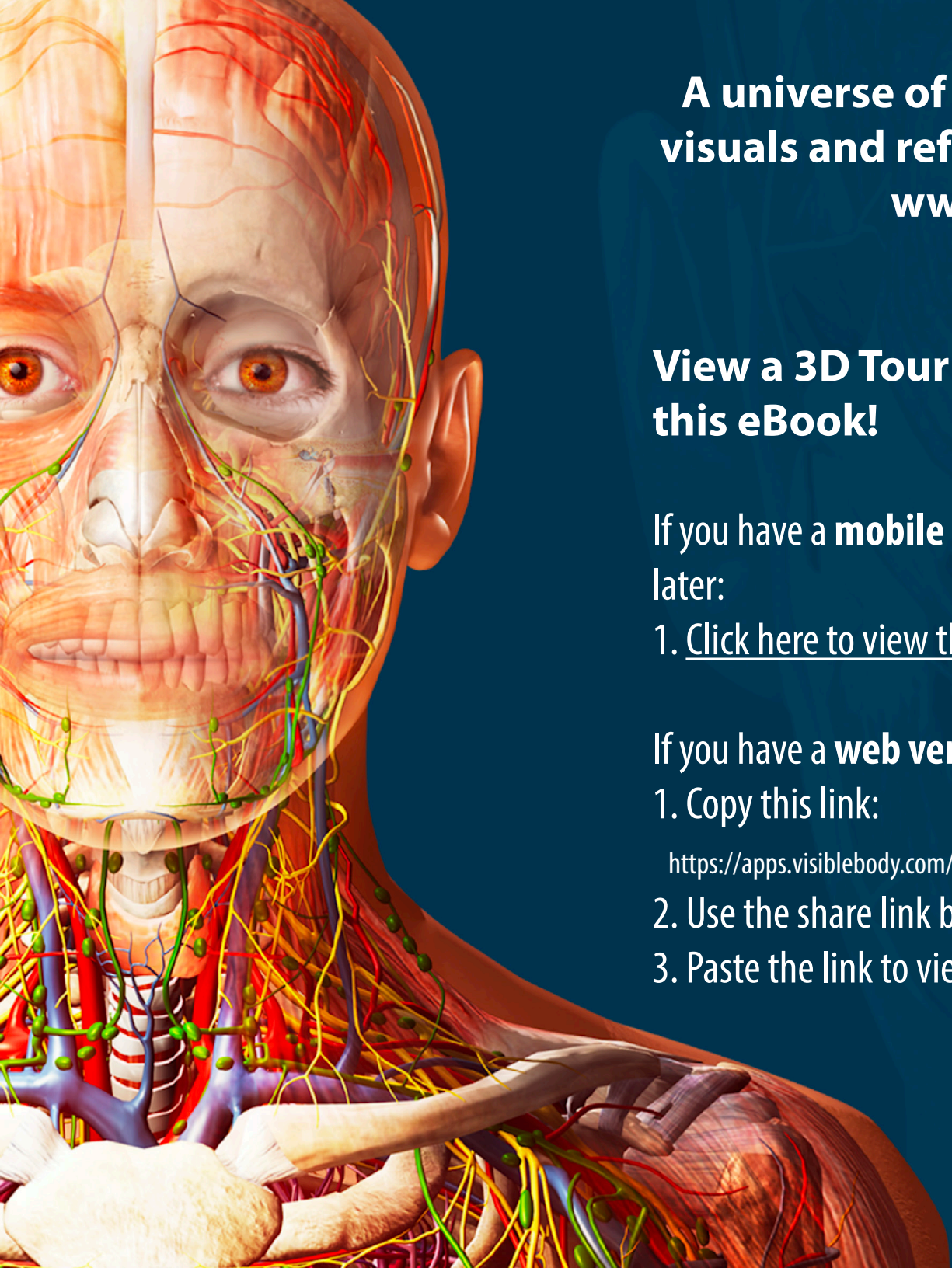
The internal and external obliques assist the muscles that run along the sides of the spine to achieve this motion.

# SPINE ROTATION

Spine rotation can most simply be described as a “trunk twist”. This motion allows you to turn your torso while keeping your pelvis relatively stable.

Once again, the obliques work in concert with muscles running along the spine to achieve this movement.





**A universe of anatomical and physiological  
visuals and reference texts at your fingertips!  
[www.visiblebody.com](http://www.visiblebody.com)**

**View a 3D Tour of all the images featured in  
this eBook!**

If you have a **mobile version** of Human Anatomy Atlas 2021.1 or  
later:

1. [Click here to view the tour.](#)

If you have a **web version** of Atlas:

1. Copy this link:

[https://apps.visiblebody.com/share/?p=vbhaa&t=4\\_34603\\_637569482247969650\\_409621](https://apps.visiblebody.com/share/?p=vbhaa&t=4_34603_637569482247969650_409621)

2. Use the share link button in the app.

3. Paste the link to view the tour.