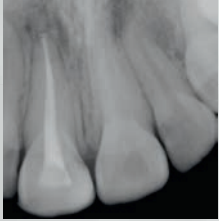

Septodont Case Studies *Collection*

No. 20 - July 2020

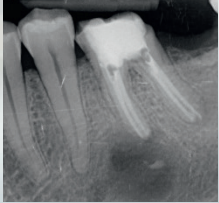
Acute Apical Periodontitis

Dr. Antonio Fernando Herrera de Luna



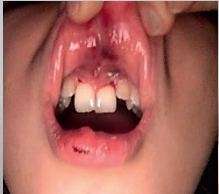Periapical healing: BioRoot™ RCS Bioactive potential

Dr Rocco Zaccone, Dr Patrizio Galeano



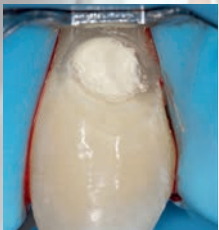Traumatized teeth management

Dr. Antonio Fernando Herrera de Luna



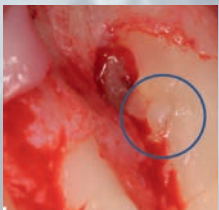Vital pulp therapy

Dr Martin Stalla



External Cervical resorption

Dr Giovanni Marzari



Focus on:
BioRoot™ RCS
and **Biodentine™**



Editorial



Since its foundation Septodont has developed, manufactured and distributed a wide range of high quality products for dental professionals.

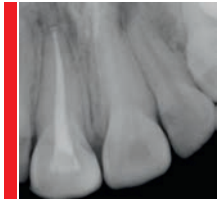Septodont recently innovated in the field of endodontics, dentine care, bone grafting and gingival preparation with the introduction of BioRoot™ RCS, Biodentine™, R.T.R. and Racegel which are appreciated by clinicians around the globe.

Septodont created the “*Septodont Case Studies Collection*” - a series of case reports - in 2012 to share with you their experience and the benefits of using these innovations in daily practice. Over the past years, authors from more than 15 countries have generously contributed to the success of our magazine that is now distributed on the 5 continents.

Each new issue of the Case Studies Collection is the opportunity to discover new clinical challenges and their treatment solutions. This 20th issue features 3 cases for BioRoot™ RCS and 2 cases for Biodentine™:

- BioRoot™ RCS is the new paradigm for endodontic obturations. Its outstanding sealing properties combined with anti-microbial and bioactive properties allow to get a high seal of the endodontium without having to use complex warm gutta techniques.
- Biodentine™, the first biocompatible and bioactive dentin replacement material. Biodentine™ uniqueness not only lies in its innovative bioactive and “pulp-protective” chemistry, but also in its universal application, both in the crown and in the root.

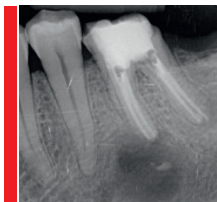
Content



Acute Apical Periodontitis of an upper right central incisor, obturated with BioRoot™ RCS

Dr Antonio Fernando Herrera de Luna

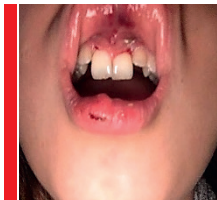
4



Periapical healing: BioRoot™ RCS Bioactive potential

Dr Rocco Zaccone, Dr Patrizio Galeano

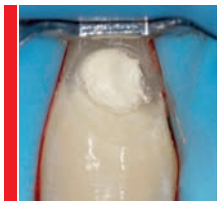11



Traumatized teeth management

Dr Antonio Fernando Herrera de Luna

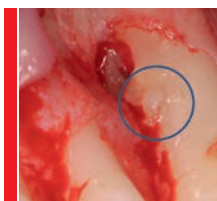
15



Vital pulp therapy on external cervical resorption using Biodentine™

Dr Martin Stalla

22



External Cervical resorption: decision making and treatment using Biodentine™ and bioceramic sealers

Dr Giovanni Marzari

29

Acute Apical Periodontitis of an upper right central incisor, obturated with BioRoot™ RCS

Author: Dr Antonio Fernando Herrera de Luna

Practicing at a Specialized Endodontic Clinic since April 1989.

Research professor in the Endodontics department at Valle de México University's Reynosa campus from 2000 to 2017; professor of theory and clinical work in the Endodontics postgraduate program at UANL from 2009 to 2015.

Summary

Introduction: 18-year-old female patient with a history of 1.1 tooth trauma, restored with resin a month ago. Radiographically, a fairly extensive restoration and a large periapical lesion are observed.

Methods: The patient was diagnosed with acute apical periodontitis. Root canal treatment was undertaken, performing access opening, cleaning, shaping and disinfection of the root canal and placement of calcium hydroxide for 1 month, and subsequent filling

with BioRoot™ RCS sealer and gutta-percha; control examinations were performed at 4, 5 and 7 months.

Discussion: It is interesting to note that although this patient was very young, periodontitis and all its symptoms had been developed within 1 month.

Conclusion: Clinical success of cleaning, shaping, disinfecting and sealing the canal with biocompatible bioceramic sealant.

Introduction

Apical periodontitis may be caused by exogenous or endogenous factors. Exogens may include microorganisms and their toxins, their harmful metabolic by-products, chemical agents, mechanical irritation, foreign bodies, or trauma.

Evidence therefore exists to assert that bacteria are the major etiologic factor in the development of apical periodontitis.⁽¹⁾ As in this particular case, received impact trauma is a primary etiologic factor in the occurrence of periodontitis, and a secondary factor is the bacterial contamination caused by exposure of the dentin tubules to bacteria at the time of the dental fracture; it should be emphasized that the dentin tubules present a clear route to the cavity where the pulp tissue is located, which then becomes necrotic, causing periodontitis.

The success of root canal treatment in apical periodontitis cases depends on adequate cleaning, shaping, disinfection and filling of the root canals.

The primary objectives in cleaning and shaping the root canal system are as follows: a) Remove soft and hard infected tissue. b) Open access for irrigants and to the apical space of the canal. c) Prepare a space for the application of intra-canal treatment and the subse-

quent filling. d) Maintain the integrity of root structures. (2) Root canal sealers are necessary to seal the space between the dentin walls and the interface with the filling material. The sealers also fill bubbles and irregularities in the main, lateral and canal areas, and also fill the spaces between the accessory gutta-percha points used in lateral condensation and serve as lubricants during the filling process. Sealers must be biocompatible and well tolerated by the periapical tissues. (3)

In comparative in vitro studies in periodontal ligament cells, bioroot has been shown to have greater bioactivity than zinc oxide and eugenol; it has also been shown to have fewer toxic effects and to generate increased secretion of antigenic and osteogenic factors. The rapid binding of the sealer to the periodontal ligament result in a visible response of the periodontal ligament cells is visible, showing that this is an appropriate methodology. (4)

This sealer is highly hydrophilic, which provides the advantage of allowing natural humidity in the dental canals and tubes, unlike other sealers, the behavior of which is impacted by humidity. They are dimensionally stable, and do not contract while hardening, but in fact expand slightly, and are insoluble in tissue fluids. (5)

Clinical Case

An 18-year-old female patient presented with pain symptoms. Upon visual and instrumental inspection, we observed a tooth with an extensive resin restoration in the cervical and coronal third, which had been placed after the tooth fractured just over a month ago; she had gone to a dentist 3 days after the fracture occurred. The dentist who treated her told us that he had disinfected the cavity with Consepsis chlorhexidine solution (Ultradent), performed an indirect

capping with TheraCal (Bisco Dental) and restored the tooth with Z250 light-cure resin (3M). He also reported that the tooth was vital at that time, since it responded to cold, heat, and to air from a triple syringe. After restoration, she remained asymptomatic for almost three weeks. Symptom onset occurred at the start of the fourth week, especially when chewing. Always with the examination, palpation and percussion tests were positive, and vita-

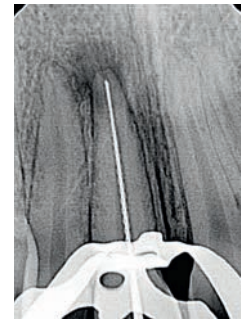
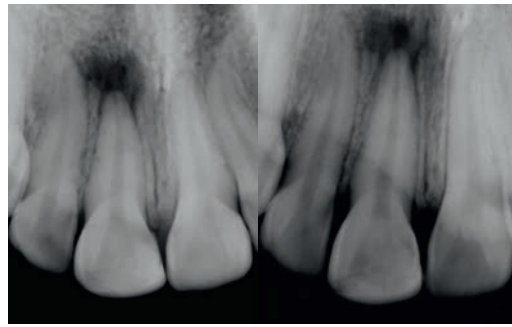
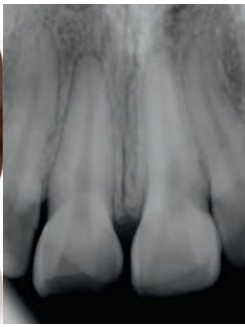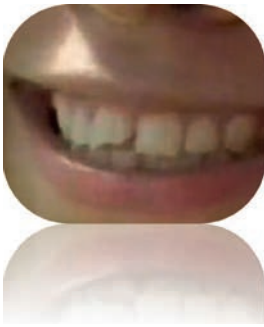
lity tests with cold and heat were negative. Radiographically, a well-circumscribed, substantial lesion was observed. The diagnosis was Acute or Symptomatic Apical Periodontitis.

We proceeded to anesthetize and isolate tooth 1.1, performed antiseptis of the operative field with Isodine, moving from the center of the tooth to the periphery, spanning the clamp and approximately 2 centimeters of the dental dam. Subsequently, we opened an access using a long-shank, ball-shape #4 carbide burr, creating a triangular access cavity; we then proceeded to make a glide path in the canal, using Mani brand RT files, guided by an NSK Ipex II apex locator, and finally obtained a root canal measurement using a #30 RT file at 24 mm, taking a reference point at the incisal edge. Having obtained the root canal measurement, we proceeded to use Gates-Glidden drills at the cervical and middle thirds of the canal from 1 to 5, always recapitulating with the #25 file and irrigating with 1.25% sodium hypochlorite; we then began rotary instrumentation of the canal using the MANI Silk system, in the following sequence: 20/04.25/04.25/06.35/04.30/06.40/04; for the remaining diameters, 45/04 and 04/50 HyFlex tools were used, and manual recapitulation performed with a 45 RT file.

A final passive irrigation was then performed with 5% hypochlorite for 5 minutes, followed by irrigation with saline solution; subsequently 17% EDTA was placed for a final irrigation with saline solution; the area was then dried with #45 paper points and recapitulated with a 45 RT tool. Calcium hydroxide mixed with iodoform and propylene glycol was then placed and introduced into the canal using a file 2 sizes smaller than the master file. In this case, a number 35 was used, and medication was left in for 3 weeks. At the next appointment, the patient was anesthetized, isolated, and irrigated with saline solution. The root canal was then dried and filling was performed. A

size 45 gutta-percha point was fitted in and a cone test was performed. The BioRoot™ RCS sealer cement was prepared according to the manufacturer's instructions (I personally use a chilled mixing pad so as to increase the working time of the cement); after placing the powder on the mixing pad using the spoon included in the kit and dividing it into 4 segments, 5 drops of the liquid were added and mixed into the powder segment by segment, using very short spatula movements and continuously rotating the mixing pad to accelerate the mixing process; once this was achieved, finally, one more drop of the liquid was added to obtain the proper consistency for greater cement plasticity, and the consistency checked by drawing out a strand; this entire procedure was performed in one minute. Once the sealer was prepared, the canal was sealed using cold lateral compaction. The #45 gutta-percha master point was then placed with the bio-root sealer and brought to the depth previously sounded with a pumping motion to allow the sealant to settle free of any bubbles. A previously calibrated MA57 spacer was then used for lateral gutta-percha condensation to accommodate the Fine-Fine accessory cones, which were put in with sealer as well; condensation was verified by an obturation X-ray test, and then the protruding points were severed using a 33L spoon heated directly in a burner flame; vertical compaction was performed, a D11 spacer placed in the center of the gutta-percha mass, obturation performed with a medium point, and the excess cut off using the 33L spoon, and one last vertical condensation conducted using a Glick #1 tool. The cavity was then cleaned with an alcohol swab and a sterile Teflon swab, and Cavit was placed as a provisional restoration.

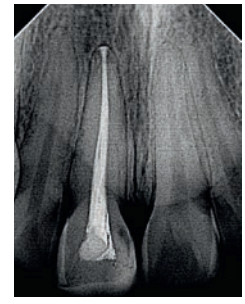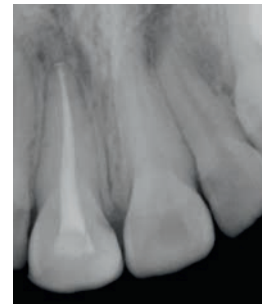
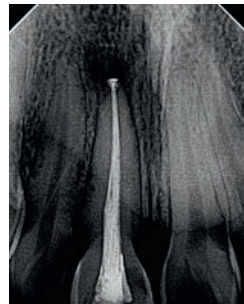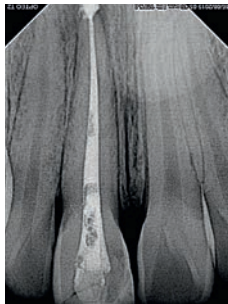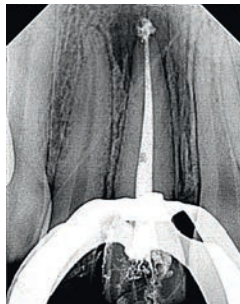The patient was referred to her dentist for the subsequent final restoration. Clinical and radiographic controls were performed at 4, 5, and 7 months.



Post-trauma preoperative X-ray 05/07/2019, 1 month prior to treatment.

Preoperative X-rays the day treatment began, 16/08/2019.

Radiographic root canal measurement. 16/08/2019.



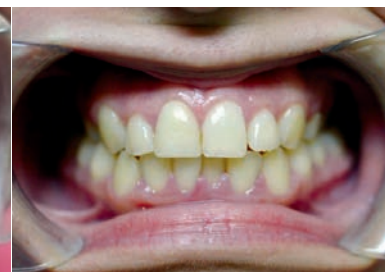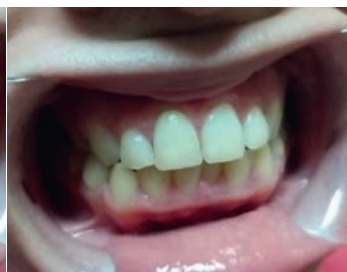
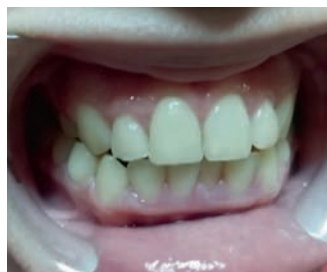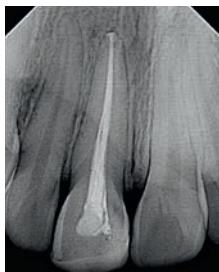Intra-canal medication 16/08/2019.

Intra-canal medication prior to obturation, 16/08/2019.

Lateral obturation technique, using gutta-percha and BioRoot™ RCS sealer, 10/09/2019.

1st clinical-radiographic control at 4 months, 22/01/2020.

2nd clinical examination X-ray 5 months, 24/02/2020.



3rd clinical examination. 7 months. X-ray. 07/04/2020.

Clinical photographs. 07/04/2020.

Discussion

The etiology, pathogenesis, and histopathology of apical periodontitis are similar to those of marginal periodontitis. Both diseases are caused by bacterial infection and involve pathological changes in the alveolar bone, the periodontal ligament and the cementum. Marginal periodontitis affects the coronal periodontal tissues, while apical periodontitis affects the apical periodontal tissues. Bone loss is one of the characteristic factors in both diseases; bone crest is lost in marginal periodontitis, and apical bone undergoes resorption in apical periodontitis. (1)

A major biological goal of root canal therapy is the management of apical periodontitis through the disinfection and subsequent sealing of the root canal system; in terms of the traditional concepts used in endodontic therapy, the cleaning then shaping of root canals was for many years considered the proper order; it has now emerged that it is appropriate to reverse the order typically applied, and instead first shape and then clean; the current concept is shaping with new instrumentation systems, and most practitioners now favor the preparation of

canals with a greater taper and the conservation of more of the tooth structure, implementing cleaning through the irrigation of the canals with different techniques and implements, whether passive, sonic or ultrasonic. (2)

In regard to immediate intra-canal medication with Calcium Hydroxide in teeth presenting apical periodontitis, Dr. Safavi has reported that exposure of bacterial lipopolysaccharides (lps) to calcium hydroxide causes hydrolysis of

the lipid component, resulting in endotoxin degradation.

An important complement to the obturation of root canals is the use of a good endodontic sealer. Tricalcium silicate-based sealers exhibit proven bioactivity in the presence of tissue fluids, with the deposition of hydroxyapatite ions on the surface of the material. This bioactivity induces the formation of hard tissue and the healing of connective tissue. (6)

Conclusion

Success in the repair process subsequent to a root canal treatment is measured by the absence of the clinical signs and symptoms of a persistent periapical condition. The definitive measure of success, however, is periapical repair, because the goal of treatment is the resolution of periapical disease. Clinical assessment of a successful treatment is based on the absence of signs of infection and inflammation such as pain; percussion sensitivity; tenderness to the palpation of the surrounding periapical tissues; absence of inflammation or sinus tract, and above all the radiographic demonstration of a reduction in the size of the periapical lesion. Most periapical lesions repair within the first year; depending on the size of the injury, repair may continue for up to four years or more. (7)

In this particular case, the trauma caused by the dental fracture and the exposure of the dentin to the oral environment for 3 days were most likely the cause of the impending pulp necrosis and the rapid development of symptomatic apical periodontitis.

Sealing the root canal system is a very important part of endodontic treatment, and using a bioactive sealer is essential to ensure a successful one. Tricalcium silicates are highly hydrophilic which provides the advantage of allowing natural humidity in the dental canals and tubules, unlike other sealers, the behavior of which is impacted by humidity. They are dimensionally stable, and do not contract while hardening, but in fact expand slightly, and are insoluble in tissue fluids. (5)

**Author:****Dr. Antonio Fernando Herrera de Luna**

Oral surgeon, graduated from the Technological University of Mexico in 1986.

Post-graduate work in endodontics at the Oral Rehabilitation Research and Specialization Center (CIERO) from January 1987 to July 1988.

Residency at the department of endodontics, Mogi-das Cruces University-Sao Paulo, Brazil, from January to July 1991.

Professor of endodontics and research professor at the College of Dentistry of the Valle de Mexico University, Reynosa campus, from 2000 to December 2017.

Ex-professor in theory and clinical work in the postgraduate endodontics program at UANL.

Licensed; 1st, 2nd, 3rd and 4th recertification by the Mexican Endodontics Council.

Member of the ADM (Mexican Dental Association) since 1992.

Member of AME (Mexican Endodontics Association A.C.) since 1995.

Lecturer at AME.

President of the Mexican Association of Endodontics, College of Endodontics Specialists, A.C. two-year term June 2013-June 2015.

Various publications in the Endodontics Field in the magazine of the Mexican Dental Association (ADM) and in the magazine of the Mexican Endodontics Association (AME).

Participated as an international lecturer on the subject of endodontic regeneration, presenting in:

- Japan at the World Endodontic Congress in May 2013 (IFEA).
- Brazil at the Congress of the Brazilian Endodontic Society and the Latin American Endodontic Society (SELA) in November 2014.
- Barcelona at the Congress of the European Endodontic Society (ESE), September 2015.

Visiting professor for the postgraduate program in endodontics at the autonomous university of Yucatan and Ciudad Juarez.

"Dr. Fernando Campuzano" medal, awarded by the College of Oral Surgeons of Reynosa, A.C. in February 2004.

"Dr. Fernando Campuzano Odontological Merit Award", awarded by the National Council of the ADM, August 2009.

"Teaching Career Prize" awarded by Valle de Mexico University, Reynosa campus, December 5, 2013.

Egregius academic excellence award for educational work granted by Valle de Mexico University, Reynosa campus, October 20, 2017.

Presented at more than 100 conferences at the national and international level.

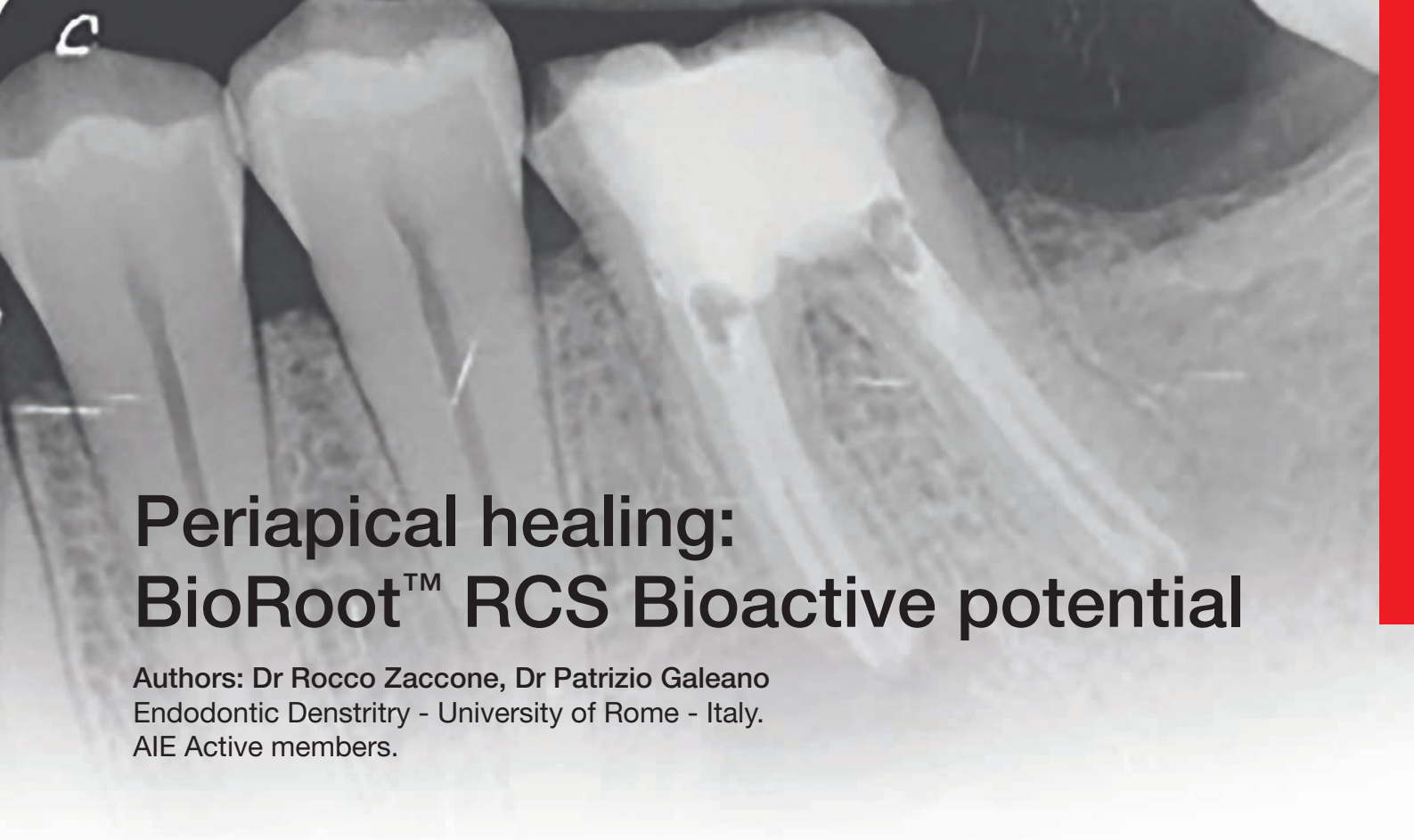
Exclusive private endodontics practice from 1989 to date in the city of Reynosa Tamaulipas.

Conference topics:

1. Bioactive cements.
2. Cleaning and shaping of root canals with cutting edge instruments.
3. Endodontic regeneration: current concepts and clinical cases.
4. Endodontic diagnosis and pulp and periapical pathology.

References

1. Lin Louis M; Huang George T.J; Pathobiology Of Apical Periodontitis; Chapter 15; Pages 631-632. Cohen's Pathways Of The Pulp. Eleventh edition. Kenneth M. Hargraves, Louis H Berman. Editor - Ilan Rotstein. Elsevier 2016.
2. Peters Ove. A; Peters Christine I.; Basrani Bettina. Cleaning And Shaping The Root Canal System. Chapter 6. Page 210. Cohen's Pathways Of The Pulp. Eleventh edition. Kenneth M. Hargraves, Louis H Berman. Editor - Ilan Rotstein. Elsevier 2016.
3. Johnson William; Kulild James C; Tay Franklin; Obturation Of The Cleaned And Shaped Root Canal System. Chapter 7. Page 290. Cohen's Pathways Of The Pulp. Eleventh edition. Kenneth M.hargraves, Louis H Berman. Editor - Ilan Rotstein. Elsevier 2016.
4. Camps Jean; Jeanneau Charlotte; Laurent Patrick; About Imad. Bioactividad Del Sellador Endodontico A Base De Silicato De Calcio-Bio-Root-Rcs.interacciones Con Celulas Humanas Del Ligamento Parodontal – Estudio In Vitro. [bioactivity of BioRoot-RCS calcium silicate based endodontic sealer. Interactions with human periodontal ligament cells - in vitro study] Journal of Endodontics. A.A.E. 2015.
5. Trope Martin; Bunes Alf; Debelian Gilberto; Root Filling Materials And Techniques, Bioceramics A New Hope. Endodontics Topics, 2015. Vol 32. Pages 86-96.
6. Arias Moliz MT; Camilleri J. The effect of the final irrigant on the antimicrobial activity of root canal sealers. Journal of Dentistry. 2016 Elsevier, Ltd.
7. Xuan-Li NG; Gulavibala K. Evaluation Of Outcomes. Chapter 11. Pages 478. Cohen's Pathways Of The Pulp. Eleventh edition. Kenneth M. Hargraves, Louis H Berman. Editor - Ilan Rotstein. Elsevier 2016.



Periapical healing: BioRoot™ RCS Bioactive potential

Authors: Dr Rocco Zaccone, Dr Patrizio Galeano
Endodontic Denstritry - University of Rome - Italy.
AIE Active members.

Summary

In this case report, we will talk about the properties and regenerative capacity of BioRoot™ RCS. In addition to the antibacterial and biocompatibility properties, bioceramics are characterized by a very important regenerative capacity. In this case

of a 3.6 retreatment of an extensive periapical lesion, we have used BioRoot™ RCS: we noticed an extremely rapid recovery considering that only 8 months have elapsed between the first and the last X-Ray.

Introduction

Primary endodontic treatment does not always result in clinical success.

The causes? They may be multiple and determined by three main consequences:

- 1) An incomplete cleaning / shaping / filling of the root canals
- 2) The presence of radiologically visible lesions
- 3) Pain of the patient during percussion, palpation and chewing.

Retreatment is the best therapeutic approach to solve these clinical situations, if well performed, with a success rate of 85%, as reported in the articles. This procedure has the purpose

of shaping, cleaning and filling the parts that have been treated with the aim of reducing the contamination of the bacteria present in the root canals and responsible for endodontic lesions.

When should retreatment be done?

- 1) Presence of radiologically visible lesions
- 2) Presence of iatrogenic damage
- 3) Presence of an incongruous treatment, even in the absence of symptoms, if on the same session we have to do a prosthetic rehabilitation
- 4) Persistent pain symptoms even in the absence of injury.

What are the various phases that characterize retreatment?

- 1) Isolation with rubber dam
- 2) Removal of the previous restoration and of any carious tissue
- 3) Obtaining a correct access to the canal system
- 4) Removal of the materials present inside the endodontic space
- 5) Shaping, cleaning and filling of the root canal.

The success rate in retreatment is certainly lower than in the primary treatment as we can find some bacterial species within the canals, such as the *Enterococcus faecalis* and the *treponema denticola*, which are much more resistant to the various mechanical and irrigation phases which characterize a retreatment and also for their ability to penetrate the dentinal tubules.

Therefore the success rate can be considerably increased by using materials that guarantee both an intimate adhesion to the canal walls and

a long-term stability. Before, the gold standard of the endodontic seal was represented by the vertical hot condensation of Schilder. But today, the tendency is to believe that the cold closure with single cone associated the bioceramic cement can guarantee us the three-dimensional stability of the long-term endodontic seal that we are constantly searching for.

In fact, with hot sealing, the gutta percha contracts as it gets cold, creating a gap between itself and the walls of the canal, which over time will potentially allow any residual bacteria to re-colonize the endodontic space; instead the bioceramics, as in this clinical case presented and treated with the BioRoot™ RCS (Septodont), are cements that have advantages such as:

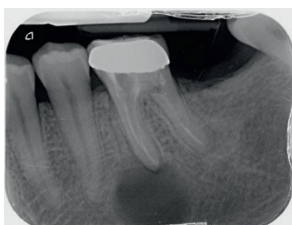
- 1) No presence of resin therefore no retraction
- 2) No vacuum in the interface
- 3) No tubular infiltration
- 4) Hydroxyapatite formation and dentin mineralization.

Clinical case

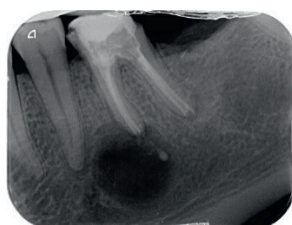39-year-old male MLR Caucasian patient reported by a colleague who could not completely remove a fiber post in the distal root; he was performing retreatment because the root canals, under X-ray examination, appeared to be undersized and under-prepared. (X-ray 1) The patient complained of pain during palpation and percussion, and the clinical picture showed the presence of an active vestibular fistula. The radiographic examination shows an extended periradicular lesion of the mesial root. (X-ray 2) Once the operating field is isolated, the pin is removed from the distal root through the use of the operating microscope which had previously

been neither found nor treated; at the same time the old filling material is removed from the canals m.v and m.l. , which turned out to be undersized in the preparation, creating an adequate preparation under continuous alternate washes of hypochlorite and EDTA at 17% constantly activated with sonic tips.

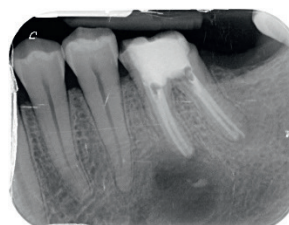The closure of the root canals was performed cold with gutta-percha cones, chosen according to the new canal preparation, and BioRoot™ RCS. The X-rays made at 3 and 5 months after the closure show that, even after a very short time, there was a complete healing of the bone. (X-ray 3 and X-ray 4)



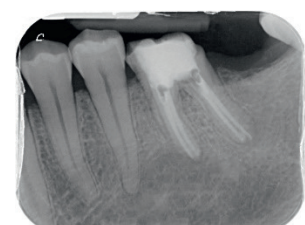X-ray 1



X-ray 2



X-ray 3



X-ray 4

Discussion

Bioceramics are today quite known materials in the literature, mainly because they represent an important step forward in the search for the ideal root canal sealer. The BioRoot™ RCS guarantees us innumerable properties including extraordinary sealing capacities, antimicrobial activity that stimulates periapical healing. It is a bioactive material that continues to produce hydroxyapatite for a long time after mixing, adapting to the dentinal walls and optimizing its sealing capacity. This is a very interesting material because it adheres very well to both dentin and gutta-percha, therefore it can be used in cold closing techniques. How is it used? Once the cone is prepared according to the diameter. We have to cut it to the proper working length. Then, we mix the powder with the liquid to obtain a viscous / fluid consistency.

Subsequently the cone is wet with the mix and inserted several times until the root canal is submerged by the cement and the surfaces of the master cone are completely covered by the same. In this way we will be sure that the BioRoot™ RCS cement will seal the apical portion of the canal where the greatest chances of endodontic success are played. Cold closure, using any other endodontic cements on the market can be absorbed over time, and it has always been considered an ineffective technique. On the other hand, with the discovery of bioceramics, the cement plays a crucial role because it permanently seals the root canal including the apex. The gutta-percha cone - which must be brought up to the apex - has the function of being only a guide for possible future retreatment.

Conclusion

The case described above shows us how BioRoot™ RCS, thanks to its ability to firmly adhere both to the gutta-percha and to the walls of the canal definitively seals the apical third, which allow us to obtain healing in a short

amount of time by its antimicrobial properties. However, further clinical studies must be performed to assess the effectiveness of this technique on the long term.



Authors:
Dr Rocco Zaccone

Doctor Rocco Zaccone is specialized in the use of the operating microscope and he practices his profession in many cities in Italy, especially in Rome, Capri and Florence.

Professor at the Post-graduate Master of the "Catholic University of the Sacred Heart" in Rome, he keep working as tutor at the Endodontics department of the Polyclinic Agostino Gemelli of Rome.

He holds the role of active member of AIE (Italian Endodontics Academy) and he founded together with Prof. Grande, Dr. Galeano and Dr. Del Giudice the "Francesco Riitano Study Group".

Speaker at national courses and conferences, he spends his free time looking for new dental techniques.



Dr Patrizio Galeano

Graduated with honors in Dentistry and Dental Prosthesis from the University of Rome "Tor Vergata" in 2005.

From 2001 to 2014 Dr Galeano participated in the clinical, didactic activity of the chair of Dentistry Conservative and Endodontics of the same University.

Active Member of the Italian Academy of Endodontics (AIE).

Ordinary member of the European Endodontic Society (ESE).

Ordinary member of the Italian Academy of Conservation (AIC).

He holds the role of tutor at the International Master in Endodontics at the Catholic University of the Sacred Heart in Rome and lecturer at the ASO course in Rome directed by Igea Media.

Founding member of the study group "Francesco Riitano".

Speaker at national courses and conferences.

He carries out his freelance activity with particular interest in the fields of Endodontics and Restoration.

References

1. Viapiana R, Moizadeh AT, Camilleri L, Wesselink PR, Tanomaru Filho M, Camilleri J. Porosity and sealing ability of root fillings with gutta-percha and BioRoot™ RCS or AH Plus sealers. Evaluation by three ex vivo methods. *Int Endod J.* 2016;49(8):774-82.
2. Camps J, Jeanneau C, El Ayachi I, Laurent P, About I. Bioactivity of a Calcium Silicatebased Endodontic Cement (BioRoot™ RCS): Interactions with Human Periodontal Ligament Cells In Vitro. *J Endod.* 2015;41(9):1469-73.
3. Jeong JW, DeGraft-Johnson A, Dorn SO, Di Fiore PM. Dentinal Tubule Penetration of a Calcium Silicatebased Root Canal Sealer with Different Obturation Methods. *J Endod.* 2017;43(4):633-637.
4. McMichael GE, Primus CM, Opperman LA. Dentinal Tubule Penetration of Tricalcium Silicate Sealers. *J Endod.* 2016;42(4):632-6.
5. Alshehri M, Alamri HM, Alshwaimi E, Kujan O. Micro-computed tomographic assessment of quality of obturation in the apical third with continuous wave vertical compaction and single match taper sized cone obturation techniques. *Scanning.* 2016;38(4):352-6.
6. Donnermeyer D, Bunne C, Schäfer E, Dammaschke T. Retreatability of three calcium silicate-containing sealers and one epoxy resin-based root canal sealer with four different root canal instruments. *Clin Oral Investig.* 2017 Jun 22. doi: 10.1007/ s00784-017-2156-5. (Epub ahead of print)



Traumatized teeth management

Author: Dr Antonio Fernando Herrera de Luna

Practicing at a Specialized Endodontic Clinic since April 1989.

Research professor in the Endodontics department at Valle de México University's Reynosa campus from 2000 to 2017; professor of theory and clinical work in the Endodontics postgraduate program at UANL from 2009 to 2015.

Summary

Introduction: Traumatized teeth always present a major challenge; if a good diagnosis is made, we can establish an objective prognosis in the case and determine an optimal use of techniques and materials.

Methods: We first performed a repositioning of the dislocated and fractured teeth, applying anesthesia, and after moving them to their original sites, they were immediately splinted with orthodontic wire. In time, they presented with apical periodontitis; they were treated with calcium hydroxide, then filled with gutta-percha and BioRoot™ RCS bioceramic sealer. Controls were taken at 4 and 22 months.

Discussion: Trauma is always a difficult terrain to navigate, especially when it comes to obtaining successful results, which greatly depend on the clinician's skill, speed and use of adequate materials.

Conclusion: The clinical management of traumatized teeth must always be guided by concepts of biology, and must use techniques and materials that promote the best healing and repair.

Introduction

Subluxation of a tooth after trauma is a simple loosening of the tooth, without any displacement. However, tooth luxation only implies dislocation, rather than actual displacement from the socket (avulsion). Dislocation damage is the most common type of dental trauma. With subluxation, severe damage to the blood vessels supplying the pulp is highly unlikely, so there is a possibility that it will survive. On the other hand, in injuries caused by luxation, where the pulpal blood vessels are severely damaged at the apex, there is still the possibility of revascularization if the fragments are repositioned promptly, infection is prevented, and the root is immature and with an open apex. One dislocated tooth had to be de-impacted and moved from its new location back to its correct location. For mature teeth that have been dislocated, there is no chance of pulp revascularization. The pulp should therefore be removed 2 weeks after repositioning, and the canal subsequently obturated (1).

The various types of dislocation injuries can be defined as follows:

1. Concussion: Implies that no displacement of the tooth has occurred; there will be normal mobility and sensitivity to percussion.
2. Subluxation: Sensitive to percussion, increased mobility, but no still no displacement.
3. Lateral dislocation: Involves buccal, lingual or palatal, distal or incisal displacement.
4. Extrusive dislocation: Involves displacement in a coronal direction.
5. Intrusive dislocation: It involves a displacement in an apical direction, within the socket.

Dislocation injuries as a group are the most common of all traumatic injuries, with a reported incidence ranging from 30 to 44%.

Teeth with lateral or extrusive dislocation must be repositioned as soon as possible.

The clinical guidelines of the International Association of Dental Trauma (IADT) suggests 2 weeks of physiological splint in cases of extrusive dislocation and 4 weeks for lateral dislocation.

When, in addition to an extrusive dislocation, there is also a root fracture present at the site, as in this particular case, it is recommended that the segments be reapproximated to the extent possible.

Where the coronal and apical pulp are necrotic, treatment is more complicated.

Endodontic treatment through a fracture is extremely difficult. Endodontic maneuvers, medications, and filling materials all have a detrimental effect on healing at the fracture site. (3) Tricalcium silicate-based sealers exhibit proven bioactivity in the presence of tissue fluids, with the deposition of hydroxyapatite ions on the surface of the material. This bioactivity induces the formation of hard tissue and the healing of connective tissue. (4)

Clinical case

A 21-year-old female patient reports slipping when getting out of the bathtub, and failing to stop her fall with her hands received a direct blow to the maxillary anterior area.

She presented at the office two days after the incident with dislocation of both maxillary central incisors in an anteroposterior direction, such that

the longitudinal axis of both central incisors had changed as a result of the trauma, preventing her from achieving normal occlusion in that area. The X-rays show foreshortened images; tooth 1.1 has been displaced from its socket, and tooth 2.1 clearly shows a horizontal fracture at the junction of the middle and apical third, with

displacement of the root and crown fragment about 7 mm in a coronal direction.

Anesthesia was applied to the maxillary central area and the upper centrals were then repositioned, moving them into place with the fingers, using controlled pressure; once they had been returned to their proper longitudinal axis, we used a splint made of 3 tongue depressors, one placed on top of the other and attached at the ends with adhesive tape, asking the patient to bite down on the splint by pressing against it, and maintaining pressure until the teeth were completely repositioned. Immediately, then, and without the patient releasing pressure on the depressor splint, we splinted the teeth with orthodontic wire and fluid resin, from canine to canine. Antibiotic and anti-inflammatory drugs were prescribed and a return appointment was set 2 weeks later.

Three weeks later the patient returned, presenting apical periodontitis in 1.1; even in the presence of the splint, the following protocol was applied: having obtained the root canal measurement, we proceeded to use Gates-Glidden drills at the cervical and middle thirds of the canal from 1 to 5, always recapitulating with the #25 file and irrigating with 1.25% sodium hypochlorite; we then began rotary instrumentation of the canal using the MANI Silk system, in the following sequence: 20/04.25/04.25/06.35/04.30/06.40/04 and for the remaining diameters using 45/04 and 04/50 HyFlex tools, and manually recapitulating with a 45 RT file; finally calcium hydroxide and iodoform powder were applied, with propylene glycol as a vehicle. An X-ray was taken and a substantial extrusion of material was observed. The patient returned 15 days later, with the splint still on; obturation was performed using gutta-percha and Sealapex sealer.

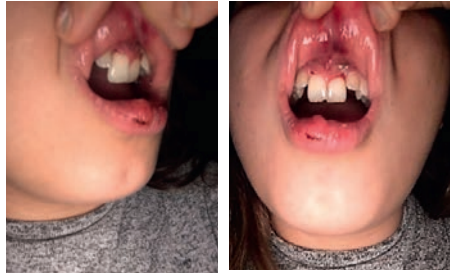3 months later, with the splint off, the patient returned for a first control examination; tooth 1.1 presented no symptoms, but tooth 2.1 was sensitive to palpation and percussion; upon radiographic analysis a radiolucent area was observed at the root surface in the area of the

fracture, along with a sinuous tract. We explained to the patient that the prognosis for that tooth in the fracture area was poor, and she decided to make an attempt.

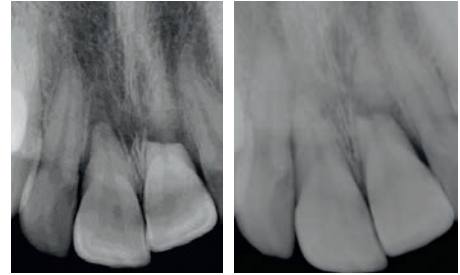
The patient scheduled an appointment to start work on tooth 2.1 just 1 month 10 days later. Treatment of tooth 2.1 was started using the same instrumentation protocol as had been applied for tooth 1.1, applying the same final apical diameters, but performing chlorhexidine irrigation, as we did not want to irritate the fractured portion with hypochlorite; calcium hydroxide with iodoform was then placed using a propylene glycol vehicle. An appointment was set for 15 days later for a control examination and to perform the filling and/or replace the calcium hydroxide.

The patient returned after 15 days, asymptomatic and presenting no sinuous tract, and obturation was performed using gutta-percha and BioRoot™ RCS sealer following the manufacturer's preparation instructions. A size 45 gutta-percha point was fitted in and a cone test was performed. The BioRoot™ RCS sealer cement was prepared according to the manufacturer's instructions (I personally use a chilled mixing pad so as to increase the working time of the cement); after placing the powder on the mixing pad using the spoon included in the kit and dividing it into 4 segments, 5 drops of the liquid were added and mixed into the powder segment by segment, using very short spatula movements and continuously rotating the mixing pad to accelerate the mixing process; once this was achieved, finally, one more drop of the liquid was added to obtain the proper consistency for greater cement plasticity, and the consistency checked by drawing out a strand; this entire procedure was performed in one minute. A MA57 spreader was used to make room for the fine accessory points. Once this process was complete, obturation was verified with an X-ray, a heated tool was used for cutting, and vertical condensation was performed. Clinical and digital radiography controls were then performed at 4 and 22 months, providing clinical and radiographic evidence of repair, particularly in tooth 2.1, where the patient presented an apical horizontal fracture.

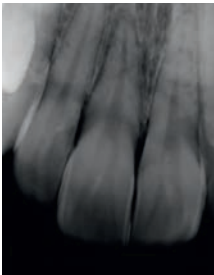
Photographs and X-rays



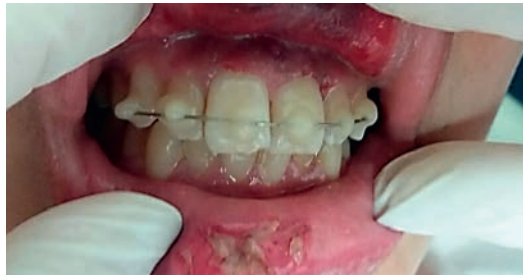Initial post-trauma photographs taken by patient.



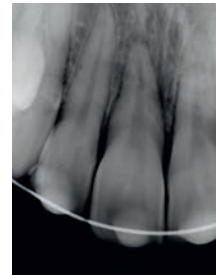
Initial X-rays.



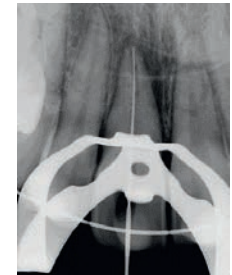Repositioning of fragments.



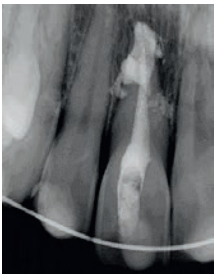
Splinting with orthodontic wire and resin.



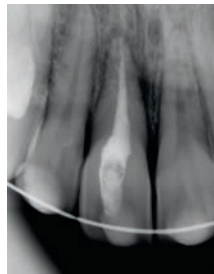
X-rays of splint.



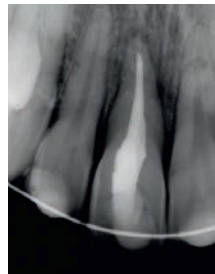
April 7th, 2017. 3 weeks later patient presents with apical periodontitis in tooth 1.1.



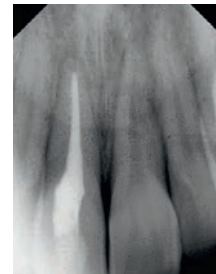
Placement of calcium hydroxide with iodoform in a propylene glycol vehicle, 07/04/2017.



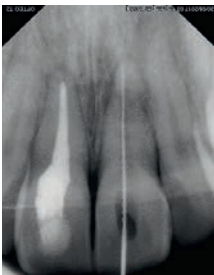
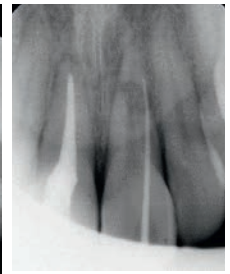21/04/2017 calcium hydroxide with iodoform in a propylene glycol vehicle (15 days).



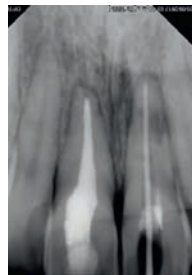
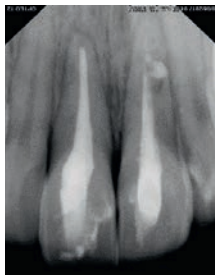
Final X-ray, 21/04/2017 (1.1) tooth sealed with gutta-percha and sealapex.



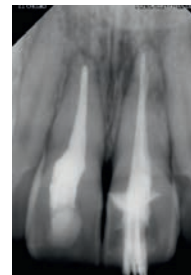
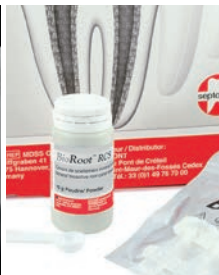1st control, 3 months, July 20th, 2017 (2.1 sinuous tract, fistulography performed).



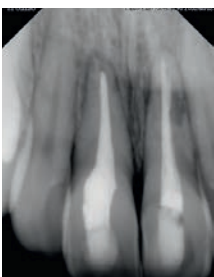
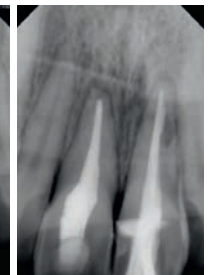
Instrumentation and placement of medication 30/08/2017 (2.1).



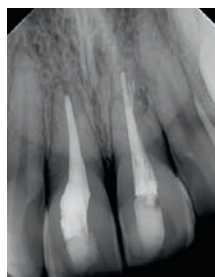
Points and BioRoot™ RCS sealer X-ray test.



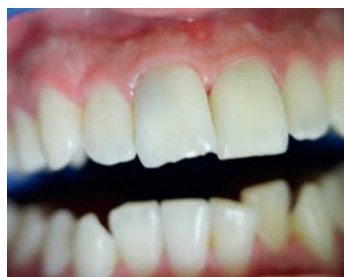Obturation X-ray test 20/09/2017.



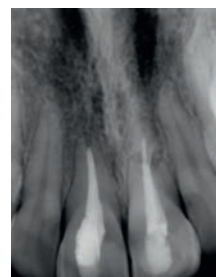
Final X-ray 20/09/2017.



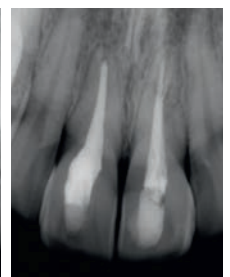X-ray control at 4 months.



Clinical photography control at 4 months.



Control at 22 months.



Discussion

In this specific case, tooth 1.1 was described as having an extrusive dislocation, and tooth 2.1 as having an extrusive dislocation with an oblique root fracture in the apical third.

Traumatic impact may occur in teeth from different directions. Most often, traumatic impact to teeth occurs at the vestibular surface at approximately a right angle to the root axis. With other directions of impact, other fracture lines may be seen. In regard to the direction and position of the fracture lines caused by frontal blows, four categories of fractures are observed:

1. Horizontal fractures of the crown.
2. Horizontal fractures in the cervical third of the root.
3. Oblique fractures of the crown and root.
4. Oblique fractures of the root alone.

Frontal impacts to the vestibular part of the anterior teeth generate forces that tend to displace the crown in a lingual direction. A situation may then arise where the bone and periodontal ligament have resisted displacement. In the marginal and apical areas,

the bone and the periodontal ligament exert a compressive force on the root surface in the middle zone, referred to as zone (a), and another compressive force in the apical zone, referred to as zone (b). Consequently, tension will develop between the two opposing force zones (a) and (b); the root thus becomes fractured, since the tensile strength of the fragile dental tissues is much less than the compression force. A fracture thus occurs along the oblique line connecting compression zones (a) and (b) (5).

Dislocation injuries result in damage to the insertion apparatus (periodontal ligament and cementum); the severity of the case depends on the type of injury that has occurred. The apical neurovascular supply to the pulp is thus affected to various degrees, ranging from disturbed pulp to non-vital or necrotic pulp.

Healing may be favorable or unfavorable; after a dislocation injury, repair will be favorable if the initial physical damage to the root surface and the resulting inflammatory response to the damaged external root surface are recovered by cementum. (2)

Conclusion

Extrusive dislocations have a good prognosis as long as they are repositioned as soon as possible and immediately splinted. If the apex is immature they will probably undergo revascularization, but if it is mature, endodontic treatment is the only option. (1) Complications arise when in addition to the dislocation there is a fracture, as in this case, where in one of the teeth a horizontal separation occurred at the junction of the middle and apical third. Fortunately, we were able to reposition it and restore it to its original position. Calcium hydroxide was used in both teeth, because both developed apical periodontitis (6) once they had been repositioned and splinted. For the fracture, however, the decision was made to use a tricalcium silicate-based cement sealer with the specific

intention of promoting better healing and repair of the hard tissue involved in the injury. (4)

Healing of the root fracture occurs in this case as a repair with calcified tissue; the line of the fracture can be observed radiographically, but the fragments are in close contact. The teeth were asymptomatic upon palpation and upon percussion, and presented no sinus tract; radiographically there was no periapical pathology or reabsorption areas. (3) In this case, the intention of using a tricalcium silicate based sealer was to induce hard tissue formation in the fracture area. These sealers exhibit proven bioactivity in the presence of tissue fluids, with the deposition of hydroxyapatite ions on the surface of the material. This bioactivity induces the formation of hard tissue and the healing of connective tissue. (4)



Author:

Dr Antonio Fernando Herrera de Luna

Oral surgeon, graduated from the Technological University of Mexico in 1986.

Post-graduate work in endodontics at the Oral Rehabilitation Research and Specialization Center (CIERO) from January 1987 to July 1988.

Residency at the department of endodontics, Mogi-das Cruces University-Sao Paulo, Brazil, from January to July 1991.

Professor of endodontics and research professor at the College of Dentistry of the Valle de Mexico University, Reynosa campus, from 2000 to December 2017.

Ex-professor in theory and clinical work in the postgraduate endodontics program at UANL.

Licensed; 1st, 2nd, 3rd and 4th recertification by the Mexican Endodontics Council.

Member of the ADM (Mexican Dental Association) since 1992.

Member of AME (Mexican Endodontics Association A.C.) since 1995.

Lecturer at AME.

President of the Mexican Association of Endodontics, College of Endodontics Specialists, A.C. two-year term June 2013-June 2015.

Various publications in the Endodontics Field in the magazine of the Mexican Dental Association (ADM) and in the magazine of the Mexican Endodontics Association (AME).

Participated as an international lecturer on the subject of endodontic regeneration, presenting in:

- Japan at the World Endodontic Congress in May 2013 (IFEA)
- Brazil at the Congress of the Brazilian Endodontic Society and the Latin American Endodontic Society (SELA) in November 2014.
- Barcelona at the Congress of the European Endodontic Society (ESE), September 2015.

Visiting professor for the postgraduate program in endodontics at the autonomous university of Yucatan and Ciudad Juarez.

"Dr. Fernando Campuzano" medal, awarded by the College of Oral Surgeons of Reynosa, A.C. in February 2004.

"Dr. Fernando Campuzano Odontological Merit Award", awarded by the National Council of the ADM, August 2009.

"Teaching Career Prize" awarded by Valle de Mexico University, Reynosa campus, December 5, 2013.

Egregius academic excellence award for educational work granted by Valle de Mexico University, Reynosa campus, October 20, 2017.

Presented at more than 100 conferences at the national and international level.

Exclusive private endodontics practice from 1989 to date in the city of Reynosa Tamaulipas.

Conference topics:

1. Bioactive cements.
2. Cleaning and shaping of root canals with cutting edge instruments.
3. Endodontic regeneration: current concepts and clinical cases.
4. Endodontic diagnosis and pulp and periapical pathology.

References

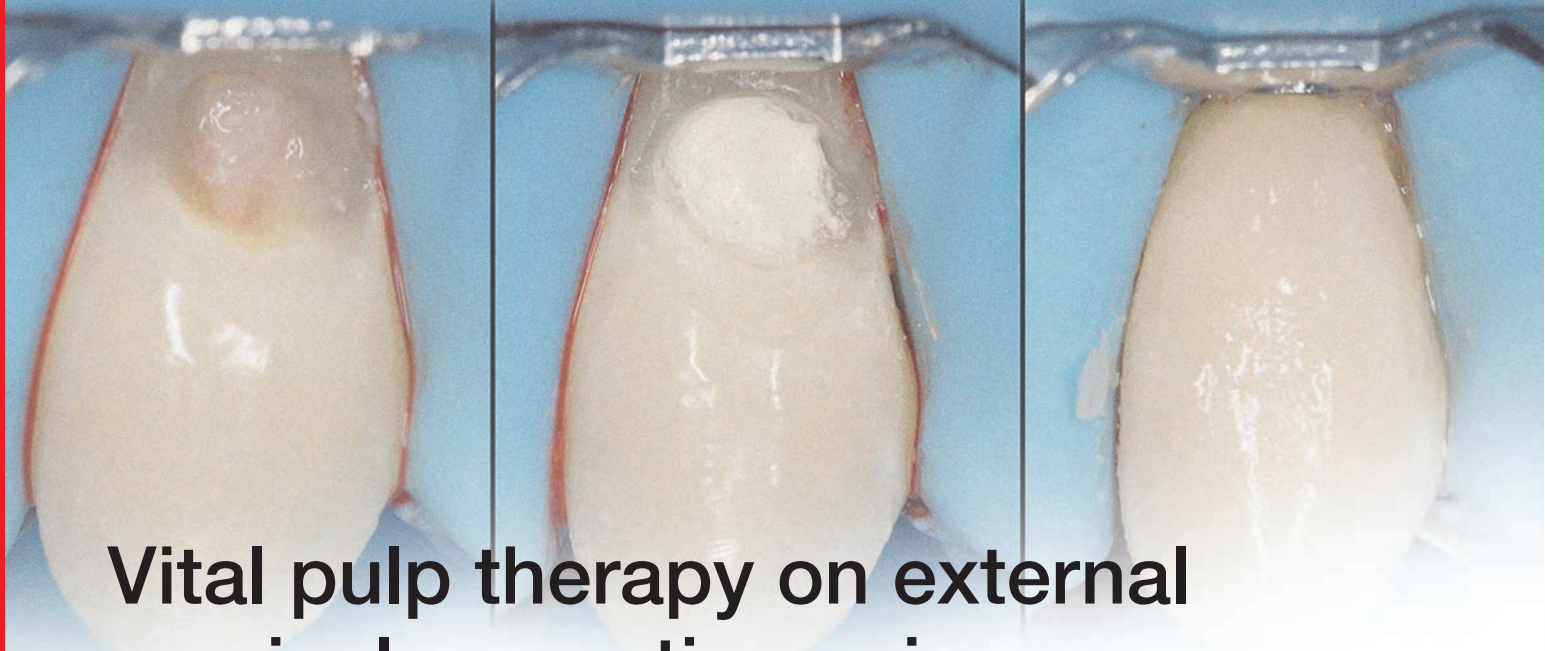
1. Pitt Ford TR Odor TM; Endodontic Aspects of Traumatic Injuries. Harty's Endodontics in Clinical Practice. Edited by T.R. Pitt Ford. Wright Editorial. Fourth Edition. 2001.
2. Trope Martin; Barnet Frederic; Sigurdson Asgeir; Chivian Noah. The Role of Endodontics After Dental Traumatic Injuries. Page 777. Cohen's Pathways of the Pulp. Eleventh Edition. Edit. Elsevier. 2016.
3. Trope Martin; Barnet Frederic; Sigurdson Asgeir; Chivian Noah. The Role of Endodontics After Dental Traumatic Injuries. Page 774. Cohen's Pathways of the Pulp. Eleventh Edition. Edit. Elsevier.2016.
4. Arias Moliz MT; Camilleri J. The effect of the final irrigant on the antimicrobial activity of root canal sealers. Journal of Dentistry. 2016 Elsevier. Ltd.
5. Andreasen, JO DDS. Lesiones Traumáticas de los dientes. [traumatic injury in teeth] Chapter 1, Clasificación, etiología y epidemiología [classification, etiology and epidemiology] pgs. 12-15. Editorial Labor.S.A. Impreso en España 1980.
6. Sjogren U; Figdor D; Spanberg L; Sundqvist.G; The antimicrobial effect of calcium hidroxide as a short term intracanal dressing. Int.Endod.J.Vol 24. Pg. 119. 1991.

Download the complete series

Septodont Case Studies Collection

www.septodont.com





Vital pulp therapy on external cervical resorption using Biodentine™

Author: Martin Stalla

DACCS Conservative dentistry and endodontics (UCL, Brussels, Belgium).

Hospital specialist dentist at Saint-Luc University Clinics (Brussels, Belgium).

Associate clinician, D.R.I.M team (Brussels, Belgium).

Exclusive endodontist in a private clinic.

Abstract

During the process of an external cervical resorption (ECR), the underlying pulp tissue remains vital until advanced stages. The development of the resorption is initiated via a punctual external entrance through the dentin and develops centripetally in the three dimensions of space within the dentin. The pulp does not intervene in any way in the advancement of resorption, and even on the contrary, tends to limit its advance by maintaining a protective layer

on its periphery called Peri-radicular Resorption Resistant Sheet (PRRS). It is therefore important, when conditions allow it, to try to preserve the dental pulp when treating this kind of pathosis. In this context, the present article presents the case of a canine requiring a vital pulp therapy using Biodentine™ (Septodont) during the treatment of ECR, involving the elevation of a flap and composite placement.

Introduction

An external cervical resorption corresponds to a destruction of the mineralized dental tissue in the cervical region. This phenomenon is initiated via a punctual external entrance through the dentin (possibly made possible by a cemento-ligament discontinuity) and develops centripetally in the three dimensions of space within the dentin.

under the action of clastic cells. (*Patel, IEJ,2018*) If left untreated, the resorption area can gradually extend centripetally until it surrounds the root canal system. The pulp tissue is considered to be protected by a non-mineralized and non-uniform barrier (thickness ranging from 70 to 490 micrometers) called Periradicular

Resorption Resistant Sheet (PRRS). However, despite the maintenance of the integrity of the odontoblastic layer and the underlying pulp tissue in initial stages, cellular changes within the pulp seem to eventually take place, such as odontoblastic atrophy, dispersed pulp calcification, formation of pulp stones, etc. In advanced cases, pulpitis or eventually pulp necrosis can occur. (Mavridou, JOE, 2016)

The resorptive defect is quickly colonized by the cells of the surrounding tissues (bone, periodontal ligament, gum). In case of ECR, due to the coronal position of the defect, the tissue developing there originates from the gum and constitutes a fibro-vascular granulation tissue.

Thus, in some advanced cases, it is possible to see a cervical pink coloration due to this underlying highly vascularized infiltrating tissue. This rather rare clinical picture called "pink spot" is pathognomonic of ECRs and allows an easier diagnosis. (Bergmans, JCP, 2002)

In general, the diagnosis of ECR constitutes a challenge in terms of detection (clinical and radiographic) and therapeutic strategy to adopt. In fact, except in advanced cases, teeth with this kind of damage are asymptomatic and the pulp tissue is still alive. (Patel, IEJ, 2018)

Therefore, it is important not to sacrifice pulp vitality whenever possible and thus to prefer a more "pulp friendly" approach. This therapeutic option is dependent on various factors such as the position and extent of the defect, the ease of operation, the initial symptomatology.

Through this case report, a therapeutic proposal for maintaining pulp vitality has been illustrated.

Case report

A Caucasian woman of 26 years without medical history has been followed in our dental clinic for 4 years for a buccal external cervical resorption in tooth #23 with a visible pink spot (Fig. 1a).

The patient reported a history of orthodontic treatment 9 years ago, but no history of trauma. In the absence of symptoms (induced or spontaneous) and size change, clinical and radiographic follow-up was carried out annually.

Radiographically, apical retro-alveolar images taken with a sensor holder did not reveal any progression of the lesion, nor any enlargement of the periodontal space (Fig. 1b).

Clinically, the cold sensitivity pulp tests remained normal, i.e. transitory pain disappearing immediately after withdrawal of the stimulus. Periodontal health remained stable with good plaque control.

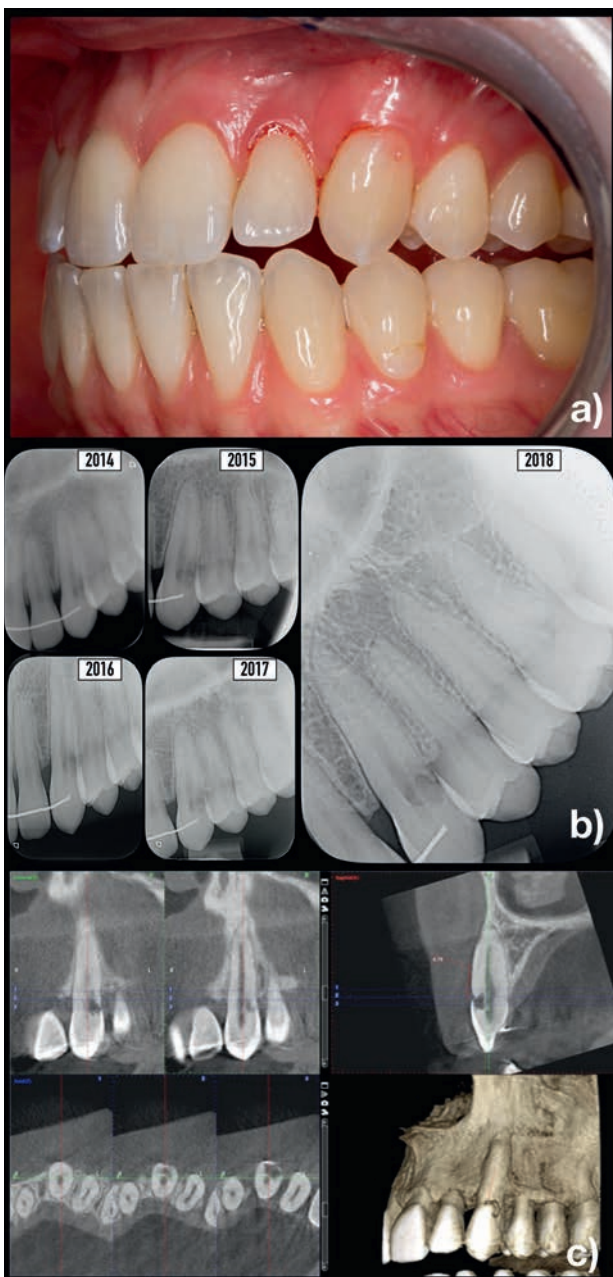


Fig. 1: Diagnosis a) initial situation b) radiographic monitoring c) CBCT pre-op.

However, an onset of cold-induced sensitivity led to a new appointment request in 2018. Clinically, the cold sensitivity test was positive, with exacerbated pain that stopped quickly after withdrawal of the stimulus. The diagnosis of reversible pulpitis was made and a CBCT was prescribed in order to plan the intervention. The resorption area located at the CEJ level was spreading circumferentially (with an angulation from 90° to 180°) and seemed to be confined to the dentine, classification 1Bd according to Patel, IEJ, 2018 (Fig. 1c).

On the day of the intervention, the patient had an antiseptic mouthwash (1 minute Corsodyl - CHX 0.2%). A tracing para-apical anesthesia was then performed (Scandonest-Septodont).

The surgical approach was then made via an intra-sulcular incision from tooth #21 to #25 and the flap was elevated (Fig. 2).

On Fig. 2a, (A) is the portal of entry of the resorption, which then spreads in all directions inside the tooth destroying cementum, dentin and enamel. An enamel fenestration (visible on Fig. 2a as (B) is the consequence of the dental tissue loss.

The resorption area was filled by a granulation tissue coming from the gum. This underlying highly vascularised inflammatory tissue gives the pink color of the pathognomic pink spot through the thinned enamel.

This residual layer of enamel was removed with a diamond bur under water, allowing a direct view of the underlying granulation tissue (Fig. 2b):

The whitish appearance of this tissue on Fig. 2b is due to local ischemia after local anesthesia with vasoconstrictors as well as to the section of vascular supply during the intrasulcular incision.

The tooth was isolated with a rubber dam, stabilised by an incisal clamp. This presented two advantages: 1) creating better conditions in terms of asepsis in case of a pulp exposure during the excavation (given the thinness of the PRRS layer (Fig. 3a) and 2) insuring better conditions for the bonding procedure (being in the aesthetic zone, a composite resin here was preferable).

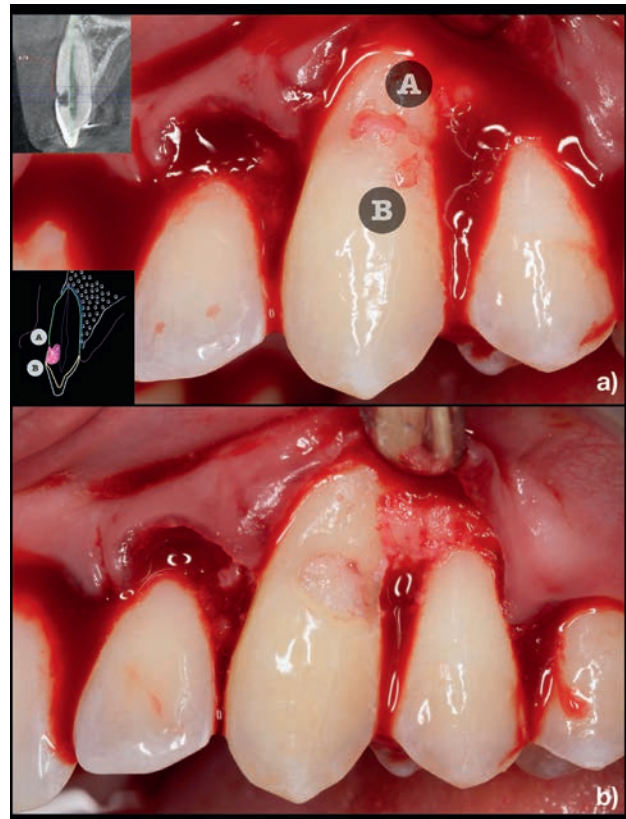


Fig. 2: Surgical access: a) flap raised b) view of the underlying granulation tissue

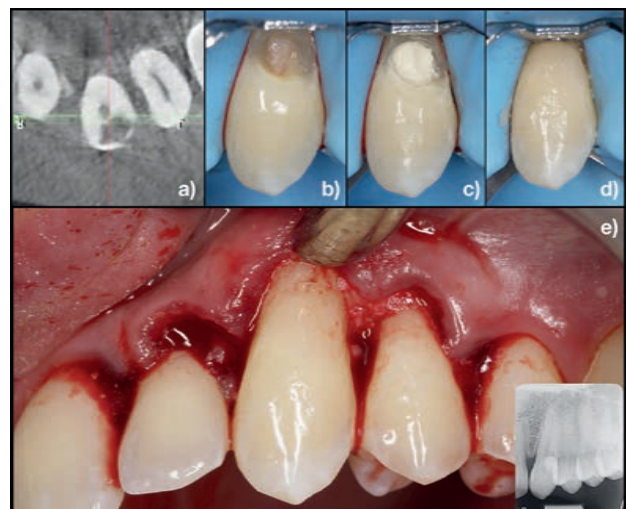


Fig. 3: Vital Pulp Therapy a) 3D extension of the resorption b) direct view of the PRRS c) indirect pulp capping using a liner of Biodentine™ d) Composite filling e) composite filling after polishing.

Granulation tissue (not adhering to the tooth) was removed by hand excavator. The excavation of resorption tissue was carried out under magnification (Zeiss microscope, Pico) using a tungsten carbide round bur under water until a sound dentin was obtained. At the end of the excavation, there was a close pulp proximity but the PRRS had been preserved (avoiding any iatrogenic exposure) (Fig. 3b).

A cervical enamel bevel was made to improve the aesthetic integration of the future composite and improve the bonding interface.

Given the symptomatology (reversible pulpitis) and close pulp proximity, indirect pulp capping was performed using Biodentine™ (*Fig. 3c*).

After complete setting of Biodentine™, a self-etch adhesion protocol (Clearfil SE Bond, Kuraray) was performed with selective enamel etching with phosphoric acid 40%, then an anterior composite (Clearfil Majesty, shade body A3, Kuraray) was applied and light-cured (*Fig. 3c*).

The rubber dam was removed and the composite was polished under water (*Fig. 3d*).

The flap was then sutured using 5.0 silk thread. Classical post-operative instructions were given to the patient. A check at 1 week was planned to remove the sutures. Controls at 1 month, 3 months, 6 months, and 1 year were planned to ensure monitoring of symptoms and to assess gingival healing (*Fig. 4*).

At the 1 year check-up appointment, the patient did not report any aesthetic complaint or any pain. The cold sensitivity test for tooth #23 was still positive and normal, the periodontal health was good and stable with optimal plaque control. The patient being in her first trimester of pregnancy at the 1-year control appointment, the apical radiography was postponed until after delivery.

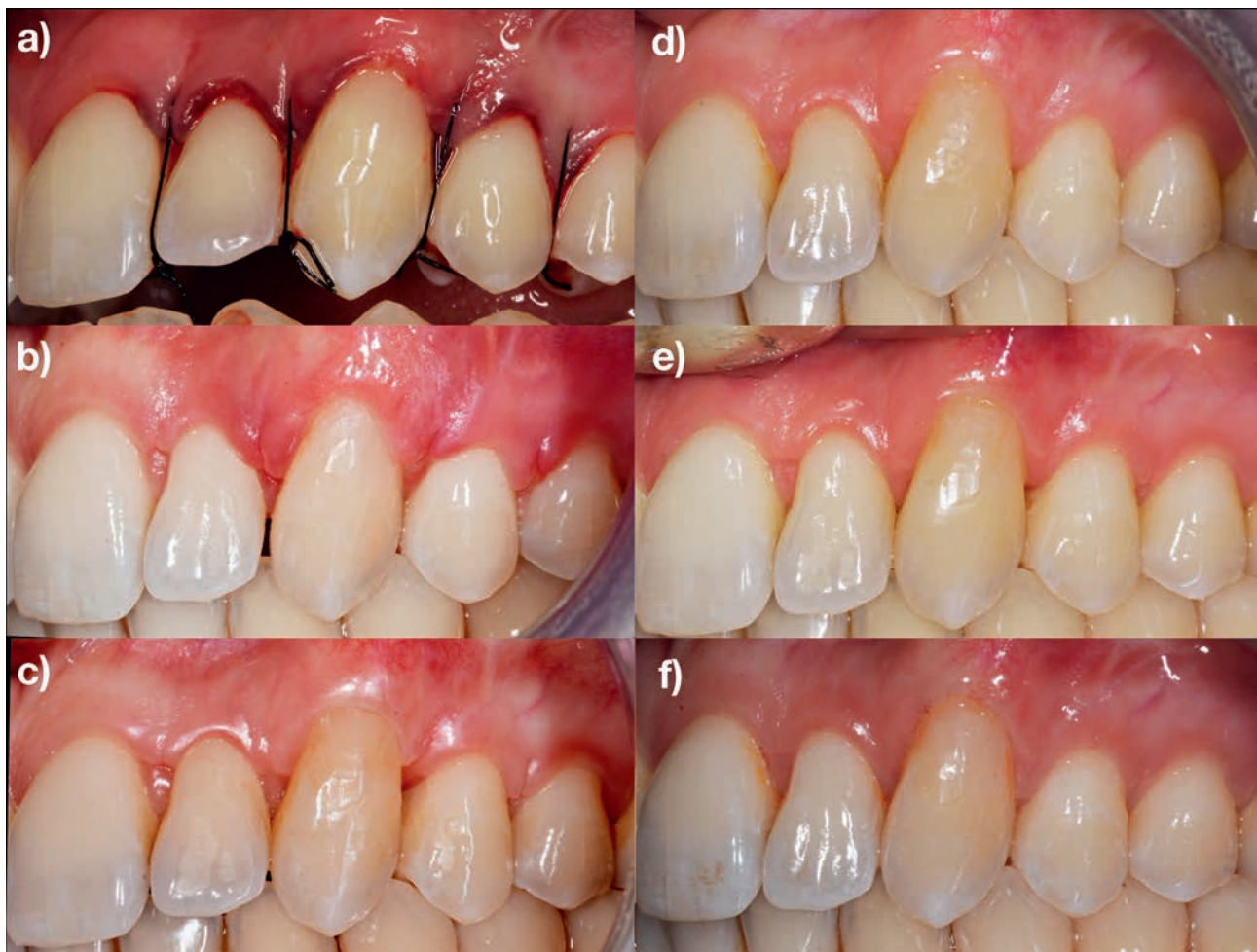

Fig. 4: Gum evolution a) On the day of the surgery, b) after 1 week, c) 1 month, d) 3 months, e) 6 months, f) 1 year

Discussion

The initiation of the resorptive process was described to be favoured when a cemento-enamel discontinuity was present, opening a gap with direct access to dentin. The exposed dentin then becomes more vulnerable to a resorptive attack mediated by circulating immune cells or cells from surrounding tissues (periodontal ligament, bone, or gingival cells). (*Mavridou, JOE, 2016*)

Simplifying the resorption mechanism to only a destructive action is overly simplistic. Indeed, different mechanisms come into play concomitantly at different levels on the same resorptive area. There is obviously a clastic activity mediated by odontoclasts, but active repair mechanisms are also taking place (notably secretion of osteoid tissue) as well as a reshaping of this tissue within this same defect. These resorption and repair mechanisms take place concomitantly in a dynamic equilibrium and therefore make ECRs a dynamic process in constant evolution. (*Mavridou, JOE, 2016*)

As a result, the annual monitoring carried out using retro-alveolar (hence 2D) images appears unsuitable given the three-dimensional evolution of the resorption area. Periapical radiographs have some limitation in detecting resorptions because of geometric distortion, anatomical noise, and their lack of information concerning the depth of the resorption. (*Patel, IEJ, 2018*). Moreover, in the present case, the different periapical radiographs of annual control did not have the same angulation despite the use of a X-raysensor holder. It means that comparing these images may not be sufficient to ensure a good surveillance of the disease evolution.

On the other hand, symptomatic surveillance in the absence of aesthetic complaints seems rational. Nevertheless, given the ease of surgical access to the defect, a more rapid intervention would probably have been indicated to intercept resorption at an earlier stage, thereby reducing the risk pulp involvement. The intervention at the stage of reversible pulpitis was without a doubt indicated here.

From a gingival point of view, excessive traction from the suture thread associated with incomplete plaque control led to initial scarring in the form of a « double papilla », which improved over time. The buccal position of the root, the fine gingival biotype associated with the cervical location of the composite, led in all likelihood to the recession observed at the one-year control appointment.

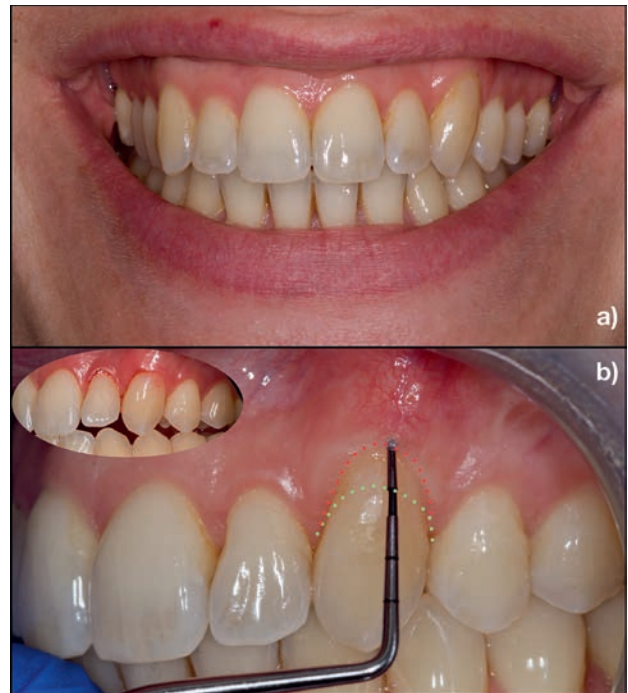

Fig. 5: Smile line at 1 year a) general smile b) gingival discovery with a view of the recession

his nevertheless did not bother the patient, who was satisfied with the end result (*Fig. 5*).

From the pulpal point of view, given the positive pre-operative sensitivity test, it was deemed essential in this case to try to preserve tooth vitality. According to clinical tests and the history of pain, the pulpal involvement seemed to be reversible. The correlation between clinical tests and the real histological state of the pulp was reported to be fairly high (*Ricucci, JOE, 2014*). The pulpal inflammation present in this case was not due to the resorption itself but rather to the spread of pathogen-associated molecular

patterns through the weakened axial dentine layer (*Reeves*). The pulp is then likely to return to normal conditions after the removal of the pro-inflammatory stimuli, provided that the cavity is sealed via the placement of a hermetic filling material. The question of the ideal material to choose was therefore raised taking into account various parameters, notably the pulp proximity and the management of the aesthetic aspect. There is currently no significant short-term difference between Biodentine™ and glass cement ionomer regarding the preservation of pulp vitality on a tooth with reversible pulpitis of carious origin (*Hashem, Clin Oral Investig, 2019*). Nevertheless, a Biodentine™ liner was applied here for its anti-bacterial properties, but mostly for its biocompatibility given the extremely close proximity. The idea was to induce the release of dentin growth factors, which could promote the secretion of tertiary dentin.

Working under rubber dam allowed to wait during the complete setting time without contamination of the working area. Finally, given the aesthetic component of the lesion, Biodentine™ was preferred to MTA to avoid ulterior dental staining.

A composite was preferred here given the aesthetic needs and the good isolation conditions, allowing optimal bonding placement.

Given the close pulp proximity and the large dentin adhesion required in a cervical defect, a self-etch bonding protocol with selective enamel etching was chosen. This was reported to be more predictable than a total-etch one (*B. Van Meerbeek, Journal of dentistry 1998*). Again, the objective here was to reduce any possible additional cause of iatrogenic pulpal inflammation.

Finally, regular follow-up appointments made it possible to ensure the long-term success of the procedure in terms of both symptoms and gingival healing. There is currently no consensus on the ideal intervals between control appointments. However, given the risk of recurrence of the resorptive process (if both resorptive tissue and inflammation remain) it is important to monitor these cases regularly and over the long term. (*Patel. 2018*)

Conclusion

External cervical resorptions are difficult both to understand and to manage. Indeed, their position makes their detection and differential diagnosis difficult. The affected teeth most often remain vital and asymptomatic, which explains their often fortuitous discovery. Pulp vitality is not involved in the mechanism of

propagation of resorption, so, when conditions allow, it is best to keep the tooth vital. Indirect Biodentine™ pulp capping performed during the management of an ECR seems to be an efficient therapeutic solution providing both short and long term pulp survival.



Author:
Dr Martin Stalla

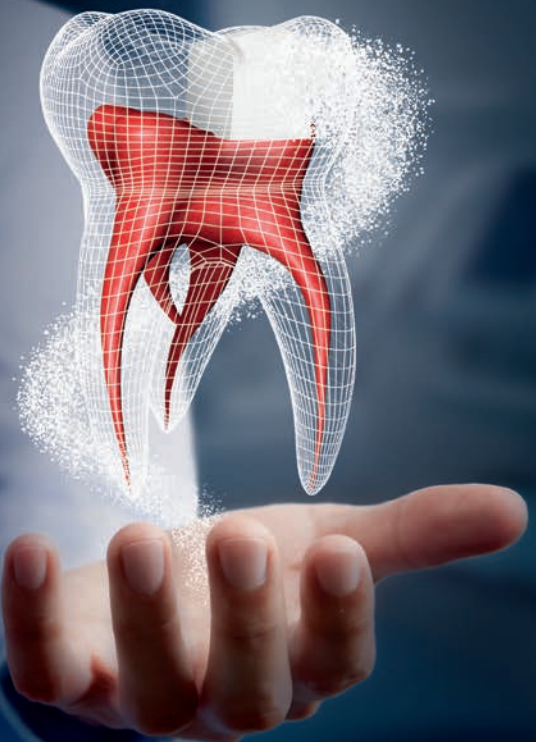
Dr Stalla completed his license and master of dentistry at the Catholic University of Louvain. After his graduation in 2016, he completed his certificate in endodontics and conservative dentistry during 3 years (full-time) at the department of Professor Julian Leprince at Saint-Luc University Hospital, Brussels. Dr Stalla is now a part-time hospital dentist specialist, and an exclusive endodontist the rest of the time.

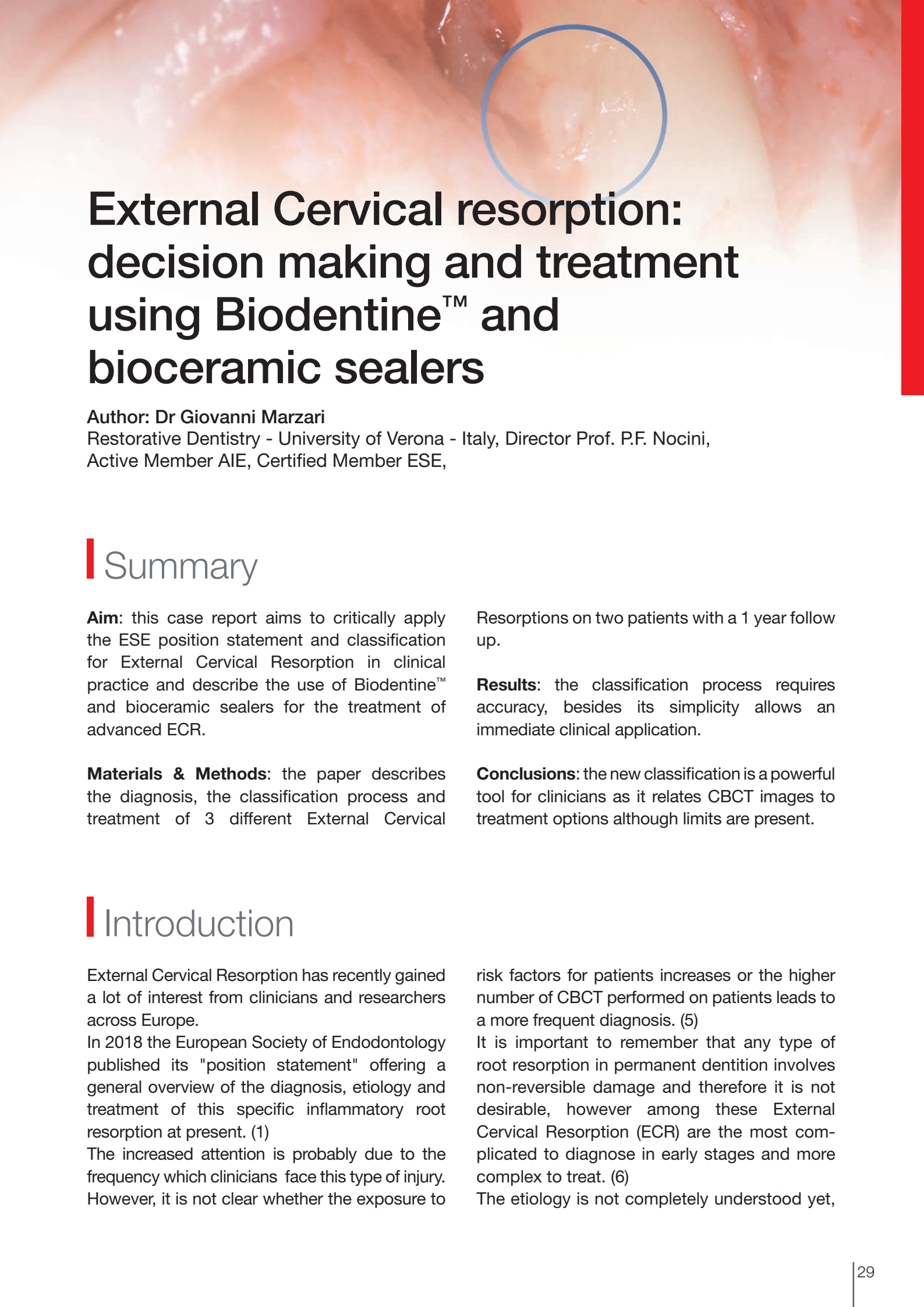
References

- External cervical resorption-part 1: histopathology, distribution and presentation, Patel, IEJ 2018.
- External cervical resorption-part 2: Management, Patel, IEJ 2018.
- Understanding External Cervical Resorption in Vital Teeth, A. M. Mavridou, JOE 2016.
- Mineral trioxide aggregate and other bioactive endodontic cements: an updated overview part I: vital pulp therapy, Parirokh, IEJ, 2018.
- Tissue responses in the rat to trichloroacetic acid: an agent used in the treatment of invasive cervical resorption. Australian Dental Journal 33, 451–61. Heithersay GS, Wilson DF (1988).
- Bergmans.L, Van Cleynenbreugel J, Verbeken E, Wevers M, Van Meerbeek B, Lambrechts P (2002) Cervical external root resorption in vital teeth, X-ray microfocus-tomographical and histopathological case study. Journal of Clinical Periodontology 29, 580–5. 2002.
- Correlation between Clinical and Histologic Pulp Diagnoses, Ricucci, JOE, 2014.
- The relationship of bacterial penetration and pulpal pathosis in carious teeth, Reeves.
- Evaluation of the Efficacy of Calcium Silicate vs. Glass Ionomer Cement Indirect Pulp Capping and Restoration Assessment Criteria: A Randomised Controlled Clinical trial-2-year Results, Hashem, Clin Oral Investig, 2019.
- The clinical performance of adhesive, B. Van Meerbeek, Journal of dentistry 1998.
- European Society of Endodontology position statement: External Cervical Resorption, S. Patel, IEJ, 2018.

Biodentine™

“First ever
Biological
Bulk Fill”





External Cervical resorption: decision making and treatment using Biodentine™ and bioceramic sealers

Author: Dr Giovanni Marzari

Restorative Dentistry - University of Verona - Italy, Director Prof. P.F. Nocini,
Active Member AIE, Certified Member ESE,

Summary

Aim: this case report aims to critically apply the ESE position statement and classification for External Cervical Resorption in clinical practice and describe the use of Biodentine™ and bioceramic sealers for the treatment of advanced ECR.

Materials & Methods: the paper describes the diagnosis, the classification process and treatment of 3 different External Cervical

Resorptions on two patients with a 1 year follow up.

Results: the classification process requires accuracy, besides its simplicity allows an immediate clinical application.

Conclusions: the new classification is a powerful tool for clinicians as it relates CBCT images to treatment options although limits are present.

Introduction

External Cervical Resorption has recently gained a lot of interest from clinicians and researchers across Europe.

In 2018 the European Society of Endodontology published its "position statement" offering a general overview of the diagnosis, etiology and treatment of this specific inflammatory root resorption at present. (1)

The increased attention is probably due to the frequency which clinicians face this type of injury. However, it is not clear whether the exposure to

risk factors for patients increases or the higher number of CBCT performed on patients leads to a more frequent diagnosis. (5)

It is important to remember that any type of root resorption in permanent dentition involves non-reversible damage and therefore it is not desirable, however among these External Cervical Resorption (ECR) are the most complicated to diagnose in early stages and more complex to treat. (6)

The etiology is not completely understood yet,

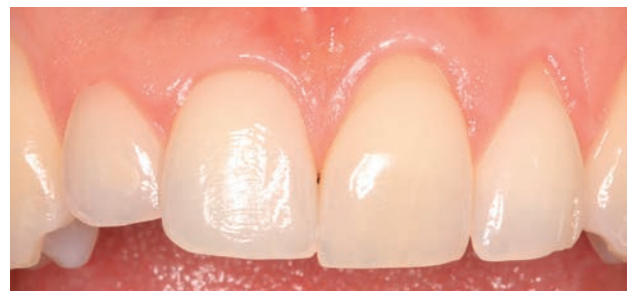An accredited hypothesis suggests that the inflammatory process arises from a damage to the periodontal ligament associated with factors that maintain clastic activity. (1) ECRs are dynamic lesions that evolve from destructive phases to repair phases with variable times and degrees of invasiveness. Heathersay et al. in 1999 introduced a 4-stage classification, correlating each stage to the

success rate in the treatment. More recently Patel et al. suggested a new classification based on three-dimensional radiological diagnosis, correlating the different stages to the therapeutic options that can be followed. The purpose of this case report is to highlight how the use of the ESE guidelines can be introduced into clinical practice by the use of Biodentine™.

Clinical case #1

A 39-year-old female patient with a negative medical history (8), came in for a visit referred by a colleague who during the periodical clinical inspection identified a small reddish buccal lesion on tooth 12. (figs. 1 and 2) On the same day a periapical X-ray was detected. Dental history reports a trauma involving second sextant that occurred about 15 years earlier. (5, 12).

The clinical examination confirms a small lesion of the buccal enamel of 12, the pulp sensitivity tests were physiological and no mobility associated. The periapical radiographic examination (fig. 3) shows an extensive radicular radiolucency that does not involve the root canal. (5) At cervical level, the co-presence of the 2 main phases of the RCI is noted: distally the clastic phase, while mesially the replacement phase.



The diagnosis for element 12 is Grade 4 iexternal cervical resorption according to Heithersay. (5) The clinical and radiographic examination is extended to the whole second sextant: element 11 is also affected by an ECR with clinical characteristics similar to the previous one, however classified as Heithersay grade 3. (5) Three-dimensional analysis of the lesion is a key factor in planning the therapeutic approach and establishing an initial prognosis of the element, as well as allowing identification of early stage lesions (1, 3, 5, 6), as it is the extension of the area involved in the reabsorption and its position to influence the success of the treatment.

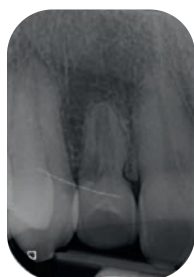

Fig. 1

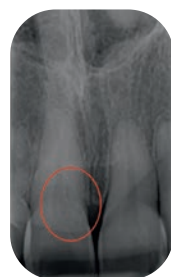

Fig. 2

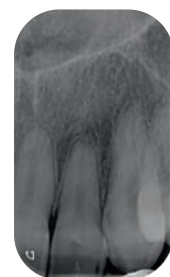
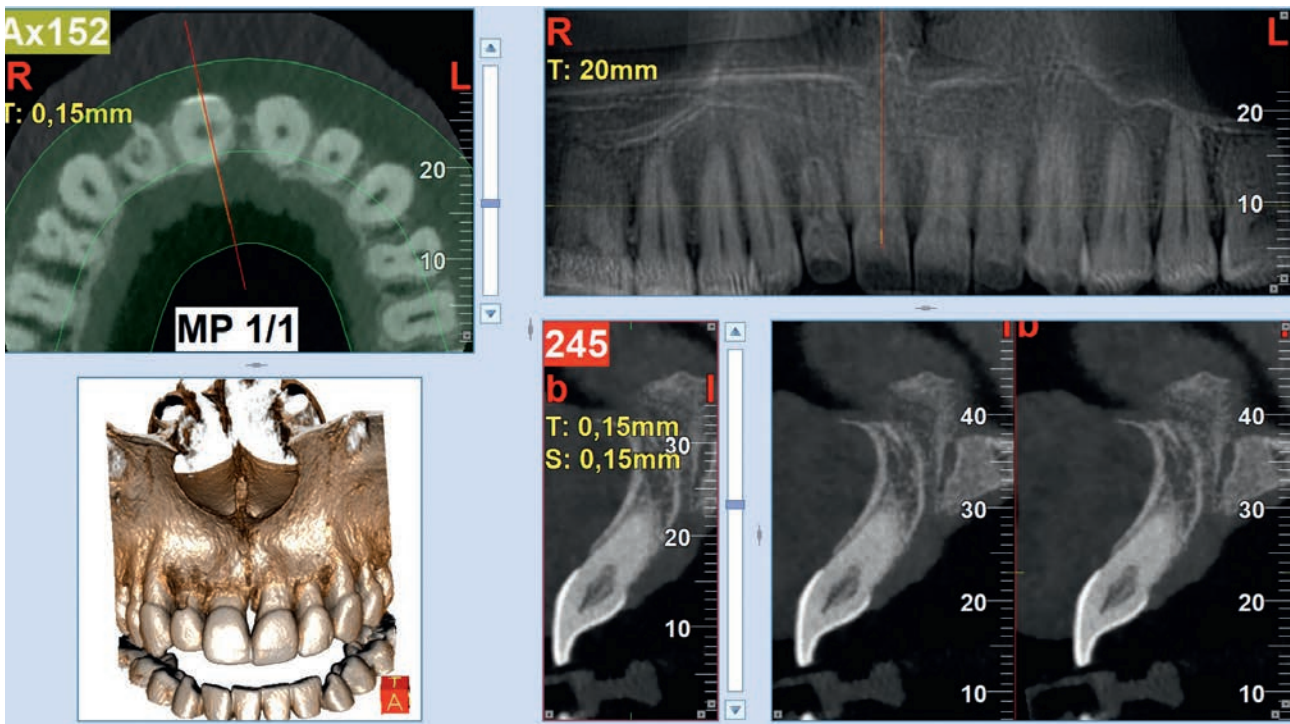


Fig. 3

Hight	Circumferential Involvement	Proximity to root canal
Gr1at CEJ level (supracrestal)	A: $\leq 90^\circ$	d: limited to dentin
Gr2 extending to coronal third of the root (subcrestal)	B: between 90° e 180°	p: probable endodontic involvement
Gr3 extending to middle third of the root	C: between tra 180° e 270°	
Gr4 extending to apical third of the root	D: $>270^\circ$	



A high resolution CBCT with 5x3 FOV of the second sextant is then prescribed.

Patel and colleagues based on the analysis of three-dimensional radiographic images proposed a scheme to represent the extent of the lesions in three dimensions (tab. 1) (1).

The same authors propose to associate different therapeutic options to each type of classified lesion as follows:

1. Surgical access and repair of the lesion associated with/without endodontic treatment.

The excavation of the defect after surgical access and direct restoration is indicated on small coronal lesions or for classes 1Ad, 2Ad, 2Bd.

The same treatment, but associated with endodontic treatment is indicated for the same previous classes, but with subgroup "p" (proximity to the endodontic space) or 1Ap, 2Ap, 2Bp.

2. Internal repair associated with endodontic treatment.

Endodontic treatment associated with careful cleaning of the inflammatory tissue through endodontic access is indicated for coronal land medium lesions with extension plus 2Cp, 2Dp, 3Cp, 3Dp.

3. Intentional Replantation

The extraction of the previously endodontically treated tooth, cleaning of the lesion associated with root plastic or restoration of the defect is indicated for deep but limited lesions such as extension 3Ad, 3Bd.

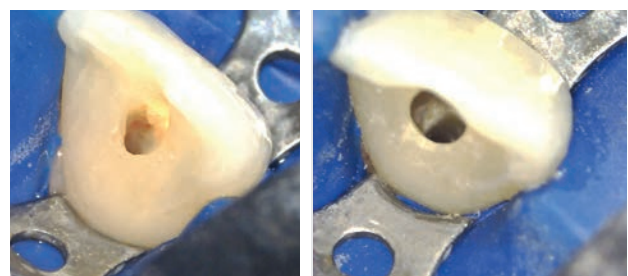4. Periodic Follow up

It is indicated for inaccessible or very large lesions 2-4Dd, 2-4Dp.

5. Extraction

Finds its indication if the tooth cannot be restored with functional and aesthetic success.

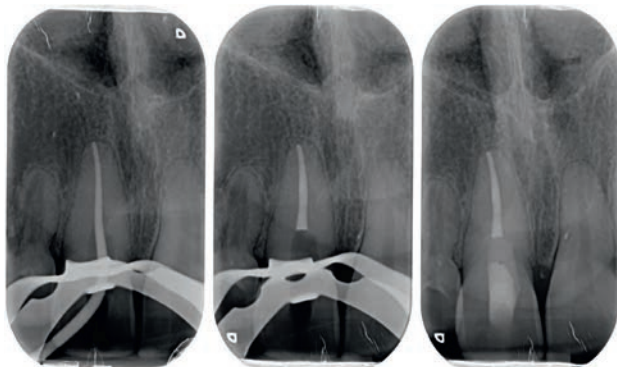
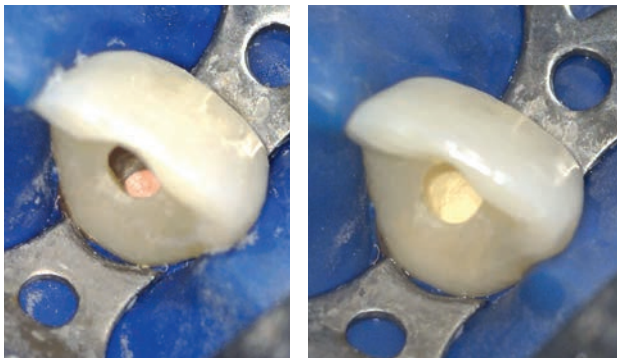
In the described case, therefore, tooth 12 is classified 4Dp. In detail: the apical third (Gr4) is affected by resorption, the extension is circumferential (D) and the root canal appears in close proximity to the lesion (p).



The tooth does not require restoration to maintain relational function and aesthetics. An annual radiographic and clinical follow-up was therefore

proposed without further treatment, informing the patient of the poor prognosis of the element. Tooth 11, on the other hand, is involved within the coronal third even if sub-crestal (Gr2) with an extension of 90 ° (A) and an important proximity to the root canal, therefore it has been classified 2Ap.

The approach suggested by Patel et al. for 2Ap cases is the excavation and repair of the inflammatory tissue with a surgical approach following the endodontic treatment of the tooth. In our opinion, it is also important to consider the outcome of the surgical approach which can be different according to the accessibility



of the defect. If the lesion is buccal or palatine (possible gingival recession) rather than interproximal (predicted hard and soft tissue loss involving adjacent teeth). And further the position of the tooth in the arch where, as in our case, the aesthetic result becomes a factor of primary importance.

Then, an internal repair approach associated with endodontic treatment was chosen for element 11 (2Ap).

The treatment plan provided the isolation of the operating field, the creation of endodontic access and the complete removal of the inflammatory tissue with micro excavators and ultrasound tips. After completing the debridement of the infiltrated dentine, the endodontic system was cleaned, shaped and filled to the apical limit of the resorption. The remaining defect was then repaired with Biodentine™ (Septodont, France) in the same session. Given the hardening of the biomaterial (9, 10), the access cavity was sealed with bonded composite material.

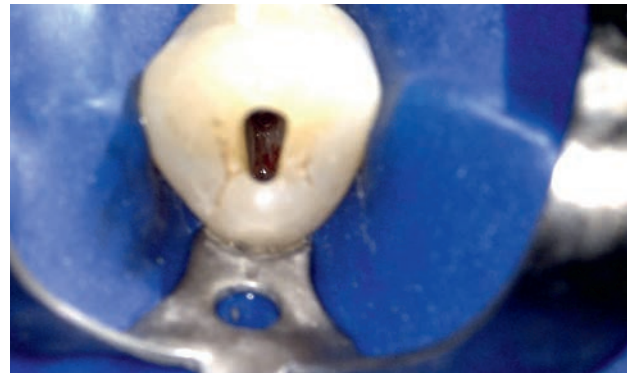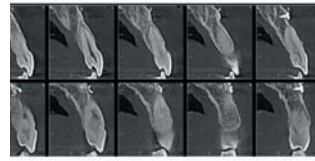
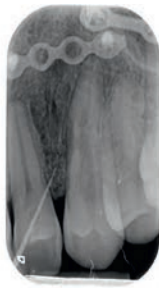
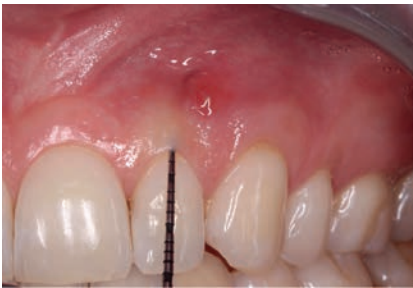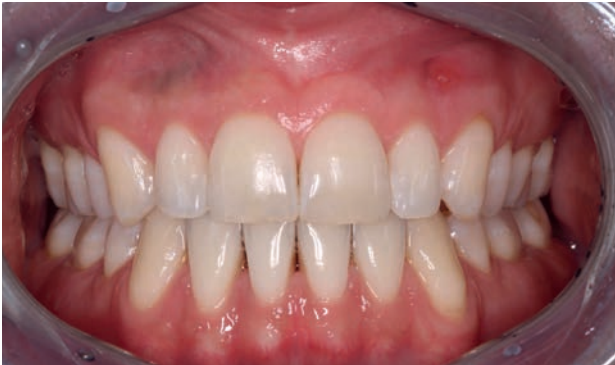The clinical and radiographic follow up at two years is reported.

Tooth 12 is asymptomatic, physiological periodontal probing, physiological mobility and positive for pulp sensitivity tests.

Tooth 11 is asymptomatic, physiological periodontal probing, physiological mobility and absence of discoloration.

The radiographic examination shows no evolution of the RCI at 12 and the presence of hard lamina on the whole root contour of 11.

Clinical case #2



A 30 years old male, was referred to our office due to a sinus track present buccally between tooth 22 and 23. During the anamnestic interview no recent dental treatment or systemic disease were reported. Relating to dental history, although, the patient signals a previous orthodontic treatment and orthognathic surgery performed 6 years earlier. No symptoms were complained.

A clinical examination was performed: physiological periodontal probing was found in all quadrants, buccal palpation was negative, pulpal sensitivity tests (EPT and cold) were physiological, 23 was tender to percussion.

The periapical X-ray with fistulography reveals a radiolucency along the root of 23 extending from

the coronal to the middle third of the root canal, on the other hand sinus track drained from the interproximal bone peak between 22 and 23 giving no further information.

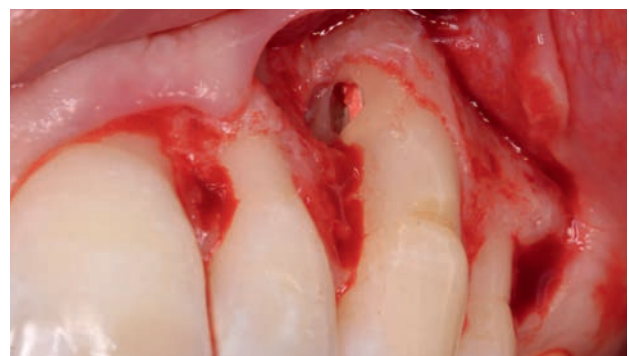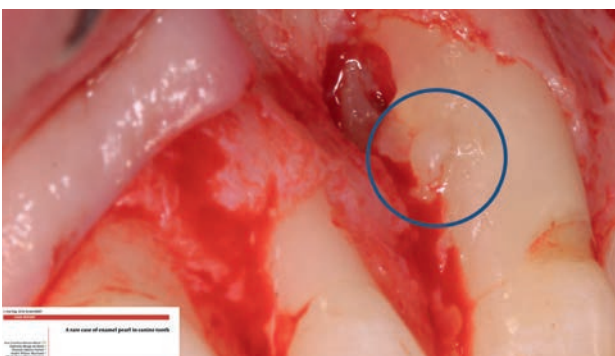
The history of orthodontic treatment and tooth position suggested a ECR.

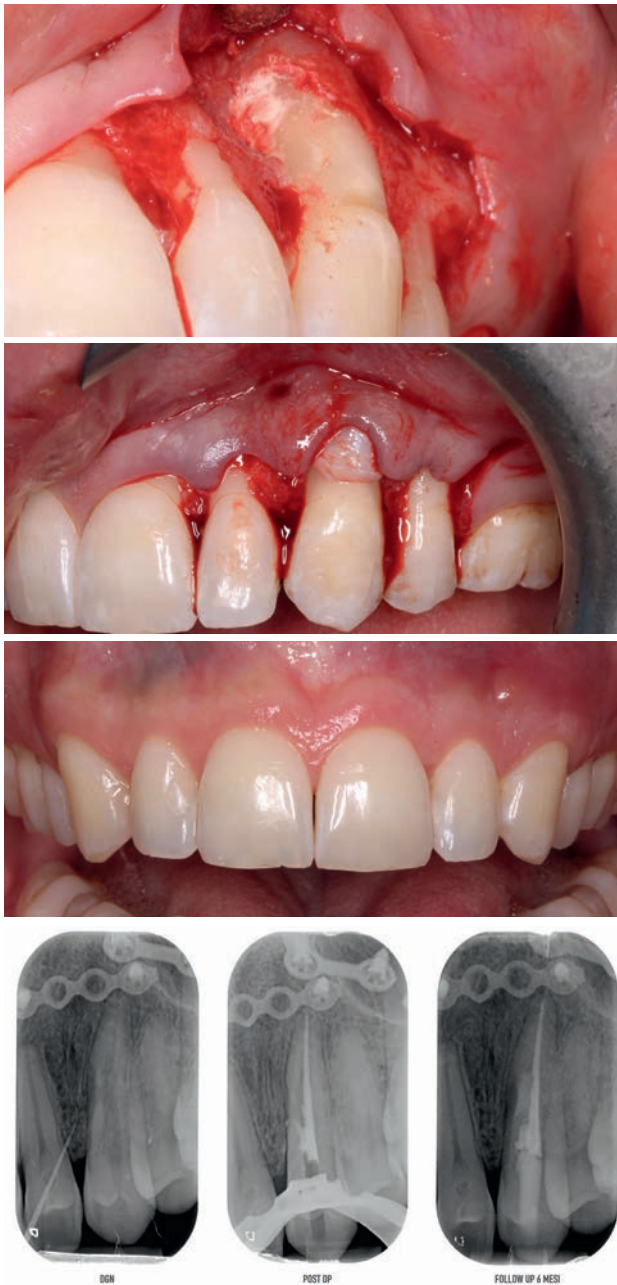A CBCT was taken in order to confirm diagnosis and classify the lesion accordingly.

A Gr3-B-p External Cervical Resorption was identified.

Unclear origin of the sinus track was adduct to a superinfection of the inflammation tissue as described by previous case reports.

Due to patient's highly esthetic concerns, intentional replantation was declined. The patient approved an orthograde and surgical approach. The final treatment plan included the endodontic





treatment of 23 as the lesion involved the root canal space, followed by the elevation of a full thickness flap allowing the surgical debridement and repair of the resorption.

During the endodontic treatment several ports of entrance of the resorption tissue were identified coronally, while no debridement could be performed to the lesion in the middle third.

A bioceramic sealer with a cold single cone technique was used to seal the endodontic space as a completely dry the root canal could not be achieved. A bonded composite was immediately applied to seal the access cavity.

After seven days surgery was performed.

The flap elevation revealed an enamel pearl, probable portal of entry of bacteria causing the sinus track.

After removing the enamel pearl a complete debridement of the resorption tissue was performed and the cavity was repaired with Biodentine™. While waiting the material to set, rubber dam was mounted and a class V composite restoration was performed in order to allow a connective tissue graft to be placed attached to the flap.

A six weeks follow up exhibits a proper healing of the surgical wound and the closure of the sinus track.

At one year the follow up X-ray shows a normal PDL surrounding the root of tooth 23 and no further expansion of radiolucency associated with the resorption.

Discussion

The use Patel's classification requires accuracy in the procedure, however the conceptual simplicity makes it usable in daily clinical practice.

Unlike the previous classifications that correlated the extent of resorption to the prognosis of the element, the new classification used by the European Society of Endodontology relates radiographic images and practicable therapeutic options, a choice of great utility, allowing the clinician to immediately discuss with the patient. The pre-visualization of the position and extent

of the root defect through CBCT offers the clinician an important help, both for therapeutic planning and for a precise informed consent by the patient.

One limit to this classification may be the lack to consider the position of the dental element in the arch and the position of the defect relative to the root surface. Both of these aspects may influence the surgical approach to the root defect and its outcome.

Conclusions

The classification proposed in the ESE "position statement" offers to clinicians a clear and applicable tool in clinical practice.

However, the therapeutic choice should also

consider: operator's skill and experience, the patient's expectations and possible complications.



Author:

Dr Giovanni Marzari

Graduated from the University of Verona. He attended numerous Post Graduate courses specialized in Endodontics: Advanced Endodontics Santa Barbara California, Dr. Cliff J. Ruddle (USA), Fellowship at the University of Boston, Goldman Dental School Dr. Mani Mulahzade (USA), and in Clinical Periodontology, under the coordination of Dr. Luca Landi, Fixed Prosthetics, under the guidance of Dr. Dario Castellani. In 2013 earned his Master's Degree in Clinical and Surgical Microendodontics from the University of Turin, under the guidance of Dr. Elio Berutti. He is conducting his clinical activity focusing on endodontics and periodontology. He gave many national and international lectures. He is an active member of the AIE member (Accademia Italiana di Endodonzia) being part of the board of directors for 2019-2020 and certified ESE member (European Society of Endodontology). He published articles in specialized magazines and he is also the co-author of some important books in the field. Since 2015 he actively teaching as a Clinical Instructor at the Master in Clinical and Surgical Microendodontics from the University of Turin directed by prof. Elio Berutti e prof. Damiano Pasqualini. Since 2017 he is a part time Teacher at University of Verona lecturing on Restorative Dentistry.

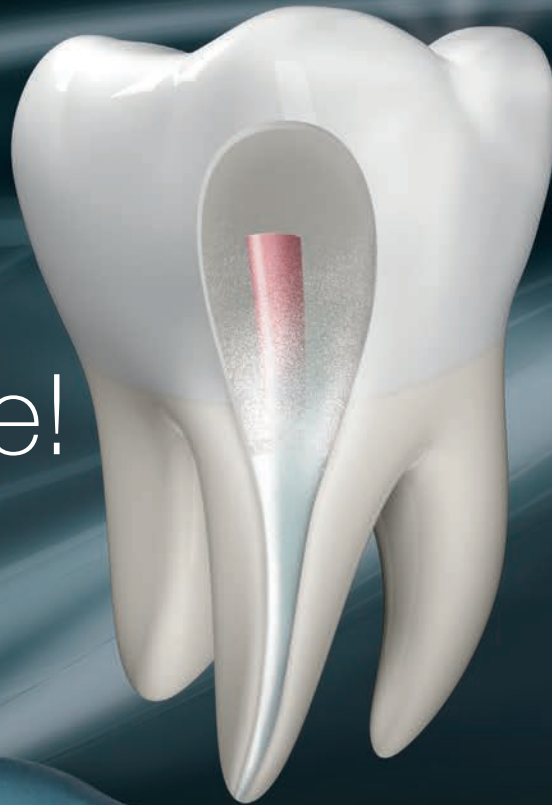
References

1. Int Endod J. 2018 Dec;51(12):1323-1326. doi: 10.1111/iej.13008. E pub 2018 Sep 26. European Society of Endodontology position statement: External Cervical Resorption. European Society of Endodontology (ESE) developed by: Patel S1,2, Lambrechts P3, Shemesh H4, Mavridou A3.
2. Int Endod J. 2018 Nov;51(11):1205-1223. doi: 10.1111/iej.12942. Epub 2018 Jun 1. External cervical resorption-part 1: histopathology, distribution and presentation. Patel S1,2, Mavridou AM3, Lambrechts P3, Saberi N1.
3. Int Endod J. 2018 Nov;51(11):1224-1238. doi: 10.1111/iej.12946. Epub 2018 Jun 9. External cervical resorption: part 2 - management. Patel S1,2, Foschi F1, Condon R1, Pimentel T1, Bhuvu B1.ù
4. Int Endod J. 2018 Feb;51(2):206-214. doi: 10.1111/iej.12824. Epub 2017 Sep 13. External cervical resorption: a three-dimensional classification. Patel S1, Foschi F1, Mannocci F1, Patel K1.
5. Aust Endod J. 1999 Aug;25(2):79-85. Invasive cervical resorption following trauma. Heithersay GS.
6. J Endod. 2017 Jan;43(1):121-125. doi: 10.1016/j.joen.2016.09.008. Epub 2016 Dec 6. External Cervical Resorption: A Comparison of the Diagnostic Efficacy Using 2 Different Cone-beam Computed Tomographic Units and Periapical Radiographs. Vaz de Souza D1, Schirru E1, Mannocci F1, Foschi F1, Patel S2.
7. J Endod. 2018 Feb;44(2):239-244. doi: 10.1016/j.joen.2017.10.001. Epub 2017 Dec 8. Impact of Cone-beam Computed Tomography on Treatment Planning for External Cervical Resorp-tion and a Novel Axial Slice-based Classification System. Goodell KB1, Mines P2, Kersten DD2.
8. J Endod. 2017 Oct;43(10):1740-1743. doi: 10.1016/j.joen.2017.03.040. Epub 2017 Jun 9. External Cervical Resorption: A New Oral Manifestation of Systemic Sclerosis.
9. J Endod. 2015 Nov;41(11):1907-12. doi: 10.1016/j.joen.2015.08.003. Epub 2015 Sep 26. Conservative Nonsurgical Treatment of Class 4 Invasive Cervical Resorption: A Case Series. Salzano S1, Tirone F2.
10. Iran Endod J. 2017 Summer;12(3):386-389. doi: 10.22037/iej.v12i3.16668. Management of Invasive Cervical Root Resorption in a Mandibular Canine Using Biodentine™ as a Restorative Material: A Case Report. Eftekhari L1, Ashraf H2, Jabbari S2.
11. J Oral Sci. 2011 Sep;53(3):397-401. Management of an extensive invasive root resorptive lesion with mineral trioxide aggregate: a case report. Danesh F1, Karamifar K, Abbott PV.
12. Aust Dent J. 2016 Mar;61 Suppl 1:82-94. doi: 10.1111/adj.12400. Prevention and management of external inflammatory resorption following trauma to teeth. Abbott PV1.
13. J Endod. 2017 Nov;43(11):1901-1908. doi: 10.1016/j.joen.2017.04.026. Epub 2017 Jul 19. Minimally Invasive Treatment of Class 4 Invasive Cervical Resorption with Internal Approach: A Case Series. Shemesh A1, Ben Itzhak J2, Solomonov M2. Arroyo-Bote S1, Bucchi C2, Manzanares MC3.
14. Oral Surg Oral Med Oral Pathol Oral Radiol Endod. 2011 Nov;112(5):e18-22. doi: 10.1016/j.tripleo.2011.04.028. Epub 2011 Aug 6. Surgical endodontic management of an invasive cervical resorption class 4 with mineral trioxide aggregate: a 6-year follow-up. Fernández R1, Rincón JG.
15. Oral Surg Oral Med Oral Pathol Oral Radiol Endod. 2000 Feb;89(2):255-8. Radiographic evidence of enamel pearls in Jordanian dental patients. Darwazeh A, Hamasha AA.

BioRoot™ RCS

No More
Compromise!

- Long term success
- Easy & fast technique



Endodontics

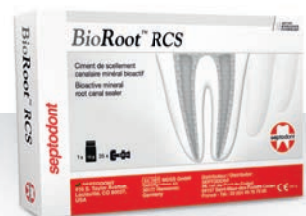For your endodontic obturations, BioRoot™ RCS offers you both an easy & fast technique along with long term clinical success. With BioRoot™ RCS, the clinical and procedural requirements that you face are fully met:

- Lateral & Apical long term seal
- Limit bacterial growth
- Easy and time effective to implement
- Cost effective

With BioRoot™ RCS, increase the standard of your endodontic obturation while optimizing your patients' chair time.

BioRoot™ RCS Succeed.

Please visit our website for more information
www.septodont.com



/// ACTIVE
BIOSILICATE
TECHNOLOGY





The Dental Pharmaceutical Company

INNOVATIVE, SAFE AND EFFECTIVE SOLUTIONS FOR DENTISTRY WORLDWIDE