

Adolescent Patient with Bilateral Crossbite Treated with Surgically Assisted Rapid Maxillary Expansion: A Case Report Evaluated by the 3D Laser Scanner, and Using FESA Method

Ivanov I. Ch.¹, Velemínská J.², Dostálová T.¹, Foltán R.³

¹Department of Paediatrics Stomatology, Second Faculty of Medicine, Charles University in Prague and University Hospital Motol, Prague, Czech Republic;

²Department of Anthropology and Human Genetics, Faculty of Science, Charles University in Prague, Prague, Czech Republic;

³Department of Stomatology, First Faculty of Medicine, Charles University in Prague and General University Hospital in Prague, Prague, Czech Republic

Received May 11, 2011; Accepted September 26, 2011.

Key words: Bilateral crossbite – Maxillary expansion – Laser scanning – Morphometric methods

Abstract: Our purpose in this case report is to present an orthodontic treatment obtained and the results achieved in 17-year-old white female patient with Angle Class II malocclusion and bilateral posterior crossbite. Patient was treated with bonded acrylic Hyrax appliance and surgically assisted rapid maxillary expansion (SARME). The multiloop system 0.16 TMA (β titanium) arch wire was used in the alignment phase and on purpose to prohibit bite opening and optimize three-dimensional movement control. After treatment bonded lingual retainers were placed in between maxillary central incisors and in mandible canine-to-canine. A functional removable Klammt appliance was used for retention. The 3D Laser Scanner Roland LPX-250 was used in order to obtain digital dental casts. Evaluation of the treatment results was measured on these models and using finite element scaling analysis (FESA). An Angle Class I relationship was obtained after

This study was supported by research project No. MSM 0021620843 of the Ministry of Education, Youth and Sports, and project IGA MZ CR, No. NS/10560-3.

Mailing Address: Ilija Christo Ivanov, MD., Department of Paediatrics Stomatology, Second Faculty of Medicine, Charles University in Prague and University Hospital Motol, V úvalu 84, 150 06 Prague 5, Czech Republic; Phone/Fax: +420 224 433 100; e-mail: ivanov@orthoprague.cz

2½ years of treatment, function and facial aesthetics were improved. The shape of the palate changed significant in the width direction, not significantly in length and high direction. The greatest expansion of palate was found in the region between the palatal cusps of the first molars 26.6%, followed by first 21.9% and second premolars 16.5%. SARME in adult patients with bilateral cross bite and maxillary deficiency lead to satisfactory results. The 3D laser scanned models and their measurements, using advanced software's are successfully used for precise studies.

Introduction

Rapid maxillary expansion (RME) is an effective method in correcting maxillary transverse deficiency, thereby correcting posterior crossbite by increasing intermolar width. In contemporary orthodontics RME have been routinely used for management of transverse arch deficiencies.

The first attempt at surgically assisted maxillary expansion (SARME) was by E. H. Angle in San Francisco in 1860. This process was well documented in the orthodontic literature and has some supporters – in the USA: Farrar 1888, Godbard 1893, Black 1893, Monson 1898, Landsberger 1910; in Europe: Babcock 1911, Huet 1926, Derichsweiler 1953, Korkhaus 1953 – and adversaries like Case 1893, Ketchham 1912, Dewey 1913. Surgical approaches, from a subtotal Le Fort I to more limited osteotomies (Alpern and Yurosko, 1987) of the lateral maxilla and palate, when combined with fixed palatal expanders, have been successful in allowing the palatine suture to split and the maxilla to widen. In adolescent and adult patients expansion protocols have been advocated for a variety of purposes as: crossbite correction, avoiding problems of pain, swelling and ulceration, and for reducing tooth rotations and root resorptions (Mossaz et al., 1992; Pogrel et al., 1992).

Different types of palatal expanders can be used – Haas 1961, Isaacson and Murphy 1964, Biederman 1968. In 1982 Howe introduced a bonded maxillary expander, which was modified by McNamara at Michigan University (USA). The fixed expander can be activated for either rapid (0.5 mm or more per day), semi-rapid (0.25 mm/day), or slow (1 mm/week) expansion. In SARME it is recommended to open the screw about 1 mm per day.

The evaluation techniques studying effects of RME ranging from manual measurement of dental casts, lateral and posteroanterior cephalographs, more sophisticated digital probes and digital imaging system, to a three-dimensional helical computed tomography (Taufarová, 2006; Phatouros and Goonewardene, 2008).

The purpose of using a 3D method to evaluate morphologic changes after SARME in our case report is to show one of the contemporary sophisticated techniques, which can be widely used for precise measurements in the future.

History and aetiology

A 17-year-old girl presented for orthodontic treatment. Her chief concern was that she did not like her crowded teeth in the frontal region and aesthetic dental and facial appearance, when smiling. Medical history included allergy to dust and pollen for which she irregularly used Zodac (Zentiva, k.s., Prague, Czech Republic). The allergy was also the reason for frequent breathing through the mouth, which appear to cause a narrowing of the upper jaw. She had an orthodontic treatment with removable appliances for about a year at the age of ten. The patient reported that her younger sister wore a removable orthodontic appliance. Her mother had a bimaxillary crowding, too.

Diagnosis

The patient appeared facially symmetrical with normal lip competence. When smiling, she showed tooth crowding and unaesthetic buccal corridors. She had a long lower facial height and straight profile. TMJ functions were normal. Masticatory muscles appeared slightly hypotonic.

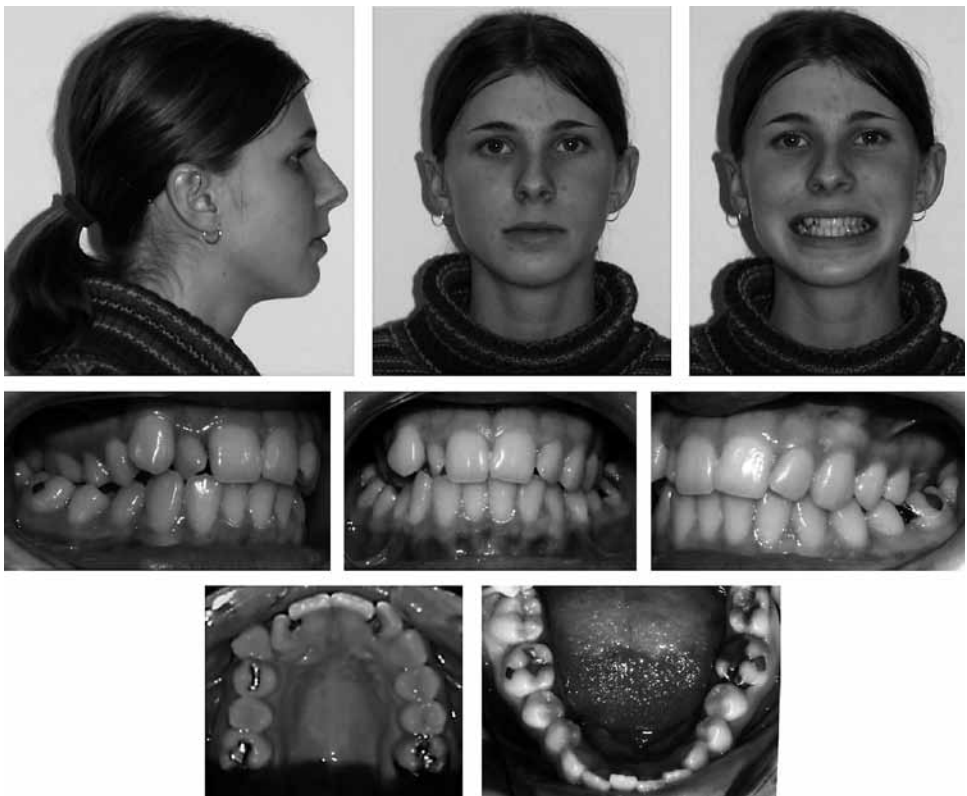

Figure 1 – Pretreatment: intraoral photographs, revealing patient's bilateral crossbite and extraoral photographs showing the main reason for complaint – maxillary crowding and unaesthetic "buccal corridors".



Figure 2 – 3D Laser Scanner Roland LPX-250.

Metoda:					
Williams					
A-N-Pg	3.3 °	4.8 °	-5.5	2.0	9.5
A-N-B	0.3 °	-1.0 °	-4.5	3.0	10.5
S-N-A	80.2 °	81.1 °	71.5	82.0	92.5
S-N-Pg	76.9 °	76.3 °	69.5	80.0	90.5
S-N-B	76.6 °	77.4 °	70.0	79.0	88.0
Pr-N-A	1.9 °	2.3 °	-1.0	2.0	5.0
CL/ML	63.6 °	65.0 °	52.0	70.0	88.0
Pg-N-B	-0.3 °	1.0 °	-6.5	1.0	8.5
Iis/NL	102.6 °	101.3 °	82.0	110.0	128.0
Ili/ML	91.2 °	96.7 °	73.0	94.0	115.0
Wits	1.8 mm	-1.8 mm	-6.0	3.0	6.0
N-S-Ar	116.0 °	116.9 °	109.0	124.0	139.0
N-S-Ba	125.7 °	126.5 °	117.5	131.0	144.5
NL-ML	27.7 °	22.8 °	7.0	25.0	43.0
NSL-NL	11.9 °	15.9 °	-1.0	8.0	17.0
NSL-ML	39.6 °	38.7 °	15.0	33.0	51.0
NL/OLs	16.1 °	20.6 °	-2.0	10.0	22.0
OLI/ML	23.5 °	18.1 °	5.0	20.0	35.0
Go-Gx-Ar	17.1 °	19.9 °	11.5	19.0	26.5
Ar-Go-Me	132.6 °	131.4 °	108.0	128.0	144.0
Predkus	3.4 mm	2.1 mm	-3.0	3.0	9.0
Prekus	1.8 mm	1.3 mm	-3.5	2.5	8.5
1+1	126.5 °	123.3 °	108.0	132.0	156.0
1-APg	2.9 mm	5.3 mm	-8.0	1.0	10.0

Figure 3 – Pretreatment and posttreatment tracing.

The patient exhibited an Angle half-cusp Class II malocclusion on the right, and Class I malocclusion on the left side. She also had a bilateral crossbite: right from the maxillary lateral incisors to second molars, left at first and second molars (Figure 1). In the maxillary and the mandibular arches, there was considerable crowding. Crowding of a 7.8 mm was presented in the upper jaw and 3.5 mm in the lower arch. Transversal lack of space linear measured in between mesiopalatal

cusps of upper first molars and lower first molars central groove, was 8 mm. Her midline was centred.

The panoramic radiograph demonstrated that the complete dentition was present. In the third molar area only the upper left third molar bud was developing. Alveolar bone and root length appeared normal.

The cephalometric analysis demonstrated a Class I skeletal pattern (Wits 1.8 mm), without any major aberrations (Figures 2 and 3).

Treatment plan

1. Splitting of the mid palatal suture with a Hyrax appliance combined with surgically assisted rapid maxillary expansion (SARME).
2. Full upper and lower jaw fixed appliances for alignment and correction of general crowding, rotations and coordination of dental arches.
3. Finishing by establishment of a stable, functional and aesthetic occlusion.
4. Retention – fixed upper central incisors and lower canine to canine; functional removable appliance for night wearing.
5. Extraction of the upper left third molar in the future.

Treatment progress

A bonded acrylic Hyrax expander was inserted three days before the surgical phase. Hyrax screw 13 mm by Leone has been used. The working bite for the expander was set higher in order to control the vertical dimension and prevent bite opening. Immediately after surgery the screw was opened 0.8 mm by the surgeon. In five days the patient continued to open the screw two times daily

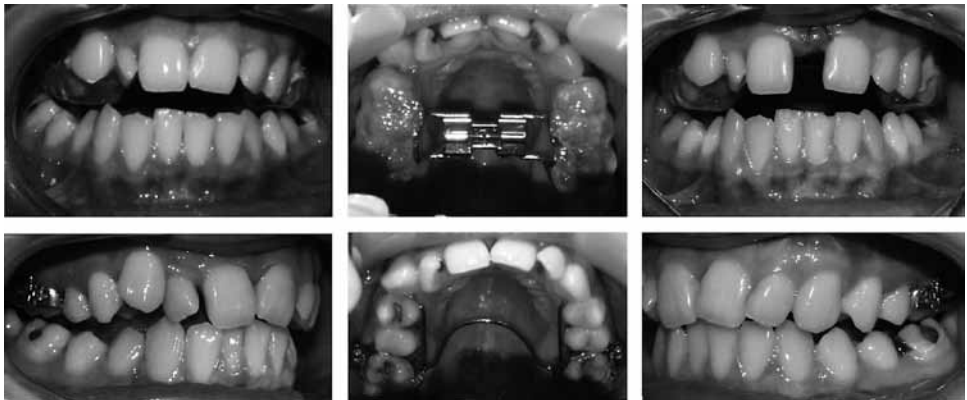


Figure 4 – Top left and top centre: the bonded Hyrax appliance in place. Top right: the large midline diastema confirming successful splitting of the palatal suture. Bottom left and right: crossbite correction and closure of the central diastema through a combination of skeletal relapse and tooth movement created by stretched gingival fibres. Bottom centre: bands on the first molars and transpalatal arch immediately after removal of the Hyrax expander. It is clear that posterior open bite occurs, when upper jaw widens.

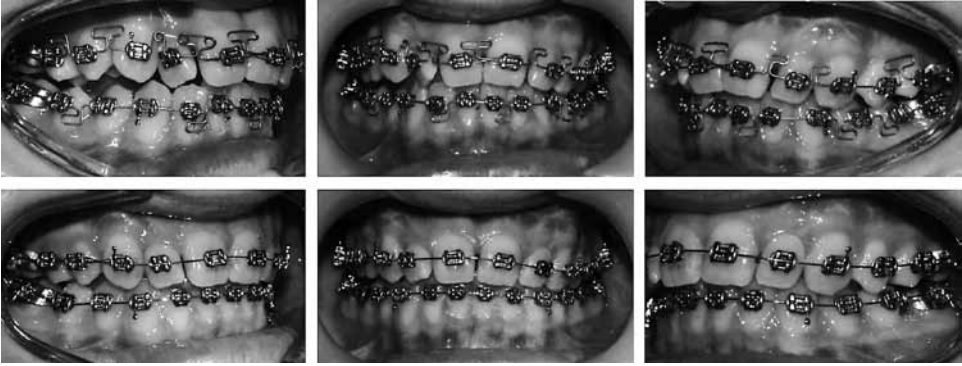


Figure 5 – Top row: first phase of the fixed appliance treatment alignment using 0.16 TMA multiloop archwires. Bottom row: initialization of root tipping NiTi 0.17×25 in use. Posterior open bite is closed as effect of uprighting, derotation and alignment of the teeth.

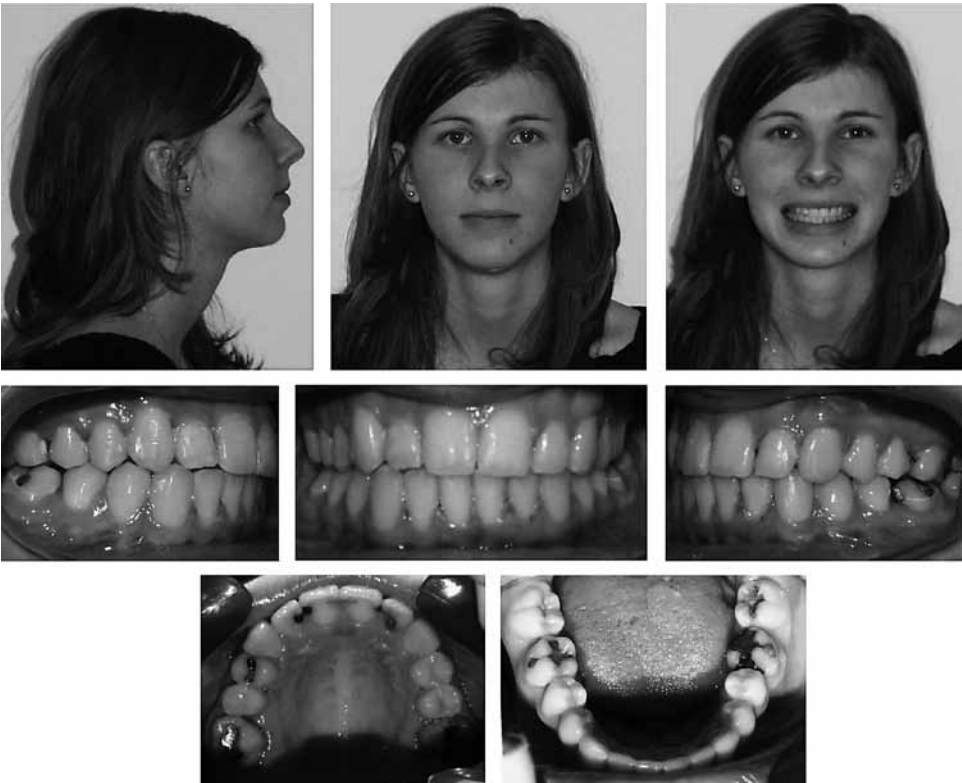


Figure 6 – Posttreatment dental photographs show crossbite correction, Angle Class I occlusion; straightening of the occlusal plane and good occlusion and intercuspation. The facial photographs demonstrate better skeletal and soft tissue patterns, and a pleasant smile.

until an opening of 9 mm in the region of the first molars was achieved. Then the appliance was locked for three months to help new bone formation. After removal of the Hyrax, a transpalatal arch with arms to first premolars was placed for anchorage. Temporarily lateral open bite occurred (Figure 4).

Treatment was accomplished with the Gemini braces by 3M Unitek (Roth prescription with 0.18 inch slot from canine to canine for better torque control and 0.22 inch slot in the premolar region). In order to prohibit bite opening, 0.16 TMA multiloop wires, manufactured in the dental practice, were placed in both upper and lower jaw. This clinical procedure helped to correct tooth rotation and align teeth without any wire changes, but only activation within 10 to 15 months. Lateral open bite was closed (Figure 5). At the end of treatment, 17×25 resilient stainless steel arch wires, with first-, second-, and third order bands were placed to achieve the final occlusion. II Class elastics were applied for establishment of more stable and functional Class I occlusion. No vertical elastics were used. The patient's cooperation was optimal and the appliances were removed 2 years and 3 months after the start of treatment. Total treatment time was 2 years and 6 months.

Retention

Branded titanium retainers (Dentaurum) bonded with a light cure resin Retensin MT and Opticor flow (Sofa Dental) were used for fixed retention from canine to canine in the mandible and between central incisors in the maxilla. The patient was shown how to maintain good oral hygiene with floss and correct methods for brushing the teeth.

A functional removable appliance of the Klammt type was manufactured for night-time wearing. The retention plan called for the retainer to be worn afternoon and night time for a year, then at night only for another year, followed by an as needed basis.

Final evaluation and results achieved

The treatment goals were correction of bilateral crossbite and crowding in the upper and lower jaws, and correction of the Angle Class II dental relationship on the right side. Surgically assisted rapid maxillary expansion (SARME) avoided the painful opening of a mid-palatal suture and prevented rotations and vestibular inclinations of teeth involved in the appliance. It also led to more stable results after treatment completion (Haas, 1980; Betts et al., 1995; Singh et al., 1999). Photographs show a symmetric, harmonious relationship of the facial soft tissue, a nice smile, and a pleasant profile (Figures 6 and 7).

The main problem was to prohibit bite opening during palatal expansion. Therefore Hyrax bite plates were set higher than physiological occlusion to transmit tooth intrusion. In the initial phase 0.16 TMA arch wires were manufactured in the dental practice, even though this process is time consuming and requires good knowledge of multiloop system functions and very good

technical skills of the dentist. The wires helped to correct all rotations and enabled very good three-dimensional bite control without bite opening.

The patient had no TMJ dysfunctions either before or after treatment. The panoramic radiograph revealed proper root paralleling and no signs of bone or root resorption. Superimposition and comparison of the profiles before and after treatment illustrates favourable mandibular growth in downward and forward direction (Figure 7). Even though due to unfavourable growth Wits change within 3.2 mm (from +1.8 mm to -1.8 mm), the vertical dimension stayed in a proper control (Figure 3).

The results of SARME and the orthodontic treatment were investigated on the basis of geometric morphometrics. To digitize the maxillary dental plaster casts, we used a three-dimensional laser scanner Roland LPX-250 (Roland DG, Hamamatsu, Japan) with a lateral resolution of 200 µm (Figure 2). Scanning was performed using Dr. Picza 3 software (Roland DG). The casts were scanned on the rotated plate from a direction perpendicular to the occlusal plane. Raw scan data were processed using Pixform reverse engineering software (Roland DG).

To determine whether the configurations before and after treatment differed, MorphoStudio 3.0 software was used. The palatal model geometry at the start of treatment was compared with the corresponding palatal geometry after completion of the treatment. In order to demonstrate areas size changes, a finite element scaling analysis (FESA) was undertaken that incorporated the splice interpolation function. Based on this approach, form differences can be described graphically. A log-linear interpolation of the area change values was used to generate pseudo-colour maps which provide graphical displays of geometrical change after treatment (Singh and Thind, 2003). Pink colour demonstrates greatest increase, green colour neutral changes and blue colour indicate relative decrease of the definite area.

The shape of the palate changed significant in the width direction, not significantly in length and high direction (Figures 8 and 9). The greatest expansion

Table 1 – Differences in the lower jaw width before and after treatment measured between: 1. canines, from mezial contact points of canines with incisors, 2. canine cusps, 3. lingual cusps of the first lower premolars, 4. lingual cusps of the second lower premolars, 5. mesiolingual cusps of the first lower molars

Lower jaw (mm)	Before	After	Difference
1.	20.76	21.34	0.58
2.	21.20	28.24	7.04
3.	26.85	29.78	2.93
4.	33.73	33.91	0.18
5.	37.19	38.47	1.28

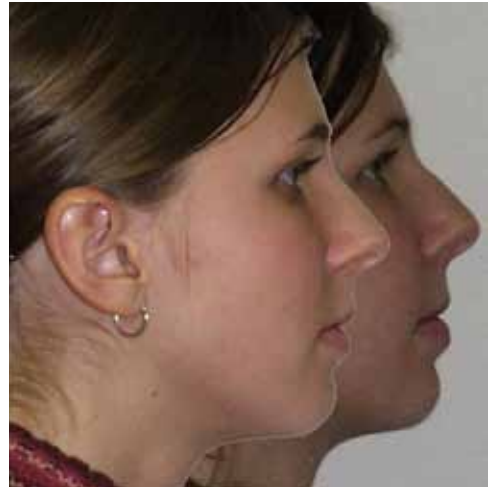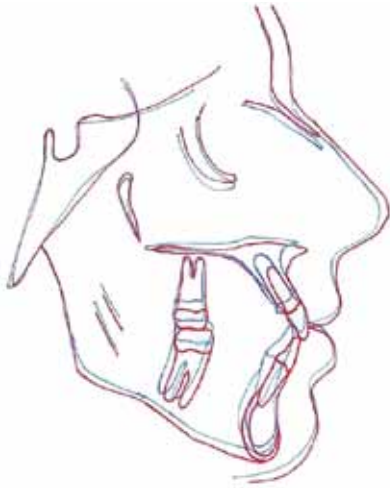


Figure 7 – Pretreatment (blue line)/posttreatment (red line) superimposition and photographs.

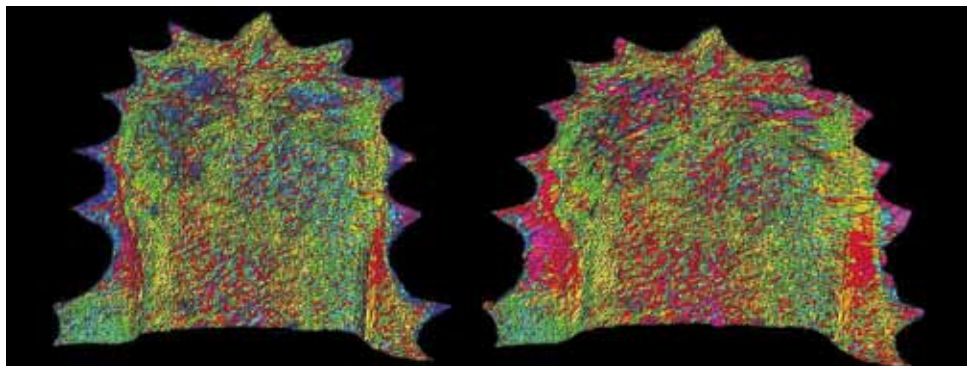


Figure 8 – Pretreatment (on the left) and posttreatment (on the right) shape of the patient palate (superior view). Colored map is graphic result of FESA analysis which informs about size change of definite area (pink color demonstrates greatest increase, green color neutral changes and dark blue color decrease).

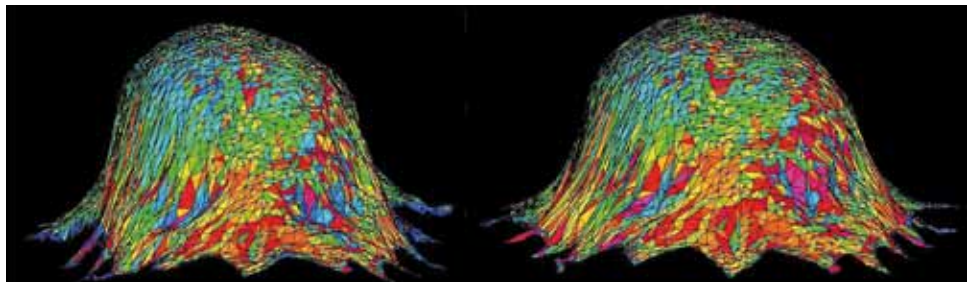
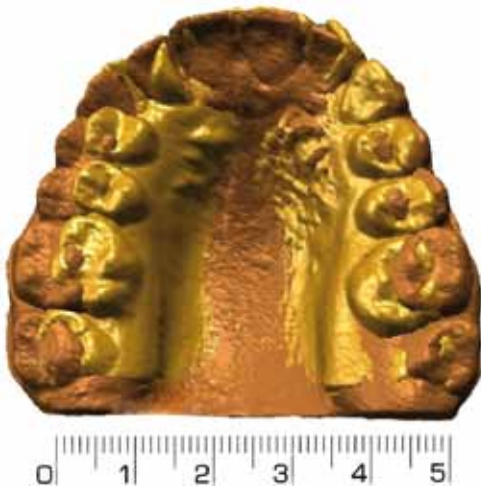

Figure 9 – Pretreatment (on the left) and posttreatment (on the right) shape of the patient palate (frontal view). Colored map is graphic result of FESA analysis which informs about size change of definite area (pink color demonstrates greatest increase, green color neutral changes and dark blue color decrease).




Figure 10 – 3D dental casts images before (on the left) and after (on the right) treatment. Scan data were processed using Pixform reverse engineering software (Roland DG).



Distance	Before	After	Difference (%)
M1	32.930	41.704	26.644
P1	31.515	36.739	16.576
P2	27.325	33.322	21.947
I2	23.624	28.170	19.243

Figure 11 – Digital models superimposition (golden – before treatment; brown – after treatment) using Pixform reverse engineering software (Roland DG) and the results of the widening (in percents). M1 – intermolar distance; P2 – second premolars distance; P1 – first premolars distance; I2 – distance in between lateral incisors distal incisal edges.

of palate was found in the region between the palatal cusps of the first molars 26.6%, followed by first 21.9% and second premolars 16.5% (Figures 10 and 11). Graphic comparison using FESA analysis informed then for instance about particular surface area increase in proximity of first molars (Figure 11).

Changes in the lower jaw were measured by electronic calliper. Greater alteration was found in between lower canines, followed by the first lower premolars (Table 1).

The effect of treatment was to normalize transversal, sagittal and vertical patterns of occlusion. Angle I Class occlusion on both sides was achieved. Thanks to transversal expansion there was enough space to resolve crowding and rotations in the upper jaw and to allow a better position of the lower jaw. All treatment goals were satisfied and patient was very pleased with the treatment, which resulted in a good facial appearance and full smile.

Discussion

There are many reasons why crossbite occurs: jaw size and heredity, delayed loss of deciduous teeth, mouth breathing, tongue thrusting and thumb sucking. The consequences of not treating the problem are severe and can include facial asymmetry, narrowing of the nasal airways, myofunctional problems and temporomandibular joint (TMJ) disorders. Crossbite correction in children should begin as early as possible, when the facial bones are not yet fused to allow for brain and facial development, and the mid-palatal suture is not yet consolidated. In adults in most cases it requires the use of a Hyrax appliance and surgically assisted rapid maxillary expansion (SARME), and in some cases maxillofacial surgery for facial asymmetry correction.

Rapid maxillary expansion (RME) was initially advocated for use in children. It was conceived as a way of maximizing skeletal change and minimizing dental change. Krebs, using metallic implants, demonstrated that approximately 50% of the expansion achieved by RME in children was skeletal and the remainder was dentoalveolar. In a recent paper, Capellozza and co-workers (1996) attempted sutural expansion in 38 non-growing subjects with mixed results. Failure to expand, pain, swelling, or ulceration were frequent complications. Vardimon and co-workers (1991) have expressed concern about root resorption with toothborne expanders in non-growing subjects.

The original idea of surgically assisted expansion was that cuts in lateral buttress of the maxilla would decrease resistance to the point where the mid-palatal suture could be forced open. Since it works in patients in their 20s it was decided to use this method in our patient (Proffit, 2007).

SARME is a true orthopaedic expansion, starting at the apex of the palatal vault with bone apposition at the suture. Most patients with maxillary transverse deficiencies have malocclusions without associated facial dysplasia. These patients are usually reluctant to undergo surgery to correct dental alignment problems.

Cases requiring more than 8 mm to 10 mm of expansion, severe unilateral posterior crossbites with diminished prospect of mandible centring, and patients with significant gingival recession are likely candidates for SARME.

Different methods for SARME and orthodontic treatment results evaluations can be used. Method used by us allows precise scan of one dental cast at time. The three-dimensional helical computed tomography described by Australian authors, helps to make scans for up to six dental casts (Phatouros and Goonewardene, 2008). This is more expensive method, but less time consuming.

Conclusion

Several studies have shown that rapid maxillary expansion RME appliances contribute to the increase in the vertical dimension. This was the reason why in this case it was decided to combine surgically assisted rapid maxillary expansion with an acrylic bonded expander. This can minimize bite opening, as a study by Asanza and co-workers (1997) showed. For the same reason surgery-manufactured 0.16 TMA wires were used in the alignment phase of the treatment.

Every late adolescent and adult crossbite case needs good evaluation prior to a decision as to whether nonsurgical RME or referral for surgical assistance would be more appropriate. In our opinion SARME in adult patients may lead to better and more stable results.

The 3D dimensional surface laser scanning technique and computerized cast analysis, using advanced software's are successfully used for very precise studies in patients with maxillary expansion with SARME or without it.

In a next few years we can expect, that 3D laser scanning or other precise scanning method, and work with a digital models, will become a routine method in orthodontic measurements as it gives better visualization of treatment outcomes (Oliveira et al., 2004).

References

- Alpern, M. C., Yurosko, J. J. (1987) Rapid palatal expansion in adults with and without surgery. *Angle Orthod.* **57**, 245–263.
- Asanza, S., Cisneros, G. J., Nieberg, L. G. (1997) Comparison of Hyrax and bonded expansion appliances. *Angle Orthod.* **67**, 15–22.
- Betts, N. J., Vanarsdall, R. L., Barber, H. D., Higgins-Barber, K., Fonseca, R. J. (1995) Diagnosis and treatment of transverse maxillary deficiency. *Int. J. Adult Orthodon. Orthognath. Surg.* **10**, 75–96.
- Capelozza, L., Neto, J. C., da Silva, O. G., Ursi, W. J. S. (1996) Non-surgically assisted rapid maxillary expansion in adults. *Int. J. Adult Orthodon. Orthognath. Surg.* **11**, 57–66.
- Haas, A. J. (1980) Long-term posttreatment evaluation of rapid palatal expansion. *Angle Orthod.* **50**, 189–217.
- Mossaz, C. F., Byloff, F. K., Richter, M. (1992) Unilateral and bilateral corticotomies for correction of maxillary transverse discrepancies. *Eur. J. Orthod.* **14**, 110–116.
- Oliveira, N. L., Da Silveira, A. C., Kusnoto, B., Viana, G. (2004) Three-dimensional assessment of morphologic changes of the maxilla: a comparison of 2 kinds of palatal expanders. *Am. J. Orthod. Dentofacial Orthop.* **126**(3), 354–362.

- Phatouros, A., Goonewardene, M. S. (2008) Morphologic changes of the palate after rapid maxillary expansion: a 3-dimensional computed tomography evaluation. *Am. J. Orthod.* **134**, 117–124.
- Pogrel, M. A., Kaban, L. B., Vargarik, K., Baumrind, S. (1992) Surgically assisted rapid maxillary expansion in adults. *Int. J. Adult Orthodon. Orthognath. Surg.* **7**, 37–41.
- Proffit, W. R. (2007) *Contemporary Orthodontics*, 4th Edition. Mosby, St. Louis.
- Singh, G. D., Thind, B. S. (2003) Effects of the headgearactivator Teuscher appliance in the treatment of Class II division 1 malocclusion: a geometric morphometric study. *Orthod. Craniofac. Res.* **6**, 88–95.
- Singh, G. D., McNamara, J. A. Jr., Lozanoff, S. (1999) Finite-element morphometry of soft tissue morphology in subjects with untreated Class III malocclusions. *Angle Orthod.* **69**, 215–224.
- Tauferová, E. (2006) Dentoalveolární změny po rychlé palatinální expanzi a chirurgicky asistované rychlé palatinální expanzi. *Ortodoncie* **15(2)**, 42–54. (in Czech)
- Vardimon, A. D., Graber, T. M., Voss, L. R., Lenke, J. (1991) Determinants controlling iatrogenic external root resorption and repair during and after palatal expansion. *Angle Orthod.* **61**, 113–122 (commentary on pages 123–124).