

Ahmanson/UCLA Adult Congenital Heart Disease Center

FOR THOSE TOUCHED BY CONGENITAL HEART DISEASE

SPRING 2012



Center Updates

New UCLA Cardiovascular Center houses the ACHD outpatient clinic

We are pleased to announce the opening of the UCLA Cardiovascular Center in the 100 UCLA Medical Plaza building. This facility is located on the 6th floor, in suite 630 and houses the Ahmanson/UCLA Adult Congenital Heart Disease Center, as well as several other cardiovascular subspecialties. All of your outpatient cardiology appointments, including cardiac testing, will take place in this one location.


New ACHD Website

Please visit our updated Ahmanson/UCLA Adult Congenital Heart Disease Center website at: www.uclahealth.org/achd and give us your feedback!

Patient / Family Forum & Reception May 24th, 2012

Special Tribute in Honor of Dr. John Child's Retirement

You are invited to attend our patient/family forum and reception at Ronald Reagan UCLA Medical Center on Thursday May 24th, 2012 from 5 pm to 7 pm in the Tamkin auditorium on the B1 level. We will have a patient panel and discussion, and a special tribute honoring Dr. John S. Child and his 35-year career at UCLA. A cocktail reception will follow. Valet parking in front of Ronald Reagan UCLA Medical Center is \$11. Please RSVP by May 21st, to achdc@mednet.ucla.edu or call (310) 825-2019.



Welcome to Dr. Jeannette Lin

Dr. Jeannette Lin will join the faculty of the Ahmanson/UCLA Adult Congenital Heart Disease Center on July 1, 2012. She is currently on faculty at UC Irvine Medical Center, after completing an advanced fellowship in ACHD at UCLA. Her extended role at UCLA will involve one week a month at the Ahmanson/UCLA ACHDC, while she continues to grow her ACHD practice at UCI for the rest of the month. Dr. Lin stood out to our patients last year as an extremely compassionate and accomplished clinician; she will be warmly welcomed by all when she returns in July.

Faculty and Contact Information

Faculty

Ahmanson/UCLA ACHDC Faculty

John Child, MD Director

Jamil Aboulhosn, MD

Co-director, Interventional Cardiology

Leigh Reardon, MD Congenital Cardiology

Daniel Levi, MD Interventional Cardiology

Kevin Shannon, MD Electrophysiology

Jeremy Moore, MD Electrophysiology

Kalyanam Shivkumar, MD Electrophysiology

Ravi Mandapati, MD Electrophysiology

Hillel Laks, MD Cardiothoracic Surgery

Brian Reemtsen, MD Cardiothoracic Surgery

Pamela Miner, NP Nurse Practitioner

Linda Houser, NP Nurse Practitioner

ACHDC Staff

Jennifer Doliner, RN Nurse Coordinator

Yvonne Jose Administrative Manager

Contact Us

How to Contact the Center

Patient Calls (310) 794-9629 or (310) 825-9011

Nurse Coordinator (310) 794-5636

Fax Numbers (310) 825-6346 or (310) 825-9012

Email: achdc@mednet.ucla.edu

Website: www.uclahealth.org/ACHDC

Information & Resources

Adult Congenital Heart Association (ACHA)

Website: www.achaheart.org

Call (888) 921-ACHA

Email: info@achaheart.org

International Society for Adult Congenital Heart Disease (ISACHD)

Website: www.isachd.org

Faculty Profile

Jamil Aboulhosn, MD



Jamil Aboulhosn, MD

Dr. Jamil Aboulhosn is set to take over as Director of the Ahmanson/UCLA Adult Congenital Heart Disease Center on July 1st, 2012. He will be following in the very impressive footsteps of our founding director Dr. Joseph Perloff, and more recently, our current director Dr. John Child who will be retiring at the end of June 2012. Dr. Aboulhosn represents the next generation of specially trained adult congenital heart disease cardiologists, having focused most of his adult cardiology training and an advanced fellowship on caring for adults with congenital heart disease. He has additional, advanced training and expertise in complex interventional catheterization treatments, including transcatheter valve replacement. Dr. Aboulhosn has been the Co-director of the center for the past three years and the Director of Research at the center for the past five years. He will carry the Center through its fourth decade of existence, focusing on expanding and improving clinical services and research operations to continue to provide world-class and cutting-edge care to our growing number of patients

Dr. Aboulhosn was born in Lebanon and lived there until 10 years of age before moving with his family to Nairobi, Kenya where his father worked as a diplomat. He moved to the United States in 1989 and graduated from UC Riverside in 1995, majoring in biomedical sciences and minoring in world history. He received his medical degree from UCLA in 1999, and completed his cardiology fellowship at Harbor

UCLA Medical Center in 2005. After making adult congenital heart disease his focus during cardiology training, he completed an advanced fellowship with the Ahmanson/UCLA Adult Congenital Heart Disease Center in 2006. He spent an additional 2 years as a junior faculty member undergoing further training on transcatheter interventions in congenital heart disease. Since his arrival as a fellow, Dr. Aboulhosn has become an invaluable member of our ACHD team, so much so, that he was named Director of Research in 2006 and Co-director of the Center in 2009. He has also become a leader on the national ACHD scene, playing an integral role in multi-center ACHD research (he is the current president-elect of the Alliance for Adult Research in Congenital Cardiology) and chairing the Annual Adult Congenital Heart Association National Conference in 2011. He has extended our reach in providing specialty ACHD care, by directing an ACHD clinic in Las Vegas, Nevada as part of the Children's Heart Center of Nevada.

"Dr. Aboulhosn represents the next generation of specially trained adult congenital heart disease cardiologists, having focused most of his adult cardiology training and an advanced fellowship on caring for adults with congenital heart disease."

Dr. Aboulhosn has earned accolades for his expertise in ACHD, but is also a very accomplished artist. He calls this a hobby, but his talent for drawing complex cardiac diagrams of heart defects is well recognized by all who have worked with him and is sought after by colleagues at UCLA and around the country as illustrations for numerous manuscripts and textbooks focusing on congenital heart disease. In his occasional downtime, he enjoys drawing, painting, sculpting historical miniatures, writing and illustrating fantasy short stories, and playing soccer. He is an avid fan of the Los Angeles Lakers and Liverpool Football Club. Dr. Aboulhosn is married to Julie Kasem and has two beautiful daughters, Bella and Sophie.

UCLA Adult Congenital Heart Patient Receives Hybrid Heart Procedure that Saves Her Life



Dr. Aboulhosn with ACHD patient, Patricia.

Patricia age 49, was born with complex congenital heart disease, specifically, transposition of the great arteries, VSD, pulmonary valve stenosis, and anomalous pulmonary veins. She was a “blue baby” and despite surgical intervention at a young age, she continued to be cyanotic (blue) and severely limited. And that was the least of her worries. A huge aneurysm in her pulmonary artery was a ticking time bomb and her heart and liver were failing, all adding to the reasons why it was too risky for her to receive the heart/lung transplant she desperately needed to survive. She had been seen at multiple academic medical centers and told that there was nothing more to offer and she would not be a candidate for transplant.

She was referred to the Ahmanson/UCLA Adult Congenital Heart Disease Center to assist in her management. Our team of adult congenital cardiologists and cardiac surgeons wouldn't give up hope. Drs. Aboulhosn and Laks performed a high-risk, hybrid heart procedure that removed the aneurysm, replaced a failed heart valve and repaired another and also closed a hole in Patricia's heart. She has been successfully discharged from the hospital and is recovering well; she no longer needs a heart/lung transplant.

Since this procedure on Feb. 7th 2012, she is no longer blue, she is more active and energetic, and Patricia is now taking medications only for her heart. She says she can't believe it and has to pinch herself as a reminder that it's real. She had been told since childhood that she would not survive

for more than a few years. According to her sister Cathy, it's the first time since Patricia's birth that she has a positive prognosis for the future.

Dr. Jamil Aboulhosn, Co-director of the Ahmanson/UCLA Adult Congenital Heart Disease Center, says the UCLA team is dedicated to helping patients like Patricia with complex congenital heart disease live more fulfilled lives using available technologies and procedures and working to develop new ones.

There were major challenges to Patricia's surgery. The 11-cm aneurysm threatening Patricia's life is one of the largest seen, and severe pressure elevation in her lungs increased the likelihood that the aneurysm could burst at any moment. Patients with severe lung pressure elevation, known as pulmonary hypertension, are deemed too high risk to undergo open heart surgery on a heart-lung machine. Drs. Aboulhosn and Laks devised a plan to perform the operation using a novel “hybrid” intervention to shorten her time on the heart-lung machine, giving Patricia a better chance of surviving the operation. Hybrid interventions are performed by a surgeon and an interventional cardiologist, allowing the team to combine the strengths of traditional heart surgery with less invasive catheter-based interventions to shorten the duration of procedures, make them less invasive, and improve safety.

First Patricia's chest needed to be opened, which itself is challenging in the presence of highly abnormal anatomy and scarring from prior operations. Next, Dr. Laks placed Patricia on the heart-lung machine and opened her pulmonary artery aneurysm. Dr. Aboulhosn then used a new balloon-mounted “Melody valve” to replace her failing pulmonary valve and close a hole in her heart; procedures that typically would take more than an hour to perform by traditional surgical techniques were performed in less than 10 minutes. Dr. Laks went on to resect the aneurysm and place a synthetic tube in its place. Patricia's tricuspid valve was also surgically repaired.

The use of the hybrid technique shortened Patricia's time on the heart-lung machine by more than an hour. The procedure was

uncomplicated and Patricia came off the heart-lung machine without difficulty. Her circulating oxygen saturation had improved from 72 percent immediately before the surgery to 97 percent immediately afterwards. She was moved to the ICU and her breathing tube was removed within 12 hours. She was discharged home on February 22nd 2012, without the need for supplemental oxygen.

Just a few weeks later, Patricia is feeling much better. Her oxygen level is in the 90s rather than 70s, meaning that tissues are receiving adequate oxygen. She is more active, walking without difficulty, and looking forward to the future.

Research in Progress

Contraceptive Practices in Females with Congenital Heart Disease:

Questionnaire survey for females over the age of 18 with CHD, focusing on contraceptive practices, side effects, complications, and menstrual abnormalities.

Inhaled Iloprost for the treatment of pulmonary hypertension in adults with CHD: three-month trial of inhaled medication, self-administered six times a day.

Bosentan for reduction in pulmonary pressures in adolescents and adults with Fontan/single ventricles: three-month trial of oral medication twice a day

Gene study for patients with Shone's syndrome: one-time blood test

For more information regarding any of the above studies, please email achdc@mednet.ucla.edu or call (310)794-5636.

Three UCLA Heart Patients Share Their Stories



Tom, age late 50's

The birth of a child is something we've all seen a hundred times in movies and documentaries: The doctor holds up a pink newborn who, if not already screaming, will be after a sharp slap.

The birth of our first child wasn't like the movies. After suffering through my wife's caesarian (though not nearly as much as she), my initial view of our first child was of a bluish baby boy gasping for breath. Though this was my first time in a real delivery room, it didn't feel right. That feeling was quickly confirmed by the behavior of the professionals in the delivery room. They were clearly freaked.

Fortunately, under the circumstances, the hospital we had chosen had a NICU and that's where my son immediately went, into an oxygen tent. A neonatal specialist was called in, and within hours the doctors had non-invasively made a preliminary diagnosis of transposition of the great arteries. We were told in doctor-speak that this condition is "incompatible with life" and we needed to promptly have our son transported to a hospital that does neonatal cardiac surgery. We were given several choices — and just a few minutes to decide. We chose UCLA.

We never regretted our choice.

Amazingly, the preliminary diagnosis was spot on and four days later, UCLA's Dr. Hillel Laks performed an arterial switch on our tiny boy while his mom was still recuperating from her C-section at the other hospital. Today our son is a strapping 24-year-old college graduate living

and working in San Francisco. He continues to be followed at the Ahmanson/UCLA ACHDC.

So do I. You see, I too was born with a heart defect, though a different one: Tetralogy of Fallot.

Looking back, the first weeks of our son's life must have been even tougher on my parents who lived through this intense, surreal experience twice: heart surgery for their son and thirty years later heart surgery for their grandson. Twice sitting in one of those grim waiting rooms, waiting.

When I was very young I had been told that because my heart defect was "congenital," my children had no increased risk for heart defects. It's now known there is a small but real risk of passing on CHD to your offspring, which we learned the hard way. So, when my wife became pregnant with our daughter, we ordered up a fetal echocardiogram. Her heart was no bigger than a walnut but the doctor said it looked just fine. And so it is. The same goes for the rest of our family.



Kristin, age 30


I have always enjoyed challenging myself and often sought out new adventures and experiences. As a result I have run three half marathons, numerous 10Ks, and hope to one day complete a full marathon. I also have been

fortunate to experience living in California, New York City, Mexico, Italy and now Puerto Rico. Like most parents, mine always supported my dreams and goals, however due to the fact I was born with transposition of the great arteries and a ventricular septal defect, I'm sure their adventure-loving daughter gave them more than a few gray hairs. Yet despite my congenital heart defect, my parents have never (yes, never) used my heart condition as a reason why I could not or should not do something.

I had my first open-heart surgery in 1989 at the age of 8, when I had an arterial switch. My second surgery was at the age of 19 when I had my aorta and aortic valve replaced. Due to the fact I have a mechanical aortic valve and take coumadin, pregnancy risk has always been a topic of discussion during my annual cardiology appointments. In 2009, when my husband and I found out I was pregnant, I immediately switched to Lovenox (an injectible blood thinner that is safer for my baby than coumadin) and began administering the two shots a day needed to maintain my anticoagulation. Initially my pregnancy progressed perfectly and I was even able to continue running. However at 28 weeks, I began to bleed and was diagnosed with placenta previa, and as a result I was put on hospital bedrest due to the complications of being anticoagulated. My husband and I were very fearful both for my own health and the health of our unborn son as we continued to wait and see if I would be able to carry the baby to term. At 33 weeks, I had a caesarian section since I continued to bleed heavily and the risks of remaining pregnant were too great. My son, Oliver, was born seven weeks premature, but luckily with no other major health concerns and especially no cardiac complications. Two days after Oliver's birth I developed a fever of 104.5° F and was subsequently diagnosed with an E. coli infection. Once I was on antibiotics and my fever dissipated, I was able to focus on caring for my baby and regaining the strength I had lost during the extended bedrest. In addition, my husband and I were relieved that Oliver was doing well and that we could concentrate on him getting strong enough to come home.

Thanks to my parents I have been blessed with the opportunity to have a family of my own. Oliver is thriving and is a very happy and healthy little boy. Without my parents' strength to let me

live my own life and not limit my hopes and dreams despite the fact I have a congenital heart defect, I might not have had the courage to have a biological child. I feel very blessed to have a healthy child and to have received the medical care I needed to manage such difficult situations. Now as a parent myself, I recognize the constant strength my parents demonstrated and hope I will be able to support and encourage my son in a similar fashion.



Keyota, age 33

When she was just 16 weeks pregnant, Keyota received the news no mother to be ever wants to hear. Testing had revealed that her unborn daughter had a severe form of congenital heart disease and would require open-heart surgery shortly after birth.

Keyota is all too familiar with the subject. As a baby, she had been diagnosed with Ebstein's anomaly, a type of congenital heart defect that affects one of the four heart valves, the tricuspid valve, causing it to leak and resulting in abnormalities of heart chamber size and function. She had also been born with a hole in her heart and abnormalities of the pulmonary veins. Keyota had been through two open-heart surgeries in childhood and one as an adult to correct this problem. In fact, she had undergone her most recent operation, a valve replacement, just 13 months prior to becoming pregnant. She had experienced problems with heart rhythm after this last surgery, requiring the placement of a pacemaker. Her pregnancy was unexpected, and it was feared that Keyota's heart would not be strong enough to withstand the stress. Despite the risks, Keyota made the choice to not terminate the pregnancy.

Although the overall risk is relatively low, women with congenital heart disease do have a

4 to 15 percent greater chance of giving birth to a baby with a heart defect. Among the general population, the risk is approximately 0.8 percent, or 8 in 1000 live births. The type of congenital heart disease affecting the child can be similar to that of the parent, or can be completely different. A fetal echocardiogram revealed that her daughter's heart had only one effective pumping chamber and would require several operations to fully correct the circulation.

Fortunately, a skilled team of UCLA cardiac surgeons, high-risk obstetricians, pediatric and adult cardiologists and neonatologists stood ready to help. When Keyota announced her decision to proceed with the pregnancy, the team moved quickly to organize her care. She was seen during each trimester by Dr. Jamil Aboulhosn of the Ahmanson/UCLA Adult Congenital Heart Disease Center, who examined her and performed regular echocardiograms to ensure that her heart was tolerating the changes of pregnancy. Dr. Mark Sklansky, chief of Pediatric Cardiology at UCLA and the doctor who had diagnosed her daughter's heart defect, kept close watch on the baby's developing heart. Dr. Brian Koos of UCLA High Risk Obstetrics monitored and managed the pregnancy.

On December 12, 2011, Keyota was admitted to UCLA for delivery. The following day, her daughter, Faith, was born by caesarean section and transferred to the neonatal intensive care unit. At only 6 days of age, little Faith was taken to the operating room where Dr. Brian Reemtsen performed the first (and most complicated) of three surgeries aimed at correcting the baby's circulation. Coincidentally, Dr. Reemtsen was the surgeon who had performed Keyota's valve replacement surgery just over a year earlier. Like her mom, Faith did very well during and after the operation. Just over three weeks following the surgery, Faith was discharged home with her proud and happy parents.

While many challenges lie ahead for both Keyota and Faith, one thing is certain. The specialized teams of medical practitioners here at UCLA will be standing behind them to ensure bright futures for both mother and daughter.

More information on Keyota's story can be found at www.newsroom.ucla.edu



How Can You Help?

The Ahmanson/UCLA Adult Congenital Heart Disease Center (ACHDC) relies in large part upon donations in order to meet its needs to pursue the goals of the Center. Tax-deductible contributions made to the Center directly support:

- *Patient programs focused on enhancing quality of life*
- *Research programs aimed at improving life expectancy*
- *Training programs integral to preparing future providers to carry on the highest level of care*

You can learn more about how to support the ACHDC by visiting www.uclahealth.org/achd and clicking on "ways to give"

You can also call (310) 825-2019 if you would like to discuss specific gift options, or to get more information.

With Special Thanks

Gold level donors

Mr. Albert Praw & Mrs. Heidi Praw
Mr. Douglas Praw & Dr. Stephanie Smooke Praw

Silver level donors

Dr. Charles Berst, PhD and
Mrs. Roelina Berst
Mrs. Jane Lopatt

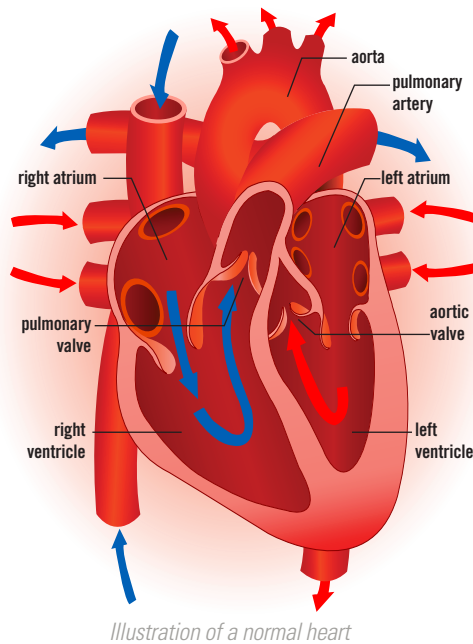
Transposition of the Great Arteries

What is transposition of the great arteries (TGA)?

In the normal heart, oxygen-depleted blood is pumped from the right side of the heart, through the pulmonary artery, to the lungs to pick up oxygen. The oxygen-rich blood then returns from the lungs to the left side of the heart via pulmonary veins, and then is pumped out the aorta to the rest of the body (see illustration of normal heart). Simple transposition of the great arteries means that the pulmonary artery and the aorta are swapped; the aorta arises from the right ventricle and the pulmonary artery from the left ventricle. If this swap exists in isolation, the circulation that results is not compatible with life. In essence, the oxygen-depleted blood is pumped out the aorta, without picking up oxygen in the lungs. Similarly, the pulmonary artery repeatedly pumps oxygen-rich blood back to the lungs without any route to transport oxygen to the tissues of the brain, heart and body. To survive the first days of life, the newborn must have some way for blood to get from one side of the heart to the other. Usually this comes in the form of a patent ductus arteriosus, a naturally occurring connection during fetal life between the aorta and pulmonary artery. But this structure usually closes in the first day or two after birth since its purpose is only to provide a route for blood to bypass the fluid filled lungs while the baby is in the uterus. Once this duct closes, the newborn either needs to have a co-existing hole in the heart (atrial or ventricular septal defect) to survive, or one needs to be created via catheters or surgery.

When is TGA usually diagnosed?

TGA is almost always diagnosed shortly after birth because the baby shows signs of cyanosis (blue lips, nose, tongue, skin). A hole between the right and left chambers of the heart is necessary for the survival of the newborn with TGA, as it provides a route for oxygen-rich blood to reach the brain and the rest of the body. Some babies do okay for several days due to a patent ductus arteriosus. Without this ductus, the newborn requires a hole across the atrial septum to survive, and sometimes it is necessary to do emergency surgery to create a hole. This hole can also be created by using catheters to perforate the septum and allow blood to cross.



How is TGA treated?

As described above, the immediate treatment of a newborn with TGA is to create a hole between the right and left sides of the heart so oxygen-rich blood can reach the tissues of the body. The first surgical repair of TGA was an atrial switch operation (Mustard or Senning), which involved surgical baffles created to divert oxygen-depleted blood returning from the body across the atrial septum and into the left ventricle, which connects to the pulmonary artery. In a similar fashion the oxygen-rich blood returning from the lungs is diverted across the atrial septum via a surgical baffle to the right ventricle which connects to the aorta. With this crossover in the atrium, children with TGA were surviving infancy for the first time with favorable prospects for long-term survival. Surgical advances in the early 1980's improved to permit a more "anatomic" corrective surgery for TGA, involving an arterial switch. This literally involved transecting the aorta and pulmonary artery and re-connecting them to the opposite sides of the heart, thereby allowing the right ventricle to properly flow to the pulmonary artery and the left ventricle to connect to the aorta. The challenge of this operation was the need to reconnect the vital coronary arteries to the new origin of the aorta without compromising blood flow to the heart muscle.

What are the long-term problems that occur after TGA repairs?

With the current surgical approaches to TGA, nearly 90 percent of babies born with this heart defect can survive to adulthood. While patients who have undergone the Mustard or Senning atrial switch operation can enjoy very normal lifestyles, they are at risk for complications that can affect quality of life and long-term survival. Because these operations allow the right ventricle to function as the main pump to the aorta, the problems that can be expected over time involve weakening of this pump and the possible need for medications to support its function. In rare instances, the pump function cannot be preserved and the patient will ultimately need heart transplantation. Heart rhythm problems originating from the upper chambers of the heart (atrial flutter or atrial fibrillation) are relatively common in adults who have had Mustard or Senning operations. This is related to multiple tiny scars in the atrial walls from previous surgical sutures. These abnormal rhythms may require medications, and can often be effectively treated with catheter-based interventions. For some patients, placement of a pacemaker may be required. For patients who have undergone an arterial switch operation, some of the long-term problems involve narrowing at the site where the aorta or pulmonary artery was sutured in place. This can cause increased pressure and damage to the pulmonary or aortic valves, and may need surgical or catheter-based intervention. Some patients with arterial switch operations may ultimately require valve replacement, particularly of the aortic valve.

What type of cardiac follow-up is necessary for TGA?

Patients with TGA require lifelong follow-up of their heart condition at a facility specializing in adult congenital heart disease (ACHD). Occasionally, surgical or catheter-based procedures are required, and establishing regular care with a qualified ACHD center will enable accurate assessment and timing of these procedures, if necessary.