



Splinting of Mini Implants Used to Assist Complete Mandibular Overdentures with Two Different Bar Designs: A 3-Year Clinical and Radiographic Study

Radwa M.K. Emera⁽¹⁾ and Heba Nabil⁽²⁾

Codex : 48/1810

azhardentj@azhar.edu.eg

http://adjg.journals.ekb.eg

DOI: 10.21608/adjg.2018.5235.1004

ABSTRACT

Purpose: Clinical and radiographic evaluation of early loaded four splinted mini dental implants (MDIs) with two different bar designs for assisting mandibular complete overdenture. **Materials and Methods:** Twenty completely edentulous patients (10 males and 10 females) with mean age of 52.5 years old were selected for this study. All patients received four mini implants in the mandibular interforaminal area. Patients were assigned into two equal groups according to splinting bar design, where it was milled bar for **Group I** and round bar joint for **Group II**. Maxillary complete denture was constructed for each patient against implant assisted mandibular overdenture. Peri-implant soft tissue health parameters were monitored and cervical bone height changes were evaluated through standardized periapical radiographs just after loading of mini implants and 6, 12, 24 and 36 months later as represented by (T_0), (T_6), (T_{12}), (T_{24}), and (T_{36}) respectively. **Results:** Insignificant difference of all peri-implant soft tissue health parameters was observed over time within each group and between the two groups at all observational times. Peri-implant marginal bone resorption was significantly higher in group I in comparison to group II at T_6 , T_{12} and T_{36} . Significant difference was found between T_0 and T_6 in both groups and also between T_{24} and T_{36} in group I. **Conclusions:** Both milled and round bar splints can provide a satisfactory clinical outcome for early loaded mini implants assisting mandibular complete overdenture. However, splinting with milled bars seems to be associated with a higher rate of peri-implant marginal bone loss.

KEYWORDS

Mini dental implants,
milled bar,
round bar joint,
clinical/radiographic
assessment.

INTRODUCTION

Mini dental implants (MDIs) were reported as a useful treatment option for enhancing retention of overdentures⁽¹⁾. Four mini-implants retained complete mandibular overdenture may be the treatment of choice for edentulous patients with severely resorbed ridges. Use of mini-implants is a helpful clinical alternative to conventional implants,

1. Associate Professor, Removable Prosthodontics Department, Faculty of Dentistry, Mansoura University. Mansoura. Egypt

2. Teaching Assistant, Removable Prosthodontics Department, Faculty of Dentistry, Mansoura University. Mansoura. Egypt

regarding the reduced surgical time, bleeding, postoperative pain and healing period^(2,3). They can be inserted through one-stage surgical technique if larger sized implants can't be applied without bone reshaping or grafting^(4,5). No complicated techniques or traumatic invasive procedures are required, but only one guiding-drill is needed for mini implants placement⁽⁶⁾. Mini implants can modify the patient's quality of life if the treatment with conventional implants do not meet the patient's financial means⁽⁷⁾.

Survival rate of mini implants ranged between (83.9%) and (97.5%) considering implants position and transferred stresses⁽⁸⁾. load transmission to implants is highly affected by design of used attachments⁽⁹⁾. Clinically, attachments that permit a uniform distribution of occlusal forces between abutments are preferable regarding implant survival and bone preservation⁽¹⁰⁾. A variety of attachments can be applied to mini implants for retaining overdentures⁽¹¹⁾. Different types of solitary attachments were successfully used with mini implants such as ball attachment^(2,12-14), O-ring^(15,16) and magnetic attachment^(15,17). Moreover, splinting bar attachments were also used^(18,19).

It was concluded that splinting of mini implants, used to retain complete mandibular overdenture, showed a decreased level of transmitted stresses to bone and consequently less induced peri-implant bone loss in comparison to unsplinted implants⁽¹⁸⁾. Two bar design concepts are available for splinting implants assisting complete overdentures; the round bar joints and milled bars. Bar joint attachments allow mild vertical and rotational movements of the overdenture in addition to its stress breaking effect⁽²⁰⁾. In contrast, milled bars possess precisely milled, vertically parallel guiding planes that allow intimate contact to the denture base thus offer greater stability and resistance to rotational and lateral forces⁽²¹⁾. Consequently, the present study aimed to prospectively evaluate the impact of these two different bar designs on splinting mini implants assisting complete mandibular overdentures regarding peri-implant soft tissue health and vertical bone loss.

MATERIALS AND METHODS

Twenty completely edentulous patients of both sexes (10 females and 10 males) and age range of 45 to 60 years old were selected from the outpatient-clinic of Removable Prosthodontics Department, Faculty of Dentistry, Mansoura University. Approval of the research protocol was done by the faculty Ethical Committee. Detailed study strategy was clarified to all patients before getting informed signed consent.

Selected patients were healthy with no systemic diseases that interfere with implants osseointegration. Anterior mandibular bone length was sufficient to allow proper implant placement as assessed by digital panoramic radiograph. Patients were of class I Angel's maxillo-mandibular relation with at least 22mm of restorative space as detected by tentative jaw relation. Cases with bone metabolic disorders or history of parafunctional habits as clenching or bruxism were excluded.

The scheduled treatment plan for all patients was to receive maxillary complete dentures against mandibular complete overdentures assisted by four splinted mini dental implants through the following steps:

D)-pre-surgical procedures:

1. Maxillary and mandibular master casts were obtained from secondary impressions of rubber base material (*Coltenespeedex, Switzerland*). For planning the future sites of the four mini implants, mandibular cast was fixed to the table of a milling machine for drilling four equidistant, linearly distributed and vertically parallel holes in the interforaminal region. The holes dimensions were identical to selected mini implants size (15mm length and 2.9 mm diameter) (*MDI System O-Ball implants.3M ESPE. United States*) (fig.1). Four mini implant analogues were secured in the drilled holes of the model (*MDI Hybrid Lab Analogue 2.9mm.3M ESPE. United States*) (fig.2).




Fig. (1) Drilling of four parallel holes in the interforaminal area of the cast corresponding to each implant site.

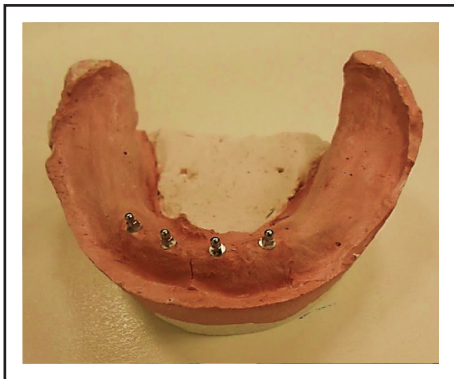

Fig. (2) Installed four mini implants analogues in the drilled holes of the cast.

2. Autopolymerized acrylic resin bar was milled on the four implants analogues while the cast was fixed to the milling machine. The bar was parallel walled and of 4mm height. Hygienic space of 1.5mm was preserved below the bar. Labial and lingual guiding planes of the bar were refined using a 4° tapered bur.
3. Duplicating impression of the mandibular model was made, while the fabricated acrylic bar was secured to the analogues, and poured in dental stone. To construct the maxillary complete denture and mandibular final overdenture, record blocks were fabricated on the maxillary

master cast and mandibular duplicate one for maxillomandibular relation record. The scheme of balanced lingualized occlusion was followed for arranging the acrylic resin artificial teeth. Dentures were flaked, finished and polished.

4. The milled acrylic bar was modified to act as a surgical guide for MDIs placement with respect to the preplanned implants positions as follows:
 - a- Four vertical parallel holes were drilled through the top surface of the bar opposite to each implant position using a 3mm diameter round bur on the milling machine
 - b- Residual alveolar ridge of the mandibular cast was covered with autopolymerized acrylic resin base that was connected to the acrylic bar. (fig.3).

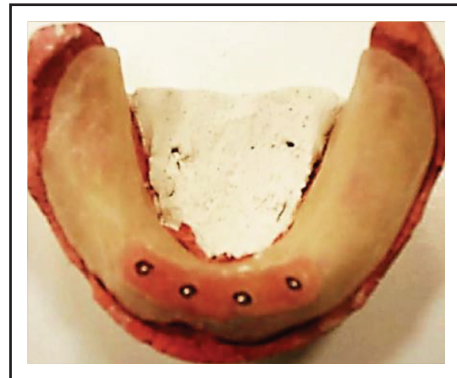

Fig. (3) Milled acrylic resin bar with four drilled holes corresponding to each implant site and added acrylic base.

II- Surgical procedures:

Placement of all implants was done under local anesthesia through one stage flapless implant placement protocol. After complete seating of the surgical guide template, tissue punch was used to cut 3mm circular soft tissues corresponding to each MDI location through the drilled holes of the acrylic bar (fig.4.a). Drilling was started using the pilot drill (1.1 mm diameter) in a pumping action under profuse irrigation. After perforation of crestal cortical bone, drilling was continued to about 3/4

the implant length. Drilling procedure was done completely through the surgical template to ensure parallelism of the four mini implants (fig.4.b). Finally torque ratchet wrench was used to drive the implant into its final position at 35N/cm torque) (fig.4.c,d). Mandibular denture fitting surface was relieved and tissue conditioning material was applied.

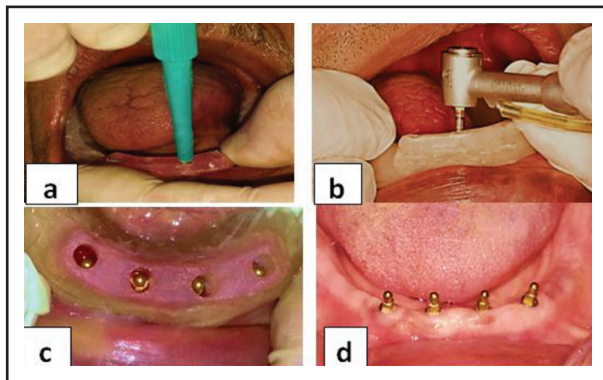


Fig. (4)

- Cutting of 3mm circular soft tissues corresponding to each MDI location using tissue punch.
- Drilling procedure was done completely through the surgical template.
- The four mini implants appear in their final positions through the guide template.
- Final placement was achieved where all blasted surfaces were engaged in bone at the appropriate level subgingivally

III-Patients grouping:

Random assigning of patients into two equal sized groups (10 patients each, with equal number of both sexes in each group) was done according to bar design used for splinting the mini implants. Milled bar was used for **Group I** and round bar joint for **Group II**.

IV- Prosthetic procedures:

- After one week of implant placement, O-Ball impression copings were directly snapped to the MDIs. A closed tray pick up impression technique was applied (fig.5). Mini implants lab analogs were pushed into the coping till observing a snap fit. The impression was poured into dental stone.

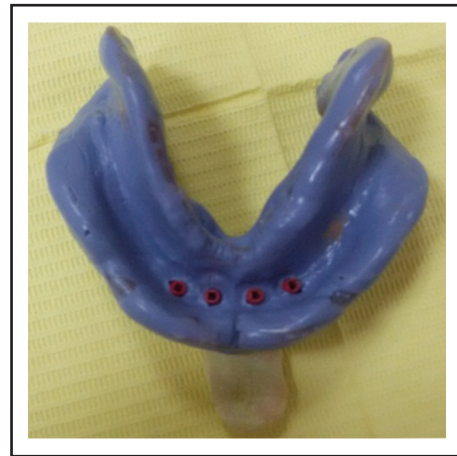

Fig. (5) Closed tray pick-up final impression with the four O-Ball impression copings.

2- Bar construction:

Milled bar fabrication for group I:

Scanning of the final model was done to produce a 3D virtual image of the four mini implants analogues and the underlying residual ridge (fig.6.a). The resin bar was sectioned from the surgical template and scanned (fig.6.b). The obtained bar 3D image was overlapped on that of the four MDIs maintaining a hygienic space of at least 1mm below the bar. Different bar aspects were manipulated with 3shapes cad system (*3-Shape dental system. TRIOS*) (fig.7). Final design of the virtual bar was transferred to the milling machine to be duplicated within a wax blank. The wax pattern was cast into cobalt chromium alloy and the bar was finished and polished.

Round-bar joint construction for group II:

Four virtual identical abutments (2mm thick) were designed to cover each implant abutment. Scanned image of the prefabricated round bar plastic pattern (*RHIN 83 OT BAR multi use*) was overlapped on the four virtual abutments to obtain the final bar design (fig.8). The same steps of milled bar construction was followed.

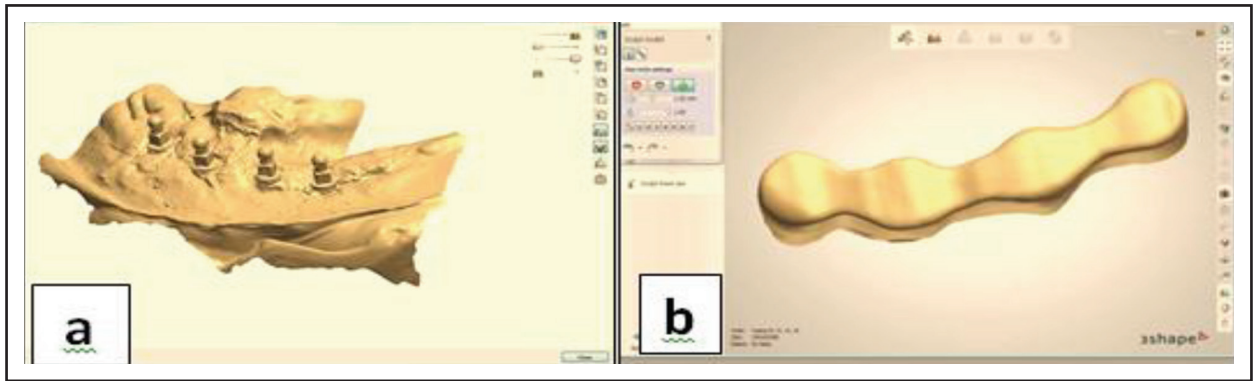


Fig. (6) **a:** 3D virtual image of the digitallly scanned master cast with the four MDI Lab Analogs. **b:** 3D virtual image of the digitallly scanned acrylic resin milled bar.

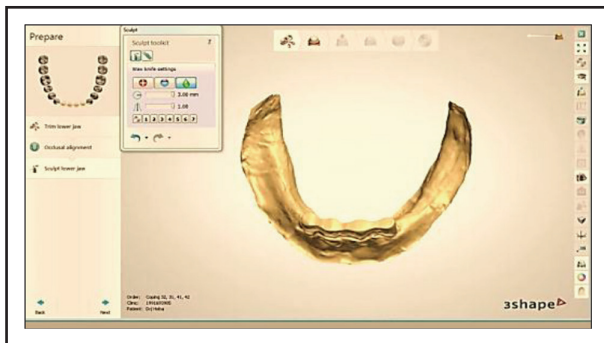

Fig. (7) Final software design of the milled bar.

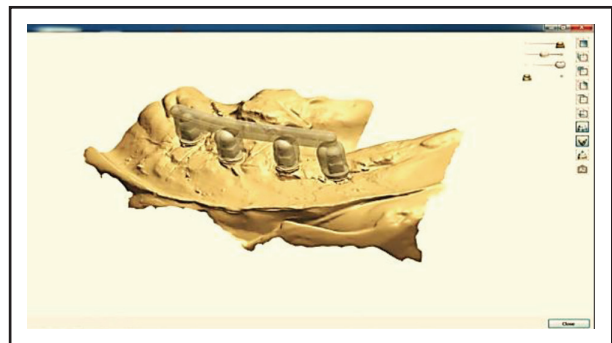

Fig. (8) Superimposed round bar virtual pattern on the four virtual abutments.

3- Retentive clips pick up procedure

Cementation of bars was done after two weeks of implants placement (fig 9.a,b). Passive fit of mandibular overdenture was tried using pressure indicating paste with repeated denture insertion and removal. When accepted passive fit was achieved, three retentive custom-made metal clips (for milled

bar) and ready-made plastic clips (for round bar) were picked up in the overdenture intaglio surface using autopolymerized acrylic resin under light closing force of the patient in centric occlusion (fig 10.a,b). The patients were instructed in oral hygiene control protocol and scheduled for regular follow-up visits.

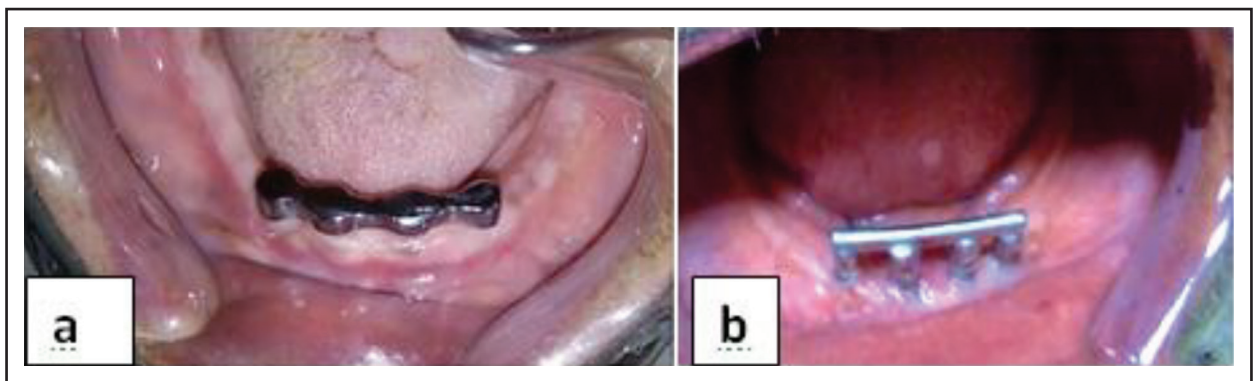


Fig. (9) **a:** Cemented finished and polished milled bar. **b:** Cemented finished and polished round bar.

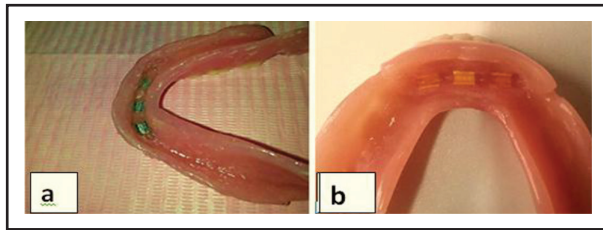


Fig. (10) Fitting surface of mandibular overdenture after picking-up of retentive clips of: (a) Milled bar. (b) Round bar

V- Clinical and radiographic evaluation:

Evaluation was done by the same examiner for each MDI at the beginning of implant loading (T_0), and 6 (T_6), 12 (T_{12}), 24 (T_{24}) and 36 (T_{36}) months later.

Clinical evaluation:

Recording of gingival index (GI)⁽²²⁾ and modified plaque index (PI)⁽²³⁾ was done. Probing pocket depth (PD) was measured from marginal gingival border to the tip of a calibrated plastic periodontal probe. GI, PI and PD were recorded at the four surfaces (buccal, lingual, mesial, and distal) of each MDI and mean values were calculated.

Radiographic evaluation:

Marginal bone loss (MBL):

A standardized periapical radiographs were taken using long-cone parallel technique and customized film holders to assess peri-implants marginal bone loss. The periapical films were conventionally processed and scanned. The radiographic images were digitized and magnified approximately 15X. Subsequently, reference points and lines were traced by Corel-draw program (*CORELDRAW, version IITM*). Implant length in the radiograph and actual implant length were compared to calculate magnification error and obtain the actual values of peri-implant bone measurements (fig.11.a). Bone height was measured in millimeters as the distance from point A (the implant neck) to point B (most coronal point of bone-implant contact) (fig.11.b).

Calculation of bone loss was done by subtracting bone levels at each follow-up period from that of (T_0). MBL was calculated at each implant proximal surfaces and the mean values were calculated.

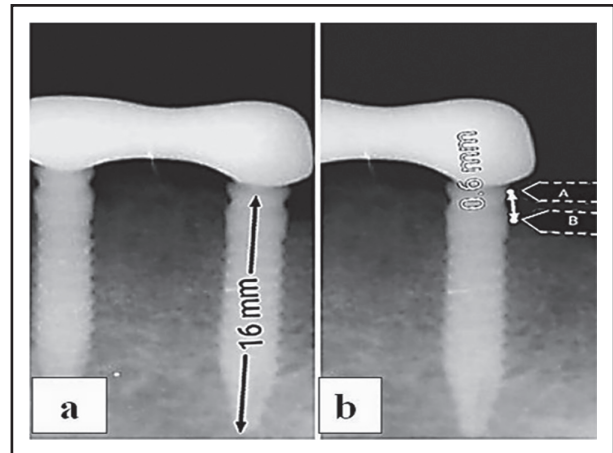


Fig. (11) **a:** Measuring implant length in the radiograph. **b:** Bone height measurement in millimeters as the distance from point A (the implant neck) to point B (most coronal point of bone-implant contact).

Statistical analysis:

Obtained data was analyzed by SPSS computer software (*Version 21 SPSS, Chicago. IL, USA*). Normal distribution of variable's data was evaluated using one sample Kolmogorov Smirnov test. Normally distributed continuous data (vertical bone loss) were described as (mean \pm standard deviation) while nonparametric continuous data (probing depth) and ordinal data (gingival and plaque scores) were described as (median and range). For vertical bone loss, unpaired sample *t*-test was applied to compare the two groups. Multivariate analysis (general linear model) was applied for comparison of all observational periods within each group, and paired sample *t*-test was applied for comparison of each two periods. For probing depth, gingival score and plaque score, the Mann-Whitney test was applied to compare both groups, Friedman-test was applied for comparison of all observational periods within each group, and Wilcoxon signed-rank test was applied for comparison of each two periods. (P) was significant if <0.05 at 95% confidence interval.

RESULTS

Descriptive statistics of peri-implant tissue health parameters regarding gingival index (GI), plaque index (PI) and periodontal depth (PD) of both groups at different observational periods are

presented in table (1). No statically significant difference of all parameters was observed over time in both groups according to (Freidman-test) where $P > 0.05$. At all observation times, insignificant changes were observed in GI, PI and PD between both groups (Mann-Whitney test, $P > 0.05$)

Table 1: Comparison of peri-implant tissue health parameters (gingival index, plaque index and periodontal depth) at different observational periods of both groups:

	T ₀	T ₆	T ₁₂	T ₂₄	T ₃₆	Freidman test P
Gingival index						
Group I /M(Min-Max)	0(0-1)	0(0-1)	0(0-1)	1(0-2)	1(0-2)	0.106
Group II /M(Min-Max)	0(0-0)	0(0-1)	0(0-1)	0(0-1)	1(0-1)	0.22
Mann-Whitney test (P)	0.071	0.492	0.307	0.410	0.609	
Plaque index						
Group I /M(Min-Max)	0(0-0)	0(0-1)	1(0-2)	1(0-2)	1(0-2)	0.06
Group II /M(Min-Max)	0(0-0)	0(0-1)	0(0-1)	1(0-2)	1(0-2)	0.08
Mann-Whitney test (P)	1.00	0.480	0.255	0.756	1.00	
Probing depth						
Group I /M(Min-Max)	1(0.5-1)	1(0.5-1.5)	1(1-1.5)	1(1-1.5)	1(1-2)	0.064
Group II /M(Min-Max)	1(0.5-1)	1(0.5-1)	1(0.5-1.5)	1(1-1.5)	1(1-1.5)	0.15
Mann-Whitney test (P)	1.00	0.57	0.59	1.00	0.552	

T₀: at the time of implants loading T₆: after 6 months of implants loading T₁₂: after 12 months of implants loading T₂₄: after 24 months of implants loading T₃₆: after 36 months of implants loading Min: Minimum Max: Maximum Group I: Milled bar Group II: Round bar joint.

Multiple comparisons by Wilcoxon signed rank test of GI, PI and PD between each two observational times within each group, showed insignificant difference as shown in table (2)

Table 2: Multiple comparisons of GI, PI and PD scores between different follow up periods for each group where each cell represent P value of Wilcoxon signed rank test:

	T ₀ -T ₆	T ₆ -T ₁₂	T ₁₂ -T ₂₄	T ₂₄ -T ₃₆
Gingival index				
Group I	1.00	0.317	0.157	1.00
Group II	0.083	1.00	0.20	0.80
Plaque index				
Group I	0.083	0.320	1.00	1.00
Group II	0.317	0.157	0.439	0.30
Probing depth				
Group I	0.37	0.31	1.00	0.180
Group II	1.00	0.35	0.33	1.00

T₀: at the time of implants loading T₆: after 6 months of implants loading T₁₂: after 12 months of implants loading T₂₄: after 24 months of implants loading T₃₆: after 36 months of implants loading Group I: Milled bar

Group II: Round bar joint.

Mean values of marginal bone loss (MBL) of both groups is presented in table (3) at different follow up periods. Increased bone loss was observed overtime with a tendency to be stabilized after 6 months of implants loading. MBL was significantly higher in group I (milled bar) in comparison to group II (rounded bar) at T₆, T₁₂ and T₃₆ (unpaired sample t test, P= 0.00, 0.004 and 0.01 respectively). While insignificant difference was found at T₂₄ (P= 0.09). General linear model (Multivariate analysis) showed significant marginal bone loss for both groups where P=0.001 for group I and 0.007 for group II.

Table 3: Mean values of vertical bone loss of both groups at different follow up periods:

	Group I (Mean ± SD)	Group II (Mean ± SD)	Unpaired t-test
T ₀	0	0	
T ₆	0.708± 0.021	0.524± 0.143	0.000*
T ₁₂	0.806± 0.417	0.657± 0.161	0.004*
T ₂₄	1.013± 0.205	0.779± 0.251	0.097
T ₃₆	1.25± 0.179	1.017± 0.421	0.004*
General linear model (P)	0.001*	0.007*	

T₀: at the time of implants loading

T₆: after 6 months of implants loading

T₁₂: after 12 months of implants loading

T₂₄: after 24months of implants loading

T₃₆: after 36months of implants loading

SD: Standard deviation

Group I: Milled bar

Group II: Round bar joint.

*: Significant difference

Multiple comparisons of marginal bone loss using paired sample T-test between each two observational times for both groups are showed in table (4). For group I, significant difference was found between T₀ and T₆ and also between T₂₄ and T₃₆, while significant difference was only found between T₀ and T₆ for group II according to paired sample T-test.

Table 4: Shows multiple comparisons of marginal bone loss between each two observational periods for both groups where each cell represent P value of Paired sample T-test:

	T ₀ -T ₆	T ₆ -T ₁₂	T ₁₂ -T ₂₄	T ₂₄ -T ₃₆
Group I	0.000*	0.356	0.075	0.003*
Group II	0.000*	0.079	0.077	0.065

T₀: at the time of implants loading

T₆: after 6 months of implants loading

T₁₂: after 12 months of implants loading

T₂₄: after 24months of implants loading

T₃₆: after 36months of implants loading

SD: Standard deviation

Group I: Milled bar

Group II: Round bar joint.

*: Significant difference

DISCUSSION

Four mini implants were used in this study to assist complete mandibular overdenture. Mini implants were inserted in the interforaminal area, equidistant and parallel to each other. Two different bar designs were applied for splinting mini implants, the rigidly anchored milled bar and the resilient round bar.

As an alternative to the routinely used two conventional implants to assist complete mandibular overdentures, four mini implants of maximum length (corresponding to height of mandibular anterior bone) were used to compensate their reduced diameter. The flapless surgical technique of mini implants placement was followed to maintain the blood supply and allow minimal disruption to periosteal and endosteal bone and preservation of peri-implant bone height after surgery^(24,25). The goal of splinting the four mini implants with bar attachment was to share the load on more osseointegrated surfaces and effectively distribute the applied forces⁽²⁶⁾.

No statically significant difference of all peri-implant soft tissue health parameters was observed in both groups over time and at different observation

periods between groups. This result is in agreement with a previous study that observed obvious insignificant difference of peri-implant soft tissue outcome between resilient prosthesis-anchorage designs and a rigid stabilization with milled bars. No negative affect on implants and peri-implant tissues was observed either by resilient anchorage or by rigid stabilization ⁽²⁷⁾.

Retrospective analysis of patients who received implant retained prostheses with different designs of bar attachment (one-piece anterior milled bars, prefabricated round bars, and two bilateral milled bars) was performed to evaluate the peri-implantitis prevalence. No significant difference was found between the different bar designs ⁽²⁸⁾. Moreover, insignificant difference of peri-implant tissue health parameters was reported between different bar designs (prefabricated bars and cast bars) after five to ten years of prosthetic loading ⁽²⁹⁾.

When the load magnitude is increased over the physiologic threshold of bone adaptation, bone-implant anchorage may be lost, compromising implant success. Implant failure over the long term is caused by ongoing marginal bone loss ^(30, 31). Therefore; measuring peri-implant marginal bone loss is one of the important outcome parameter in implant dentistry, and considered as an indication of implant success ⁽³²⁾.

In this study, the highest MBL mean values of both groups were observed in the first 6 months of implant loading after which the rate of bone resorption decreased until became stable. This finding is convenient to that of previous studies of mini implants ^(12,14,18) and also similar to that observed with conventional implants ⁽³³⁾. This can be attributed to bone remodeling which begins immediately after implant insertion and represents the active phase of bone changes.

Significant bone loss was found at T_{36} in comparison to T_0 for both groups, this may be caused by reduced mini implants diameter that was reported to increase stress concentration at the bone/implant

interface⁽³⁴⁻³⁸⁾. However, the observed cervical bone loss around MDIs used in this research was comparable to that documented for conventional implants, which ranged between 0.2 and 1.9 mm after the first year ⁽³⁹⁾.

Marginal bone resorption was significantly higher in group I (milled bar) in comparison to group II (rounded bar joint) at T_6 , T_{12} and T_{36} . Moreover, significant difference was found between T_0 and T_6 and also between T_{24} and T_{36} for group I, while significant difference was only found between T_0 and T_6 for group II. This result may be owing to the different design concept of the two used bar attachments. Resilient joint bars permit rotational movement of the overdenture base upon occlusal loading thus providing dual mucosa and implants support ⁽⁴⁰⁾. Using resilient bars showed significant decrease in peri-implant bone strain ⁽⁴¹⁾. In contrast, use of rigidly anchored milled bars prevents rotational movement of the prosthesis ^(42, 43). Precise fitting of the overdenture base to milled bars, obtained by accurate milling, provides effective stability and resistance to lateral and rotational forces ⁽⁴³⁻⁴⁵⁾. Rigid bar attachments allow distribution of load between the implants with no sharing of posterior residual ridges ⁽⁴⁵⁾.

This biomechanical behavior of these two different bar designs was also proved by a similar research that evaluated posterior ridges resorption generated by complete mandibular overdentures retained by four splinted mini implants with milled and round bars. It was concluded that milled bars appeared to be accompanied by less resorption of mandibular posterior alveolar ridges when compared to round bar joints. That finding was explained by the dual mucosa-implant support obtained by round bars that permit free vertical rotation of the prosthesis during function and transfer diverse loads to the posterior edentulous area, with minimal stresses applied to the implants ⁽¹⁹⁾.

CONCLUSION

Both milled and round bar splints can provide a satisfactory clinical outcome for early loaded mini implants assisting mandibular complete overdenture. However, splinting with milled bars seems to be associated with a higher rate of peri-implant marginal bone loss.

RECOMMENDATION

Further clinical and radiographic studies with longer follow up periods are still required.

ACKNOWLEDGMENT

The authors would like to express their deep appreciation to Prof. Ahmed Habib, Professor of Removable Prosthodontics, Faculty of Dentistry, Mansoura University for his encouragement, guidance and support to perform this work.

REFERENCES

- Misch K, Neiva R. :Small-diameter implants for optimal stabilization of implant-supported overdentures. *Pract Proced Aesthet Dent.* 2007;19: 428-431.
- Scarano A.: Small-diameter dental implants: An adjunct for retention, stability, and comfort for the edentulous patient. *J Osseointegr* 2012;3:48-50.
- Batisse C, Bonnet G, Bessadet M, Veyrune JL, Hennequin M, Peyron MA, Nicolas E :Stabilization of mandibular complete dentures by four mini implants: Impact on masticatory function, *Journal of Dentistry . J Dent.* 2016; 50:43-50.
- Cho Sc, Froum S, Tai CH, Cho YS, Elian N, Tarnow DP. : Immediate loading of narrow-diameter implants with overdentures in severely atrophic mandibles. *Pract Proced Aesthet Dent,* 2007;19:167-174.
- Christensen GJ. :The 'mini'-implant has arrived. *J Am Dent Assoc.* 2006;137: 387-390.
- Griffitts TM, Collins CP, Collins PC. : Mini dental implants: An adjunct for retention, stability and comfort for the edentulous patient. *Oral Surg Oral Med Oral Pathol Oral Radiol Endod.* 2005;100:80-84.
- Gregori M. Kurtzman; Douglas F. Dompkowski: Improving Mandibular Denture Retention with Sterngold ERA® Mini-Implants. *Inside Dent* 2008;4: 2-4.
- Sabet ME, Shawky AM ,Aly Ragab DA.: Evaluating the use of ERA Mini Dental Implants Retaining Mandibular Overdenture (In Vitro Study) . *Dentistry* 2014;4:1000197.
- Chun HJ, Park DN, Han CH, Heo SJ, Heo MS, et al. : Stress distributions in maxillary bone surrounding overdenture implants with different overdenture attachments. *J Oral Rehabil* 2005; 32: 193-205.
- Porter JA, Petropoulos VC, Brunski JB. :Comparison of Load Distribution for Implant Overdenture Attachments. *Int J Oral Maxillofac Implants* 2002;17: 651- 662.
- Christensen GJ. : The increased use of small-diameter implants. *J Am Dent Assoc.* 2009;140:709-712.
- Jofré J, Hamada T, Nishimura M, Klattenhoff C. The effect of maximum bite force on marginal bone loss of mini-implants supporting a mandibular overdenture: a randomized controlled trial. *Clin.Oral Impl. Res.* 21, 2010; 243-249.
- Elsayad M. A., Gebreel A. A., Fouad M. M. ,El Shoukoui A. H. : The clinical and radiographic outcome of immediately loaded mini implants supporting a mandibular overdenture. A 3-year prospective study. *Journal of Oral Rehabil* 2011 38; 827-834.
- Šćepanović M.,Todorović A., Marković A., Patnogić V., Miličić B., Moufti A., Mišić T. :Immediately loaded mini dental implants as overdenture retainers: 1-Year cohort study of implant stability and peri-implant marginal bone level. *Annals of Anatomy* 2015; 199: 85-91.
- Thomas R. Momeburg, Perter A. PrÖschel: Success rates of microimplants in edentulous patients with residual ridge resorption. *Int J Oral Maxillofac Implants* 2008; 23:270-276.
- Kanazawa M., Feine J., Esfandiari S. :Clinical guidelines and procedures for provision of mandibular overdentures on 4 mini-dental implants., *J Prosthet Dent.* 2017; 117:22-27.
- Eunjee L., Soo-Yeon S.: The influence of the number and the type of magnetic attachment on the retention of mandibular mini implant overdenture. *J Adv Prosthodont* 2017;9:14-21.
- Jofre J, Cendoya P, Munoz P: Effect of splinting mini-implants on marginal bone loss: a biomechanical model and clinical randomized study with mandibular overdentures *Int J Oral Maxillofac Implants* 2010;25:1137-1144.
- Nabil H, Emera R.M, Habib A, Abdel fadeel E: Joint versus milled-in bars splint for mini implant used to retain mandibular overdenture: A Study of Posterior Area Changes. *Mansoura J of Dentistry.* 2016;3:37-41.
- Shafie H., Obeid G.: Principles of attachment selection for implant-supported overdenture and their impact on surgical approaches. *Oral Maxillofac Surg* 2011;19: 1-36.

21. Al-Harbi S.: Implant supported milled bar mandibular overdenture with locator attachments: Clinical considerations and laboratory techniques. *Int Dentistry*. 2006;8:54-64.
22. Løe H, Silness J. Periodontal disease in pregnancy: Prevalence and severity. *Acta Odontol Scand*. 1963; 21: 532-551.
23. Mombelli A, Van Oosten MAC, Schürch E, Lang NP. The microbiota associated with successful or failing osseointegrated titanium implants. *Oral Microbiol Immunol*. 1987; 2: 145-151.
24. Bulard RA, Vance JB. Multi-clinic evaluation using mini dental implants for long-term denture stabilization: a preliminary biometric evaluation. *Compend Contin Educ Dent*. 2005;26:892-897.
25. Jeong SM, Choi BH, Li J, Kim HS, Ko CY, Jung JH et al. Flapless implant surgery: an experimental study. *Oral Surg Oral Med Oral Pathol Oral Radiol Endod*. 2007;104:24-28.
26. Gulizio MP, Agar JR, Kelly JR, Taylor TD.: Effect of implant angulation upon retention of overdenture attachments, *J Prosthodont*. 2005;14: 3-11.
27. Weinlander M, Piehslinger E, Krennmair G.: Removable implant-prosthetic rehabilitation of the edentulous mandible: five-year results of different prosthetic anchorage concepts. *Int J Oral Maxillofac Implants* . 2010;25:589-597.
28. Rinke S, Rasing H, Gersdorff N, Buegers R, Roediger M. Implant-supported overdentures with different bar designs: A retrospective evaluation after 5-19 years of clinical function. *J Adv Prosthodont*. 2015 ; 7: 338-343.
29. Lehmann KM1, Kämmerer PW, Karbach J, Scheller H, Al-Nawas B, Wagner W: Long-term effect of overdenture bar design on peri-implant tissues. *Int J Oral Maxillofac Implants*. 2013;28:1126-1131.
30. De Smet E., Van Steenberghe D, Quirynen M, Naert I. :The influence of plaque and/or excessive loading on marginal soft and hard tissue reactions around Brånemark implants: A review of literature and experience. *Int J Periodontics Restorative Dent*. 2001; 21: 381- 393.
31. Van Steenberghe D, Naert I, Jacobs R, Quirynen M.: Influence of inflammatory reactions vs occlusal loading on peri-implant marginal bone level. *Adv Dent Res* 1999; 13: 130-135.
32. Hermann, J.S, Schoolfield, J.D, Nummikoski, P.V, Buser, D, Schenk, R.K, Cochran, D.L : Crestal bone changes around titanium implants: a methodological study comparing linear radiographic with histometric measurements. *Int. J. Oral Maxillofac. Implants*. 2001 16, 475-485.
33. Weber HP, Buser D, Fiorellini JP, Williams RC. Radiographic evaluation of crestal bone levels adjacent to nonsubmerged titanium implants. *Clin Oral Implants Res* 1992; 3: 181-188.
34. Petrie CS, Williams JL: Comparative evaluation of implant designs: Influence of diameter, length, and taper on strains in the alveolar crest. A three-dimensional finite-element analysis. *Clin Oral Implants Res*. 2005;16:486-494.
35. Baggi L, Cappelloni I, Di Girolamo M, Maceri F, Vairo G.: The influence of implant diameter and length on stress distribution of osseointegrated implants related to crestal bone geometry: A three-dimensional finite element analysis. *J Prosthet Dent*. 2008;100:422-431.
36. Kong L, Sun Y, Hu K: Bivariate evaluation of cylinder implant diameter and length: A three-dimensional finite element analysis. *J Prosthodont* 2008;17:286-293.
37. Ding X, Liao SH, Zhu XH, Zhang XH, Zhang L : Effect of diameter and length on stress distribution of the alveolar crest around immediately loaded implants. *Clin Implant Dent Relat Res*. 2009;11:279-287.
38. Ding X, Zhu XH, Liao SH, Zhang XH, Chen H: Implant-bone interface stress distribution in immediately loaded implants of different diameters: A three-dimensional finite element analysis. *J Prosthodont* 2009;18: 393-402.
39. Gotfredsen K, Holm B: Implant-supported mandibular overdentures retained with ball or bar attachments: a randomized prospective 5-year study. *Int J of Prosthodontics* 2000 ;13: 125-130.
40. De Baat C, Cune MS, Carlsson GE: A survey of implant-retained superstructure types in the edentulous mandible in The Netherlands. *Ned Tijdschr Tandheelkd*. 2005; 10:363-367.
41. Mateus B Fernandes, Lourenco Correr-Sobrinho, Rafael Leonardo: The influence of clip material and cross sections of the bar framework associated with vertical misfit on stress distribution in implant-retained overdentures. *Int J Prosthodont* 2014;27:26-32.
42. Krennmair G, Krainhöfner M, Piehslinger E: Mandibular overdentures retained with a milled bar: A retrospective study. *Int J Oral Maxillofac Implants* 2007;22:987-994.
43. Galindo DF: The implant-supported milled-bar mandibular overdenture. *J Prosthodont* 2001;10:46-51
44. Brudvik JS, Chigurupati K. The milled implant bar: an alternative to spark erosion: *J Can Dent Assoc*. 2002; 68:485-488.
45. Hebel KS, Galindo D, Gajjar RC. Implant position record and implant position cast: minimizing errors, procedures and patient visits in the fabrication of the milled-bar prosthesis. *J Prosthet Dent*. 2000; 83:107-116.