

Review

An introduction to understanding elevation-based topography: how elevation data are displayed – a review

Michael W Belin MD and Stephen S Khachikian MD
Albany Medical College, Albany, New York, USA

ABSTRACT

The increased frequency of refractive surgery and the shift towards the correction of higher-order aberrations necessitates a more detailed understanding of corneal shape. Early topography systems were based on Placido technology, as this was initially more intuitive for the general refractive surgeon. Newer computerized corneal modelling has increased our knowledge beyond what was previously possible. Elevation-based systems utilize a direct triangulation technique to measure the corneal surface. Elevation-based Scheimpflug imaging has advantages in that it allows for the measurement of both the anterior and posterior corneal surfaces. Posterior measurements are often the first indicators of future ectatic disease, in spite of completely normal anterior curvature. Examination of the posterior corneal surface can often reveal pathology that would otherwise be missed if one was relying on anterior analysis alone. Although there is little disagreement in diagnosing clinically evident keratoconus, agreement on what constitutes 'form fruste' or preclinical keratoconus remains elusive. The ability of elevation-based topography to analyse both anterior and posterior corneal surfaces adds significantly to our ability to identify eyes believed to be 'at risk'. As more knowledge is gained, it is appreciated that a full understanding of the workings of the human eye requires knowledge obtained from more than just one surface.

Key words: corneal topography, ectasia, keratoconus.

INTRODUCTION

If you were to give a spectacle lens to an ophthalmologist and asked for a description of the properties of the lens, he/she would likely put it into a lensometer and tell you the

power of the lens. If you gave the same lens to an optician or optical engineer and asked for a description of the lens, you would likely get a reading of the anterior and posterior curvature with a Geneva lens clock, a measurement of the lens centre thickness, overall diameter, the location of the optical centre, a description of how the shape transitions from the centre to the periphery and the lens material.

Both descriptions are correct, but one is more detailed. The ophthalmologist's reading of the single power of the lens (in air) is optically correct but tells us very little about how the lens actually performs. The optician's description was actually devoid of any power description. By knowing the physical properties supplied by the Optician, however, you could reconstruct the lens and compute the lens power. There are an infinite variety of lenses that can be constructed with the same optical power. If you wanted to duplicate the lens, the single power reading is insufficient. Often forgotten is that characteristics such as anterior lens curvature and centre thickness do affect how the lens actually performs when placed on the patient. Do you ever wonder why some patients come in with the same prescription in two pairs of glasses (e.g. I just got a second pair of glasses.), but complain that one is better than the other. Anterior lens curvature and centre thickness affects image magnification. The location of the optical centre affects induced prism. These are all items we need to take into account (but rarely do).

Experienced contact lens fitters are familiar with the difference between power, shape, size and thickness. Contact lenses are typically described by posterior curvature (whether in dioptres or radius of curvature in *mm*), the lens diameter and the lens power (e.g. 44.0 D/9.6 mm/ – 3.50). The actual power of the contact on each individual eye, however, may vary greatly from eye to eye. We know that the effective power of the contact will change depending on the shape of the underlying cornea. A 3.50-D contact will have a different effective power on a flat cornea than it would

■ Correspondence: Dr Michael W Belin, Albany Medical College – Ophthalmology, 156 Thornberry Lane Rensselaer, Albany, NY 12144, USA.

Email: mwbelin@aol.com

Received 17 January 2008, accepted 6 June 2008.

Statement of any conflict or commercial interest: Dr Belin serves as a consultant to OCULUS.

© 2008 The Authors

Journal compilation © 2008 Royal Australian and New Zealand College of Ophthalmologists

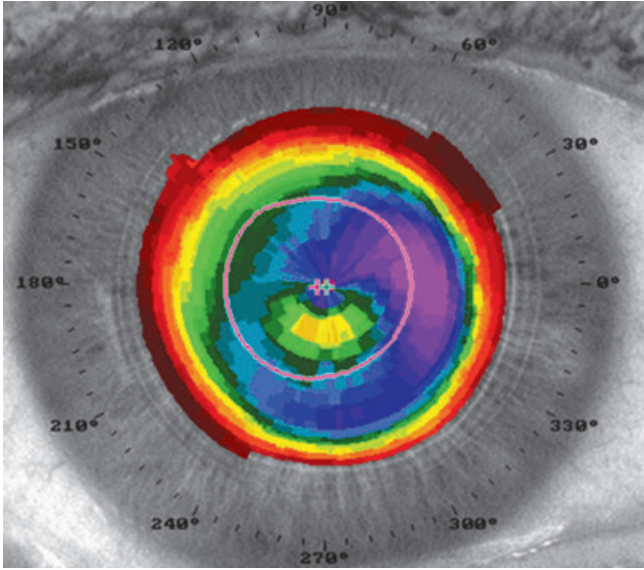


Figure 1. The image above shows the typical corneal coverage of a Placido map (TechnoMed C-Scan). Placido topographers only gather curvature data from the central 8 mm to 9 mm of the cornea. This limited coverage can exclude many peripheral corneal abnormalities.

on a steeper cornea. Additionally, even if you were to keep the 'power' of the contact constant, you could change its effective power by altering its base curvature. This is the concept of lens vault. We should know that if we alter one physical property (e.g. base curve) we often have to make a compensatory adjustment in another (e.g. power). The relationship between physical properties and optical properties here is well understood.

When we drive to the office most of us looked at our speedometers. In older cars, speed is determined by the rotation of the tires. There is a simple gear/cable mechanism that measures the rate of tire rotation. Most people do not know that if you changed the size of your tires or even went from summer to winter tires you could affect your speedometer's accuracy. The speedometer was still just as precise in measuring what it was meant to measure (how fast the tires are rotating), it is just that our assumptions (the size of the tires) that is wrong. Newer cars come with GPS navigation (Global Positioning System). GPS uses a series of orbiting satellites and triangulation to determine where you are at any instant in the Earth. The process of triangulation is amazingly accurate, and standard personal GPS devices have an accuracy of about 10 feet (e.g. It can tell which side of the road you are on.). GPS devices can also give us the speed that our vehicle

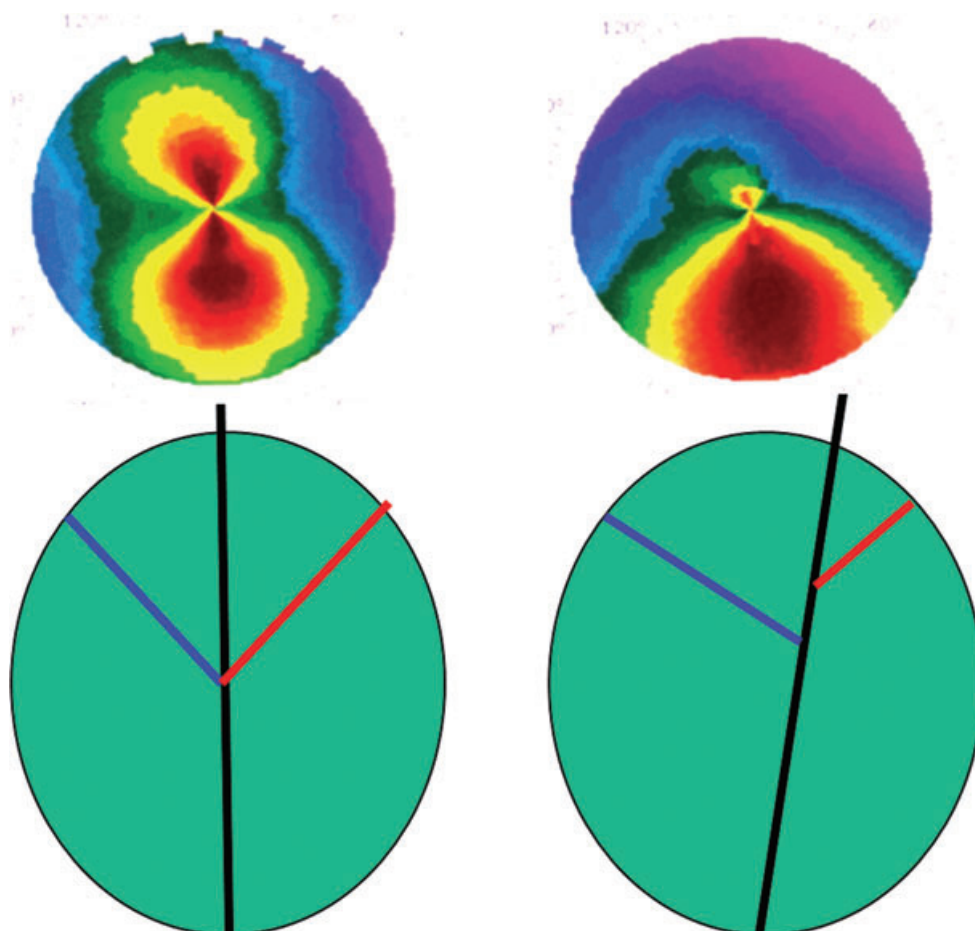


Figure 2. Representation of corneal axial curvature analysis. A change in the reference axis can create different axial curvature maps from the same shape. The map on the left appears as a 'normal' symmetric astigmatism. The map on the right appears 'abnormal' with a highly asymmetric bowtie pattern. Both images, however, were generated from the same astigmatic test object.

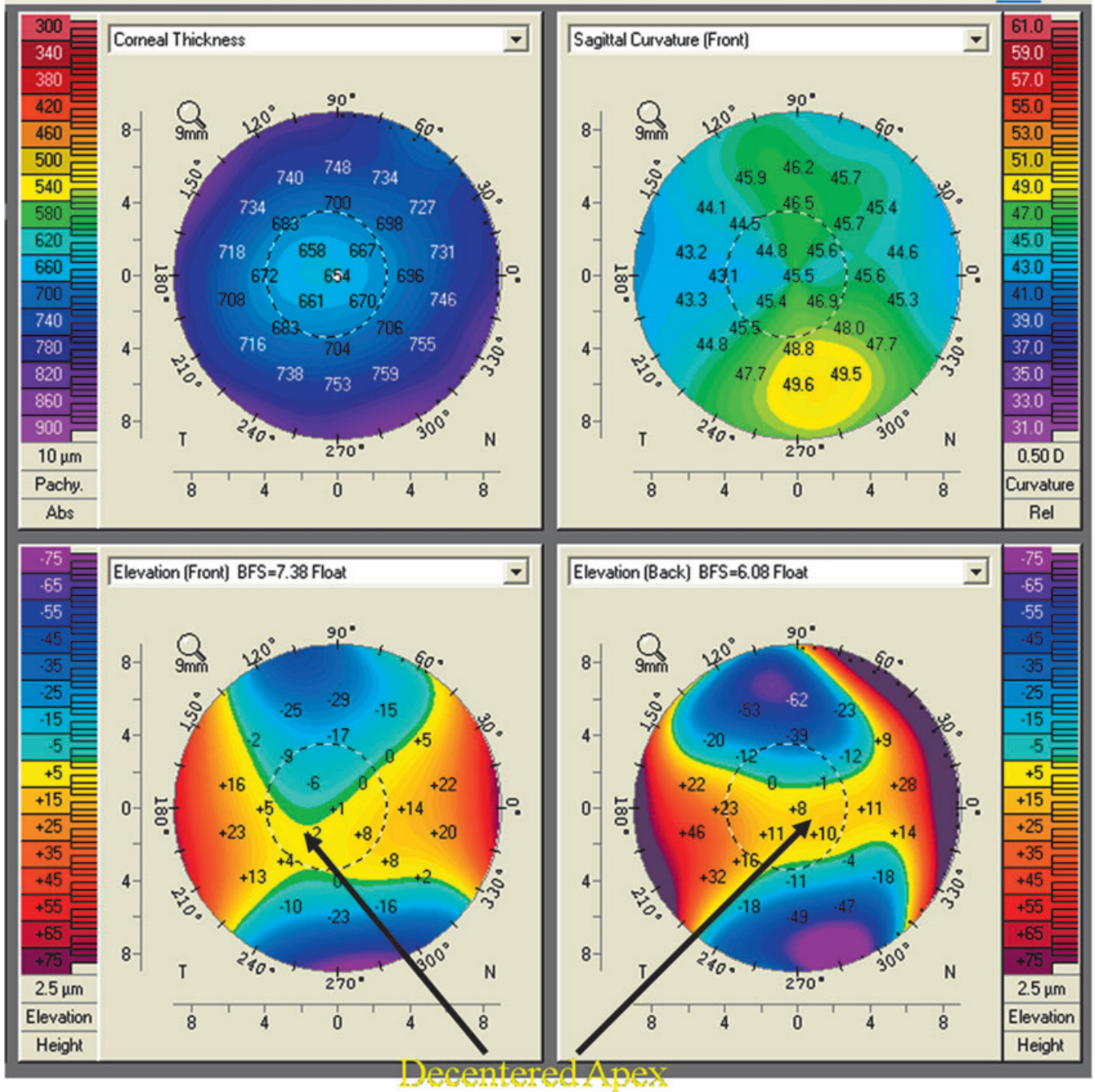


Figure 3. A four-image composite map of a normal astigmatic cornea (Oculus Pentacam). The asymmetric bowtie pattern seen in the curvature map (upper right) is created by a normal astigmatic cornea when the corneal apex and the reference axis do not coincide. The anterior elevation subtraction map shows that the apex of the cornea is slightly displaced but the elevation pattern is normal.

is travelling. There are no physical connections to the car, no measurement of the tires and no knowledge of how fast the tires are rotating. What is known, however, is where you are at any instant. If you know your location in space over time, you can easily compute the speed of the vehicle. We can obtain the same information from the GPS device that we get from the speedometer. The difference is that the speedometer makes certain assumptions (e.g. tire size, etc.), and the

GPS device makes no such assumptions. It does not really care about these properties. It simply knows where you are and where you were. With that information it can compute speed, acceleration, direction and location. In other words, if it knows where you are at every instant, it can compute almost every parameter that you would want. No matter how accurate your speedometer is, it can never give you a location. Our brains, however, are used to thinking in speed.

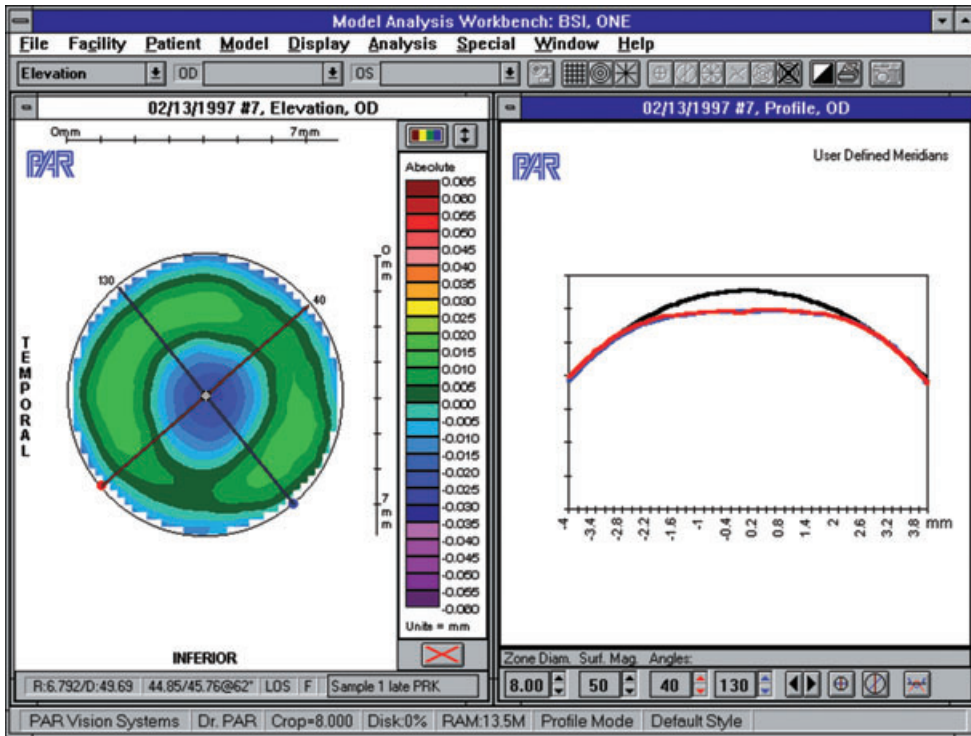


Figure 4. Elevation subtraction & profile map (PAR Technology CTS). The map on the left is a standard subtraction map showing central corneal flattening post PRK. The image on the right is an elevation profile of the principle meridians (red, blue) as compared with a more spherical profile.

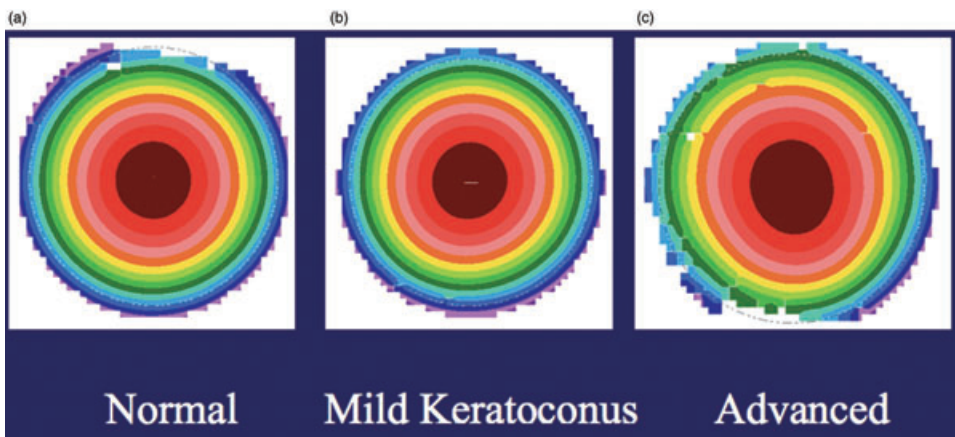


Figure 5. Raw elevation maps generated by using data from a normal cornea (a), a mild cone (b) and an advanced cone (c) (PAR Technology CTS). A side by side comparison of the raw elevation maps from three different corneas shows that adequate qualitative comparison is not possible without comparing the data with an appropriate reference surface.

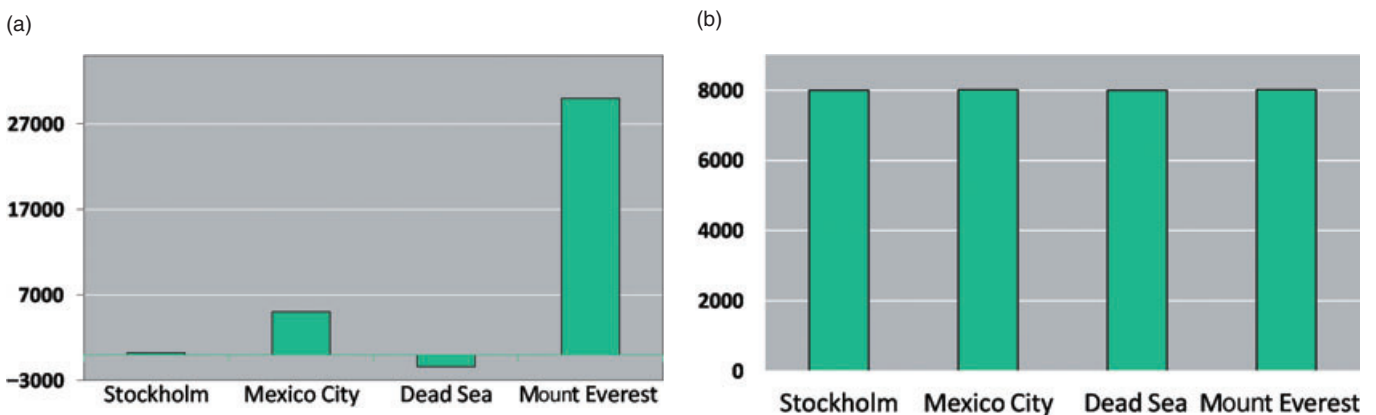


Figure 6. Elevation bar graphs. The graphs above show elevation data for the same four points on the Earth's surface. (a) The graph uses sea level as the reference surface and allows the observer to clearly see the elevation differences between the four locations. (b) When using a different reference surface (the centre of the Earth) the elevation differences cannot be detected by visual inspection.

Figure 7. Side by side comparison of effect of different elevation reference surfaces (Oculus Pentacam). The elevation subtraction map shows corneal elevation data from a patient with advanced keratoconus as compared with a best-fit-sphere (a). The cone and associated area of elevation can clearly be seen. (b) shows the same elevation subtraction data by using a toric ellipsoid as a reference surface. While the area of the cone is still visible, it is muted by the use of a suboptimal reference surface.

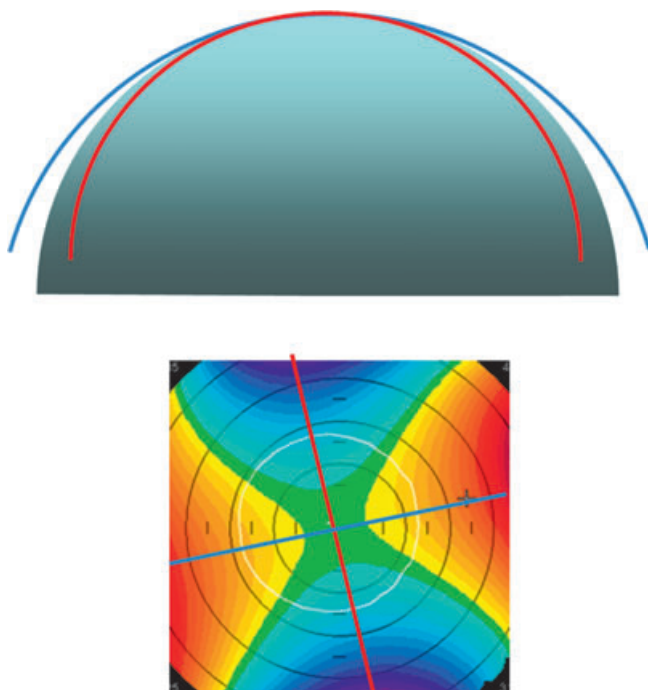
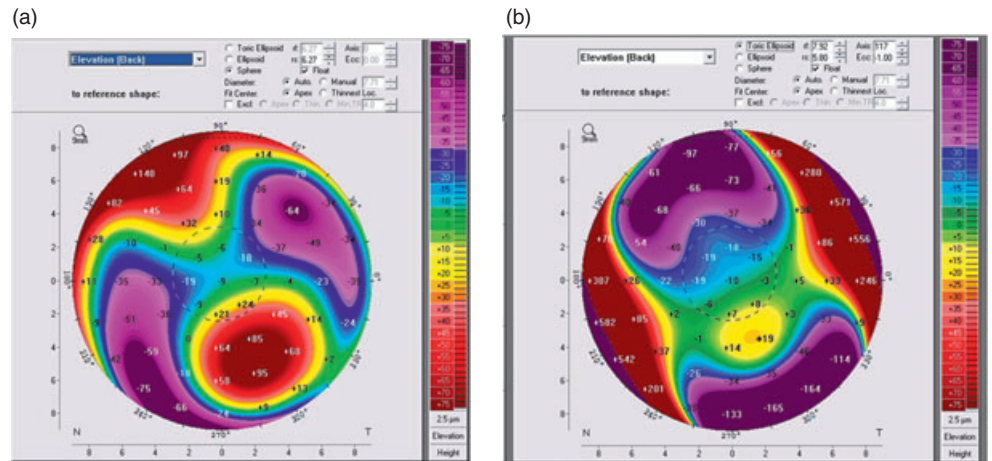


Figure 8. The figure above depicts elevation data of a cornea with regular astigmatism. The upper image shows the flat and steep meridians as compared with a best-fit-sphere in profile view. The steep meridian (red) is below the best-fit-sphere, and the flatter meridian (blue) falls above the best-fit-sphere. The elevation subtraction map below shows the flatter meridian elevated above the best-fit-sphere (warm colours) and the steeper meridian below the best-fit-sphere (cool colours)

The next time you are pulled over for speeding, you are unlikely to hear the officer say 'Do you know where you were 30 seconds ago?'

What do any of these examples have to do with elevation topography? They all demonstrate the disparity between routine measurements and the physical properties of the object being measured. Eventually, we hope to show you

how this relates to the differences between measuring the corneal curvature and measuring its elevation.

The term corneal 'topography' is, for the most part, a misnomer. True topography implies knowledge of the exact contour or shape. Most corneal topographical systems are Placido-based, analysing rings that are reflected off the corneal surface. The term 'videokeratoscope' more accurately reflects the technology of these instruments. These systems measure the angle of reflection and compute curvature as its first derivative. As with the power description of the spectacle lens discussed above, a curvature description alone does not allow us to reconstruct the corneal shape. Two homes may have both been built on flat land (i.e. same curvature), but if one was 5 feet below sea level and the other 10 feet above (different elevations), their 'performance' through a severe hurricane would probably be dramatically different. There is a reason why topographic maps of the Earth are elevation based and not curvature based.

BACKGROUND

In 1619, Father Christopher Scheiner observed that shiny glass spheres of different radii reflected images of different sizes. He then produced a series of progressively larger spheres and made efforts to determine corneal curvature by matching the size of the image of a window frame reflected from a subject's cornea with that produced by one of the calibrated spheres.¹ Ramsden later added a magnification system and also introduced a doubling device, in which the examiner matches the corneal reflection to itself. The first true keratometer was described in 1854 by Herman Van Helmholtz and was later improved upon by Javal, Schiøtz and others.² The ability of the keratometer to measure the corneal radius of curvature is based on the ability of the anterior corneal surface to behave like a convex mirror and reflect light. The accuracy of the keratometer is conditional on the uniformity of the central corneal curvature over the area measured because only one circular image is reflected.^{3,4} Keratometry, however, provides no information about areas central or peripheral to the points measured.

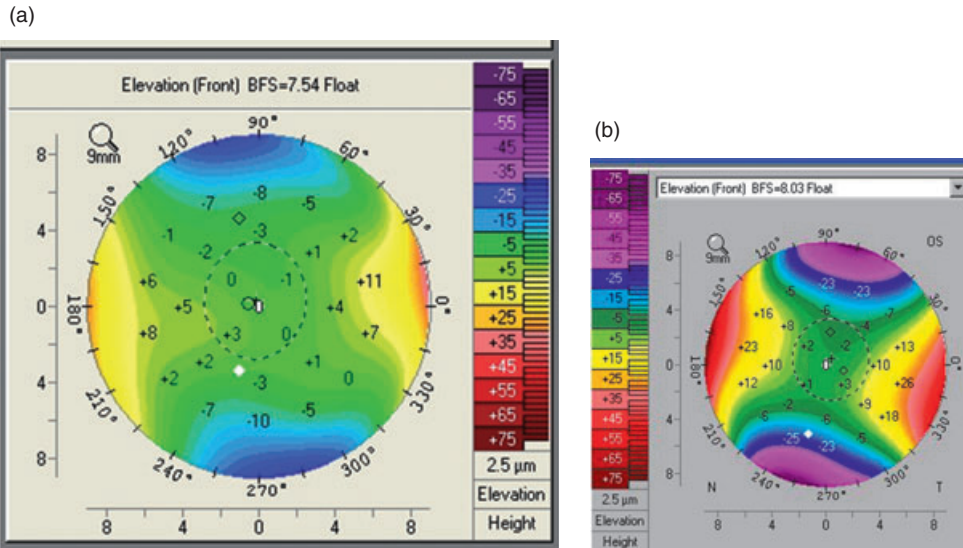


Figure 9. The figures above show how different amounts of astigmatism are seen in elevation subtraction maps. The elevation subtraction map in (a) shows little deviation from the best-fit-sphere in the periphery, with the elevation difference along the principle meridians increasing. (b) also shows the elevation difference along the principle meridians increasing in the periphery, but by a significantly greater degree (Oculus Pentacam).

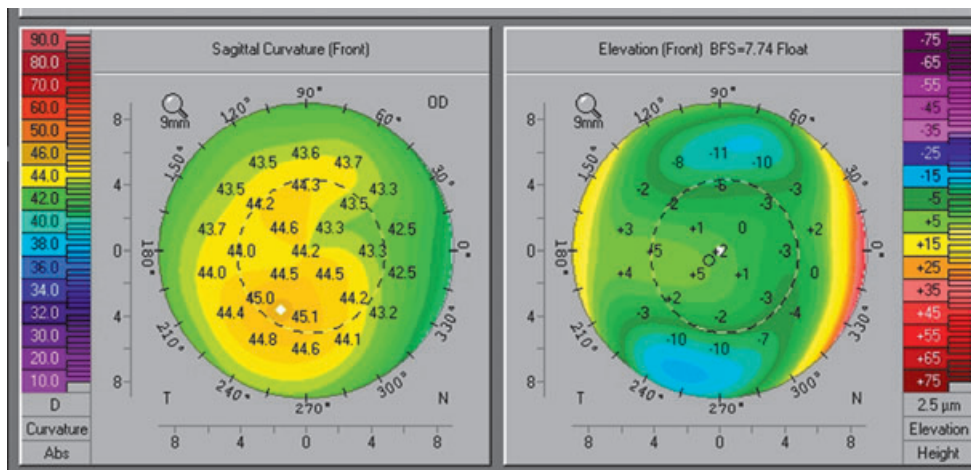


Figure 10. The map (Oculus Pentacam) depicts very mild irregular astigmatism seen on both the anterior curvature and the anterior elevation subtraction map. Although each astigmatic axis can be identified, the principal meridians are not orthogonal (90° apart).

KERATOSCOPY

Efforts to obtain more complete qualitative information about the shape of the cornea led to the development of keratoscopic imaging modalities. Whereas the keratometer only analyses approximately 6% of the corneal surface, keratoscopy can evaluate about 60% of the total corneal area (limited by the optics of the reflecting system itself). Cuignet first described the technique of keratoscopy in the 1820s.⁵ Henry Goode described the first keratoscope in 1847.⁶ Antonio Placido was the first to photograph the corneal reflections of a series of illuminated concentric rings in the 1880s. In 1896, Gullstrand was the first to quantitatively analyse photo-keratoscopic images of the cornea.⁷

When the rings of the target are located in the same plane, the instrument is referred to as a flat-target keratoscope. Collimating keratoscopes place rings in different planes along the interior of a column and in this way are able to maximize the amount of corneal surface that can

reflect the target mires.⁸ Most modern corneal topography instruments are of the collimating variety. In general, the reflective mires will appear closer together on steeper parts of the cornea and farther apart in flatter areas. Corneal astigmatism will show up as an ellipse with the major axis of the ellipse corresponding to the flat meridian and the minor axis the steep meridian. A limitation of this technique is that only relatively large amounts of astigmatism are grossly visible. If distortion is only minor it is not likely to be visible by this relatively crude modality. It is generally accepted that astigmatism of at least 3 D must be present to be detected by traditional keratoscopy.⁹ The major advantage of keratoscopy over keratometry is that it provides information from a larger portion of the corneal surface and provides permanent photographic documentation.

VIDEOKERATOSCOPY

Although the keratometer provided limited quantitative information and keratoscopy provided qualitative

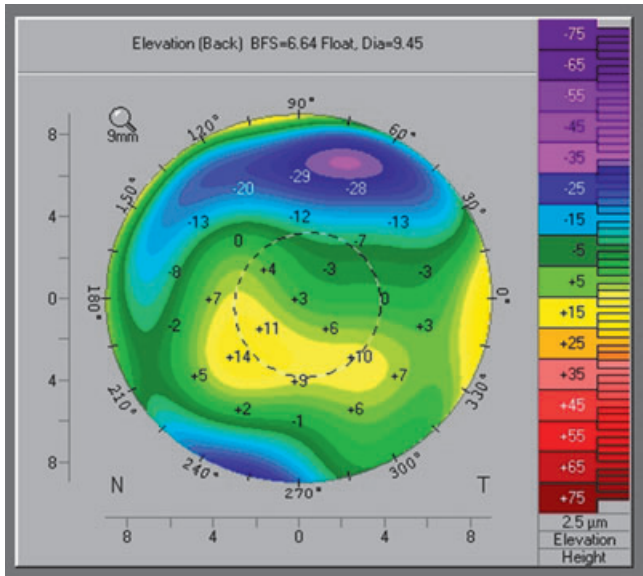


Figure 11. The elevation subtraction map reveals an irregularly irregular cornea where the principle meridians are difficult to identify (Oculus Pentacam).

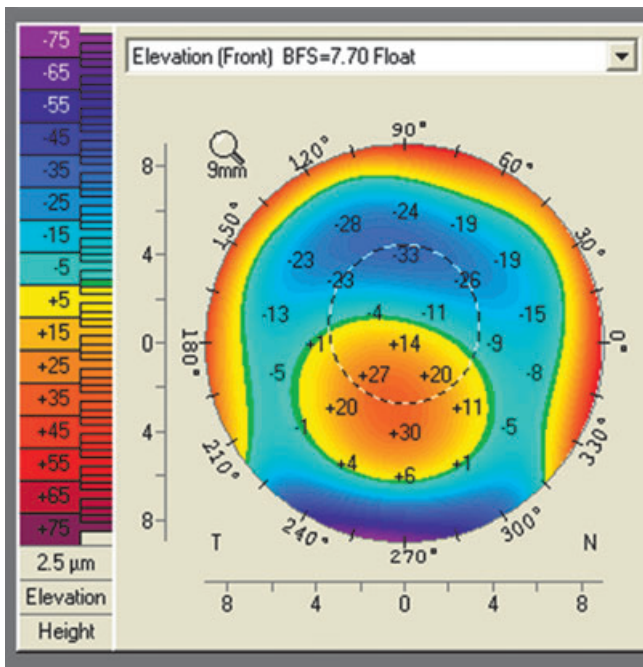


Figure 12. Anterior elevation subtraction map of a patient with keratoconus. The central island of elevation is clearly visible, and it corresponds to the location of the cone. The degree of elevation off the best-fit-sphere corresponds to the severity of the disease when compared with a standardized reference surface (e.g. sphere based on central 8-mm zone) (Oculus Pentacam).

information, it was the union of rapid computer analysis and image processing by Klyce in 1984 that transformed the gross keratoscopic examination of the cornea into the high-speed world of digital imaging.¹⁰ Computerized

videokeratoscopes are capable of digitizing information from thousands of points on the corneal surface to produce detailed colour-coded maps depicting corneal curvature. Since its introduction, videokeratoscopy has become an increasingly important tool for assessing anterior corneal curvature.

CURVATURE LIMITATIONS

There are, however, significant limitations in trying to describe the cornea with a curvature map. First, there are the physical limitations of a Placido-based, reflecting type system:

- 1 The area of corneal coverage is limited to about 60% of the corneal surface eliminating important data for many peripheral or para-central pathologies (i.e. pellucid marginal degeneration, keratoconus).¹¹ (Fig. 1: 60%)
- 2 There is no information about the posterior corneal surface. It is believed that many ectatic disorders may present with changes on the posterior surface before changes can be seen on the anterior corneal surface. At the recent American Society of Cataract and Refractive Surgery Meeting (2008, Chicago), changes on the posterior corneal surface were shown in 88% (22/25) of contralateral eyes of patients previously diagnosed with unilateral keratoconus by standard Rabinowitz criteria. (Salomao M, Ambrosio R Jr. *Corneal Tomographic Study of Contralateral Normal Eyes of Patients with Very Asymmetric [‘Unilateral’] Keratoconus.*)
- 3 Without measurement of the anterior and posterior surfaces, pachymetric maps depicting the distribution of corneal thickness cannot be made.

Additionally, there are limitations in attempting to reconstruct the corneal surface based on curvature measurements (similar to the measurement of the spectacle lens in the INTRODUCTION).¹² The standard topographic curvature (axial or sagittal curvature) is a referenced based measurement. It is not a unique property of the cornea. The same shape can have many different ‘curvatures’ depending on which axis is used to make the measurement (Fig. 2: reference axis bowtie). Most of us visualize the eye as a Gullstrand-reduced eye, assuming that the eye is symmetric, with the line of sight, visual axis, centre of pupil and corneal apex all crossing at a common point. This, however, is not the case.^{3,4} More so, we assume that the measurement axis of the Placido system also coincides. Most people do not look through the centre of their cornea. The line of sight and the measurement axis of the videokeratoscope are not the same.^{13,14} The infant with pseudo-strabismus demonstrates these principals. The infant looks as though their eyes are not straight (their line of sight does not go through the corneal apex), but when you perform a cross-cover test, the eyes are straight. When you perform a Hirschberg test, however, the reflected light appears displaced. This is because a reflected image (same as in a Placido videokerato-

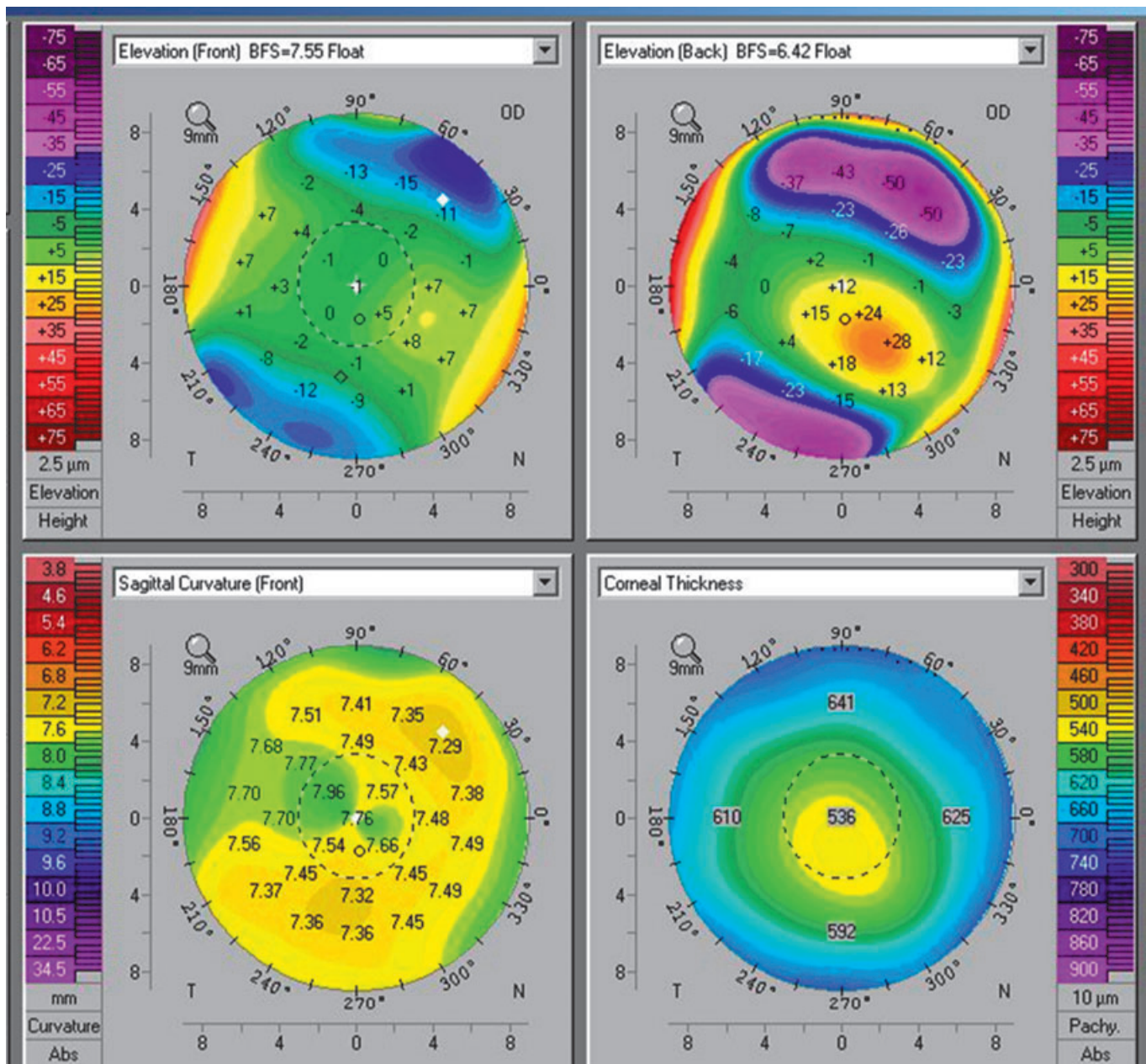


Figure 13. An Oculus Pentacam-generated four-view composite map with anterior and posterior elevation subtraction maps, sagittal curvature and pachymetry shown. In spite of a normal anterior surface (both elevation and curvature) the posterior elevation subtraction and pachymetric maps demonstrate an early ectatic change.

scope) needs to align normal to the corneal surface. When the apex and the line of sight differ, the reflected image appears abnormal (in the adult imaged on a Placido videokeratoscope this would appear as an asymmetric bowtie) (Fig. 3: asymmetric bowtie), but the eye is physically normal. This is the problem with trying to reconstruct shape from a curvature measurement. There are other methods of depicting curvature (i.e. instantaneous or local) that obviate some, but not all, of the above limitations. Sagittal (axial) curvature, however, remains the most commonly used.

ELEVATION-BASED TOPOGRAPHY

True topographic imaging implies shape and requires the generation of an X, Y and Z coordinate system. The first commercially available elevation-based system was the PAR Corneal Topography System (PAR CTS) (PAR Technology, New Hartford, NY). The PAR CTS used a stereo-triangulation technique to make direct measurements of the corneal surface. The PAR CTS used a grid pattern composed of horizontal and vertical lines projected onto the anterior

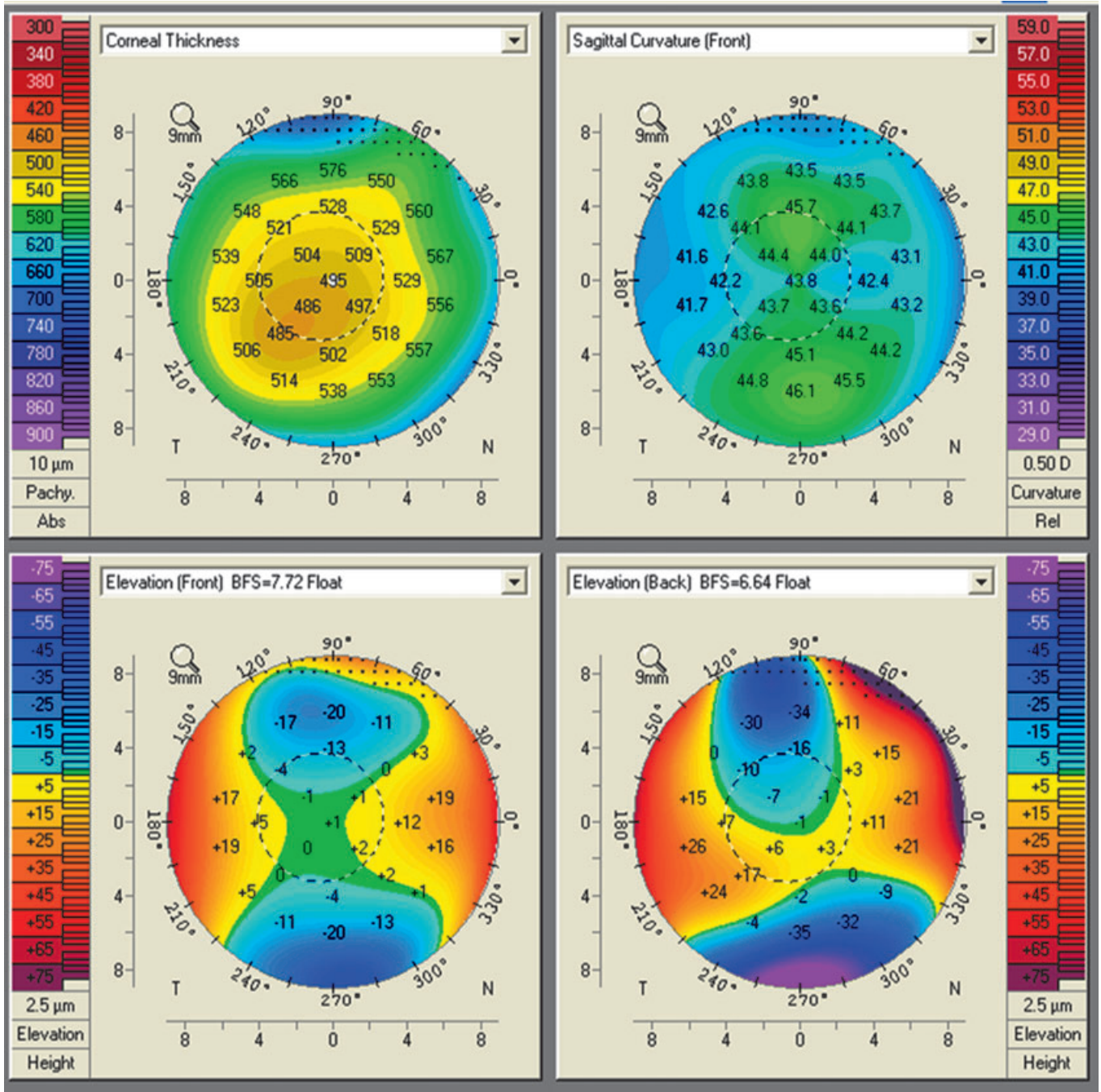


Figure 14. The four-view composite map (Oculus Pentacam) shows an asymptomatic patient presenting for refractive surgical evaluation. Although there are no obvious abnormalities in the curvature or elevation maps the large displacement of the thinnest point from the corneal apex may suggest early ectatic disease.

corneal surface. In order to visualize the grid, the PAR system required a small amount of fluorescein placed in the tear film. From the known geometry of the grid projection and imaging system's optical paths, rays can be intersected in three-D space to compute the X, Y and Z coordinates of the surface.¹⁵ Because the system projected a pattern onto the cornea it was limited to measuring only the anterior corneal surface, as in all Placido-based reflective systems. While, the

system is no longer commercially available, it was the first system to utilize elevation data in a clinically useful form and had documented accuracy at least twofold greater than Placido-based systems at that time.¹⁶

The first elevation system with the capability to measure both the anterior and posterior corneal surfaces utilized a scanning-slit technique of optical cross sectioning. Measuring both corneal surfaces potentially offered diagnostic

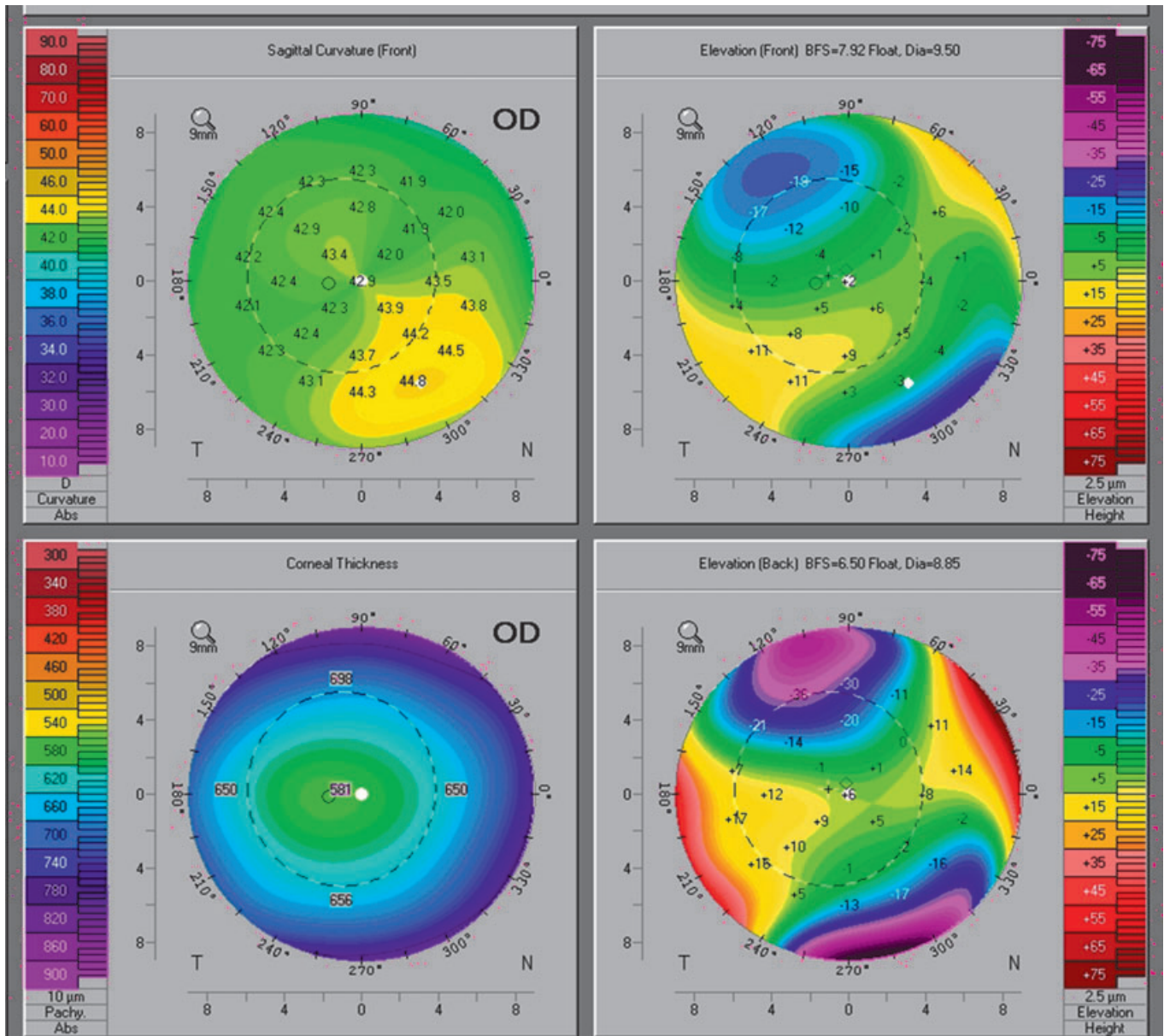


Figure 15. A four-image composite map (Oculus Pentacam) of a normal astigmatic cornea. The asymmetric bowtie pattern seen in the curvature map is created when the reference axis and the corneal apex do not coincide. The anterior elevation subtraction map shows that the apex of the cornea is displaced inferiorly, but the elevation and pachymetry are both normal.

advantages and allowed the computation of a pachymetry map (as corneal thickness is the difference between the anterior and posterior surfaces). Numerous articles have since outlined the limitations of this device, particularly in locating the posterior corneal surface and the underestimation of corneal thickness after refractive surgery.^{17–25}

Currently three systems use a form of optical cross sectioning to triangulate both the anterior and the posterior corneal surfaces. These systems are the Bausch & Lomb Orbscan (Bausch & Lomb, Rochester, NY), which utilizes scanning-slit technology and the Oculus Pentacam (OCULUS Optikgerate GmbH, Wetzlar, Germany) and the Ziemer Galilei (Port, Switzerland), which utilizes rotating Scheimpflug imaging.

The rotating Scheimpflug technique does not appear to suffer from the same limitations as the scanning-slit device with regard to post refractive measurements.^{26–32}

Although differences exist between the systems they all display elevation data in the fashion that was first with the PAR CTS in 1990 (Fig. 4: PAR elevation). Typically, the clinician views elevation data not in its raw form (actual elevation data) but compared with some reference shape. The maps typically display how the actual corneal elevation data compares (deviates) with this known shape. The reason for this is to magnify the differences and allow the clinician a qualitative map that will highlight clinically significant areas. The method of depicting the elevation data and the

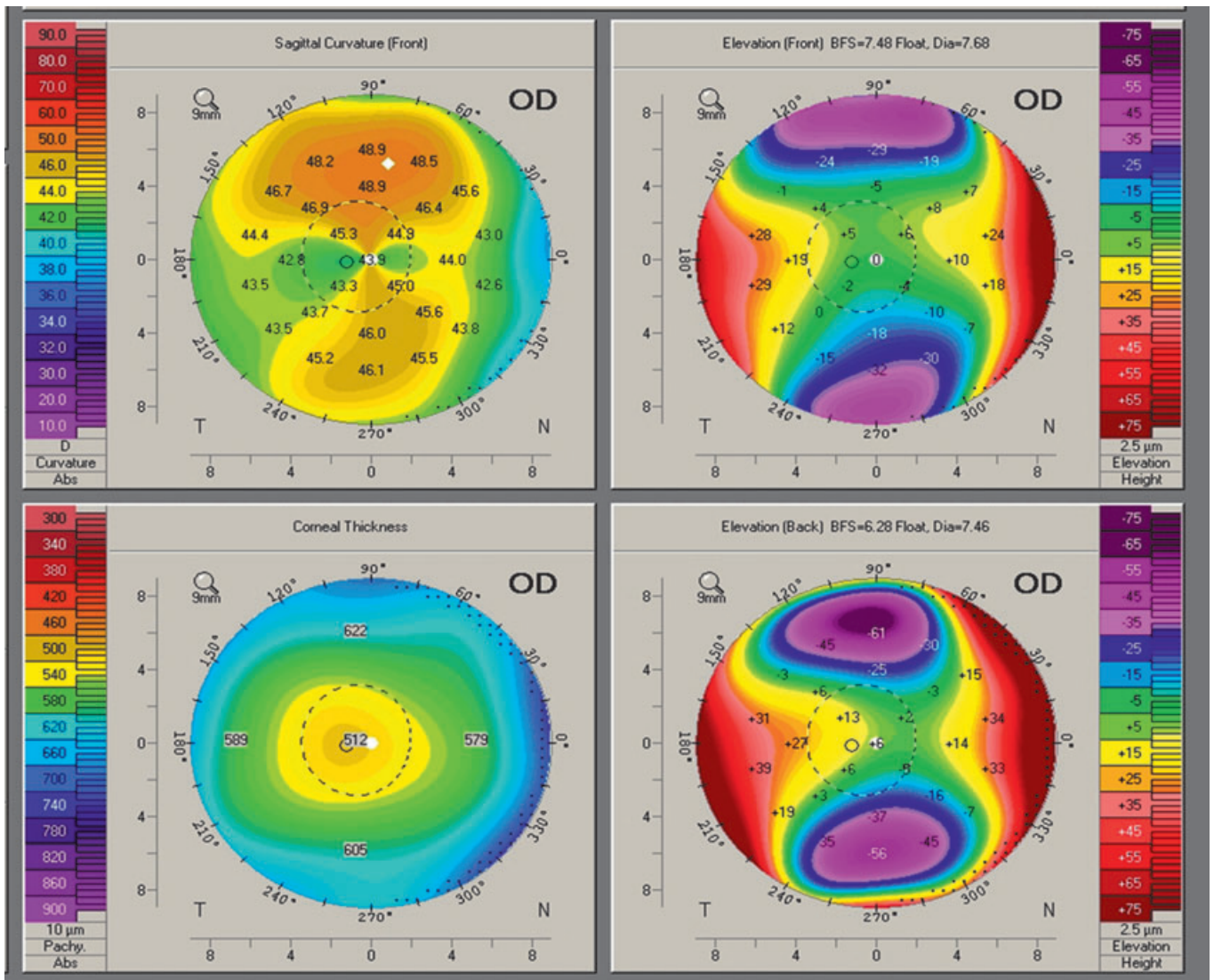


Figure 16. A four-image composite map of a normal astigmatic cornea (Oculus Pentacam). The asymmetric bowtie pattern seen in the curvature map is created when the reference axis and the corneal apex do not coincide. The anterior elevation subtraction map shows that the apex of the cornea is displaced superiorly, but the elevation is normal.

reference shapes commonly used (best-fit-sphere [BFS], best-fit-ellipse and the best-fit-toric ellipsoid) were first introduced by MW Belin in 1990 (University of Rochester Annual Eye Meeting, Rochester, NY 1990) on the PAR CTS. The reason for viewing elevation data in this format is that the actual raw elevation data lacks qualitative patterns that would allow the clinician to easily separate normal from abnormal corneas (Fig. 5: raw composite). In other words, raw elevation data for normal eyes look surprisingly similar to the raw elevation data in abnormal eyes (e.g. keratoconus). This is not an uncommon approach. When one wants to highlight an abnormality, you typically attempt to remove the 'background noise'. In the case of elevation data, the 'background' noise is any shape that will help demonstrate the clinically significant abnormalities. This is similar to looking at a topographic map of the Earth. The most commonly used refer-

ence surface is a sphere at sea level. Cartographers choose sea level because it was intuitive (easy for the user to comprehend), but also because it conveyed useful information in a fashion that was quantitatively useful. Maps could be redrawn by using the centre of the Earth as a reference point (as opposed to sea level). The maps would be just as accurate. The information would be just as valid. The reader of the map, however, would have a hard time differentiating Mount Everest from the Dead Sea. The height difference between the top of Mount Everest and the bottom of the Dead Sea is the same regardless of whether you use 'sea level' or the 'centre of the Earth' as the reference. To a computer the difference looks the same (slightly over 5 miles), but to the observer's eye the difference between 8000 and 8005 miles (using the centre of the Earth) is not discernible (Fig. 6: graphs). It is the same with depicting elevation maps of

the corneal surface (the terms 'Elevation Maps' while ingrained are incorrect. A better term would be an 'Elevation Subtraction Map' because we do not look at the actual elevation data, but only the data after subtracting out some reference shape). As with the maps of the Earth, the accuracy of the maps is not dependent upon the reference surface. It does not matter what surface is removed. The elevation difference between two corresponding points of the cornea (as with Mount Everest and the Dead Sea) remains the same. The reference surface affects the qualitative appearance, but not a quantitative one. As with the topographic map of the Earth, the key is to choose a reference surface that best demonstrates the clinical abnormalities you are looking for.

For refractive surgery screening and for most clinical situations using a BFS gives the most useful qualitative map (i.e. easiest to read and understand). Fitting a BFS to the central 8 to 9-mm zone appears best, as this provides adequate data points and most users should be able to obtain maps without extrapolated data out to this zone. Because the normal eye is an aspherical prolate surface the central 8- to 9-mm zone yields a reference surface that allows for subtle identification of both ectatic disorders and astigmatism. Larger zones would typically yield a flatter BFS and smaller zones a steeper BFS. Although other shapes may have some clinical utility, shapes that more closely approximate a cone (e.g. toric ellipsoid) will actually mask the cone as the best-fit-toric ellipsoid more closely matches the cone contour. It should be noted that for study purposes or when comparing elevation changes over time it can be beneficial to fix the BFS radius so that it is the same across all exams. For screening purposes, however, this is not necessary (Fig. 7: sphere *vs* toric ellipsoid).

SAMPLES ELEVATION SUBTRACTION MAPS

By definition, an astigmatic surface is one that has two meridians of different curvature. When these principal meridians are orthogonal (90° apart) the surface is said to be regular. Regular astigmatism shows a classic pattern where the flat meridian is raised off the BFS and the steep meridian is below (or depressed) the BFS (Fig. 8: schematic astigmatism). The larger the astigmatism the greater the difference between corresponding points on the principal meridians. Additionally, the further you go out from the centre the greater the deviation from the BFS (Fig. 9: sample astigmatism low & high).

Irregular astigmatism is by definition where the principal meridians are non-orthogonal. This is readily apparent in the standard elevation subtraction map. Mild changes may still be associated with good best spectacle corrected vision (BSCVA), but larger amounts of irregular astigmatism are typically associated with a reduction in BSCVA (Fig. 10: sample mild irregular astigmatism). In this example, fitting a toric ellipsoid has some clinical utility. Although the BFS is still best for screening, a toric ellipsoid can mimic what is correctable by spectacles (both sphere and cylinder) and

differences from the toric ellipsoid should correlate to the reduction in BSCVA (this is effectively what some have called an irregularity map).

Irregularly irregular corneas are so distorted that the principal meridians can often not be identified. These corneas are almost always pathologic, associated with a significant reduction in BSCVA and may be seen in conditions such as keratoconus, anterior dystrophies and corneal scarring (Fig. 11: sample irregularly irregular astigmatism).

An ectasia is a protrusion of the corneal surface. These can occur on the anterior corneal surface, the posterior surface or both. In keratoconus, when a BFS is fit to a cone the apex of the cone appears as a circular area of positive deviation off the BFS ('island'). This pattern ('island') is distinct from the positive elevations seen on the flat meridian of an astigmatic eye. The purpose of utilizing the reference surface is to allow for qualitative separation of normal and abnormal corneas. The magnitude (height) of the island corresponds to the degree of elevation off the more normal cornea. The size of the base of the island corresponds to the extent of the cornea involved in the ectatic process. The location of the 'island' more clearly demonstrates the location of the cone (See CONE LOCATION) (Fig. 12: sample island).

The above patterns can be seen on both anterior and posterior surfaces. It should be realized that because the posterior surface contributes minimally to the overall refractive power of the cornea, changes on the posterior corneal surface may not cause visual complaints. It is not uncommon to see an astigmatic pattern on the posterior surface but a relatively spherical anterior cornea. Additionally, early ectatic changes may be seen solely on the posterior cornea (e.g. keratoconus or post-LASIK ectasia) prior to any changes on the anterior corneal surface. These patients have abnormal corneas in spite of excellent BSCVA. The posterior corneal surface may serve as an earlier indicator of ectatic changes than the anterior corneal surface (Fig. 13: sample isolated posterior).

Although not an elevation map, the pachymetric map represents the spatial difference between the anterior and posterior corneal surface and in as such is totally dependent on accurate elevation data. In addition to identifying thin corneas, the overall pachymetric distribution may be another indicator of pathology. Normal corneas are typically thinnest in the central region and thicken in the periphery. Displacement of the thinnest region is often seen in keratoconus and may at times predate changes on either the anterior or posterior surfaces (Fig. 14: sample isolated pachymetric displacement).

DISPLACED APEX SYNDROME

Earlier we discussed some of the limitations of trying to use curvature to depict true shape. Early studies reported an incidence of 'form fruste' keratoconus or 'keratoconus suspect' as high as 17% of patients seeking refractive surgery.³³ Certain investigators initially pointed out that this high false-positive rate was related to the limitations

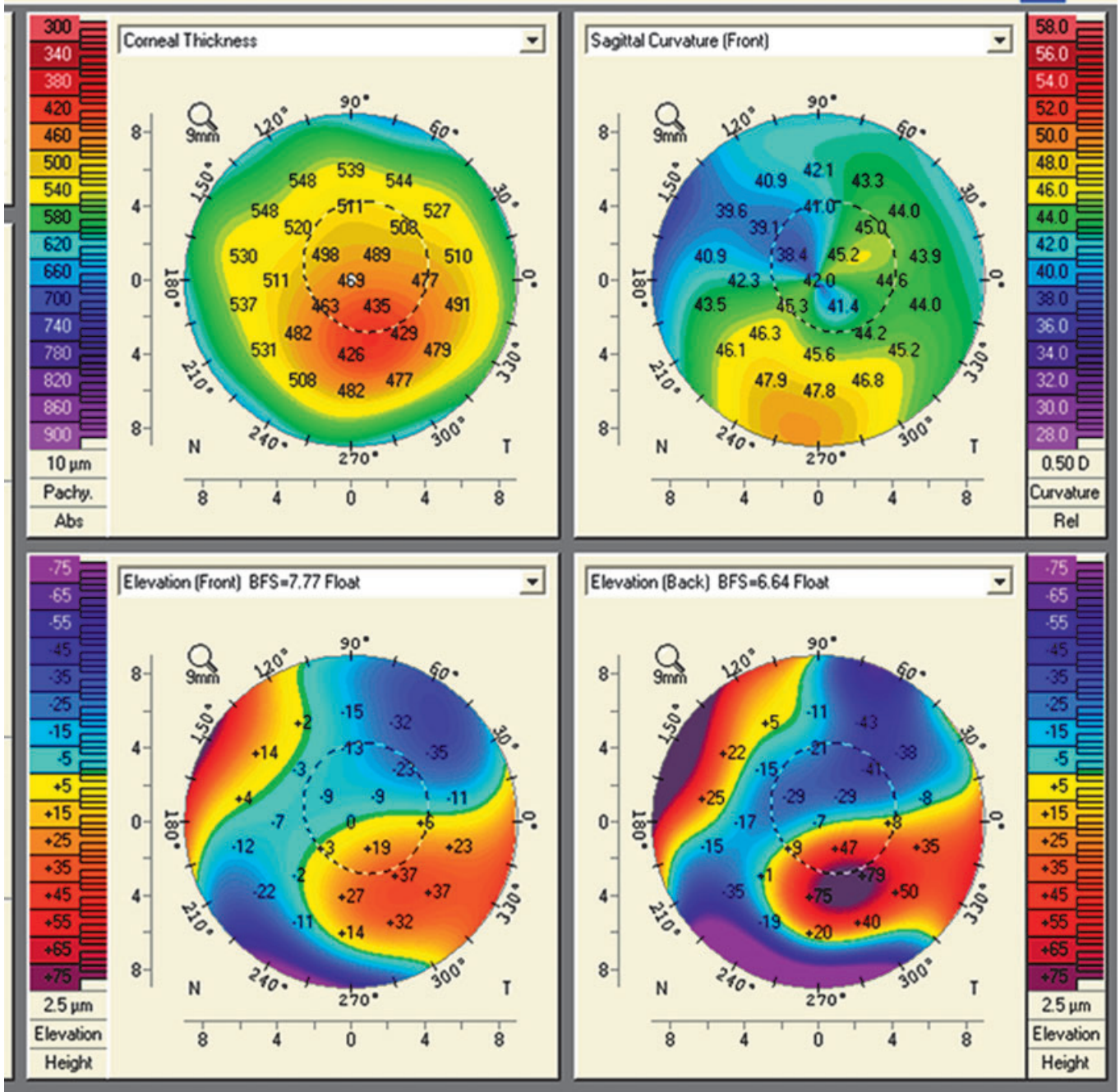


Figure 17. A four-image composite map of a patient with keratoconus (Oculus Pentacam). The curvature map (upper right) does not accurately reflect the location of the pathology. The elevation (anterior and posterior subtraction) and pachymetry maps are able to more accurately localize the cone.

of sagittal- or axial-based curvature reconstructions and Placido-derived topography systems.^{11,34} Curvature maps on asymmetric corneas are prone to pattern errors because of the difference between the curvature map's reference axis, the line of sight and the corneal apex.^{3,4} Many of these so-called keratoconus patients have what is now recognized as a displaced corneal apex (commonly inferior).³⁵ These patients demonstrate an elevated I-S ratio (i.e. inferior corneal axial power >1.5 D steeper than the comparable

superior corneal region). However, they have no other clinical or topographic aspects of keratoconus. These patients have a more normal topography pattern when imaged on an elevation-based topography system and commonly do not meet the keratoconus criteria of some of the newer keratoconus detection subprograms (Fig. 15: sample displaced apex) (Fig. 16: sample displaced apex superior). The classic asymmetric inferior bowtie pattern can be produced by a completely normal astigmatic eye if the curvature's reference

axis does not go through the corneal apex (see Fig. 2) (In actuality what more typically occurs is that the patient does not look through the centre of their cornea, the so-called positive angle kappa). Patients with a displaced apex syndrome typically have normal pachymetry, orthogonal astigmatism, stable refractions and BSCVA of 20/20 or better.³⁵ Many patients in the literature who have been described as having early keratoconus based solely on curvature maps (and reported to have excellent results from refractive surgery) have instead *what is more likely* a 'displaced apex syndrome' and *would probably* not meet the criteria for keratoconus on elevation topography.^{36–38}

CONE LOCATION

Similar to the above discussion, sagittal or axial curvature maps are poor indicators of the location of the cone in keratoconus and commonly exaggerate its peripheral appearance. Both anterior elevation subtraction maps, posterior elevation subtraction maps and pachymetric maps more accurately locate the true cone position. The recent increase in diagnosing pellucid marginal degeneration is, at least in part, because of a reliance on trying to use a curvature map to depict shape (Fig. 17: sample faulty location). It should be understood the limitations on axial or sagittal curvature are the same limitations whether the maps are Placido generated or elevation generated. The limitations are not with the machine or the technology. They are innate limitations in that type of curvature measurement.

SUMMARY

Elevation-based topography offers important advances over Placido-based devices. The ability to image the posterior cornea and to produce an accurate pachymetric map is itself significant. Elevation subtraction maps are also more accurate in determining the cone morphology and in separating the false-positive keratoconus suspect often because of a displaced corneal apex. Accurate imaging of both the anterior and posterior corneal surfaces should improve both the surgeons' and clinicians' armamentarium.

REFERENCES

1. Miller D, Greiner JV. Corneal measurements and tests. In: Albert DM, Jakobiec FA, eds. *Principles and Practice of Ophthalmology*. Philadelphia, PA: W.B. Saunders Company, 1994; 7.
2. Dabiezies OH, Holladay JT. Measurement of corneal curvature: keratometer (ophthalmometer). In: Kastle PR, ed. *Contact Lenses: The CLAO Guide to Basic Science and Clinical Practice*, Vol. 1. Dubuque, IA: Kendall/Hunt Publishing Company, 1995; 253–89.
3. Arffa RC, Klyce SD, Busin M. Keratometry in refractive surgery. *J Refract Surg* 1986; 2: 6.
4. Rubin ML. *Optics for Clinicians*. Gainesville, FL: Triad Publishing Company, 1993.
5. Brody J, Waller S, Wagoner M. Corneal topography: history, technique and clinical uses. *Int Ophthalmol Clin* 1994; 34: 97–207.
6. Levine JR. The true inventors of the keratoscope and photokeratoscope. *Br J Hist Sci* 1965; 2: 324–41.
7. Brody J, Waller S, Wagoner M. Corneal topography: history, technique and clinical uses. *Int Ophthalmol Clin* 1994; 34: 197–207.
8. Maquire LJ. Keratometry, photokeratoscopy and computer-assisted topographic analysis. In: Krachmer JH, Mannis MJ, Holland EJ, eds. *Cornea – Fundamentals of Cornea and External Disease*. St. Louis, MS: Mosby, 1997; 223–35.
9. Wilson SE, Klyce SD. Advances in the analysis of corneal topography. *Surv Ophthalmol* 1991; 35: 269–77.
10. Klyce SD. Computer-assisted corneal topography. High-resolution graphic presentation and analysis of keratoscopy. *Invest Ophthalmol Vis Sci* 1984; 25: 1426–35.
11. Committee on Ophthalmic Procedures Assessment Cornea Panel, Cohen EJ (Chair). Corneal Topography. *Ophthalmology* 1999; 106: 1628–38.
12. Belin MW, Zloty P. Accuracy of the PAR Corneal Topography System with spatial misalignment. *CLAO J* 1993; 19: 64–8.
13. Mandell RB. The enigma of the corneal contour. *CLAO J* 1992; 18: 267–73.
14. Arffa RC, Warnicki JW, Rehkopf PG. Corneal topography using rasterstereography. *Refract Corneal Surg* 1989; 5: 414–17.
15. Belin MW, Litoff D, Strods SJ, Winn SS, Smith RS. The PAR Technology Corneal Topography System. *Refract Corneal Surg* 1992; 8: 88–96.
16. Schultze RL. Accuracy of corneal elevation with four corneal topography systems. *J Refract Surg* 1998; 14: 100–4.
17. Cairns G, Ormonde SE, Gray T *et al*. Assessing the accuracy of Orbscan II post-LASIK: apparent keratectasia is paradoxically associated with anterior chamber depth reduction in successful procedures. *Clin Experiment Ophthalmol* 2005; 33: 147–52.
18. Cairns G, McGhee CN. Orbscan computerized topography: attributes, applications, and limitations. *J Cataract Refract Surg* 2005; 31: 205–20.
19. Hashemi H, Mehravaran S. Corneal changes after laser refractive surgery for myopia: comparison of Orbscan II and Pentacam findings. *J Cataract Refract Surg* 2007; 33: 841–7.
20. Prisant O, Calderon N, Chastang P *et al*. Reliability of pachymetric measurements using orbscan after excimer refractive surgery. *Ophthalmology* 2003; 110: 511–15.
21. Kamiya K, Oshika T, Amano S, Takahashi T, Tokunaga T, Miyata K. Influence of excimer laser photorefractive keratectomy on the posterior corneal surface. *J Cataract Refract Surg* 2000; 26: 867–71.
22. Naroo SA, Charman WN. Changes in posterior corneal curvature after photorefractive keratectomy. *J Cataract Refract Surg* 2000; 26: 872–8.
23. Seitz B, Torres F, Langenbucher A, Behrens A, Suárez E. Posterior corneal curvature changes after myopic laser in situ keratomileusis. *Ophthalmology* 2001; 108: 666–72.
24. Wang Z, Chen J, Yang B. Posterior corneal surface topographic changes after laser in situ keratomileusis are related to residual corneal bed thickness. *Ophthalmology* 1999; 106: 406–9.
25. Baek T, Lee K, Kagaya F, Tomidokoro A, Amano S, Oshika T. Factors affecting the forward shift of posterior corneal surface

- after laser in situ keratomileusis. *Ophthalmology* 2001; **108**: 317–20.
26. Ciolino JB, Belin MW. Changes in the posterior cornea after laser in situ keratomileusis and photorefractive keratectomy. *J Cataract Refract Surg* 2006; **32**: 1426–31.
 27. Buehl W, Stojanac D, Sacu S, Drexler W, Findl O. Comparison of three methods of measuring corneal thickness and anterior chamber depth. *Am J Ophthalmol* 2006; **141**: 7–12.
 28. Lackner B, Schmidinger G, Pieh S, Funovics MA, Skorpik C. Repeatability and reproducibility of central corneal thickness measurement with Pentacam, Orbscan, and ultrasound. *Optom Vis Sci* 2005; **82**: 892–9.
 29. Lackner B, Schmidinger G, Skorpik C. Validity and repeatability of anterior chamber depth measurements with Pentacam and Orbscan. *Optom Vis Sci* 2005; **82**: 858–61.
 30. O'Donnell C, Maldonado-Codina C. Agreement and repeatability of central thickness measurement in normal corneas using ultrasound pachymetry and the OCULUS Pentacam. *Cornea* 2005; **24**: 920–4.
 31. Ucakhan OO, Ozkan M, Kanpolat A. Corneal thickness measurements in normal and keratoconic eyes: Pentacam comprehensive eye scanner versus noncontact specular microscopy and ultrasound pachymetry. *J Cataract Refract Surg* 2006; **32**: 970–7.
 32. Ciolino JB, Khachikian SS, Cortese MJ, Belin MW. Long-term stability of the posterior cornea after laser in situ keratomileusis. *J Cataract Refract Surg* 2007; **33**: 1366–70.
 33. Wilson SE, Klyce SD. Screening for corneal topographic abnormalities before refractive surgery. *Ophthalmology* 1994; **101**: 147–52.
 34. McGhee CNJ, Weed KH. Computerized videokeratography in clinical practice. In: McGhee CNJ, Taylor HR, Gartry DS *et al.*, eds. *Excimer Lasers in Ophthalmology: Principles and Practice*. London: Martin Dunitz Ltc, 1997.
 35. Belin MW, Khachikian SS. New devices and clinical implications for measuring corneal thickness. *Clin Experiment Ophthalmol* 2006; **34**: 729–31.
 36. Bilgihan K, Ozdek SC, Konuk O, Akata F, Hasanreisoglu B. Results of photorefractive keratectomy in keratoconus suspects at 4 years. *J Refract Surg* 2000; **16**: 438–43.
 37. Sun R, Gimbel HV, Kaye GB. Photorefractive keratectomy in keratoconus suspects. *J Cataract Refract Surg* 1999; **25**: 1461–6.
 38. Kremer I, Shochot Y, Kaplan A, Blumenthal M. Three year results of photoastigmatic refractive keratectomy for mild and atypical keratoconus. *J Cataract Refract Surg* 1998; **24**: 1581–8.