

Technical Note

Anatomic Posterolateral Corner Reconstruction

Raphael Serra Cruz, M.D., Justin J. Mitchell, M.D., Chase S. Dean, M.D.,
Jorge Chahla, M.D., Gilbert Moatshe, M.D., and Robert F. LaPrade, M.D., Ph.D.

Abstract: Posterolateral corner injuries represent a complex injury pattern, with damage to important coronal and rotatory stabilizers of the knee. These lesions commonly occur in association with other ligament injuries, making decisions regarding treatment challenging. Grade III posterolateral corner injuries result in significant instability and have poor outcomes when treated nonoperatively. As a result, reconstruction is advocated. A thorough knowledge of the anatomy is essential for surgical treatment of this pathology. The following technical note provides a diagnostic approach, postoperative management, and details of a technique for anatomic reconstruction of the 3 main static stabilizers of the posterolateral corner of the knee.

The posterolateral corner (PLC) of the knee consists of important stabilizing structures that play a crucial role in varus and rotational stability through all ranges of motion.¹⁻³ The 3 major static stabilizers of the PLC are the fibular collateral ligament (FCL), popliteus tendon (PLT), and popliteofibular ligament (PFL).¹ The anatomic and biomechanical properties of these structures have been studied in detail and are important to understand for both clinical examination and anatomic reconstruction techniques.^{1,2,4} The mechanism of injury to the PLC usually involves direct varus stress, hyperextension, or twisting of the knee. These injuries rarely occur in isolation and are typically associated with anterior cruciate ligament (ACL) or posterior cruciate ligament (PCL) tears.⁵⁻⁷

Animal and clinical studies have reported that grade III PLC injuries heal poorly without surgical intervention, resulting in varus and rotational instability of the

knee.^{8,9} Persistent posterolateral instability leads to a varus thrust gait, which increases forces on the medial compartment of the knee. This may result in meniscal injuries and accelerated medial compartment osteoarthritis.⁹ Chronic posterolateral instability has also been shown to increase forces on the ACL and PCL, which can potentially lead to graft failure in the setting of multiligament injury.¹⁰⁻¹²

Historically, both repair and reconstruction have been used for treating PLC tears. PLC repairs have been reported to have a higher reoperation rate when compared with reconstructive techniques.¹³ As a result, reconstruction is recommended for grade III injuries.¹³⁻¹⁵ The purpose of this article is to describe an anatomic reconstruction technique of the 3 major stabilizers of the PLC using a split Achilles tendon allograft.

Objective Diagnosis

Physical examination of patients with PLC injuries may vary, but increased varus, external rotation, and recurvatum laxity are typically observed.¹⁶ In addition, it is critical to examine and document the status of the common peroneal nerve, due to its anatomical proximity and high incidence of associated injury (~13%) with PLC injuries.⁵ It is also essential to observe the gait pattern and observe for a varus thrust gait.

Weight-bearing hip-knee-ankle radiographs are obtained to assess lower limb alignment, because varus malalignment in chronic PLC injuries must be addressed with a biplanar osteotomy prior to ligament reconstruction.¹⁷ Not addressing the malalignment can lead to reconstruction graft failure. Stress radiographs are essential for the objective diagnosis of PLC lesions and have been shown to be a reliable and

From the Steadman Clinic (J.J.M., R.F.L.) and the Steadman Philippon Research Institute (R.S.C., J.J.M., C.S.D., J.C., G.M., R.F.L.), Vail, Colorado, U.S.A.; Instituto Brasil de Tecnologias da Saúde (R.S.C.), Rio de Janeiro, Brazil; OSTRC, The Norwegian School of Sports Sciences (G.M.), Oslo, Norway; and Orthopedic Department (G.M.), Oslo University Hospital, Oslo, Norway.

The authors report the following potential conflicts of interest or sources of funding: R.F.L. receives support from Arthrex, Smith & Nephew, and Ossur. Received December 13, 2015; accepted February 2, 2016.

Address correspondence to Robert F. LaPrade, M.D., Ph.D., Chief Medical Officer, Steadman Philippon Research Institute, The Steadman Clinic, 181 West Meadow Drive, Suite 400, Vail, CO 81657, U.S.A. E-mail: drlaprade@sprivil.org

© 2016 by the Arthroscopy Association of North America
2212-6287/151174/\$36.00

<http://dx.doi.org/10.1016/j.eats.2016.02.006>

reproducible objective method to evaluate the severity of this injury.^{17,18} Bilateral varus stress radiographs should be performed at 20° of knee flexion (Fig 1A), and lateral gapping is assessed by measuring the shortest distance between the subchondral bone surface of the most distal aspect of the lateral femoral condyle and the corresponding tibial plateau (Fig 1B). It has been reported that the current diagnostic algorithm for an isolated complete FCL tear is a side-to-side difference of 2.7 to 4.0 mm, while a difference greater than 4 mm represents an associated grade III PLC injury.¹⁷ Magnetic resonance imaging is performed to diagnose acute lesions, determine the location of the damaged structures, and assess concurrent injuries.¹⁹

Surgical Technique

Patient Positioning

The patient is positioned supine on the operating table, and an examination under anesthesia is performed to confirm the diagnosis. The surgical limb is then placed into a leg holder (Mizuho OSI, Union City, CA), and the nonsurgical limb is placed into an abduction stirrup (Birkova Product, Gothenburg, NE). A well-padded tourniquet is placed in the upper thigh of the operative leg, which is then prepped and draped in a standard fashion.

Surgical Approach

An abbreviated surgical outline is summarized in Table 1. A lateral hockey stick skin incision is made along the iliotibial band (ITB) and distally extended between the fibular head and Gerdy tubercle (Video 1 and Fig 2). The subcutaneous tissue is then dissected, and a posteriorly based flap is developed in order to preserve the vascular support to the superficial tissues. The long and short heads of the biceps femoris are exposed.

A neurolysis of the common peroneal nerve is performed next (Fig 3). The nerve is typically located posteromedially to the long head of the biceps femoris and should be dissected up to 6 cm proximally. Distally,

Table 1. Abbreviated Surgical Outline

Basic Surgical Plan
Surgical approach
Neurolysis of the common peroneal nerve
Posterolateral dissection
Identification of the FCL remnant and fibular attachment
Drilling of the fibular head tunnel and then the tibial tunnel and placement of passing sutures
Identification of the femoral insertion of the FCL and PLT
Drilling of the FCL and PLT femoral tunnels and placement of passing sutures
Proximal fixation and distal passage of the grafts
Distal fixation of the grafts (fibular head first and then tibia)

FCL, fibular collateral ligament; PLT, popliteus tendon.

5 to 7 mm of the peroneus longus fascia is incised in order to prevent nerve irritation or a foot drop due to postoperative swelling. After the neurolysis, the interval between the lateral gastrocnemius tendon and soleus muscle is identified by blunt dissection and the posteromedial aspect of the fibular styloid and the popliteus musculotendinous junction are palpated.

A horizontal incision is made over the distal portion of the long head of the biceps femoris (beginning approximately 1 cm proximal to the fibular head), in line with its fibers. The underlying biceps bursa is incised in order to locate the midportion of the FCL remnant, which is tag stitched using a no. 2 Fiberwire (Arthrex, Naples, FL; Fig 4A). Tensioning of the tag stitch will help to identify both FCL attachment sites for an accurate femoral tunnel location.

Subperiosteal dissection of the lateral aspect of the fibular head is performed in an anterior to posterior direction and is distally extended to the champagne glass drop-off of the fibular head (Fig 4B). Extending the dissection distally beyond this point can put the common peroneal nerve at risk. Typically, a small sulcus can be palpated where the distal FCL inserts on the fibular head. Posteriorly, a small elevator is used to dissect off the soleus muscle from the posteromedial aspect of the fibular head, where the fibular tunnel will be created.

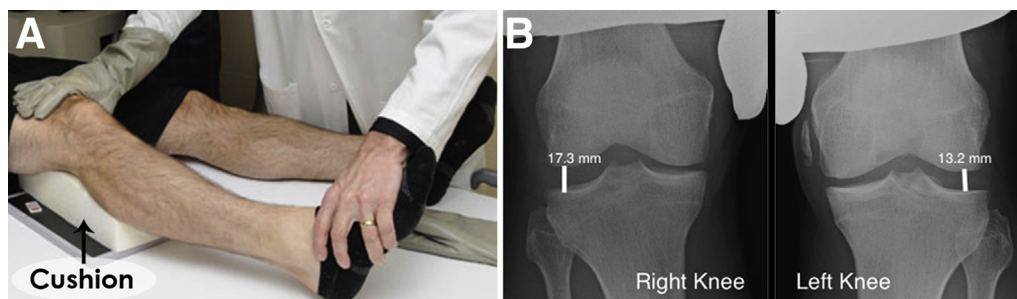


Fig 1. (A) Varus stress x-ray of a right knee being performed on a patient with suspected posterolateral corner injury. (B) Comparative plain bilateral x-ray images demonstrating a side-to-side difference of 4.1 mm, which indicates a complete posterolateral corner injury on the right knee.

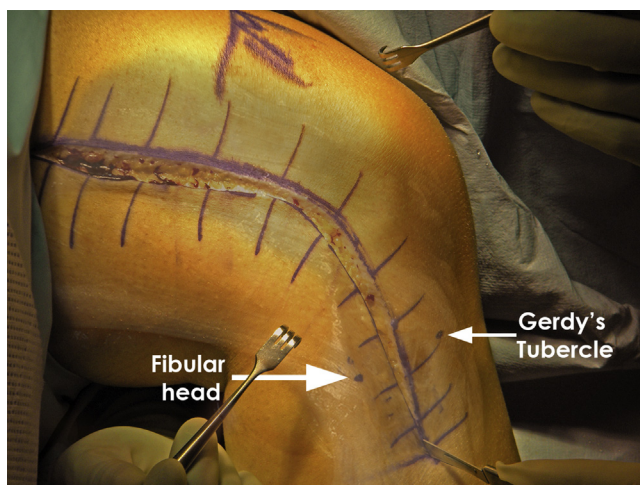


Fig 2. Intraoperative picture of a right knee with a superimposed anatomic image demonstrating the landmarks for the hockey stick incision used in the posterolateral corner reconstruction. The incision starts proximally along the iliotibial band and goes distally between Gerdy tubercle and the fibular head.

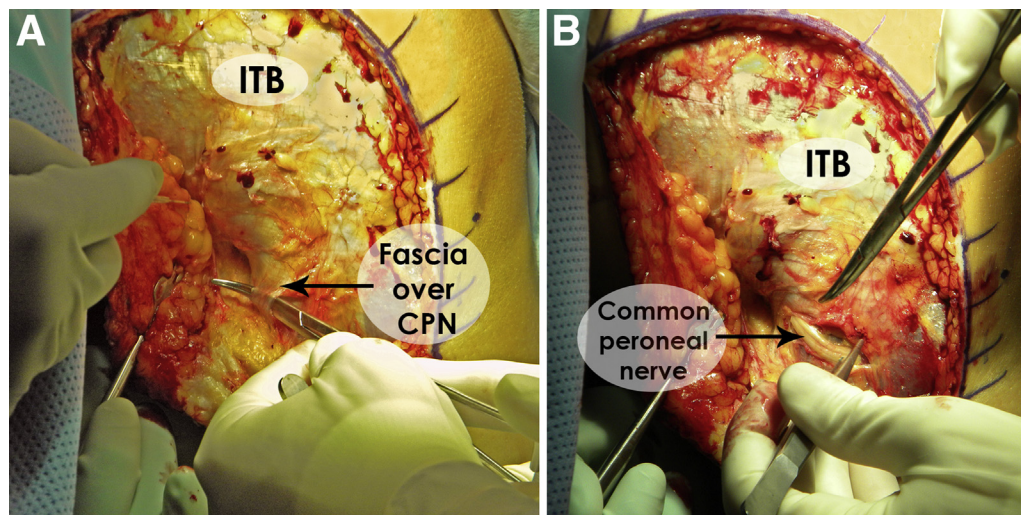
A Chandler retractor (V. Mueller, BD, Franklin Lakes, NJ) is placed behind the fibular head to protect the neurovascular bundle. With the aid of a collateral ligament aiming device (Arthrex), a guide pin is drilled from the lateral aspect of the fibular head (FCL attachment) to the posteromedial downslope of the fibular styloid. The entry point of the guide pin should be immediately above the champagne glass drop-off (Fig 5A), at the distal insertion site of the FCL, which has been described to be 28.4 mm from the styloid tip and 8.2 mm posterior to the anterior margin of the fibular head.¹ A risk of fracture of the fibular head exists when reaming the tunnel too proximally. After ensuring proper positioning of the guide pin, a 7-mm

reamer (Arthrex) is used to drill the fibular tunnel. A passing suture is then placed through the tunnel leaving the loop anterolaterally in order to facilitate future passage of the graft.

Attention is then turned to creating the tibial tunnel. The flat spot on the anterolateral tibia located distal and medial to Gerdy tubercle, just lateral to the tibial tubercle, is next identified. This will be the starting point for the tibial tunnel. The tibial popliteal sulcus is identified by palpation of the posterolateral tibial plateau to localize the site of the popliteus musculotendinous junction, where the posterior aperture of the tibial tunnel should be created. This point is located 1 cm proximal and 1 cm medial to the fibular tunnel. In order to protect the neurovascular bundle, a Chandler retractor is placed anterior to the lateral gastrocnemius. According to the aforementioned locations, a guide pin is then placed in an anterior to posterior direction, using a cruciate aiming device (Arthrex; Fig 5B). After confirming the proper location of the guide pin posteriorly, a 9-mm tunnel is overreamed and a passing suture is placed, leaving the loop posteriorly to facilitate graft passage.

Once the distal tunnels are completed, the next step is to identify the proximal insertions of the FCL and the popliteus tendon. Tensioning the tag suture previously placed on the FCL and palpating its proximal attachment will help locate the femoral attachment site. The ITB is then split approximately 4 cm in line with its fibers slightly anterior to the palpated FCL attachment. In situations where it is not possible to identify the FCL insertion by this technique, it can be located 1.4 mm proximal and 3.1 mm posterior to the lateral epicondyle.¹ Sharp dissection is performed in this location in a proximal to distal direction exposing the lateral epicondyle and the small sulcus in the FCL attachment

Fig 3. Intraoperative picture of a right knee demonstrating the dissection technique to locate the common peroneal nerve (CPN) (A) and the common peroneal nerve already identified while a neurolysis is performed (B). ITB, iliotibial band.



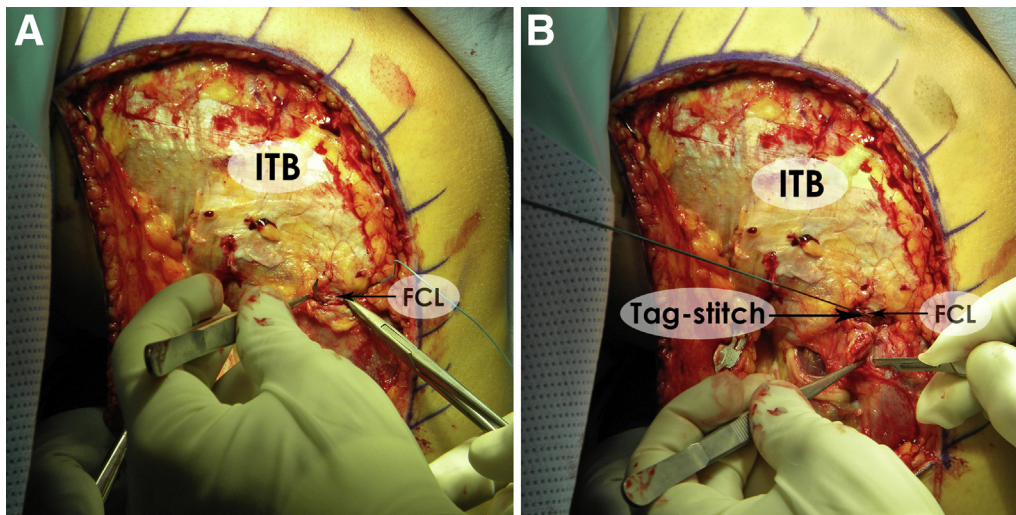


Fig 4. Picture of a right knee demonstrating the placement of a tag stitch on the midsubstance of the fibular collateral ligament (FCL) through a small incision over the biceps bursa (A) and the subperiosteal dissection of the fibular head in order to expose the correct place for the FCL tunnel (B). ITB, iliotibial band.

site (Fig 6A). Using a collateral ligament reconstruction aiming sleeve (Arthrex), a guide pin is drilled over the FCL attachment site (Fig 6B) and should exit the medial aspect of the distal thigh, about 5 cm proximal and anterior to the adductor tubercle. This positioning should avoid the trochlea and a possible ACL tunnel, in cases of combined ligament reconstruction.

The femoral attachment of the PLT has been reported to be located 18.5 mm anterior to the FCL insertion, in the anterior fifth of the popliteal sulcus.¹ An arthrotomy is required due to the intra-articular insertion of the PLT. A vertical incision is made to the lateral capsule at the PLT insertion site with care not to damage the ITB. The PLT attachment is identified, and sharp

dissection is begun anteriorly and carried posteriorly away from the cartilage of the femoral condyle. A guide pin is then inserted at this location, parallel to the FCL pin and in a similar fashion. After ensuring the correct placement of both pins and checking their distance (Fig 7), a 9-mm reamer is used to drill both tunnels to a depth of 25 mm (socket) and a passing suture is placed into each tunnel to facilitate graft passage.

The graft used for this technique is a split Achilles tendon allograft (Allosource, Centennial, CO). The minimum length of the graft required is 22 cm. Both grafts are prepared to create 9 × 20 mm sized bone plugs, and 2 no. 5 Fiberwire (Arthrex) sutures are threaded through drill holes placed in each bone plug.

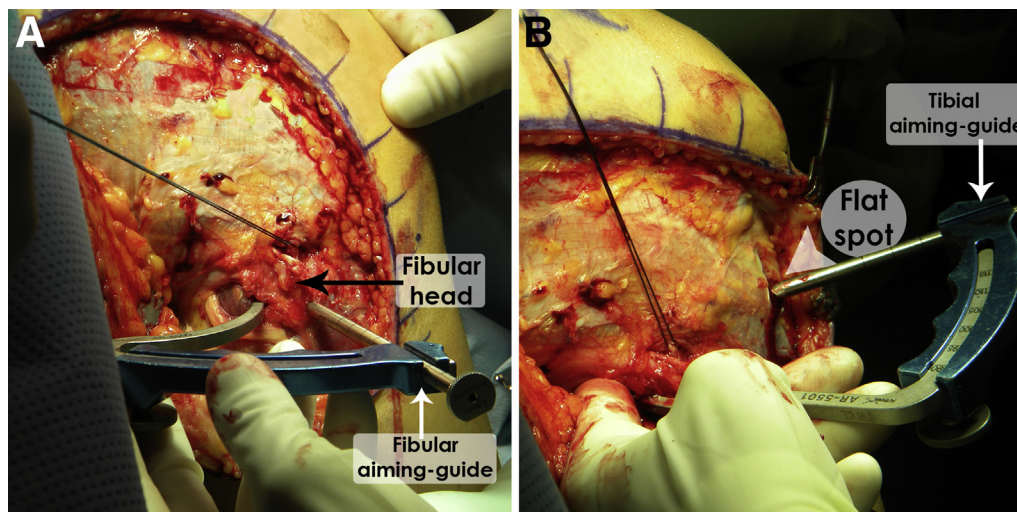
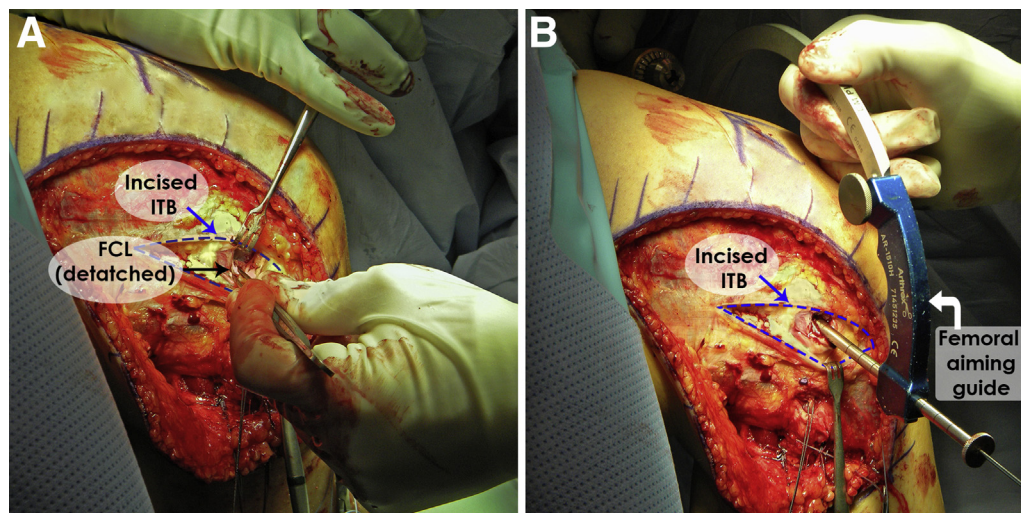


Fig 5. Desired placement of the distal tunnels on an exposed right knee. (A) Collateral aiming guide (fibular) placed on the fibular head from a point immediately above the lateral champagne glass drop-off, pointing to the posteromedial downslope of the fibular styloid. (B) Collateral aiming guide (tibial) positioned over the flat spot on the proximal tibia, aiming the popliteus sulcus on the posterolateral aspect of this bone. The exit point for the tibial tunnel should be located 1 cm proximal and medial relative to the exit point of the fibular tunnel.

Fig 6. Intraoperative picture of a right knee, demonstrating an opening on the iliotibial band (ITB) through which the surgeon can find the proximal attachment of the fibular collateral ligament (FCL) (A) and femoral aiming guide placed over the proximal FCL attachment location (B). The guide pin should exit the medial aspect of the distal thigh, anterior, and proximal relative to the entry point.



The distal aspect of both grafts are tubularized with a whip-stitched suture to a 7-mm diameter. Using sutures previously left in place, the grafts are pulled into their respective femoral tunnels and each one is secured with a 7 × 20 mm cannulated screw (Arthrex) with the aid of a guide pin placed between the cancellous surface of the bone plugs and the rim of the tunnels. It is recommended to use a cannulated plastic sheath protector (Arthrex) during screw placement in order to avoid damage to the graft (Fig 8A).

After both grafts are firmly secured into their femoral tunnels, they are passed distally through the soft tissues. The popliteus graft is passed along the popliteal hiatus in the posterolateral capsule and should exit between the lateral gastrocnemius and the soleus muscles. After creating a soft tissue channel by blunt

dissection, the FCL graft is passed under the superficial layer of the ITB (Fig 8B) and then through the fibular head tunnel in an anterolateral to posteromedial direction, using the passing sutures previously left in place. The FCL graft is then secured anterolaterally into the fibular head with a 7 × 23 mm bioabsorbable screw (Arthrex), using a guide pin placed below the graft in the distal aspect of the tunnel. During this fixation, tension is applied to the distal end of the graft and the knee should be at 20° of flexion and neutral rotation, while applying a gentle valgus force to reduce any lateral compartment laxity (Fig 9A).

Both grafts are then passed together through the tibial tunnel, using a passing suture previously left in place, from posterior to anterior. After cycling the knee several times through a complete range of motion, the grafts are fixed to the tibia with a 9 × 23 mm bioabsorbable screw (Arthrex). During this fixation, the knee is kept in 60° of flexion and neutral rotation, while an assistant applies tension to the distal end of both grafts (Fig 9B).

After fixation of all structures, knee stability and range of motion are assessed to confirm that neither residual laxity nor joint overconstraint exists. A backup fixation can be performed with a staple placed just below the tibial tunnel, securing both grafts. After irrigation of the tissues, the lateral capsule is closed with a no. 0 Vicryl (Ethicon, Somerville, NJ) suture and the ITB incision is closed with no. 0 Vicryl (Ethicon) sutures. The portion of the anterior arm of the long head of the biceps femoris partially detached during the exposure of the fibular head should be reattached with sutures through the periosteum of the lateral edge of the fibular head. The superficial layers are closed in a regular fashion using subcutaneous skin sutures. The pearls and pitfalls of this procedure are summarized in Table 2.

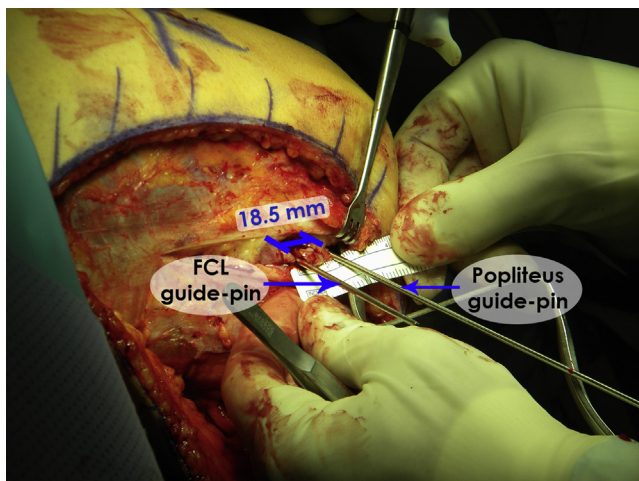


Fig 7. Intraoperative image demonstrating the relationship between the fibular collateral ligament and popliteus femoral tunnels in a right knee. The anatomic distance between these 2 structures is reported to be 18.5 mm.

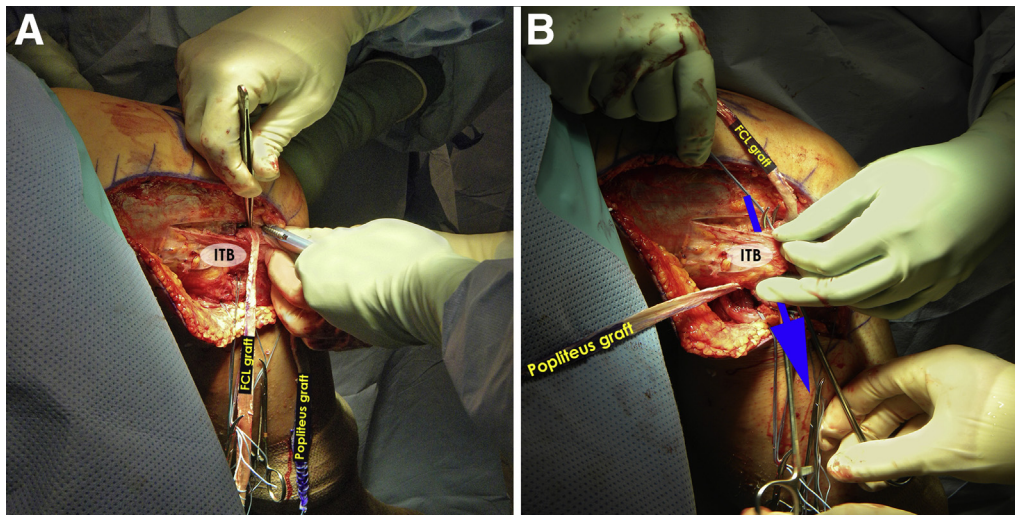


Fig 8. (A) Right knee during the proximal fixation of the fibular collateral ligament (FCL) and popliteus grafts with metallic interference screws. The screws are placed between the cancellous surface of the bone block and the rim of the tunnels. (B) Distal passage of the grafts after proximal fixation. The popliteus graft has already been passed through the popliteus hiatus, and the fibular collateral ligament graft is about to be passed underneath the superficial layer of the iliotibial band (ITB), as indicated by the blue arrow.

Rehabilitation

After PLC reconstruction, patients use a knee immobilizer and mobilize non-weight bearing for 6 weeks. Formal rehabilitation begins immediately postoperatively and focuses on restoration of tibiofemoral and patellofemoral range of motion, edema, and pain management as well as restoration of quadriceps function. Passive range of motion is initiated on the first day postoperatively and is gradually progressed to full range of motion as tolerated. A goal

of at least 90° of knee flexion is desired by 2 weeks postoperatively. At 6 weeks, patients are permitted to begin spinning on a stationary bike and wean off crutches. Once they are fully weight bearing, patients begin closed chain strengthening exercises with training parameters focused on first developing a muscular endurance base before progressing to muscular strength and power development. Isolated open chain hamstring strengthening is limited to avoid stressing the reconstruction until a minimum of

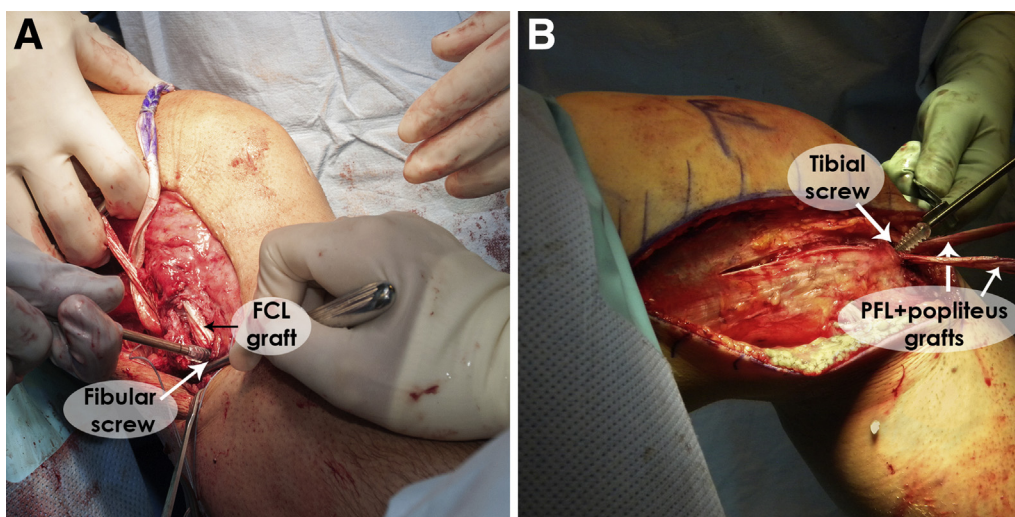


Fig 9. Distal fixation of the posterolateral corner reconstruction grafts in a right knee. (A) Fibular collateral ligament (FCL) fixation with a 7 × 23 bioabsorbable screw. The knee is placed at approximately 20° of flexion and neutral rotation, and a gentle valgus force is applied, while the assistant applies tension to the graft. (B) Simultaneous tibial fixation of both grafts with a 9 × 23 bioabsorbable screw. This time the knee is positioned at 60° of flexion and neutral rotation. PFL, popliteofibular ligament.

Table 2. Pearls and Pitfalls of Anatomic Posterolateral Corner Reconstruction

Pearls	Pitfalls
Leaving passing sutures after drilling each tunnel facilitates further passage of grafts	To avoid common peroneal nerve injury, do not slide the scalpel distal to the fibular champagne glass drop-off and always face the blade to the bone.
When the CPN cannot be found behind the biceps femoris tendon, it should be dissected 2-3 cm distal to the lateral aspect of the fibular head. Gentle palpation will help to identify it.	Placing the fibular tunnel too high can fracture the fibular head. The guide pin should be placed slightly above the champagne glass drop-off.
Including the peroneus longus fascia when performing the neurolysis of the CPN helps prevent irritation to the nerve due to postoperative swelling and facilitates its retraction during the procedure.	To avoid fibular fracture in small patients while reaming the fibular tunnel, the reamer can be downsized from 7 mm to 6 mm.
Having an assistant with a no. 15 blade to cut the soft tissues while the surgeon uses a blunt clamp to dissect the CPN helps prevent inadvertent lesion of this nerve.	Drilling the tibial guide pin lateral to the flat spot can make it slip into the anterior compartment and put the proximal tibiofibular joint at risk.
After reaming the fibular tunnel, use a blunt device (e.g., trocar) to pass through the tunnel and check the proper exit point posteriorly. The blunt device should be left in place while drilling the tibial guide pin for manual reference of the tibial guide pin. The tibial exit point should be located 1 cm proximal and 1 cm medial to fibular tunnel exit point.	Splitting the ITB posterior to the FCL attachment on the femur will hamper visualization. Making the incision slightly anterior to the FCL attachment will avoid this issue.
Leaving the FCL remnant in place may help keep some proprioceptive function of these fibers.	Drilling the femoral tunnels parallel to the joint can interfere with the intercondylar notch or other possible concomitant reconstruction tunnels and also puts the saphenous nerve at risk. Aiming the guide pin about 5 cm proximal and anterior to the adductor tubercle on the medial side should avoid these problems.
If local conditions hamper identification of the femoral popliteal sulcus, its location can be estimated by bringing the knee to 70° of flexion and making the vertical arthrotomy about 1 cm distal to the FCL attachment in a plane parallel to the fibular shaft.	Nonanatomic placement of the tunnels can jeopardize the reconstruction. Only ream the tunnels after making sure the guide pins are in the correct place. On the femur, respect the reported anatomic distance of 18.5 mm between the FCL and popliteus attachments.
The use of a chuck to insert the screw guide pins makes it easier and prevents bending during this procedure. If there is some difficulty, pull the bone plug a little back and insert it again along with the pin.	If tunnels are not properly cleared of soft tissues, passage of the grafts can be difficult.
One of the grafts can be marked with methylene blue to differentiate them and facilitate identification during the surgery.	Leaving the bone plug or screw proud over the femoral tunnels can cause irritation to adjacent soft tissues (especially the ITB). Use a marking pen to delineate the bone-tendon transition in the grafts and make sure the bone plugs are completely recessed inside the tunnels.
Before fixing the distal portions of the grafts, make sure the popliteus is deep to the FCL in order not to interfere with their function.	Not using a screw protector during screw placement on the femur can cause damage to the grafts.

CPN, common peroneal nerve; FCL, fibular collateral ligament; ITB, iliotibial band.

4 months postoperatively. Situations in which the tibia is subject to posterior sag or external rotation should also be avoided for a period of 4 months. Running exercises, along with speed and agility workouts, may begin once appropriate strength and power characteristics have been developed, typically around 6 months after surgery. Return to sports or activity is allowed when normal strength, stability, and knee range of motion comparable to the contralateral side have been achieved (usually between 6 and 9 months and based on associated cruciate ligament or other structure surgery). [Table 3](#) provides a summary of the rehabilitation program.

Discussion

This anatomic PLC reconstruction technique has demonstrated improved subjective and objective patient outcomes compared with nonsurgical treatment or repair^{14,20} and has been reported to restore near native knee stability in cadaveric studies.^{21,22} Grade III injuries to the PLC are best treated with surgical intervention, as symptomatic instability of the knee remains a significant risk when treated nonoperatively.^{5,23} In

2004, LaPrade et al.²¹ described an anatomic reconstruction of the PLC using the native attachments of the FCL, PLT, and PFL. This was one of the earliest descriptions of a surgical option to recreate the anatomy of the 3 main static stabilizers of the PLC and is the basis for our current approach. This technique restores near-native varus and rotational stability to the knee. Outcomes studies have shown significant postoperative improvement in scores for varus opening at 20°, external rotation at 30°, reverse pivot shift, and single-leg hop.²⁰

The biomechanical importance of this anatomic-based technique was reinforced in 2010 by McCarthy and associates²⁴ as they demonstrated the need for an anatomic reconstruction of the PFL to restore knee stability. LaPrade et al.²² published a biomechanical analysis of the PLT, demonstrating its role as a primary static stabilizer to external rotation. A prospective evaluation by Geeslin et al.¹⁴ demonstrated significant improvements in all IKDC objective scores, side-to-side differences in varus stress radiographs, and improvement in mean Cincinnati and IKDC subjective outcomes scores.

Table 3. Posterolateral Corner Rehabilitation Summary

Exercise	Week													
	1	2	3	4	5	6	7	8	9	10	12	16	20	24
Initial exercises:														
Flexion/extension, wall slides			●	●	●	●	●	●	●	●	●			
Flexion/extension, seated/calf assisted or prone	●	●	●	●	●	●	●	●	●	●	●			
Patella/tendon mobilization	●	●	●	●	●	●	●	●						
Quad series	●	●	●	●	●	●	●	●						
Hamstring sets							●	●	●	●	●	●	●	●
Sit and reach for hamstrings (no hyperextension)					●	●	●	●						
Ankle pumps	●	●	●	●	●	●	●	●	●					
Crutch weaning							●	●	●					
Toe and heel raises								●	●	●				
Balance series										●	●	●	●	●
Weight-bearing strength exercises:														
Double knee bends								●	●	●	●	●	●	
Double leg bridges									●	●	●			
Reverse lunge, static holds								●	●	●	●			
Beginning cord exercises										●	●			
Balance squats											●	●	●	●
Single leg dead lift											●	●	●	●
Leg press to max 70° knee flexion									●	●	●	●	●	●
Sports test exercises													●	●
Agility exercises:														
Running progression														
Initial, single plane														●
Advance, multidirectional														●
Functional sports test														●

● = Do exercise for that week.

Several alternative techniques for treatment of PLC injuries have been proposed. While some investigators have advocated direct repair of the injured structures, various reconstructive options have been reported. These PLC reconstruction techniques can be generally categorized as fibular sling with or without posterior capsular shift, biceps femoris tendon transfer, or anatomic-based reconstruction as described elsewhere.²⁵

While results of different techniques do not provide sufficient data for direct comparison, recent systematic reviews of PLC injuries by Geeslin et al.²⁵ and Moulton et al.²⁶ reported that techniques were not standardized and differed based on time to presentation, surgeon preference, and availability of reparable tissue. In general, surgeons advocate for reconstruction of chronic injuries but differ significantly in management of acute injuries. In the setting of bony avulsions or acute injuries with adequate soft tissue quality, some investigators chose to restore knee stability with primary repair of damaged structures, with staged reconstruction of associated cruciate injuries. This acute repair strategy was associated with a 38% failure rate and was less successful when compared with a 9% failure rate in more comprehensive reconstructive options with concurrent cruciate ligament reconstruction. Levy et al.¹⁵ further reinforced the importance of reconstruction in

their systematic review, concluding that reconstruction provides better outcomes than repair of PLC injuries; however, no recommendations were made with regard to the type of reconstruction. Yoon and colleagues²⁷ compared a nonanatomic fibular sling PLC reconstruction technique with an anatomic-based reconstruction and demonstrated improved Lysholm scores and improved varus and external rotation laxity in the anatomic reconstruction group.

As a result of these findings, we recommend anatomic reconstruction of acute PLC injuries with treatment of concomitant injuries in a single surgery. This recommendation holds true in chronic situations; however, caution should be taken with chronic injuries to evaluate for varus malalignment, which should be addressed prior to any reconstructive procedure for the PLC.

Considering the contribution of the PLC to the posterolateral stability of the knee and the inherent bony instability of the convex lateral tibial plateau, it has become clear that restoration of the native anatomy of PLC structures is of paramount importance.^{25,26,28} While studies regarding the anatomic-based reconstruction have demonstrated promising results, one concern regarding this technique is its high technical demand and steep learning curve (Table 4 summarizes the advantages and limitations of the anatomic reconstruction technique).

Table 4. Advantages and Risks/Limitations for the Anatomic Posterolateral Corner Reconstruction Technique

Advantages	Risks/Limitations
The technique restores the 3 main stabilizers of the posterolateral aspect of the knee.	The use of allograft tissue can predispose to a small risk of disease transmission.
Anatomic posterolateral corner reconstruction can be performed in both acute and chronic settings in appropriately indicated patients.	This surgical approach is technically demanding, requiring proficiency with surgical dissection
This technique has been evaluated biomechanically and validated using patient reported outcome studies.	Damage to the common peroneal nerve can potentially occur; careful dissection and placement of retractors should be observed.
The anatomy of the posterolateral corner structures can usually be visualized to ensure appropriate placement of the tunnels.	Fracture of the fibular head: correct placement of the tunnel reduces the risk of this complication
Patients with associated proximal tibiofibular joint instability will benefit from this reconstruction since it will add stability to this joint.	Failure due to unrecognized malalignment; especially in chronic cases, the patient should have a complete evaluation of the standing alignment and tibial slope.

Long-term studies should be performed to ensure maintenance of both stability and functionality, restored after surgery. This technique will continue to be studied and evaluated within our group, and we also encourage other surgeons to further evaluate the validity of this technique and to perform continued assessment for long-term results.

References

- LaPrade RF, Ly TV, Wentorf FA, Engebretsen L. The posterolateral attachments of the knee: a qualitative and quantitative morphologic analysis of the fibular collateral ligament, popliteus tendon, popliteofibular ligament, and lateral gastrocnemius tendon. *Am J Sports Med* 2003;31:854-860.
- LaPrade RF. Force measurements on the fibular collateral ligament, popliteofibular ligament, and popliteus tendon to applied loads. *Am J Sports Med* 2004;32:1695-1701.
- Gollehon DL, Torzilli PA, Warren RF. The role of the posterolateral and cruciate ligaments in the stability of the human knee. A biomechanical study. *J Bone Joint Surg Am* 1987;69:233-242.
- LaPrade RF, Bollom TS, Wentorf FA, Wills NJ, Meister K. Mechanical properties of the posterolateral structures of the knee. *Am J Sports Med* 2005;33:1386-1391.
- LaPrade RF, Terry GC. Injuries to the posterolateral aspect of the knee. Association of anatomic injury patterns with clinical instability. *Am J Sports Med* 1997;25:433-438.
- Noyes FR, Barber-Westin SD, Albright JC. An analysis of the causes of failure in 57 consecutive posterolateral operative procedures. *Am J Sports Med* 2006;34:1419-1430.
- LaPrade RF, Hamilton CD, Engebretsen L. Treatment of acute and chronic combined anterior cruciate ligament and posterolateral knee ligament injuries. *Sports Med Arthrosc* 1997;5:91-99.
- LaPrade RF, Wentorf FA, Crum JA. Assessment of healing of grade III posterolateral corner injuries: an in vivo model. *J Orthop Res* 2004;22:970-975.
- Griffith CJ, Wijdicks CA, Goerke U, Michaeli S, Ellermann J, LaPrade RF. Outcomes of untreated posterolateral knee injuries: an in vivo canine model. *Knee Surg Sports Traumatol Arthrosc* 2011;19:1192-1197.
- Harner CD, Vogrin TM, Hoher J, Ma CB, Woo SL. Biomechanical analysis of a posterior cruciate ligament reconstruction. Deficiency of the posterolateral structures as a cause of graft failure. *Am J Sports Med* 2000;28:32-39.
- LaPrade RF, Resig S, Wentorf F, Lewis JL. The effects of grade III posterolateral knee complex injuries on anterior cruciate ligament graft force. A biomechanical analysis. *Am J Sports Med* 1999;27:469-475.
- LaPrade RF, Muench C, Wentorf F, Lewis JL. The effect of injury to the posterolateral structures of the knee on force in a posterior cruciate ligament graft: a biomechanical study. *Am J Sports Med* 2002;30:233-238.
- Black BS, Stannard JP. Repair versus reconstruction in acute posterolateral instability of the knee. *Sports Med Arthrosc* 2015;23:22-26.
- Geeslin AG, LaPrade RF. Outcomes of treatment of acute grade-III isolated and combined posterolateral knee injuries: a prospective case series and surgical technique. *J Bone Joint Surg Am* 2011;93:1672-1683.
- Levy BA, Dajani KA, Morgan JA, Shah JP, Dahm DL, Stuart MJ. Repair versus reconstruction of the fibular collateral ligament and posterolateral corner in the multiligament-injured knee. *Am J Sports Med* 2010;38:804-809.
- LaPrade RF, Wentorf F. Diagnosis and treatment of posterolateral knee injuries. *Clin Orthop Relat Res* 2002:110-121.
- LaPrade RF, Heikes C, Bakker AJ, Jakobsen RB. The reproducibility and repeatability of varus stress radiographs in the assessment of isolated fibular collateral ligament and grade-III posterolateral knee injuries. An in vitro biomechanical study. *J Bone Joint Surg Am* 2008;90:2069-2076.
- Arthur A. Proximal tibial opening wedge osteotomy as the initial treatment for chronic posterolateral corner deficiency in the varus knee: a prospective clinical study. *Am J Sports Med* 2007;35:1844-1850.
- LaPrade RF, Gilbert TJ, Bollom TS, Wentorf F, Chaljub G. The magnetic resonance imaging appearance of individual structures of the posterolateral knee: a prospective study of normal knees and knees with surgically verified grade III injuries. *Am J Sports Med* 2000;28:191-199.
- LaPrade RF, Johansen S, Agel J, Risberg MA, Moksnes H, Engebretsen L. Outcomes of an anatomic posterolateral knee reconstruction. *J Bone Joint Surg Am* 2010;92:16-22.

21. LaPrade RF, Johansen S, Wentorf FA, Engebretsen L, Esterberg JL, Tso A. An analysis of an anatomical posterolateral knee reconstruction: an in vitro biomechanical study and development of a surgical technique. *Am J Sports Med* 2004;32:1405-1414.
22. LaPrade RF, Wozniczka JK, Stellmaker MP, Wijdicks CA. Analysis of the static function of the popliteus tendon and evaluation of an anatomic reconstruction: the "fifth ligament" of the knee. *Am J Sports Med* 2010;38:543-549.
23. LaPrade RF, Griffith CJ, Coobs BR, Geeslin AG, Johansen S, Engebretsen L. Improving outcomes for posterolateral knee injuries. *J Orthop Res* 2014;32:485-491.
24. McCarthy M, Camarda L, Wijdicks CA, Johansen S, Engebretsen L, LaPrade RF. Anatomic posterolateral knee reconstructions require a popliteofibular ligament reconstruction through a tibial tunnel. *Am J Sports Med* 2010;38:1674-1681.
25. Geeslin AG, Moulton SG, LaPrade RF. A systematic review of the outcomes of posterolateral corner knee injuries. Part 1. Surgical treatment of acute injuries. *Am J Sports Med* 2016;44:1336-1342.
26. Moulton SG, Geeslin AG, LaPrade RF. A systematic review of the outcomes of posterolateral corner knee injuries. Part 2. Surgical treatment of chronic injuries [published online August 10, 2015]. *Am J Sports Med*. doi:10.1177/0363546515593950.
27. Yoon KH, Bae DK, Ha JH, Park SW. Anatomic reconstructive surgery for posterolateral instability of the knee. *Arthroscopy* 2006;22:159-165.
28. LaPrade RF. *Posterolateral knee injuries: anatomy, evaluation, and treatment*. New York: Thieme, 2006.