

ANATOMY/PHYSIOLOGY

SPRING 2013

NAME:

Health and Wellness Department - Conestoga High School, 200 Irish Road, Berwyn, PA 19312
Ms. Marcia Mariani, Health & Wellness Department / email: marianim@tesd.net

Anatomy/Physiology Course Information

Purpose

To introduce students to the study of gross anatomy and physiology in preparation for the college-level course(s) required for all students entering the field of Health Sciences.

Recommendation

If students are planning a career in a Health Science field, it is strongly recommended that they work to achieve a grade of 90% or higher for their transcript for college and health science program acceptance.

Course Content and Materials

The course will use Human Anatomy & Physiology by Elaine Marieb and The Anatomy Coloring Book by Wynn Kapit and Lawrence M. Elson. It is the responsibility of each student to purchase the coloring book. Colored pencils, index cards and blue books are available to students on request to their classroom teacher. Additional support and course materials are available in this course notebook.

Assessment

Students will have Chapter Tests on Chapters 1, 2 and 3.

Students will have Chapter and Practical Tests on Chapters 5 and 6.

Study Groups will create an electronic research project for their chosen organ system.

Students will have an assignment calendar that designates homework for the Chapter Review Packets and Coloring Assignments.

Group Bonus activities will be provided for extra credit at random intervals

Wellness Department Health Sciences Award

By taking the course, you are automatically eligible for nomination for this award. The Conestoga senior who earns the highest overall average in their Health Education and Anatomy/Physiology with intention of pursuing a career in Health Science will win this award. In the case of a tie, the department will then look to grades in other department courses, participation in the Allied Health Program and student resumes relative to Health Sciences work.

**ANATOMY/PHYSIOLOGY
CHAPTER TEST REVIEWS
TEST FORMAT**

TEST REMINDERS:

- YOU WILL HAVE ONE PERIOD TO COMPLETE CHAPTER EXAMS
- CHOOSE THE BEST ANSWER FOR EACH QUESTION
- SOME QUESTIONS WILL REQUIRE MORE THAN ONE BEST ANSWER

PLANNED TEST FORMAT: Objective Questions

- ❖ STANDARD MULTIPLE CHOICE
- ❖ STANDARD TWO-COLUMN MATCHING
- ❖ FIVE-CHOICE MATCHING
- ❖ CHOOSE THE BEST OF TWO (DIRECTIONAL TERMS)
- ❖ REVERSE DEFINITIONS (definition provided, name the system)

PLANNED TEST CONTENT:

- EACH EXAM WILL CONTAIN CONTENT FROM THE FOLLOWING: CHAPTER CONTENT, CHAPTER PACKET
- EACH EXAM MAY CONTAIN PREVIOUSLY LEARNED INFORMATION (i.e. motions may be on the Chapter 2 test) SINCE LEARNING IS TO BE CUMULATIVE
- LABELING OF ANATOMICAL TERMS
- DEFINING ANATOMICAL TERMS
- APPLICATION OF ANATOMICAL TERMS TO BODY MOVEMENT AND PROCESSES
- APPLICATION OF ANATOMICAL TERMS TO REAL LIFE

PLANNED GRADING:

- ❖ OBJECTIVE QUESTIONS: 1 POINT PER ANSWER POSSIBLE = 62 POINTS
- ❖ MOTIONS: 20 POINTS
- ❖ TOTAL POINTS POSSIBLE = 82 POINTS

NOTES/REMINDERS:

Human Anatomy/Physiology Group Research Project

Purpose:

- To introduce your chosen body system to your classmates by explaining why it is important and amazing!
- To educate your classmates on the gross anatomy, physiology and basic functions/purpose of your chosen body system.
- To demonstrate how the individual parts of your chosen system combine to function.
- To explain how those functions serve the body as a whole – specifically how it may partner with other systems.
- To demonstrate and provide examples of at least two conditions which may result if the system fails to function as expected.
- To test your classmates' knowledge of your chosen body system.

Research:

- Gather background information on the components of your body system and their functions using at least **five** reliable health science resources. You should rely primarily on .gov; .edu; and some .org websites. You should also use reference books and professional journals/magazines. You should avoid Wikipedia and organizations that may have a bias viewpoint or are trying to make money from selling a product or philosophy.
- Create a basic outline of the content you feel would best achieve your project purpose.
- Find two graphics that would support your content.
- Find at least two online video or visual clips that you can insert as hyperlinks in your project to further explain structure and function to your classmates.

Create Your Electronic Project:

- Cover Page that includes your name and grade.
- A minimum of five pages of written text that fulfill the purpose of the project.
- Your hyperlinks/reference links should be included throughout the project to support/explain the written content.
- Bibliography of all materials/resources/research and reference links used to create your project.
- Create the evaluation tool your peers will complete.
- Create an electronic answer key for your teacher.

Peer Evaluation Tool:

- Create a 20 question worksheet or quiz for your classmates to print and complete.
- Please use questions that are purposeful rather than just creating 'busy work' questionnaires!
- Be sure all answers are available via the written text and/or the links in your project.
- Be sure answers would have only one **best** answer.

Submit Your Project:

- Project Due Date: Friday, December 14, 2012 no later than 11:59:59pm
- Project should be submitted electronically to Synergy – specifically, your project topic's folder.
- Email the electronic answer key **ONLY** to Ms. Mariani (honor system!).
- Be sure to submit the hard copy of the grading form attached to this page.

Our Topic _____

Notes:

**ANATOMY-PHYSIOLOGY ORGAN SYSTEM RESEARCH PROJECT
GRADING RUBRIC**

GROUP NAMES _____

_____ APPROVED TOPIC (YES/NO) – FAILURE TO USE APPROVED TOPIC WILL RESULT IN ZERO GRADE

_____ PROJECT SUBMITTED BY DEADLINE (10) NOTE: ADDITIONAL 5-POINT DEDUCTION PER 12 HOURS LATE

_____ INTRODUCTION (10)

_____ REQUIRED WRITTEN CONTENT LENGTH OF 5 PAGES WITHOUT GRAPHICS (20)

- ALL PARTS OF SYSTEM DISCUSSED
- ACCURATE AND CONCISE INFORMATION

_____ MINIMUM OF 2 REQUIRED GRAPHICS - 1 PAGE OF CONTENT (10)

- CLEAR REPRESENTATION OF WRITTEN CONTENT
- GRAPHICS SERVE TO FURTHER EDUCATE PEERS

_____ CLARITY/PURPOSE/EDUCATIONAL VALUE OF SUPPORTING WEB VISUAL # 1 (10)

_____ CLARITY/PURPOSE/EDUCATIONAL VALUE OF SUPPORTING WEB VISUAL #2 (10)

_____ GROSS ANATOMY CONTENT (20)

- PARTS
- FUNCTION
- RELATIONSHIP TO BODY AS A WHOLE

_____ PHYSIOLOGY CONTENT (20)

- PARTS
- FUNCTION
- RELATIONSHIP TO BODY AS A WHOLE

_____ ORIGINALITY/CREATIVITY OF CONTENT (10)

_____ DISEASE/CONDITION # 1 (10)

_____ DISEASE/CONDITION # 2 (10)

_____ BIBLIOGRAPHY (20)

- MINIMUM OF 5 SOURCES OBTAINED AND USED
- RELIABILITY OF HEALTH SCIENCE SOURCES
- MOST CURRENT INFORMATION AVAILABLE UNLESS USED FOR HISTORICAL REFERENCE
- PROPER USE OF MLA FORMATTING

_____ 20-QUESTION TEST OF PEER KNOWLEDGE (REVIEW WORKSHEET) (20)

- PURPOSEFUL QUESTIONS
- CLARITY OF QUESTIONS
- FORMAT OF QUESTIONS

_____ OVERALL TOPIC COVERAGE, QUALITY AND CLARITY (20)

_____ **TOTAL POINTS EARNED OF 200**

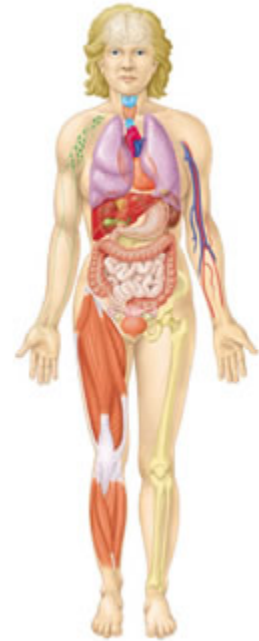CHAPTER 1

THE HUMAN BODY

AN ORIENTATION

Chapter 1 Objectives

Most of us are naturally curious about our bodies; we want to know what makes us tick. This curiosity is even seen in infants, who can keep themselves happy for a long time staring at their own hands or pulling their mother's nose. Older children wonder where food goes when they swallow it, and some believe that they will grow a watermelon in their belly if they swallow the seeds. They scream loudly when approached by medical personnel (fearing shots that sting), but they like to play doctor. Adults become upset when their hearts pound, when they have uncontrollable hot flashes, or when they cannot keep their weight down. Anatomy and physiology, subdivisions of biology, explore many of these topics as they describe how our bodies are put together and how they work.



Objective Checklist

An Overview of Anatomy and Physiology

- Define *anatomy* and *physiology*.
- Explain how anatomy and physiology are related.

Levels of Structural Organization

- Name the levels of structural organization that make up the human body and explain how they are related.
- Name the organ systems of the body and briefly state the major functions of each system.
- Classify by organ system all organs discussed.
- Identify the organs shown on a diagram or a dissectible torso.

Maintaining Life

- List functions that humans must perform to maintain life.
- List the survival needs of the human body.

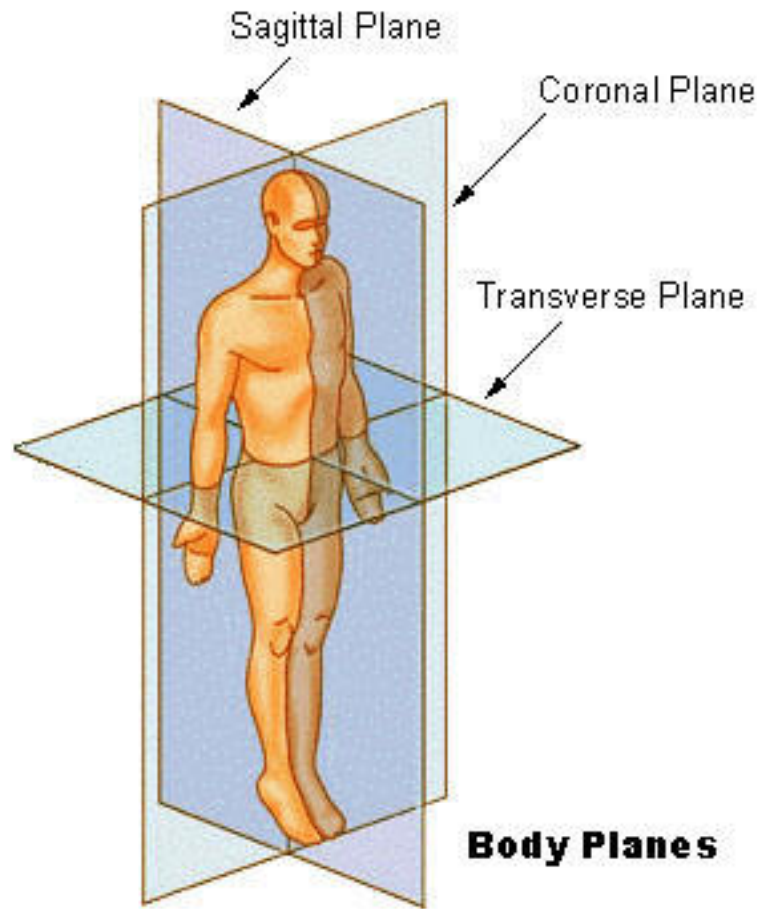
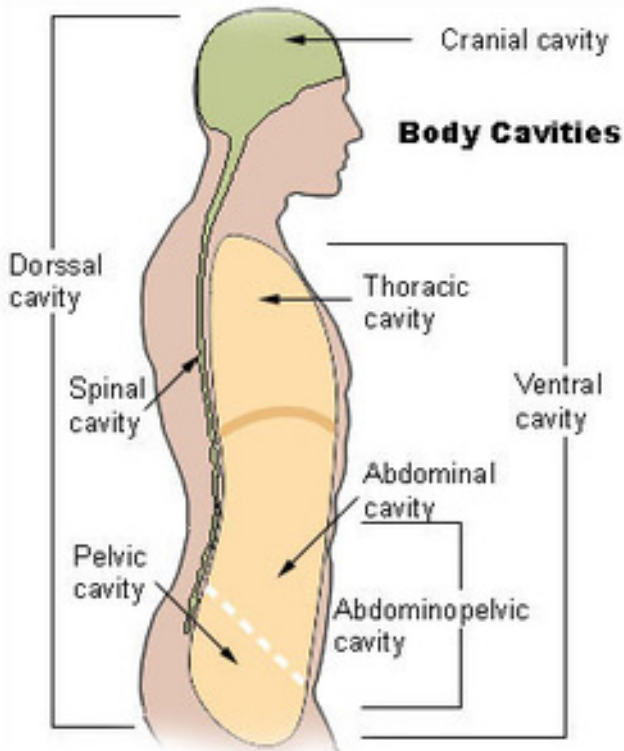
Homeostasis

- Define *homeostasis* and explain its importance.
- Define *negative feedback* and describe its role in maintaining homeostasis and normal body function.

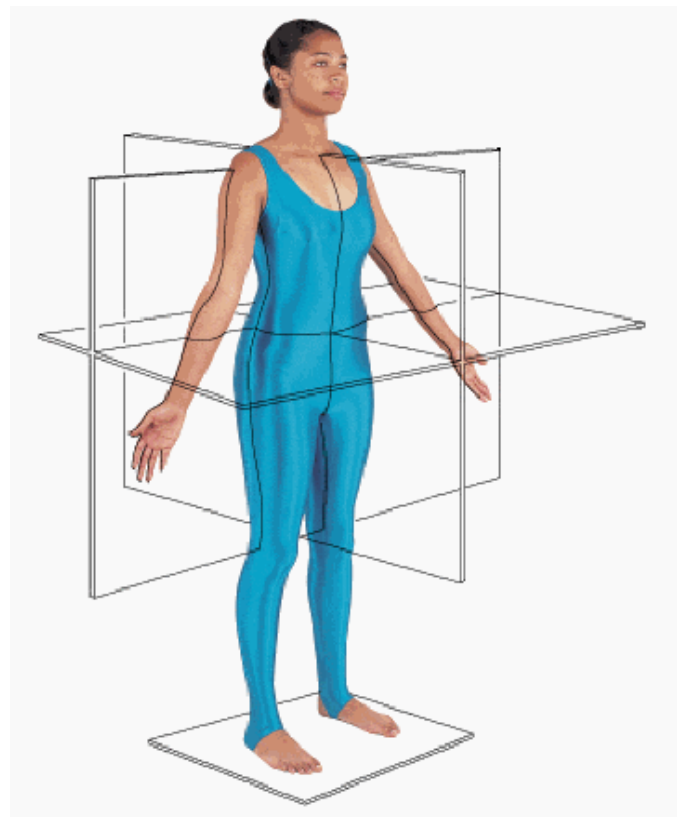
The Language of Anatomy

- Describe the anatomical position verbally or demonstrate it.
- Use proper anatomical terminology to describe body directions, surfaces, and body planes.
- Locate the major body cavities and list the chief organs in each cavity.

Body Orientation



Fold Your Paper...
Quiz Yourself...



Body Planes (see diagram)

Plane –

Median –

Sagittal –

Coronal or Frontal –

Transverse or Cross Horizontal –

Body Sections

Section -

Sagittal Section -

Midsagittal Section or Median Section -

Frontal or Coronal Section -

Tranverse or Cross Section -

Landmarks

Meatus – an opening or tunnel through any part of the body

Process – a thin projection or prominence

Projection – (protuberance) – something that juts out

Foramen – a hole or opening

Condyle – a rounded bump on a bone where it forms a joint with another bone or bones

Epicondyle – a projection on a bone, above another part, the condyle

Plate – a flat structure or part

Regional Terms: Anterior Body Landmarks

Abdominal –

Antecubital –

Axillary –

Brachial –

Buccal –

Cervical –

Digital –

Femoral –

Inguinal –

Oral –

Orbital –

Patellar –

Pubic –

Thoracic –

Umbilical –

Regional Terms: Posterior Body Landmarks

Deltoid –

Gluteal -

Lumbar -

Occipital -

Popliteal -

Scapular -

Sural -

Anatomical Directions or Positions

Anatomical Position –

Cranial/Superior -

Caudal/Inferior -

Anterior/Ventral -

Posterior/Dorsal -

Medial -

Lateral -

Intermediate -

Proximal -

Distal -

Superficial -

Deep -

Body Cavities (see diagram)

Dorsal Cavity -

Cranial Cavity –

Spinal Cavity –

Ventral Cavity -

Superior Thoracic Cavity –

Abdominopelvic Cavity –

Bone Markings

Projections Where Muscles Attach:

Tuberosity –

Crest –

Trochanter –

Line –

Tubercle –

Epicondyle –

Spine –

Projections That Form Joints:

Head –

Facet –

Condyle –

Ramus –

Depressions/Openings for Vessels/Nerves:

Meatus –

Sinus –

Fossa –

Groove –

Fissure –

Foramen –

Motions

Flexion –

Inversion –

Extension –

Eversion –

Hyperextension –

Dorsiflexion –

Rotation –

Plantar flexion –

Abduction –

Retraction –

Adduction –

Protraction –

Circumduction –

Elevation –

Lateral Flexion –

Depression –

Lateral/External Rotation –

Upward Rotation –

Medial/Internal Rotation –

Distraction (Traction) –

Supination –

Compression –

Pronation -

Opposition –

Radial/Ulnar Deviation -

Notes on Page Numbers for diagrams:

Muscle Attachments

Origin –

Insertion –

Tendon –

Muscle –

The Five Golden Rules of Skeletal Muscle Activity:

- 1 – All muscles cross at least one joint.
- 2 – Typically, the bulk of the muscle lies proximal to the joint crossed.
- 3 – All muscles have at least two attachments: the origin and the insertion.
- 4 – Muscles can only pull, they never push.
- 5 – During contraction, the muscle insertion moves toward the origin.

Types of Muscles

Prime Movers –

Antagonists –

Synergists –

Fixators -

GROUP CHALLENGE: Answer the following on a separate sheet of paper

Action: Lifting your backpack with your right hand from the floor to your right shoulder

Challenge: List each of the above in the order they are used.

Medical Imaging

MEDICAL RADIOGRAPHY:

PROJECTIONAL RADIOGRAPHS (X-RAYS)

FLUOROSCOPY

NUCLEAR MEDICINE:

GAMMA CAMERAS

PET (POSITRON-EMISSION TOMOGRAPHY)

TOMOGRAPHY:

CT OR CAT SCANS (COMPUTED TOMOGRAPHY or COMPUTED AXIAL TOMOGRAPHY)

LINEAR TOMOGRAPHY

ORTHOPANTOMOGRAPHY (OPT or OPG)

POLY TOMOGRAPHY

ZONOGRAPHY

DSR (DYNAMIC SPATIAL RECONSTRUCTION)

MEDICAL ULTRASONOGRAPHY or ULTRASOUND IMAGING

MRI (MAGNETIC RESONANCE IMAGING)

MPI (MAGNETIC PARTICLE IMAGING) - (FEB. 2009 BY ROYAL PHILIPS ELECTRONICS)

ELECTRON MICROSCOPY

PHOTOACOUSTIC IMAGING IN BIOMEDICINE

DIGITAL INFRARED IMAGING THERMOGRAPHY

THREE-DIMENSIONAL IMAGING

Group Bonus Opportunity

What are 3 new types of medical imaging that are in use or are in the process of being approved for use today? Describe each and the stage of use/approval.

PLANES, ORIENTATION, DIRECTION AND MOTION PRACTICE

- 1 As the ballroom dance couple waltzed around the floor, they maintained perfect posture in each other's _____ planes.
- 2 The Frisbee sailed over the players' head following the _____ plane.
- 3 As Lady pranced by Tramp, he "checked her out" from _____ to _____.
- 4 When Mary accepted John's proposal, he slipped the engagement ring onto her finger from the _____ to the _____ end.
- 5 Xena, seeing no other option to save the town from 'a really bad guy', slid her sword into the 'bad guy' from the _____ aspect of his abdomen to the _____ until he collapsed.
- 6 To perform access the man's beating heart, the Cardiothoracic Surgeon made a _____ Section along the sternum to break open the rib cage.
- 7 In performing a Mastectomy, the surgeon's first incision was into the _____ region of the woman's body.
- 8 So she wouldn't have a sore arm for softball practice, Theresa opted to have her shot in her _____ region.

- 9 To grasp the handle of the pencil sharpener, Sarah used finger _____
- 10 To perform Jumping Jacks in P.E. class, the students used _____ and _____ of the legs and arms.
- 11 To drink the hot chocolate from his mug, John used _____ of the wrist and forearm.
- 12 To release the Frisbee from her hand, Clara used _____ of the wrist to complete a perfect throw.
- 13 Look... up in the sky... it's a bird... it's a plane... it's _____ of the neck!
- 14 When the ballerina _____ her ankle to rise up onto the very tippy top of her toes, John thought to himself... 'Wow... that must *really* hurt!'
- 15 Julia was constantly _____ and _____ her scapula's in class to the point where other kids never had a chance to raise their hands.

MAKE YOUR OWN:

16

17

18

NAME: _____

Wake Up!

Directions: Describe the motions you use each morning to get ready for school. Match each action with its appropriate motion. You will NOT use all of the motions listed! You will not use any motion twice!

1. Getting out of bed... both feet are on the floor... to stand up you must...
 - a. feet _____
 - b. knees _____
 - c. hips _____

2. Washing your hair...
 - a. Your shoulders must _____ when moving in a superior direction
 - b. Your shoulders must _____ when moving in an inferior direction.

3. To put on deodorant...
 - a. The wrist of the applying hand must _____ and _____
 - b. The shoulder of the receiving underarm must _____

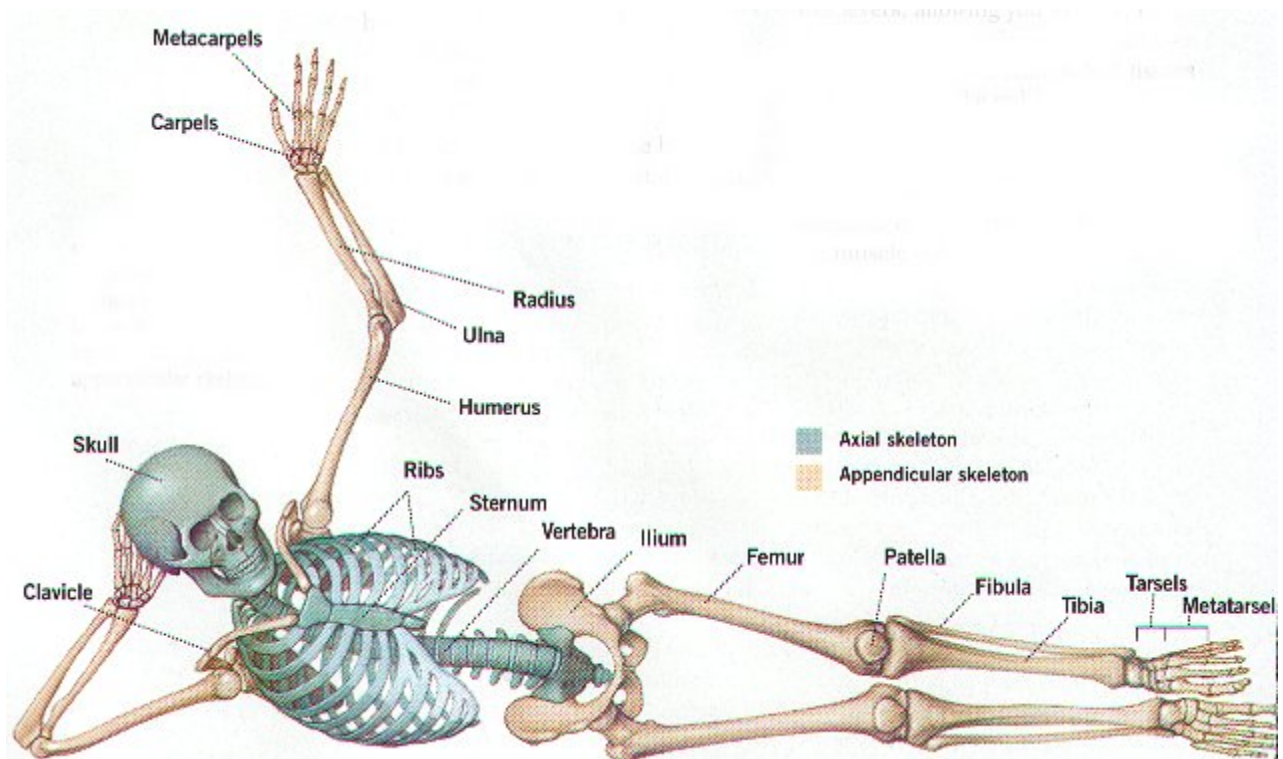
4. To put on your jeans...
 - a. To lift your leg into your jeans, your hip must _____
 - b. To push your foot through the opening at the bottom, your foot through the opening at the bottom, your knee must _____

5. To put your foot into your shoe...
 - a. Your foot must first _____

STUDENT ACTIVITIES:

- 1 **ASSUME THE ANATOMICAL POSITION. HOW DOES THIS POSITION DIFFER FROM THE “USUAL” STANDING POSITION? WHY IS KNOWING THIS POSITION IMPORTANT TO YOUR CURRENT STUDIES?**
- 2 **REMOVE ALL THE ORGANS FROM PAT... RETURN THEM TO THEIR PROPER ANATOMICAL LOCATION. AS YOU REPOSITION EACH ORGAN, SAY ITS NAME AND BODY CAVITY. WHAT ELSE CAN YOU TELL US ABOUT EACH ORGAN?**
- 3 **SHOW HOW A CHAIR WOULD BE CUT ALONG THE SAGITTAL, FRONTAL AND TRANSVERSE PLANCES. WHICH (IF ANY) OF THESE SECTIONS WOULD YIELD A “USEABLE” CHAIR? WHY WOULD THE OTHERS NOT?**
- 4 **WHY DO YOU THINK A DOG INSTINCTIVELY CURLS OVER AND PROTECTS ITS ABDOMEN WHEN THAT BODY REGION IS APPROACHED EVEN PLAYFULLY?**
- 5 **TWO PEOPLE HAVE RAPIDLY GROWING TUMORS. THE TUMOR IS IN THE DORSAL CAVITY IN ONE OF THESE INDIVIDUALS AND IN THE VENTRAL CAVITY IN THE OTHER. WHICH OF THESE PEOPLE WILL DEVELOP SYMPTOMS FIRST AND WHY?**
- 6 **YOUR TEACHER WILL CALL OUT ANATOMICAL TERMS. YOU AND YOUR CLASSMATES MUST POINT TO THE NAMED REGIONS OR AREAS ON YOUR OWN BODY.**
- 7 **HOW IS SCRATCHING AN ITCH AN EXAMPLE OF NEGATIVE FEEDBACK?**
- 8 **COMMENT ON THE FUNCTIONAL RELATIONSHIPS BETWEEN MUSCLES AND BONES.**
- 9 **COMMENT ON THE FUNCTIONAL RELATIONSHIPS BETWEEN THE RESPIRATORY AND CIRCULATORY SYSTEMS.**
- 10 **ACTIVITY ON THE IMPORTANCE OF RELATIVELY CONSTANT CONDITIONS ON OPTIMAL FUNCTIONING OF ANY SYSTEM:**
 - **USE A SIMPLE BATTERY-OPERATED CLOCK AS YOUR SUBJECT. WHAT WOULD HAPPEN IF IT WAS...**
 - a. **immersed in water**
 - b. **hit with a hammer**
 - c. **heated until it was red-hot**
 - d. **had its battery removed**
 - **WHAT CONDITIONS WOULD BE BEST SUITED FOR THE CLOCK TO OPERATE? WHAT SINGLE TERM DESCRIBES THOSE CONDITIONS?**
- 11 **WHAT IS THE MEANING OF THE WORD “ALIVE”? DEVELOP A LIST OF CHARACTERISTICS ASSOCIATED WITH BEING “ALIVE”.**
- 12 **PRINT, PHOTOCOPY OR CUT OUT AN ARTICLE FROM A RELIABLE SOURCE THAT DESCRIBES AN EVENT OR PROBLEM IN THE YEAR 2002-2003 THAT THREATENS HOMEOSTASIS – EVEN SURVIVAL. BE PREPARED TO DESCRIBE THE PROBLEM AND HOW IT REPRESENTS A THREAT TO THE BODY.**
- 13 **THE MAGNETIC HUMAN PROJECT.**

CHAPTER 5



THE SKELETAL SYSTEM

FUN FACTS OF LITTLE INTEREST TO NO ONE BUT ANATOMY GEEKS:

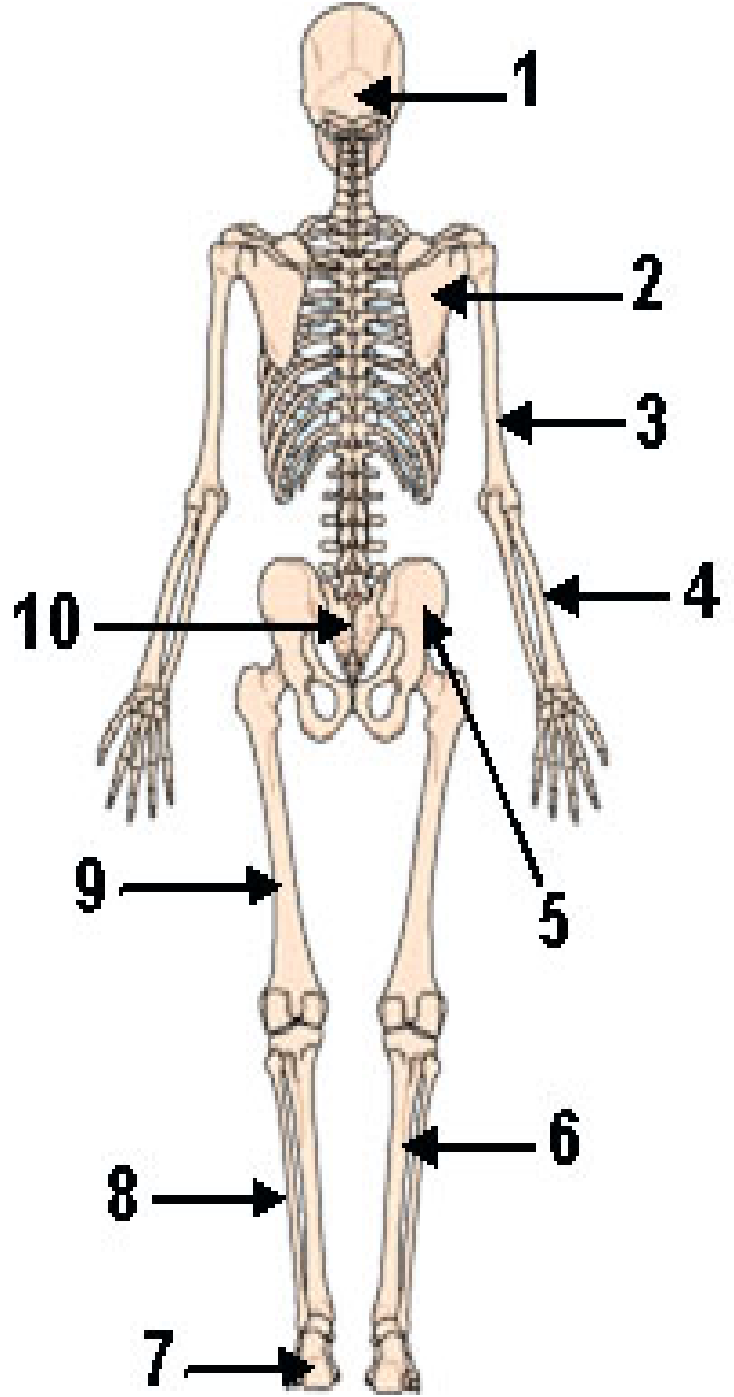
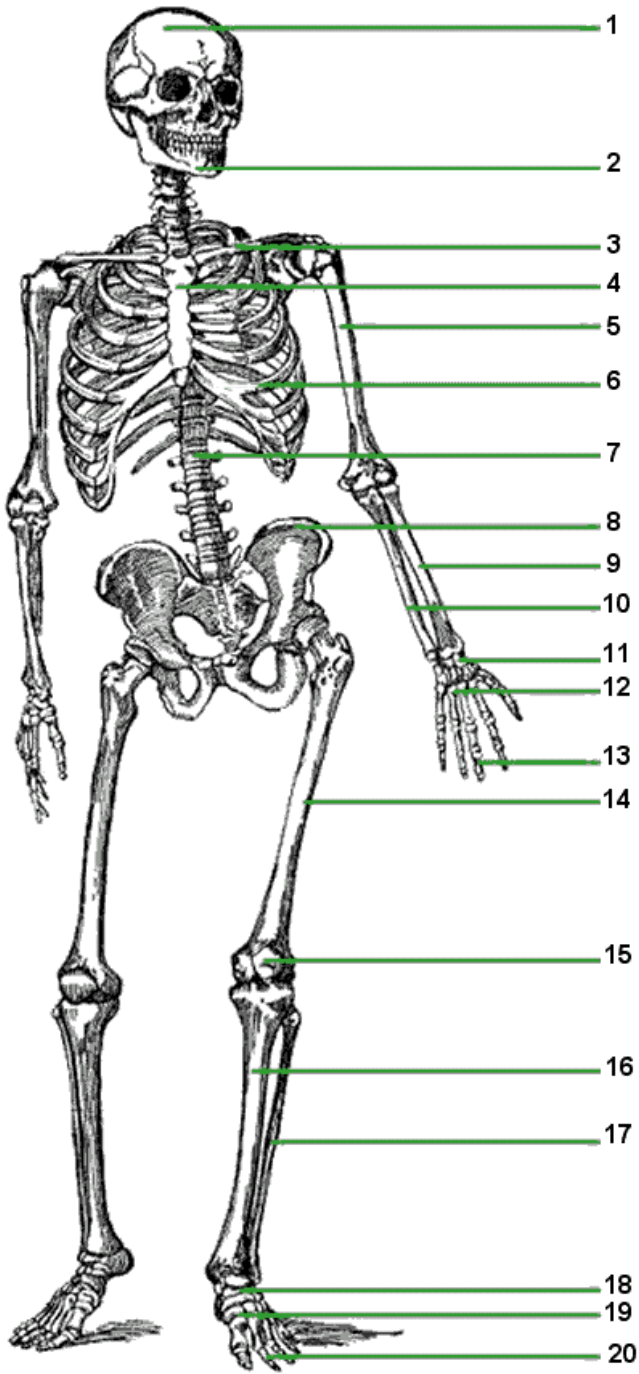
- ❖ Without the skeleton we would collapse... literally, we would fall down – no walking for us! We would have a great view of... the floor... nothing but a blob of stuffed skin!
- ❖ How many bones? You were born with over 300... some of those fused together over the years, so an adult skeleton has 206 bones with some people having less if one was removed, some more if they were born with an extra appendage or so.
- ❖ Our skeleton stays together because of ligaments that attach many of our bones to each other.
- ❖ Bones cannot move without the help of muscles. Muscles are attached to bones by tendons.
- ❖ Bones are alive... they are made up of many bone cells and have a blood supply. The blood supply brings food (nutrients) and oxygen to the bone and takes the waste products away.
- ❖ If a bone “dies”, it cannot repair itself and must either be fused to surrounding bone or replaced by an artificial joint or limb.

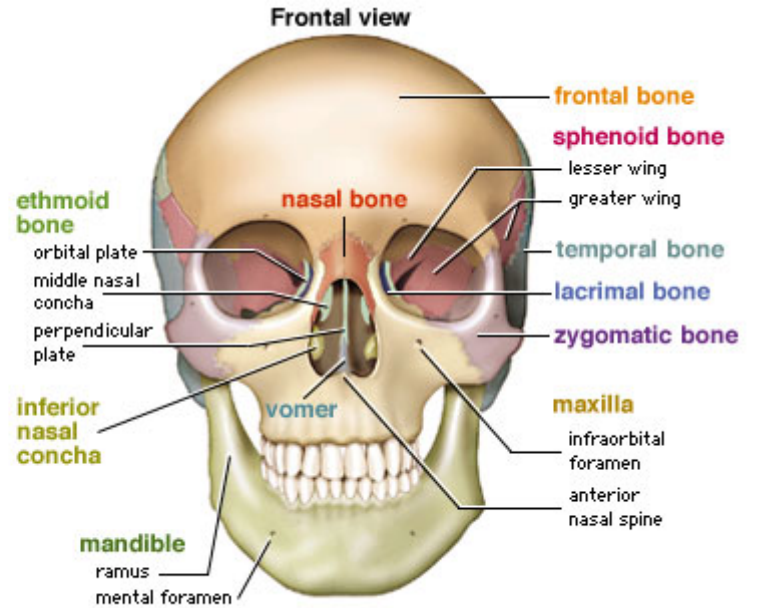
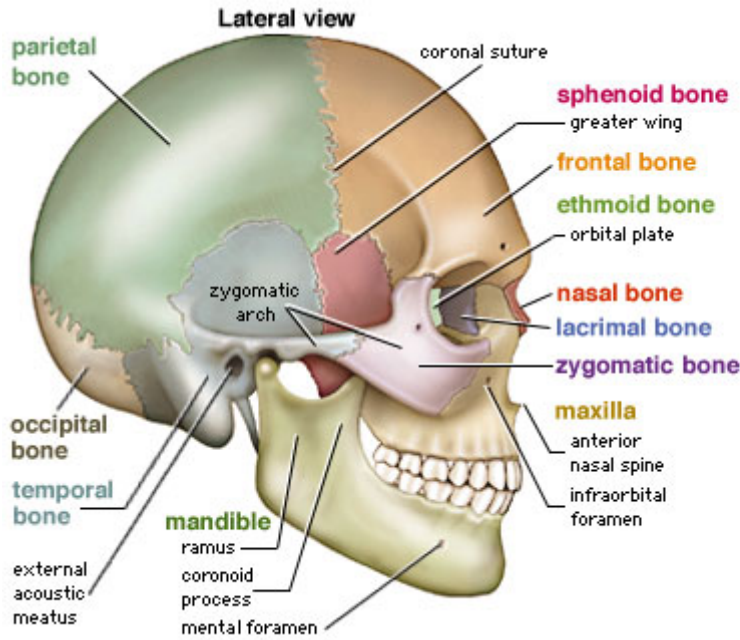
GATHER MORE FUN FACTS OF YOUR OWN!

CHAPTER 5: THE SKELETAL SYSTEM

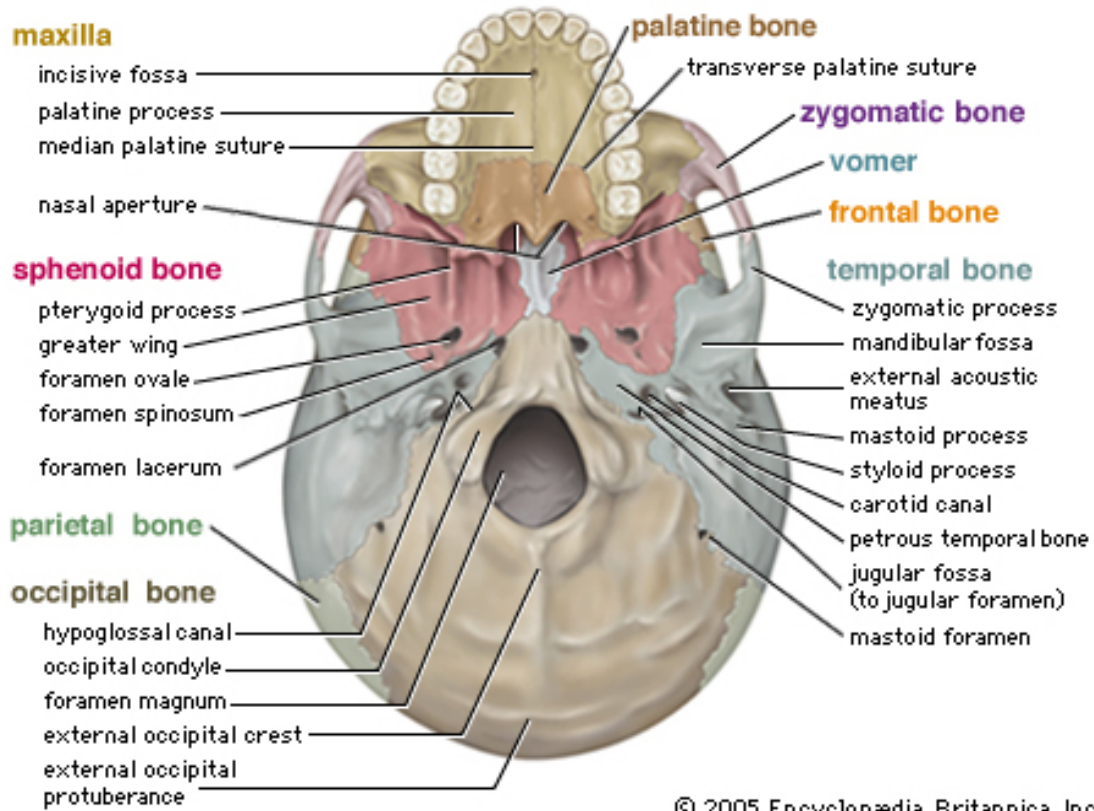
- I BONES: AN OVERVIEW**
 - A FUNCTIONS OF THE BONES**
 - B CLASSIFICATION OF BONES**
 - C STRUCTURE OF A LONG BONE**
 - 1. GROSS ANATOMY
 - 2. MICROSCOPIC ANATOMY
 - D BONE FORMATION, GROWTH, AND REMODELING**
 - E BONE FRACTURES**
- II AXIAL SKELETON**
 - A SKULL**
 - 1. CRANIUM
 - a. Frontal Bone
 - b. Parietal Bones
 - c. Temporal Bones
 - d. Occipital Bone
 - e. Sphenoid Bone
 - f. Ethmoid Bone
 - 2. FACIAL BONES
 - a. Mandible
 - b. Maxillae
 - c. Palatine Bones
 - d. Zygomatic Bones
 - e. Lacrimal Bones
 - f. Nasal Bones
 - g. Vomer Bone
 - h. Inferior Conchae
 - 3. THE HYOID BONE
 - 4. FETAL SKULL
 - B VERTEBRAL COLUMN (SPINE)**
 - 1. CERVICAL VERTEBRAE
 - 2. THORACIC VERTEBRAE
 - 3. LUMBAR VERTEBRAE
 - 4. SACRUM
 - 5. COCCYX
 - C BONY THORAX**
 - 1. STERNUM
 - 2. RIBS
- III APPENDICULAR SKELETON**
 - A BONES OF THE SHOULDER GIRDLE**
 - B BONES OF THE UPPER LIMBS**
 - 1. Arm
 - 2. Forearm
 - 3. Hand
 - C BONES OF THE PELVIC GIRDLE**
 - D BONES OF THE LOWER LIMBS**
 - 1. Thigh
 - 2. Leg
 - 3. Foot
- IV JOINTS**
 - A SYNARTHROSES**
 - B AMPHIARTHROSES**
 - C DIARTHROSES**
- V DEVELOPMENTAL ASPECTS OF THE SKELETON**

Practice Quiz: Full Anterior/Posterior Skeleton

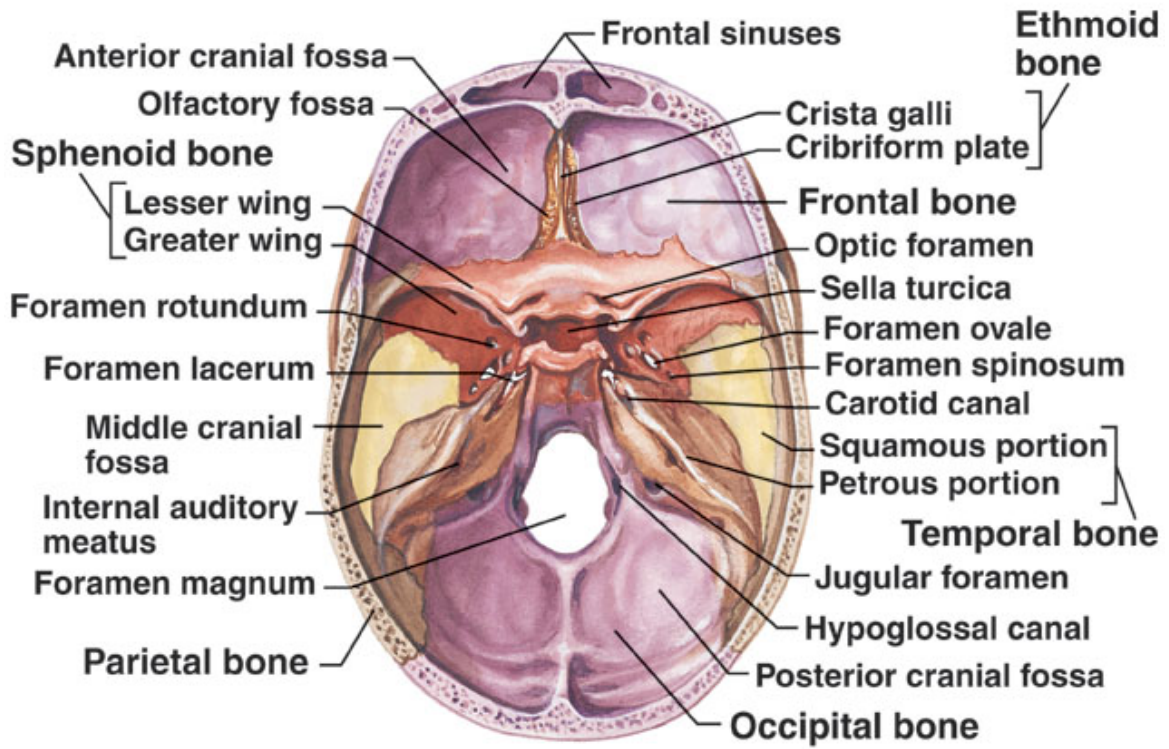


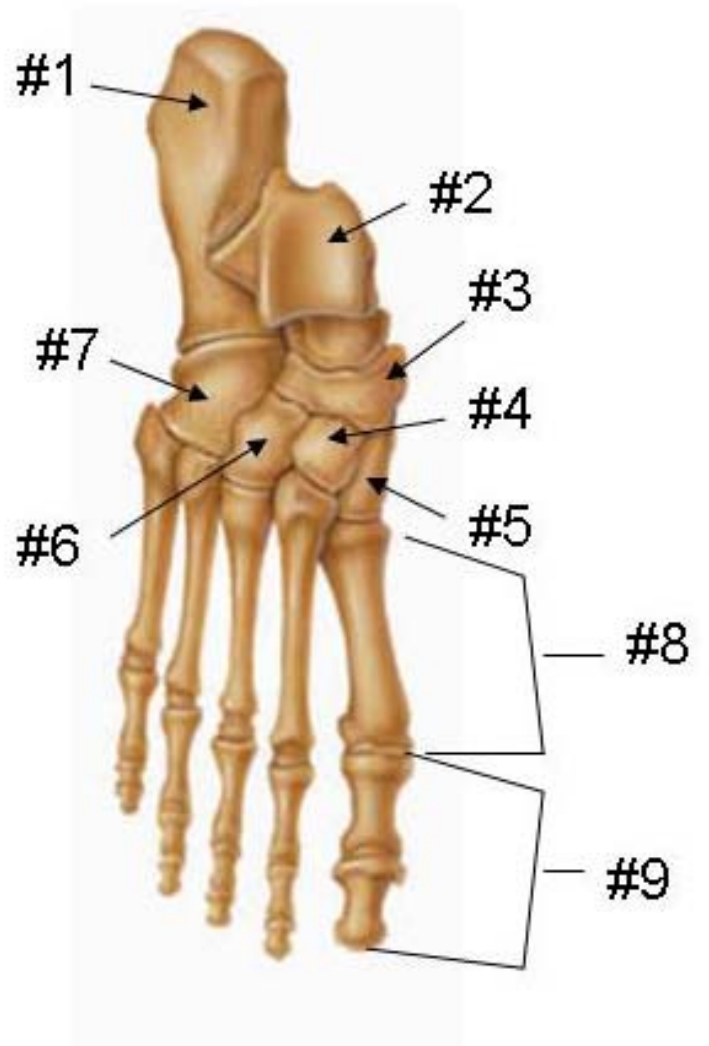
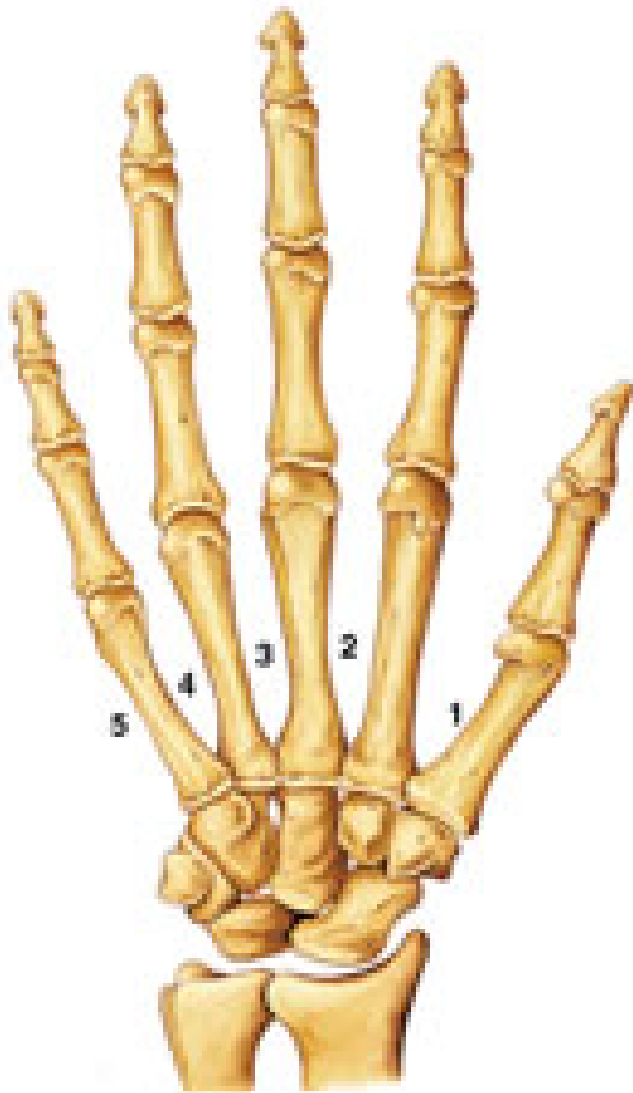


© 2003 Encyclopædia Britannica, Inc.

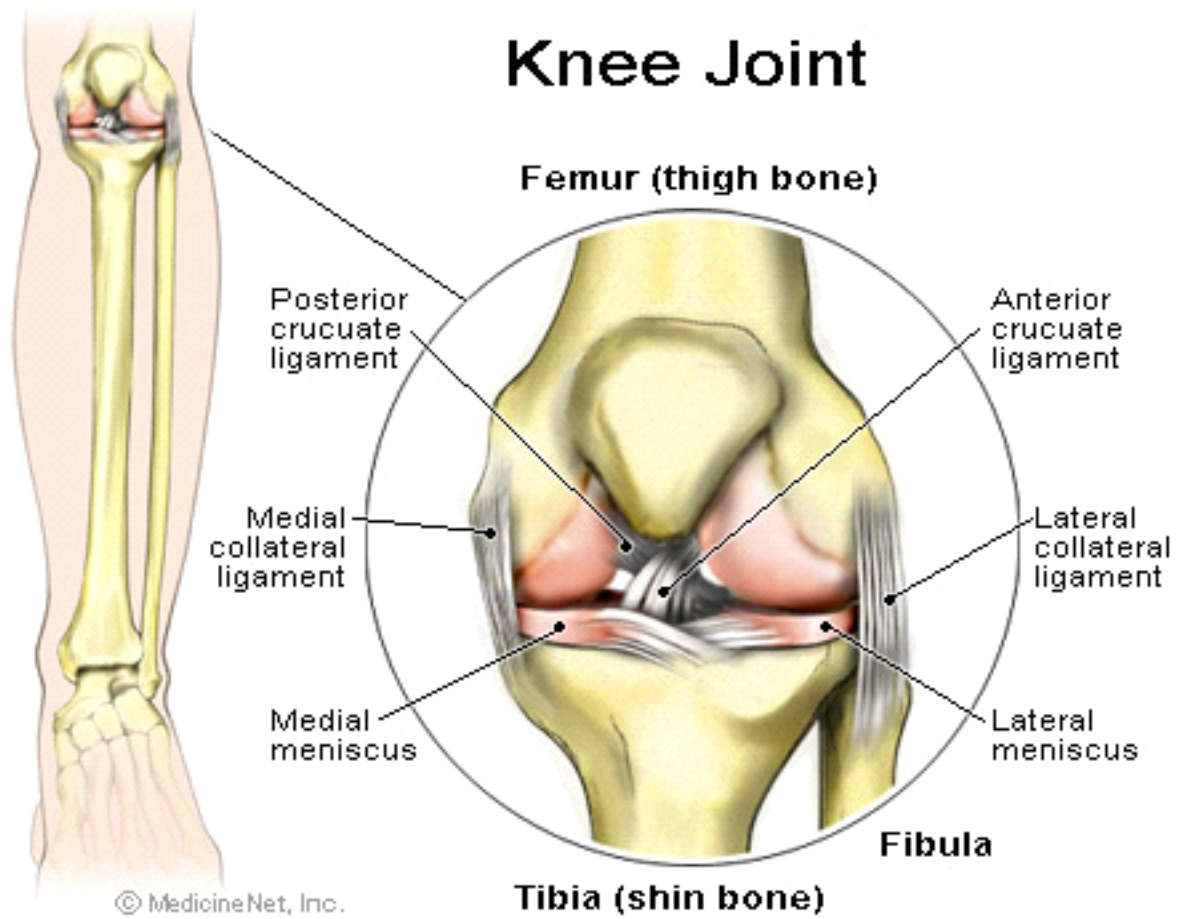


© 2005 Encyclopædia Britannica, Inc.





Knee Joint



LEARNING ANATOMY: THOUGHTS TO PONDER, ACTIVITIES TO TRY...

- 1 WHAT ARE THE DIFFERENCES BETWEEN THE SKELETONS OF: MALES AND FEMALES, ATHLETES AND SEDENTARY PEOPLE, YOUNG AND THE ELDERLY? HETEROTROPHIC BONES AND ACCESSORY BONES MAY BE FOUND IN MANY PEOPLE. WHAT INFORMATION CAN SKELETONS PROVIDE IN FORENSIC MEDICINE?**
- 2 DID YOU KNOW: OSTEOGENIC SARCOMA AND LEUKEMIA ARE COMMON CANCERS IN PEOPLE EXPOSED TO RADIATION BECAUSE OF THE DEPOSITION OF MINERALS IN BONE.**
- 3 BONE IS NOT A STATIC TISSUE... RATHER, IT IS VASCULAR AND CONSTANTLY PRODUCED AND REABSORBED FOR THE PURPOSE OF CALCIUM HOMEOSTASIS AND TO ALLOW IT TO ACCOMMODATE FUNCTIONAL AND GRAVITATIONAL STRESS. MODERATE WEIGHT-BEARING EXERCISE WILL STIMULATE BONE FORMATION AND MAY HELP PREVENT DISEASES SUCH AS OSTEOPOROSIS.**
- 4 OSSIFICATION IS INCOMPLETE AT BIRTH. WHAT IS THE TIMETABLE FOR OSSIFICATION?**
- 5 WHAT ARE THE RISK FACTORS FOR OSTEOPOROSIS? WHAT ARE SOME CURRENT TREATMENTS? WHAT ARE SOME PROPOSED FUTURE THERAPIES?**
- 6 DID YOU KNOW THAT YOU CAN STAND ON A CHINA CUP? THIS IS A DEMONSTRATION OF THE COMPRESSIONAL STRENGTH THAT CALCIUM/BONE SALTS PROVIDE TO BONE TISSUE. WHY? CAN YOU USE A LEATHER BELT TO DEMONSTRATE THE TENSILE STRENGTH THAT COLLAGEN PROVIDES TO BONE TISSUE?**
- 7 USING SKIPPY, DEMONSTRATE THE MOVEMENTS THAT ARE PERMITTED AT DIARTHROTIC JOINTS.**
- 8 USE SKIPPY AND HIS GRAVEYARD BONES TO LOCATE THE VARIOUS BONES OF THE SKELETON.**
- 9 IDENTIFY THE ROLES OF CALCIUM IN THE BODY (OTHER THAN MAKING BONES HARD)**
- 10 WHAT ARE THE VARIOUS HORMONAL INFLUENCES ON THE SKELETON? WHAT DRUGS ARE CURRENTLY USED TO HELP CORRECT GIGANTISM AND DWARFISM?**
- 11 WHY ARE INCOMPLETE OR GREENSTICK FRACTURES MORE COMMON IN CHILDREN THAN IN ADULTS?**
- 12 CLASSIFY THE BONES OF SKIPPY'S GRAVEYARD AS LONG, SHORT, FLAT OR IRREGULAR.**

BONE LIST

1ST INCISOR	HEAD OF RADIUS	PELVIC BRIM (ARCUATE LINE)
1ST MOLAR	HUMERUS	PHALANGES
2ND INCISOR	ILIAC CREST	PISIFORM
2ND PREMOLAR	ILIAC FOSSA	POSTERIOR INFERIOR ILIAC SPINE
ACETABULUM	INFERIOR ANGLE	PROXIMAL PHALANX
ACROMIOCLAVICULAR JOINT	INFERIOR PUBIC RAMUS	PROXIMAL TIBIOFIBULAR JOINT
ACROMION PROCESS	INFRASPINOUS FOSSA	PUBIC SYMPHYSIS
ALVEOLAR MARGINS	INTERCONDYLAR EMINENCE	RADIAL TUBEROSITY
ANTERIOR BORDER OF TIBIA	INTERCOSTAL CARTILAGE	RADIUS
ANTERIOR INFERIOR ILIAC SPINE	INTERTROCHANTERIC CREST	SACRAL SPINE
ATLAS	INTERTUBERCULAR GROOVE	SACROILIAC JOINT
AXILLARY BORDER	INTERVERTEBRAL DISK	SACRUM
AXIS	IP JOINT	SCAPULA
BASE OF METACARPAL	ISCHIAL SPINE	SCAPULAR SPINE
BODY OF STERNUM	LACRIMAL BONE	SPHENOID BONE
BODY OF VERTEBRA	LAMBDOIDAL SUTURE	SPINOUS PROCESS
CALCANEUS	LATERAL CONDYLE	SQUAMOUS SUTURE
CANINE TEETH	LATERAL EPICONDYLE	STYLOID PROCESS OF RADIUS
CAPITULUM	LATERAL MALLEOLUS	STYLOID PROCESS OF SKULL
CARPAL BONES	LATERAL PTERYGOID PLATE	STYLOID PROCESS OF ULNA
CERVICAL SPINE	LESSER TROCHANTER	SUPERIOR ANGLE
COCCYX	LESSER TUBERCLE	SUPERIOR ARTICULAR PROCESS
CORACOID PROCESS	LUMBAR SPINE	SUPERIOR BORDER
CORONAL SUTURE	LUMBAR VERTEBRA	SUPERIOR PUBIC RAMUS
CRANIUM	LUNATE	TALOCRURAL JOINT (ANKLE)
CUBOID	MANDIBLE	TALUS
DISTAL PHALANX	MANDIBULAR FOSSA	TARSAL BONES
DISTAL TIBIOFIBULAR JOINT	MANDIBULAR RAMUS	TEMPORAL BONES
ETHMOID BONE	MANUBRIUM	TEMPORALMANDIBULAR JOINT
EXTERNAL AUDITORY MEATUS	MASTOID BONE	THORACIC SPINE
EXTERNAL OCCIPITAL PROTUBERANCE	MAXILLA	THORACIC VERTEBRA
FALSE PELVIS	MEDIAL EPICONDYLE	TIBIA
FALSE RIB	MEDIAL MALLEOLUS	TIBIAL TUBEROSITY
FEMUR	MEDIAL PTERYGOID PLATE	TRANSVERSE PROCESS
FIBULA	METACARPAL	TRAPEZIUM
FLOATING RIB	METATARSAL	TROCHLEA
FORAMEN MAGNUM	MIDDLE PHALANX	TROCHLEAR NOTCH
FRONTAL BONE	MP JOINT	TRUE PELVIS
GLABELLA	NASAL BONE	TRUE RIB
GLENOHUMERAL JOINT	NAVICULAR	ULNA
GLENOID FOSSA	NECK OF FEMUR	VERTEBRAL BORDER
GREATER TROCHANTER	OBTURATOR FORAMEN	VERTEBRAL FORAMINA
GREATER TUBERCLE	OCCIPITAL BONE	VOMER
GREATER WING OF SPHENOID	OCCIPITAL CONDYLES	XIPHOID PROCESS
HAMATE	OLECRANON PROCESS	ZYGOMATIC BONE
HEAD OF FEMUR	PALATINE BONE	ZYGOMATIC PROCESS
HEAD OF FIBULA	PARIETAL PROCESS	LORDOSIS
HEAD OF HUMERUS	PATELLA	KYPHOSIS
HEAD OF METACARPAL		

CHAPTER 6

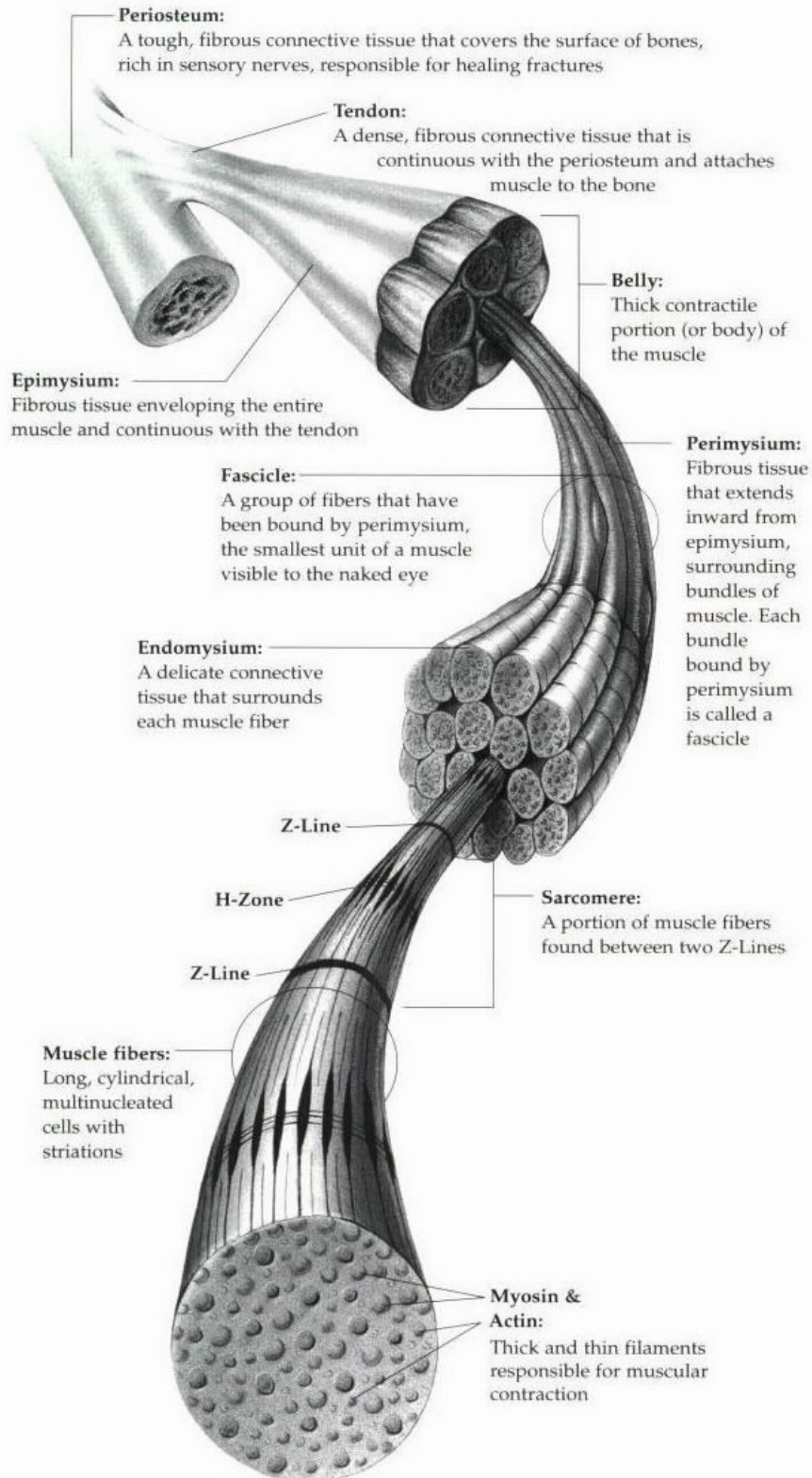
THE MUSCULAR SYSTEM

CHAPTER 6: THE MUSCULAR SYSTEM

- I OVERVIEW OF MUSCLE TISSUES
 - A MUSCLE FUNCTIONS
 - B MUSCLE TYPES
 - 1 Skeletal muscle
 - 2 Smooth muscle
 - 3 Cardiac muscle
- II MUSCLE ACTIVITY
 - A STIMULATION AND CONTRACTION OF SINGLE SKELETAL MUSCLE CELLS
 - 1 The Nerve Stimulus and Action Potential
 - 2 Mechanism of Muscle Contraction: The Sliding Filament Theory
 - B CONTRACTION OF A SKELETAL MUSCLE AS A WHOLE
 - 1 Graded Responses
 - a Muscle Response to Increasingly Rapid Stimulation
 - b Muscle Response to Stronger Stimuli
 - 2 Muscle Fatigue and Oxygen Debt
 - 3 Types of Muscle Contractions – Isometric, Isotonic, Isokinetic
 - 4 Muscle Tone
 - 5 Effect of Exercise on Muscles
- III BODY MOVEMENTS AND NAMING SKELETAL MUSCLES
 - A TYPES OF BODY MOVEMENTS
 - B TYPES OF MUSCLES
 - C NAMING SKELETAL MUSCLES
- IV GROSS ANATOMY OF SKELETAL MUSCLES
 - A HEAD MUSCLES
 - 1 FACIAL MUSCLES
 - a Frontalis
 - b Orbicularis Oculi
 - c Orbicularis Oris
 - d Buccinator
 - e Zygomaticus
 - 2 CHEWING MUSCLES
 - a Masseter
 - b Temporalis
 - B TRUNK AND NECK MUSCLES
 - 1 ANTERIOR MUSCLES
 - a Sternocleidomastoid
 - b Pectoralis Major
 - c Intercostal Muscles
 - d Muscle of the Abdominal Girdle
 - 2 POSTERIOR MUSCLES
 - a Trapezius
 - b Latissimus Dorsi
 - c Deltoid
 - C MUSCLES OF THE UPPER LIMB
 - 1 MUSCLES OF THE HUMERUS THAT ACT ON THE FOREARM
 - a Biceps Brachii
 - b Triceps Brachii
 - D MUSCLES OF LOWER LIMB
 - 1 MUSCLES CAUSING MOVEMENT AT THE HIP JOINT
 - a Iliopsoas
 - b Adductor Muscles
 - c Gluteus Maximus
 - d Gluteus Medius
 - 2 MUSCLES CAUSING MOVEMENT AT THE KNEE JOINT
 - a Sartorius
 - b Quadriceps Group
 - c Hamstring Group
 - 3 MUSCLES CAUSING MOVEMENT AT THE ANKLE AND FOOT
 - a Tibialis Anterior
 - b Peroneus Muscles
 - c Gastrocnemius
- V DEVELOPMENTAL ASPECTS OF THE MUSCULAR SYSTEM

MUSCLE PHYSIOLOGY STUDY GUIDE

Muscle Anatomy



I. THREE TYPES OF MUSCLE TISSUE FOUND IN THE HUMAN BODY

- A. SMOOTH

- B. CARDIAC

- C. SKELETAL

II. THE GENERAL CHARACTERISTICS AND PROPERTIES OF EACH ARE:

PROPERTIES	SMOOTH	CARDIAC	SKELETAL
FIBER LENGTH	50-200	NA	25,000
MARKINGS	NON-STRAITED	STRIATIONS	STRIATIONS
NUCLEI	SINGLE	SINGLE	MULTIPLE
CONTRACTION	VERY SLOW	MODERATE	VERY QUICK
EFFECT OF CUT NERVE FIBER	SLIGHT	SLIGHT	TOTAL PARALYSIS

III. SKELETAL MUSCLE

- A. SKELETAL MUSCLE IS HIGHLY SPECIALIZED TO AND SPECIFICALLY ADAPTED TO CARRY OUT THREE MAJOR FUNCTIONS
 - 1. BODY MOTION
 - 2. HEAT PRODUCTION (40%-50% OF HEAT PRODUCTION)
 - 3. POSTURE AND BODY SUPPORT

- B. SKELETAL SYSTEM DIVIDED INTO TWO GROUPS
 - 1. MUSCLES OF THE AXIAL SKELETON (FACIAL, MASTICATION, NECK, EYE, VERTEBRAE)
 - 2. MUSCLES OF THE APPENDICULAR SKELETAL (GIRDLES, APPENDAGES)

- C. TERMINOLOGY ASSOCIATED WITH MUSCLES
 - 1. ORIGIN - STATIONARY ATTACHMENT
 - 2. INSERTION - MOVEABLE ATTACHMENT
 - 3. TENDON - ATTACH MUSCLE TO BONE
 - 4. GASTER - MUSCLE BULK
 - 5. APONEUROSIS - SHEETLIKE LAYER OF CONNECTIVE TISSUE

D. DESCRIPTION OF THE ANATOMY OF SKELETAL MUSCLE

1. THE ENTIRE MUSCLE IS WRAPPED IN A SHEATH CALLED THE EPIMYSIUM
2. THE PERIMYSIUM SEPARATES THE MUSCLE INTO BUNDLES OR FASCICLES
3. THE ENDOMYSIUM SEPERATES EACH INDIVIDUAL MUSCLE CELL
4. EACH MUSCLE FIBER (CELL) CONTAINS MYOFIBRILS
5. EACH MYOFIBRIL CONTAINS THE CONTRACTILE PROTEINS MYOSIN AND ACTIN
6. EACH MUSCLE FIBER (CELL) IS SURROUNDED BY A PLASMA MEMBRANE CALLED THE SARCOLEMMA
7. THE CYTOPLASM OF THE CELL IS CALLED THE SARCOPLASM
8. THE SARCOPLASMIC RETICULUM IS A NETWORK MEMBRANE ENCLOSED TUBULES THAT FORM A SLEEVE AROUND EACH MYOFIBRIL (IMPORTANT IN METABOLIC FUNCTION)
9. THE T-TUBULES RUN TRANSVERSE THROUGH THE MUSCLE FIBER AND ARE INTERNAL EXTENSIONS OF THE SARCOLEMMA
10. THE T-TUBULES AND THE RETICULUM ARE INVOLVED IN THE TRANSMISSION OF THE NERVE IMPULSE TO THE MUSCLE FIBER

E. DESCRIPTION OF MUSCLE STRIATIONS

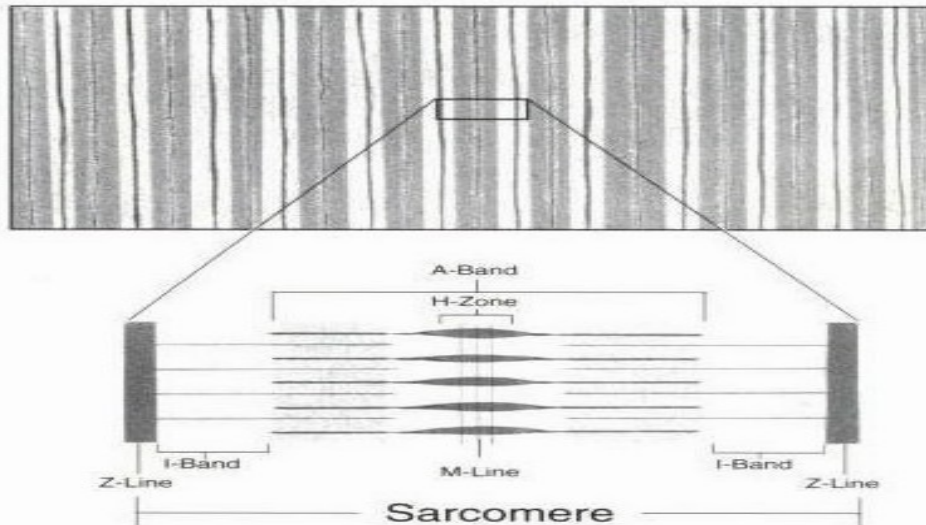
1. I BAND
ACTIN FILAMENTS (LIGHT)
2. A BAND
MYOSIN (DARK) AND OVERLAPPING ACTIN FIBERS
3. H BAND
PORTION OF MYOSIN NOT OVERLAPPING ACTIN
4. Z BAND
IN THE MIDDLE OF I BAND (BOUNDARY) AND ARE THE UNITS OF CONTRACTIONS

Muscle-Micro Anatomy

Each muscle cell is encapsulated in a membrane called a sarcolemma. Within each cell are hundreds of long, thread-like structures called *myofibrils* that run parallel to each other. Each myofibril is made of smaller strands called *myofilaments*. These strands are the basis of muscle contraction. There are two types of myofilaments: *actin* and *myosin*.

The characteristic striation that appears on muscle histology slides is caused by overlapping myofilaments. Actin filaments are thin strands and appear lighter when overlapping each other. Myosin strands are thicker and appear darker when overlapping each other.

Skeletal Muscle Fibers



Each contraction subunit, or sarcomere, extends from one Z-line to the next Z-line. Each sarcomere consists of two I-bands, two Z-lines, one A-band, one H-zone and one M-line.

I-band: The width is made of actin filaments. It extends from the edge of one stack of myosin filaments to the next.

Z-line: This line defines the union point of two sarcomeres and the anchoring point of actin filaments.

A-band: This band extends over the length of a stack of myosin filaments. The outer edges of an A-band appear darker than the center due to actin filaments partially extending into the A-band.

H-zone: The lighter center of an A-band consisting of only stacks of myosin filaments.

M-line: A dark line through the center of the H-zone that depicts lateral connections between myosin filaments.

Contraction

Individual muscle cells typically do not extend the length of the muscle. The uniform force of a contraction is generated by connective tissue that binds the muscle fibers together. As a contraction occurs, all the bundles move as a complete unit.

During a contraction, the distance between Z-lines is decreased due to myosin filaments sliding across actin filaments. Cross-bridges (minute protrusions from myosin filaments) extend out toward actin filaments. When a contraction occurs, these cross-bridges attach to actin filaments and pull the actin filaments and Z-lines toward the center of the A-band. The A-band remains the same length during a contraction, while the I-band and H-zone shorten.

F. MUSCLE CONTRACTION

1. MUSCLE FIBER IS STIMULATED BY A NERVE FIBER THAT RELEASES ACETYLCHOLINE
2. ACETYLCHOLINE CAUSES THE MUSCLE FIBER TO CONDUCT AN IMPULSE THAT REACHES THE DEEP PARTS OF THE FIBER
3. A MUSCLE IMPULSE SIGNALS THE SARCOPLASM TO RELEASE CALCIUM IONS
4. CROSS BRIDGES FORM BETWEEN ACTIN AND MYOSIN AND THE ACTIN GIBER MOVES INWARD
 - a. TROPOMYOSIN IS FOUND ON THE ACTIN FILAMENT
 - b. TROPONIN ATTACHED TO THE SURFACE OF TROPOMYOSIN
 - c. AT REST THIS ARRANGEMENT PREVENTS CROSS BRIDGES
 - d. CALCIUM CHANGES ARRANGEMENT AND ALLOWS CROSS BRIDGES
5. MUSCLE FIBERS RELAX WHEN THE CALCIUM IONS MOVE BACK TO THE SARCOPLASM
6. CHOLINESTERASE DECOMPOSES ACETYICHOLINE
7. ATP SUPPPLIES ENERGY NEEDED FOR MUSCLE CONTRACTION
8. CREATINE PHOSPHATE STORES ENERGY THAT CAN BE USED TO PRODUCE ATP
9. ACTIVE MUSCLES DEPEND ON RESPIRATION AND AS A RESULT PRODUCE HEAT

G. OXYGEN SUPPLY AND OXYGEN DEBT

1. ANAEROBIC RESPIRATION PRODUCES FEW ATP MOLECULES
2. AEROBIC RESPIRATION PRODUCES THE BULK OF ATP AND REQUIRES OXYGEN
3. MYOGLOBIN STORES OXYGEN IN THE MUSCLE FIBER
4. OXYGEN DEBT OCCURS DURING STRENUOUS EXERCISE WHEN OXYGEN IS DEPLETED AND LACTIC ACID FORMS
5. THE AMOUNT OF OXYGEN NEEDED TO CONVERT LACTIC ACID TO GLUCOSE AND RESTORE ATP SUPPLY IS OXYGEN DEBT
6. THE CONVERSION OF LACTIC ACID TO GLUCOSE OCCURS IN THE LIVER

H. MUSCLE FATIGUE

1. A FATIGUED MUSCLE LOSES THE ABILITY TO CONTRACT
2. MUSCLE FATIGUE IS DUE TO ACCUMULATED LACTIC ACID
3. ATHLETES PRODUCE LESS LACTIC ACID BECAUSE OF THE ABILITY TO SUPPLY OXYGEN IN GREATER AMOUNTS

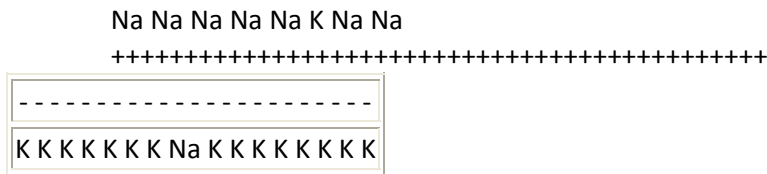
IV. MUSCULAR RESPONSES

- A. THRESHOLD STIMULUS IS THE MINIMAL STIMULUS NEEDED FOR MUSCULAR CONTRACTION
- B. THE ALL OR NON RESPONSE OF A MUSCLE MEANS IF IT CONTRACTS, IT WILL CONTRACT COMPLETELY
 1. MOTOR UNITS
 2. RECRUITMENT OF MOTOR UNITS
 - a. LOW STIMULUS INTENSITY FEW CONTRACT
 - b. HIGH LEVEL STIMULUS ALL MAY CONTRACT
- C. STAIRCASE EFFECT (TREPPE)
 1. INACTIVE MUSCLE UNDERGOES A SERIES OF TWITCHES
 2. EACH STIMULUS IS OF INCREASING STRENGTH
 3. STAIRCASE EFFECT IS DUE TO FAILURE TO REMOVE ALL CALCIUM IONS

- D. SUSTAINED CONTRACTIONS
 - 1. A RAPID SERIES OF TWITCHES MAY PRODUCE SUMMATION OF TWITCHES OR A SUSTAINED CONTRACTION
 - 2. WHEN THERE IS NO RELAXATION THE CONTRACTION IS TERMED TETANIC (TETANUS)
- E. RECORDING A MUSCLE CONTRACTION
 - 1. LATENT PERIOD - TIME BETWEEN STIMULUS AND CONTRACTION
 - 2. REFRACTORY PERIOD - BRIEF TIME BETWEEN CONTRACTIONS WHEN A MUSCLE FIBER WILL NOT CONTRACT

V. DEPOLARIZATION OF MEMBRANES

- A. AT REST THE INTERIOR OF A CELL MEMBRANE IS NEGATIVE AND THE OUTSIDE POSITIVE
- B. THE INTERIOR CONTAINS MANY TIMES MORE POTASSIUM IONS THAN SODIUM. THE EXTERIOR CONTAINS MORE SODIUM THAT POTASSIUM



- C. Na / K PUMP MAINTAINS AMOUNT
- D. DIFFERENCE IN CHARGE IS THE RESTING POTENTIAL
- E. WHEN NERVE RELEASES ACETYLCHOLINE, MEMBRANE CHANGES PERMEABILITY
- F. OUTSIDE IS NEGATIVE, INSIDE IS POSITIVE
- G. SYNAPTIC CLEFT IS 200 ANGSTROMS WIDE (ANGSTROM IS 8-10cm)
- H. DEPOLARIZATION BEGINS AT ACETYLCHOLINE RECEPTORS
- I. ACETYLCHOLINE CAUSES CHANNELS TO OPEN AND K AND Na TO DIFFUSE
- J. CONTINUES USUALLY IN WAVES

VI. MUSCLES

TERMS

- SARCOLEMMA:** MUSCLE CELL MEMBRANE
- MUSCLE FIBER:** MUSCLE CELL
- MYOFIBRILS:** SUB UNITS OF MUSCLE FIBERS, SEVERAL HUNDRED TO SEVERAL THOUSAND
- FILAMENT:** 1500 MYOSIN (APPROXIMATE) 3000 ACTIN (ESTIMATED)
- MYOSIN:** LARGE FILAMENT, GLOBULAR HEAD
- ACTIN:** THIN FILAMENT
- I BAND (LIGHT):** ISOTROPIC (EQUAL REFRACTION OF LIGHT) TO LIGHT, CONTAINS ONLY ACTIN
- A BAND (DARK):** ANISOTROPIC (UNEQUAL REFRACTION OF LIGHT) TO LIGHT

H ZONE:	MYOSIN ONLY
SARCOPLASM:	CYTOPLASM OF THE MUSCLE CELL
SARCOPLASMIC RETICULUM:	ENDOPLASMIC RETICULUM OF THE MUSCLE CELL
MOTOR END PLATE:	AREA OF SARCOPLASM ADJACENT TO AXON TERMINAL
TELODENDRIUM:	AXON TERMINAL
MYONEURAL JUNCTION:	MOTOR END PLATE AND AXON TERMINAL
SYNAPTIC BULB:	AAT END OF AXON
SYNAPTIC VESICLES:	STORE ACETYLCHOLINE
SYNAPTIC GUTTER:	TROUGH IN SARCOLEMMA UNDER BULB
SYNAPTIC CLEFT:	SPACE BETWEEN AXON AND SARCOLEMMA
SUBNEURAL CLEFT:	FOLDS IN SARCOLEMMA ALONG SARCOLEMMA ALONG GUTTER

MYOSIN FILAMENT - MW 480,000
200+ MYOSIN MOLECULES

MUSCLE ACTION POTENTIAL

-80 TO -90 MILLIVOLTS (SAME AS MYELINATED NERVE FIBERS)

DURATION: 1-5 MILLISECONDS (5 TIMES AS LONG AS MYELINATED NERVE)

VELOCITY: 3-5 METERS PER SECOND (1/18 THE VELOCITY OF NERVE CONDUCTION)

FIBERS

TYPE I: SLOW TWITCH, SLOW OXIDATIVE HIGH # MITOCHONDRIA, HIGH IN GLYCOGEN

TYPE IIB: FAST TWITCH, FAST OXIDATIVE HIGH # MITOCHONDRIA, LOW IN GLYCOGEN

TYPE IIA: FAST TWITCH, FAST OXIDATIVE

****MOST MUSCLE CONTAINS ALL THREE**

GROUPS

SLOW - SOLEUS

MODERATE - GASTROCNEMIUS

FAST - EYE MUSCLES

TWITCH SLOW VS FAST

OCULAR MUSCLE: 1/40 SECOND NEEDED FOR EYE MOVEMENT

GASTROCNEMIUS: 1/15 SECOND NEEDED FOR MODERATE WALKING OR JUMPING

SOLEUS: 1/5 SECOND (SLOW) NEEDED ONLY FOR SLOW REACTIONS TO SUPPORT BODY AGAINST GRAVITY

MUSCLE CONTRACTION RECORDINGS ON MYOGRAM

LATENT PERIOD - 10 M SEC

CONTRACTION - 40 M SEC

RELAXATION - 50 M SEC

REFRACTORY PERIOD: WHEN MUSCLE WILL NOT RESPOND TO ADDITIONAL STIMULI

TREPPE (STAIR CASE): CAUSED BY INCREASED CALCIUM

TETANUS: TWO STIMULI, SECOND DELAYED UNTIL AFTER REFRACTORY BUT BEFORE MUSCLE IS RELAXED = WAVE SUMMATION

MULTIPLE MOTOR UNIT SUMMATION: SEVERAL STIMULI AT SAME TIME BUT AT DIFFERENT LOCATIONS

UNFUSED TETANUS: 20-30 STIMULI PER SECOND WITH ONLY PARTIAL RELAXATION

FUSED TETANUS: 35-50 STIMULI PER SECOND WITH NO RELAXATION (CAUSED BY ADDITIONAL CALCIUM PRESENT)

REGENERATION OF MUSCLE TISSUE

SKELETAL: MUSCLE FIBERS CAN'T DIVIDE

***AFTER FIRST YEAR OF LIFE ALL GROWTH IS BY HYPERTROPHY RATHER THAN HYPERPLASIA*

SATELLITE CELL: STEM CELLS (DORMANT)

-DURING POST NATAL GROWTH SATELLITE FUSE WITH MUSCLE FIBERS INCREASE LENGTH AND PERSIST AS A LIMITED LIFE LONG SOURCE OF MUSCLE CELLS

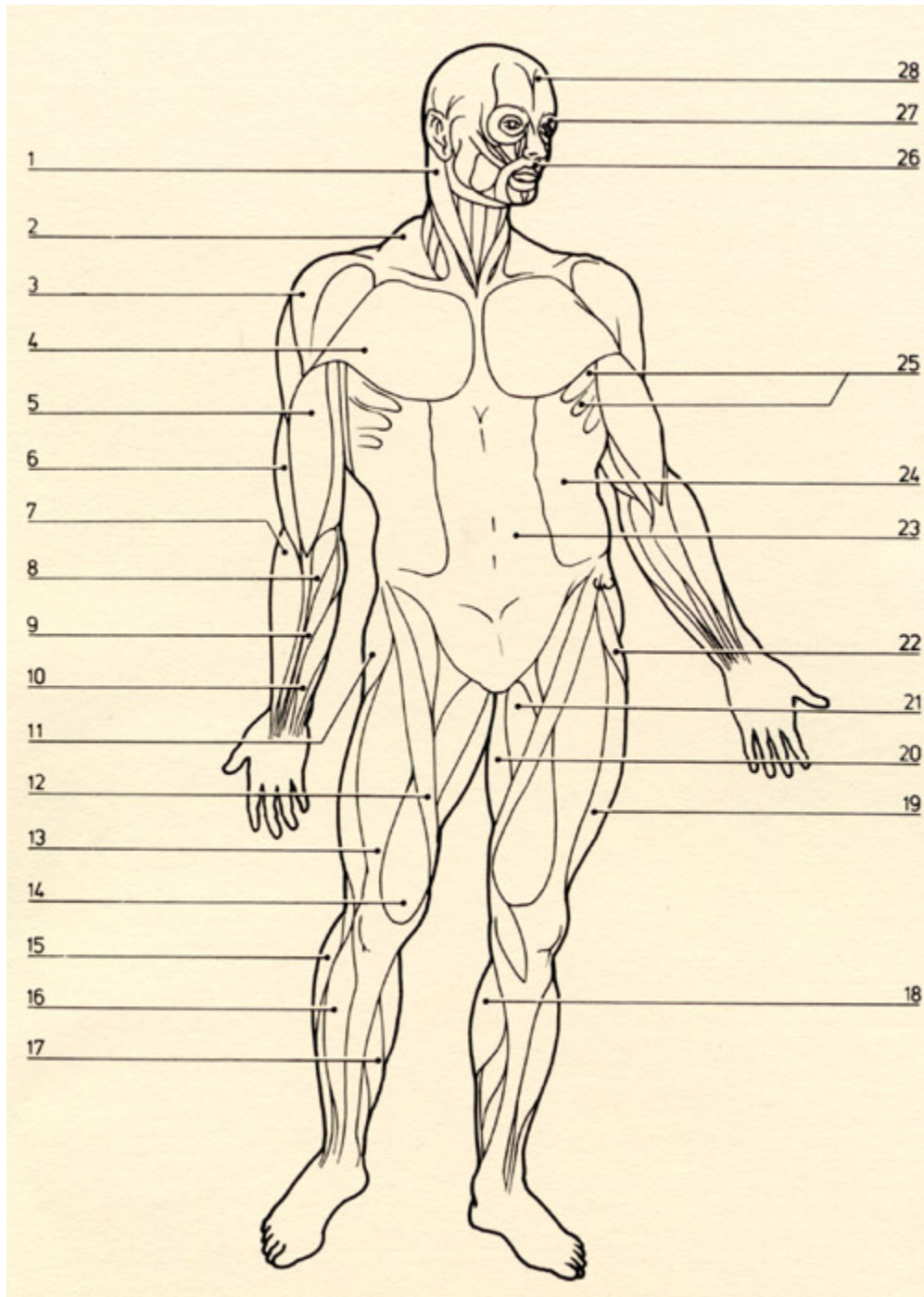
CARDIAC: NO REGENERATION, HEALING IS BY SCAR TISSUE, NO SATELLITE CELLS

SMOOTH: PERICYTES-STEM CELLS IN BLOOD VESSELS

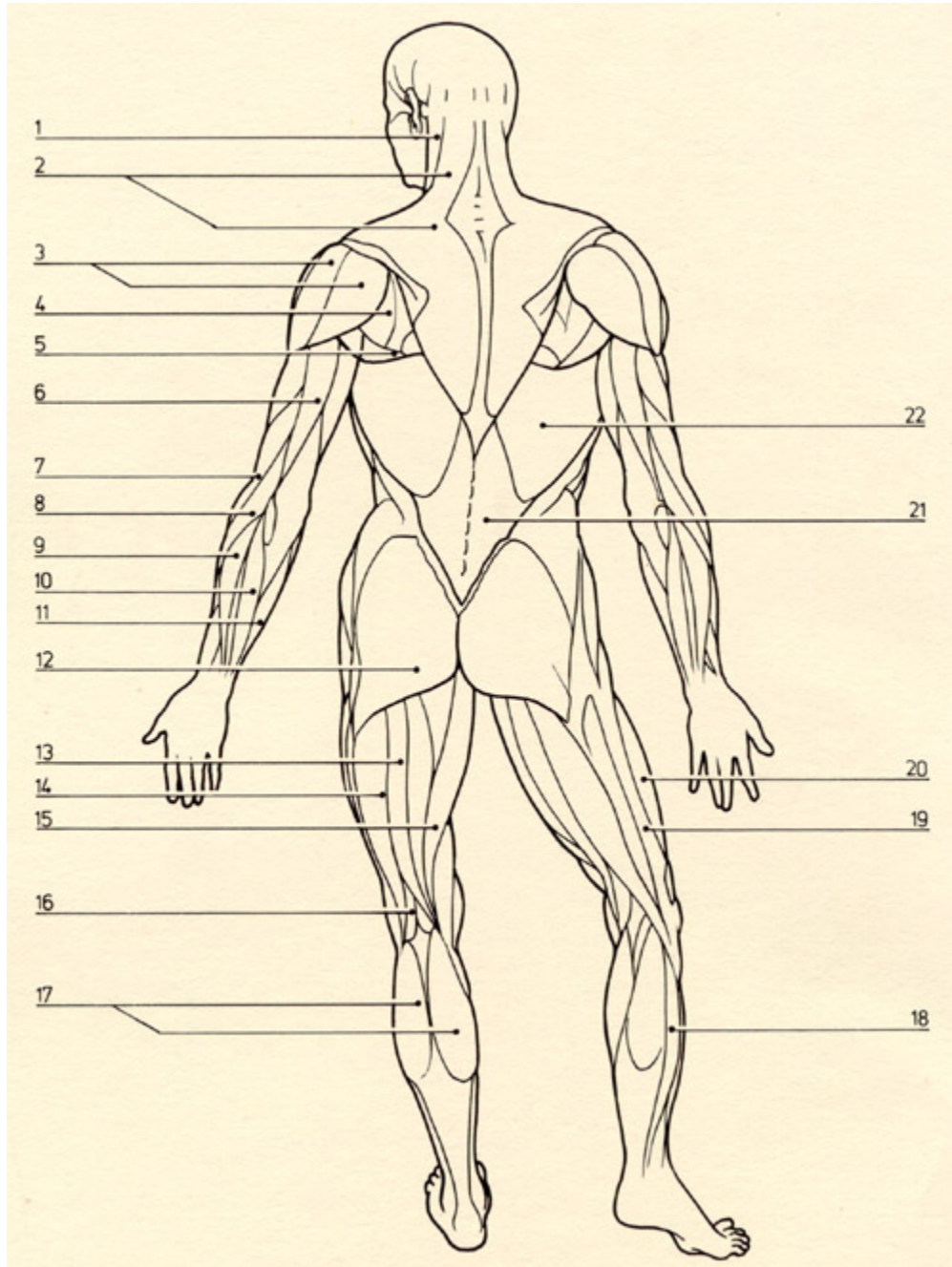
LEARNING MUSCLE ANATOMY - THOUGHTS TO PONDER, STUFF TO TRY...

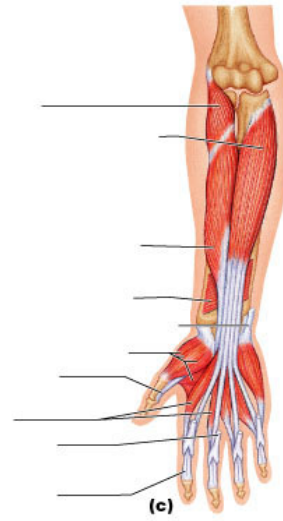
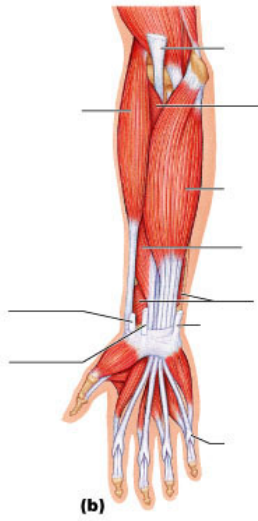
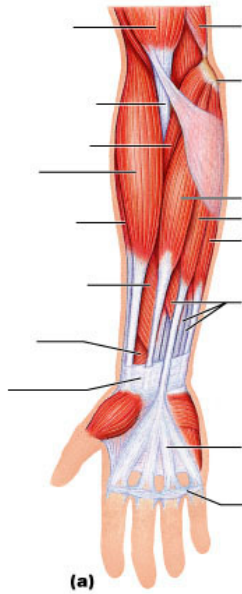
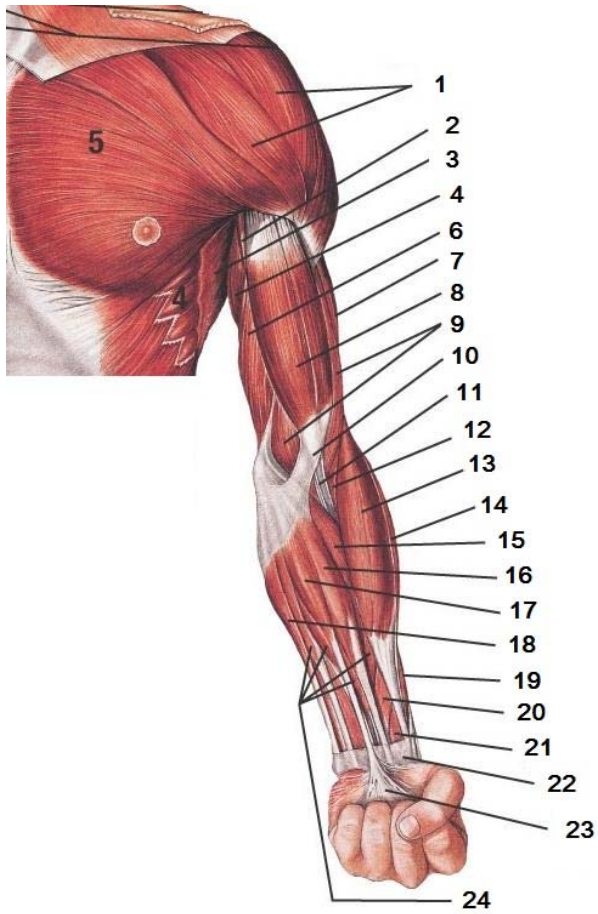
- 1** Remembering the terms myofiber, myofibril and myofilament can be a bit confusing for some... just remember that the longer word represents the smallest structure.
- 2** You will build a 3-D model that represents one third of the inner-most structure of a muscle as the class learns how muscles work. After building your model, you will explain how your section works. After each group explains their model, you will explain the function from nerve impulse to action using all three models. HINT for model building... a disk-shaped styrofoam piece can be used as Z lines on pickup sticks that represent thin myofilaments. Thick myofilaments can be represented by pickup sticks attached to a stand such as a small ring stand from the Chem Lab!
- 3** If you are unsure of how to imagine a thick myofilament, think of a large salted pretzel stick... that should do the trick!
- 4** Can you make all of the movements we've discussed? Stand up and try it!
- 5** Do not try to memorize the action, origin and insertion of every single muscle! Learn five and understand WHY the action, origin and insertion are what they are! Then, apply this understanding to any muscle and you should be able to locate the action, origin and insertion of each.
- 6** How will the following affect the Neuromuscular Junction? Botulism, Snake Venom and Myasthenia Gravis
- 7** How will an exercise program affect aerobic capacity and muscle mass?

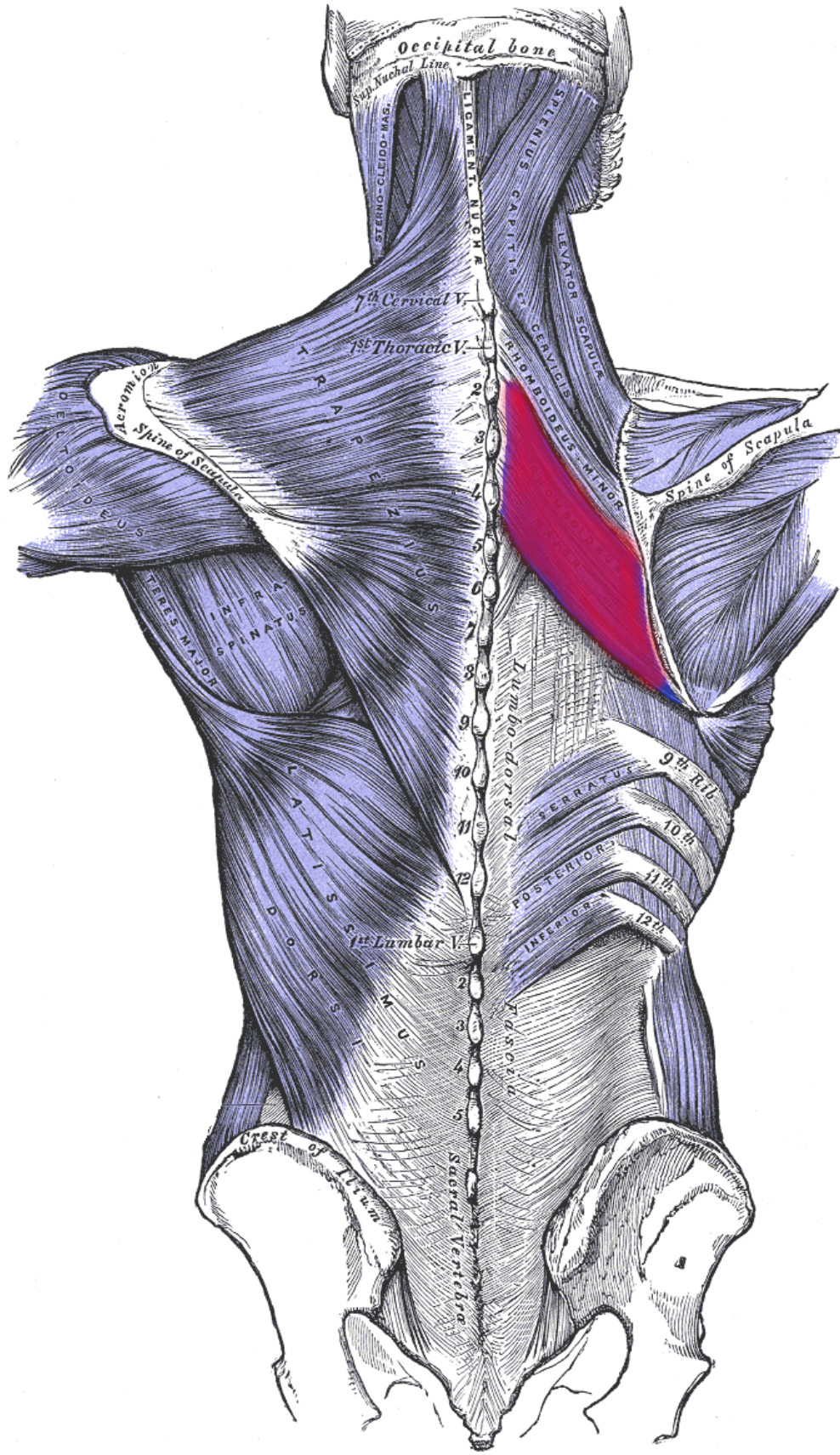
MUSCULATURE – ANTERIOR VIEW



MUSCULATURE – POSTERIOR VIEW







MUSCLE TERMINOLOGY LIST

SKELETAL MUSCLE (i.e. BICEPS BRACHII)

EPIMYSIUM (DEEP FASCIA)

MUSCLE BELLY (FACIAE-SURROUNDED FIBERS)

FASCICLE (BUNDLE OF FIBERS)

MUSCLE FIBER (SINGLE CELLS)

PERIMYSIUM (SURROUNDS FASCICLE BUNDLES)

ENDOMYSIUM (SURROUNDS EACH MUSCLE FIBER)

NEUROVASCULAR BUNDLE (NERVE, ARTERY, VEIN)

TENDON (MERGED MUSCLE FIBERS AT ENDS)

ATTACHMENT (PERIOSTEUM OR ANOTHER TENDON)

APONEUROSIS (BROAD, FLAT TENDONS)

NAMING SKELETAL MUSCLES:

- ATTACHMENT
- SHAPE
- # OF HEADS
- FUNCTION
- POSITION

MUSCLE ACTION:

- PRIME MOVER (AGONIST)
- ANTAGONIST
- FIXATOR
- SYNERGIST (NEUTRALIZER)

MUSCLE MOVEMENTS/MOTIONS:

- FLEXION
- EXTENSION
- HYPEREXTENSION
- SUPINATION
- PRONATION
- ELEVATION
- DEPRESSION
- PROTRUSION
- RETRACTION
- LATERAL FLEXION
- ROTATION
- PROTRACTION
- UPWARD ROTATION
- MEDIAL ROTATION
- LATERAL ROTATION
- ADDUCTION
- ABDUCTION
- CIRCUMDUCTION
- OPPOSITION
- INVERSION
- EVERSION
- DORSIFLEXION
- PLANTAR FLEXION

LEVERS

- 1st - MOST EFFICIENT
- 2nd
- 3rd - LEAST EFFICIENT

FULCRUM (JOINT)

EFFORT (MUSCLE)

RESISTANCE (WEIGHT)

MUSCLE ATTACHMENT:

- ORIGIN
- INSERTION

MUSCLES OF FACIAL EXPRESSION:

- ORBICULARIS OCULI
- NASALIS
- ZYGOMATICUS MAJOR
- RISORIIUS
- FRONTALIS
- ORBICULARIS ORIS
- DEPRESSOR ANGULI OCULI
- BUCCINATOR
- OCCIPITALIS
- PROCERUS

MUSCLES OF MASTICATION:

- TEMPORALIS
- MASSETER
- MEDIAL PTERYGOID
- LATERAL PTERYGOID

ANTERIOR & LATERAL MUSCLES OF THE NECK

- SUPRAHYOID MUSCLES
- HYOID BONE
- INFRAHYOID MUSCLES
- SEMISPINALIS CAPITIS
- SPLENIUS CAPITUS
- LEVATOR SCAPULAE
- SCALENUS: ANT; MED; POST
- STERNOCLEIDOMASTOID

DEEP MUSCLES OF BACK & POSTERIOR NECK

- SPLENIUS
- ERECTOR SPINAE
- TRANSVERSOSPINALIS GROUP

MUSCLES OF THORAX & POST. ABDOMINAL WALL

- THORACIC DIAPHRAGM
- EXTERNAL INTERCOSTAL
- INTERNAL INTERCOSTAL
- INNERMOST INTERCOSTAL
- ILIOPSOAS
- PSOAS MAJOR
- ILIACUS
- QUADRATUS LUMBORUM

MUSCLES OF ANT. ABDOMINAL WALL

- TRANSVERSUS ABDOMINIS
- RECTUS ABDOMINIS
- INTERNAL OBLIQUE
- EXTERNAL OBLIQUE

MUSCLES OF SCAPULAR STABILIZATION

- TRAPEZIUS
- RHOMBOID MAJOR
- RHOMBOID MINOR
- LEVATOR SCAPULAE

- SERRATUS ANTERIOR
- PECTORALIS MINOR

MUSCLES OF MUSCULOTENDINOUS CUFF

- SUPRASPINATUS
- INFRASPINATUS
- TERES MINOR
- SUBSCAPULARIS

MOVERS OF THE SHOULDER JOINT

- DELTOID
- PECTORALIS MAJOR
- LATISSIMUS DORSI
- TERES MAJOR
- BICEPS BRACHII
- TRICEPS BRACHII (LONG HEAD)

MOVERS OF ELBOW & RADIOULNAR JOINTS

- BICEPS BRACHII
 - BRACHIALIS
 - BRACHIORADIALIS
 - PRONATOR TERES
 - TRICEPS BRACHII
 - ANCONEUS
 - BICEPS BRACHII
 - SUPINATOR
 - PRONATOR TERES
 - PRONATOR QUADRATUS
- 4 flexors
- 2 extensors
- 2 supinators
- 2 pronators

FLEXORS OF WRIST & HAND

- FLEXOR DIGITORUM PROFUNDUS
 - FLEXOR POLLICIS LONGUS
 - FLEXOR DIGITORUM SUPERFICIALIS
 - FLEXOR CARPI ULNARIS
 - PALMARIS LONGUS
 - FLEXOR CARPI RADIALIS
- DEEP
- SUPERFICIAL

EXTENSORS OF WRIST & HAND

- EXTENSOR INDICIS
 - EXTENSOR POLLICIS LONGUS
 - EXTENSOR POLLICIS BREVIS
 - EXTENSOR CARPI ULNARIS
 - EXTENSOR DIGITI MINIMI
 - EXTENSOR DIGITORUM
 - EXTENSOR CARPI RADIALIS LONGUS
 - EXTENSOR CARPI RADIALIS BREVIS
 - ABDUCTOR POLLICIS LONGUS
- DEEP
- SUPER.

MOVERS OF HAND JOINTS (INTRINSICS)

EXTENSOR/FLEXOR RETINACULUM

PALMAR APONEUROSIS / CARPAL TUNNEL

THENAR EMINENCE

- OPPONENS POLLICIS
- ABDUCTOR POLLICIS BREVIS
- FLEXOR POLLICIS BREVIS

HYPOTHENAR EMINENCE

- OPPONENS DIGITI MINIMI
- ABDUCTOR DIGITI MINIMI
- FLEXOR DIGITI MINIMI BREVIS

DEEP MUSCLES

- ADDUCTOR POLLICIS

MUSCLES OF THE GLUTEAL REGION

- GLUTEUS MAXIMUS
- GLUTEUS MEDIUS
- GLUTEUS MINIMUS
- TENSOR FASCIAE LATAE
- PIRIFORMIS
- OBTURATOR INTERNUS
- OBTURATOR EXTERNUS
- QUADRATUS FEMORIS
- ILIOTIBIAL TRACT

MUSCLES OF THE POSTERIOR THIGH

- HAMSTRING GROUP
 - SEMIMEMBRANOSUS
 - SEMITENDINOSUS
 - BICEPS FEMORIS

FLEXORS OF THE KNEE JOINT

EXTENSORS OF THE HIP JOINT

MUSCLES OF THE MEDIAL THIGH

- PECTINEUS
- ADDUCTOR BREVIS
- ADDUCTOR LONGUS
- ADDUCTOR MAGNUS
- GRACILIS
- OBTURATOR EXTERNUS
- INGUINAL LIGAMENT

MUSCLES OF THE ANTERIOR THIGH

- SARTORIUS
- ILIOPSOAS
- PATELLAR LIGAMENT
- QUADRICEPS FEMORIS GROUP
 - RECTUS FEMORIS
 - VASTUS LATERALIS
 - VASTUS INTERMEDIUS
 - VASTUS MEDIALIS

MUSCLES OF THE ANTERIOR & LATERAL LEG

- TIBIALIS ANTERIOR
- EXTENSOR DIGITORUM LONGUS
- EXTENSOR HALLUCIS LONGUS
- FIBULARIS TERTIUS
- FIBULARIS LONGUS
- FIBULARIS BREVIS

MUSCLES OF THE POSTERIOR LEG

- TIBIALIS POSTERIOR
- FLEXOR DIGITORUM LONGUS
- FLEXOR HALLUCIS LONGUS
- POPLITEUS
- PLANTARIS
- SOLEUS
- GASTROCNEMIUS

MUSCLES OF THE FOOT (INTRINSICS)

EXTENSOR DIGITORUM BREVIS

EXTENSOR HALLUCIS BREVIS

TERMINOLOGY OF MUSCLE ACTION/PHYSIOLOGY

- ACETYLCHOLINE
- ACTIN
- ACTION POTENTIAL
- ADENOSINE TRIPHOSPHATE (ATP)
- AEROBIC RESPIRATION
- ANAEROBIC GLYCOLYSIS
- CREATINE PHOSPHATE (CP)
- DIRECT PHOSPHORYLATION OF ADP BY CP
- LACTIC ACID & LACTIC ACID FORMATION
- MUSCLE FATIGUE
- OXYGEN DEBT
- SODIUM IONS
- MOTOR UNIT
- MYOFIBRILS
- MYOSIN
- NEUROMUSCULAR JUNCTION
- NEUROTRANSMITTER
- SARCOLEMMMA
- I BAND (LIGHT)
- A BAND (DARK)
- Z LINE
- H ZONE
- SARCOMERES
- CROSS BRIDGES (MYOSIN HEADS)
- SARCOPLASMIC RETICULUM (SR)
- MYOFILAMENTS
- SARCOPLASM
- SPIRAL/FIGURE 8 BUNDLES
- INTERCALATED DISKS (JUNCTIONS)
- SYNAPTIC CLEFT
- CONTRACTION/SHORTENING
- IRRITABILITY
- CONTRACTILITY
- NERVE FIBER OR AXON
- AXONAL TERMINALS
- SLIDING FILAMENT THEORY & MUSCLE CONTRACTION
- SKELETAL/CARDIAC/SMOOTH
- SKELETAL = STRIATED = VOLUNTARY
- ENDOMYSIUM
- PERIMYSIUM
- FASCICLE
- EPIMYSIUM
- TENDONS
- APONEUROSES
- SMOOTH = NONSTRIATED = INVOLUNTARY
- CARDIAC = STRIATED = INVOLUNTARY
- MUSCLE FUNCTION
 - PRODUCES MOVEMENT
 - MAINTAINS POSTURE

○ STABILIZES JOINTS

○ GENERATES HEAT

- TETANUS
- ALL OR NONE LAW OF MUSCLE CELLS
- ISOTONIC CONTRACTIONS
- ISOMETRIC CONTRACTIONS
- MUSCLE TONE
- AEROBIC OR ENDURANCE
- RESISTANCE

NAMING MUSCLES

- RECTUS = STRAIGHT
- OBLIQUE = SLANTED
- MAXIMUS = LARGEST
- MINIMUS = SMALLEST
- LONGUS = LONG
- LOCATION OF ORIGIN/INSERTION
- LOCATION IN RELATION TO BONE
- NUMBER OF ORIGINS (BI, TRI, QUAD)
- MUSCLE SHAPE - DELTOID = TRIANGLE
- ACTION OF THE MUSCLE (FLEXOR)

DEVELOPMENTAL ASPECTS OF THE SYSTEM

- QUICKENING – FETAL MOVEMENT
- MUSCULAR DYSTROPHY
- DUCHENNE MUSCULAR DYSTROPHY
- DEVELOPMENTAL MOTOR SKILLS
- MYASTHENIA GRAVIS

HOMEOSTATIC BALANCE

- ENDOCRINE SYSTEM
- LYMPHATIC SYSTEM/IMMUNITY
- DIGESTIVE SYSTEM
- URINARY SYSTEM
- NERVOUS SYSTEM
- RESPIRATORY SYSTEM
- CARDIOVASCULAR SYSTEM
- REPRODUCTIVE SYSTEM
- INTEGUMENTARY SYSTEM
- SKELETAL SYSTEM

ORGAN SYSTEM PROJECT

Written Notes & Reminders

Web Materials

References

