

# Anesthesia for Liver Transplantation



Dieter Adelman, MD<sup>a</sup>, Kate Kronish, MD<sup>a</sup>, Michael A. Ramsay, MD, FRCA<sup>b,\*</sup>

## KEYWORDS

- Liver transplantation • Anesthesia • Liver • Cirrhosis • End stage liver disease
- Coagulopathy

## KEY POINTS

- Each program appoints a director of liver transplant anesthesia, who must meet the requirements of the American Society of Anesthesiologists and the United Network for Organ Sharing.
- Liver cirrhosis may cause major dysfunction in all organ systems.
- Cirrhotic cardiomyopathy may be masked by the typical high cardiac output and low peripheral vascular resistance often found in liver failure.
- Portopulmonary hypertension and hepatopulmonary syndrome often found with liver cirrhosis are at opposite ends of a vascular endothelial dysfunction pathway.
- The proper management of the coagulopathy of a failing liver requires an understanding of clot formation in “real time” and routine laboratory coagulation tests.

## LIVER: BASIC ANATOMY AND PHYSIOLOGY

The liver is the largest internal organ in the body, receiving 25% to 30% of the cardiac output. It has a dual blood supply. The hepatic artery provides 25% and the portal vein provides 75% of the blood supply. Each vessel provides 50% of oxygen delivery. In liver transplantation (LT), adequate flow through the hepatic artery is essential for the viability of a new liver graft.<sup>1</sup> Terminal branches of both the arterioles and venules drain into sinusoids, where Kupffer cells filter and degrade particulate matter such as endotoxins from the blood. Venous drainage is through hepatic veins into the inferior vena cava. Bile canaliculi, between hepatocytes, form into bile ducts that drain into the intestine.

---

D. Adelman and K. Kronish have contributed equally to this article.

Disclosure Statement: None of the authors have financial disclosures related to this article.

<sup>a</sup> Department of Anesthesiology and Perioperative Care, University of California San Francisco, Box O648, 4th Floor MUE, 500 Parnassus Avenue, San Francisco, CA 94143, USA; <sup>b</sup> Department of Anesthesiology, Baylor University Medical Center, 3500 Gaston Avenue, Dallas, TX 75246, USA

\* Corresponding author.

E-mail address: [docram@baylorhealth.edu](mailto:docram@baylorhealth.edu)

Anesthesiology Clin 35 (2017) 491–508  
<http://dx.doi.org/10.1016/j.anclin.2017.04.006>

[anesthesiology.theclinics.com](http://anesthesiology.theclinics.com)

1932-2275/17/© 2017 Elsevier Inc. All rights reserved.

The liver plays a major role in the metabolic pathway of carbohydrates, fats, and proteins. Glucose is stored as glycogen and is converted by the liver to lactate, with the generation of energy. Protein is metabolized to ammonia and urea, which is then excreted in the urine. The liver also produces nearly all the plasma proteins, except immunoglobulins. Notably, the liver produces albumin, which serves as the most abundant plasma protein, the body's primary transport protein and major determinant of oncotic pressure. Another important liver function is drug metabolism, especially via the cytochrome p450 isoenzymes. The liver is also involved in hormone, vitamin, and mineral metabolism.

### LIVER DISEASE: PATHOPHYSIOLOGY

A thorough understanding of the pathophysiology of liver disease is required to care for the liver transplant patient. The etiologies of the liver disease that most frequently need transplantation are listed in **Box 1**.

In the United States, hepatitis C virus is currently the number one indication for LT, with hepatic malignancy second. Given the new effective antiviral therapies for hepatitis C virus and the increasing obesity epidemic, nonalcoholic fatty liver disease is likely to become the most common cause of liver disease in the United States in the future.

#### *Liver Cirrhosis*

The term liver cirrhosis was coined by Rene Laennec in the 1840s. Hepatocellular death can occur via necrosis or apoptosis, most often owing to ischemia, viruses, and drug and alcohol toxicity. Cirrhosis refers to the damaging effects of inflammation, hepatocellular injury, and the resulting fibrosis and regeneration of the liver, all of which result in loss of normal liver function. Increased resistance to blood flow through the liver leads to portal hypertension and the development of varices. The failing liver is no longer able to clear the toxins that pass through it. Extensive endothelial dysfunction adversely affects all major organs.

Two commonly used scoring systems assess the severity of liver dysfunction. The Child-Turcotte-Pugh (CTP) classification has been used to assess surgical risk in

#### **Box 1**

#### **Common liver diseases that present at selection committee for possible transplantation**

Viral Hepatitis  
 Alcoholic (Laennec's) cirrhosis  
 Nonalcoholic steatohepatitis or nonalcoholic fatty liver disease  
 Hepatocellular cancer  
 Primary sclerosing cholangitis  
 Primary biliary cirrhosis  
 Autoimmune hepatitis  
 Cryptogenic cirrhosis  
 Drug induced (acetaminophen, amiodarone)  
 Acute liver failure  
 Genetic: amyloidosis, Wilson's disease

cirrhotic patients, and the Model for End-stage Liver Disease (MELD) score is validated to assess survival on the liver transplant waiting list.

The CTP score is calculated from:

Prothrombin time (seconds)

Encephalopathy

Ascites

Bilirubin (mg/dL)

Albumin (g/dL)

International Normalized Ratio (INR)

The MELD score calculation uses:

Serum creatinine (mg/dL)

Bilirubin (mg/dL)

INR

The sickest patients, who are most likely to die awaiting LT, receive highest waitlist priority. The CTP severity score was initially used to allocate livers. In 2002, the MELD score replaced the CTP score for liver allocation. It is a better predictor of 3-month waitlist mortality and is less subjective. In 2016, serum sodium was added to the MELD score for liver allocation, now called the MELD-Sodium. Higher waitlist priority is also given to patients with certain disease processes, such as acute liver failure, primary nonfunction of a recently transplanted liver, and hepatocellular carcinoma. These patients are given exception points because their increased waitlist mortality is not reflected in the MELD score. Rules regarding scoring and exception points are changing to attempt to address inequities in access.

## TRANSPLANT SELECTION COMMITTEE

Before patients are accepted on the liver transplant waiting list, their suitability for transplantation must be assessed by a selection committee. This committee includes surgeons, hepatologists, anesthesiologists, and social workers. They focus on medical comorbidities, functional status, and a psychosocial evaluation. In the United States alone, 40,000 patients die of liver disease each year, but only 6000 liver transplants are performed annually. Thus, organ stewardship is extremely important. Selection committees are tasked with choosing patients with the greatest likelihood of successful transplantation and posttransplant survival. The presence of anesthesiologists on selection committees is important to assess the perioperative risk. Contraindications to transplantation include active alcohol and substance abuse, active infection, malignancy outside of the liver, and the lack of social support and finances. Advanced multiorgan system failure may be a contraindication to transplant, or may require multiorgan transplantation. Given that deceased organ availability does not meet waitlist demand, living donation of partial livers has emerged as alternative, particularly for patients with low MELD scores.<sup>2</sup>

## PREOPERATIVE ASSESSMENT

The patient admitted for possible LT has often spent many months on the waiting list. At the time of transplantation, their MELD score might have increased significantly. This patient may be significantly sicker than when they were discussed at the selection committee. Therefore, all patients require careful reassessment by the anesthesiologist. If this patient is now too sick to be transplanted, the graft can be used to save another life.

Some conditions that may critically affect the management of the liver recipient are cirrhotic cardiomyopathy (CM), portopulmonary hypertension (POPH), hepatopulmonary syndrome (HPS), acute tubular necrosis of the kidney, cerebral edema, and severe electrolyte derangements. Competency with transesophageal echocardiography (TEE), the availability for renal replacement therapy, and the ready access to consultants are paramount.

## CENTRAL NERVOUS SYSTEM: HEPATIC ENCEPHALOPATHY AND ACUTE LIVER FAILURE

Chronic liver dysfunction is associated with the accumulation of neurotoxins such as ammonia, short chain fatty acids, and mercaptans. These toxins can bypass the liver via portosystemic shunts. Their metabolism is impaired in liver dysfunction. In the central nervous system, ammonia is metabolized to glutamine. Glutamine increases intracellular osmolality and can lead to cerebral edema.<sup>3</sup>

Benzodiazepines should be used with care because they may potentiate this encephalopathy and precipitate hepatic coma.

The nonabsorbable disaccharide lactulose and nonabsorbable antibiotics such as rifaximin can reduce bacterial production of ammonia and treat hepatic encephalopathy in chronic liver disease.<sup>4</sup> As liver failure progresses, encephalopathy may deteriorate to hepatic coma and cerebral edema develops (**Box 2**). Acute management of hepatic encephalopathy consists of early intubation for airway protection to prevent

### Box 2

#### Classification of hepatic encephalopathy

##### Unimpaired

- No signs or symptoms
- Normal psychometric or neuropsychological tests

##### Grades 0 to 1

- Also known as minimal or covert hepatic encephalopathy
- No overt clinical symptoms to mild decrease in attention span, awareness, altered sleep rhythm
- Abnormal psychometric or neuropsychological tests

##### Grade 2

- Obvious personality change, inappropriate behavior, asterixia, dyspraxia, disorientation, lethargy
- Objectively disoriented to time

##### Grade 3

- Somnolence, gross disorientation, bizarre behavior
- Objectively disoriented to time and space

##### Grade 4

- Coma

*From Suraweera D, Sundaram V, Saab S. Evaluation and management of hepatic encephalopathy: current status and future directions. Gut Liver 2016;10(4):510; with permission.*

aspiration, maintain oxygenation, and prevent hypercarbia. Mild hypocapnia and mild hypothermia may be helpful for neuroprotection.

In patients with cerebral edema, increased intracranial pressure can be managed by the placement of an intracranial pressure monitoring system. The common indications are papilledema, cerebral swelling, cardiovascular instability, and high ammonia levels. Coagulopathy associated with acute liver failure puts patients at increased risk for intracranial hemorrhage from the placement of invasive intracranial pressure monitors. Administration of blood products, factor concentrates, or recombinant activated factor VII can mitigate this risk.<sup>5,6</sup> Some centers use artificial liver support systems as a bridge to LT. Renal replacement therapy may be necessary to treat acidosis, hyperkalemia, volume overload, and elevated ammonia and lactate levels.<sup>3,7</sup>

## THE CARDIOVASCULAR SYSTEM

Cardiac dysfunction may be a consequence of liver disease, independent of liver disease or owing to a condition that affects both the heart and the liver. The typical hemodynamic changes associated with cirrhosis are decreased systemic vascular resistance and high cardiac output.<sup>8</sup> Although the left ventricular ejection fraction might be preserved, cardiac function in cirrhosis can be severely impaired. CM is difficult to identify, and clinicians not familiar with liver disease might mischaracterize the heart function as that of a well-trained athlete when in fact it is severely weakened. Therefore, cardiologists consulted should be very familiar with liver disease and its effects on the heart.

### ***Cirrhotic Cardiomyopathy***

Cardiomyopathy, characterized by systolic and diastolic dysfunction and electrophysiologic changes, may exist to some degree in all patients with liver cirrhosis.<sup>8–10</sup> It initially presents as a blunted response to  $\beta$ -adrenergic receptor agonists, so vasopressor therapy may not be effective in traditional doses. CM is defined as an impaired contractile responsiveness to physiologic or pharmacologic stress, impaired left ventricular relaxation, and electrophysiologic abnormalities with prolonged QT interval.<sup>8,11</sup> Diagnostic criteria are presented in [Table 1](#). Early onset of atrial fibrillation is also common.<sup>12</sup>

Both systolic and diastolic dysfunction are best evaluated using echocardiography, although a hyperdynamic circulation in the patient with liver cirrhosis can make the echocardiographic examination more difficult. Previously undiagnosed CM can present at the time of LT, with invasive monitoring showing low cardiac output in the presence of high filling pressures. TEE can help to assess for CM that may have developed since the last evaluation.

Cardiac failure may be precipitated by the increased cardiac output that follows transjugular intrahepatic portosystemic shunt placement or LT itself. The presence of diastolic dysfunction has been associated with an increased risk of death in patients with cirrhosis.<sup>13,14</sup> Patients with CM are also at increased risk for graft failure or death during LT.<sup>15,16</sup> This cardiomyopathy is progressive without LT ([Fig. 1](#)). Successful transplantation can reverse the effects of CM, although physiologic changes may take up to 6 months to resolve.<sup>17</sup>

### ***Primary Cardiac Disease***

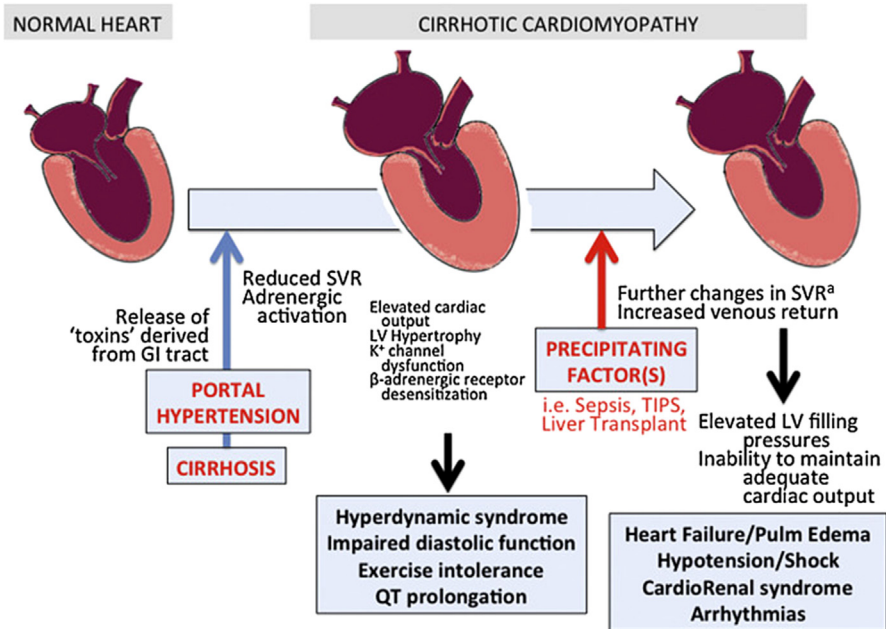
#### ***Coronary artery disease***

All liver transplant waitlist patients should be screened for coronary artery disease (CAD). Traditional risk factors include hypertension, smoking, diabetes, hypercholesterolemia,

Table 1 Diagnostic tests for cirrhotic cardiomyopathy	
Methods	Signs
Electrocardiogram	• Prolonged QT interval
Exercise test	• Reduced exercise tolerance
Cardiopulmonary exercise test	• Alteration of aerobic capacity (peak $\text{VO}_2$ ) or ventilatory efficiency ( $\text{VE}/\text{VCO}_2$ or OUES)
Six-minute walk test	• Reduced tolerance
Echocardiography	• Systolic dysfunction (LVEF <55%) • Diastolic dysfunction • Left ventricular hypertrophy • Diastolic dysfunction (mean $\text{E}/\text{E}'$ index >10)
Exercise or dobutamine stress echocardiography	• Reduced contractile reserve
Magnetic resonance	• Systolic dysfunction (LVEF <55%) • Diastolic dysfunction (peak filling rate) • Left ventricular hypertrophy
BNP/NT-proBNP	• Elevated levels

**Abbreviations:** A wave, peak late atrial filling velocity ( $\text{A}$ ,  $\text{cm s}^{-1}$ ); BNP, brain natriuretic peptide; EDT, E wave deceleration time (m/s); E wave, peak early filling velocity ( $\text{E}$ ,  $\text{cm s}^{-1}$ ); LVEF, left ventricular ejection fraction; OUES, oxygen uptake efficiency slope; proBNP, prohormone brain natriuretic peptide; VE, ventilator efficiency;  $\text{VE}/\text{VCO}_2$ , minute ventilation/carbon dioxide production;  $\text{VO}_2$ , oxygen volume (oxygen consumption);  $\text{VCO}_2$ , carbon dioxide production.

From Zardi EM, Zardi DM, Chin D et al. Cirrhotic cardiomyopathy in the pre- and post-liver transplantation phase. *J Cardiol* 2016;67(2):128; with permission.



**Fig. 1.** The progression of cirrhotic cardiomyopathy. GI, gastrointestinal; LV, left ventricular; SVR, systemic vascular resistance; TIPS, transjugular intrahepatic portosystemic shunt. (From Zardi EM, Zardi DM, Chin D et al. Cirrhotic cardiomyopathy in the pre- and post-liver transplantation phase. *J Cardiol* 2016;67(2):127; with permission.)

obesity, and genetic history. These comorbidities are especially likely in patients with nonalcoholic fatty liver disease. The prevalence of CAD in transplant candidates with 2 or more traditional risk factors is 50%.<sup>18–20</sup> In patients who receive adequate treatment for CAD before transplantation, postoperative outcomes are comparable to patients without CAD.<sup>21</sup>

Hypertrophic cardiomyopathy can increase perioperative cardiovascular complications in patients presenting for LT. Strategies for successful management include preoperative alcohol septal ablation, and careful intraoperative management using TEE to optimize contractility and heart rate.<sup>22,23</sup>

Diseases affecting both the liver and the heart include alcoholic disease, amyloid disease, obesity, and hemosiderosis. Combined heart transplantation and LT can be considered if the risk of single organ transplant is high, such as in patients with familial amyloid disease.<sup>24</sup>

### ***Preoperative Cardiac Assessment***

---

Cardiac testing for all patients evaluated for LT should include an electrocardiogram and transthoracic echocardiography.<sup>25</sup> A prolonged QT interval and atrial fibrillation can be detected using an electrocardiogram. Impaired diastolic function can be detected using left ventricular inflow velocities (E:A ratio) and tissue Doppler (E:E' ratio, velocity of myocardial displacement).<sup>11</sup> Dobutamine stress echocardiography and myocardial perfusion scintigraphy are widely used to assess left ventricular function and screen for ischemic heart disease. In patients with multiple risk factors or when noninvasive testing is suggestive of ischemia, coronary angiography is indicated for diagnosis and possible treatment.<sup>25</sup>

## **PULMONARY SYSTEM**

Pulmonary dysfunction affects up to 50% of patients with liver disease. The major pulmonary concerns are: refractory hepatic hydrothorax, HPS, POPH, hemorrhagic hereditary telangiectasia, interstitial lung disease, and alpha-1-antitrypsin deficiency-related emphysema.

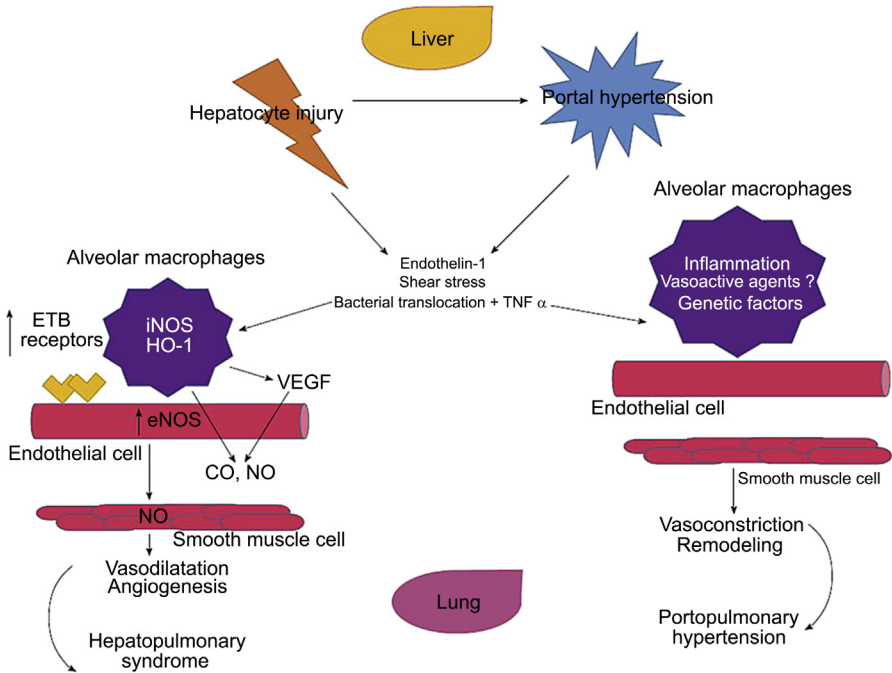
### ***Hepatic Hydrothorax***

---

Cirrhosis can cause a restrictive ventilation defect. Ascites passes into the pleural space through defects in the diaphragm and leads to pleural effusions. Conservative management includes diuretic therapy and salt restriction. Thoracentesis and pleural catheters may be indicated in refractory patients.<sup>26</sup> Hepatic hydrothorax is reversible after LT.

The pulmonary vascular endothelium is a vital organ that impacts vasoregulation, the fluidity, antithrombosis, laminar blood flow, permeability, and growth of the surrounding smooth muscle. Portal hypertension exposes the pulmonary vascular endothelium to inflammatory cytokines and stress forces owing to high laminar flow. This leads to endothelial dysfunction with either a predominantly vasodilatory pulmonary circulation (HPS) or a restrictive, vasoconstrictive circulation resulting in POPH (**Fig. 2**).

HPS is characterized by a triad of a decreased oxygen saturation in the presence of advanced liver disease and intrapulmonary vascular dilatation. It is present in 5% to 30% of patients evaluated for LT. Pulmonary arteriovenous shunts and capillary vasodilation caused by portal hypertension lead to a reduced capillary transit time and diminished oxygen diffusion.<sup>27–29</sup> The end result is that many of the red cells are not fully saturated with oxygen.



**Fig. 2.** Pathophysiology of the hepatopulmonary syndrome and portopulmonary hypertension. <sup>a</sup>Worsening cirrhosis or sepsis lead to a further reduction in Systemic Vascular Resistance (SVR), whereas a rapid increase in SVR is seen after liver transplant. CO, carbon monoxide; eNOS, endothelial nitric oxide synthase; ETB, endothelin type B; HO-1, heme oxygenase 1; iNOS, inducible nitric oxide synthase; NO, nitric oxide; TNF- $\alpha$ , tumor necrosis factor alpha; VEGF, vascular endothelial growth factor. (Adapted from Surani SR, Mendez Y, Anjum H, et al. Pulmonary complications of hepatic diseases. *World J Gastroenterol* 2016;22(26):6010; with permission.)

Pulse oximetry can be used to screen for HPS. Oxygen saturations (SpO<sub>2</sub>) of less than 96% require further evaluation. Diagnosis is confirmed by transthoracic echocardiography showing a delayed right-to-left shunt using agitated saline. After administration of agitated saline into the venous system, contrast microbubbles appear in the left heart after a delay of 3 to 6 heart beats; with intracardiac shunts, contrast microbubbles are seen moving from the right to left heart immediately. The decrease in oxygen content is defined by an increased alveolar–arterial oxygen gradient of equal to or greater than 15 mm Hg while breathing room air in the sitting position.<sup>29</sup>

Clinical signs in patients with HPS are digital clubbing, cyanosis, and platypnea (dyspnea that is worse upon moving from supine to upright position). This form of dyspnea is unique to HPS. Patients diagnosed with HPS have a 2-fold increased risk of mortality compared with cirrhotic patients without HPS. They are granted MELD exception points for higher waitlist priority. There is currently no medical treatment for HPS.

In severely hypoxic patients, extracorporeal membrane oxygenation can facilitate successful LT.<sup>30</sup> After transplantation, resolution of HPS can be expected within 1 to 2 years.<sup>31</sup>

POPH results when the pulmonary vascular endothelium is exposed to inflammatory cytokines, including endothelin-1. This leads to vasoconstriction, proliferation of



endothelium and smooth muscle, and platelet aggregation. Eventually fibrosis results. This obstruction to flow leads to pulmonary hypertension and right heart failure. The severity of POPH is graded based on right heart catheterization data (Table 2).

Adequate right ventricular (RV) function is essential for survival during LT. Even mild RV dysfunction can cause the new liver graft to become congested and fail. Severe RV dysfunction can lead to intraoperative death.<sup>32</sup> The use of venous–arterial extracorporeal membrane oxygenation improves survival in this patient group. Both POPH and HPS may exist together; however, POPH may not reverse after LT.<sup>33</sup>

All LT candidates must be screened for POPH. The prevalence is about 5%.<sup>34</sup> An RV systolic pressure of greater than 50 mm Hg and/or significant RV hypertrophy or dysfunction is an indication for right heart catheterization to characterize the pulmonary hemodynamics. True POPH must be differentiated from pulmonary hypertension generated from high cardiac output, volume overload, or venous hypertension (Fig. 3).

Without treatment, POPH is associated with a 1-year survival of 35% to 46%.<sup>35,36</sup> The medical treatment for POPH is improving. There are 3 therapeutic classes available: prostacyclin analogues, phosphodiesterase inhibitors, and endothelin receptor antagonists. Mild POPH presents with normal perioperative risk for LT. Moderate POPH is associated with increased perioperative mortality, and severe POPH is considered a contraindication to LT. Patients with severe POPH can undergo LT only if their pulmonary arterial pressures can be lowered using medical therapy and if RV function is adequate.

Patients diagnosed with POPH in the operating room immediately before LT should have an assessment of RV function by TEE. If there is evidence of RV dysfunction, LT must be deferred. Patients with a mean pulmonary artery pressure of less than 35 mm Hg and a PVR of less than 240 dyn.sec.cm<sup>-5</sup> can safely undergo LT. Reperfusion is the most critical period during LT. Cardiac output can significantly increase with reperfusion, causing an acute increase in the mean pulmonary artery pressure, which can lead to RV failure. The following interventions have salvaged some transplants: inhaled nitric oxide, intravenous or inhaled prostacyclins, milrinone, and extracorporeal membrane oxygenation.<sup>37</sup>

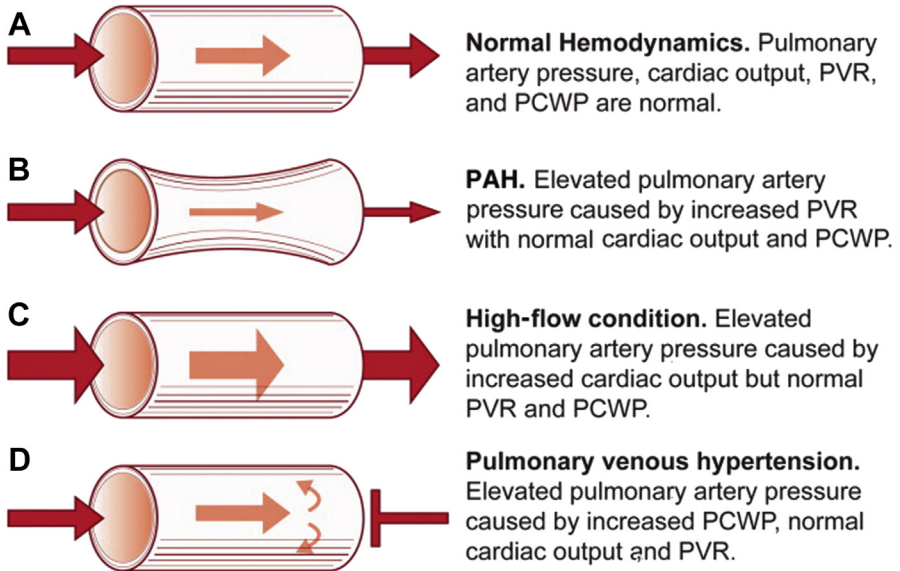
## THE RENAL SYSTEM

Hepatorenal syndrome (HRS) is a functional renal impairment in patients with advanced liver disease or severe fulminant liver injury. It is characterized by increased renal vasoconstriction, a reduced glomerular filtration rate, subsequent increase in creatinine, and impaired sodium and water excretion.

Portal hypertension leads to profound systemic and splanchnic vasodilatation and intravascular volume depletion. This increases renal vasoconstriction via both the renin–angiotensin–aldosterone pathway and sympathetic nervous system activation. Renal vasoconstriction leads to significant hypoperfusion of the kidney.<sup>38</sup> HRS is

**Table 2**  
Classification of portopulmonary hypertension

	Mean Pulmonary Artery Pressure (mm Hg)	Pulmonary Vascular Resistance (dyn.sec.cm <sup>-5</sup> )	Pulmonary Capillary Wedge Pressure (mm Hg)
Normal	<25	—	—
Mild	25–35	>240	<15
Moderate	35–45		
Severe	>45		

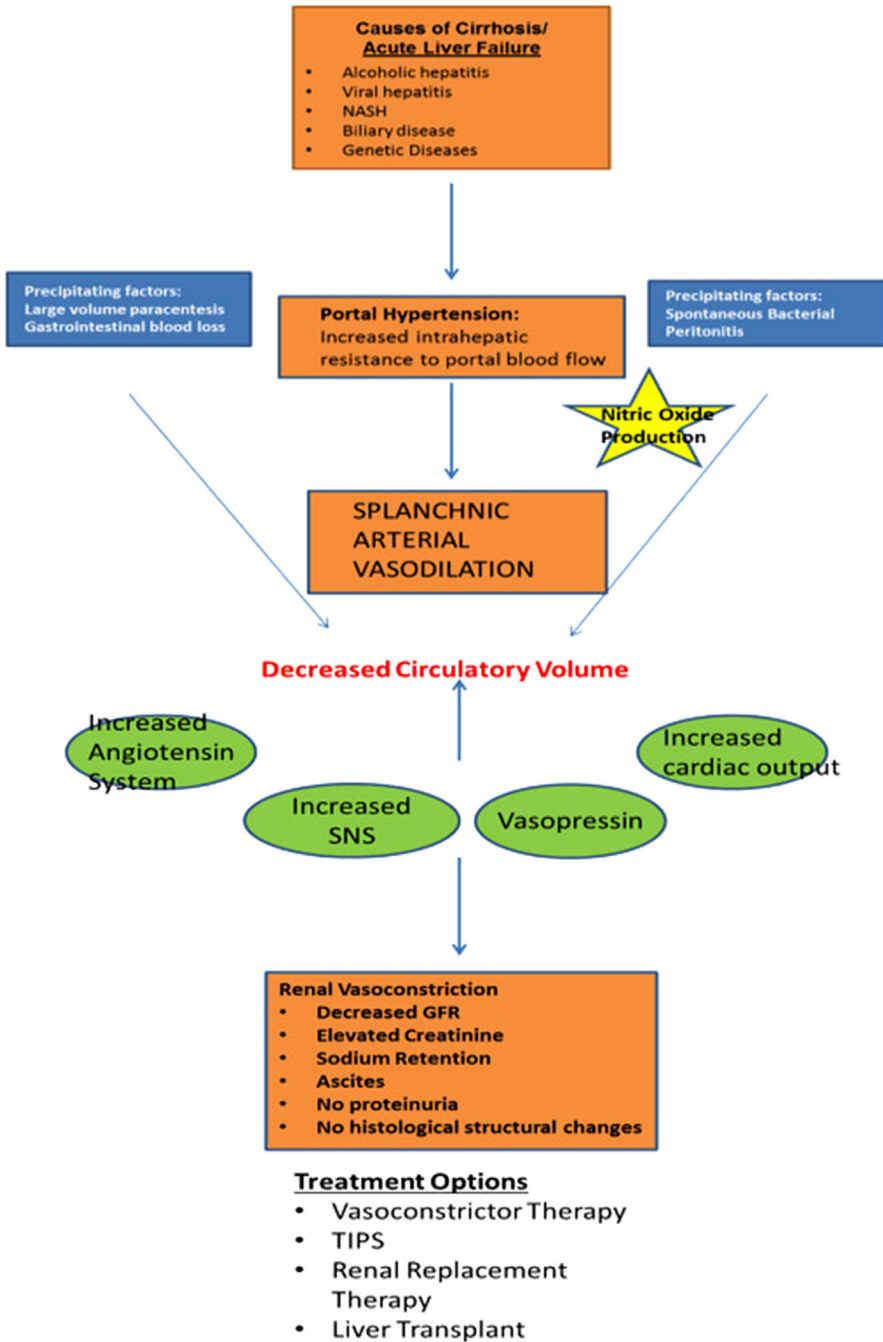


**Fig. 3.** (A–D) Etiologies of pulmonary hypertension in the liver transplant candidate. Only (B) is true portopulmonary hypertension. PAH, pulmonary arterial hypertension; PCWP, pulmonary capillary wedge pressure; PVR, pulmonary vascular resistance. (From Safdar Z, Bartolome S, Sussman N. Portopulmonary hypertension: an update. *Liver Transpl* 2012;18(8):883; with permission.)

classified as type 1, with rapid deterioration in renal function, and type 2 with a more gradual deterioration in renal function. Type 1 HRS has a 2-week mortality of about 80% whereas in type 2 HRS, kidney function declines more slowly and survival rates without LT are around 6 months. The diagnosis is based on the absence of primary kidney disease, proteinuria, or systemic hypovolemia causing renal hypoperfusion. There is normal urinary sediment, low urinary sodium (<10 mEq/L), uremia, and oliguria. Unfortunately, serum creatinine is a poor marker for renal dysfunction in HRS because these patients are usually cachectic with poor muscle mass. HRS type 1 can be treated with albumin in combination with the vasoconstrictor terlipressin.<sup>38</sup> Other vasoconstrictors used are vasopressin, the alpha-adrenergic receptor agonist midodrine, and norepinephrine. Renal replacement therapy may be used to stabilize the HRS patients before LT. HRS is reversible with LT. Prolonged endothelial damage can lead to irreversible tubular necrosis. A combined liver–kidney transplant should then be considered (Fig. 4).

### THE COAGULATION SYSTEM

Liver disease has a complex effect on coagulation. It is widely understood to increase risk of bleeding: hepatic synthesis of procoagulant factors such as the vitamin K–dependent coagulation factors II, VII, IX, and X are reduced, and thrombocytopenia is common. However, the liver also produces the anticoagulant factors protein C, protein S, and antithrombin III, which are reduced in liver disease. Coagulation factor VIII, which is synthesized in the endothelium, is increased in patients with liver disease. Despite low platelet counts, platelet adhesion and aggregation might be normal, because of increased endothelial production of von Willebrand factor.<sup>39–41</sup> Thus,



**Fig. 4.** The basic mechanism of the hepatorenal syndrome. GFR, glomerular filtration rate; NASH, nonalcoholic steatohepatitis; SNS, sympathetic nervous system; TIPS, transjugular intrahepatic portosystemic shunt. (From Shah N, Silva RG, Kowalski A, et al. Hepatorenal syndrome. Dis Mon 2016;62(10):367; with permission.)

coagulation dysfunction in liver disease can better be described as a fragile balance between low levels of both procoagulation and anticoagulation factors.<sup>40</sup> During LT, both bleeding as well as thromboembolic complications may occur (Table 3). Adequate coagulation requires sufficient amounts of thrombin. Thrombin then triggers the formation of a strong clot made of fibrinogen and platelets that can withstand fibrinolysis. The INR, although often used to assess the risk of bleeding in patients with liver disease, provides only a partial picture of the state of coagulation.<sup>2</sup>

Point-of-care global viscoelastic coagulation tests such as thromboelastography (Haemonetics Corporation, Braintree, MA) and thromboelastometry (TEM International GmbH, Munich, Germany) can help to evaluate clot formation in whole blood. Thromboelastography/thromboelastometry can determine the quality of clot formation (generation of thrombin), clot strength (the effect of fibrinogen and platelets), and fibrinolysis.<sup>42–44</sup> The degree of coagulopathy varies widely with the underlying liver disease. Patients with hepatocellular carcinoma often have normal coagulation profiles. Despite a prolonged INR, some patients show a hypercoagulable profile in thromboelastography. This could likely indicate an increased risk for thromboembolic complications.<sup>45</sup>

In addition, bleeding in patients with liver disease is not always owing to coagulopathy. Other common causes include portal hypertension and varices, endothelial dysfunction, renal failure, and disseminated intravascular coagulation.<sup>46</sup>

## ANESTHESIA MANAGEMENT

Except for elective living donor liver transplants, the majority of liver transplants are performed as emergency cases. Many recipients have multiorgan dysfunction at the time of transplantation.

Basic intraoperative monitoring includes central venous and intraarterial pressure monitoring. In patients with suspected cardiac dysfunction or POPH, pulmonary artery catheter placement and/or TEE may be indicated. Echocardiography is a powerful tool to assess major hemodynamic changes and guide inotropic therapy. It also can detect major complications early such as intracardiac thromboembolism or air embolism.<sup>47</sup>

The use of thromboelastography for coagulation monitoring and ultrasound guidance for vascular catheter placement are center specific. Rapid infusion devices and red cell salvage systems are used in some centers. The availability of a rapid

**Table 3**

**Hemostatic system alterations that contribute to bleeding or hemostasis**

### Changes That Impair Hemostasis

Thrombocytopenia  
 Platelet function defects  
 Enhanced production of nitric oxide and prostacyclin  
 Low levels of factors II, V, VII, IX, X, and XI  
 Vitamin K deficiency  
 Dysfibrinogenemia  
 Low levels of  $\alpha$ 2-antiplasmin, factor XIII, and thrombin-activatable fibrinolysis inhibitor  
 Elevated tissue plasminogen activator levels

### Changes That Promote Hemostasis

Elevated levels of von Willebrand factor  
 Decreased levels of ADAMTS-13  
 Elevated levels of factor VIII  
 Decreased levels of protein C, protein S, antithrombin,  $\alpha$ 2-macroglobulin, and heparin cofactor II  
 Low levels of plasminogen

From Lisman T, Caldwell SH, Burroughs AK, et al. Hemostasis and thrombosis in patients with liver disease: the ups and downs. *J Hepatol* 2010;53(2):363; with permission.

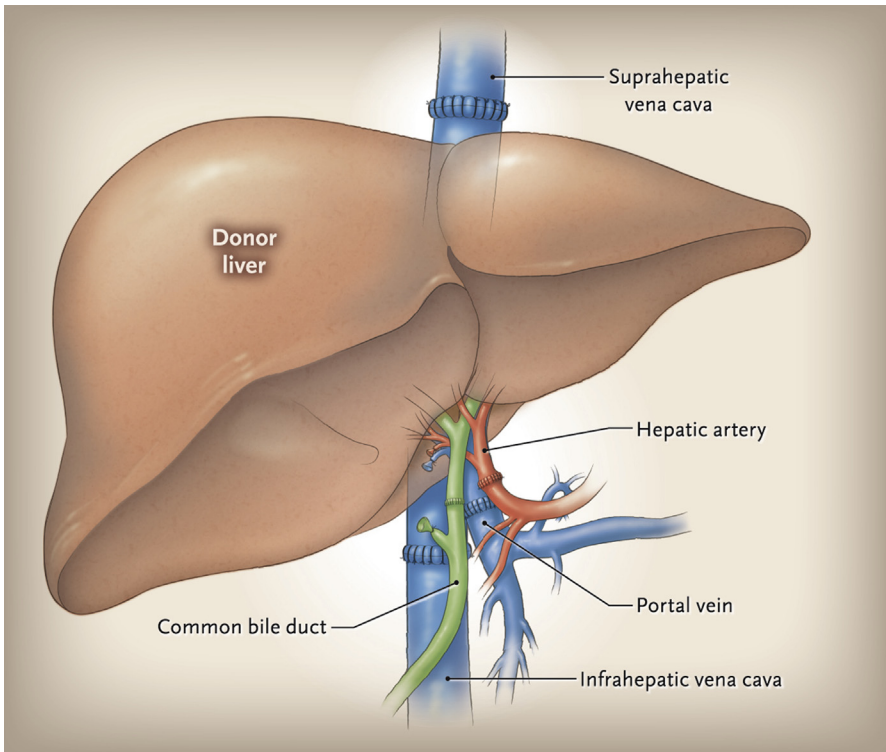
response laboratory service with rapid turnaround times and blood bank services are essential.<sup>48</sup>

Electrolyte derangements should be monitored closely. With the new MELD-Sodium scoring system, more patients with hyponatramia are likely to be transplanted. If serum sodium is increased too rapidly, central pontine myelinolysis can occur.

The operation is divided into 3 phases: preanhepatic, anhepatic, and the neohepatic phases. During the preanhepatic phase, the native liver is dissected and then removed. Blood loss during this phase can be considerable. Compression or occlusion of major blood vessels can cause further hemodynamic compromise. This phase ends in the clamping of the inferior vena cava, portal vein and hepatic artery, and removal of the liver.

There are 3 basic surgical techniques for liver transplant:

- A. Total occlusion of the vena cava and the portal vein (“full clamp,” **Fig. 5**): This results in a severe reduction in venous return to the heart during the anhepatic phase. The presence of portal varices and other new vessels in patients with longstanding cirrhosis can ameliorate this effect. Care must be taken not to overcompensate with significant volume expansion, because this volume will return to the circulation upon unclamping. The resulting hypervolemia can lead to venous congestion and poor function of the new liver.



**Fig. 5.** Liver transplant with replacement of the vena cava (“full clamp”). (From Dienstag JL, Cosimi AB. Liver transplantation — a vision realized. *N Engl J Med* 2012;367(16):1484; with permission.)

- B. “Piggy-back” technique: The inferior vena cava is only partially occluded with a side-biting clamp. The portal vein is still fully clamped throughout the anhepatic phase. With partial return of blood from the inferior vena cava to the heart, hemodynamics are usually more stable than with a full clamp.
- C. Venovenous bypass: Venous blood from the inferior vena cava and femoral vein is returned into the internal jugular vein using extracorporeal venovenous cannulas and a centrifugal pump. Care must be taken to avoid air emboli, thromboembolism and hypothermia. In theory, this approach might be renoprotective and cause less cardiac strain. But clinical trials proving this advantage are currently lacking. The use of this practice seems to be decreasing.<sup>49</sup>

During the anhepatic phase, the new liver is anastomosed into place and reperfused. As the vena cava is unclamped, adequate return of venous blood volume to the heart is restored. Blood pressure and cardiac output improve. The portal vein is then opened, causing the cold, acidotic, hyperkalemic blood from below the clamp and from the liver graft itself to circulate directly into the right heart. This can cause a significant decrease in blood pressure, bradycardia, other arrhythmias, and occasionally cardiac arrest. Severe hypotension upon unclamping is called reperfusion syndrome and can be ameliorated by administration of calcium chloride, bicarbonate, epinephrine, and vasopressin.<sup>50</sup> The time taken to sew the new graft in place is the warm ischemia time. Warm ischemia is very damaging to the graft, and thus limiting warm ischemia time is critical to graft function.

The neohepatic phase consists of the hepatic artery and bile duct anastomoses, often with a concomitant cholecystectomy. During this time, the anesthesiologist is looking for signs that the new liver is beginning to function—improvement in acidosis and clearing of lactic acid, and improved hemostasis and production of bile. Hemostasis requires excellent surgical skills, temperature control and the early diagnosis and treatment of fibrinolysis. Failure to do so leads to breakdown of existing clots and the development of diffuse bleeding.

Maintenance of a low central venous pressure may reduce venous bleeding during hepatectomy.<sup>51,52</sup> For patients with severe portal hypertension, octreotide infusion may be indicated to reduce the portal venous pressure.<sup>53</sup> Vasopressors commonly used during LT are norepinephrine, vasopressin, and epinephrine.<sup>54</sup> Ionized calcium frequently decreases and needs to be replaced.

Treatment of abnormal laboratory values such as low platelet counts, low fibrinogen, and high prothrombin times is only required if there is clinical bleeding. These laboratory values frequently normalize as the new graft functions and platelets return to the circulation from the spleen. In case of bleeding, patients are treated with factor replacement, blood, and platelets. Approaches to resuscitation and treatment of high blood loss differ by institution.

Renal dysfunction, with poor urine output and rising creatinine, may occur during transplantation, especially after a full caval clamp, long anhepatic time, or prolonged hypotension. Patients with volume overload, hyperkalemia, or hyponatremia may benefit from continuous venovenous hemodialysis that can be instituted in the operating room or upon arrival to the intensive care unit.

## POSTOPERATIVE COURSE

Early extubation is feasible in select patients after LT.<sup>55</sup> The new graft must show good function by beginning clearance of acidosis and falling lactate levels. Monitoring of neuromuscular blockade is essential before extubation. Patients must also be cooperative, and pain must be controlled adequately. They must meet usual standard

extubation criteria. In some institutions, extubated patients with good liver function can bypass the intensive care unit and are sent to the postoperative recovery unit and then to a regular surgical floor or step-down unit.

Occasionally, the abdominal distension owing to an especially large organ or tissue swelling might prevent primary closure of the surgical wound. These patients are at risk for abdominal tamponade. Abdominal closure can be delayed for several days after transplantation to prevent abdominal compartment syndrome.

Measures must be taken to avoid central line-associated infections. Invasive lines should be removed as soon as appropriate. Function of the new graft must be monitored closely, looking especially for signs of infection, bleeding, and acute rejection. Some patients with bleeding or graft dysfunction may require emergent return to the operating room. Patients may have a difficult postoperative course with significant multiorgan dysfunction, and these patients require expert intensive care.

## REFERENCES

1. Abbasoglu O, Levy MF, Testa G, et al. Does intraoperative hepatic artery flow predict arterial complications after liver transplantation? *Transplantation* 1998;66:598–601.
2. Volk ML, Biggins SW, Huang MA, et al. Decision making in Liver Transplant Selection Committees A Multicenter Study. *Ann Intern Med* 2011;155:503–8.
3. Suraweera D, Sundaram V, Saab S. Evaluation and management of hepatic encephalopathy: current status and future directions. *Gut Liver* 2016;10:509–19.
4. Vilstrup H, Amodio P, Bajaj J, et al. Hepatic encephalopathy in chronic liver disease: 2014 Practice Guideline by the American Association for the Study Of Liver Diseases and the European Association for the Study of the Liver. *Hepatology* 2014;60:715–35.
5. Vaquero J, Fontana RJ, Larson AM, et al. Complications and use of intracranial pressure monitoring in patients with acute liver failure and severe encephalopathy. *Liver Transpl* 2005;11:1581–9.
6. Shami V. Recombinant activated factor VII for coagulopathy in fulminant hepatic failure compared with conventional therapy. *Liver Transpl* 2003;9:138–43.
7. Rabinowich L, Wendon J, Bernal W, et al. Clinical management of acute liver failure: results of an international multi-center survey. *World J Gastroenterol* 2016;22:7595–603.
8. Wiese S, Hove JD, Bendtsen F, et al. Cirrhotic cardiomyopathy: pathogenesis and clinical relevance. *Nat Rev Gastroenterol Hepatol* 2013;11:177–86.
9. Ruíz-del-Árbol L, Serradilla R. Cirrhotic cardiomyopathy. *World J Gastroenterol* 2015;21:11502–21.
10. Lee SS. Cardiac abnormalities in liver cirrhosis. *West J Med* 1989;151:530–5.
11. Zardi EM, Zardi DM, Chin D, et al. Cirrhotic cardiomyopathy in the pre- and post-liver transplantation phase. *J Cardiol* 2016;67:125–30.
12. Zardi EM, Abbate A, Zardi DM, et al. Cirrhotic cardiomyopathy. *J Am Coll Cardiol* 2010;56:539–49.
13. Karagiannakis DS, Vlachogiannakos J, Anastasiadis G, et al. Diastolic cardiac dysfunction is a predictor of dismal prognosis in patients with liver cirrhosis. *Hepatology Int* 2014;8:588–94.
14. Ruíz-del-Árbol L, Achécar L, Serradilla R, et al. Diastolic dysfunction is a predictor of poor outcomes in patients with cirrhosis, portal hypertension, and a normal creatinine. *Hepatology* 2013;58:1732–41.

15. Sonny A, Ibrahim A, Schuster A, et al. Impact and persistence of cirrhotic cardiomyopathy after liver transplantation. *Clin Transplant* 2016;30:986–93.
16. Carvalho F, Rodrigues C, Adrego T, et al. Diastolic dysfunction in liver cirrhosis: prognostic predictor in liver transplantation? *Transplant Proc* 2016;48:128–31.
17. Torregrosa M, Aguadé S, Dos L, et al. Cardiac alterations in cirrhosis: reversibility after liver transplantation. *J Hepatol* 2005;42:68–74.
18. Lee BC, Li F, Hanje AJ, et al. Effectively screening for coronary artery disease in patients undergoing orthotopic liver transplant evaluation. *J Transpl* 2016;2016:7187206.
19. Carey WD, Dumot JA, Pimentel RR, et al. The prevalence of coronary artery disease in liver transplant candidates over age 50. *Transplantation* 1995;59(6):859.
20. VanWagner LB, Serper M, Kang R, et al. Factors associated with major adverse cardiovascular events after liver transplantation among a national sample. *Am J Transplant* 2016;16:2684–94.
21. Wray C, Scovotti JC, Tobis J, et al. Liver transplantation outcome in patients with angiographically proven coronary artery disease: a multi-institutional study. *Am J Transplant* 2013;13:184–91.
22. Hage FG, Bravo PE, Zoghbi GJ, et al. Hypertrophic obstructive cardiomyopathy in liver transplant patients. *Cardiol J* 2008;15:74–9.
23. Robertson A. Intraoperative management of liver transplantation in patients with hypertrophic cardiomyopathy: a review. *Transplant Proc* 2010;42:1721–3.
24. Barbara DW, Rehfeldt KH, Heimbach JK, et al. The perioperative management of patients undergoing combined heart-liver transplantation. *Transplantation* 2015;99:139–44.
25. Martin P, DiMartini A, Feng S, et al. Evaluation for liver transplantation in adults: 2013 practice guideline by the American Association for the Study of Liver Diseases and the American Society of Transplantation. *Hepatology* 2014;59:1144–65.
26. Porcel JM. Management of refractory hepatic hydrothorax. *Curr Opin Pulm Med* 2014;20:352–7.
27. Castaing Y, Manier G. Hemodynamic disturbances and VA/Q matching in hypoxic cirrhotic patients. *Chest* 1989;96:1064–9.
28. Cosarderelioglu C, Cosar AM, Gurakar M, et al. Hepatopulmonary syndrome and liver transplantation: a recent review of the literature. *J Clin Transl Hepatol* 2016;4:47–53.
29. Rodriguez-Roisin R, Krowka M, Herve P, et al. Pulmonary-hepatic vascular disorders (PHD). *Eur Respir J* 2004;24:861–80.
30. Gupta S, Castel H, Rao RV, et al. Improved survival after liver transplantation in patients with hepatopulmonary syndrome. *Am J Transplant* 2010;10:354–63.
31. Collisson EA, Nourmand H, Fraiman MH, et al. Retrospective analysis of the results of liver transplantation for adults with severe hepatopulmonary syndrome. *Liver Transpl* 2002;8:925–31.
32. Ramsay M. Portopulmonary hypertension and right heart failure in patients with cirrhosis. *Curr Opin Anaesthesiol* 2010;23:145–50.
33. Kaspar MD, Ramsay MA, Shuey CB, et al. Severe pulmonary hypertension and amelioration of hepatopulmonary syndrome after liver transplantation. *Liver Transpl Surg* 1998;4:177–9.
34. Krowka MJ, Swanson KL, Frantz RP, et al. Portopulmonary hypertension: results from a 10-year screening algorithm. *Hepatology* 2006;44:1502–10.



35. Robalino BD, Moodie DS. Association between primary pulmonary-hypertension and portal-hypertension - analysis of its pathophysiology and clinical, laboratory and hemodynamic manifestations. *J Am Coll Cardiol* 1991;17:492–8.
36. Swanson KL, Wiesner RH, Nyberg SL. Survival in portopulmonary hypertension: Mayo Clinic experience categorized by treatment subgroups. *Am J Transplant* 2008;8:2445–53.
37. Krowka MJ, Fallon MB, Kawut SM, et al. International liver transplant society practice guidelines: diagnosis and management of hepatopulmonary syndrome and portopulmonary hypertension. *Transplantation* 2016;100:1440–52.
38. Nadim MK, Kellum JA, Davenport A. Hepatorenal syndrome: the 8th International Consensus Conference of the Acute Dialysis Quality Initiative (ADQI) Group. *Crit Care* 2012;16:R23.
39. Schaden E, Saner FH, Goerlinger K. Coagulation pattern in critical liver dysfunction. *Curr Opin Crit Care* 2013;19:142–8.
40. Tripodi A, Mannucci PM. The coagulopathy of chronic liver disease. *N Engl J Med* 2011;365:147–56.
41. Lisman T, Porte RJ. Rebalanced hemostasis in patients with liver disease: evidence and clinical consequences. *Blood* 2010;116:878–85.
42. Hartmann M, Szalai C, Saner FH. Hemostasis in liver transplantation: pathophysiology, monitoring, and treatment. *World J Gastroenterol* 2016;22:1541–50.
43. Clevenger B, Mallett SV. Transfusion and coagulation management in liver transplantation. *World J Gastroenterol* 2014;20:6146–58.
44. Mallett S. Clinical Utility of Viscoelastic Tests of Coagulation (TEG/ROTEM) in patients with liver disease and during liver transplantation. *Semin Thromb Hemost* 2015;41:527–37.
45. Krzanicki D, Sugavanam A, Mallett S. Intraoperative hypercoagulability during liver transplantation as demonstrated by thromboelastography. *Liver Transpl* 2013;19:852–61.
46. Tripodi A. The coagulopathy of chronic liver disease: is there a causal relationship with bleeding? No. *Eur J Intern Med* 2010;21:65–9.
47. Robertson AC, Eagle SS. Transesophageal echocardiography during orthotopic liver transplantation: maximizing information without the distraction. *J Cardiothorac Vasc Anesth* 2014;28:141–54.
48. Schumann R, Mandell MS, Mercaldo N, et al. Anesthesia for liver transplantation in United States academic centers: intraoperative practice. *J Clin Anesth* 2013;25:542–50.
49. Gurusamy KS, Koti R, Pamecha V, et al. Venovenous bypass versus none for liver transplantation. *Cochrane Database Syst Rev* 2011;(3):CD007712.
50. Paugam Burtz C, Kavafyan J, Merckx P, et al. Postreperfusion syndrome during liver transplantation for cirrhosis: outcome and predictors. *Liver Transpl* 2009;15:522–9.
51. Jones RM, Moulton CE, Hardy KJ. Central venous pressure and its effect on blood loss during liver resection. *Br J Surg* 1998;85:1058–60.
52. Massicotte L, Lénis S, Thibeault L, et al. Effect of low central venous pressure and phlebotomy on blood product transfusion requirements during liver transplantations. *Liver Transpl* 2006;12:117–23.
53. Byram SW, Gupta RA, Ander M, et al. Effects of continuous octreotide infusion on intraoperative transfusion requirements during orthotopic liver transplantation. *Transplant Proc* 2015;47:2712–4.

54. Wagener G, Kovalevskaya G, Minhaz M, et al. Vasopressin deficiency and vasodilatory state in end-stage liver disease. *J Cardiothorac Vasc Anesth* 2011;25:665–70.
55. Aniskevich S, Pai S-L. Fast track anesthesia for liver transplantation: review of the current practice. *World J Hepatol* 2015;7:2303–8.