

APC™

in Flexible Endoscopy



Argon Plasma Coagulation

> *A New Paragon
In Flexibility and Efficiency*



Important note

ERBE Elektromedizin GmbH has taken the greatest possible care when compiling these recommendations. Nevertheless, it is impossible to exclude the possibility that errors may be contained herein. The information and recommendations given herein may not be construed as constituting any basis for any claims against ERBE Elektromedizin GmbH. Should legal regulations stipulate liability, such liability shall be limited to intentional misconduct or gross negligence.

The data in respect to areas of application, application duration, or the use of instruments is based on clinical experience; it is important to remember that individual centers and physicians may favor techniques which differ from the information contained within this document.

© on all drawings & illustrations: ERBE Elektromedizin GmbH
(with the exception of photographs of applications)

Contact Information

ERBE USA, Inc.
2225 Northwest Parkway
Marietta, GA 30067-9317
Tel. 800. 778. 3723
Fax. 770. 955. 2577
www.erbe-usa.com

Contents

1.0 Technology	4
1.1 Argon Plasma Coagulation (APC™)	4
1.2 APC Modes	4
1.2.1 FORCED APC®	4
1.2.2 PULSED APC®	5
1.2.3 PRECISE APC®	5
1.3 Description of the Units	6
1.4 APC Instruments	7
1.4.1 APC Probes	7
2.0 Practical Application	8
2.1 Tissue Effects	8
2.2 Recommendations for Applications	8
2.2.1 Factors Influencing the Tissue Effect	8
2.2.2 Duration of Activation	8
2.2.3 Power (“max. watts”) Setting or “Effect” Setting if Using the PRECISE APC Mode	9
2.2.4 Probe Distance	9
2.2.5 Static and Dynamic Applications	9
2.2.6 Different Tissue Sensitivities	9
2.2.7 Which APC Mode Should be Used for Which Areas?	10
2.3 Important Clinical Aspects for the Application of APC	11
2.4 Gastroenterology	12
2.4.1 Devitalization	12
2.4.2 Hemostasis/Coagulation	13
2.4.3 Tumor Ablation	14
2.4.4 APC and Stents	15
2.5 Tracheobronchial Tract	15
2.5.1 Recanalization	15
2.5.2 Hemostasis	16
2.5.3 Stent In-growth and Over-growth	16
3.0 Adverse Conditions and Avoiding Complications	17
4.0 Literature	18

1.0 Technology

1.1 Argon Plasma Coagulation (APC™)

APC™ is a monopolar electro-surgical procedure in which electrical energy is transferred to the target tissue using ionized and, thus, conductive argon gas (argon plasma), without the electrode coming into direct contact with the tissue (Fig. 1).

In contrast to laser technology procedures, the transfer of energy between the electrode and the tissue occurs in accordance with electrophysical laws (electrical field), and not the laws of optics. The argon plasma follows the path of least electrical resistance, regardless of whether the tissue lies directly in front of the electrode or lateral to it, and regardless of the direction of the flow of the argon gas. For the transfer of energy, it is important to ensure the greatest possible concentration of gas between the tip of the probe and the target tissue.

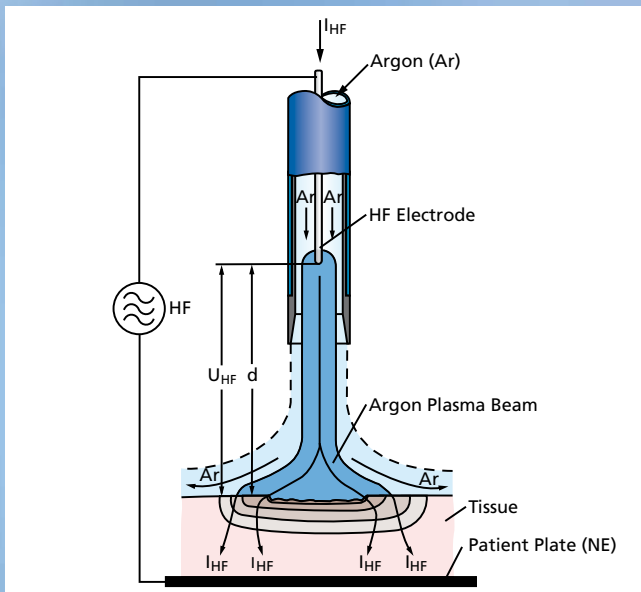


Fig. 1: Transfer of energy from the APC probe to the tissue using ionized argon gas (argon plasma). HF = electrosurgical unit. I_{HF} = high frequency/electrosurgical current, U_{HF} = high frequency voltage, d = distance between electrode and target tissue, Ar = argon, NE = patient plate.

This phenomenon offers particular advantages for endoscopic applications as it permits the argon plasma to be applied both en face and tangentially (Fig. 2), allowing less accessible regions to be treated.

Properties of Argon Gas

Argon (Ar) is a colorless, odorless and tasteless noble gas which is present in air at a percentage of 0.93 Vol %. It is chemically inert and, therefore, non-toxic.

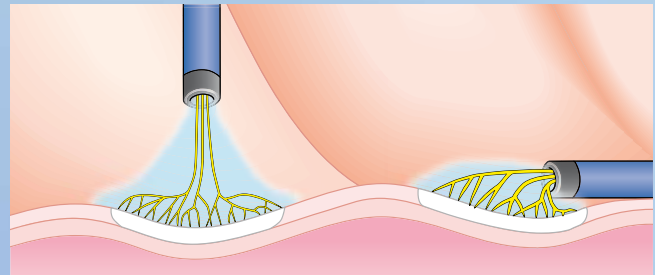


Fig. 2: En face and tangential APC. Light blue: argon gas, yellow-black: argon plasma energy.

1.2 APC Modes

The APC modes, described in more detail below, are current waveforms used for coagulation in monopolar applications. The APC modes: FORCED APC®, PULSED APC® Effect 1 and Effect 2 as well as PRECISE APC® have different coagulation properties that are more suitable for various clinical requirements (See Chapter 2, “PRACTICAL APPLICATION”).

1.2.1 FORCED APC®

The FORCED APC mode in the VIO® APC/ESU System is very similar to the first generation ERBE system (i.e., APC Model 300®/ESU ICC® Model) mode, which was introduced globally in 1992 (USA 1996).

Characteristics

- ⚡ High-frequency voltage increases when the output setting (i.e., wattage) is increased (Fig. 3)
- ⚡ High-frequency output can be adjusted to a maximum of 120 watts
- ⚡ Consistent firing at 30 watts or above with an application distance of up to 5 mm
- ⚡ Continuous application of energy (Fig. 3)
- ⚡ Improved efficiency due to the technology of the VIO Systems: **Tissue effect around 50% higher** than ICC System technology when using the same output settings

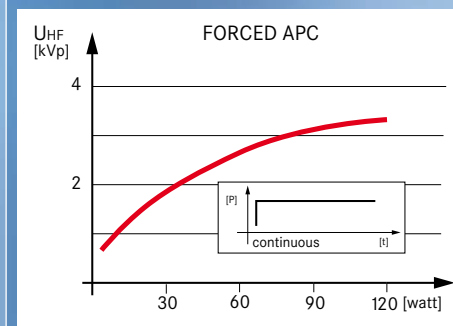


Fig. 3: FORCED APC: Increased voltage (red curve) depending on the selected high-frequency output. Continuous energy output over time (small illustration).

1.2.2 PULSED APC®

The application of energy with the PULSED APC® Effect 1 and Effect 2 is discontinuous (i.e., pulsed) using two different frequencies (Fig. 4). The average energy output over time is the same for both modes.

Characteristics

- ⚡ PULSED APC Effect 1: Higher energy output per pulse with a longer interval between pulses (approx. 1 pulse/second)
- ⚡ PULSED APC Effect 2: Greater number of pulses (16 pulses/second) with a lower energy output per pulse
- ⚡ Compared to FORCED APC®: Constant high-frequency voltage over the whole setting range
- ⚡ Consistent firing from 10 watts with application distances of up to 7 mm (distance between the probe and the tissue). This is limited due to hollow organ intervention.
- ⚡ High-frequency energy output can be adjusted between 1 and 120 watts

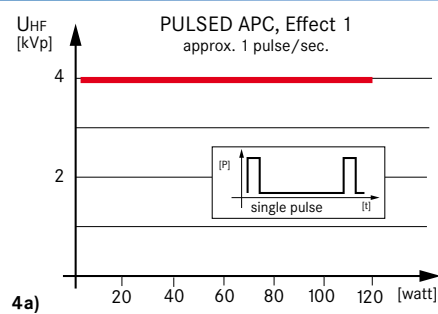
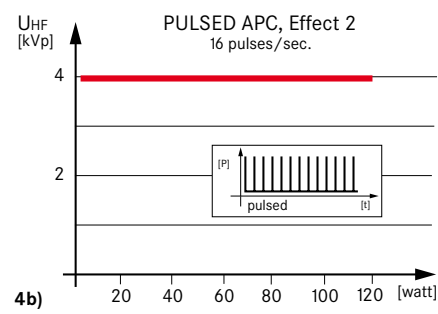


Fig. 4: The voltage for the modes PULSED APC Effect 1 (4a) and PULSED APC Effect 2 (4b) remains constant (red line). The energy is applied with automatic intervals to the tissue in individual pulses (PULSED APC Effect 1) or with a higher number of pulses (PULSED APC Effect 2).



1.2.3 PRECISE APC®

The PRECISE APC® mode has an automatic adjustment control which adjusts the argon plasma regardless of the impedance of the overall system (plasma regulation).

Characteristics

- ⚡ Continuous application of energy
- ⚡ The intensity of the ionized plasma increases when the Effect setting is increased (Fig. 5)
- ⚡ The intensity can be adjusted using the Effect settings 1–8
- ⚡ The tissue effect is more or less independent of the distance (up to 5 mm) between the probe and the tissue (See Fig. 14 on pg. 9)

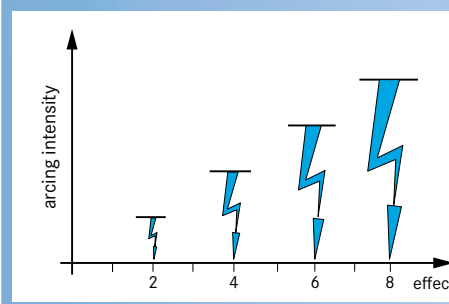


Fig. 5: With the PRECISE APC mode, the intensity of the plasma increases when the Effect setting is increased.

1.3 Description of the Units

The following is a depiction (Fig. 6a) of a complete VIO® ESU/APC System for endoscopic applications, including:

- a VIO ElectroSurgery Unit (ESU) [Model VIO 300 D]
- the associated Argon Plasma Coagulator (Model APC™ 2)
- the Irrigation Pump (Model EIP 2)
- integrated on the VIO Cart


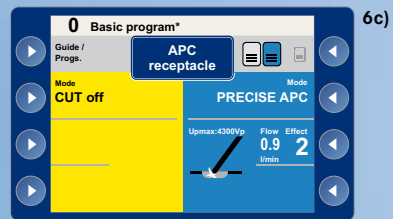
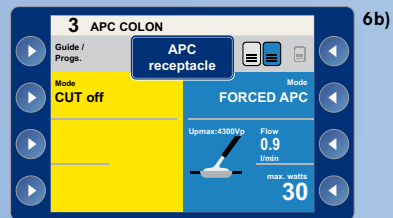


Fig. 6a: VIO workstation

User Interface

All APC modes are coagulation modes and are displayed on the monitor or user interface in the blue field (Figs. 6b and 6c). For the FORCED and PULSED APC® modes, the intensity of the thermal effect can be adjusted using the power (“max. watts”) setting, while for the PRECISE APC® mode, adjustments are made using the “Effect” setting (Figs. 6b and 6c). The gas flow can also be adjusted within certain defined limits depending upon the APC instrument (i.e., applicator or probe) being used (Fig. 6d).

The fill level of the argon gas tank is indicated in the submenu “Select Gas Flow.” If the level in the tank falls below a specific fill level, this will be indicated accordingly on the screen—both when not in use and during use. (Fig. 6d).



Figs. 6b-6d: User interface of the VIO system. Adjustment parameters for the FORCED APC® mode (6b), and the PRECISE APC mode (6c); submenu “Gas Flow” (6d).

APC Purge Button

To have attached APC instruments ready for immediate activation, the instruments should be filled with argon gas prior to the first application. This can be carried out manually by using the **purge button** (Fig. 7).



Fig. 7: Purge button (red arrow) on the APC 2.

1.4 APC™ Instruments

1.4.1 APC Probes

The term “**APC™ Probe**” is used below to describe **flexible** APC instruments which are typically used in endoscopic interventional procedures. In principle, APC probes differ according to their:

- ↕ diameter
- ↕ (working) length
- ↕ tip design (e.g., circumferential)

The length of the endoscope and the size of a working channel being used will dictate the diameter of the APC probe being employed. The distal tip design will determine the direction of the argon gas flow and, for the most part, the plasma direction (Fig. 8a) which will create various plasma and tissue effects (Fig. 8b). There is a choice of Axial (A) StraightFire probes (axial probe tip), SideFire (S) probes (lateral probe tip), and Circumferential (C) probes (circular/360° radius, probe tip).

Probe Tip Design

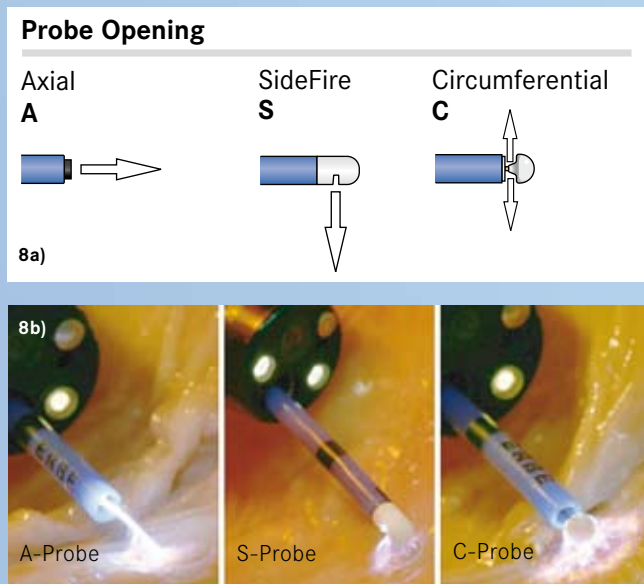


Fig. 8a: Direction of the argon gas flow (arrows) depending on the position of the probe tip design or probe tip; **Fig. 8b:** Plasma and tissue effects of A, S and C probes.

Black rings are visible in intervals of 10 mm at the distal tip of the probe (Fig. 9). To prevent any flashover of the argon plasma to the endoscope (i.e., to keep the beam from damaging the end of the scope), the distal tip of the APC probe should be extended at least 10 mm outside the endoscope. Clearance is achieved once the first black ring of the distal tip is visible through the endoscope (Fig. 9, red marking). The black marking rings can also be used as a scale to estimate distance and the size of lesions.




Fig. 9: Flexible APC probe with connector plug and probe tip with black scale rings.

ERBE APC probes have been designed with instrument recognition. Typically, the VIO® ESU/APC System is programmed with default (starting) settings (Note: Some probes will need an APC hose). Settings can be altered, but only within defined limits. All settings should be confirmed prior to activation.

2.0 PRACTICAL APPLICATION

2.1 Tissue Effects

The tissue effect of APC™ is created by endogenous heating of the target tissue during application of electrical current and/or voltage. Temperature rise can be a determinant of thermal insult (Fig. 10a):

1. Hyperthermia; 2. Devitalization; 3. Coagulation; 4. Desiccation; 5. Carbonization; and 6. Vaporization.

While the insult associate of 1, 2, 3, 4 and 6 may be what is desired clinically, carbonization (or charring) should be kept to a minimum. Argon gas displaces oxygen, thereby minimizing carbonization and preventing an oxidation reaction. The art of APC application is to limit the depth of thermal “insult” to the targeted tissue (Fig. 10b).

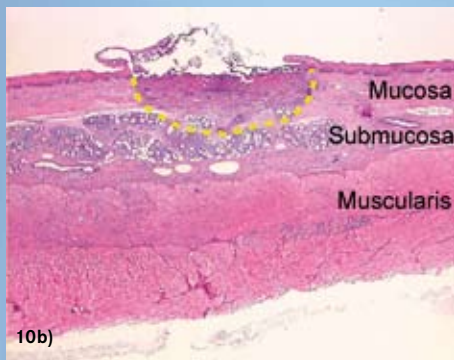
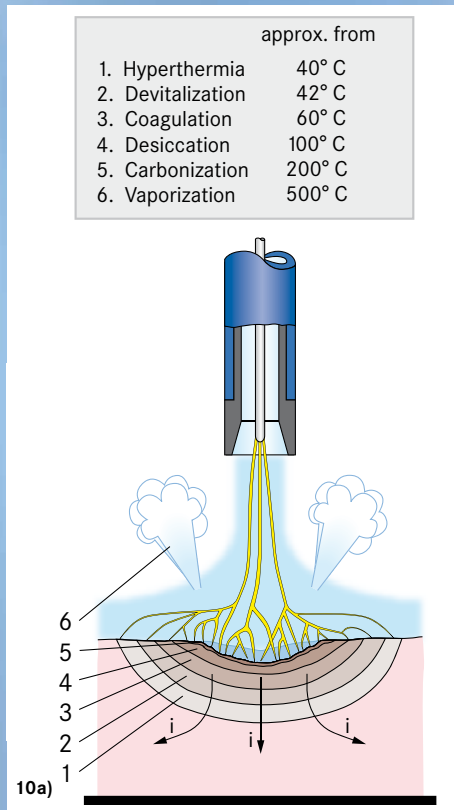


Fig. 10a: Temperature-dependent tissue effects. The arrows marked as “i” indicate the flow of current;
Fig. 10b: Histological cross-section (H&E staining) of a (porcine) esophagus; Radial spread of the coagulation zone (yellow dotted line) after APC application (PRECISE APC® Effect 1, 1 second).

2.2 Recommendations for Applications

2.2.1 Factors Influencing the Tissue Effect

The extent of the thermal insult of APC on tissue depends on several factors. The three most important factors influencing coagulation depth are listed in order of decreasing importance (Fig. 11):

1. The duration of the application, in particular in static applications (i.e., when the probe is stationary)
2. The power (i.e., “max. watts”) setting or “Effect” setting if using the PRECISE APC mode
3. The distance of the probe to target tissue (operative distance)*

* Note: If using the PRECISE APC mode with a probe distance less than 5 mm from the target tissue, the thermal impact is relatively constant.

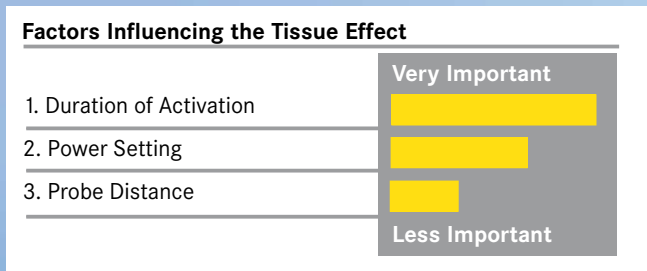


Fig. 11: Factors influencing the tissue effect.

2.2.2 Duration of Activation

When the duration of activation, or application time over the same area is increased, the depth of the tissue being affected will increase (Fig. 12; cf. also 2.2.5). Therefore, the physician should treat with an activation time that corresponds with the desired thermal effect. Nonetheless, the clinician should always use the lowest possible application duration at the beginning of an application and then, while visually monitoring the treated area, gradually increase the duration until the desired clinical outcome is achieved. This applies in particular when treating “difficult” anatomy (e.g., thin-walled areas).

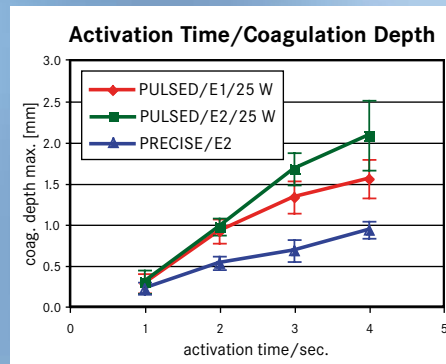


Fig. 12: Depth effect depending on the duration of activation with the APC modes in a bovine liver. Testing was performed with an ESU (VIO® 300 D Model)/APC (APC 2 Model) System along with an A-type (StraightFire) APC probe, O.D. 2.3 mm. Also, the application was vertical and the probe distance was 5 mm.

2.2.3 Power (“max. watts”) Setting or “Effect” Setting if Using PRECISE APC® Mode

The output setting [i.e., power (“max. watts”) or “Effect” for the PRECISE APC® mode] depends on the location and the size (diameter, depth, elevation) of the area being treated. Figs. 13a and 13b show the increase in depth of penetration depending upon the power or Effect setting with the PULSED APC® and PRECISE APC modes. Generally, output setting guidelines are as follows:

- ✦ Lower output settings are suitable for the treatment of very superficial small areas, in applications with very thin-walled tissue structures
- ✦ Mid-range output settings are used in flexible endoscopy for a wide range of applications where hemostasis, devitalization (i.e., depriving tissue of life), and/or reduction of undesirable growth is desired
- ✦ Very high relative output settings are typically used in palliative treatments, when devitalization is required, and in the reduction of tissue

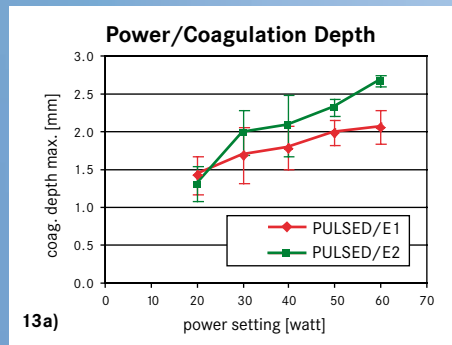


Fig. 13a: Depth of penetration on bovine liver depending on the power setting when using PULSED APC mode with an A-type (StraightFire) APC™ probe, O.D. 2.3 mm;

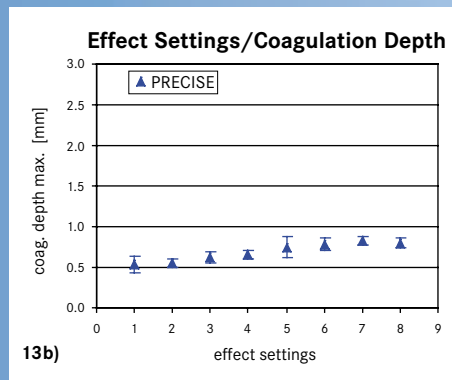


Fig. 13b: Depth of penetration on bovine liver depending on the Effect setting when using PRECISE APC with an A-type (StraightFire) APC probe, O.D. 1.5 mm. Testing was performed with an ESU (VIO® 300 D Model)/APC (APC 2 Model) System. Also, the application was vertical, the probe distance was 5 mm, and the application duration was 3 seconds.

2.2.4 Probe Distance

When using the modes FORCED APC®, PULSED APC Effect 1 and PULSED APC Effect 2, the following applies: As the distance of the distal tip of the probe to the tissue increases, the tissue effect becomes more superficial, and the penetration depth decreases. When using the PRECISE APC mode, the tissue effect remains more or less constant up to a distance of 5 mm. However, due to plasma regulation with the PRECISE APC mode, an increase in penetration depth may occur with probe distances greater than 5 mm from the target tissue (Fig. 14).

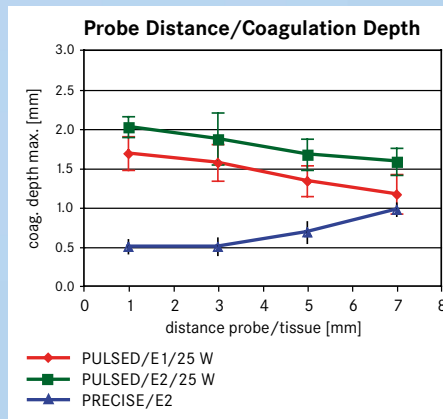


Fig. 14: Depth of effect depending on the distance of the probe to the bovine liver, using an ESU (VIO® 300 D Model)/APC (APC 2 Model) System with an A-type (StraightFire) APC probe, O.D. 2.3 mm. Also, the application was vertical, and the application duration was 3 seconds.

2.2.5 Static and Dynamic Applications

When APC™ is applied statically (i.e., the probe is focused only on a single area), the thermal penetration depth will increase over time. If applied for long periods in the same area, carbonization or vaporization can occur, which may lead to over-treatment and adverse events. Therefore, when carrying out a static application for a superficial treatment, short activation times of 1 to 2 seconds are recommended.

When using APC dynamically, move the instrument with paintbrush-like strokes over the target area while observing the target tissue effect.

2.2.6 Different Tissue Sensitivities

When carrying out APC in the gastrointestinal tract, it is important to take into account the different thermal sensitivities of wall structures (Fig. 15).

Thermal sensitivity may be increased if the lumen wall has been excessively distended by the insufflation of air.

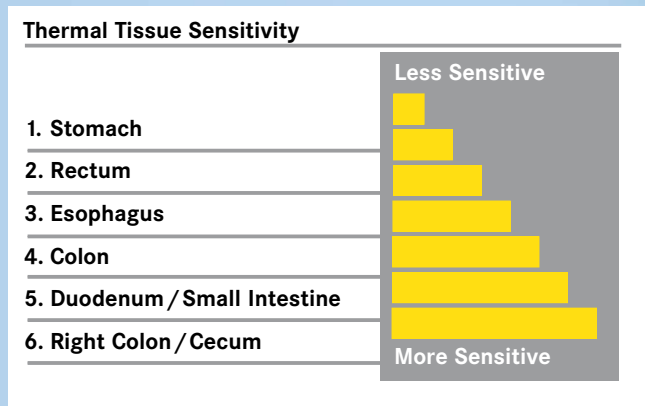


Fig. 15: Thermal tissue sensitivity.

2.2.7 Which APC™ Mode Should be Used for Which Areas?

Different APC™ modes are suitable for different applications, depending on the location of the target tissue requiring treatment, and the intended desired clinical outcome.

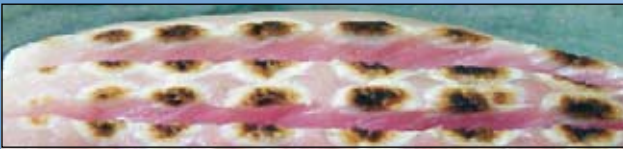FORCED APC®

ERBE's VIO® Model ESU is approximately 50% greater in efficiency in regards to tissue effect, compared to the technology of our older generation ICC Models. That said, the FORCED APC® mode in a VIO ESU/APC System is used particularly for hemostasis of small diffuse areas of bleeding, as well as the devitalization (i.e., depravity of life) and reduction of target tissue. The characteristic feature of this mode is the constant ionized plasma in an ever-changing environment of resistance variables. Figure 16 shows the resulting effect (depth of thermal insult and relative diameter of coagulation volume) of FORCED APC at various settings in an ex vivo model. The ex vivo bench testing of FORCED APC is indicative of its potential to rapidly devitalize target tissue for ablative and hemostatic purposes.

Areas of Application:

- ✦ Rapid devitalization of target tissue for ablative and hemostatic purposes
- ✦ Acute bleeding
- ✦ Devitalization and reduction of undesirable lesions

Fig. 16



Initial ex vivo bench testing. In vivo clinical results will vary.

PULSED APC® Effect 1 and Effect 2

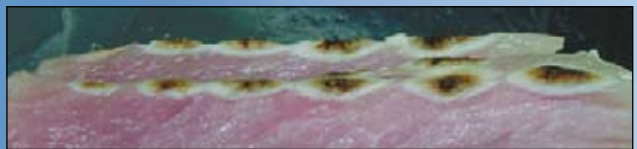The PULSED APC® modes – Effect 1 and Effect 2 – are used for the hemostasis of diffuse areas of bleeding, as well as for the devitalization (i.e., depravity of life) and reduction of target tissue when controlled power output is preferred (e.g., in thermosensitive areas and/or in thin-walled structures).

Since this APC mode is pulsed and not continuous, its ionized plasma is more dispersive, with less output energy being delivered (Fig. 17 PULSED APC Effect 2 ex vivo bench testing) relative to FORCED APC modes. As a result, the effect on tissue is controlled and more superficial. Therefore, with visual monitoring, there is generally less carbonization and less complicated target tissue application in vivo. While more superficial in nature, long activations can cause significant and deep devitalization of tissue.

Areas of Application:

- ✦ Hemostasis of diffuse bleeding over larger areas
- ✦ PULSED APC Effect 1 (short individual pulses): More focused (less diffuse) ionized plasma for static applications in the treatment of smaller, more superficial areas, as well as thermosensitive and/or thin-walled structures
- ✦ PULSED APC Effect 2 (higher frequency of pulses): For the treatment of diffuse, superficial anatomy for devitalization and reduction of target tissue using static applications for longer periods of time

Fig. 17



Initial ex vivo bench testing. In vivo clinical results will vary.

PRECISE APC®

The PRECISE APC® mode creates a superficial coagulation effect using a low-energy output per unit of time. It is therefore suitable in temperature-sensitive areas and/or within thin-walled structures. For the most part, the tissue effect is independent of the distance between the probe and the tissue, and only a superficial thermal effect is created. The fact that the effect created is independent of the distance between the probe and the tissue (up to a distance of 5 mm) is an advantage when external circumstances make it difficult or impossible to maintain a specific distance between the probe and tissue.

Areas of Application:

- ✦ Hemostasis in which the bleeding is superficial
- ✦ In thermosensitive areas and/or within thin-walled structures
- ✦ Devitalization and reduction of undesirable lesions/remnants that are superficial in nature
- ✦ In situations where it is hard to maintain a specific probe distance from the tissue (e.g., enteroscopic intervention)

Fig. 18



Initial ex vivo bench testing. In vivo clinical results will vary.

2.3 Important Clinical Aspects for the Application of APC™

Important clinical aspects for applying the new technology in ERBE's VIO® ESU/APC System, or when using APC™, are summarized as follows:

1. Greater efficiency with the VIO ESU/APC System

As compared to ERBE's first generation ESU ICC/APC 300 Models, the VIO ESU/APC Systems' output efficiency is approximately 50% greater – that is, the power (“max. watts”) settings of the VIO ESU/APC System are approximately one-half of the settings that would be employed with ICC ESU/APC Systems.

2. The APC probe must always remain in the clinician's field of vision

To prevent any damage to the instrument channel and/or the tip of the endoscope, the APC probe must extend at least 10 mm beyond the end of the scope [i.e., The first distal black ring of the APC probe must be visible (Fig. 19)]. During non-static applications, it is important (when possible) to move the endoscope backwards/forwards and side-to-side with the APC probe and never move the probe by itself except when technique or anatomy dictates (e.g., retroflexed).

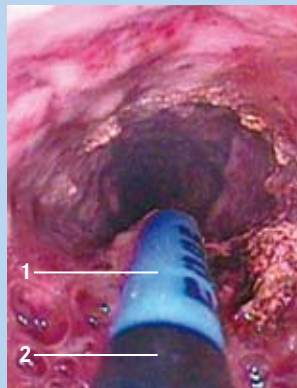


Fig. 19: Endoscopic tangential view of the tissue and the APC probe: 1) Probe tip; 2) Black marking ring.

3. Activate only when the tissue being treated is within the field-of-view

4. Use the lowest possible settings to achieve the desired thermal tissue effect

The lowest possible output setting [i.e., power (max. watts) and “Effect” when using PRECISE APC] and activation times should be used with APC treatment. As previously stated, the penetration depth of the thermal effects created by APC depends on various factors. It is particularly important to have low-energy outputs and activation times in thermosensitive areas and/or within thin-walled structures.

5. Do not activate the StraightFire APC probe when en face and touching target tissue

APC is a non-contact modality. The StraightFire probe can lightly touch tissue adjacent to targeted mucosa when working tangentially, such as in the right colon or cecum. This tangential approach (Fig. 19) maintains the non-contact principle of ionized plasma application. The outer shell of the probe is not “electrified.” If the StraightFire probe is activated while touching mucosa en face (Fig. 20a on pg. 12), it may become a contact monopolar electrode, and deeper necrosis is likely. Also, the flow of the argon gas may cause a submucosal emphysema, or collection of gas, which usually resolves spontaneously, but perforation cannot be ruled out in this case.

Circumferential probes were added to the system to allow light tamponade en face, or tangential application in difficult anatomy, in order to maintain probe position prior to activation.

A mechanical perforation can occur if the endoscope or APC probe is pushed into a wall.

To reiterate: It is particularly important when working en face with the APC StraightFire probe to maintain a sufficient distance (> 1 mm) from tissue when treating thin-walled structures (Fig. 20b on pg. 12).

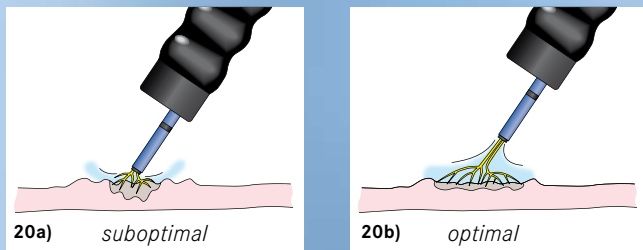


Fig. 20a: The probe is too close to the tissue, which may result in an undesirable thermal effect and/or submucosal emphysema; **Fig. 20b:** The distance of the probe is sufficient, leading to a more even distribution of current.

6. Avoid APC™ activation in close proximity of metal objects

Do not activate an APC™ probe if the distal tip is close to a metal object (e.g., metal clips, metal stents, etc.) unless the intent is to work on the object (e.g., “trimming” of a metal stent). The electric arcs could flash over and create an unintended coagulation (Fig. 21).

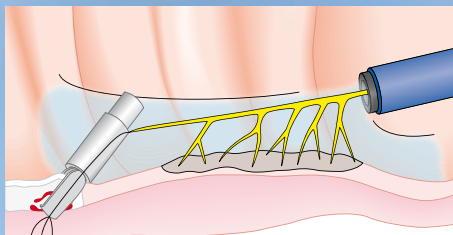


Fig. 21: Unintended flashover of electric probe to a metal clip.

Furthermore, with metal being a good conductor of electrical current, a metal object may be damaged, or tissue in contact with the object may be unintentionally burned. Finally, this issue is exaggerated when using the PRECISE APC® mode, due to plasma regulation.

7. The use of argon gas in the gastrointestinal tract may cause over-distention

If APC is being used in the gastrointestinal tract, over-distention can occur, due to the introduction of the argon gas. Therefore, the abdomen should be continuously monitored for signs of becoming overly distended. Brief and repeated aspiration of gas should be performed throughout the procedure.

8. Avoid using APC in an environment in which combustible gases are present

Prior to activation, make sure there are no endogenous combustible gases present (i.e., make sure hydrogen, methane, etc., are removed from the bowel prior to working in the tract). Also, as part of the procedure, oxygen and other gases (e.g., hydrogen) may be introduced and concentrated in an organ. In these situations, the gases should be evacuated via a channel of the scope prior to activation. Finally, combustible gaseous by-products of electrosurgery may build up. Therefore, gases should be removed routinely from the clinical site during the procedure.

9. Do not activate APC in an oxygen-rich environment

When carrying out APC applications in the presence of oxygen, the oxygen concentration should be as low as possible (i.e., below 40%, $FiO_2 < 0.4$) in order to reduce the possibility of any explosion or burning.

NOTE: Indications for use is as follows: The ERBE VIO® APC with accessories is intended to deliver argon gas for argon plasma coagulation of tissue, when used in conjunction with a compatible ERBE VIO Electrosurgical Generator (ESU) and applicators or probes. The clinical applications in gastroenterology and in the tracheobronchial system outlined in this educational brochure are commonly found in published literature. The information with the applications is being provided for guidance purposes only (i.e., clinical education per the published literature) and is not intended to endorse or infer specific indications.

2.4 Gastroenterology

See Insert A: “Gastroenterology Uses found in Clinical Literature”

2.4.1 Devitalization

Devitalization (i.e., depriving tissue of life) with APC leads to thermal damage of the tissue.

2.4.1.1 Devitalization of Adenoma Remnants (after polypectomy or EMR procedures)

After polypectomy or endoscopic mucosal resection (EMR) of adenomatous lesions, there may remain some tissue remnants along the edge of the resected area, particularly after a piecemeal EMR procedure. APC has been used to treat such small residual tissue remnants, either during the same endoscopic session or during a follow-up examination, to prevent or delay any recurrences (Fig. 22).^{5, 20, 34, 52, 54}

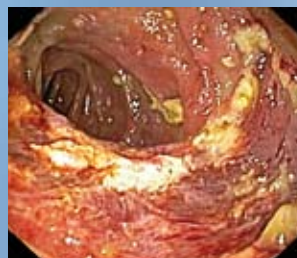

Fig. 22: APC-treated residual adenoma in the colon after endoscopic mucosal resection (EMR).

2.4.1.2 Barrett’s Esophagus

Thermoablative procedures for the removal of precancerous Barrett’s esophagus have not been sufficiently validated and are currently the subject of further clinical studies.

However, APC has been found to play a role in the removal of non-neoplastic residual Barrett’s mucosa after endoscopic removal of intestinal metaplasia (Fig. 23). APC has also been reportedly used

in such lesions for ablation of tumors which cannot be removed by repeat endoscopic resection^{23, 26, 40, 41} and for the ablation of small tumor remnants along the resected margins after endoscopic resection.

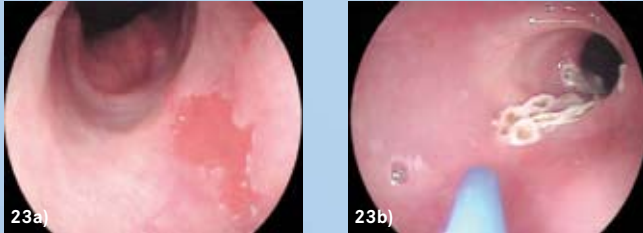


Fig. 23a: Barrett's metaplasia before and Fig. 23b: after ablation with APC™.

2.4.1.3 Zenker's Diverticulum

In the past few years, APC has been used in endoscopic procedures to treat Zenker's diverticulum.^{25, 27, 52}

The attachment of a cap to the tip of the endoscope, as well as the placing of a nasogastric tube, can help to improve visualization of the anatomical presentation (Fig. 24). An average of 2 – 3 sessions are usually required.

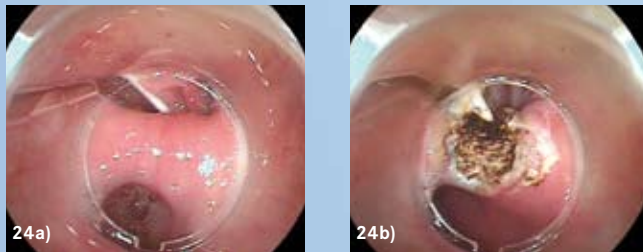


Fig. 24a: Zenker's diverticulum before and Fig. 24b: after treatment with APC, using a cap.

2.4.2 Hemostasis/Coagulation

Thermal hemostasis is achieved with relatively low-energy outputs by making use of the following effects:

1. Denaturation of small vascular lesions (thermal coagulation)
2. Activation of the endogenous clotting cascade
3. Retraction of coagulated vessels
4. Compression of vessels due to the tissue shrinkage contingent upon desiccation

APC is frequently used to treat chronic and actively bleeding lesions of the gastrointestinal tract. Especially diffuse venous and arterial bleeding can be controlled very well by APC (Fig. 25). The use of APC to treat actively spurting bleeding as part of a combined therapy is currently being studied.

To treat diffuse bleeding of large surfaces, such as radiation-induced proctopathy (radiation proctitis), it is necessary to carry out coagulation over a larger surface, while limiting the penetration depth. In such cases, it is recommended to move the

APC probe over the tissue using paintbrush-like strokes (“non-static applications”).

For the hemostasis of stronger, locally limited bleeding, a deeper coagulation or occlusion of the injured vessel is necessary. In such cases, the thermal energy should be delivered to the tissue via more static application.

2.4.2.1 Radiation Proctitis

Radiation proctitis can take the form of teleangiectasias and hemorrhagic mucosal changes in the area of the rectum (Fig. 25a). The use of APC to treat radiation proctitis may lead to an improvement of symptoms and bleeding episodes after an average of two sessions carried out at an interval of 3 – 4 weeks.^{6, 21, 30, 43, 47, 48, 51, 52}

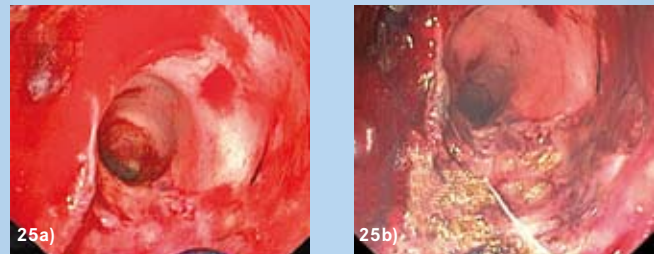


Fig. 25a: Bleeding over a larger surface area due to radiation proctitis and Fig. 25b: after hemostasis with APC.

2.4.2.2 Vascular Malformations

[Gastric antral vascular ectasia (GAVE syndrome), angiodysplasias, arterio-venous malformations (AVM), portal hypertensive gastropathy, teleangiectasias]

Many different vascular malformations, in all areas of the gastrointestinal tract, have been treated with APC, and have been used to prevent the recurrence of bleeding. Depending on the indication, APC is applied in conjunction with proton-pump-inhibitor therapy (GAVE syndrome) or other medications.^{20, 22, 30, 38, 39, 52, 53}

Usually an application using a low-energy output is sufficient to staunch the bleeding. The use of low-energy outputs also helps to minimize the risk of perforation in thin-walled areas (e.g., the small intestine or the right colon), where angiodysplasias often occur.

Endoscopic procedures, such as double-balloon endoscopy, have proved useful for the treatment of vascular malformations in the small intestine, as has the use of a cap to limit the area under treatment, to create an optimal argon gas atmosphere and help maintain the proper distance.

Figs. 26 and 27 on pg. 14 show hemostasis of angiodysplasias in the stomach and colon. Fig. 28 shows the therapeutic treatment of GAVE syndrome.

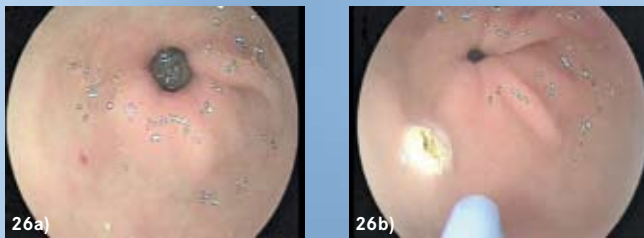


Fig. 26a: Angiodysplasia located in the gastric antrum before, and **Fig. 26b:** after treatment with APC™.

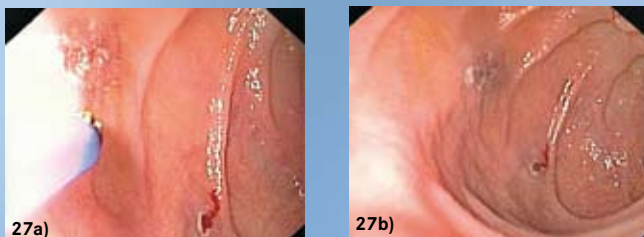


Fig. 27a: Angiodysplasia located in the colon before, and **Fig. 27b:** after treatment with APC.

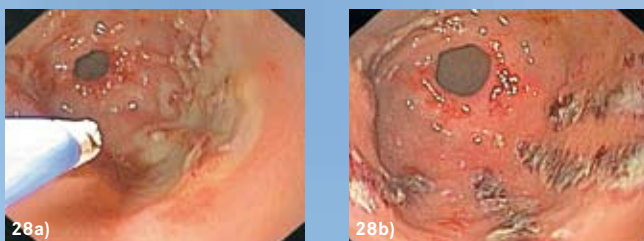


Fig. 28a: GAVE syndrome before, and **Fig. 28b:** after treatment.

2.4.2.3 Bleeding Ulcer

Current ongoing clinical studies have indicated that while the use of APC for the hemostasis of bleeding peptic ulcers is not yet commonly used, it has been shown useful in limited reports.^{7, 9, 24, 43}

The therapy is particularly useful for the treatment of Forrest Ib-IIb bleeding as part of a multimodal therapeutic approach and is currently being evaluated in clinical studies.

2.4.2.4 Variceal Bleeding

APC is not a standard therapy for the treatment of variceal bleeding. Up until now, APC was only used in investigational cases – as part of a combination therapy, not as a monotherapy. Its use is currently being evaluated in controlled studies. APC may be useful for the treatment of residual varices and/or ulcerated varices.

Due to the limited data available, it is not yet possible to offer any further discussion.^{9, 15, 28}

2.4.3 Tumor Ablation

The preferred form of tissue ablation of large tumor masses (debulking) using APC is by means of vaporization/coagulation using very high-energy outputs. In addition to the tumor masses which are directly excised, in the days following the intervention, thermally necrotized tissue will also slough off. There will also be tissue shrinkage created by desiccation of the tissue, further reducing the exophytic tissue.

In certain cases, it may be helpful to perform APC in combination with other endoscopic procedures (i.e., as bougienage) in order to ensure the free passage of nourishment (e.g., in the esophagus).

Figs. 29 and 30 show the ablation of a duodenal adenoma using APC.

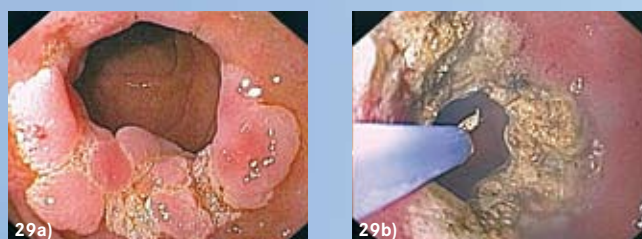

Fig. 29a: Large duodenal adenoma before, and **Fig. 29b:** after ablation using APC.

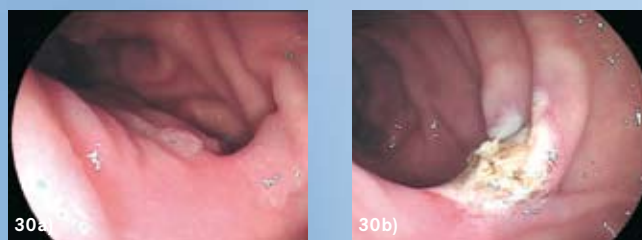


Fig. 30a: Duodenal adenoma before, and **Fig. 30b:** after APC therapy.

2.4.3.1 Stenoses (Recanalization)

While endoscopic laser ablation is the most common method used for the recanalization of obstructive lesions in the gastrointestinal tract, APC is an effective and often simpler alternative.^{1, 12, 14, 19, 25, 37, 52} In many cases, APC has already replaced the laser in everyday clinical use.

Stenotic sections may undergo mechanical dilatation prior to the procedure to prevent any build-up of potentially explosive gases; such obstructed sections should not be primarily opened up by APC.

2.4.4 APC™ and Stents

The APC™ applications described below (with the exception of section 2.4.4.1) refer primarily to its reported use with metal stents in the gastrointestinal tract.

2.4.4.1 Preparations for Stent Implantation

Prior to the implantation of a stent, it is often necessary to open up or widen the lumen. With APC, it is possible to carry out extensive recanalization of a stenosis, making subsequent placement of the stent easier.

2.4.4.2 Stent In-growth and Over-growth

Proliferation of tumor tissue through the mesh of the stent often occurs when using non-coated metal stents (Fig. 31). APC has been shown to be effective in removing such in-growths and over-growths.¹⁴

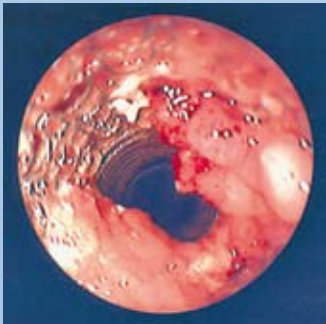


Fig. 31: Tissue over-growth of a metal stent.

2.4.4.3 Extraction of Metal Stents

When removing a metal stent, it is possible to perform an extensive APC ablation to devitalize tissue in-growths in the metal mesh before removing the stent; this will make it easier to remove the stent with forceps.

2.4.4.4 Stent Shortening (“Trimming”)

Self-expanding metal stents are often placed in patients with obstructive diseases of the gastrointestinal tract. Over time, such stents may become displaced or, if the initial placement is inaccurate, the stent may present a risk of bleeding or ulceration. In order to avoid removing the entire stent, the projecting ends of the stent have been shortened (“trimmed”) using APC,^{8, 11, 17, 48} as reported in the literature.

In such a case, the distal tip of the probe is placed close to the wire requiring separation within the stent. When the APC is activated, the ionized plasma flows to the wire closest to the probe tip, resulting in rapid heating and melting of the wire. This procedure is continued around the entire circumference of the stent until the projecting end is separated.

The shortening of plastic stents or coated metal stents with the help of APC is currently being investigated in clinical research.

2.5 Tracheobronchial Tree

See Insert B: “Pulmonary Uses found in Clinical Literature”

APC is used in therapeutic bronchoscopy interventions for the hemostasis of bleeding (local and diffuse hemoptysis), for the partial or complete recanalization of symptomatic tracheal and bronchial stenoses, and to remove malignant and benign tumor growths.^{10, 35, 36, 45}

An advantage of APC, compared to non-thermal therapeutic procedures (e.g., brachytherapy), is its immediate effect.

When using thermal procedures in the tracheobronchial tree, it is important to ensure that the concentration of oxygen in the air is low ($\leq 40\%$, $\text{FiO}_2 < 0.4$) in order to reduce the risk of any complications during application.

2.5.1 Recanalization

As in the treatment of stenoses in the gastrointestinal tract, the use of APC to treat malignant stenoses in the respiratory tract can result in an objective improvement of the stenosis and its symptoms (Fig. 32) and offers benefits for subsequent therapy, which may consist of radio- and/or chemotherapy, stent implantation or an operation.^{10, 35}

A combined approach using APC and subsequent mechanical tumor ablation (e.g., using forceps) can be used to effectively treat patients with large tumors and life-threatening stenoses.^{10, 35, 36}

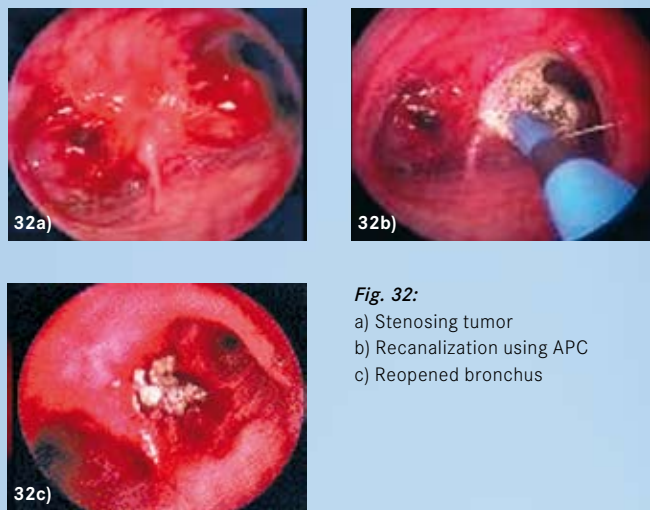


Fig. 32:
a) Stenosing tumor
b) Recanalization using APC
c) Reopened bronchus

PRACTICAL APPLICATION

2.5.2 Hemostasis

Due to the hemostatic properties of APC™ (previously described in section 2.4.2), spontaneous bleeding – including bleeding caused by tumors, local or diffuse bleeding, and bleeding after biopsies taken in the tracheobronchial tract – can be staunched effectively (Fig. 33).³⁵

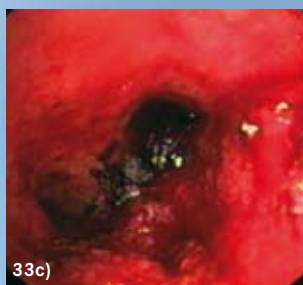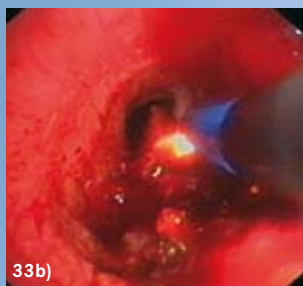

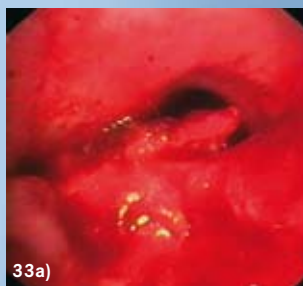
Fig. 33: Hemostasis with APC:
a) Before
b) During
c) After APC therapy

2.5.3 Stent In-growth and Over-growth

As in the gastrointestinal tract (See section 2.4.4.2), stent in-growths and over-growths in the tracheobronchial tract can be removed using APC (Fig. 34).³⁷

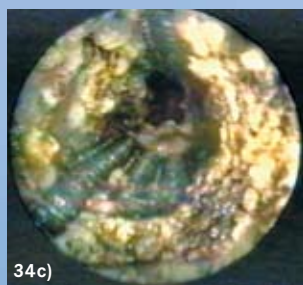
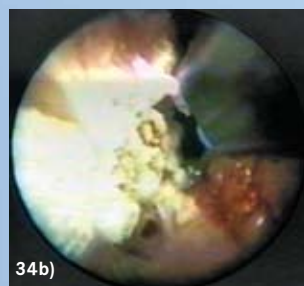
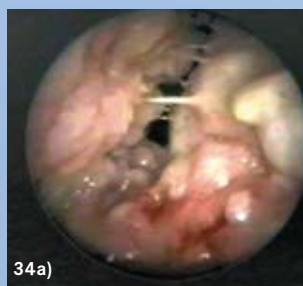

Fig. 34: Stent in-growth and over-growth:
a) Initial state
b) Treatment with APC
c) Postoperative appearance

3.0 ADVERSE CONDITIONS AND AVOIDING COMPLICATIONS

Gastrointestinal Tract

Pain

Due to the lack of innervation in most of the Gastrointestinal Tract (GIT), pain is not directly experienced during APC™ application. However, in the distal part of the anal canal (at the level of the dentate line, or in individual cases up to 1.5 cm above this line), patients may experience pain. This pain usually abates very quickly when treated conservatively with analgesics and/or anti-inflammatory medications.

Other indirect triggers of pain during the procedure may be caused by excessive dilatation, due to gas or over-manipulation of the endoscope. Similarly, after APC applications, indirect pain may be experienced in the vicinity of the dentate line, due to muscular spasms caused by extreme contractions of the external anal sphincter.^{6, 25, 29, 33, 49, 51}

Finally, after the application of APC in the esophagus, post-interventional odynophagia (painful swallowing) and retrosternal pain has been reported.

Gas Emphysema

Argon gas emphysema is a reversible collection of argon gas in the area of the target tissue and/or in the tissue in its immediate vicinity and, as a rule, has no pathological importance.^{16, 49} Clinically, it presents itself as a soft, submucosal bleb created by direct contact of the tissue with the probe. Nonetheless, the clinician should try to keep the APC probe from coming into contact with the tissue when using the StraightFire probe en face.

NeuroMuscular Stimulation (NMS)

A known risk of electrosurgery is the unintentional electrical stimulation of the patient's nerves and muscles. Such stimulation may be caused by low-frequency electrical currents, which are produced either by low-frequency power sources or electric arcs between the active electrode and the patient's tissue. This can result in strong spasms or muscle contractions.

Normal/ESU alternating current with a frequency above 300 kHz cannot stimulate nerves and muscles. If nerve or muscle stimulation is observed, the instruments and wire connections should be checked for integrity (Note: Demodulation can be caused by loose connections, incomplete insulation, etc. anywhere along the circuit including areas that may not be visible.). If the situation is not remedied, a change of cord, instrument, and/or of the Mode may rectify the situation.

Gas Explosion/Combustion

When applying APC and other energy sources in the GIT, a deflagration of potentially present, flammable gases in the intestine can occur if the intestine was not cleaned properly previous to the intervention; in the worst case, this can result in a gas explosion.^{2-4, 31, 32, 44} Follow a proper preparatory procedure to reduce the risks of bowel explosion.

Perforation

Despite its physically limited depth effect, perforation can occur when using APC.^{13, 18} The following preventive measures are therefore recommended:

- ❖ Activation in static applications should be short (1-2 sec)
- ❖ Output settings and application durations must take into account the indication and location of the lesion (thickness of the wall)
- ❖ The distance between probe and tissue should be 1-5 mm (depending on the APC mode used), especially when working en face with StraightFire probes
- ❖ Avoid physical stresses to the intestinal wall (over-insufflation, mechanical manipulation)
- ❖ Particular care must be taken when treating previously damaged tissue, (e.g., infiltrated, ulcerated or scarred tumor tissue, ulcers or muscularis mucosae exposed after endoscopic resection)

Tracheobronchial System

Gas Embolism

When applying APC, a combination of unfavorable conditions, such as large, open venous vessels and an intraluminal pressure which is higher than the venous pressure, can result in a transfer of gas from the APC probe into the open vessel, with subsequent creation of a gas embolism. This phenomenon has been described in isolated cases in which the intervention took place under general conditions of excess positive pressure; thus, it is more of a problem with laparoscopic than endoscopic interventions (e.g., bronchoscopy).

The following measures can help to prevent the occurrence of a gas embolism:

- ❖ Reduce the argon flow to the minimum level required to achieve the desired tissue effect
- ❖ Avoid holding the APC probe such that it is perpendicular to the tissue, and avoid any contact between the probe and the tissue
- ❖ Do not aim the probe directly at large, open vessels
- ❖ Maintain good field-of-view

Perforation

Despite its physically limited depth effect, perforation can occur when using APC. The following preventive measures are therefore recommended:

- ❖ Activation in static applications should be short (1-2 sec)
- ❖ Output settings and application durations must take into account the indication and location of the lesion (thickness of the wall)
- ❖ The distance between probe and tissue should be 1-5 mm (depending on the APC mode used) especially when working en face with StraightFire probes

Combustion

The presence of combustible gases should be avoided when performing APC procedures within the tracheobronchial tree. When carrying out APC in the tracheobronchial system, oxygen concentration should be as low as possible (i.e., below 40%, FiO₂ < 0.4) in order to reduce the possibility of combustion if such gases are present.

4.0 LITERATURE

Publications

1. Akhtar K, Byrne JP, Bancewicz J, Attwood SE. Argon beam plasma coagulation in the management of cancers of the esophagus and stomach. *Surg Endosc* 2000;14:1127-1130.
2. Avgerinos A, Kalantzis N, Rekoumis G, Pallikaris G, Arapakis G, Kanaghinis T. Bowel preparation and the risk of explosion during colonoscopic polypectomy. *Gut* 1984;25:361-364.
3. Bigard MA, Gelot MA, Dollet JM, Champigneulle B, Gaucher P. [Concentration of explosive colonic gases after preparation by polyethylene glycol solution]. *Gastroenterol Clin Biol* 1987;11:610.
4. Bisson B. Methane gas explosion during colonoscopy. *Gastroenterol Nurs* 1997;20:136-137.
5. Brooker J, Saunders B, Shah S, Thapar C, Suzuki N, Williams C. Treatment with argon plasma coagulation reduces recurrence after piecemeal resection of large sessile colonic polyps: A randomized trial and recommendations. *Gastrointest Endosc* 2002;55:371-375.
6. Canard JM, Vedrenne B, Bors G, Claude P, Bader R, Sondag D. [Long term results of treatment of hemorrhagic radiation proctitis by argon plasma coagulation]. *Gastroenterol Clin Biol* 2003;27:455-459.
7. Chau CH, Siu WT, Law BK, Tang CN, Kwok SY, Luk YW, Lao WC, Li MK. Randomized controlled trial comparing epinephrine injection plus heat probe coagulation versus epinephrine injection plus argon plasma coagulation for bleeding peptic ulcers. *Gastrointest Endosc* 2003;57:455-461.
8. Chen YK, Jakribettuu V, Springer EW, Shah RJ, Penberthy J, Nash SR. Safety and efficacy of argon plasma coagulation trimming of malpositioned and migrated biliary metal stents: A controlled study in the porcine model. *Am J Gastroenterol* 2006;101:2025-2030.
9. Cipolletta L, Bianco M, Rotondano G, Piscopo R, Prisco A, Garofano M. Prospective comparison of argon plasma coagulator and heater probe in the endoscopic treatment of major peptic ulcer bleeding. *Gastrointest Endosc* 1998;48:191-195.
10. Crosta C, Spaggiari L, De SA, Fiori G, Ravizza D, Pastorino U. Endoscopic argon plasma coagulation for palliative treatment of malignant airway obstructions: Early results in 47 cases. *Lung Cancer* 2001;33:75-80.
11. Demarquay J, Dumas R, Peten E, Rampal P. Argon Plasma Endoscopic Section of Biliary Metallic Prostheses. *Endoscopy* 2001;33:289-290.
12. Eickhoff A, Jakobs R, Schilling D, Hartmann D, Weickert U, Fischer K, Eickhoff JC, Riemann JF. Prospective evaluation of the new VIO 300-D Argon-Plasma-Coagulation System for palliation of gastrointestinal tumors: FORCED APC vs. PULSED APC. Eingereicht zur Publikation. *Endoscopy* 2007.
13. Farin G, Grund KE. Technology of argon plasma coagulation with particular regard to endoscopic applications. *Endosc Surg Allied Technol* 1994;2:71-77.
14. Frank J, Queck J, Koukaki S, Koch A, Beermann W, Tsenekidis S, Jollet N. Modifizierte Argon-Plasma-Koagulationsmodi und erste unizentrische klinische Erfahrungen in der gastroenterologischen Endoskopie. *Endoskopie heute* 2006;15-22.
15. Furukawa K, Aoyagi Y, Harada T, Enomoto H. The usefulness of prevention consolidation therapy of esophageal varices using an argon plasma coagulation technique. *Hepatol Res* 2002;23:220-225.
16. Grund KE, Zindel C, Farin G. [Argon plasma coagulation through a flexible endoscope. Evaluation of a new therapeutic method after 1606 uses]. Aronplasmakoagulation in der flexiblen Endoskopie. *Dtsch Med Wochenschr* 1997;122:432-438.
17. Guda NM, Freeman ML. Endoscopic transection of distally migrated biliary self-expanding metallic stents by using argon plasma coagulation: A report of 2 cases (with video). *Gastrointest Endosc* 2006;63:512-514.
18. Hammer H. Palliative Therapie des Rektumkarzinoms mit Argon-Plasma-Koagulation. *Gastrointestinal Hepatol* 2003;1:18-20.
19. Heindorff H, Wojdemann M, Bisgaard T, Svendsen LB. Endoscopic palliation of inoperable cancer of the oesophagus or cardia by argon electrocoagulation. *Scand J Gastroenterol* 1998;33:21-23.
20. Johanns W, Luis W, Janssen J, Kahl S, Greiner L. Argon plasma coagulation (APC) in gastroenterology: Experimental and clinical experiences. *Eur J Gastroenterol Hepatol* 1997;9:581-587.
21. Kaassis M, Oberti F, Burtin P, Boyer J. Argon plasma coagulation for the treatment of hemorrhagic radiation proctitis. *Endoscopy* 2000;32:673-676.
22. Kitamura T, Tanabe S, Koizumi W, Mitomi H, Saigenji K. Argon plasma coagulation for early gastric cancer: Technique and outcome. *Gastrointest Endosc* 2006;63:48-54.
23. Laethem J-LV, Cremer M, Delhay M, Devi J, Peny MO. Eradication of Barrett's mucosa with argon plasma coagulation and acid suppression: Immediate and mid-term results. *Gut* 1998;43:747-751.
24. Lesur G, Bour B, Aegerter P. Management of bleeding peptic ulcer in France: A national inquiry. *Gastroenterol Clin Biol* 2005;29:140-144.
25. Manner H, May A, Faerber M, Rabenstein T, Ell C. Safety and efficacy of a new high power argon plasma coagulation system (hp-APC) in lesions of the upper gastrointestinal tract. *Dig Liver Dis* 2006;38:471-478.
26. Manner H, May A, Miehke S, Dertinger S, Wigglinghaus B, Schimming W, Kramer W, Niemann G, Stolte M, Ell C. Ablation of nonneoplastic Barrett's mucosa using argon plasma coagulation with concomitant esomeprazole therapy (APBANEX): A prospective multicenter evaluation. *Am J Gastroenterol* 2006;101:1762-1769.
27. Mulder CJ. Zapping Zenker's diverticulum: Gastroscopic treatment. *Can J Gastroenterol* 1999;13:405-407.
28. Nakamura S, Mitsunaga A, Murata Y, Suzuki S, Hayashi N. Endoscopic induction of mucosal fibrosis by argon plasma coagulation (APC) for esophageal varices: A prospective randomized trial of ligation plus APC vs. ligation alone. *Endoscopy* 2001;33:210-215.
29. Pedrazzani C, Catalano F, Festini M, Zerman G, Tomezzoli A, Ruzzenente A, Guglielmi A, de MG. Endoscopic ablation of Barrett's esophagus using high power setting argon plasma coagulation: A prospective study. *World J Gastroenterol* 2005;11:1872-1875.
30. Postgate A, Saunders B, Tjandra J, Vargo J. Argon plasma coagulation in chronic radiation proctitis. *Endoscopy* 2007;39:361-365.
31. Probst A, Scheubel R, Wienbeck M. Treatment of watermelon stomach (GAVE syndrome) by means of endoscopic argon plasma coagulation (APC): Long-term outcome. *Z Gastroenterol* 2001;39:447-452.
32. Prost B, Poncet G, Scoazec JY, Saurin JC. Unusual complications of argon plasma coagulation. *Gastrointest Endosc* 2004;59:929-932.
33. Raillat A, de Saint-Julien J, Abgrall J. [Colonic explosion during an endoscopic electrocoagulation after preparation with mannitol]. *Gastroenterol Clin Biol* 1982;6:301-302.
34. Ravizza D, Fiori G, Trovato C, Crosta C. Frequency and outcomes of rectal ulcers during argon plasma coagulation for chronic radiation-induced proctopathy. *Gastrointest Endosc* 2003;57:519-525.
35. Regula J. Argon plasma coagulation after piecemeal polypectomy of sessile colorectal adenomas: Long-term follow-up study. *Endoscopy* 2003;35:212-218.
36. Reichle G. Die Argon-Plasma-Koagulation zur bronchoskopischen Rekanalisation und Blutstillung. *Atemw - Lungenkrkh* 2003; Jahrgang 29:258-269.
37. Reichle G, Freitag L, Kullmann HJ, Prenzel R, Macha HN, Farin G. [Argon plasma coagulation in bronchology: A new method - alternative or complementary?]. *Pneumologie* 2000;54:508-516.
38. Robertson GS, Thomas M, Jamieson J, Veitch PS, Dennison AR. Palliation of oesophageal carcinoma using the argon beam coagulator. *Br J Surg* 1996;83:1769-1771.

39. Rolachon A, Papillon E, Fournet J. [Is argon plasma coagulation an efficient treatment for digestive system vascular malformation and radiation proctitis?]. *Gastroenterol Clin Biol* 2000;24:1205-1210.
40. Roman S. Tolerance and efficacy of argon plasma coagulation for controlling bleeding in patients with typical and atypical manifestations of watermelon stomach. *Endoscopy* 2003;35:1024-1028.
41. Schulz H, Miehke S, Antos D, Schentke KU, Vieth M, Stolte M, Bayerdorffer E. Ablation of Barrett's epithelium by endoscopic argon plasma coagulation in combination with high-dose omeprazole. *Gastrointest Endosc* 2000;51:659-663.
42. Sharma P, Wani S, Weston AP, Bansal A, Hall M, Mathur S, Prasad A, Sampliner RE. A randomised controlled trial of ablation of Barrett's esophagus with multipolar electrocoagulation versus argon plasma coagulation in combination with acid suppression: Long-term results. *Gut* 2006;55:1233-1239.
43. Silva RA, Correia AJ, Dias LM, Viana HL, Viana RL. Argon plasma coagulation therapy for hemorrhagic radiation proctosigmoiditis. *Gastrointest Endosc* 1999;50:221-224.
44. Skok P, Krizman I, Skok M. Argon plasma coagulation versus injection sclerotherapy in peptic ulcer hemorrhage—a prospective, controlled study. *Hepatogastroenterology* 2004;51:165-170.
45. Soussan EB, Mathieu N, Roque I, Antonietti M. Bowel explosion with colonic perforation during argon plasma coagulation for hemorrhagic radiation-induced proctitis. *Gastrointest Endosc* 2003;57:412-413.
46. Sutedja GBCT. Endobronchial electrocautery and argon plasma coagulation. *Prog Respir Res* 2000;120-132.
47. Tam W, Moore J, Schoeman M. Treatment of radiation proctitis with argon plasma coagulation. *Endoscopy* 2000;32:667-672.
48. Tjandra JJ, Sengupta S. Argon plasma coagulation is an effective treatment for refractory hemorrhagic radiation proctitis. *Dis Colon Rectum* 2001;44:1759-1765.
49. Vanbiervliet G, Piche T, Caroli-Bosc F, Dumas R, Peten E, Huet P, Tran A, Demarquay J. Endoscopic argon plasma trimming of biliary and gastrointestinal metallic stents. *Endoscopy* 2005;37:434-438.
50. Vargo JJ. Clinical applications of the argon plasma coagulator. *Gastrointest Endosc* 2004;59:81-88.
51. Venkatesh KS, Ramanujam P. Endoscopic therapy for radiation proctitis-induced hemorrhage in patients with prostatic carcinoma using argon plasma coagulator application. *Surg Endosc* 2002;16:707-710.
52. Villavicencio RT, Rex DK, Rahmani E. Efficacy and complications of argon plasma coagulation for hematochezia related to radiation proctopathy. *Gastrointest Endosc* 2002;55:70-74.
53. Wahab PJ, Mulder CJ, den HG, Thies JE. Argon plasma coagulation in flexible gastrointestinal endoscopy: Pilot experiences. *Endoscopy* 1997;29:176-181.
54. Yusoff I. Argon plasma coagulation for treatment of watermelon stomach. *Endoscopy* 2002;34:407-410.
55. Zlatanic J, Waye J, Kim P, Baiocco P, Gleim G. Large sessile colonic adenomas: Use of argon plasma coagulator to supplement piecemeal snare polypectomy. *Gastrointest Endosc* 1999;49:731-735.

Educational books

- Classen M et al. *Gastroenterologische Endoskopie*. 2004, Georg Thieme Verlag.
- Ginsberg G et al. *Clinical Gastrointestinal Endoscopy*. 2005, Elsevier, Inc.
- Waye DJ et al. *Colonoscopy Principles and Practice*. 2003, Blackwell Publishing Ltd.

ERBE
USA INCORPORATED
Surgical Systems

ERBE USA, Inc.
2225 Northwest Parkway
Marietta, GA 30067-9317
Tel. 800. 778. 3723
Fax. 770. 955. 2577
www.erbe-usa.com