

Congenital Heart Disease

for the Adult Echocardiographer

**ASEeXAM
Review Course**

**Michael D. Pettersen M.D.
Director, Echocardiography
Rocky Mountain Hospital for Children
Denver, CO
michael_pettersen@pediatrix.com**

Congenital Heart Disease for the Adult Echocardiographer

The vast majority of congenital heart defects are currently detected within the first several years of life. Therefore, the term “adult congenital heart disease” is something of an oxymoron. In the “ancient” days before diagnostic ultrasound, there was less precision in early diagnosis. Improvements in surgical techniques for correcting most congenital cardiac defects have progressed along with our diagnostic skills, making early diagnosis easier and necessary. For all of these reasons, congenital heart disease is more commonly recognized and more frequently diagnosed today than in years past. The result of this is a declining population of adult patients with undiagnosed congenital heart defects. However, the improvements in the success of medical management and surgical repair has led to the growing number of patients who reach adulthood. The clinical course, natural history, and outcome for many of these patients is uncertain because of the time has not allowed for collection of the “unnatural history” of the repaired defects.

The ASEexam® will probably deal mainly with issues of unrepaired congenital heart disease. Therefore, these items will be emphasized in this manual and talk. However, questions may appear which deal with knowledge of congenital operations in terms of “what they do”, although the imaging issues are apparently not addressed in detail.

Basics Principles of Congenital Heart Disease

An understanding of the incidence and frequency of congenital heart disease will aid the clinician in developing an index of suspicion for variation types of defects.

Perspective

The science of pediatric cardiology is almost 50 years old. Prior to about 1947, there was very little to offer patients with congenital heart disease and many died. In the last 40 years and particularly the last 15-20, great strides have been made in imaging, surgery and interventional techniques which have significantly improved the outcome. However, since we are dealing with children who have a whole lifetime to live, we still do not know what the distant future may hold for many of our successes. This unknown perspective should be emphasized when counseling the patients and parents of children with congenital heart disease.

Incidence

The incidence of congenital heart disease is approximately 0.5-0.8% of live births. The incidence may be higher in premature babies than in full-term infants if PDA is included, and congenital cardiac malformations are much more common in stillbirths than in live births. Heart disease remains the most common lethal anomaly in the newborn. About 32,000 infants are born each year with congenital heart disease. Approximately 960,000 Americans with heart defects are alive today. 1993 death rates for congenital heart disease is about 2 per 100,000 people.

The figures quoted above do not include mitral valve prolapse (MVP) or the congenitally bicuspid aortic valve, (BAV) which occur in 4-6% and 1-2% of the population, respectively.

Frequency of Congenital Heart Defects

Congenital defects	%CHD
Simple shunts (ASD, VSD, PDA)	50
Simple obstruction (AS, PS, coarctation)	20
Complex (combination lesions, tetralogy, etc.)	30

Frequency of individual defects

Cardiac Malformation *	% CHD	M:F Ratio
Ventricular Septal Defect (VSD)	18-28	1:1
Patent Ductus Arteriosus (PDA)	10-18	1:2-3
Tetralogy of Fallot	10-13	1:1
Atrial Septal Defect (ASD)	7-8	1:2-4
Pulmonary Stenosis	7-8	1:1
Transposition of the Great Arteries	4-8	2-4:1
Coarctation of the Aorta	5-7	2-5:1
Atrioventricular Canal Defect	2-7	1:1
Aortic Stenosis	2-5	4:1
Truncus Arteriosus	1-2	1:1
Tricuspid Atresia	1-2	1:1
Total Anom. Pulm. Venous Connection	1-2	1:1

*Excludes Mitral Valve Prolapse and Bicuspid Aortic Valve

Etiology

The four etiologic agents which may cause congenital heart disease are the same as those which may cause various cancers in humans:

1. Heredity & chromosomal defects (e.g., trisomy 21, with AVSD or VSD).
2. Viruses (e.g., Rubella syndrome, with PDA).
3. Chemicals (e.g., Thalidomide, with truncus or tetralogy).
4. Radiation (e.g., x-irradiation, with VSD).

However, in most instances the etiology of congenital heart disease in humans cannot be determined and are felt to be "**multifactorial**". Multifactorial inheritance means that subsequent children will have a slightly higher incidence of congenital heart disease. The risk increase from the known 0.8% to about 2%. Recurrence risks are higher if there are more than one child in the family with CHD (about 4-6%) or if the mother is the affected individual (i.e. if the mother has CHD, the incidence is 6-10%). Most recurrence is for similar types of lesions and some risks may be higher for certain classes of defects (i.e. conotruncal defects such as tetralogy of Fallot).

Congenital Heart Disease in Common Syndromes/Chromosomal Anomalies				
ANOMALY	INCIDENCE(%)	MOST COMMON LESIONS		
		1	2	3
Trisomy 21	50	VSD	AVC	ASD
Trisomy 18*	99+	VSD	PDA	PS
Trisomy 13*	90	VSD	PDA	Dextro
45,X Turner	35	Coarct	AS	ASD
Noonan	50-80	PS	ASD	
Williams	80	Supravalve AS	Supravalve PS	VSD
Holt-Oram	70	ASD	VSD	
Marfan	50+	Aortic root dilation	MVP	
DiGeorge, 22q11	80	VSD	Arch anom.	TOF

* Generally considered lethal and probably will not survive to adulthood

The Unoperated Adult with Congenital Heart Disease

Congenital heart disease surviving to adulthood

The largest influence on the survival of patients with congenital heart disease has been by advances in surgical techniques to palliate and repair these defects. Two basic classes of problems are seen which allow survival into adult years: 1) defects which allow survivability without surgical intervention 2) defects which can be successfully repaired and survival to adulthood is anticipated. Both of these classes of patients provide a significant challenge to the clinician in the initial evaluation of these patients.

Defects which allow survivability to adulthood without surgical intervention

Defects	Survivability	Symptoms	Murmur	Cyanosis
ASD	++++	+/-	+	-
Part. anom. pulm. veins	++++	+/-	+	-
Bicuspid aortic valve	++++	-	+	-
Small VSD	++++	-	++++	-
Subaortic membrane	+++	+/-	+++	-
Ebstein's anomaly	+++	+/-	+/-	+
Corrected transposition	+++	+/-	+/-	-
Pulm. valve stenosis	+++	+/-	+++	-
Coarctation of the aorta	+++	+/-	+/-	-
Tetralogy of Fallot	+	+++	++++	+++

Defects	Survivability	Symptoms	Murmur	Cyanosis
ASD	++++	+/-	+	-
Part. anom. pulm. veins	++++	+/-	+	-
Bicuspid aortic valve	++++	-	+	-
Large VSD/AV canal	+/-	++++	+/-	++
Pulm. atresia w/ ASD	+/-	++++	+	++++
Single ventricle	+/-	++++	+++	++

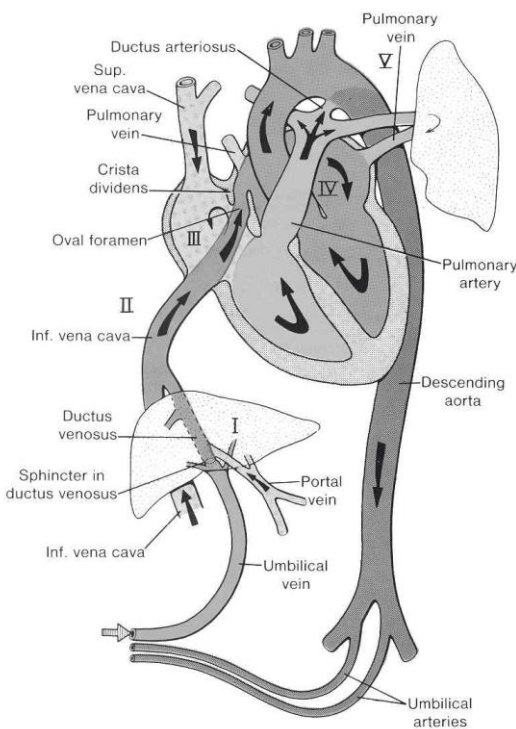
Fetal Echocardiography

(not discussed in lecture)

Fetal echocardiography may be used to detect most major and minor cardiac defects. This test is generally performed as early as 18-20 weeks gestation. This timing allows for optimal visualization of cardiac structures by balancing fetal size with the relative amount of amniotic fluid and bony rib density. The heart has completed its development by 8 weeks of gestation.

Established indications for fetal echo:

1. Previous child with heart disease
2. Personal (maternal) history of heart disease
3. Suspected heart rhythm problem in the baby
4. Fluid around the baby's heart (hydrops)
5. Suspected heart defect in the baby/abnormal OB ultrasound
6. Suspected non-cardiac defect in baby with potential related cardiac disease
7. Maternal history of diabetes
8. History of drug/medicine/teratogen use



The fetal cardiac circulation is unique. Several important principles must be understood. The lungs are not being used for oxygen exchange. Two important fetal pathways, the foramen ovale and the ductus arteriosus are used to bypass the lungs and send blood directly to the systemic circulation. A ductus venosus is present to bypass the liver and allow better oxygenated blood to pass directly to the heart and hence to the fetal systemic circulation. Fetal ventricular, aortic and pulmonary pressures are all about equal and at systemic levels. Fetal oxygen saturation is relatively low (about 60%). This is compensated for by the presence of fetal hemoglobin, which enhances oxygen extraction at low oxygen tensions.

A ductus arteriosus is necessary for survival. This is particularly true with congenital heart disease in cases of significant obstruction to either systemic or pulmonary flow (so-called "ductal dependent" lesions). The ductus arteriosus is then kept open artificially after

birth with prostaglandin E 1, infused continuously until corrective measures can be taken.

Defects which are relatively easy to detect with fetal echocardiography include those defects which have significantly abnormal 4-chamber views such as various forms of single ventricle or atrioventricular canal as well as large septal defects. Defects which are a normal part of fetal circulation may be subtle (PDA, secundum ASD) in addition to isolated anomalies of pulmonary veins or coarctation of the aorta (which may be "masked" by the presence of the large fetal ductus).

Pregnancy and Maternal Congenital Heart Disease (not discussed in lecture)

Maternal congenital heart disease poses a new set of problems for the clinician and echocardiographer. A thorough knowledge of the hemodynamics of each individual's congenital heart disease should be present before making generalizations about any individual clinical problem. Patients who have grown up with CHD, even those with multiple operative procedures, are often very ignorant of the specifics of their own heart problem. This is because the pediatric cardiologist usually directs the discussion to the responsible parent during many informative discussions. OLD RECORDS are essential in this type of evaluation so that incorrect diagnoses may be rejected.

Prior to pregnancy:

1. Pregnancy should be planned. Appropriate non-invasive or invasive evaluation of pregnancy risk should be sought.
2. Contraception should be considered. In many forms of CHD, standard-dose estrogen oral agents may increase the risk of thrombosis and should be avoided.
3. The increased recurrence risk of the offspring of affected individuals should be mentioned.

Effects of pregnancy:

1. Volume expansion: Cardiac output and total blood volume increases until about 30 weeks gestation.
2. Systemic hypertension may be present in later stages of pregnancy and may profoundly effect hemodynamics.
3. The risk of SBE is generally low.
4. Patients with obligatory intracardiac shunts are at increased risk for embolic phenomena.

Cardiac defects which are low risk:

Post repair of a simple shunt
Simple, mild valvular abnormalities
(Bicuspid AV, mild PS)

Cardiac defects which are high risk:

Eisenmengers/pulmonary hypertension - **Pregnancy contraindicated**
. Single ventricle- Fontan
Marfan syndrome
Significant aortic stenosis, coarctation
Ventricular failure

Defects not found above probably fall into a moderate risk category clinically. Tetralogy of Fallot is a good example. However, obstetricians and perinatologists do not have "moderate risk" categories, so many of these patients will be classified as high risk. More data is being collected regularly on the risk and outcome of these types of pregnancies.

Clinical and Anatomic Aspects of Congenital Heart Lesions

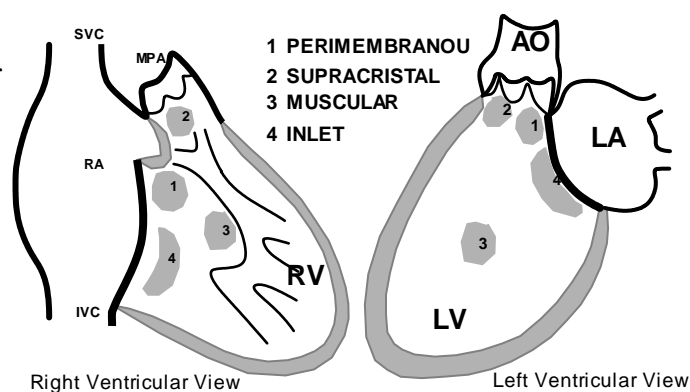
1) Ventricular Septal Defect (VSD)

Definition. A ventricular septal defect is an abnormal opening in the ventricular septum, which allows communication between the right and left ventricles. It is the most common form of congenital heart disease, accounting for about 25% of defects.

Anatomy. (1) Perimembranous VSD (membranous VSD). This is the most common form of VSD and either involves or is adjacent to the membranous septum. (2) Infundibular VSD (subpulmonary or supracristal VSD). This type of VSD involves the RV outflow tract (conus or infundibulum). These defects are frequently partially occluded by a cusp of the aortic valve, which may cause aortic insufficiency over time.

(3) Muscular VSD. This type of defect may be either single or multiple and involves the inflow or trabeculated (apical) ventricular septum.

(4) Atrioventricular septal defects (inlet VSD, AV canal) involve the inflow portion of the septum and virtually always are associated with AV valvular abnormalities.



Associated Anomalies. Approximately 25-30% of VSD's occur as isolated defects. The remainder are associated with other anomalies (e.g., PDA, ASD, coarctation) or are an integral part of certain anomalies (e.g., tetralogy, truncus, and some transpositions). Aortic insufficiency may also be present.

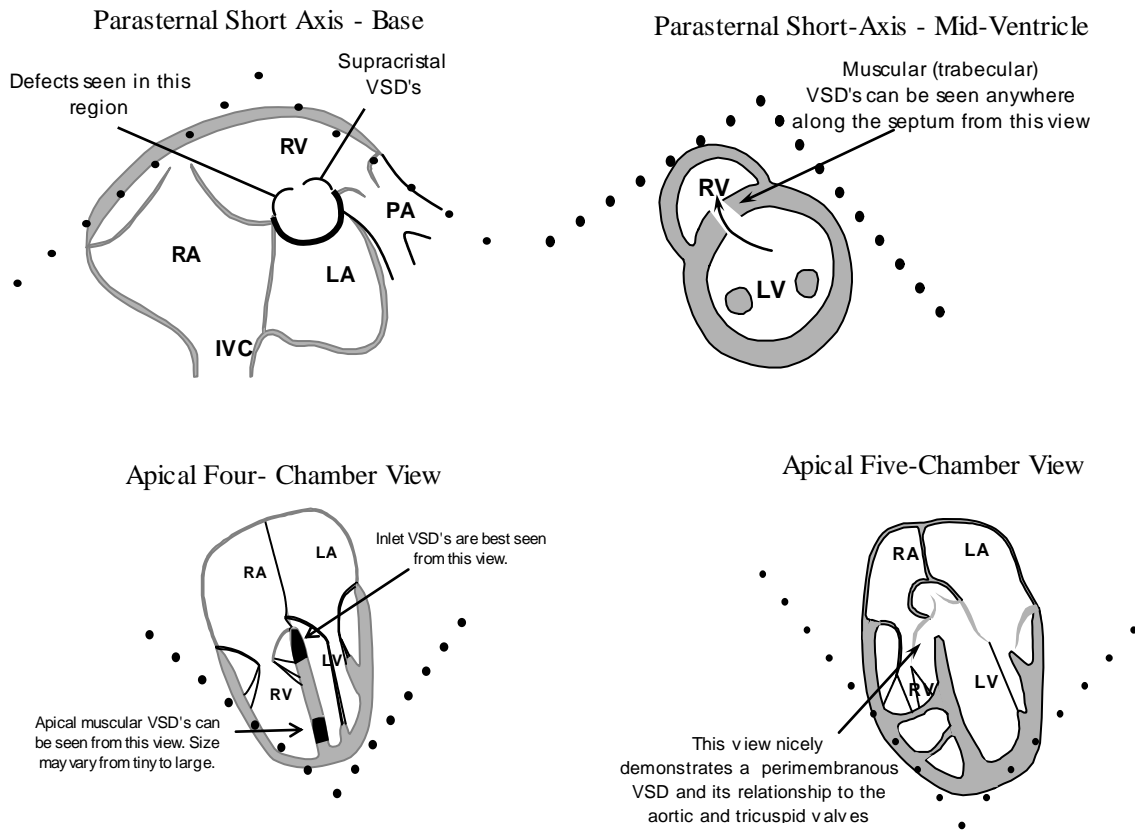
Hemodynamics. A left-to-right shunt occurs not because left ventricular pressure is higher than right ventricular pressure but because pulmonary vascular resistance is less than systemic vascular resistance. The prime directive dictates that systemic pressure is maintained, so the right ventricular pressure is raised to systemic levels if the defect is large. As a result, pulmonary arterial pressure may be greatly elevated. There is pressure hypertrophy of the right ventricle and volume hypertrophy of the left atrium and left ventricle. The pulmonary arteries will become dilated and thick-walled. The hemodynamic significance of the defect depends upon its size and the amount of flow and pressure which is transmitted to the right heart and pulmonary arteries. Large defects will allow a large amount of pressure and flow through; a phenomenon which will decrease as the size of the hole decreases.

Clinical. The small VSD has a loud holosystolic murmur along the left sternal border but is rarely symptomatic. At least 50-80% of small VSD's will close spontaneously. The large VSD is approximately as large as the aortic orifice, and such a defect is almost always symptomatic and will probably not close spontaneously. A small percentage of perimembranous defects, even though large will close or narrow. Presentation depends on size: small defects usually present as an asymptomatic murmur, larger defects usually present as a symptomatic murmur. *Symptoms include increased*

respiratory effort and/or feeding difficulties. The additional presence of an apical mitral *diastolic* flow rumble from the defect represents significantly increased flow.

In most unoperated patients with a large VSD, obstructive pulmonary vascular disease eventually develops, and a right-to-left shunt (shunt reversal) with cyanosis becomes evident (Eisenmengers syndrome). Once irreversible pulmonary hypertension is present, the VSD is considered inoperable. Even in large VSD's, Eisenmengers syndrome is uncommon under 1 year.

Echocardiographic Evaluation of VSD



Echo Checklist - VSD

1. Identify defect, scan for additional defects
2. Confirm flow through defect with color/CW
3. Measure gradient across defect
4. Measure size of defect in systole
5. Measure size of aortic anulus in systole
6. Measure RV pressure

Practical Summary - VSD

1. Timing of surgery - depends on the size of the defect. Large, non-restrictive defects are often closed within the first few months of life. Less symptomatic defects are often followed to see if they are closing with serial echo and clinical exam. Most defects requiring closure are closed by school age.

2. LA dilation - a significant VSD will generally

produce significant LA dilation as blood goes to the lungs and returns to the LA.

3. Size of the defect - can vary tremendously with a particular view and the phase of the cardiac cycle.

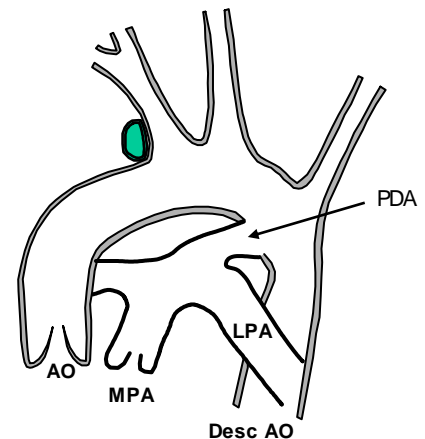
For ASD we generally look at the largest dimension. For VSD we need to know the systolic dimension. Perimembranous VSD's may be partially covered with tissue from the tricuspid valve, forming a "septal aneurysm". In this case measure the smallest orifice that the VSD jet passes through in systole.

4. Aortic regurgitation - supravalvular defects and some perimembranous defects can distort the aortic valve and cause aortic regurgitation, particularly in older children.
5. Type of surgical closure - this is an open heart procedure, median sternotomy, usually with patch closure. The patch is sewn to the RV side of the septum and may be difficult to distinguish from normal tissue after many years. Usually it is echo-bright.

2) Patent Ductus Arteriosus (PDA)

Definition. A patent ductus arteriosus is persistent patency of a normal structure, the ductus arteriosus, which is present in intrauterine life. This vessel is large in the fetus; equal in size to the main pulmonary artery and descending aorta. This vessel usually closes functionally within 12-24 hours and undergoes complete anatomic closure and fibrosis within three weeks in term newborn infants. The incidence of persistent patency is much higher in premature infants and is related to the degree of prematurity.

Anatomy. The ductus arteriosus arises from the anterior surface of the upper descending aorta just distal to the origin of the left subclavian artery. It is a short vessel which enters the main pulmonary artery medial to the left pulmonary artery branch.



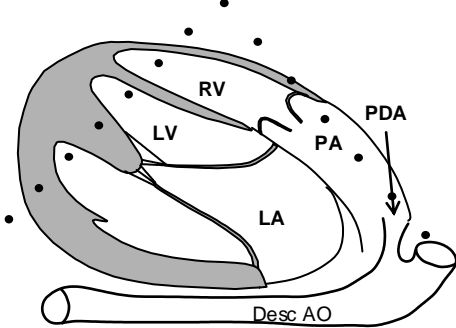
Associated Anomalies. Usually a PDA is an isolated anomaly.

Hemodynamics. A left-to-right shunt occurs in a fashion similar to that seen in VSD, because pulmonary vascular resistance is less than systemic vascular resistance. The prime directive dictates that systemic pressure is maintained, so the pulmonary arterial pressure is raised to systemic levels if the defect is large. There is pressure hypertrophy of the right ventricle and volume hypertrophy of the left atrium and left ventricle. The hemodynamic significance of the defect depends upon its size and the amount of flow and pressure which is transmitted to the pulmonary arteries. Large ducti will allow a large amount of pressure and flow through; a phenomenon which will decrease as the size of the ductus decreases. Most PDA's will undergo some degree of closure. This will restrict flow and pressure to the pulmonary arteries.

Clinical. Most PDA's will be suspected on the basis of a heart murmur. In the newborn or premature infant varying degrees of respiratory distress may be seen. Because the ductus represents a connection of the high resistance systemic circulation to the low resistance pulmonary circulation, the pulse pressure will widen and bounding pulses are often felt. The murmur in older children is high-pitched, continuous with systolic accentuation. In the premature infant, often only the systolic component of the sound is heard. Diagnosis should be made on clinical grounds and confirmed with echocardiography. No other tests are needed.

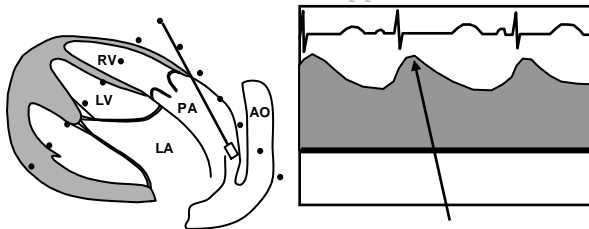
Echocardiographic Evaluation

Parasternal Ductal View
(High Left Parasternal)



The ductus arteriosus is not a difficult structure to image. Imaging planes should be sought which include a view of both the pulmonary artery and aorta. This is usually best accomplished from a sagittal plane in the high left parasternal area. Parasternal short axis views may often miss small ducti. Using color flow Doppler exclusively to identify ductal flow is often successful but may also produce mistakes when there is pulmonary hypertension and flow is right-to-left.

Doppler Flow Pattern



Pulmonary artery pressure may be calculated if one knows the systolic arm blood pressure and uses the Bernoulli equation: (Systolic pulmonary artery pressure = systolic blood pressure - $4 V_{PDA}^2$).

Practical Summary - PDA

Echo Checklist – PDA

1. Identify defect/establish diagnosis.
2. Confirm flow through defect with color.
3. Measure gradient across PDA.
4. Measure size of PDA (length & width).
5. Establish pulmonary artery and arch patency.

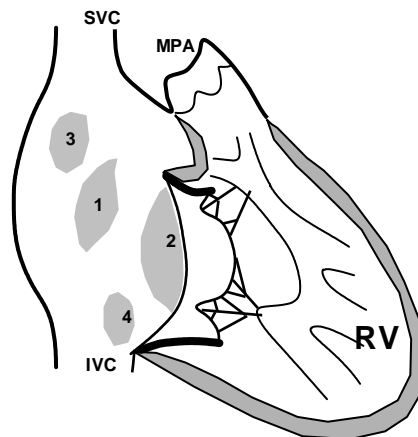
1. Timing of surgery - PDA is usually “find it - fix it”. Some very tiny PDA’s without an associated murmur (silent PDA), may not require closure. PDA in the newborn maybe closed medically with Indomethacin.
2. Catheter closure - Many non-neonatal PDA’s are being closed in the cath lab using wire coils which are positioned directly in the ductus.
- 3). Type of surgical closure - closed heart, left

lateral thoracotomy, ligation and division. If the PDA is ligated only, a few may recanalize and regain patency. If the PDA is divided, it should be gone for good.

3) Atrial Septal Defect (ASD)

Definition. An atrial septal defect is an abnormal opening in the atrial septum, which allows free communication between the right and left atria. (In one-third of normal adults, a patent foramen ovale exists; this is not an ASD.)

Anatomy. (1) Secundum ASD (ostium secundum ASD; ASD II; ASD at fossa ovalis). This is the most common form of ASD. (2) Primum ASD (ostium primum ASD; ASD I; endocardial cushion defect; partial AV canal). This form of ASD lies antero-inferior to the fossa ovalis and is often associated with a cleft mitral valve. (3) Sinus venosus ASD. This form of ASD lies posterior to the fossa ovalis and is usually associated with anomalous connection of the right pulmonary veins to the right atrium. (4) Coronary sinus ASD. This form of ASD involves the anticipated site of the coronary sinus ostium. An “unroofing” of the coronary sinus creates the defect.



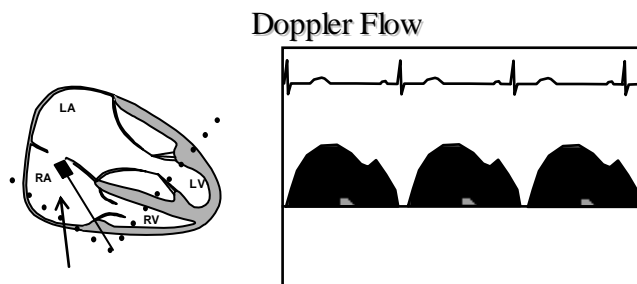
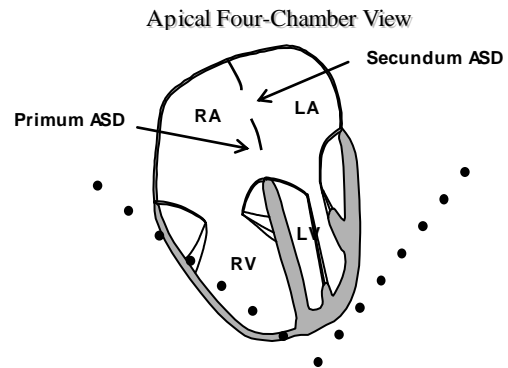
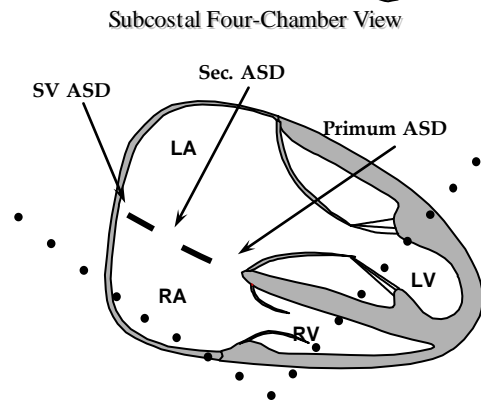
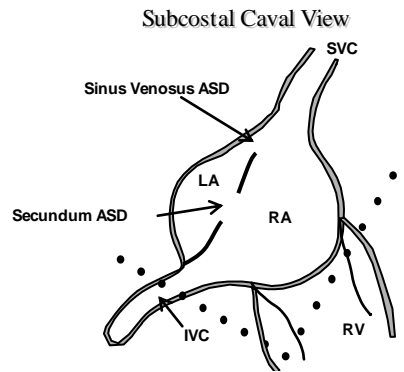
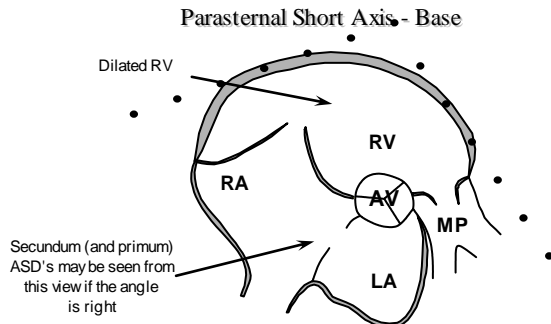
- 1 SECUNDUM**
- 2 PRIMUM**
- 3 SINUS VENOSUS**
- 4 CORONARY SINUS**

Associated Anomalies. The majority of ASD's occur as isolated lesions. When an ASD occurs with another cardiac defect, the associated anomaly is almost always the more severe lesion (e.g., VSD, PDA, tetralogy, transposition, truncus, tricuspid atresia, TAPVC).

Hemodynamics. A left-to-right shunt occurs not because left atrial pressure is slightly higher than right atrial pressure but primarily because the thin-walled right ventricle fills more easily than the thick-walled left ventricle and downstream pulmonary resistance is lower than systemic. As a result, pulmonary blood flow may be 2-4 times normal. There is dilation and volume overload of the right atrium and right ventricle. The pulmonary arteries become dilated, and eventually the tricuspid and pulmonary annuli also dilate. Because normal atrial pressures are low, there is no transmission of pressure to the pulmonary arteries.

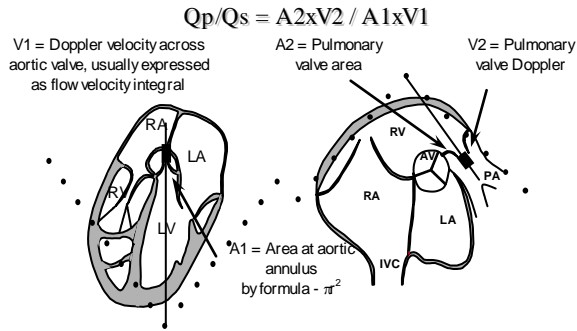
Clinical. Most patients present as an asymptomatic heart murmur after one year of age. The significance of the size of the defect is relative to the size of the patient. In general, a defect large enough to produce cardiomegaly on CXR is probably significant and may require surgical closure. The presence of a diastolic tricuspid flow rumble probably reflects a significant shunt. This lesion does not generally require catheterization, but can be repaired using echo alone. TEE may be needed in the adult. The heart murmur from an ASD is a softer systolic ejection murmur from the pulmonic area with widened and sometimes fixed splitting of the second heart sound. Diagnosis should be made by discovery of a typical heart murmur with confirmation by echocardiography. No other tests should be required.

Echocardiographic Evaluation of ASD



Doppler flow through an ASD has a characteristic pattern as shown at left. The flow begins in early systole and continues almost throughout the cardiac cycle with a broad peak in late systole and early diastole. The peak velocity is usually about 2 m/sec although the number is rarely important clinically. The pattern represents a combining of the flows from the pulmonary and systemic veins.

Pulmonary-to-Systemic Flow Ratio

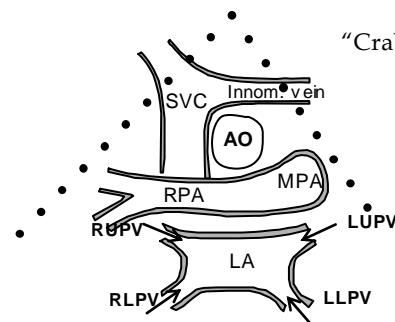


Qp/Qs - The amount of shunt through any defect may be expressed as a ratio of pulmonary to systemic flow or Qp/Qs. Normally, with no shunt, the Qp/Qs is 1. Doppler and 2-D exams can give all of the information needed to make this calculation. Measure the area of both the aortic and pulmonary valves using the equation: $area = \pi r^2$ ($r = \text{annulus diameter}/2$). Trace the Doppler flow through each valve to get the time-velocity integral and express the product of these two numbers as a ratio. A Qp/Qs > 1.5 is a significant shunt.

Identification of Pulmonary Veins

Although the surgeon will generally inspect the left atrium for the entry points of the pulmonary veins, echocardiographic identification of these structures should be carried out as part of the routine evaluation of the patient with ASD. The suprasternal short axis view or "crab" view is very helpful in this effort.

Identification of Pulmonary Veins



Echo Checklist - ASD

1. Identify defect, significant RV enlargement.
2. Confirm flow through defect with color/PW.
3. Measure size of defect in largest dimension.
4. Identify/rule out AV valve regurgitation.
5. Measure RV pressure, especially in adults.
6. If defect is questionably small, do Qp/Qs.

Practical Summary - ASD

1. Timing of surgery - usually after age 2 years, unless symptoms are present.
2. RV dilation - a significant ASD will generally produce RV dilation, a general indicator of the need to close the defect.
3. Non-surgical options - expect to see more device closures of secundum defects in the future.

4) Tetralogy of Fallot (TOF)

Definition/Anatomy. Tetralogy of Fallot is classically defined as: 1) right ventricular hypertrophy 2) ventricular septal defect 3) overriding aorta 4) pulmonary stenosis, but is actually a spectrum of defects probably resulting from abnormal conotruncal septation. This leads to anterior deviation of the infundibular septum which in turn "crowds" the right ventricular outflow tract leading to sub-pulmonary stenosis or atresia. The anterior deviation of the infundibular septum also is responsible for the malalignment ventricular septal defect and dextroposition of the aorta. Tetralogy occurs in approximately 9% of children born with congenital heart defects.

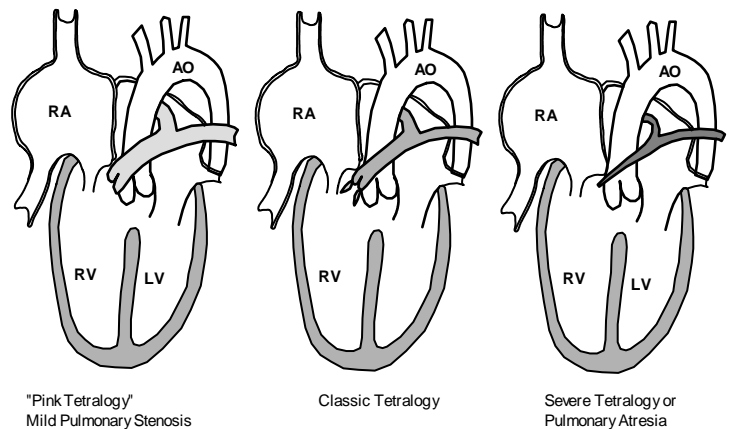
Associated Anomalies. In addition to the "tetrad" the following anomalies may co-exist: Valvular pulmonary stenosis (50-60%), Right aortic arch (25%) - usually mirror image branching, Atrial septal defect (15%), Coronary anomalies (esp. LAD from right coronary 5%) Additional muscular VSD (2%), Unilateral absent pulmonary artery (rare).

Hemodynamics. The VSD in tetralogy is virtually always large and non-restrictive, leading to systemic pressures in the right ventricle. The pulmonary stenosis in tetralogy is highly variable but usually *increases in severity* with age. Some patients with tetralogy begin life with very little pulmonary stenosis and are not cyanotic ("pink tetralogy"). These patients may even experience a short period of excessive pulmonary flow. Progressive sub-valvular (infundibular) pulmonary stenosis leads to increasing obstruction to pulmonary blood flow. With such obstruction, two things happen: 1) Right-to-left shunting occurs at the ventricular level 2) Relatively less blood gets to the lungs to become oxygenated. The combination of these two effects results in increasing cyanosis. The severity of pulmonary stenosis generally determines the magnitude of the right-to-left shunt. Unlike other large VSD's, patients with TOF will be relatively protected from the high pressure damage to the lung vasculature because the pulmonary stenosis restricts lung flow and pressure.

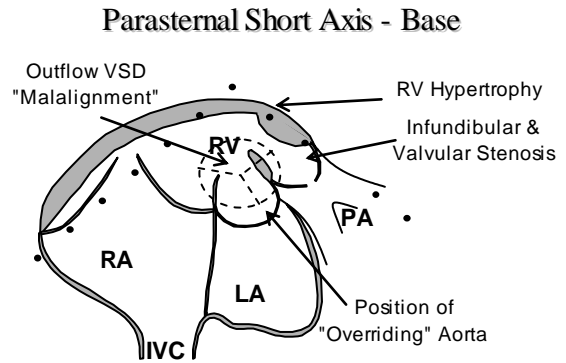
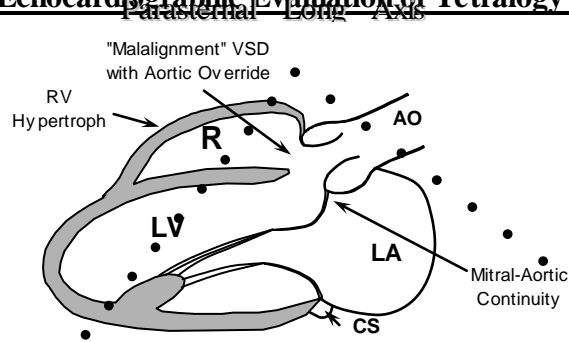
Clinical. Patients with TOF present most often as an asymptomatic heart murmur heard at the first office visit to the pediatrician or family practitioner. Some will also be picked up in the newborn period, but the murmur is often much softer at that time because 1) the subpulmonary stenosis has not developed significantly to produce turbulence and 2) pulmonary resistance is high and flow is decreased in the first day of life as the infant goes through normal transition. The children usually remain asymptomatic, with normal growth and development.

Tetralogy of Fallot

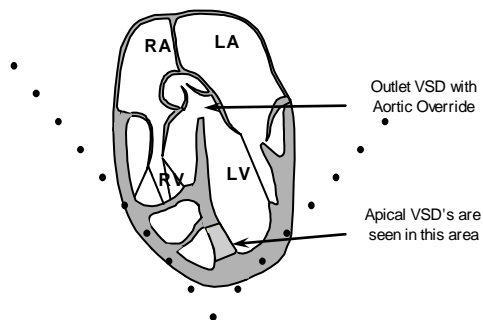
Anatomic Variables



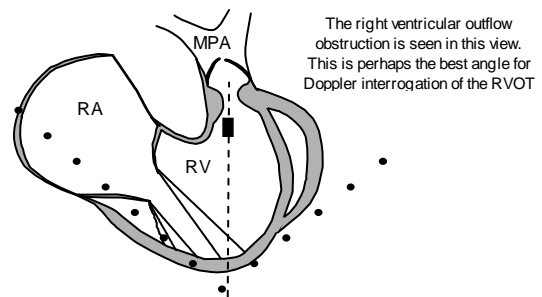
Echocardiographic Evaluation of Tetralogy of Fallot



Apical Five-Chamber



Subcostal RV Inflow/Outflow View



Echo Checklist – Tetralogy of Fallot

1. Identify all levels of right heart obstruction.
2. Accurately assess the severity of pulmonary valve and pulmonary artery hypoplasia.
3. Identify other associated defects (e.g. additional VSDs; ASDs, PDA, persistent left SVC)..
4. Delineate coronary artery anatomy.
5. Locate arch position and vessels.

Practical Summary - Tetralogy of Fallot

1. Timing of surgery - Most surgical correction is completed before 6 months of age, often within 2-3 months.
2. Complicating features - coronary anomalies, pulmonary atresia; may result in conduit repair.
3. Many repairs are done with a transannular RV outflow patch which disrupts pulmonary valve function and creates chronic pulmonary regurgitation.

5) Pulmonary Valve Stenosis

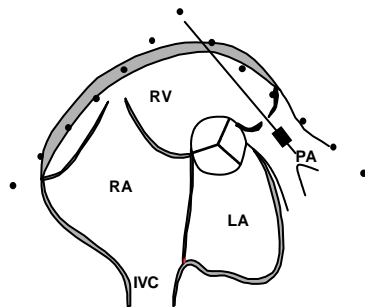
Definition. Pulmonary stenosis refers to obstruction in the region of either the pulmonary valve or the subpulmonary ventricular outflow tract.

Associated Anomalies. Most pulmonary valve stenoses are isolated lesions, but a few may be associated with a patent ductus arteriosus or aortic coarctation. Bicuspid or unicommissural pulmonary valves may be associated with subpulmonary stenosis in tetralogy or transposition or may rarely coexist with a ventricular septal defect or bicuspid aortic valve.

Hemodynamics. Due to pulmonary valvular obstruction, there is pressure hypertrophy of the right ventricle and post-stenotic dilatation of the pulmonary trunk. If subpulmonary stenosis is present (as in tetralogy), the pulmonary trunk usually is not dilated; the stenotic subpulmonary channel offers resistance to blood flow so that the high right ventricular pressure is not fully transmitted to the pulmonary valve and, as a result, no high pressure jet is forced across the valve and against the wall of the pulmonary trunk.

Clinical. Pulmonary valve stenosis usually presents as an asymptomatic systolic murmur heard best at the upper left sternal border. Even severe PS in older children rarely produces symptoms. Critical PS in the newborn may present as cyanosis and/or shock after the ductus arteriosus closes. Mild pulmonary stenosis found in the infant may become progressively worse with time, but may also get better and even resolve over several years. The process which occurs to accomplish this “cure” is not understood.

Pulmonary Stenosis



Echo Checklist – Pulmonary Stenosis

1. The size of the annulus - is it normal or hypoplastic?
2. The thickness of the valve leaflets - how dysplastic are they?
3. The leaflet excursion - how well does the valve open; do the leaflets "dome"?
4. The main pulmonary artery - is it hypoplastic? Is there post stenotic dilatation?
5. The subvalvular area - is there hypertrophy of the infundibulum and subvalvular stenosis?
6. Is a patent ductus arteriosus present?

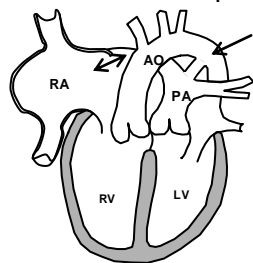
Practical Summary - Pulmonary Stenosis

1. Timing of intervention - gradients of >40-50 mm Hg. Balloon valvuloplasty is the procedure of first choice.
2. Secondary infundibular or supra-valvular stenosis may be present.

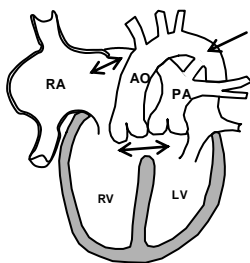
6) Transposition of the Great Arteries (TGA)

D-Transposition of the Great Arteries

D-TGA Intact Septum



D-TGA w/ VSD



Definition. Transposition is defined as connection of the aorta to the right ventricle and the pulmonary artery to the left ventricle. This abnormal ventricular arterial connection is also termed "ventriculo-arterial discordance" and probably results from abnormal conotruncal septation. Transposition occurs in approximately 4-8% of children born with congenital heart defects and is associated with a number of other heart defects including VSD and pulmonary stenosis. "Simple transposition" is a term which refers to transposition without associated defects. "D-transposition" is a term which refers to the way the conotruncal septum rotates in utero ("D" for dextro) and has been commonly applied to this entity. Transposition also occurs in children with other complex forms of congenital heart disease.

Anatomy. In transposition, the aorta arises from the right ventricle, usually in a position which is anterior and rightward of the pulmonary valve. The two great arteries course parallel to one another; a distinctly different arrangement from the normal pulmonary artery crossing over the aortic root. There are basically two forms of transposition: 1) with intact ventricular septum 2) with VSD (usually perimembranous) There is fibrous continuity between the anterior mitral leaflet and the **pulmonary valve**. For survival, areas of mixing must be present at atrial, ventricular or ductal levels. Both coronary arteries originate from the anterior great vessel (aorta).

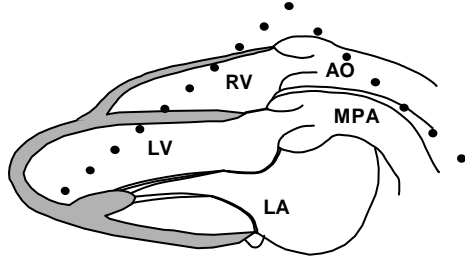
Associated Defects. Atrial septal defect, VSD - usually perimembranous, Pulmonary stenosis - subvalvular, valvular, Patent ductus arteriosus, Coarctation of the aorta

Hemodynamics. In simple transposition, desaturated blood returning to the right ventricle enters the aorta and returns to the systemic circulation (a "parallel" circulation). This causes severe systemic desaturation (cyanosis). In a similar manner, fully saturated pulmonary venous return to the left atrium, enters the left ventricle and then the pulmonary artery. This oxygenated blood then returns to the lungs where further saturation with oxygen cannot occur. Without intra cardiac mixing of systemic venous or pulmonary venous blood this physiology results in fatal hypoxia. Survival in children with transposition depends on the presence of intra cardiac (ASD, VSD) or extracardiac (PDA) shunts that allow mixing of systemic venous and pulmonary venous blood.

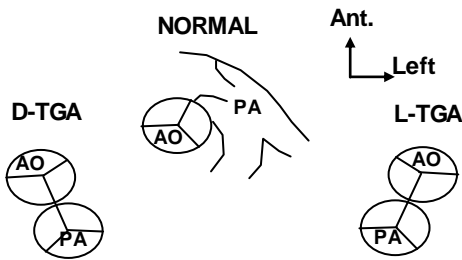
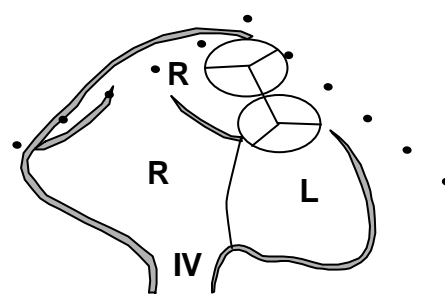
Clinical. Children with TGA are usually discovered shortly after birth because of profound cyanosis. There is generally not respiratory distress, so oxygen will not be effective in relieving the cyanosis. A hyperoxia test will not raise the PO_2 or saturation significantly. Prostaglandin E_1 should be administered and the patient transferred to a facility with experience in pediatric cardiac surgery. If saturation is extremely low, acidosis may occur. At that time catheterization with balloon atrial septostomy may be performed to improve mixing.

Echocardiographic Evaluation of Complete Transposition

Parasternal Long Axis



Parasternal Short Axis - Base



Great artery position is a key to identifying the type of transposition. Normally, the pulmonary artery wraps around the aorta anteriorly as it courses posteriorly. With D-transposition the great arteries assume a parallel course, and the aorta is located anterior and rightward of the centrally located pulmonary artery. In L-transposition (discussed later) the great arteries are again parallel, but the aorta is anterior and leftward.

Practical Summary -Transposition

1. Timing of Surgery - first week of life - arterial switch (Jatene). Older patients and adults have had “atrial switch”, Mustard or Senning operation.
2. Index of suspicion should be high in a cyanotic, otherwise well, infant.

Echo Checklist – Transposition of the Great Arteries

1. Carefully identify great vessels. Parallel great artery position, aorta anterior and rightward
2. Look for associated defects (VSD, ASD)
3. Evaluate coronary anatomy

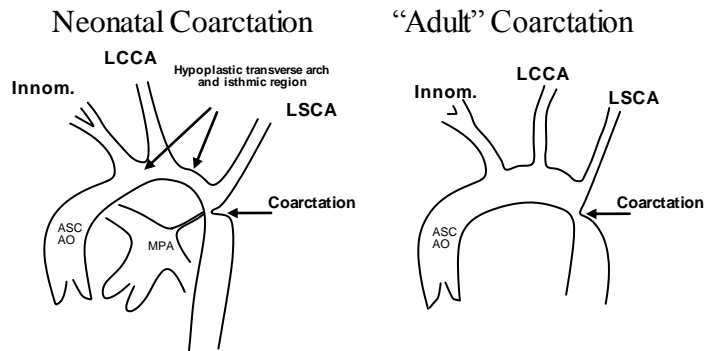
7) Coarctation of the Aorta

Definition/Anatomy. Coarctation is a narrowing in the upper descending aorta in the region of the ductus arteriosus (or ligamentum arteriosum). Almost all coarctation is juxtaductal (in the area of the ductus).

Associated Anomalies Coarctation is isolated in 50% of cases. Bicuspid aortic valve is present in 50%. VSD, PDA and other left heart obstructive lesions may also be present.

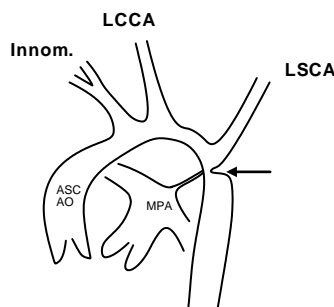
Hemodynamics. There is obstruction to left ventricular outflow producing pressure hypertrophy of the ventricle. Coarctation is also a developing lesion which may relate to the timing of ductal closure as well as the severity of associated aortic arch hypoplasia. If ductal closure results in severe and relatively sudden obstruction, then left ventricular failure usually ensues. If the obstruction is not as severe or is more gradual over many months, then collateral arteries may develop, effectively bypassing the coarctation and supplying blood to the lower body.

Clinical. Infants usually present in some degree of congestive heart failure or shock. Older children usually present with upper extremity hypertension, absent or decreased femoral pulses or a heart murmur (most often from the aortic valve). Rib notching may be seen on CXR. The difference in clinical presentation probably reflects severity, not the position of the ductus relative to the coarctation. Therefore, terms such as preductal or postductal are less accurate since they refer to anatomy, not severity. Coarctation, in most cases, is corrected upon discovery. Some mild cases may be observed for increasing severity. Echocardiography is usually the only diagnostic method which is used to evaluate coarctation. Catheterization may play a role in defining complicated anatomy or for therapeutic balloon dilation.

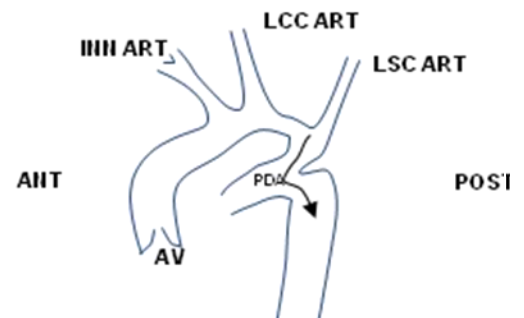


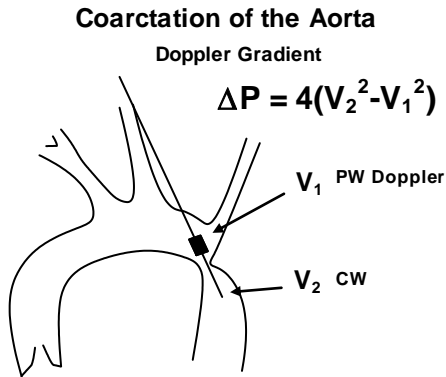
Echocardiographic evaluation of Coarctation of the Aorta

Suprasternal Long-Axis View

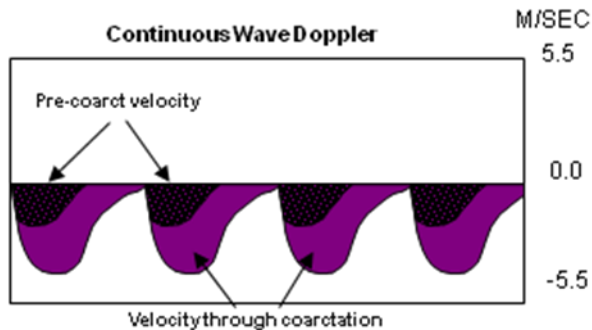


NEONATAL COARCTATION
EFFECT OF PDA





Coarctation of the Aorta
Doppler Signal



Echo Checklist – Coarctation of the Aorta

1. Evaluate arch gradient
2. Measure arch caliber
3. Look for associated anomalies (Bic. AV, PDA)
4. Evaluate ventricular function, hypertrophy

The definitive Doppler exam should be directed at the descending aorta in the area of the coarctation. The continuous wave interrogation of this area should result in the classic "sawtooth" flow pattern caused by delayed diastolic flow through the narrowed area. Frequently dual velocity envelopes will be seen representing the pre and post coarctation blood flow velocities. This classic picture may not be present: a) in a low cardiac output state, b) if the ductus arteriosus is widely patent. The gradient likewise, is not necessarily a good estimate of the coarctation severity since it is affected by the cardiac output as well as the degree of coarctation.

The peak Doppler gradient in coarctation often overestimates the true (cath-derived) gradient through the obstruction. This because the pre-coarctation velocity (influenced by the aortic valve, which is often abnormal) is sometimes high and cannot be ignored as we often do in the modified Bernoulli equation. Therefore the pre-coarctation velocity must be included in the calculation for greater accuracy as shown.

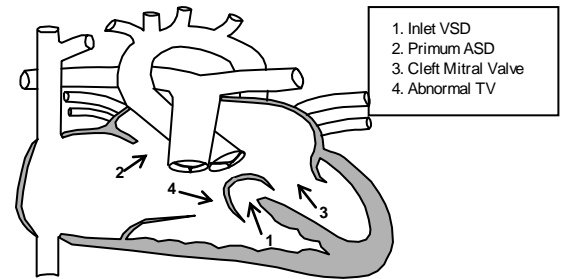
Practical Summary - Coarctation of the Aorta

1. Timing of Surgery - usually at time of diagnosis regardless of age.
2. Gradient may be low despite severe obstruction due to collateral flow.

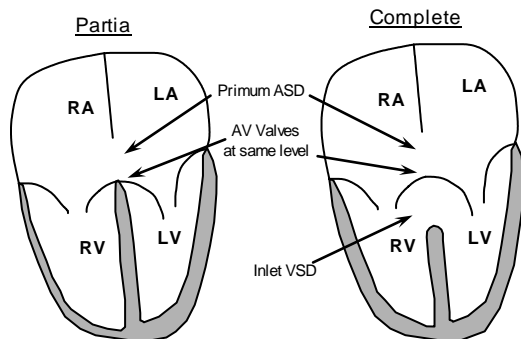
8) Atrioventricular Canal Defects (AV Septal Defect)

Definition/Anatomy. Atrioventricular canal defects (AVC) occur from a failure of the embryonic endocardial cushions to meet and normally partition the heart. The result is a defect in the center of the heart which effects the septae and the support apparatus of the AV valves. In the most severe form, which is called "**complete**", there is an ostium primum atrial septal defect, an inlet VSD, and a common AV valve that is markedly abnormal. Commonly referred to as a cleft mitral valve, this actually is a commissure between the embryologic anterior and posterior bridging leaflets which cross through the septal defects.

Atrioventricular Septal Defects (Atrioventricular Canal)



Apical 4-Chamber View



There are four basic components to atrioventricular septal defects.

1. Inlet VSD
2. Primum ASD
3. Cleft mitral valve
4. Widened antero-septal tricuspid commissure

If all four components are present a complete AV canal is present. If the VSD is absent, a partial AV canal is present.

Note that the terms: atrioventricular septal defect, atrioventricular canal defect, and endocardial cushion defect all mean the same.

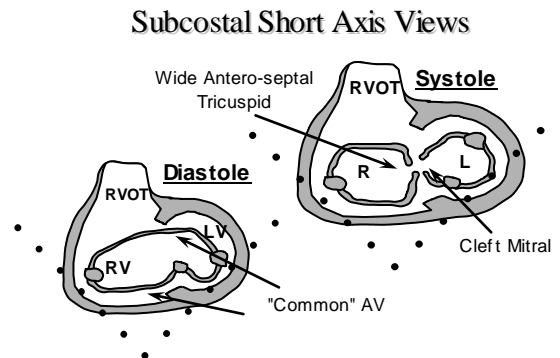
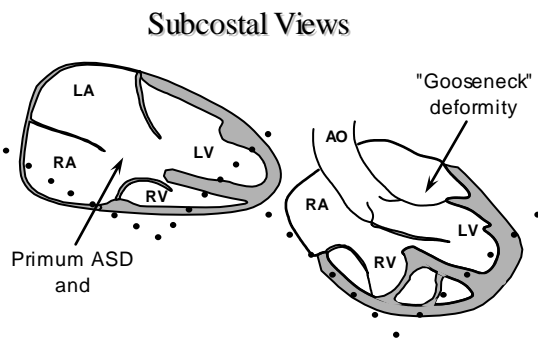
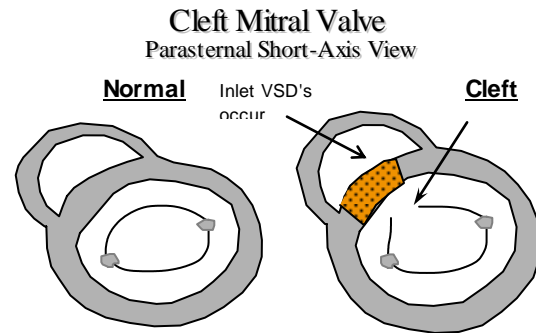
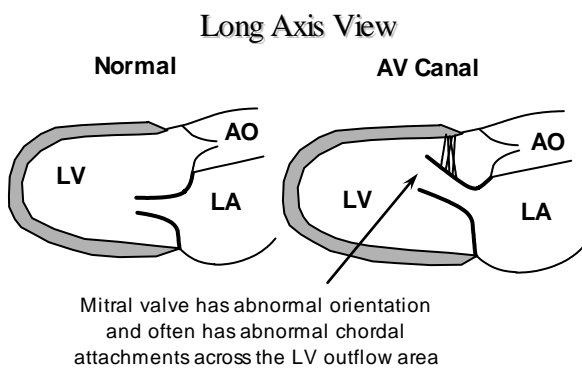
In addition, there is one leaflet committed to the left ventricle and a right lateral and right accessory leaflet committed to the right ventricle. This common AV valve can be free floating through the septal defects and unattached to any septum whatsoever, or it can be divided into right and left-sided orifices by a tongue of tissue that connects the two bridging leaflets. The latter leaves a cleft or commissure between the two bridging leaflets which allows for blood to flow from the left ventricle to the right atrium directly. If the attachments of the AV valve are to the crest of the ventricular septum, then most of the shunt will be left-to-right at the atrial level. Conversely if the septal attachments are free floating or to the crest of the ventricular septum, then a large ventricular level shunt will be present. When one or more of the components of a complete canal is absent, then the defect is called an "incomplete" form of AVC.

Associated Defects. The most common associated defect is a patent ductus arteriosus. Other lesions which may be seen include coarctation of the aorta, hypoplasia of the right or left ventricle, severe left ventricular outflow tract obstruction, double-orifice mitral valve, additional muscular VSD's, and right ventricular outflow tract obstruction with or without pulmonary valve stenosis. AVSD's are very common in association with Down Syndrome, and these patients may be at increased risk for earlier pulmonary vascular obstructive disease. Hemodynamics. The hemodynamics of this lesion depend upon which components of the AV canal are present and which predominate. If there is a large primum ASD and no VSD, then the physiology is like that discussed for ASD's. Similarly, if a large VSD is present, the physiology is that of other VSD's. The combination of ASD and VSD in complete AVSD can result in

marked volume overload of the pulmonary circulation. **The abnormalities of the AV valves result in the frequent presence of AV valve regurgitation.** There can be mitral valve regurgitation, tricuspid valve regurgitation, and a left ventricle-to-right atrial shunt. Severe AV valve regurgitation complicates the clinical course, and patients may be at a higher operative risk because of this. **Another complicating factor is the presence of unequal ventricular chamber sizes** with so-called "left" or "right" dominant AVSD's. These are associated with significantly higher morbidity and mortality and may not allow for a 4-chamber repair.

Clinical. AV canal defects are usually discovered by the presence of a heart murmur. Patients with complete AVC defect behave very much like a large VSD, which may have subtle finding early but develop signs and symptoms of congestive failure as the lung resistance drops. Patients with partial AVC behave much like patients with other type of ASD, and may be completely asymptomatic; presenting as a heart murmur.

Echocardiographic Evaluation of Atrioventricular Canal Defects



Practical summary - AV Canal

1. Timing of surgery - most often done within the first few months of life because the VSD is usually large and non-restrictive. If the ventricles are unbalanced (one ventricle hypoplastic), a pulmonary band is often done early followed by a Fontan-type repair.
2. Type of surgical closure - open heart, midline sternotomy, patch closure of defects with often some repair of the mitral valve cleft. Transesophageal echo is commonly used to evaluate the repair in the operating room.

Echo Checklist – Atrioventricular Septal Defects

1. Identify defect/establish diagnosis.
2. Confirm flow through defect with color.
3. Measure gradient across VSD.
4. Measure size of ASD/VSD.
5. AV valve commitment and attachments.
6. Measure relative sizes of ventricles.
7. Measure RV pressure.
8. Evaluate LV outflow tract.
9. Look for associated anomalies.

9) Aortic Valve Stenosis

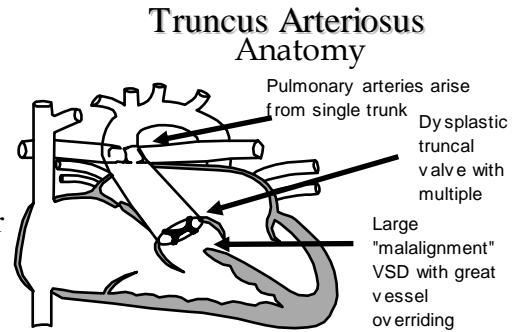
The clinical and echocardiographic issues of aortic stenosis in adults and children are approximately the same, and will not be discussed in detail in this section.

The biggest clinical problem faced by the pediatric cardiologist occurs when a valve replacement is contemplated for aortic valve disease in a small child. This complicates the situation because of the lack of small mechanical prostheses and because of the potential for growth (patients would “outgrow”) even a successful valve replacement.

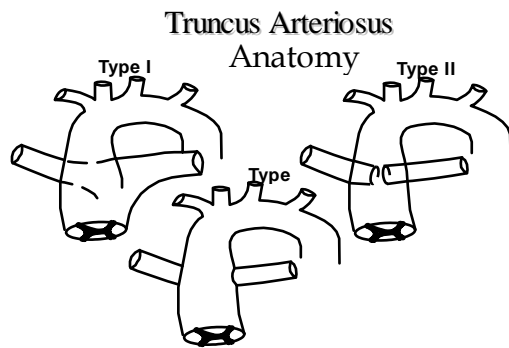
The current solution to this clinical dilemma is to wait as long as possible, balancing ventricular performance against gradient and risk. Surgical solutions which are more frequently encountered in pediatrics are a **Konno procedure**, where the aortic annulus is enlarged through the ventricular septum and patched open to accept a larger aortic prosthesis or a **Ross procedure**, where the patient's native pulmonary valve is excised and placed in the aortic position (the pulmonary valve is replaced by a homograft prosthesis). In the Ross procedure, the coronary artery origins must be explanted and reimplanted into the aortic root.

10) Truncus arteriosus

Definition. Truncus arteriosus may be defined as origin of a single great artery from the heart which then gives rise to both the pulmonary arteries and aorta. Essential in the definition of truncus arteriosus is the **absence** of a pulmonary valve whether patent or atretic. Truncus arteriosus occurs in approximately 2% of patients with congenital heart disease.



Anatomy. The intracardiac anatomy of truncus arteriosus is very similar to that of tetralogy of Fallot. A large VSD of the "malalignment" type is seen in the outflow septum with overriding of a great vessel. In this case the overriding vessel is not the aorta but a common "trunk" which gives rise to both the aorta and pulmonary arteries. The valve in this great artery is called the "truncal" valve and is often abnormal. It may have 2-6 cusps and is often thickened and dysplastic with varying degrees of stenosis and insufficiency. The pulmonary arteries arise from the trunk just distal to the truncal valve in several different orientations.



Associated Defects.

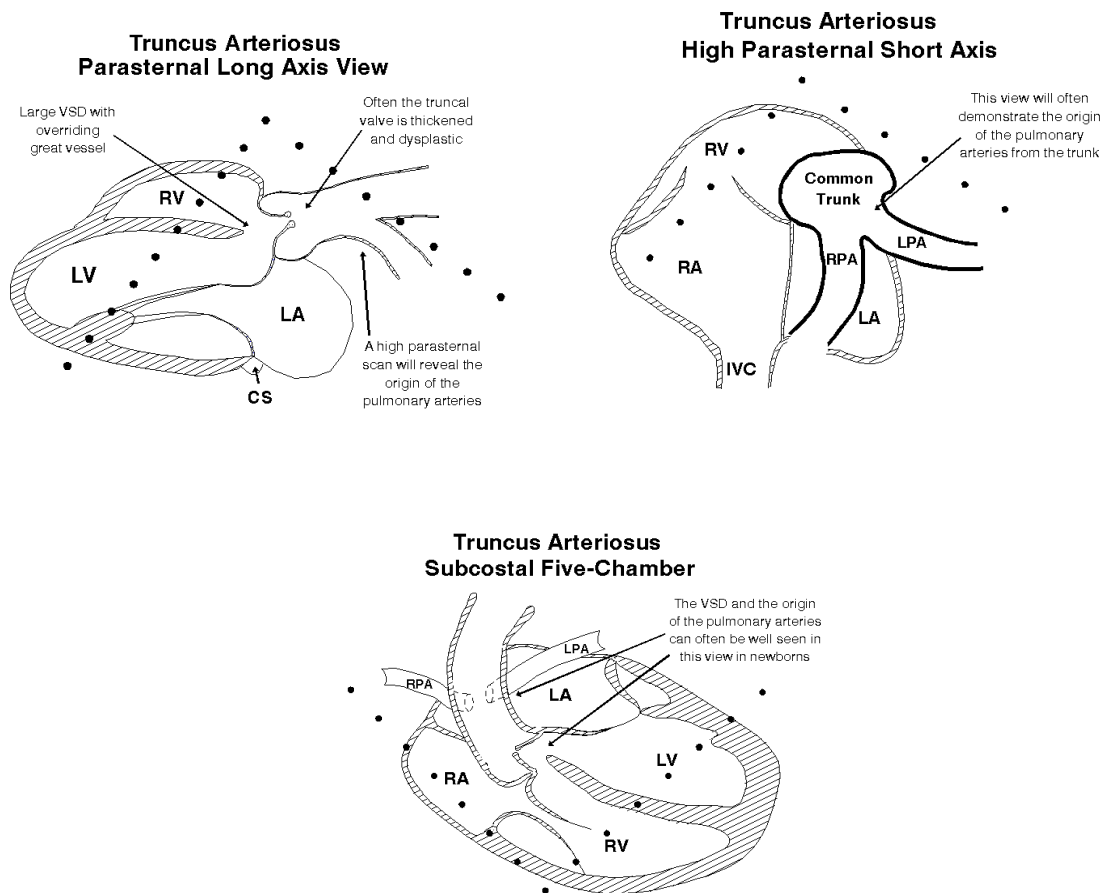
- Abnormal origin and course of coronary arteries (37-49%)
- Right aortic arch (30%)
- Abnormal number of truncal valve cusps: trileaflet (69%), quadricuspid (22%), bicuspid (9%)
- Absence of one pulmonary artery (16%)
- Interruption of the aortic arch (15%)
- Left SVC (12%)
- Secundum ASD (9-20%)
- Truncal valve stenosis and insufficiency

Hemodynamics. Mixing of arterial and venous blood occurs at the ventricular level and in the common trunk and may produce mild cyanosis. The right ventricle and usually both pulmonary arteries are under systemic (high) pressure. Truncal valve stenosis produces pressure overload of both ventricles. Truncal valve insufficiency may also be severe, resulting in further volume overload. The frequent occurrence of associated defects, often makes a bad situation worse. Interruption of the aortic arch leads to severe obstruction to systemic flow (in neonates) after closure of the ductus arteriosus. Absence of one pulmonary artery will place a tremendous amount of flow into the remaining artery. The frequent occurrence of truncal valve abnormalities also places added strain on the heart.

Clinical. Patients with truncus arteriosus are usually discovered shortly after birth due to a heart murmur from flow across the often abnormal truncal valve. However, since the pulmonary arteries arise from the trunk and since this structure is at systemic pressure, severe pulmonary overcirculation and congestive heart failure ensue as pulmonary resistance falls after birth. Heart failure symptoms usually are more

prevalent than cyanosis and heart failure is often severe and early.

Echocardiographic Evaluation of Truncus Arteriosus



Echo Checklist – Truncus Arteriosus

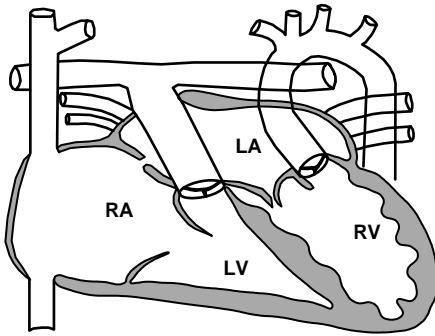
1. Evaluate truncal valve morphology and hemodynamics.
2. Delineate origin/course of the main pulmonary trunk, right and left pulmonary arteries.
3. Evaluate ventricular function.
4. Evaluate anatomy and branching of aortic arch.

Practical Summary - Truncus Arteriosus

1. Timing of surgery - usually as a newborn or within the first month.
2. The repair utilizes an extra-cardiac conduit (RV-PA) which will require multiple re-operations for conduit changes with growth and age.

11) Congenitally Corrected Transposition of the Great Arteries (L-TGA)

Corrected Transposition
Anatomy



opposite of normal).

Anatomy. This entity is also called "L-transposition", "ventricular inversion" and a number of other names to try to identify the complexity of the problem. For this discussion, the term ventricular inversion may be the easiest to understand. The morphologic (that is, coarsely trabeculated and triangular shaped) right ventricle is located under the left atrium on the left and posterior side of the heart and the morphologic left ventricle (smooth walled, conical shape) is located under the right atrium on the right and anterior side of the heart. The atrioventricular valves go with the ventricles. This means that the tricuspid valve is still within the body of the right ventricle even though the right ventricle is on the left. The aorta ends up in a position which is anterior and leftward of the pulmonary (exactly the

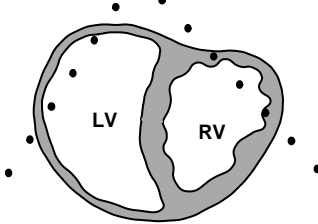
Pathophysiology and Blood Flow. Despite the abnormal connection (discordance), the blue blood goes to the lungs and the red blood goes to the aorta. In the absence of associated defects, the blood flow through these hearts is entirely normal. Any derangement in flow is due to additional, associated defects.

Associated Defects. Ventricular septal defect, most often perimembranous, is the most common defect, occurring 80% of the time. Some degree of pulmonary valve stenosis is seen in about 59% of cases. Tricuspid valve (left AV valve) abnormalities including Ebstein's malformation are present in up to 90% of patients. The significance of this finding is that this valve is now the systemic AV valve and regurgitation is less well tolerated. Conduction abnormalities particularly complete heart block are seen in up to 30% of cases. Dextrocardia is present in 25% of cases, adding another level of complexity to the anatomy.

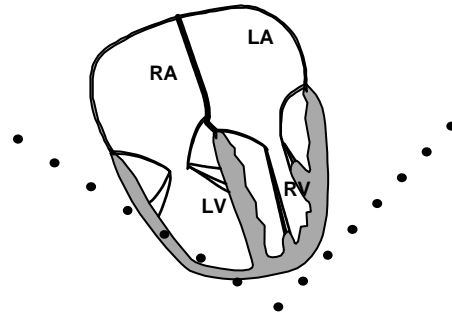
Associated Defects

- Atrial septal defect
- Ventricular septal defect
- Pulmonary stenosis, subpulmonary stenosis
- Dysplastic left AV(tricuspid) valve
- Straddling left AV valve
- Superio-inferior ventricles
- Aortic/ subaortic stenosis
- Coarctation of the aorta/ arch anomalies
- Visceral situs abnormalities (situs inversus)
- Abnormalities of cardiac position (dextrocardia)
- Rhythm abnormalities (heart block, SVT)

Corrected Transposition
Parasternal Short-Axis View



Corrected Transposition
Apical Four-Chamber



Echo Checklist – Corrected Transposition

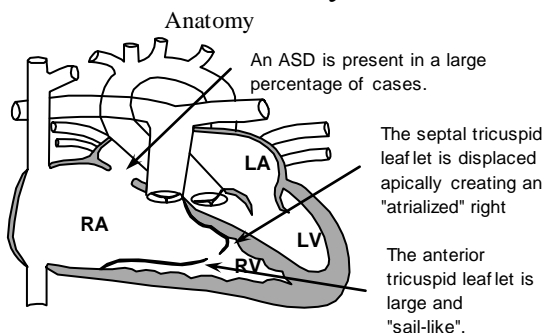
1. Identify the basic anatomy - abnormal semilunar valve position
2. Identify associated defects (VSD, PS)
3. Check ventricular function (morphologic right ventricle is systemic ventricle)
4. Evaluate left sided AV valve morphology and integrity

Practical Summary - Corrected Transposition

1. Timing of surgery - depends upon the nature of the associated defects (VSD, PS).
2. High incidence of complete heart block, either spontaneous or post-operative.

12) Ebstein's Anomaly of the Tricuspid Valve

Ebstein's Anomaly



Anatomy. Ebstein's anomaly is a severe deformity of the tricuspid valve which results from failure of the normal development of the septal and posterior leaflets. These leaflets become displaced apically and adherent to the wall of the right ventricle and septum. The anterior leaflet becomes enlarged and "sail-like" with variable attachments to the trabecular portion of the right ventricle and outflow area. In a small percentage of cases, the tricuspid valve can be imperforate, or stenotic creating an unusual tricuspid valve atresia or stenosis.

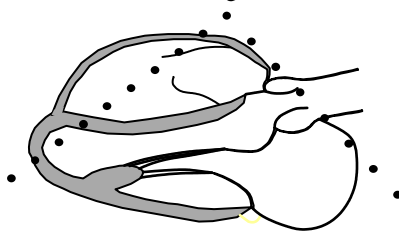
Pathophysiology and Blood flow. The apical displacement of the valve reduces the effective volume of the right ventricle available for pumping function. In addition, the Ebstein's valve usually is quite insufficient. All of these factors contribute to tricuspid insufficiency, poor forward flow, and the potential for right-to-left shunt through and ASD or foramen ovale. The net result of the poor forward flow may mimic pulmonary atresia. Thus, patients with Ebstein's anomaly may be profoundly cyanotic, particularly as newborns. This cyanosis usually resolves after several weeks and patients with Ebstein's anomaly may be clinically quite well for many years into young adulthood. Those patients with an ASD will usually begin shunting right-to-left in the late teen years and symptoms of exertional dyspnea may occur.

Ebstein's anomaly is an extremely rare deformity. Patients usually present as infants. The heart may be markedly enlarged, usually due to right atrial enlargement. Dysfunction of both right and left ventricles may be present. The diagnosis is made by echocardiography. There is usually little need for other tests. Care must be taken to identify the chordal attachments of the mobile anterior leaflet.

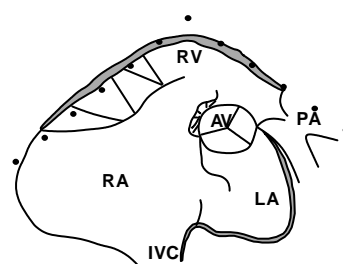
Associated Defects. An atrial septal defect is present in 40-60% of patients with Ebstein's. Right atrial enlargement is present to varying degrees, but may be significant resulting in massive cardiomegaly on chest x-ray. Ventricular defects are occasionally present. Patients with this problem have a higher incidence of the Wolff-Parkinson-White syndrome and resultant supraventricular tachycardia.

Echocardiographic Evaluation of Ebstein's Anomaly

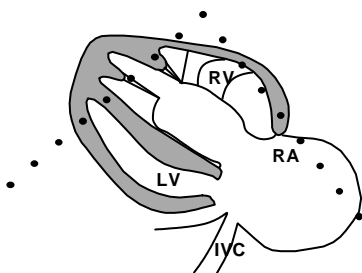
Ebstein's Anomaly
Parasternal Long Axis View



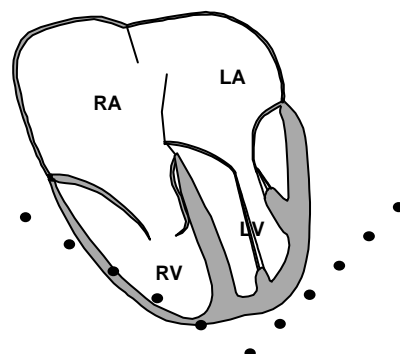
Ebstein's Anomaly
Parasternal Short Axis - Base



Ebstein's Anomaly
Parasternal RV Inflow



Ebstein's Anomaly
Apical Four-Chamber View



Echo Checklist – Ebstein’s Anomaly

1. Define septal tricuspid displacement
2. Check attachments, tethering, mobility of the anterior tricuspid leaflet
3. Check for ASD and direction of shunting
4. Check septal position and ventricular function

Practical Summary - Ebstein’s Anomaly

1. Timing of surgery - Depends upon the severity of the deformity, clinical status and presence of ASD.
2. Enlarging heart size, exertional problems, developing cyanosis, may be clinical indications to intervene.
3. Operation to close ASD and repair tricuspid valve should be timed to avoid multiple operations.



Unique Congenital Obstructions

There are many intracardiac obstructive lesions which are congenital, and therefore, unique to pediatric cardiology. It is uncommon for congenital heart disease to be found in multiple members of a single family. However, when this does occur with right or left-sided obstructive lesions, the same side of the heart is usually affected. For example, one sibling may have subaortic stenosis, and another sibling may have coarctation of the aorta. It is also common for multiple left-sided obstructive lesions to be found in the same patient. When this occurs, it is called Shone’s syndrome. The following are brief descriptions of several of the uniquely congenital obstructive lesions with their echocardiographic features.

LEFT HEART OBSTRUCTIVE LESIONS

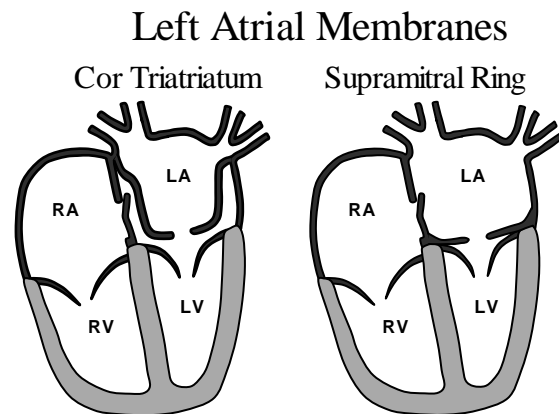
Cor Triatriatum (three atria)

This lesion is a membrane within the left atrium which obstructs pulmonary venous inflow into the body of the left atrium. Embryologically, the pulmonary veins form a confluence behind the left atrium, and this ‘common pulmonary vein confluence’ grows toward the back of the left atrium, merges with the rest of the forming left atrium, and forms a single, larger chamber. In fact, most of the tissue present in the normal left atrium is made up of tissue from the primitive pulmonary venous confluence. The embryologic left atrium remains as the left atrial appendage.

Cor triatriatum results from failure of the common pulmonary vein to be incorporated completely into the posterior of the left atrium. This produces the appearance of a third atrial chamber. The common pulmonary venous chamber (third atrium) remains separate from the rest of the left atrium except for a small, stenotic orifice. The atrial appendage, foramen ovale and mitral valve are on the "down stream side" or distal to the obstructive membrane. The mitral valve is usually normal. Symptoms from this obstruction are similar to mitral stenosis, with tachypnea and pulmonary venous edema. This defect may not produce any symptoms initially after birth since the degree of obstruction is variable and the pulmonary flow is initially low. Symptoms may take weeks or months to become evident. Repair is an open procedure to remove the membrane. The timing of surgery is dictated by the symptoms.

Supravalvar Mitral Ring

Supravalvar mitral ring is another intracardiac obstructive lesion which can form within the left atrium and obstruct pulmonary venous inflow. The embryologic origin of this obstruction is unknown. In at least 90% of cases, supravalvar mitral ring is associated with other left heart obstructions (Shone's syndrome). The location of this fibrous ridge is between the left atrial appendage and the mitral valve. It can be distinguished from cor triatriatum by its location below the atrial appendage, rather than above it. The usual supravalvar mitral ring is very close to the mitral valve, with separation from the mitral leaflets frequently only noted during diastole. The membrane may become adherent to the mitral valve itself and cause thickening and abnormal motion of the mitral valve leaflets. Symptoms are those of mitral stenosis, including tachypnea, breathlessness with exertion, and pulmonary venous edema. Symptoms of supramitral membrane usually, but not always, occur somewhat later in childhood. Repair of supramitral membrane is similar to that of cor triatriatum.



Imaging/Doppler of Left Heart Inflow Obstructions

The membrane of cor triatriatum and the supravalvar mitral ring may each be visualized in the parasternal long axis view, in the subcostal frontal and oblique views, and in the apical four chamber view. The various subcostal views and parasternal long axis view may be most helpful in demonstrating whether the membrane is above or below the level of the left atrial appendage.

With cor triatriatum, the color flow mosaic jet begins at the membrane orifice into the LA. The CW Doppler beam should be aligned with the color flow jet to obtain the peak velocity across the obstructive orifice. With the supravalvar mitral ring, the color mosaic usually begins just at the valve and sprays into the ventricle. Its Doppler flow pattern would be delineated in a fashion similar to that of mitral stenosis. Evaluation with pressure $\frac{1}{2}$ time and peak/mean gradient should be done.

Late postoperative imaging should reveal normal anatomy and function. Residual mitral valve stenosis or regurgitation should be evaluated, although these are unusual findings. Early postoperative imaging should document the resolution of pulmonary hypertension if it was present preoperatively.

Subaortic Stenosis

Membranous Subaortic Stenosis

Discrete, membranous subaortic stenosis makes up 85% of the subaortic stenosis found in childhood. In this type, a thin, diaphragm-like membrane is found below the aortic valve roughly in parallel to the plane of the aortic annulus. Usually, the membrane is from one to a few millimeters below the aortic annulus. It is attached to the ventricular septum on the rightward anterior aspect, and usually forms a 'curtain-like' ring in the left ventricular outflow tract. It may occasionally be associated with a small perimembranous ventricular septal defect, coarctation of the aorta, or valvular aortic stenosis. The obstructive membrane creates an eccentric, turbulent jet of blood flow beginning below and extending through the aortic valve. This flow disturbance may cause thickening of the aortic valve over time. Aortic


insufficiency frequently develops since the membrane blocks part of the aortic valve but allows accelerated flow across the rest of the valve. Aortic regurgitation is rarely severe. Symptoms and clinical findings are similar to those of aortic valve stenosis.

Tunnel Subaortic Stenosis

Tunnel subaortic stenosis makes up the other 15% of subaortic stenosis. Many authors believe that there is a spectrum of disease between the thin membrane described above and tunnel subaortic stenosis. In tunnel subaortic stenosis, a fibrous or fibromuscular cuff of obstructive tissue of variable length develops below the aortic valve in the left ventricular outflow tract. It is often associated with concentric left ventricular hypertrophy, and less commonly with asymmetric septal hypertrophy and hypercontractility of the LV. It may also be found in patients with multiple left heart obstructions (Shone's syndrome). Symptoms and clinical findings are similar to those of aortic valve stenosis.

Imaging/Doppler of Subaortic Stenosis

Parasternal long axis, apical, and subcostal oblique views of the LV outflow tract are best for imaging both types of subaortic stenosis. When imaging patients with the discrete subaortic membrane, the membrane is very thin, so that the highest frequency transducer that is practical will give the best images. With both types of subaortic stenosis, the aortic and mitral valves may also be abnormal and should get special attention. With discrete subaortic stenosis, the peak gradient should be obtained and most closely correlates with the gradient at catheterization. Combining pulsed wave Doppler with continuous wave Doppler can help to localize the level of obstruction within the left ventricular outflow tract. The presence or absence of aortic insufficiency should be carefully noted and quantitated. With tunnel subaortic stenosis, the modified Bernoulli equation may underestimate the peak gradient (by neglecting viscosity) compared to measurement at catheterization.



Perioperative Echo/Doppler

It is our practice to perform intraoperative transesophageal echocardiography to further demonstrate the anatomy of the subaortic stenosis for the surgeon immediately before resection. After rewarming and removal from bypass, the patient's LV function is re-evaluated, the LV outflow tract is scanned for the presence of residual obstruction, any residual gradient across the LVOT is quantified, and aortic valve insufficiency is re-assessed.

Late postoperative evaluations concentrate on the status of the aortic valve. A small percentage of subaortic membranes will grow back and require reoperation.



Coronary Arteries

Coronary artery anomalies may be classified into:

- 1) Abnormalities of clinical importance
- 2) Abnormalities of surgical importance

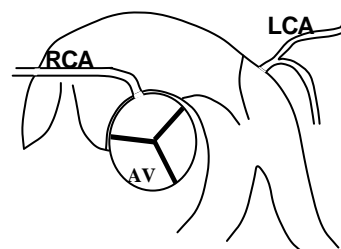
Abnormalities of Clinical Importance

Anomalous left coronary artery from the pulmonary artery

This rare coronary anomaly generally presents clinically at about 2-3 months of age. Understanding the physiology is important to understand the disease. As fetal and newborn pulmonary resistance falls, there is diminished perfusion to the left coronary system. This results in progressive ischemia to the left ventricle.

Infants will often present with diaphoresis, crying with feeds (infant angina) and irritability. During this time, the right coronary enlarges and there is development of collateral flow through the right coronary to the left. This may often be exuberant and some patients will survive this period and redevelop good ventricular function. The majority will present much as a dilated cardiomyopathy, with signs of congestive heart failure and angina, both subtle in the infant. Echocardiographically this may be mistaken for dilated cardiomyopathy or myocarditis, so careful evaluation of the coronary anatomy is needed. The anomalous coronary may exhibit significant shunting into the main pulmonary artery. The site of entry can be variable and sometime deceptive. An ECG showing signs of LV ischemia in children is pathognomonic for this entity. It is also known as the Bland-White-Garland syndrome.

Anomalous LCA from Pulmonary Artery

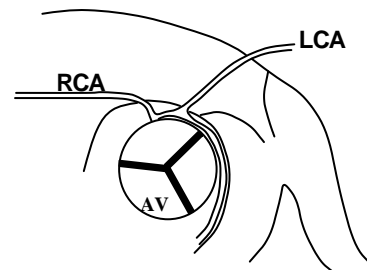


Treatment is surgical with the aim of re-establishing a two coronary system. This may be accomplished by several techniques, but the most common is simple re-implantation of the anomalous coronary.

Anomalous left coronary from the right coronary

This is another rare coronary anomaly. In this instance the left coronary arises from the right sinus of Valsalva as a single coronary or with a separate orifice from the right coronary. In either case, the course of the coronary is between the two great arteries. This entity has been described in cases of syncope, chest pain, and sudden death in teenagers and young adults.

Anomalous LCA from Right Coronary



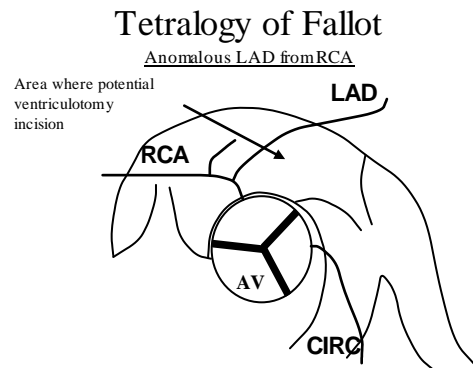
Echocardiographically it is difficult to visualize in many patients. The best clue may be the absence of the normal origin of the left main coronary from the left coronary sinus.

Abnormalities of Surgical Importance

Anomalous left anterior descending coronary from the right coronary

This anomaly is found in about 5% of patients with conotruncal anomalies, particularly tetralogy of Fallot. The left anterior descending (LAD) coronary arises from the right coronary and courses over the right ventricular outflow tract to its usual destination. The surgical importance arises from the frequent use of an incision in the right ventricular outflow tract to relieve subpulmonary obstruction. If the coronary anomaly is unknown, this may result in inadvertent severing of the artery with catastrophic results. The presence of this anomaly may significantly alter the timing or style of surgery. It is often the reason that artificial conduits are used in this repair.

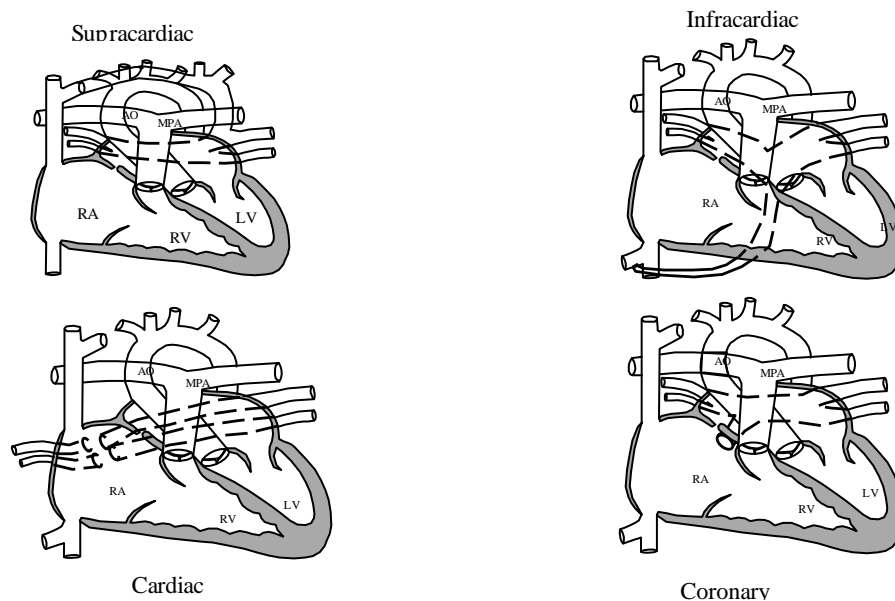
Echocardiographically this entity is much as seen above. The origin and course of the LAD must be carefully examined from multiple views.



Anomalous Pulmonary Venous Return

Anomalous pulmonary venous return is a rare congenital anomaly which has several anatomic variations. The most common is supracardiac (45% of total cases). There are features from each for of TAPVR which are common to each entity. These are easily seen on echocardiography. Anomalous pulmonary veins will connect to the systemic venous system. Therefore, echocardiographic evaluation should include a careful examination of usual systemic veins as well as their embryologic remnants. These include the IVC, SVC, Left SVC and coronary sinus. Anomalous pulmonary venous return may also be “mixed” and use some connections for right-sided veins and other connections for the left-sided veins. Infracardiac (infradiaphragmatic) TAPVR is often a surgical emergency because these veins are almost invariably obstructed as they pass through the liver. Other forms of TAPVR may also become obstructed and this should be evaluated. Infracardiac forms of TAPVR account for 24% of total cases with 26% presenting as direct cardiac connections. The most common of these is direct connection to the coronary sinus, behind the left atrium. This form is generally unobstructed and may remain asymptomatic for some time. Five percent of cases represent mixed forms of connection.

Total Anomalous Pulmonary Venous Return



Echo Features of TAPVR

1. Large right ventricle
2. Smaller left heart
3. Right to left atrial shunt (ASD is always present)
4. Possible complex ventricular anatomy (single ventricle)

General Principles of Postoperative Congenital Heart Disease

Repair of congenital heart disease has progressed tremendously over the last 40-50 years, resulting in improved survival for many defects which are otherwise lethal if left untreated. Diagnostic techniques such as echocardiography and cardiac catheterization have also undergone significant improvement which has aided in this effort. The general trend in this area in recent years has been to repair early and not perform the so-called palliative operations, done more frequently in the past. As techniques have improved in the

operating room for managing small infants on cardiopulmonary bypass, this has become technically possible.

There have been multiple choice questions on past **ASCexams** which ask for knowledge of the meaning of the surgical procedures shown at the right. Those names which are underlined

have become common acronyms for the procedure. Study this list!

1938 - Gross - ligation of PDA
1944 - <u>Blalock, Taussig</u> - systemic-pulmonary shunt/subclav. art to pulm artery
1945 - Gross, Crafoot - repair of coarctation
1946 - <u>Potts</u> - descending aorta to LPA shunt/direct side-to-side anastomosis
1952 - Muller - pulmonary artery band
1953 - Gibbon - repair of ASD
1954 - Lillehei - repair of VSD
1954 - <u>Glenn</u> - SVC to PA shunt
1954 - <u>Mustard</u> - atrial correction of transposition
1955 - Lillehei, Kirklin - repair of TOF
1960 - <u>Waterston</u> - aorta to RPA shunt/ direct side-to-side anastomosis
1964 - <u>Rastelli</u> - conduit to replace pulmonary artery/close VSD
1967 - <u>Rashkind</u> - balloon atrial septostomy (catheter)
1971 - Fontan, Kreutzer - repair of tricuspid atresia
1976 - <u>Jatene</u> - arterial switch for transposition
1978 - - cold blood cardioplegia

Palliative vs. Corrective Procedures

Palliative operations provide a temporary surgical treatment for a compelling clinical conditions (i.e. extreme cyanosis, marked pulmonary hypoplasia, severe pulmonary overcirculation, etc).

The definition of a corrective surgical procedure is controversial. Corrective operations can produce one or more of the following three objectives: normal anatomy, normal hemodynamics, and/or normal physiology. The ideal corrective surgical procedure is one which will produce normal anatomy, hemodynamics and physiology in a single stage without the need for future reoperations. An example of an ideal corrective surgical procedure is the primary closure of an atrial septal defect.

Certain procedures produce only a physiologic correction. An example of such a procedure is a total cavopulmonary connection (Fontan procedure). This correction is performed in hearts with single ventricle physiology.

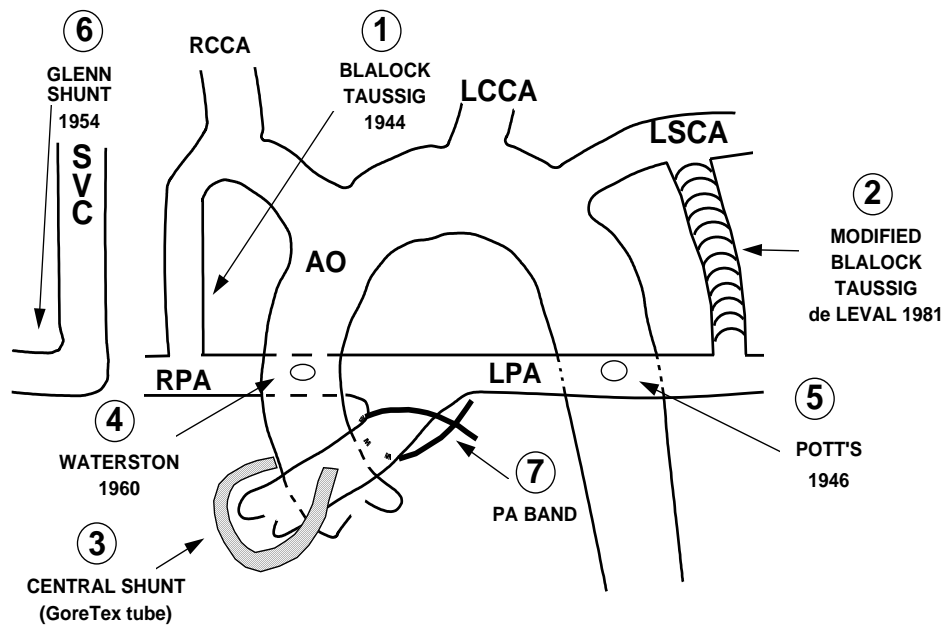
Palliative Operations

Palliative operations are done when circumstances do not allow for a complete repair. The reasons are varied and may relate to the anatomy, size of the patient and surgeons skill and experience. Different types of palliative operations are listed below.

Table of Palliative Operations

Operation	Description	Utility	Complications
1. Classic Blalock-Taussig Shunt	Subclavian artery to pulmonary artery	Increases pulmonary blood flow	Distortion of pulmonary artery
2. Modified Blalock-Taussig Shunt	Subclavian artery to pulmonary artery Gore-tex interposition graft	Increases pulmonary blood flow	Distortion of pulmonary artery
3. Central shunt	Ascending aorta to pulmonary artery graft	Increases pulmonary blood flow	Less distortion
4. Waterston shunt	Ascending aorta to right pulmonary artery anastomosis	Increases pulmonary blood flow	Distortion of pulmonary artery, pulm. hypertension
5. Pott's Shunt	Descending aorta to left pulmonary artery anastomosis	Increases pulmonary blood flow	Distortion of pulmonary artery, pulm. hypertension
6. Glenn Shunt	SVC to right pulmonary artery	Provides flow under low pressure to PA	Pulmonary AV fistula
7. Pulmonary Artery Band	Constricting band around MPA	Reduce pulmonary blood flow	Distortion of pulmonary artery flow

Palliative Operations



Corrective Operations

Operations which are considered to be “corrective” should return all of the blood to the point where it would go in a normal 4-chamber heart. Ideally this should also involve two ventricles. Some “corrective” operations do not restore completely normal valvular integrity (e.g. tetralogy of Fallot).

The Fontan-type Operation for Single Ventricle*

The concept of partial circulatory bypass of the right heart was first successfully achieved in 1958 by Glenn. The concept was later modified and popularized by Fontan (1971) and Kreuzer (1971). Newer modifications have directly joined the inferior and superior vena cavae using a tunnel through the right atrium with direct caval anastomosis to the pulmonary arteries (the so-called “total cavo-pulmonary

Goals of the Fontan Operation

1. Separate systemic and pulmonary circulations.
2. Remove volume load from the (single) pumping chamber.

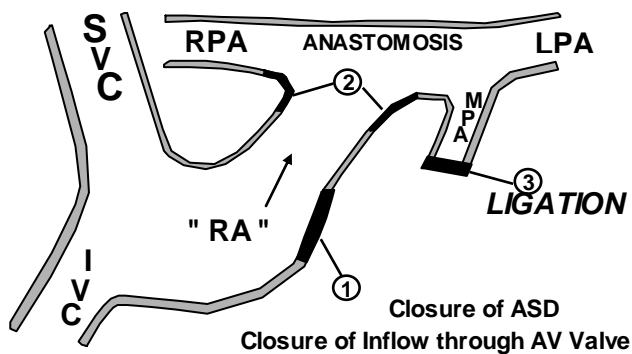
Fontan - Operative Concept

1. Direct the systemic venous blood to the lungs.
2. No pumping chamber in the pulmonary circuit.
3. Allow ventricle(s) to pump pulmonary venous blood to body.

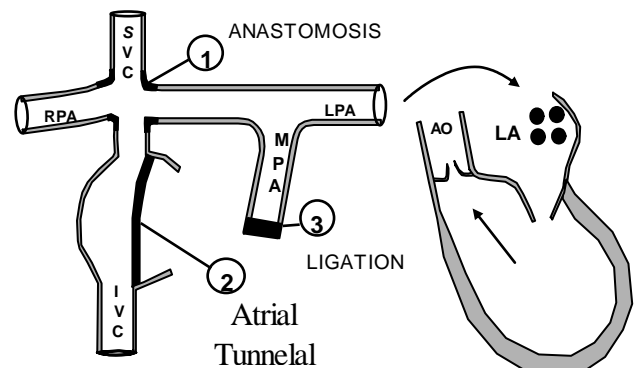
anastomosis”).

Knowledge of this operation is important because, although it is used on only rarely occurring defects, it is a unifying concept, which when taken as a whole, encompasses many different patients.

Modified Fontan - Kreuzer Operation



Total Cavo-Pulmonary Anastomosis



Congenital heart defects which are repaired using the Fontan operation

- Hypoplastic left heart syndrome
- Hypoplastic right heart syndrome
- Tricuspid valve atresia or mitral valve atresia
- Double-inlet single ventricle
- Common-inlet single ventricle
- Complex AV valve straddling which results in one hypoplastic ventricle

Exam Tips

Exam items which have previously appeared are no guarantee that they will be on every exam. The exam writers choose from a question bank and each year's exam differs from previous exams. Like most board exams, questions are evaluated after each exam for validity and some are discarded if the answers clearly do not produce a consensus. The following represent some tips which have been given by previous examinees based on their experience to give course participants an idea of the type of questions which they might face.

Congenital things which have appeared on previous exams:

→ Video Test

- ♥ VSD w/ aneurysm vs. ruptured sinus of Valsalva
- ♥ Supracristal VSD with aortic regurgitation
- ♥ Secundum ASD demonstrated by negative contrast

→ Written Test

- ♥ Description of Ebstein's anomaly
- ♥ Associated problems w/ bicuspid aortic valve
 - Post-stenotic dilation, coarctation, degeneration
 - Bicuspid vs. unicommissural
- ♥ Picture of sub-aortic membrane
- ♥ Picture of tricuspid atresia
- ♥ Picture of L-Transposition – a favorite question
- ♥ Knowledge of AV canal defects
- ♥ Anomalous left coronary artery from the pulmonary artery (ALCAPA)
- ♥ Associations w/ primum ASD – know cleft MV
- ♥ QP/QS calculations – usually with an ASD
- ♥ Sinus venosus ASD – TEE picture and common associations – know PAPVR
- ♥ Timing of fetal echocardiography
 - Know what might be hard to spot in a 20-week fetus – perimembranous VSD
 - Easy things to spot are hypoplastic chambers or big VSD's, AV canal, conotruncal defects
- ♥ Knowledge of associations with supracristal VSD – aortic cusp prolapse
- ♥ Look-alikes for DORV and VSD – tetralogy of Fallot
- ♥ Case of adult w/ PO tetralogy and increased RV pressure – think peripheral PS
- ♥ Noonan's, William's, Turner's, Marfan's syndromes – associated anomalies
- ♥ Common associated lesions with coarctation (other left heart obstructions)
- ♥ Uhl's Anomaly

Uhl's anomaly is a very rare anomaly with parchment-like right ventricle and almost complete absence of RV muscle fibers. In appearance it has similarities to Ebstein's anomaly, except that the tricuspid valve is anatomically normal. It has been associated with arrhythmogenic right ventricular dysplasia.