

Implant based rehabilitation options for the atrophic edentulous jaw

KR Spencer

Melbourne Oral & Maxillofacial Surgeon, Melbourne, Victoria, Australia.

ABSTRACT

The atrophic and edentulous jaw can pose a number of challenges for the implant clinician. In simple terms, the amount of bone that remains is insufficient for the conventional placement of a dental implant. A variety of treatment strategies can be employed to enable implants to be placed despite the paucity of bone stock in either the mandible or the maxilla. Conceptually these strategies follow one of two pathways: either augmentation of the bone, or the novel utilization of the remaining bone. This article will discuss patient assessment, treatment planning, and the range of contemporary options available to enable fixed implant based rehabilitation of each jaw. “The edentulous patient is an amputee, an oral invalid, to whom we should pay total respect and rehabilitation ambitions” (P-I Branemark, September 2005).

Keywords: all on 4, alveolar atrophy, distraction osteogenesis, implant rehabilitation, mandibular grafting, maxillary grafting.

Abbreviations and acronyms: CT = Computer tomography; OPG = Orthopantomogram.

Accepted for publication October 2017.

INTRODUCTION

Anatomic changes in the atrophic jaw

As described and classified in the classical paper by Cawood and Howell,¹ in a study of 300 dried skulls, the alveolar process of the jaws undergo a progressive and predictable horizontal and vertical anatomical change following tooth loss.

Over time, the alveolar bone is completely resorbed and even basal bone loss can occur as a result of overloading from ill-fitting dentures (Fig. 1).

In the maxilla the bone loss can be so severe that less than a millimetre of bone remains between the oral cavity and nasal or sinus cavities, and in the mandible the bone loss can result in exposure the inferior alveolar nerves (Fig. 2).

Furthermore, with advanced atrophy, an unfavourable Class III intermaxillary relationship develops mainly due to maxillary retrusion, this further complicates both ideal implant positioning and prosthetic rehabilitation.

PATIENT ASSESSMENT

Patient history, examination and investigation are, as always, essential in treatment planning. Smoking, diabetes, and a compromised immune system, along with

various medications including those taken for osteoporosis can all reduce the success of both bone grafting and subsequent implant treatment.

Clinical examination is undertaken to assess the intermaxillary relationship along with the health of the oral cavity and to exclude any pre-existing oral pathology.

Measurement and photography of the resting vertical dimension of the face, along with the height of the smile needs to be documented in maxillary rehabilitation cases in order to ensure that the transition zone between the oral mucosa and the prosthesis is hidden under the upper lip.

The use of cone beam CT scanning is essential in the treatment planning process as it allows the clinician to accurately visualise both the volume and configuration of the residual bone (Fig. 3). In addition, in the maxilla, it allows both the health and degree of pneumatization of the sinus cavities to be assessed. In the

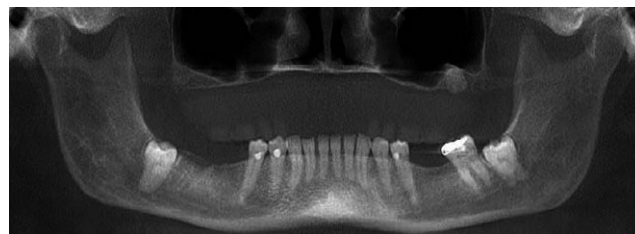


Fig. 1 Extreme maxillary atrophy in a long-term denture wearer.

mandible, it is an invaluable tool in preventing surgical misadventure when it appears there is adequate bone for implantation on an OPG (Fig. 4).

AUGMENTATION OF THE REMAINING MAXILLARY BONE

MAXILLARY REHABILITATION OPTIONS

Table 1. Maxillary rehabilitation options

Augmentation of the remaining bone	Utilization of the remaining bone
Sinus floor elevation +/- grafting	Short implants Tuberosity implants
Onlay bone graft	Pterygoid implants
Le Fort 1 osteotomy + bone graft	"All-on-4®" Zygoma implants

A number of techniques have been described to augment maxillary alveolar ridge width and height. In severe 3-dimensional atrophy, these techniques can be combined.

1. Sinus Floor elevation

Sinus floor elevation using the lateral window technique was first described by Tatum over 40 years ago. In this technique, access to the maxillary sinus is obtained via a lateral bone window. The window is elevated and swung upwards and medially whilst being careful to ensure preservation of the sinus membrane (Fig. 5).

A variety of materials can then be utilized to graft the sinus floor including autogenous bone, alloplastic materials as well as carrier devices containing growth factors. If sufficient bone remains for primary stability, then implantation and grafting can be performed simultaneously.

Del Fabbro *et al.*² performed a systematic review of studies of over two thousand patients who underwent

sinus lift surgery and subsequent implantation. Nearly 7000 implants were followed for 12–75 months with an overall survival rate of 92.5%. The highest implant survival rate of 95.9% was reported with the use of non-autogenous grafting materials, compared to 87.7% for autogenous bone.

A graftless procedure where the void under the sinus membrane is filled with a blood clot that enables bone formation has also been described.³

2. Onlay bone graft

Where there is a significant reduction in alveolar crest width, bone can be grafted onto the anterior maxilla. If necessary, this can be done in combination with sinus lifting. The bone can be sourced from a variety of local and regional sites, with the largest available reservoir being the hip (Fig. 6).

Depending on the clinical situation, implantation may be performed simultaneously or alternatively after the graft has healed.

A systematic review of this technique reported a mean survival rate of implants of 87.75%, however a relatively high rate of both donor (10%) and recipient site complications (22%) were reported.⁴ The most significant of these complications occurs if the graft becomes exposed or infected, in which case there may be partial or total loss.

3. Le Fort I osteotomy

In order to address the combination of both an unfavourable intermaxillary relationship along with a lack of bone stock, a Le Fort I osteotomy can be combined with interpositional bone grafting. The maxilla is typically repositioned both forwards and downwards and the graft is secured to both the nasal and sinus floors. Although simultaneous grafting and implantation has been described, it is more commonly performed as a two-stage procedure. Due to the large

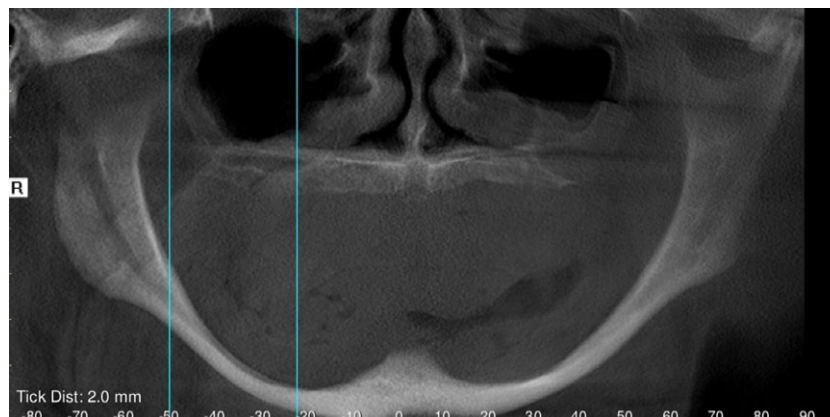


Fig. 2 Extreme mandibular atrophy with exposure of inferior alveolar nerves bilaterally.

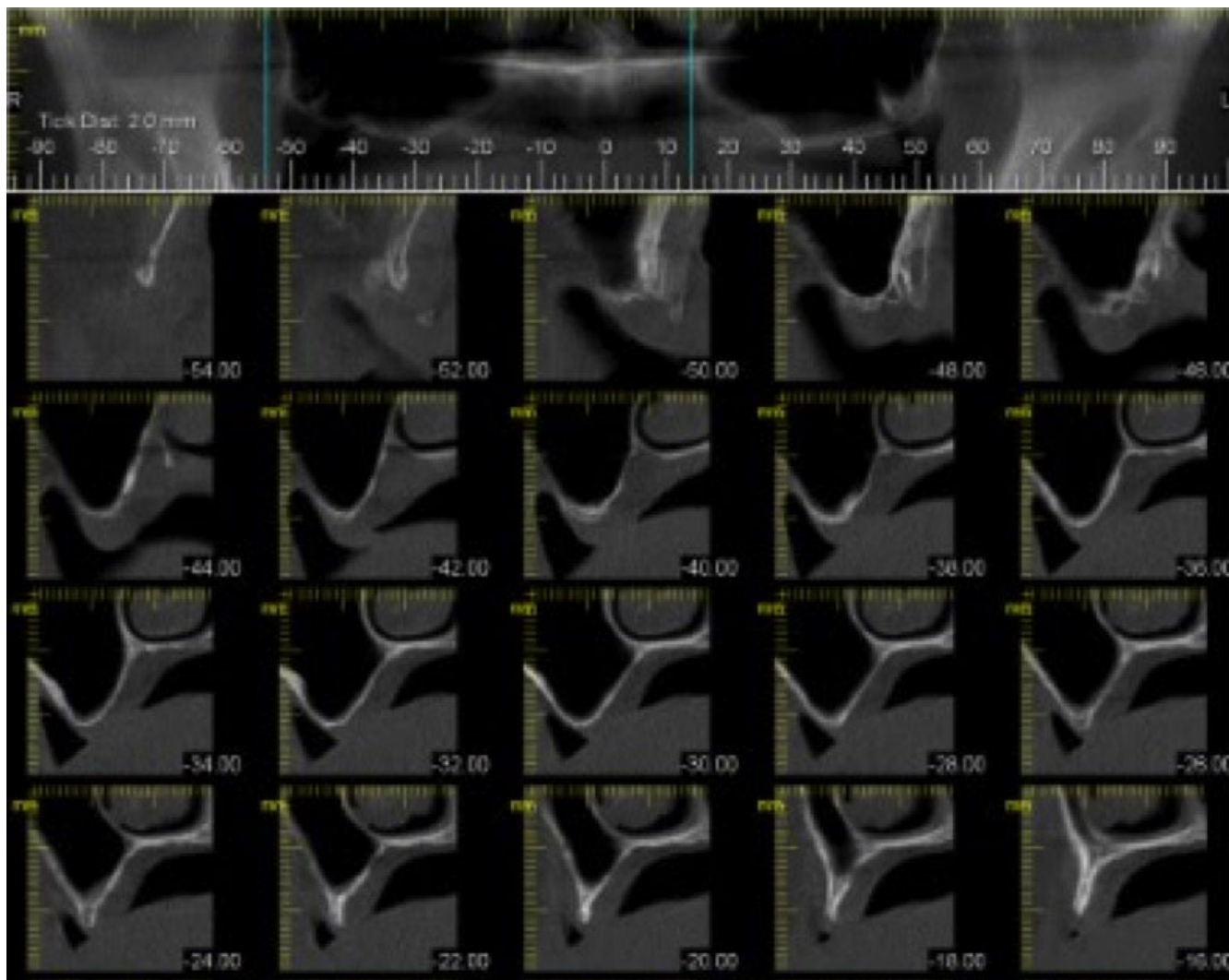


Fig. 3 Cone beam CT of atrophic edentulous maxilla.




Fig. 4 Cone beam slice reveals constriction of mandibular bone not readily apparent when viewing from front on.

amount of bone graft required, the hip is always used as the donor site.

Keller *et al.*⁵ were the first to describe the method in combination with implant treatment in 1987. Nystrom *et al.*,⁶ followed 26 patients with 167 implants for 11–16 years and reported an implant survival rate of 85%. At the end of the follow-up all the patients were still wearing their fixed implant supported

bridges. However, due to the complexity of the procedure a high incidence of complications in both the donor and recipient sites have also been reported.⁴

UTILIZATION OF THE REMAINING MAXILLARY BONE

1. Short implants

Many early studies reported lower success rates with short implants, however with improvements in implant surface technology, this is no longer the case.

Finite element analysis (FEA) confirms that the maximum stress occurs along the top 5–6 mm of an implant, and that implant diameter is more important for stress distribution than length.

If there is adequate alveolar width and a minimum of 5 mm of bone remaining to the maxillary sinus, the use of a short implant may avoid the need for

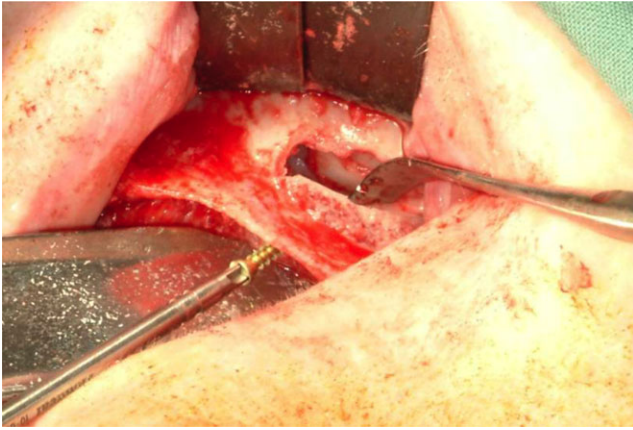


Fig. 5 Sinus floor elevation via lateral window and autogenous block graft.

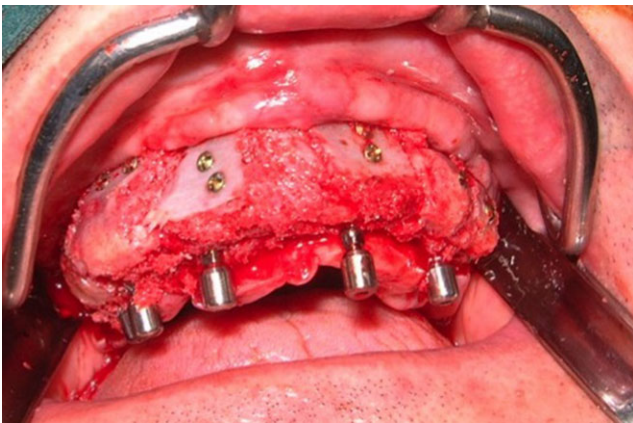


Fig. 6 Multiple autogenous onlay block grafts in combination with temporary implants used to support interim prosthesis during healing period.

bone augmentation. Nisand and Renouard⁷ in 2014 reviewed multiple studies comparing short versus standard-length implants with various vertical augmentation procedures and found similar survival rates. However, the use of short implants resulted in a faster and lower-cost treatment with reduced morbidity. They reported on 29 case series comprising 9780 short implants and found an overall cumulative survival rate of 96.67%.

2. Tuberosity implants

If there is sufficient bone posterior to the sinus cavity, an implant can be placed into the maxillary tuberosity. Lopez *et al.*⁸ reviewed studies following 113 patients with 289 implants and reported an overall survival rate over a period of 6–144 months of 94.63%. Due to the prevalence of Type III and IV bone in this region, none of the studies reviewed reported immediate load or function of the fixtures. An experienced surgeon with knowledge of the

anatomy, paying particular attention to the greater palatine artery, should perform implant placement in this region.

3. Pterygoid implants

A pterygoid implant is anchored in the pterygoid plate of the sphenoid bone, through the maxillary and palatine bones with an angulation of between 35° and 55° and a length of 10–20 mm. In a review of studies reporting on a total of 1053 pterygoid implants in 676 patients, Candell *et al.*⁹ reported a success rate of 90.7%. Pterygoid implants may have an advantage over tuberosity implants as they engage dense cortical bone, however they may be difficult to restore due to their posterior location, and the patient must have a minimum of 35 mm of mouth opening. Unfortunately the review article does not contain any information as to whether any of the implants studied were immediately loaded.

4. 'All-on-4®'

Contemporary maxillary 'All-on-4®' evolved from the original 1977 work of Branemark in which 4–6 vertically orientated implants were placed into the pre-maxilla, however in many cases this resulted in a too long distal cantilever. In order to overcome this problem, Matteson *et al.*¹⁰ in 1999, described a modification of the technique in which the posterior implants were placed at an angle parallel to the anterior wall of the maxillary sinus.

The concept of 'All-on-4®' immediate function was developed by Malo *et al.*¹¹ in 2003 and first applied to the mandible. Subsequently in 2005, he utilised the same principle in the maxilla.

A recent comprehensive article by Chan and Holmes¹² confirms the high success rate of the technique as reported by various independent authors (95.2–100%) with follow up between 1–7 years.

Currently this technique employs 4 implants: two straight anterior fixtures are combined with two distal fixtures which are tilted posteriorly and, placed anterior to the maxillary sinuses. The implants are inserted at a torque of >35 Ncm and are immediately restored. Implant placement can be performed via a conventional open surgical procedure or alternatively as a guided one by using the NobelClinician™ Software and NobelGuide® Surgical Template (Nobel Biocare AB, Zurich-Flughafen, Switzerland).

An interesting variation of the standard technique that shows promise, has been described by Jensen *et al.*¹³ for use in those patients that have significant mesial pneumatization of the sinus cavities, but adequate bone stock remaining anteriorly. In these cases trans-sinus placement of the tilted implants in

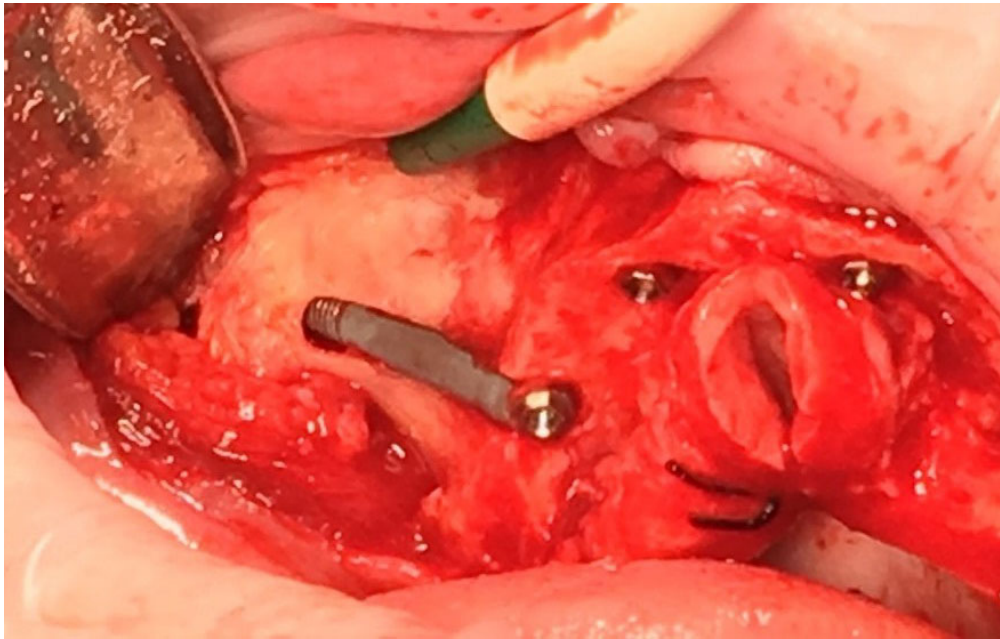


Fig. 7 Extra maxillary zygoma implant.

combination with bone morphogenetic protein 2 grafting of the sinus floor was performed. Of the 19 trans-sinus implants placed, 18 remained integrated at the 1-year follow-up. This was presented as an alternative treatment strategy to zygoma implants.

As maxillary atrophy progresses, there may be insufficient bone remaining for standard 'All-on-4[®]' or any of its variants, and in these cases, zygoma implants may be required.

5. Zygoma implants

The use of long implants to engage the bone stock within the zygoma was first described by Branemark¹⁴ in 1998. The original technique utilised bilateral zygoma implants in combination with four conventional dental implants in the anterior maxilla. The technique has since undergone several modifications. Following the 'All-on-4[®]' concept, two zygoma fixtures are now combined with two conventional implants, and in cases where there is insufficient anterior maxillary bone, four zygoma fixtures are placed (quad zygoma). As with conventional 'All-on-4[®]', the fixtures are placed into immediate function and the surgery can be performed as a conventional or guided procedure. Variations in zygoma placement surgery have been described. In the original Branemark technique, the fixtures entered the sinus cavity from a more palatal position. One of the criticisms of this method of placement was that the head of the fixture was placed too far towards the palate leading to a bulky prosthesis, which was difficult to clean.

In an attempt to address this problem, Malo¹⁵ both redesigned the zygoma implant (by narrowing the tip and removing the coronal threads) and developed the extramaxillary approach in which a channel is cut along the lateral wall of the maxilla, the sinus membrane is preserved and elevated and the implant is inset. By using this technique, the fixture head is positioned in a more prosthetically ideal position back towards the residual alveolar crest (Fig. 7).

In recent review article by Chranovic *et al.*,¹⁶ 4,556 zygoma implants were followed in 2,161 patients. The twelve-year cumulative survival rate was 95.21%, with most failures (103), occurring within the 6-month postsurgical period. Reported complications in order of prevalence were: sinusitis, soft tissue infection, paraesthesia, and oro-antral fistula.

Following the principle that four implants provide enough support for a full arch fixed prosthesis, a mixture of 'All-on-4[®]' and zygoma implants can be placed.

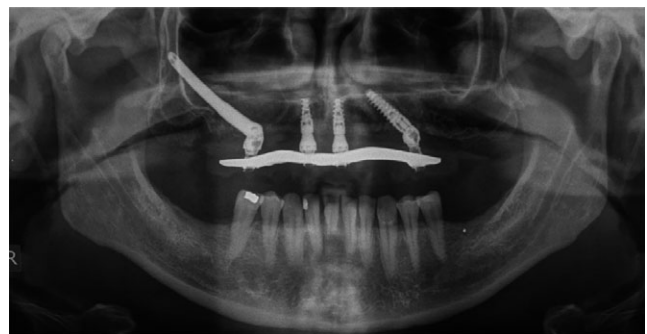

Fig. 8 Hybrid case 'All-on-4[®]' and zygoma implants.

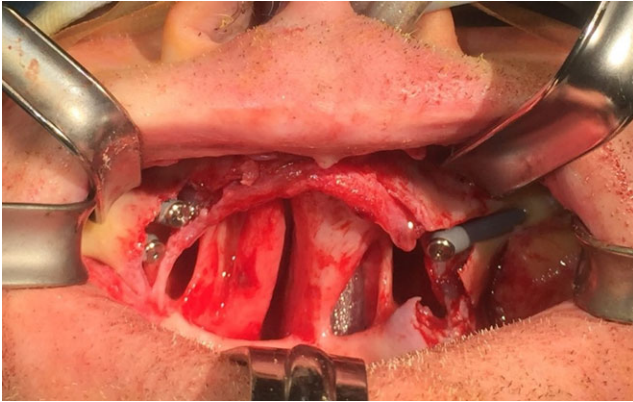


Fig. 9 Three zygoma implants placed to support an obturator in a total maxillectomy patient.

In this way, the surgeon can tailor the surgical procedure so the implants selected can make the most efficient use of the available bone stock (Fig. 8).

The versatility of zygoma implants can also be demonstrated in a variety of other clinical scenarios. For example they can be used as a ‘rescue procedure’ when failure of one or more implants occurs in an ‘All-on-4®’. In these cases the failed implant removal and the zygoma implant placement occur simultaneously. The zygoma implant is placed into immediate function as it is integrated into the existing fixed prosthesis, thus avoiding the need for the patient to wear an interim removable denture.

Zygoma implants may also be utilised to stabilise an obturator in post-maxillectomy cancer patients where the resultant defect and distorted anatomy make the wearing of a prosthesis difficult (Fig. 9).

MANDIBULAR REHABILITATION OPTIONS

Table 2. Mandibular rehabilitation options

Augmentation of the remaining bone	Utilization of the remaining bone
Bone grafting Distraction osteogenesis	Short implants Nerve repositioning “All-on-4®”

AUGMENTATION OF THE REMAINING BONE

1. Bone grafting

Block¹⁷ provides an excellent description of both the history and the variety of procedures that can be performed to augment the atrophic mandible.

Either onlay grafting or inlay ‘sandwich’ bone grafting can be performed. Grafts include corticocancellous blocks placed via intra or extra oral incisions, particulate material with membrane coverage, or

combinations of the two. The most common complications with onlay grafting are graft resorption and incisional dehiscence and graft exposure, and if this occurs some or all of the graft may be lost. Inlay grafting also has some limitations. It corrects only vertical, not horizontal defects, and the amount of vertical gain is anatomically limited to the stretch of the soft tissues attached to the superior bony segment.

2. Distraction osteogenesis

First described in 1996,¹⁸ vertical distraction osteogenesis (VDO), can be applied to either the posterior or the anterior mandible. It may have advantages over grafting procedures as there is no donor site morbidity and it may allow a greater vertical gain in bone height as the distraction process augments both hard and soft tissues. In the atrophic edentulous mandible there is seldom enough bone remaining above the inferior alveolar nerve to allow for posterior distraction. Most reported cases therefore discuss anterior distraction where a horizontal osteotomy is performed anterior to the inferior alveolar nerves. A distraction device is secured to the bone and after a latency period of 7 days, the superior bone block (transport segment) is then distracted by up to 1 mm per day.

From a review of the literature there appears to be an unacceptably high rate of reported complications (43.2–79.31%).¹⁹ These include breakage of distraction device, fracture of the transport segment or mandible, inferior alveolar nerve injury, and lingual tilting of the transport segment. Survival rates for implants placed into distracted bone are similar to those reported for cases using other methods to augment the bone.

UTILISATION OF THE REMAINING BONE

1. Short implants

For atrophic mandibles, it is the posterior segment distal to the mental foramen that poses the greatest challenge. The rationale for placing a short implant in this region is to avoid the need for additional surgical procedures and their associated risks and additional cost. At the site of implantation there must be adequate width, and the residual bone height above the nerve canal needs to be at least 8 mm (6 mm implant + 2 mm safety zone).

2. Nerve repositioning

Nerve repositioning is one of the methods available to allow implant placement in the posterior mandible of patients who do not have sufficient bone height above the nerve for conventional implant placement.

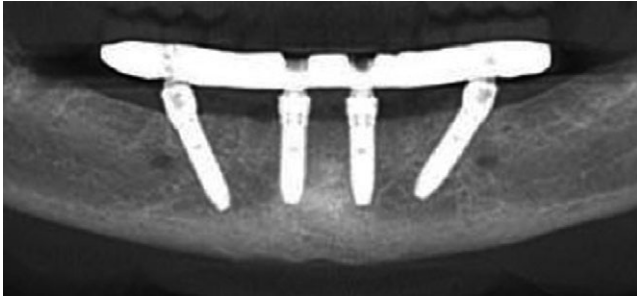


Fig. 10 Standard mandibular 'All-on-4[®]'.

It may be performed by either lateralization or transposition. In lateralization the nerve is exposed and retracted laterally during implant placement, then released to rest against the implants. In transposition, the mental foramen is included in the osteotomy, to allow the nerve to be pulled into a completely new, more posterior position.

Vetromilla *et al.*²⁰ reviewed studies reporting on both methods of nerve repositioning. Permanent neurosensory disturbance was noted in 3.4% of patients who underwent lateralisation, and 22.1% of patients who underwent transposition. The use of Piezoelectric devices may lead to a lower risk of injury, as compared to standard rotary devices, however this requires further study.

The success rate of the lateralisation regarding implant osseointegration was reported to be between 93.8% and 100%.

3. 'All-on-4[®]'

In mandibular 'All-on-4[®]', the fixtures are placed into the parasymphiseal region, with the distal implants tilted to both avoid the anterior loop of the inferior alveolar nerve, and to minimise the distal cantilever (Fig. 10). As with maxillary cases, implants are inserted with a torque of 35Ncm or greater to allow for immediate loading.

Malo *et al.*²¹ followed 324 patients for 7 years clinically and 5 years radiographically. In all cases the implants supported a full-arch immediately loaded mandibular prosthesis. The reported Implant survival rate was 95.4% and mean marginal bone loss 1.81 mm.

In some cases the degree of mandibular atrophy is so severe that 'All-on-4[®]' can pose an unacceptable risk of jaw fracture. If the patient is unwilling or unable to undergo an adjunctive procedure to allow implantation, the provision of a fixed implant retained prosthesis may not be possible. In these cases, the placement of two implants into the parasymphiseal region as the basis for an implant retained overdenture should be considered as a viable treatment alternative. Retention, stability and chewing ability can all still be improved

and multiple studies have shown both excellent long-term prosthetic and implant survival rates, along with high levels of patient satisfaction.²²

DISCUSSION

The ultimate goal of implant placement is to generate long-lasting anchorage in the best possible position for a functionally and aesthetically optimal prosthetic solution.²³ However, implant placement in atrophic edentulous jaws can pose a significant treatment challenge, as there is often both a lack of bone, and an unfavourable anatomy of the bone that remains. The clinician should be aware of the outcomes of different treatment options in order to be able to critically assess the best option for each clinical situation. A variety of different treatment strategies have been presented for use in those patients seeking a fixed implant based solution. Over the last decade, patient driven demand for an immediate single stage treatment with low morbidity has seen a significant increase in 'graftless' procedures such as 'All-on-4[®]', and now longer term data is available in the literature to support the validity of these approaches. There is also good long-term clinical data supporting the use of shorter implants as well as traditional grafting procedures such as sinus lifting and onlay grafting. However, due to the high reported complication rates, nerve repositioning and distraction osteogenesis cannot be recommended.

REFERENCES

1. Cawood JI, Howell RA. A classification of the edentulous jaws. *Int J Oral Maxillofac Surg* 1988;17:232–236.
2. Del Fabbro M, Testori T, Francetti L, *et al.* Systematic review of survival rates for implants placed in the grafted maxillary sinus. *Int J Periodont Rest Dent* 2004;24:565.
3. Riben C, Thor A. The maxillary sinus membrane elevation procedure: augmentation of bone around dental implants without grafts - A review of a surgical technique. *Int J Dent* 2012;2012:105483.
4. Milinkovic I, Cordaro L. Are there specific indications for the different alveolar bone augmentation procedures for implant placement? A systematic review. *Int J Oral Maxillofac Surg* 2014;43:606–625.
5. Keller E, Van Roekel NB, Desjardins RP, Tolman DE. Prosthetic-surgical reconstruction of the severely resorbed maxilla with iliac bone grafting and tissue-integrated prosthesis. *Int J Oral Maxillofac Implants* 1987;2:155–165.
6. Nystrom E, Nilson H, Gunne J, Lundgren S. Reconstruction of the atrophic maxilla with interpositional bone grafting/Le Fort I osteotomy and endosteal implants: a 11-16 year follow-up. *Int J Oral Maxillofac Surg* 2009;38:1–6.
7. Nisand D, Renouard F. Short implants in limited bone volume. *Periodontol* 2000 2014;66:72–96.
8. Lopes L, da Silva VF, Santiago JF Jr, Panzarini SR, Pellizzer EP. Placement of dental implants in the maxillary tuberosity: a systematic review. *Int J Oral Maxillofac Surg* 2015;44:229–238.

9. Candel E, Penarrocha D, Peñarrocha M. Rehabilitation of the atrophic posterior maxilla with pterygoid implants: a review. *J Oral Implantol* 2012;38:461–466.
10. Mattsson T, Köndell PA, Gynther GW, Fredholm U, Bolin A, . Implant treatment without bone grafting in severely resorbed edentulous maxillae. *J Oral Maxillofac Surg* 1999;57:281–287.
11. Malo P, Rangert B, Nobre M. ‘All-on-4’ immediate function concept with Branemark System Implants for completely edentulous mandibles: a retrospective clinical study. *Clin Implant Dent Relat Res* 2003;5:2–9.
12. Chan MH, Holmes C. Contemporary, ‘All-on-4’ Concept. *Dent Clin North Am* 2015;59:421–470.
13. Jensen OT, Cottam J, Ringeman J, Adams M. Trans-sinus dental implants, bone morphogenetic protein 2, and immediate function for All-on-4 treatment of severe maxillary atrophy. *J Oral Maxillofac Surg* 2012;70:141–148.
14. Branemark P-I. Surgery and fixture installation: zygomaticus fixture clinical procedures. 1st edn. Göteborg, Sweden: Nobel Biocare AB, 1998.
15. Malo P, Nobre M, Lopes I. A new approach to rehabilitate the severely atrophic maxilla using extramaxillary anchored implants in immediate function: a pilot study. *J Prosthet Dent* 2008;100:354–366.
16. Chrcanovic B, Albrektsson T, Wennerberg A. Survival and complications of zygomatic implants: an updated systematic review. *J Oral Maxillofac Surg* 2016;74:1949–1964.
17. Block MS. Color atlas of dental implant surgery, 3rd edn. Philadelphia: Saunders, 2010.
18. Chin M, Toth BA. Distraction osteogenesis in maxillofacial surgery using internal devices: review of five cases. *J Oral Maxillofac Surg* 1996;54:45–53.
19. Ugurlu F, Sener BC, Dergin G, Garip H. Potential complications and precautions in vertical distraction osteogenesis: a retrospective study of 40 patients. *J Craniomaxillofac Surg* 2013;41:569–573.
20. Vetromilla BM, Moura LB, Sonogo CL, Torriani MA, Chagas OL Jr. Complications associated with inferior alveolar nerve repositioning for dental implant placement: a systematic review. *Int J Oral Maxillofac Surg* 2014;43:1360–1366.
21. Malo P, de Araújo Nobre M, Lopes A, Ferro A, Gravito I. All-on-4 treatment concept for the rehabilitation of the completely edentulous mandible: a 7-year clinical and 5-year radiographic retrospective case series with risk assessment for implant failure and marginal bone level. *Clin Implant Dent Relat Res* 2015;17 (Suppl 2):531–541.
22. Sadowsky J, Hansen P. Evidence based criteria for differential treatment planning of implant restorations for the mandibular edentulous patient. *J Prosthodont* 2014;23:104–111.
23. Sennerby L. Dental implants: matters of course and controversies. *Periodontol* 2000 2008;47:9.

Address for correspondence:

Kevin Spencer

5th Floor 766 Elizabeth St

Melbourne, Vic. 3000

Australia

Email: spencerpa@omfs.com.au