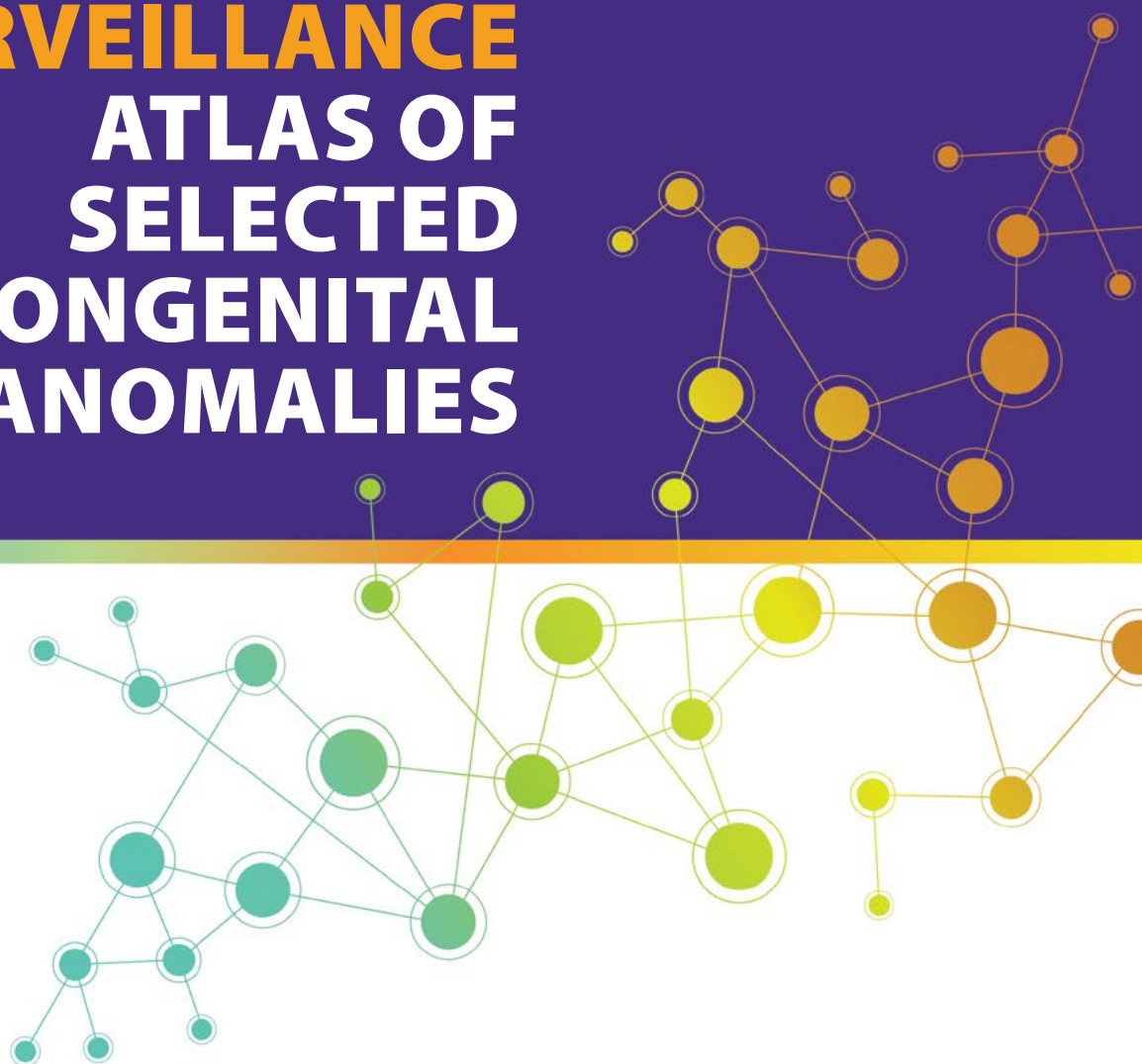


BIRTH DEFECTS SURVEILLANCE ATLAS OF SELECTED CONGENITAL ANOMALIES



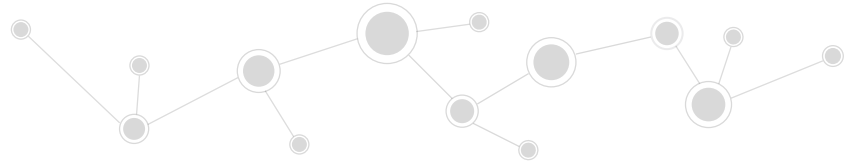
World Health
Organization



International Clearinghouse for Birth Defects
Surveillance and Research

**BIRTH DEFECTS
SURVEILLANCE**

**ATLAS OF
SELECTED
CONGENITAL
ANOMALIES**



WHO Library Cataloguing-in-Publication Data

Birth defects surveillance: atlas of selected congenital anomalies

1. Congenital Abnormalities. 2. Neural Tube Defects. 3. Public Health Surveillance. 4. Atlases. I. World Health Organization. II. Centers for Disease Control and Prevention (U.S.). III. International Clearinghouse for Birth Defects Monitoring Systems.

ISBN 978 92 4 156476 2

NLM classification: QS 675

© World Health Organization 2014

All rights reserved. Publications of the World Health Organization are available on the WHO web site (www.who.int) or can be purchased from WHO Press, World Health Organization, 20 Avenue Appia, 1211 Geneva 27, Switzerland (tel.: +41 22 791 3264; fax: +41 22 791 4857; e-mail: bookorders@who.int).

Requests for permission to reproduce or translate WHO publications –whether for sale or for non-commercial distribution– should be addressed to WHO Press through the WHO web site (www.who.int/about/licensing/copyright_form/en/index.html).

The designations employed and the presentation of the material in this publication do not imply the expression of any opinion whatsoever on the part of the World Health Organization concerning the legal status of any country, territory, city or area or of its authorities, or concerning the delimitation of its frontiers or boundaries. Dotted lines on maps represent approximate border lines for which there may not yet be full agreement.

The mention of specific companies or of certain manufacturers' products does not imply that they are endorsed or recommended by the World Health Organization in preference to others of a similar nature that are not mentioned. Errors and omissions excepted, the names of proprietary products are distinguished by initial capital letters.

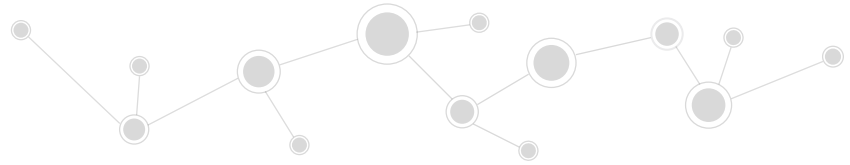
All reasonable precautions have been taken by the World Health Organization to verify the information contained in this publication. However, the published material is being distributed without warranty of any kind, either expressed or implied. The responsibility for the interpretation and use of the material lies with the reader. In no event shall the World Health Organization be liable for damages arising from its use.

The named authors alone are responsible for the views expressed in this publication.

Design and layout: Alberto March

Suggested citation

WHO/CDC/ICBDSR. Birth defects surveillance: atlas of selected congenital anomalies. Geneva: World Health Organization; 2014.



Acknowledgements

This atlas is a collaborative effort between the World Health Organization (WHO), the National Center on Birth Defects and Developmental Disabilities (NCBDDD) from the US Centers for Disease Control and Prevention (CDC), and the International Clearinghouse for Birth Defects Surveillance and Research (ICBDSR).

We would like to acknowledge the technical input in the preparation of this atlas of staff from NCBDDD, ICBDSR and WHO, particularly, from the following individuals (in alphabetical order): Mr James K Archer, Dr Jose F Arenas, Dr Alejandro Azofeifa, Dr Robert J Berry, Dr Lorenzo Botto, Dr Marie Noel Brune Drisse, Dr Luz Maria De-Regil, Ms Alissa Eckert, Ms Alina Flores, Dr Jaime Frías, Mr Dan J Higgins, Dr Margaret Honein, Ms Jennifer Hulse, Ms Christina Kilgo, Dr Pierpaolo Mastroiacovo, Dr Cynthia Moore, Dr Joseph Mulinare, Dr Teresa Murguia de Sierra, Dr Maria Neira, Dr Richard Olney, Dr Juan Pablo Peña-Rosas, Dr. Hilda Razzaghi, Dr Lisa Rogers, Dr Jorge Rosenthal, Dr Csaba Siffel, Dr Joseph Sniezek, Ms Diana Valencia, Dr Claudia Vellozzi and Ms Jennifer Williams. We would also like to thank all collaborators and partners for helping us develop illustrations and obtain photographs for this birth defects surveillance atlas.

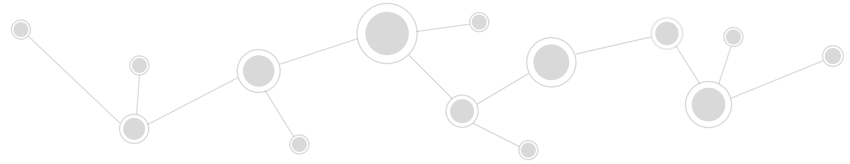
The drawings were all supplied by CDC/NCBDDD.

We would also like to thank Dr Rajesh Mehta and Dr Neena Raina from the WHO Regional Office for South-East Asia, for providing valuable feedback during the development process.

WHO, CDC and ICBDSR gratefully acknowledge the technical input of the meeting participants for the regional training on surveillance of birth defects.

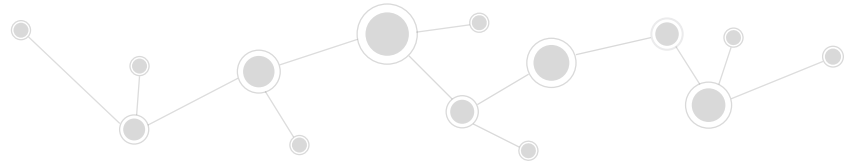
Financial support

WHO thanks the US CDC, especially the National Center on Birth Defects and Developmental Disabilities, for providing financial support for the publication of this atlas as part of the cooperative agreement 5 E11 DP002196, *Global prevention of non-communicable diseases and promotion of health*.

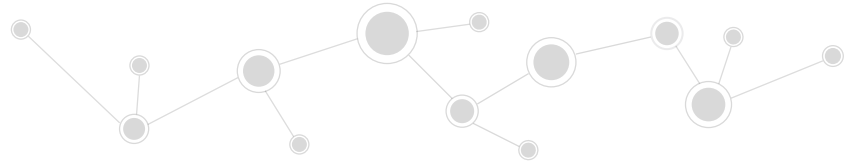


Contents

Abbreviations	vi
Objectives of the atlas	1
Congenital malformations of the nervous system: neural tube defects	2
Anencephaly (Q00.0)	4
Craniorachischisis (Q00.1)	4
Iniencephaly (Q00.2)	5
Frontal encephalocele (Q01.0)	6
Nasofrontal encephalocele (Q01.1)	6
Occipital encephalocele (Q01.2)	6
Parietal encephalocele (Q01.80)	7
Orbital encephalocele (Q01.81)	7
Nasal encephalocele (Q01.82)	7
Cervical spina bifida	8
Cervical spina bifida with hydrocephalus (Q05.0)	9
Cervical spina bifida without hydrocephalus (Q05.5)	9
Thoracic spina bifida	10
Thoracic spina bifida with hydrocephalus ((Q05.1)	11
Thoracic spina bifida without hydrocephalus (Q05.6)	11
Lumbar spina bifida	12
Lumbar spina bifida with hydrocephalus (Q05.2)	13
Lumbar spina bifida without hydrocephalus (Q05.7)	13
Sacral spina bifida	14
Sacral spina bifida with hydrocephalus (Q05.3)	15
Sacral spina bifida without hydrocephalus (Q05.8)	15
Cleft palate and cleft lip	16
Cleft palate (Q35.5)	16
Cleft lip, bilateral (Q36.0)	16
Cleft lip, specified as unilateral (Q36.9, Q36.90)	16
Cleft hard palate with bilateral cleft lip (Q37.0)	17
Cleft hard palate with cleft lip, specified as unilateral (Q37.10)	17
Congenital malformations of genital organs	18
Hypospadias (Q54, Q54.0, Q54.1, Q54.2, Q54.3, Q54.8, Q54.9)	18

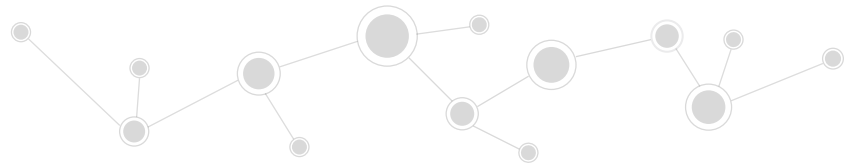


Congenital malformations and deformations of the musculoskeletal system	19
Talipes equinovarus (Q66.0)	19
Reduction defects of upper and lower limbs	19
Congenital complete absence of upper limb(s); amelia of upper limb (Q71.0)	19
Congenital absence of upper arm and forearm with hand present; phocomelia of upper limb (Q71.1)	20
Congenital absence of both forearm and hand (Q71.2)	20
Congenital absence of hand and finger(s) (Q71.3)	20
Congenital absence of finger(s) (remainder of hand intact) (Q71.30)	21
Absence or hypoplasia of thumb (other digits intact) (Q71.31)	21
Longitudinal reduction defect of radius: clubhand (congenital), radial clubhand, absence of radius (Q71.4)	22
Longitudinal reduction defect of ulna (Q71.5)	22
Split hand (congenital cleft hand) (Q71.6)	23
Congenital complete absence of lower limb(s); amelia of lower limb (Q72.0)	23
Congenital absence of thigh and lower leg with foot present; phocomelia of lower limb (Q72.1)	23
Congenital absence of both lower leg and foot (Q72.2)	24
Congenital absence of foot and toe(s) (Q72.3)	24
Congenital absence or hypoplasia of toe(s) with remainder of foot intact (Q72.30)	24
Absence or hypoplasia of first toe with other digits present (Q72.31)	25
Longitudinal reduction defect of femur (Q72.4)	25
Longitudinal reduction defect of tibia (Q72.5)	25
Longitudinal reduction defect of fibula; fibular aplasia/hypoplasia (Q72.6)	26
Split foot (congenital cleft foot) (Q72.7)	26
Exomphalos/omphalocele (Q79.2)	27
Gastroschisis (Q79.3)	28



● Abbreviations

CDC	United States Centers for Disease Control and Prevention
ICBDSR	International Clearinghouse for Birth Defects Surveillance and Research
ICD-10	<i>International statistical classification of diseases and related health problems, 10th revision</i>
NCBDDD	National Center on Birth Defects and Developmental Disabilities
RCPCH	Royal College of Paediatrics and Child Health
USA	United States of America
WHO	World Health Organization



● Objectives of the atlas

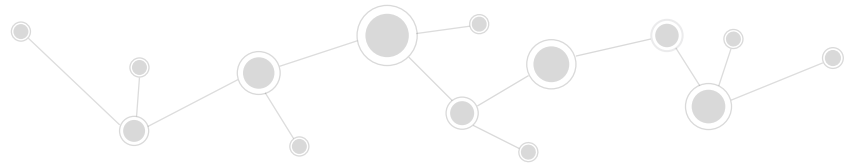
Congenital anomalies, also known as birth defects, are structural or functional abnormalities, including metabolic disorders, that are present from birth. Congenital anomalies are a diverse group of disorders of prenatal origin that can be caused by single gene defects, chromosomal disorders, multifactorial inheritance, environmental teratogens or micronutrient malnutrition.

This *Atlas of selected congenital anomalies* is a companion tool to *Birth defects surveillance: a manual for programme managers*, and is intended to help in the development, implementation and ongoing improvement of a surveillance programme for congenital anomalies, particularly in countries with limited human and financial resources.

This atlas uses the *International statistical classification of diseases and related health problems*, 10th revision (ICD-10) and the Royal College of Paediatrics and Child Health (RCPCH) extension for coding of congenital anomalies.

It provides selected illustrations and photographs of congenital anomalies that are severe enough to have a high probability of being captured during the first few days following birth. Also, because of their severity and frequency, these depicted conditions have significant public health impact, and for some there is a potential for primary prevention. When used in conjunction with the manual, the illustrations and photographs will help the reader to:

- identify an initial list of congenital anomalies to consider for monitoring;
- describe the tools needed to define and code identified cases;
- define specific congenital anomalies under surveillance.



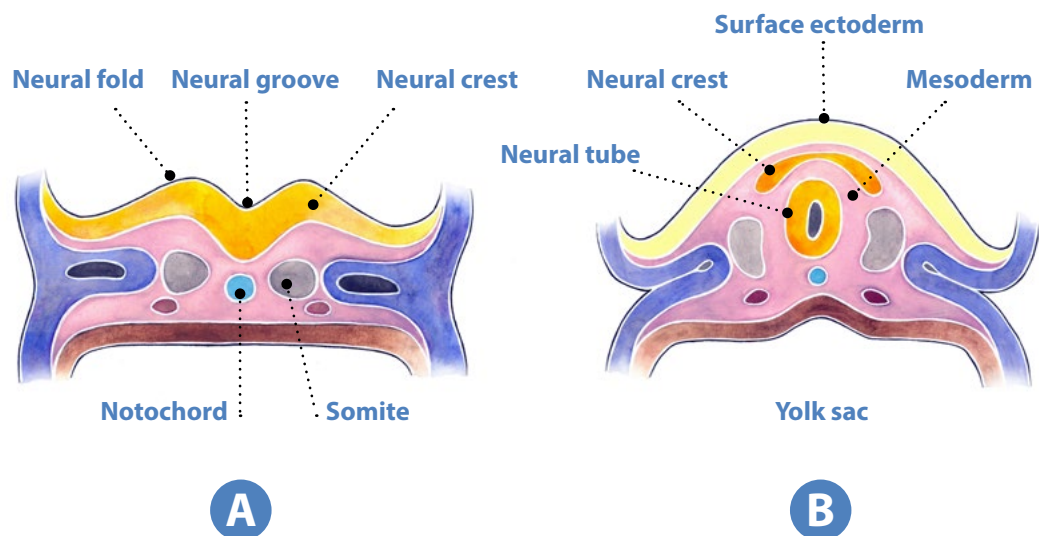
Congenital malformations of the nervous system: neural tube defects

Neural tube defects affect the brain and spinal cord, and are among the most common of the congenital anomalies (see Fig. 4.1). Panel A shows a cross section of the rostral end of the embryo at approximately three weeks after conception, showing the neural groove in the process of closing, overlying the notochord. The neural folds are the rising margins of the neural tube, topped by the neural crest, and demarcate the neural groove centrally. Panel B shows a cross section of the middle portion of the embryo after the neural tube has closed. The neural tube, which will ultimately develop into the spinal cord, is now covered by surface ectoderm (later, the skin). The intervening mesoderm will form the bony spine. The notochord is regressing. Panel C shows the developmental and clinical features of the main types of neural tube defects. The diagram in the centre is a dorsal view of a developing embryo, showing a neural tube that is closed in the centre but still open at the cranial and caudal ends. The dotted lines marked A and B refer to the cross sections shown in Panels A and B. Shaded bars point to the region of the neural tube relevant to each defect.

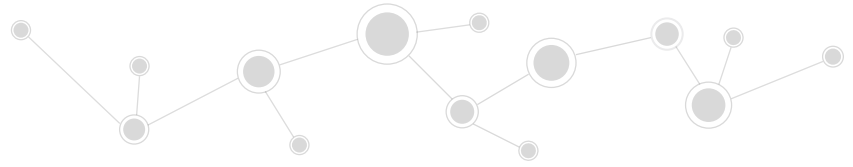
In anencephaly, the absence of the brain and calvaria can be total or partial. Craniorachischisis is characterized by anencephaly accompanied by a contiguous bony defect of the spine and exposure of neural tissue. In open spina bifida, a bony defect of the posterior vertebral arches (in this case, the lower thoracic vertebrae) is accompanied by herniation of neural tissue and meninges and is not covered by skin. In iniencephaly, dysraphia in the occipital region is accompanied by severe retroflexion of the neck and trunk. In encephalocele, the brain and meninges herniate through a defect in the calvaria. In closed spina bifida, unlike open spina bifida, the bony defect of the posterior vertebral arches (in this case, the lumbar vertebrae), the herniated meninges, and neural tissue are covered by skin.

The most prevalent types of neural tube defects are anencephaly, encephalocele and spina bifida.

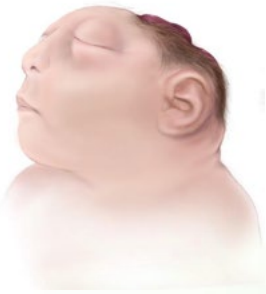Fig. 4.1. Neural tube defects



Source: adapted, with permission from the publisher, from Botto et al. *N. Engl. J. Med.* 1999;341:1509–19.



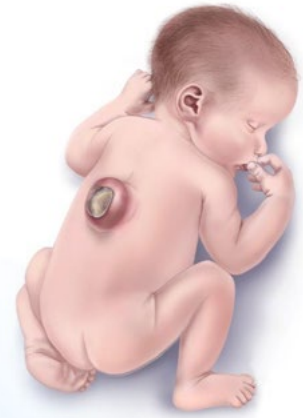Anencephaly



Craniorachischisis



Open spina bifida



Cranial neuropore

A

B

Caudal neuropore

Neural fold

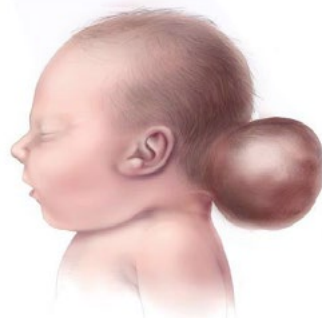C

Somite

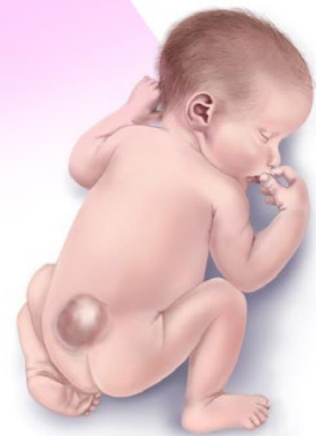Neural groove



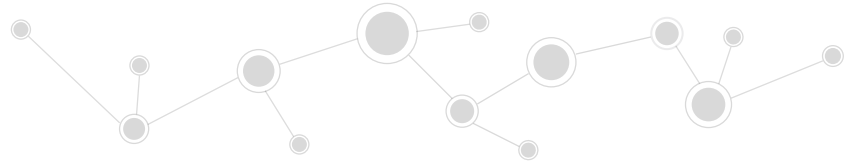
Iniencephaly



Encephalocele

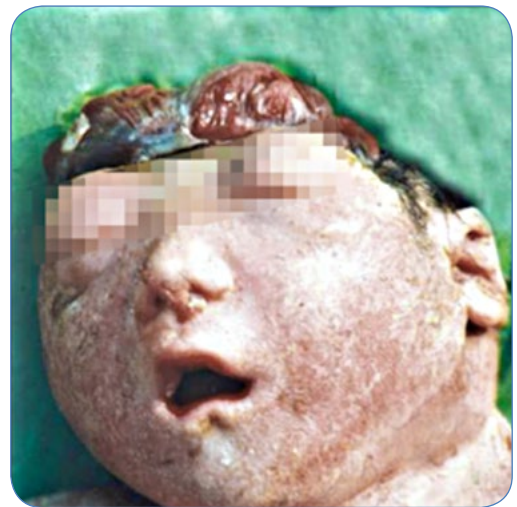
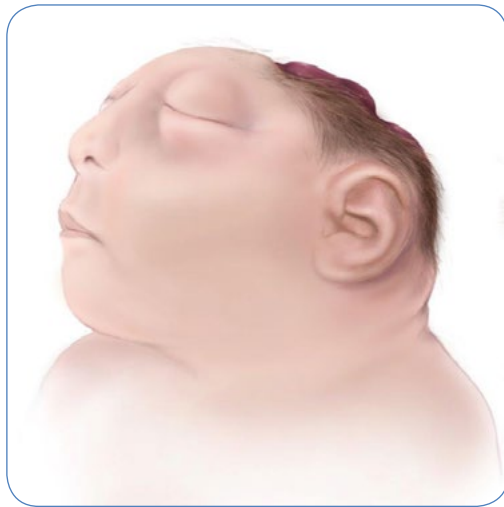
Closed spina bifida



Anencephaly (Q00.0)

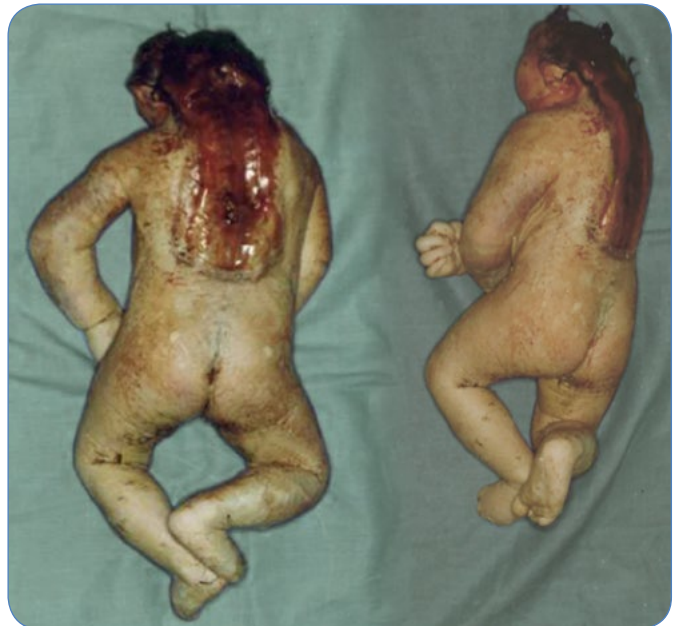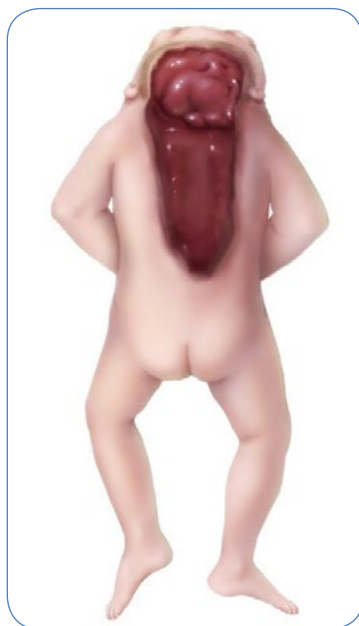A total or partial absence of the brain, together with total or partial absence of the cranial vault and the covering skin.



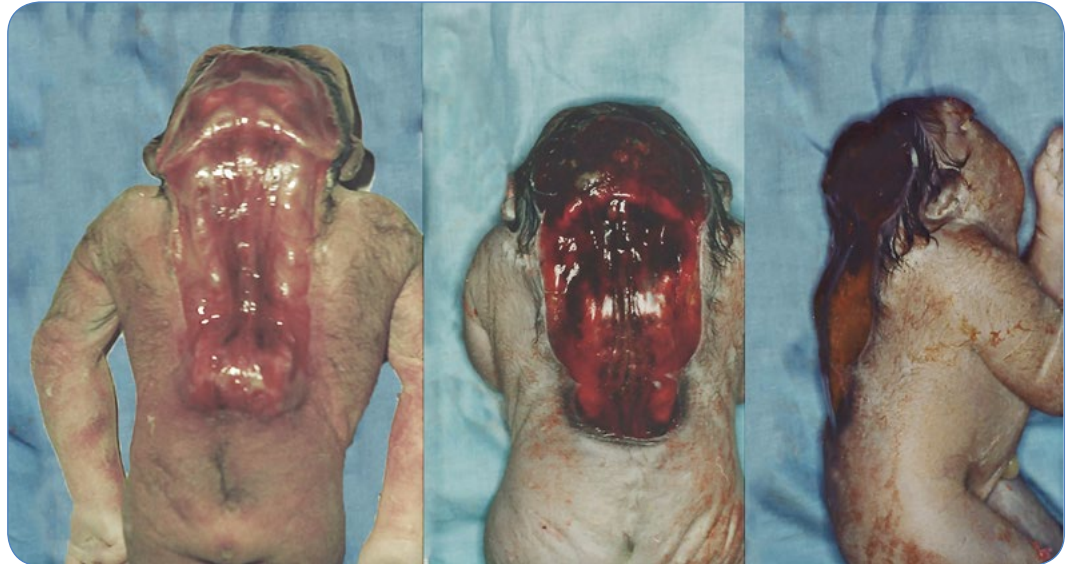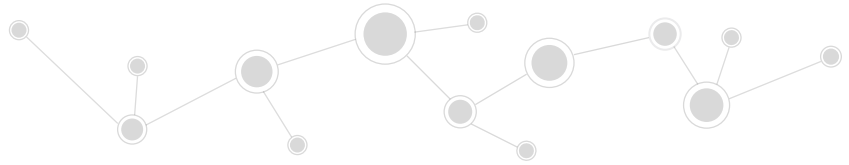
Photograph source: courtesy of CDC-Beijing Medical University collaborative project.

Craniorachischisis (Q00.1)

The presence of anencephaly with a contiguous spine defect without meninges covering the neural tissue (rachischisis).



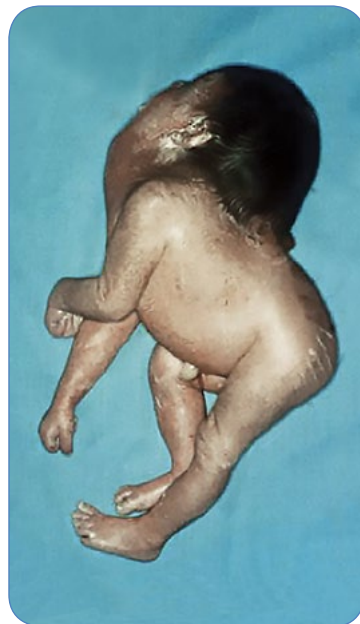

Photograph source: courtesy of CDC-Beijing Medical University collaborative project.



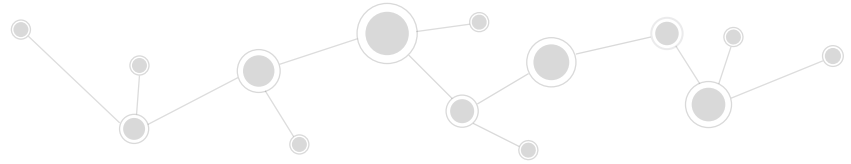
Photographs
source: courtesy
of CDC-Beijing
Medical University
collaborative project.

Iniencephaly (Q00.2)

A rare and complex neural tube defect characterized by extreme retroflexion of the head, variably combined with rachischisis of the cervical and thoracic spine and, more rarely, with occipital encephalocele. In iniencephaly, the cranium is always closed.



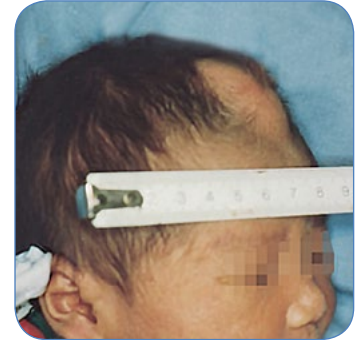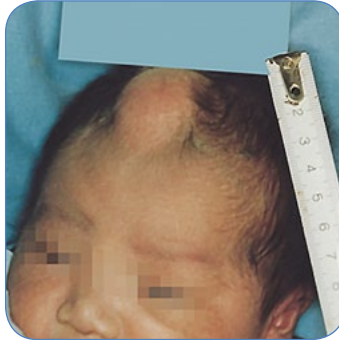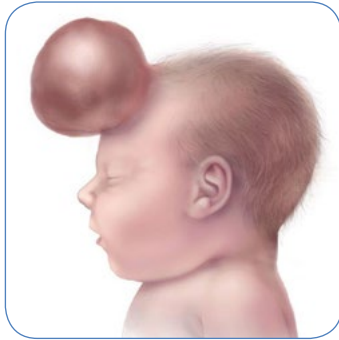Photograph
source: courtesy
of CDC-Beijing
Medical University
collaborative project.



Frontal encephalocele (Q01.0)

Herniation of brain tissue, usually covered by meninges, through a defect in the frontal bone.

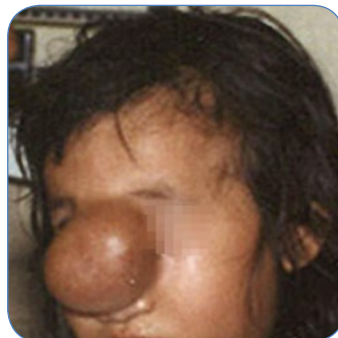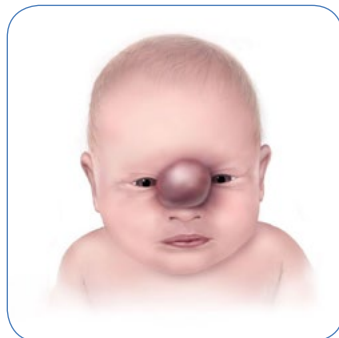Photographs
source: courtesy
of CDC-Beijing
Medical University
collaborative
project.



Nasofrontal encephalocele (Q01.1)

Herniation of brain tissue, usually covered by meninges, through an opening between the frontal bone and the nasal and ethmoid bones.

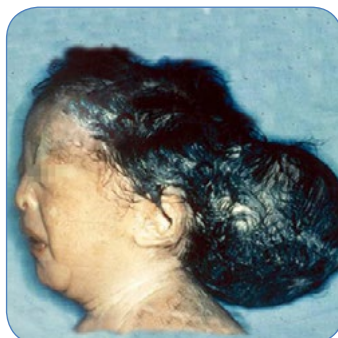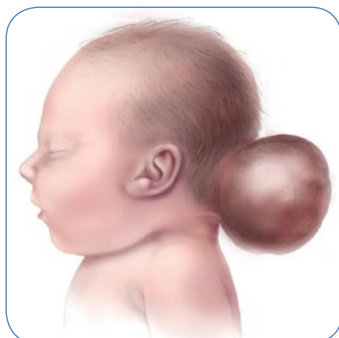Photograph source:
courtesy of Jaime
Frias, MD, USA.

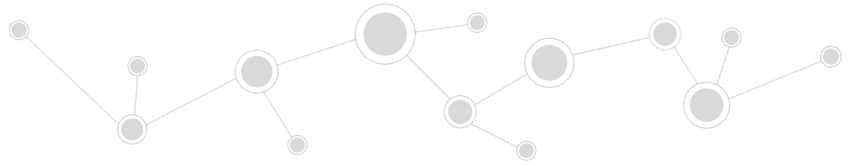


Occipital encephalocele (Q01.2)

Herniation of brain tissue, usually covered by meninges, through an opening in the occipital bone.

Photograph
source: courtesy
of CDC-Beijing
Medical University
collaborative
project.

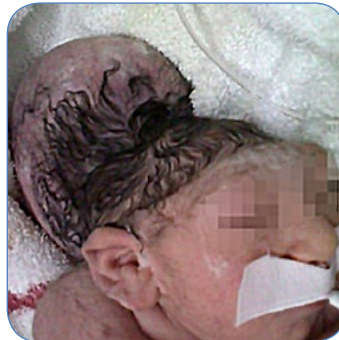
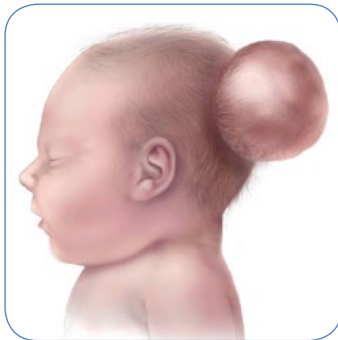


Parietal encephalocele (Q01.80)

Herniation of brain tissue, usually covered by meninges, through an opening in one of the parietal bones.

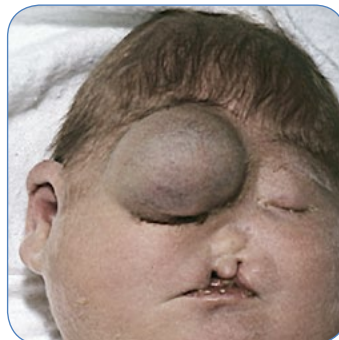
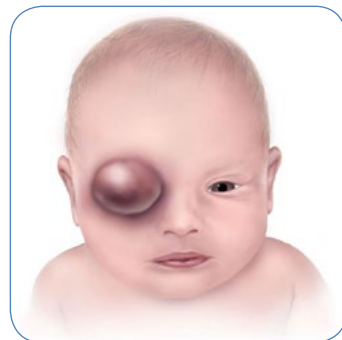Photograph source: courtesy of Registro Nacional de Anomalías Congénitas Argentina (RENAC), Centro Nacional de Genética Médica, ANLIS, Ministerio de Salud de la Nación.



Orbital encephalocele (Q01.81)

Herniation of brain tissue, usually covered by meninges, through one of the orbits.

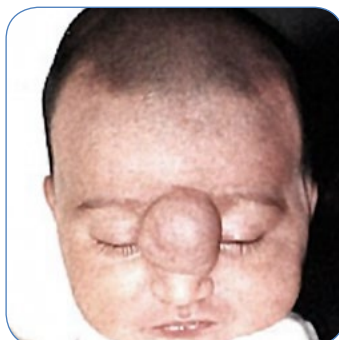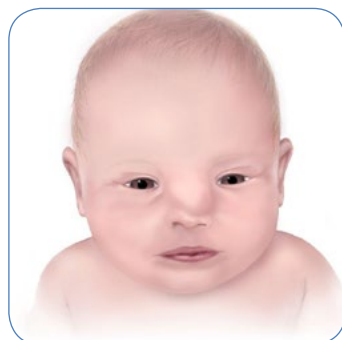Photograph source: courtesy of Jaime Frías, MD, USA.

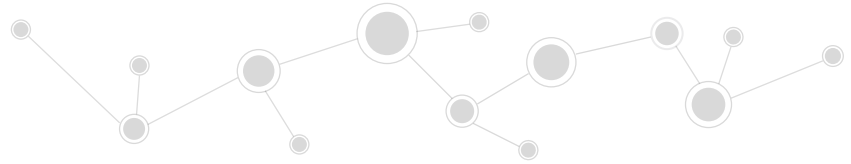


Nasal encephalocele (Q01.82)

Herniation of brain tissue, usually covered by meninges, through an opening in the nasal region.

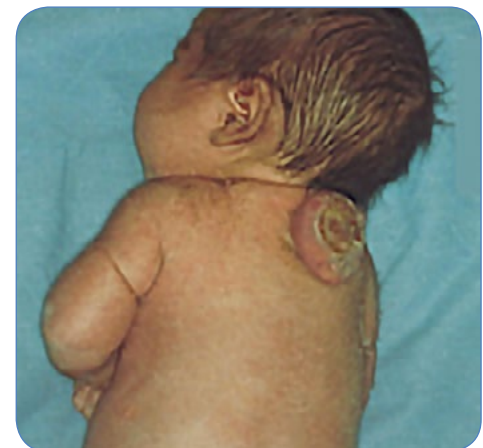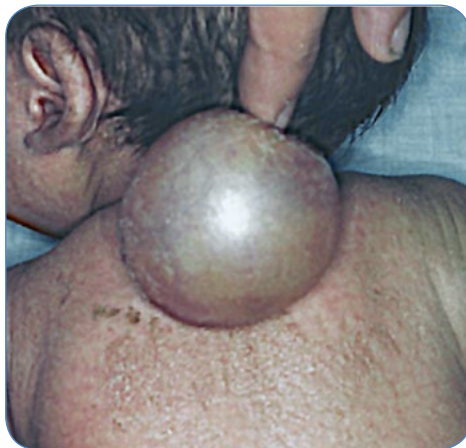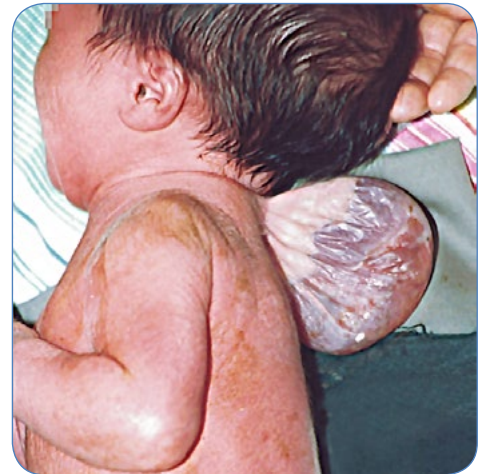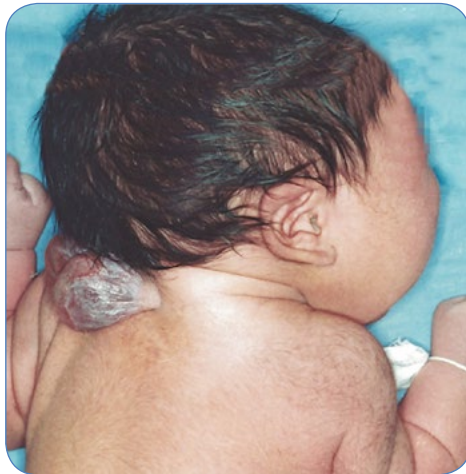Photograph source: courtesy of Estudio Colaborativo Latino Americano de Malformaciones Congénitas (ECLAMC).



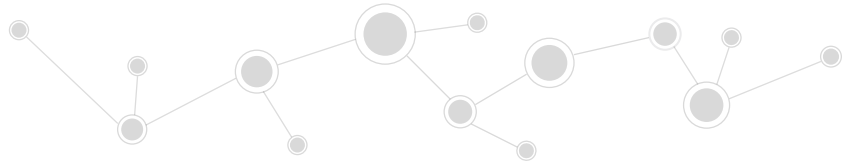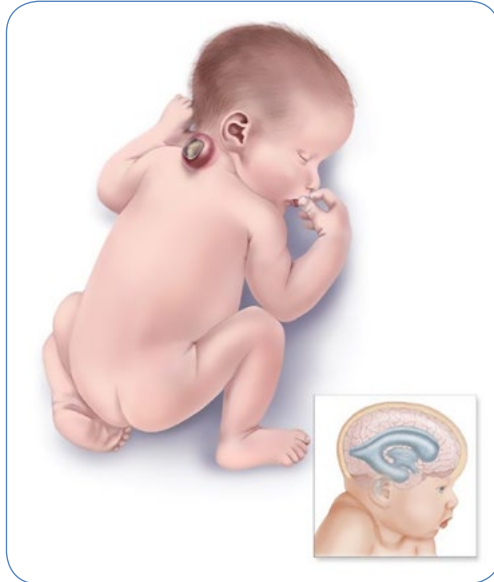


Cervical spina bifida

Most cases of cervical spina bifida will eventually develop hydrocephalus, although this may not be immediately obvious at birth; therefore, coding for cervical spina bifida with or without hydrocephalus could be difficult at birth. Close follow-up of these neonates is important for consideration of shunt surgery.

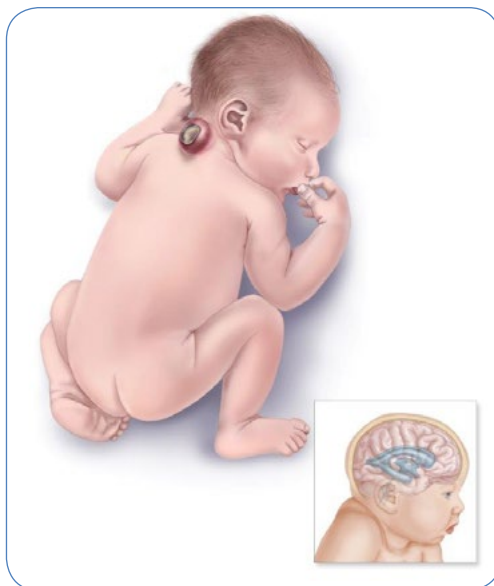

*Photographs
source: courtesy
of CDC-Beijing
Medical University
collaborative project.*



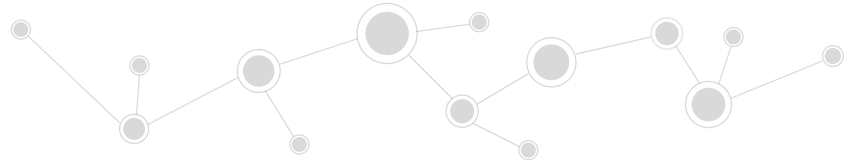
Cervical spina bifida with hydrocephalus (Q05.0)

Protrusion of meninges and/or spinal cord through an opening in the cervical region of the spine, associated with hydrocephalus. It may be open, with or without membrane covering; or closed, covered by normal-appearing skin. Hydrocephalus is present as a result of obstruction to the flow of cerebrospinal fluid, secondary to the hindbrain herniation associated with Chiari II malformation.



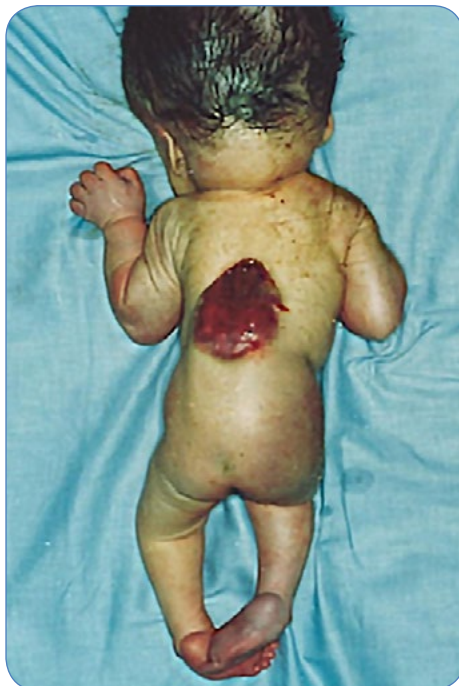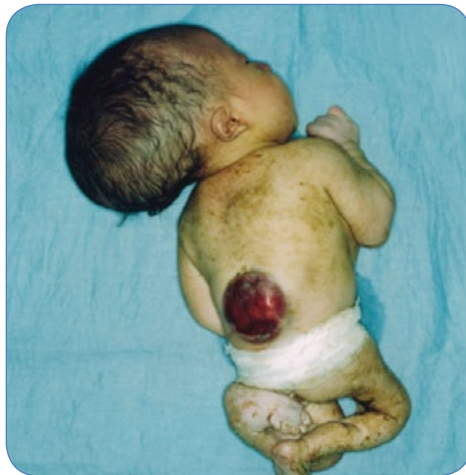Cervical spina bifida without hydrocephalus (Q05.5)

Protrusion of meninges and/or spinal cord through an opening in the cervical region of the vertebral column. It may be open, with or without membrane covering; or closed, covered by normal-appearing skin.

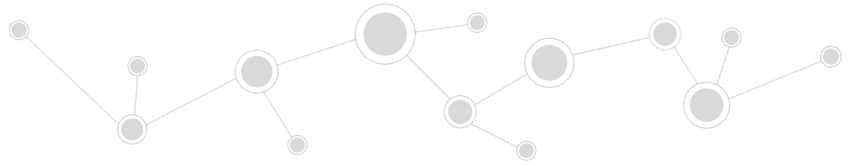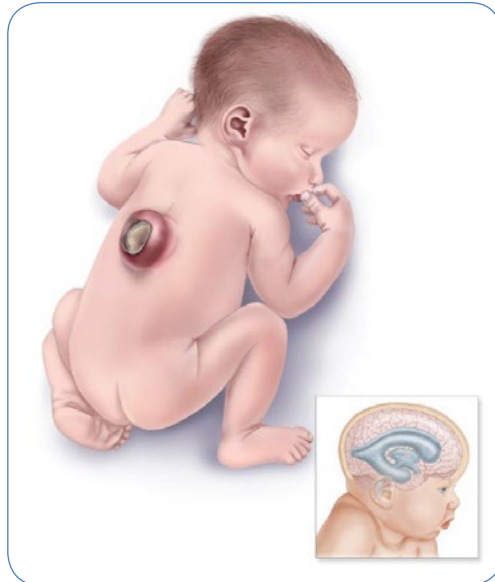


Thoracic spina bifida

Most cases of thoracic spina bifida will eventually develop hydrocephalus, although this may not be immediately obvious at birth; therefore, coding for thoracic spina bifida with or without hydrocephalus could be difficult at birth. Close follow-up of these neonates is important for consideration of shunt surgery.

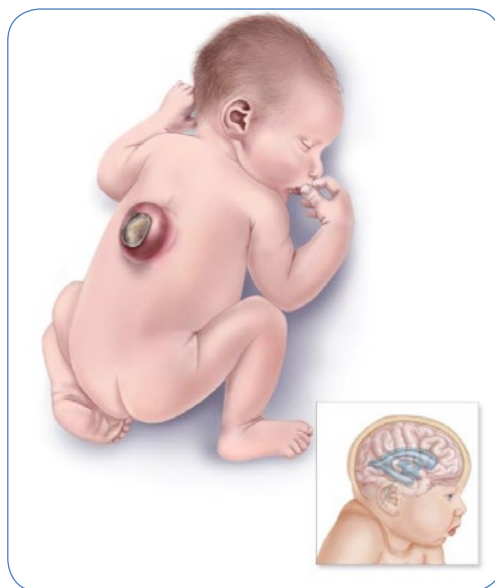

*Photographs
source: courtesy
of CDC-Beijing
Medical University
collaborative
project.*



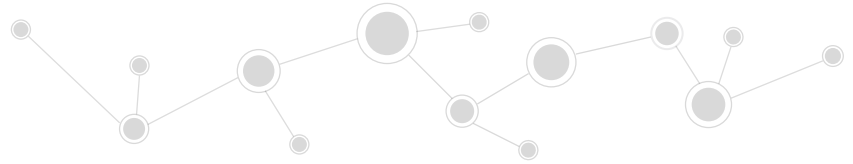
Thoracic spina bifida with hydrocephalus (Q05.1)

Protrusion of meninges and/or spinal cord through an opening in the thoracic region of the vertebral column, associated with hydrocephalus. It may be open, with or without membrane covering; or closed, covered by normal-appearing skin. Hydrocephalus is present as a result of obstruction to the flow of cerebrospinal fluid, secondary to the hindbrain herniation associated with Chiari II malformation.



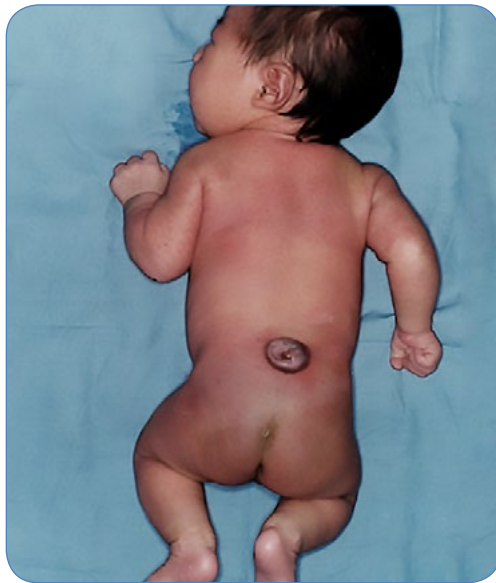Thoracic spina bifida without hydrocephalus (Q05.6)

Protrusion of meninges and/or spinal cord through an opening in the thoracic region of the vertebral column. It may be open, with or without membrane covering; or closed, covered by normal-appearing skin.

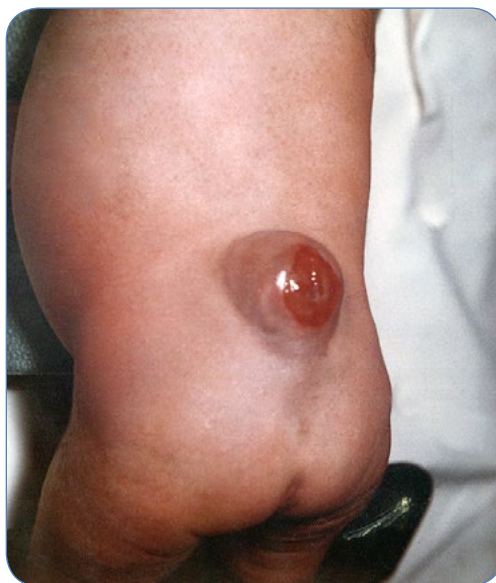
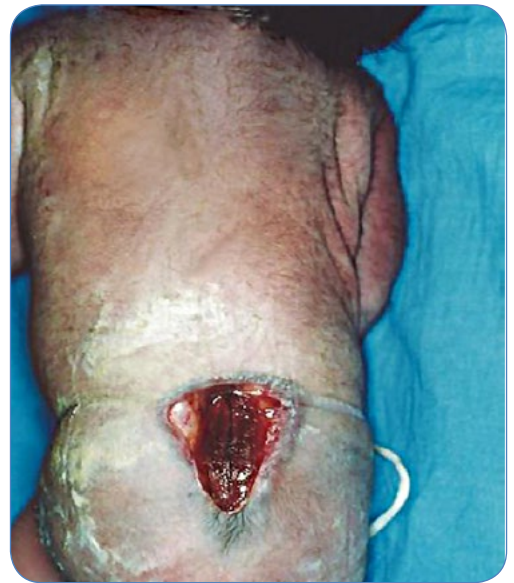
Lumbar spina bífida

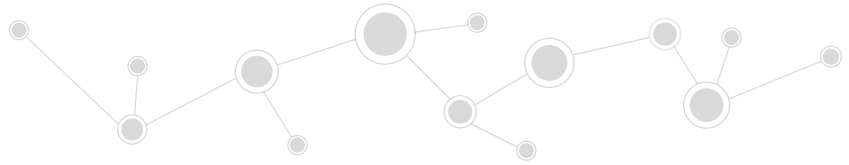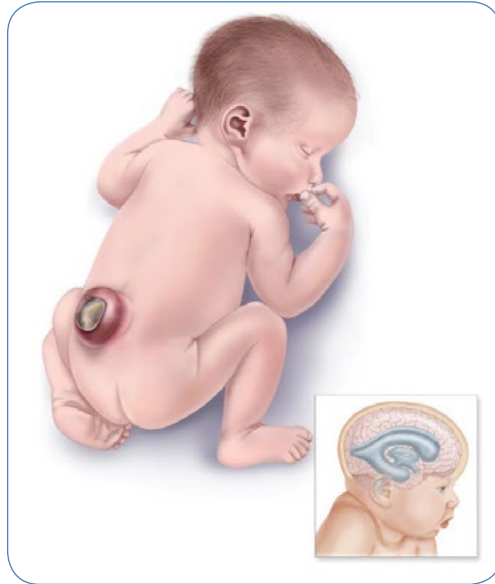
Some cases of lumbar spina bifida will eventually develop hydrocephalus, and this may not be immediately obvious at birth; therefore, coding for lumbar spina bifida with or without hydrocephalus could be difficult at birth. Close follow-up of these neonates is important for consideration of shunt surgery.



Photographs source: courtesy of CDC-Beijing Medical University collaborative project.

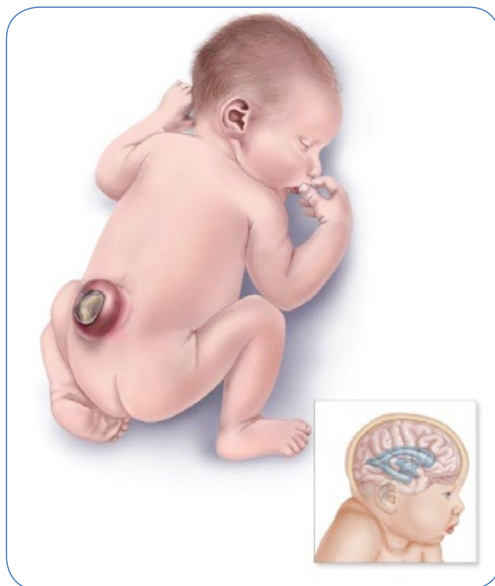

Photograph source: courtesy of Idalina Montes, MD and Rafael Longo, MD, FACS, Puerto Rico.



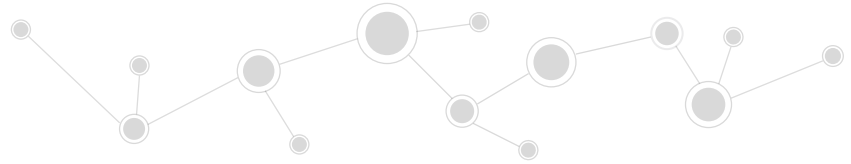
Lumbar spina bifida with hydrocephalus (Q05.2)

Protrusion of meninges and/or spinal cord through an opening in the lumbar region of the vertebral column, associated with hydrocephalus. It may be open, with or without membrane covering; or closed, covered by normal-appearing skin. Hydrocephalus is present as a result of obstruction to the flow of cerebrospinal fluid, secondary to the hindbrain herniation associated with Chiari II malformation.



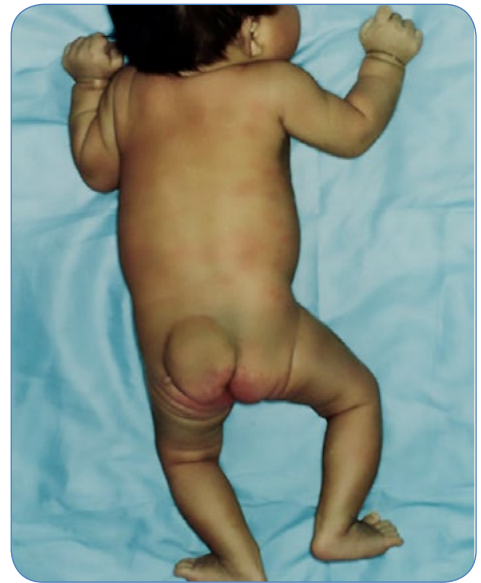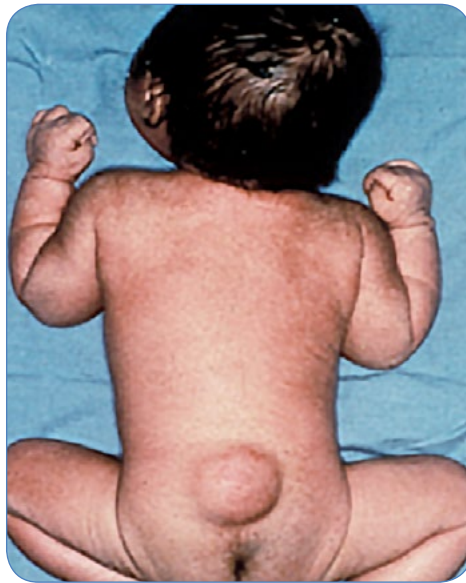Lumbar spina bifida without hydrocephalus (Q05.7)

Protrusion of meninges and/or spinal cord through an opening in the lumbar region of the vertebral column. It may be open, with or without membrane covering; or closed, covered by normal-appearing skin.

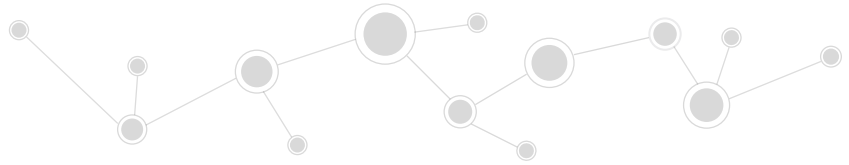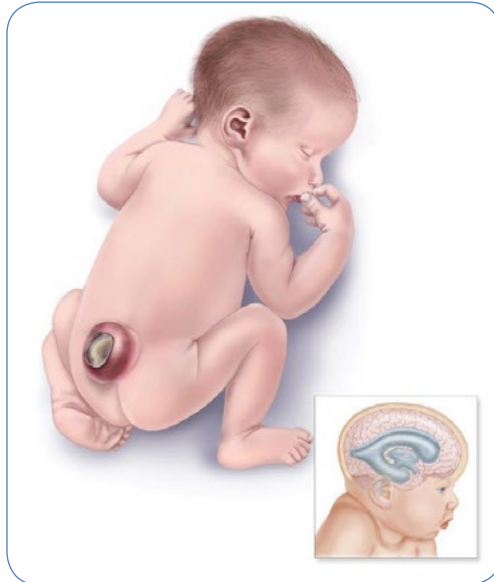


Sacral spina bifida

Few cases of sacral spina bifida will develop hydrocephalus, compared with the other types of spina bifida. The presence of hydrocephalus in infants with sacral spina bifida may not be immediately obvious at birth; therefore, coding for sacral spina bifida with or without hydrocephalus could be difficult at birth. Close follow-up of these neonates is important for consideration of shunt surgery.

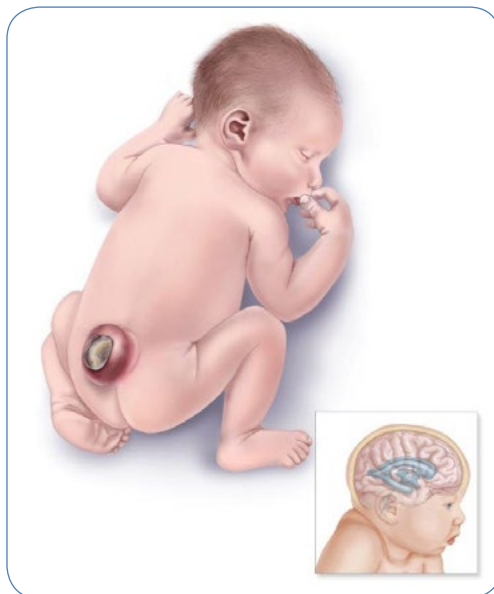

*Photographs
source: courtesy
of CDC-Beijing
Medical University
collaborative
project.*



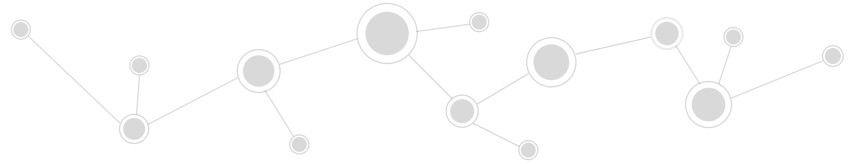
Sacral spina bifida with hydrocephalus (Q05.3)

Protrusion of meninges and/or spinal cord through an opening in the sacral region of the vertebral column, associated with hydrocephalus. It may be open, with or without membrane covering; or closed, covered by normal-appearing skin. Hydrocephalus is present as a result of obstruction to the flow of cerebrospinal fluid, secondary to the hindbrain herniation associated with Chiari II malformation.



Sacral spina bifida without hydrocephalus (Q05.8)

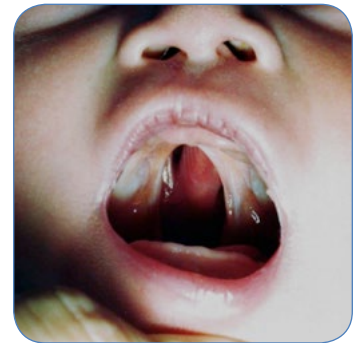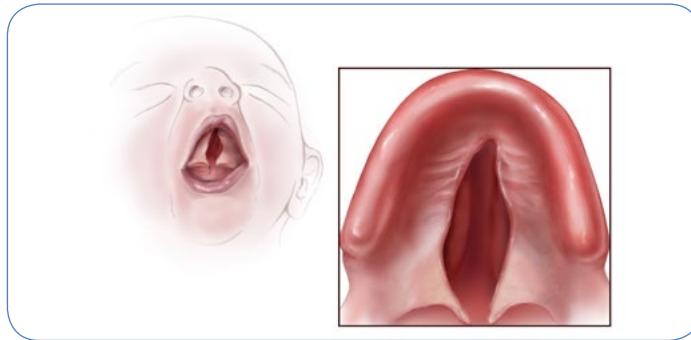
Protrusion of meninges and/or spinal cord through an opening in the sacral region of the vertebral column. It may be open, with or without membrane covering; or closed, covered by normal-appearing skin.



Cleft palate and cleft lip

Cleft palate (Q35.5)

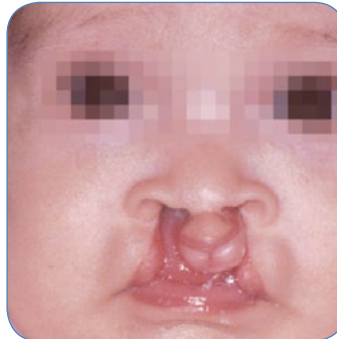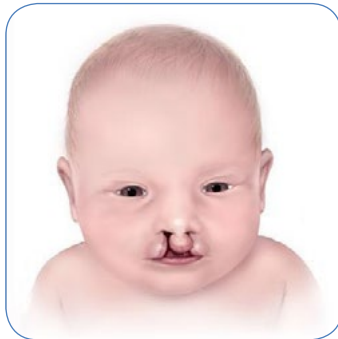Fissure of the palate, which can affect the soft and hard palate, or only the soft palate.



Photograph source: courtesy of CDC-Beijing Medical University collaborative project.

Cleft lip, bilateral (Q36.0)

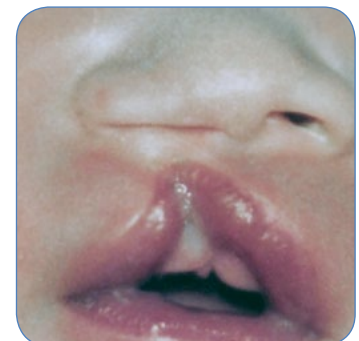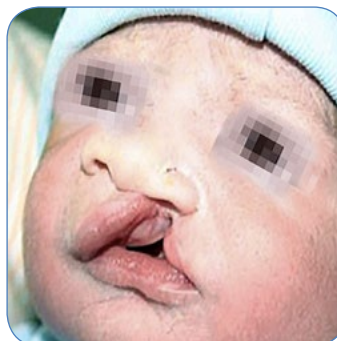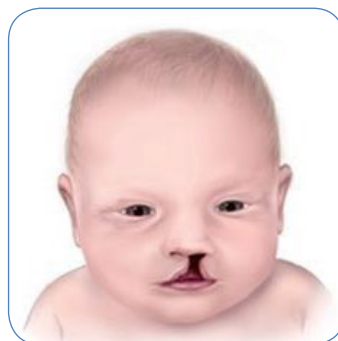
Partial or complete bilateral fissure of the upper lip that may be associated with a cleft of the gum.



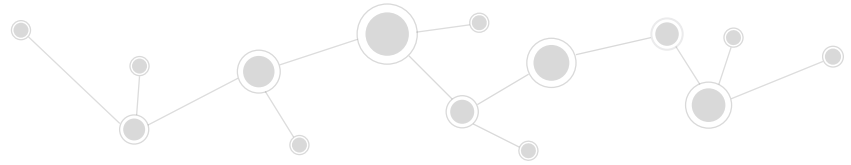
Photograph source: courtesy of Pedro Santiago, DMD and Miguel Yáñez, MD, FACS, USA.

Cleft lip, specified as unilateral (Q36.9, Q36.90)

Partial or complete unilateral fissure of the upper lip that may be associated with a cleft of the gum.



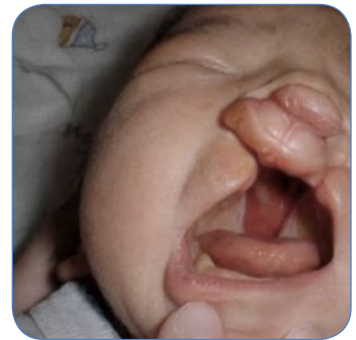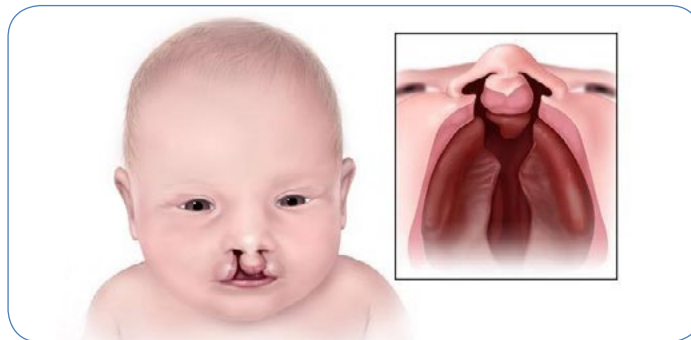
Photographs sources: courtesy of Jaime Frías, MD, USA (middle); CDC-Beijing Medical University collaborative project (right).



Cleft hard palate with bilateral cleft lip (Q37.0)

Partial or complete bilateral fissure of the upper lip, associated with a fissure of the palate.

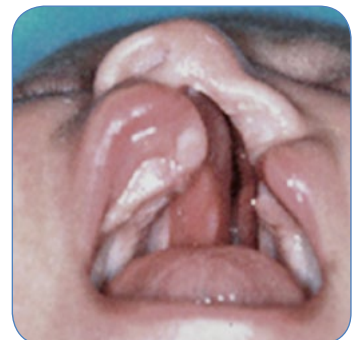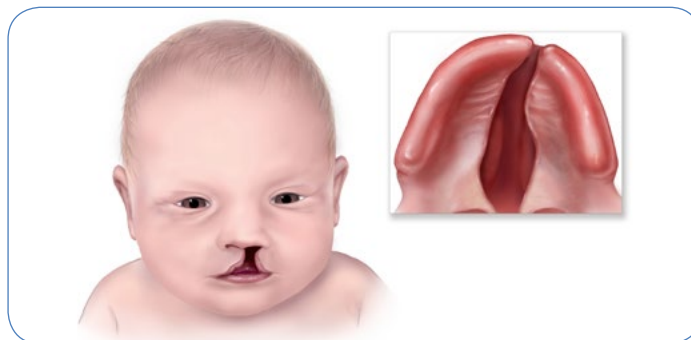
Photograph source:
courtesy of
Estudio Colaborativo
Latino Americano
de Malformaciones
Congénitas
(ECLAMC).

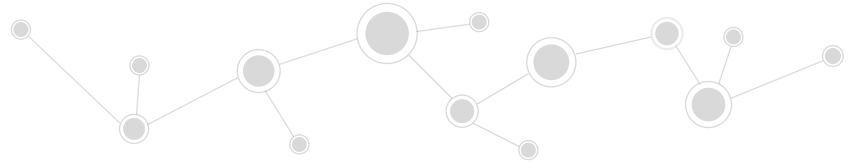


Cleft hard palate with cleft lip, specified as unilateral (Q37.10)

Partial or complete unilateral fissure of the upper lip, associated with a fissure of the palate.

Photograph source:
courtesy of
Pedro Santiago, DMD
and Miguel Yáñez,
MD, FACS, USA.





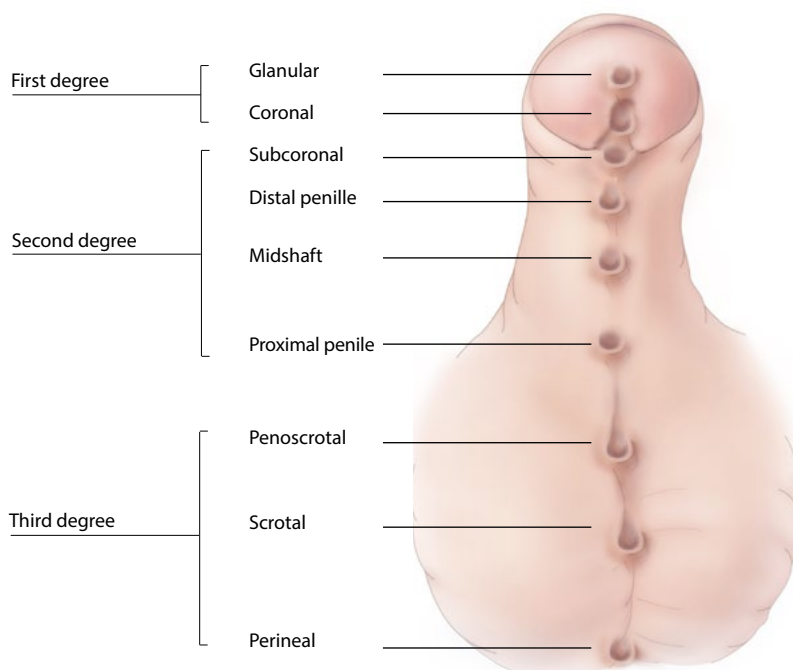
● Congenital malformations of genital organs

Hypospadias (Q54, Q54.0, Q54.1, Q54.2, Q54.3, Q54.8, Q54.9)

Displacement of the urethral meatus ventrally and proximally from the tip of the penis. It is classified according to the position of the meatus on the penis:

- First degree (Q54.0): the urethral meatus is located on either the glans (glanular hypospadias) or the corona (coronal hypospadias).
- Second degree (Q54.1): the urethral meatus is located in the balanopenile furrow or coronal sulcus (subcoronal hypospadias) or in the shaft of the penis (distal penile, midshaft, and proximal penile hypospadias).
- Third degree (Q54.2, Q54.3): the urethral meatus is located in the junction of the penis and the scrotum (penoscrotal or scrotal hypospadias) or the perineum (perineoscrotal, perineal, or pseudovaginal hypospadias).

The shortening of the ventral side of the penis found in hypospadias can result in a penile curvature, known as chordee. This is present more commonly in severe cases, but also can occur independently of hypospadias.



Subtypes:

Q54 Hypospadias (avoid using this general code if more specific information is available)

Q54.0 Hypospadias, balanic coronal glanular

Q54.1 Hypospadias, penile (subcoronal hypospadias)

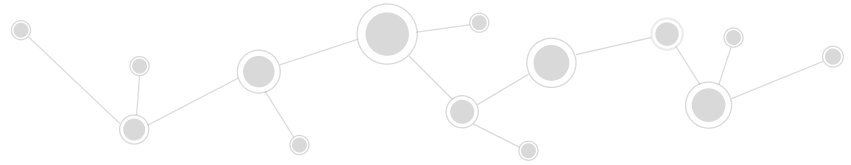
Q54.2 Hypospadias, penoscrotal

Q54.3 Hypospadias, perineal

Q54.8 Other hypospadias, excludes: female hypospadias (**Q52.81**)

Q54.9 Hypospadias, unspecified

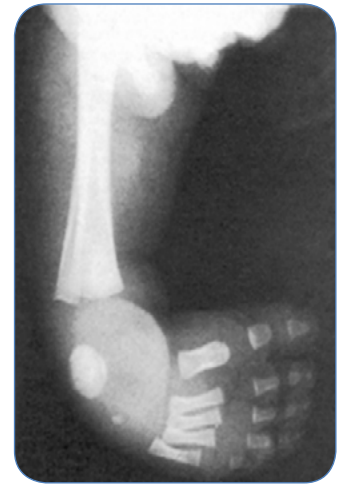
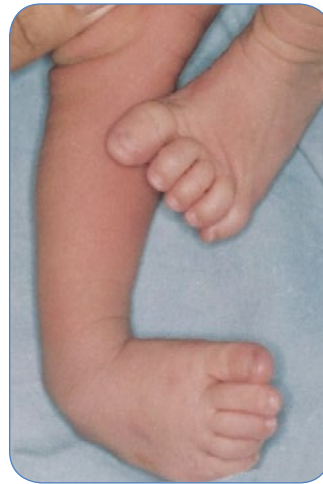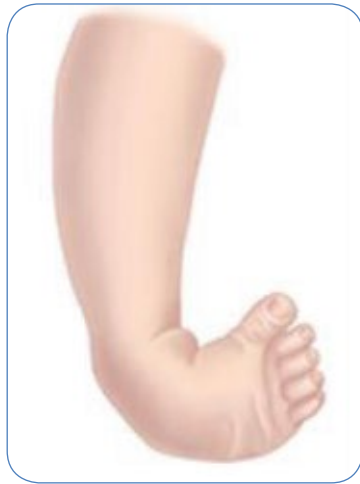Note: illustration indicates all possible locations for the malformation, but one case will not have all.



● Congenital malformations and deformations of the musculoskeletal system

Talipes equinovarus (Q66.0)

Combination of forefoot and hindfoot in equinus (plantar flexed) and in varus (rotated toward the midline). In other words, the foot points downward and inward and is rotated outward axially. Other anomalies of the foot and ankle include talipes calcaneovalgus (in which the ankle joint is dorsiflexed and the forefoot deviated outwards) and talipes calcaneovarus (in which the ankle joint is dorsiflexed and the forefoot deviated inwards).

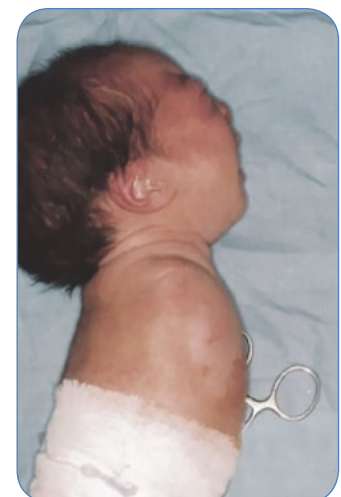
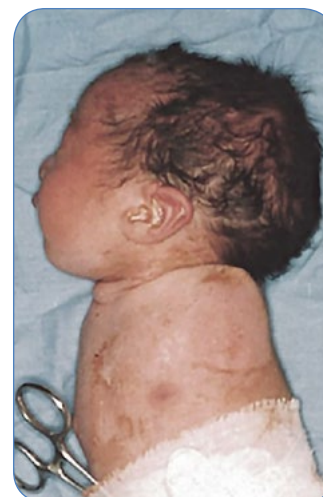
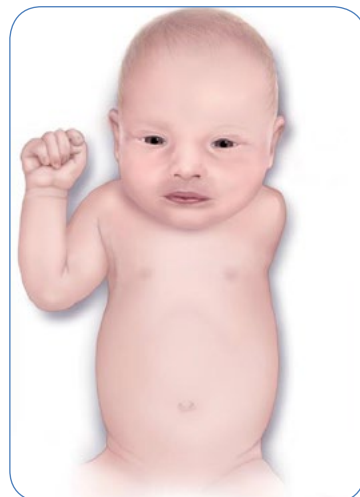Photograph and X-ray source: courtesy of Idalina Montes, MD and Rafael Longo, MD, FACS, Puerto Rico.

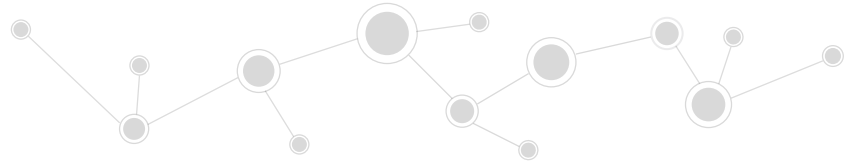
Reduction defects of upper and lower limbs

Congenital complete absence of upper limb(s); amelia of upper limb (Q71.0)

Complete absence of one or both upper limbs.

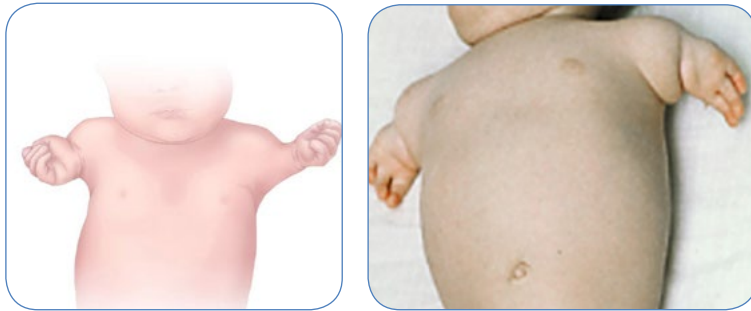

Photographs source: courtesy of CDC-Beijing Medical University collaborative project.



Congenital absence of upper arm and forearm with hand present; phocomelia of upper limb (Q71.1)

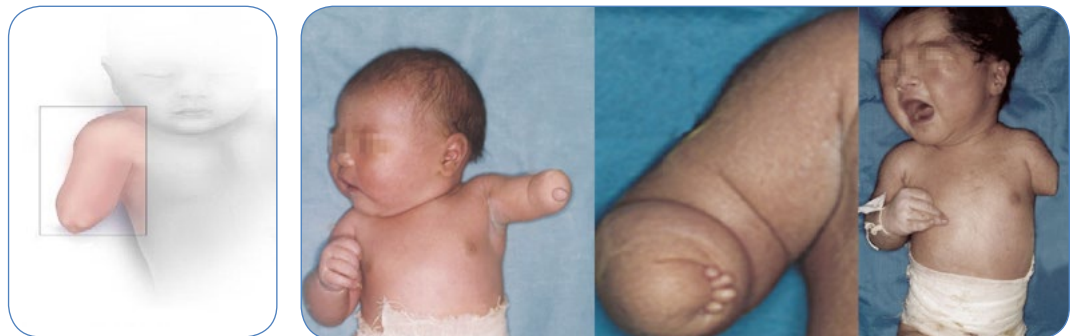Complete or partial absence of the upper arm and forearm but with the hand present.



Photograph source: courtesy of Jaime Frías, MD, USA.

Congenital absence of both forearm and hand (Q71.2)

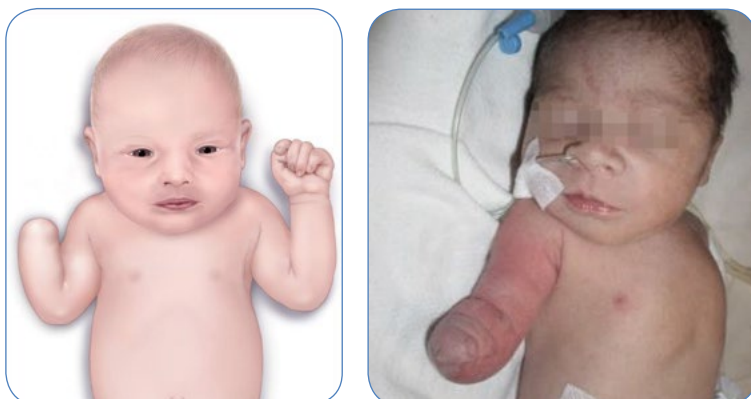Complete or partial absence of both the forearm and hand.



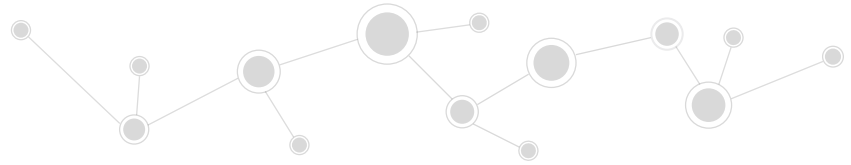
Photographs source: CDC-Beijing Medical University collaborative project.

Congenital absence of hand and finger(s) (Q71.3)

Complete or partial absence of the hand and finger(s).



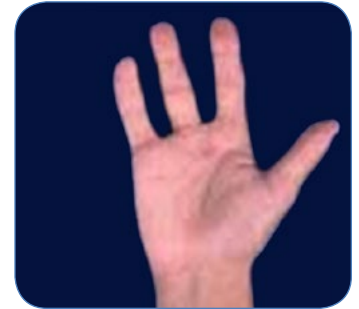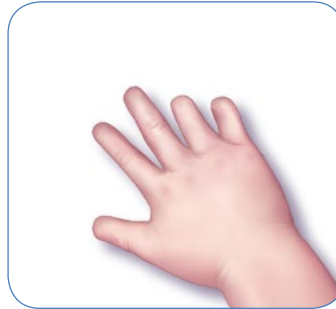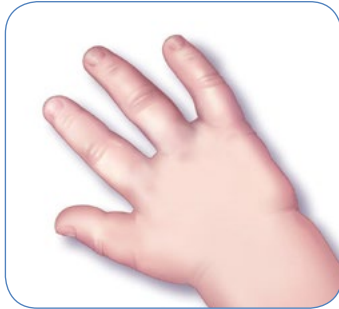Photograph source: courtesy of Estudio Colaborativo Latino Americano de Malformaciones Congénitas (ECLAMC).



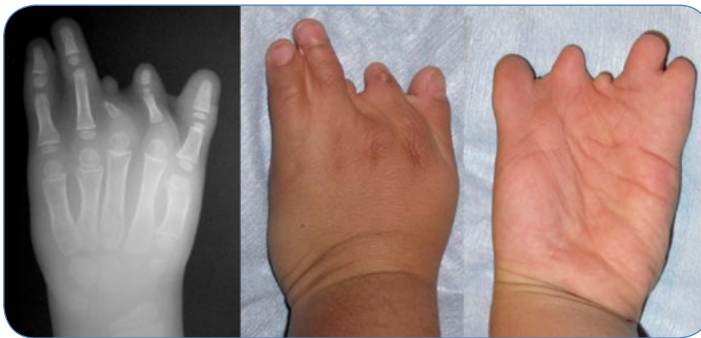Congenital absence of finger(s) (remainder of hand intact) (Q71.30)

Complete or partial absence of fingers, with the remainder of the hand intact.

Photograph source:
courtesy of John
Wiley and Sons
©2009. Biesecker
LG et al. Am. J.
Med. Genet. A.
2009;149A:93–127.

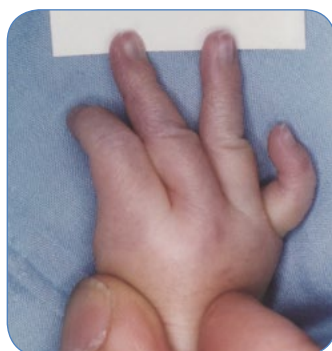

Photographs and X-ray source: courtesy of Dr
E Gene Deune, MD;
Associate Professor,
Johns Hopkins
Department of
Orthopedic Surgery,
Division of Hand
Surgery, Baltimore,
MD, USA.

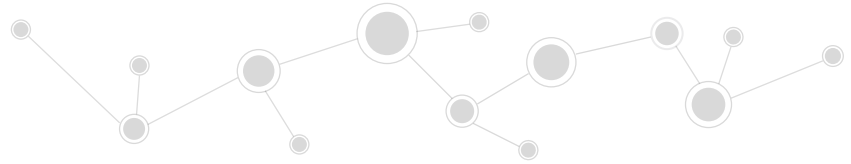


Absence or hypoplasia of thumb (other digits intact) (Q71.31)

Complete or partial absence or hypoplasia of the thumb.



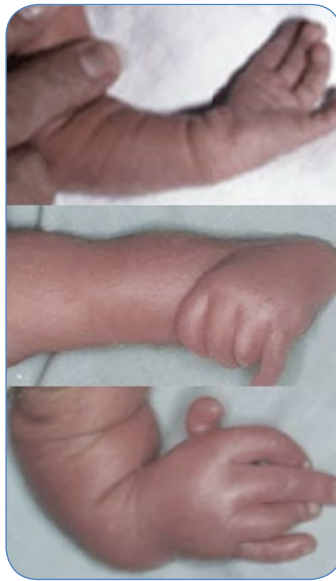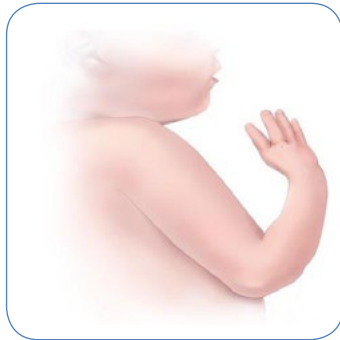Photograph source:
CDC-Beijing
Medical University
collaborative project.



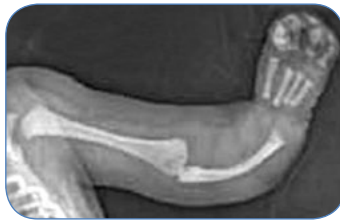Longitudinal reduction defect of radius: clubhand (congenital), radial clubhand, absence of radius (Q71.4)

Complete or partial radial aplasia/hypoplasia. Usually accompanied by complete or partial absence or hypoplasia of the thumb.

Photographs source: courtesy of CDC-Beijing Medical University collaborative project.



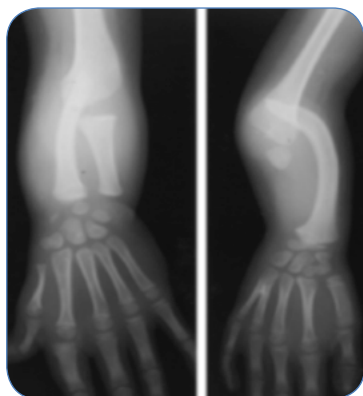
X-ray source: courtesy of John Wiley and Sons ©2011. Umaña LA et al. Am. J. Med. Genet. A. 2011;155A:3071-4.

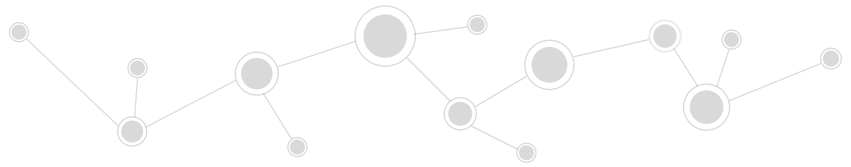


Longitudinal reduction defect of ulna (Q71.5)

Complete or partial absence of the ulna.

X-ray source: courtesy of John Wiley and Sons ©1997. Kumar D et al. Am. J. Med. Genet. A. 1997;70A:107-13.

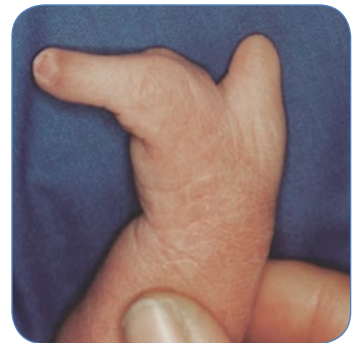
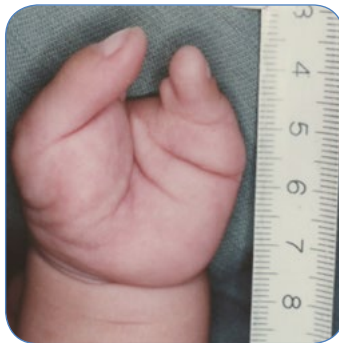
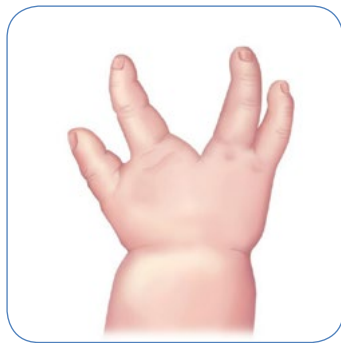

Split hand (congenital cleft hand) (Q71.6)

Complete or partial absence of central fingers and metacarpals. The terms lobster claw and ectrodactyly, used by some, should be discouraged.

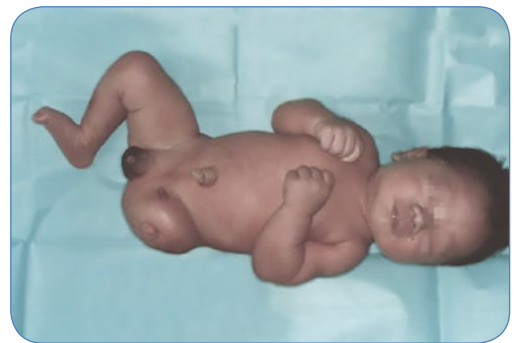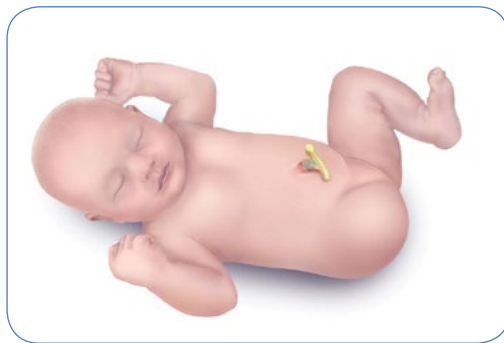Photographs
source: CDC-Beijing
Medical University
collaborative project.



Congenital complete absence of lower limb(s); amelia of lower limb (Q72.0)

Complete absence of one or both lower limb(s).

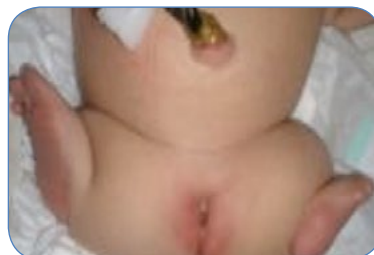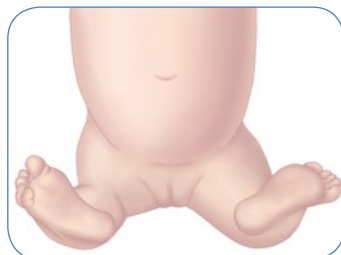Photograph source:
CDC-Beijing
Medical University
collaborative project.

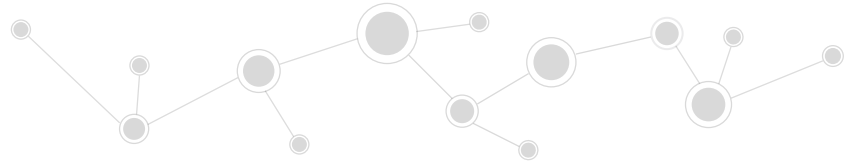


Congenital absence of thigh and lower leg with foot present; phocomelia of lower limb (Q72.1)

Complete or partial absence of the thigh and lower leg but with the foot present.

Photograph source:
courtesy of Estudio
Colaborativo Latino
Americano de
Malformaciones
Congénitas (ECLAMC).

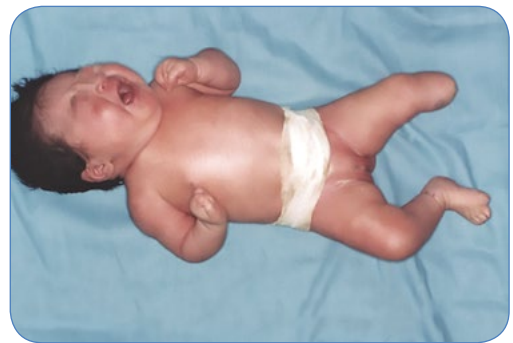
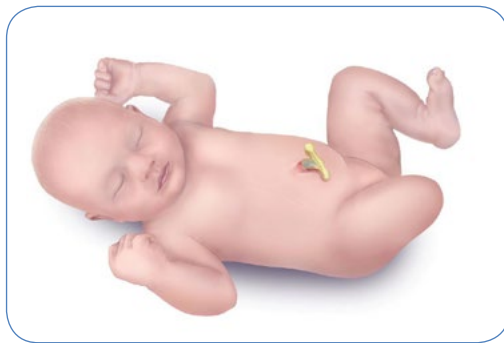


Congenital absence of both lower leg and foot (Q72.2)

Complete or partial absence of both the lower leg and foot.

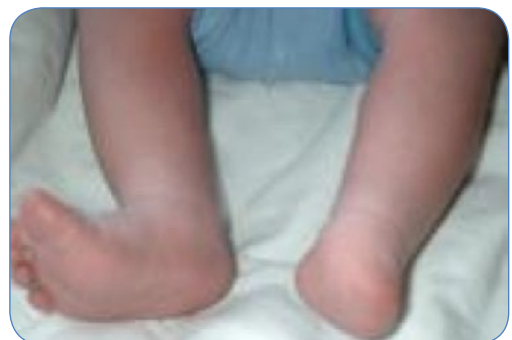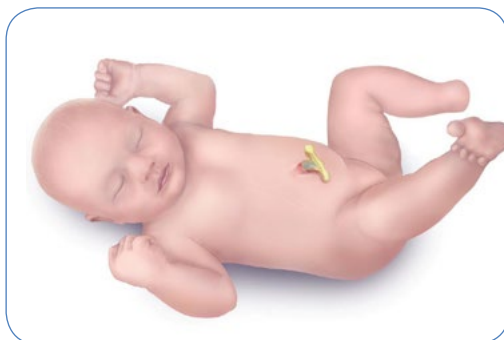Photograph source:
CDC-Beijing Medical
University collaborative
project.



Congenital absence of foot and toe(s) (Q72.3)

Complete or partial absence of the foot and toe(s).

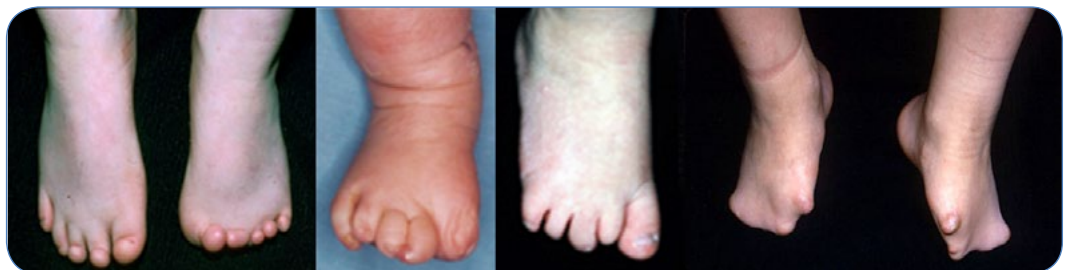Photograph source:
courtesy of Estudio
Colaborativo Latino
Americano de
Malformaciones
Congénitas (ECLAMC).

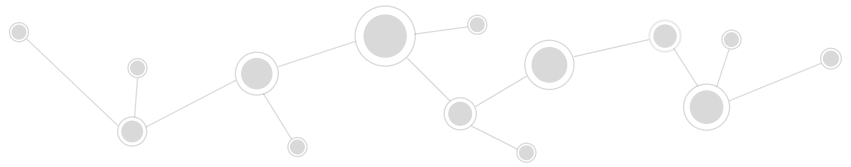


Congenital absence or hypoplasia of toe(s) with remainder of foot intact (Q72.30)

Complete absence or hypoplasia of toe(s) with the remainder of the foot intact.

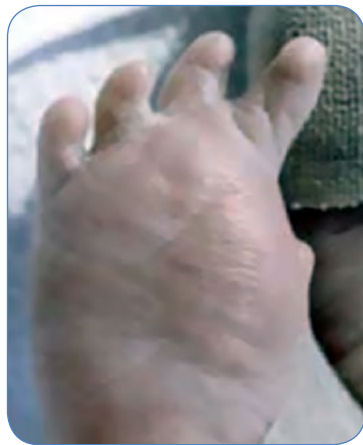Photographs source:
courtesy of John
Wiley and Sons
©2009. Biesecker
LG et al. Am. J.
Med. Genet. A.
2009;149A:93-127.





Absence or hypoplasia of first toe with other digits present (Q72.31)

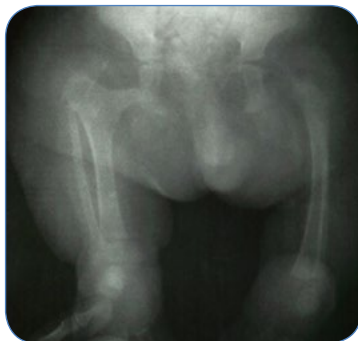Complete absence or hypoplasia of the first (great) toe with other digits present.



Photograph source:
courtesy of John Wiley
and Sons ©2009.
Biesecker LG et al.
Am. J. Med. Genet. A.
2009;149A:93–127.

Longitudinal reduction defect of femur (Q72.4)

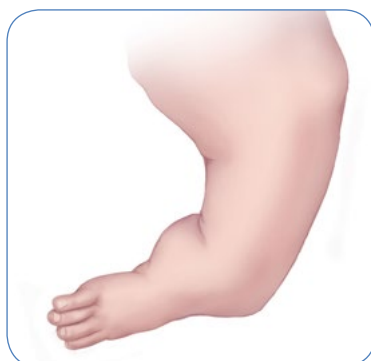Complete or partial absence of the femur.



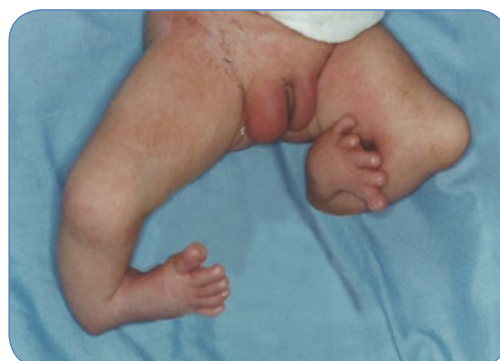X-ray source: courtesy
of Jaime Frías, MD,
USA.

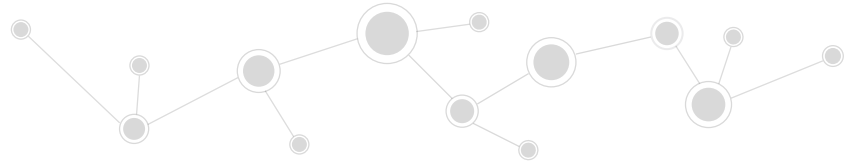
Longitudinal reduction defect of tibia (Q72.5)

Complete or partial absence of the tibia. Usually accompanied by complete or partial absence or hypoplasia of the first (great) toe.



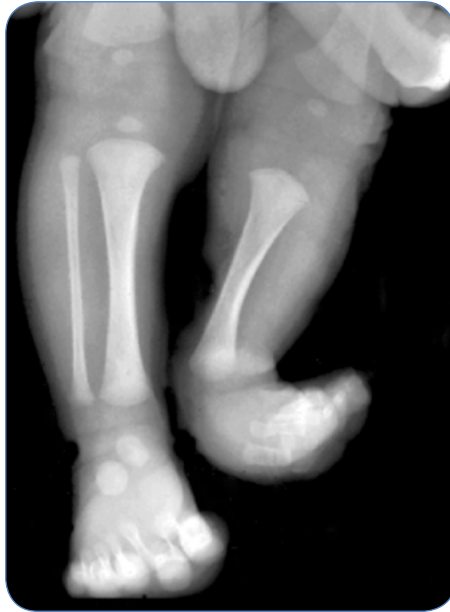Photograph source:
CDC-Beijing
Medical University
collaborative project.





Longitudinal reduction defect of fibula; fibular aplasia/hypoplasia (Q72.6)

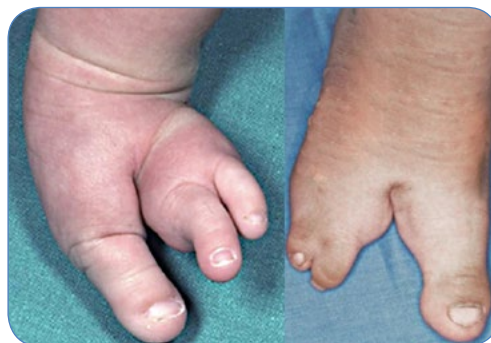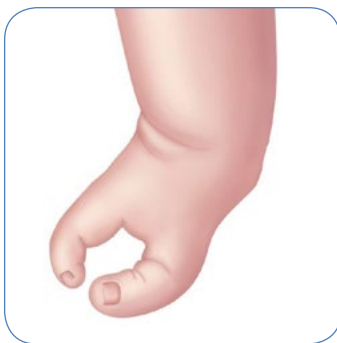Complete or partial absence of the fibula.



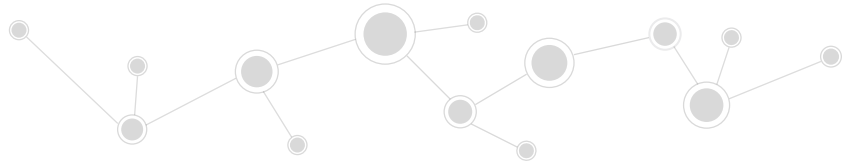
X-ray source: image reprinted with permission from Holmstrom MC et al. Medscape 2013 (<http://emedicine.medscape.com/article/1251558-overview>).

Split foot (congenital cleft foot) (Q72.7)

Complete or partial absence of central toes and metatarsals. The term ectrodactyly, used by some, should be discouraged.



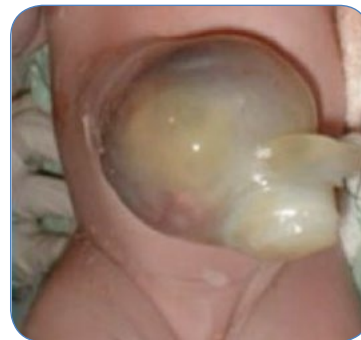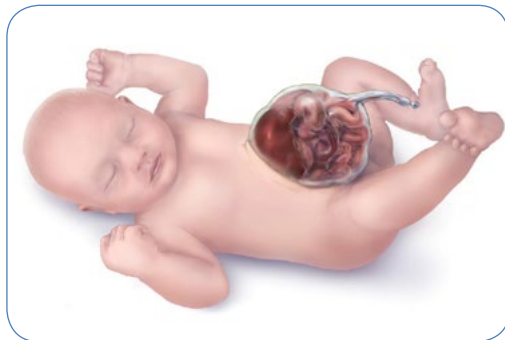Photographs source: CDC-Beijing Medical University collaborative project.



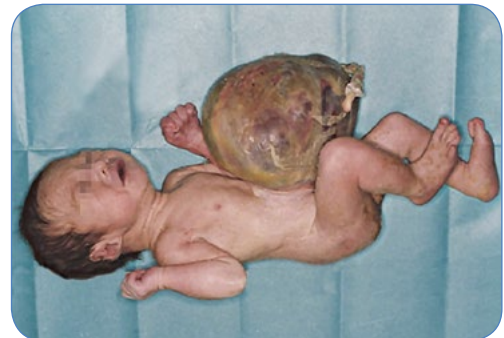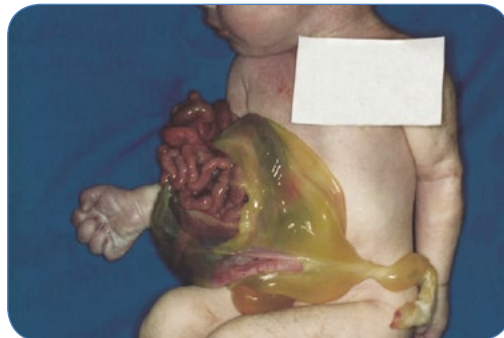Exomphalos/omphalocele (Q79.2)

Congenital anomaly of the anterior abdominal wall, in which the abdominal contents (gut, but at times also other abdominal organs) are herniated in the midline through an enlarged umbilical ring. The umbilical cord is inserted in the distal part of the membrane covering the anomaly. The herniated organs are covered by a membrane consisting of the peritoneum and amnion (but this membrane can be ruptured).

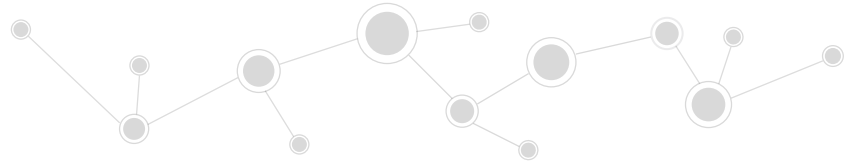
Photograph source:
courtesy of Estudio
Colaborativo Latino
Americano de
Malformaciones
Congénitas (ECLAMC).



Photographs source: CDC-Beijing
Medical University
collaborative project.

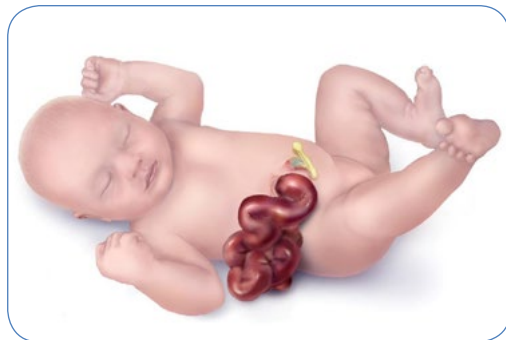

Gastroschisis and omphalocele can be confused with one another when the membrane covering the omphalocele has ruptured. In that case, the location of the abdominal opening is decisive: it is midline in omphalocele, and lateral to the umbilicus in gastroschisis.

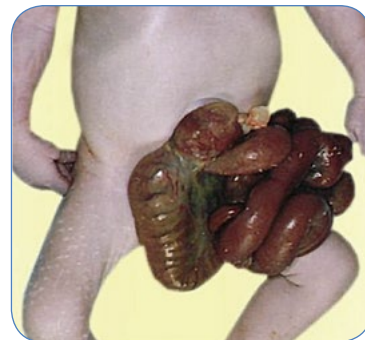

Gastroschisis (Q79.3)

Gastroschisis is a congenital anomaly of the anterior abdominal wall, accompanied by herniation of the gut and occasionally other abdominal organs. The opening in the abdominal wall is lateral to the umbilicus, and the herniated organs lack a protective membrane. Note that the extruded abdominal contents can be matted and covered by a thick fibrous material, but this membrane does not resemble skin.



Photograph source:
CDC-Beijing
Medical University
collaborative project.



Gastroschisis and omphalocele can be confused with one another when the membrane covering the omphalocele has ruptured. In that case, the location of the abdominal opening is decisive: it is midline in omphalocele, and lateral to the umbilicus in gastroschisis.



For more information, please contact:

**National Center on Birth Defects and Developmental Disabilities
Centers for Disease Control and Prevention**

1600 Clifton Rd, MS-E86, Atlanta, GA 30333, United States of America

Fax: +1 404 498 3550

<http://www.cdc.gov/ncbddd/birthdefects>

International Clearinghouse for Birth Defects Surveillance and Research

Via Carlo Mirabello 14, 00192 Roma, Italy

Fax +39 06 270 1904

Email: icbd@icbd.org

www.icbdsr.org

Department of Nutrition for Health and Development

World Health Organization

Avenue Appia 20, CH-1211 Geneva 27, Switzerland

Fax: +41 22 791 4156

Email: nutrition@who.int

www.who.int/nutrition

ISBN 978 92 4 156476 2



9 789241 564762