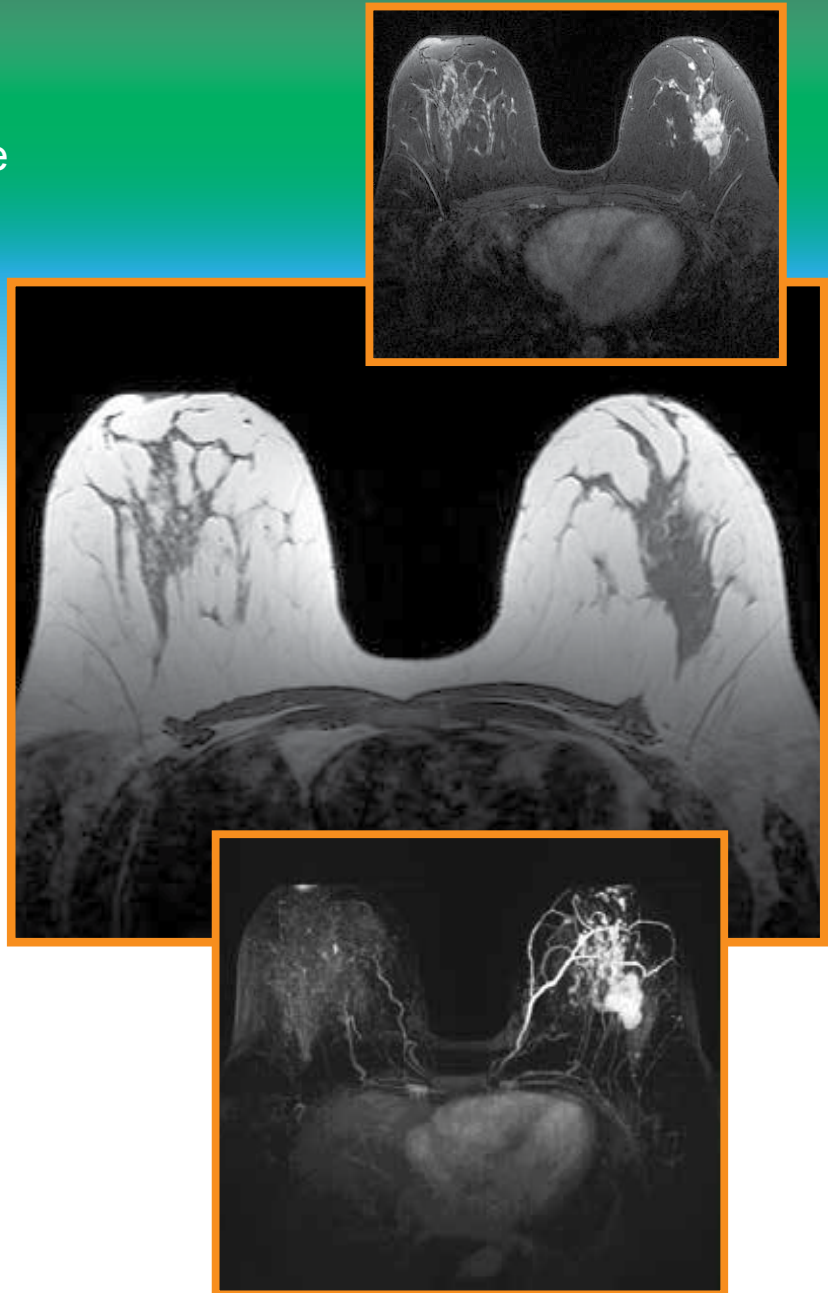


# Breast MR Protocols

## Breast MR Imaging

Suggested 1.5T and 3T Protocols for scanner vendors

- GE Healthcare
- Siemens Healthcare



This activity is jointly provided by:



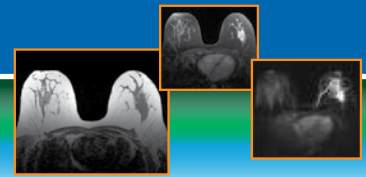
and



This activity is supported by an unrestricted educational grant from Bracco Diagnostics Inc.

Images courtesy of R. Edward Hendrick, PhD, FACR, and Roberta Strigel, MD, MS, FSBI.

For additional CME/CE activities please visit [www.ImagingEducation.com](http://www.ImagingEducation.com). **IMAGING** Education™



## BREAST MR PROTOCOLS

### FACULTY

#### **R. Edward Hendrick, PhD, FACR**

Clinical Professor  
Department of Radiology  
University of Colorado-Denver, School of Medicine  
Aurora, Colorado

#### **Roberta Strigel, MD, MS, FSBI**

Associate Professor  
Department of Radiology  
University of Wisconsin School of Medicine and Public Health  
Madison, Wisconsin

## CONTINUING EDUCATION INFORMATION

### TARGET AUDIENCE

This activity has been designed for radiologists, radiologic technologists (RTs), medical physicists, radiology nurses, and other healthcare providers involved in breast magnetic resonance imaging (MRI).

### LEARNING GOAL/PURPOSE

To provide radiologists, RTs, medical physicists, radiology nurses, and other healthcare providers involved in breast MRI with protocols/sequences that can help to optimize imaging on General Electric (GE) and Siemens MR scanners while enhancing patient safety.

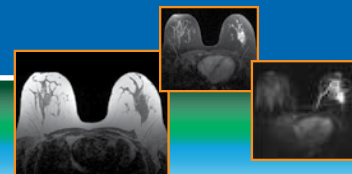
### EDUCATIONAL OBJECTIVES

After completing this activity, participants should be better able to:

- Review requirements for breast MRI, including techniques used to optimize breast magnetic resonance (MR) protocols
- Implement 1.5T and 3T breast MR protocols that provide optimal visualization of breast cancers
- Discuss breast MR image interpretation including the use of computer-aided evaluation systems

### STATEMENT OF NEED/PROGRAM OVERVIEW

- Recent advances in MRI and MR technology have greatly improved the utility of this important noninvasive diagnostic modality for detecting and staging breast cancer, monitoring response to therapy, and guiding biopsies and surgical procedures using breast MRI. These improvements include higher field strength magnets, dedicated breast coils, innovative pulse sequences, high-relaxivity contrast agents, and optimized protocols
- Breast MRI is the clinical standard for screening patients at elevated risk for breast cancer and for staging and extent of disease assessment due to the superior ability of this imaging modality to detect breast cancers occult on other imaging modalities. The American College of Radiology (ACR) Practice Guidelines for the Performance of Contrast-enhanced Magnetic Resonance Imaging of the Breast, Breast MRI Accreditation Program Requirements, and Practice Guideline for Performance of Magnetic Resonance Imaging-guided Breast Interventional Procedures provide important evidence-based guidelines for radiologists and other healthcare personnel involved in breast MRI. To capitalize on these advances, radiologists, MRI technologists, medical physicists, and radiology nurses require education that enhances their understanding of improvements in MR technology and optimal breast MRI protocols



## ACCREDITATION

### Physician Credit

This activity has been planned and implemented in accordance with the accreditation requirements and policies of the Accreditation Council for Continuing Medical Education (ACCME) through the joint providership of Medical Education Resources (MER) and ABC Medical Education LLC. MER is accredited by the ACCME to provide continuing medical education for physicians.

### Credit Designation

Medical Education Resources designates this enduring activity for a maximum of 0.5 *AMA PRA Category 1 Credit*<sup>™</sup>. Physicians should claim only the credit commensurate with the extent of their participation in the activity.

### Nursing Credit

Medical Education Resources is accredited as a provider of continuing nursing education by the American Nurses Credentialing Center's Commission on Accreditation.

The continuing education activity provides 0.5 contact hour of continuing nursing education.

MER is a provider of continuing nursing education by the California Board of Registered Nursing, Provider #CEP 12299, for 0.5 contact hour.

### Radiologic Technologist Credit

This activity is approved by the American Society of Radiologic Technologists (ASRT) for 0.5 Category A CE Credit. The ASRT is recognized by the American Registry of Radiologic Technologists as a Recognized Continuing Education Evaluation Mechanism. The ASRT had no involvement in the development of this activity.

## INSTRUCTIONS FOR RECEIVING CONTINUING EDUCATION (CME/CE) CREDIT

There is no fee for participating in and receiving CME/CE credit for this activity. The participants must

1. Read the learning objectives and faculty disclosures
2. Study the educational activity
3. Complete the online posttest by recording the best answer to each question

### Physicians and Nurses

**Original Release Date:** December 2013

**Re-review Date:** January 2022

**Expiration Date:** January 2024

Physicians CME Credit (0.5 *AMA PRA Category 1 Credit*<sup>™</sup>)

Nursing ANCC Credit (0.5 Contact Hour)

- Click on **Physicians\_and\_Nurses\_Credit** to complete the activity evaluation and posttest
- A statement of credit will be issued only upon receipt of a completed activity evaluation and a completed posttest with a score of 70% or better
- Statements of credit will be issued upon completion via e-mail

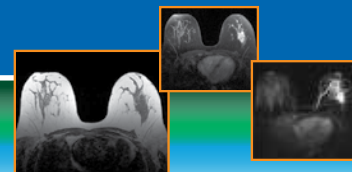
### Radiologic Technologists

**Release Date:** December 4, 2013

**Expiration Date:** January 1, 2024

CE Credit (0.5 Category A CE Credit)

- Click on **CE\_Credit** to access the posttest
- A statement of credit will be issued only upon receipt of a completed posttest with a score of 75% or better
- Statements of credit will be issued upon completion via e-mail



## DISCLOSURE OF CONFLICTS OF INTEREST

It is the policy of MER to ensure balance, independence, objectivity, and scientific rigor in all of its educational activities. In accordance with this policy, MER identifies conflicts of interest with its instructors, content managers, and other individuals who are in a position to control the content of an activity. Conflicts are resolved by MER to ensure that all scientific research referred to, reported, or used in a CME activity conforms to the generally accepted standards of experimental design, data collection, and analysis.

The **faculty** reported the following financial relationships with commercial interests whose products or services may be mentioned in this CME activity:

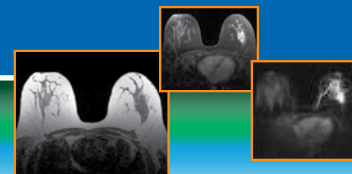
<i>Faculty</i>	<i>Reported Financial Relationship</i>
R. Edward Hendrick, PhD, FACR	Consulting fees from GE Healthcare for work on digital breast tomosynthesis.
Roberta Strigel, MD, MS, FSBI	Grants/research support from GE Healthcare.

The **content managers** reported the following financial relationship with commercial interests whose products or services may be mentioned in this CME activity:

<i>Content Manager</i>	<i>Reported Financial Relationship</i>
Andy Galler (ABC Medical Education)	No financial relationships to disclose.
Medical Education Resources	No financial relationships to disclose.

## DISCLAIMER

The content and views presented in this educational activity are those of the authors and do not necessarily reflect those of Medical Education Resources (MER), ABC Medical Education (ABC) and/or Bracco Diagnostics Inc. (Bracco). The authors have disclosed if there is any discussion of published and/or investigational uses of agents that are not indicated by the FDA in their presentations. The suggested protocols presented here were developed for adult women. The opinions expressed in this educational activity are those of the faculty and do not necessarily represent the views of MER, ABC and/or Bracco. Before prescribing any medicine, primary references and full prescribing information should be consulted. Any procedures, medications, or other courses of diagnosis or treatment discussed or suggested in this activity should not be used by clinicians without evaluation of their patient's conditions and possible contraindications on dangers in use, review of any applicable manufacturer's product information, and comparison with recommendations of other authorities. The information presented in this activity is not meant to serve as a guideline for patient management.



## BREAST MR PROTOCOLS

Breast magnetic resonance imaging (MRI) requires maximizing sensitivity and specificity for breast cancer while minimizing scan time. Only with the use of modern MRI equipment, appropriate imaging sequences, proper patient positioning, appropriate contrast agent administration, and standardized image acquisition and interpretation will sensitivity for breast cancer be maximized. Evaluation of lesion morphology and temporal enhancement kinetics are required for accurate lesion characterization to improve specificity and diagnostic accuracy. Longer overall scan times should be avoided, as they can lead to patient discomfort and motion, which in turn lead to artifacts and image degradation secondary to motion. See **Table 1** for a summary of the prerequisites for maximizing sensitivity and specificity of breast MR imaging.<sup>1-3</sup> In addition, the following text provides some additional details, as well as tips to consider, when performing breast MRI.

**Table 1: Summary of Prerequisites for Maximizing the Sensitivity and Specificity of Contrast-enhanced Breast MR Imaging<sup>1-3</sup>**

• High magnetic field strength (1.5T or greater) with a highly homogeneous magnetic field (<1 ppm over 30 cm)
• Bilateral image acquisition with a prone-positioning bilateral breast coil (7 channels or greater)
• Unenhanced imaging with a T2-weighted pulse sequence to identify cysts and contribute to lesion characterization
• Multiphase contrast-enhanced imaging with a 3D T1-weighted spoiled gradient-echo pulse sequence
• Phase-encoding direction selected to minimize artifacts across breast tissue: phase-encoding right-to-left for axial imaging, head-to-foot for sagittal imaging (frequency-encoding anterior-posterior in either case)
• Intravenous administration of a gadolinium chelate at a dose of 0.1 mmol/kg and a rate of 2 mL/sec followed by a 20 mL saline flush
• Homogeneous fat suppression across both breasts
• Thin-section acquisitions (section thickness of 3 mm or less, ideally closer to 1 mm) for the multiphase T1-weighted contrast-enhanced series
• Pixel size of less than 1 mm in each in-plane direction for the multiphase T1-weighted contrast-enhanced series
• Temporal resolution (i.e., per-series imaging time) of less than 3 minutes for imaging both breasts in the multiphase T1-weighted contrast-enhanced series

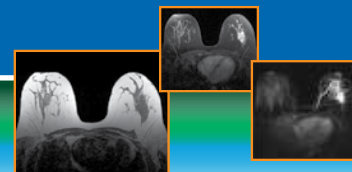
### Protocol Sequences

The American College of Radiology (ACR) Breast MRI Accreditation Program requires submission of a biopsy-proven breast carcinoma case acquired bilaterally with the following pulse sequences:<sup>2</sup>

- Localizer or scout images, preferably obtained in all 3 perpendicular planes: axial, sagittal, and coronal
- A T2-weighted (T2W)/bright fluid series of both breasts, preferably with fat-suppression, to distinguish cysts from solid lesions
- A multiphase T1-weighted (T1W) series set acquired once before and multiple times after contrast agent administration, preferably acquired as a 3D (volume) gradient-echo (GRE) pulse sequence with fat suppression, to identify the vascular bed and detect enhancing lesions in the breast

In addition, we recommend performing a 3D T1W non-fat-suppressed series prior to the multiphase series, to provide an overview of breast anatomy and to distinguish fat from water-based tissues (fibroglandular tissues, chest wall, and breast lesions).<sup>3</sup>

The multiphase dynamic contrast-enhanced (DCE) sequences (i.e., pre- and postcontrast T1W, preferably with fat suppression) are the most important images for identifying and characterizing lesions. The number and length of the individual DCE sequences is variable, but each acquisition is required to have high spatial resolution (pixel size of 1 mm or less and slice thickness 3 mm or less) per ACR guidelines. It is essential that the pre- and postcontrast technical parameters are identical so that precontrast images can be subtracted from postcontrast images. This will provide a valid subtracted series from which other post-processed images (e.g., orthogonal plane reformatted images and maximum-intensity projections [MIPs]) can be reconstructed. The protocol sequences and sequence timing should be as consistent as possible from patient to patient, regardless of breast size or body habitus to maximize spatial resolution while including all breast tissue.



It is important to be as efficient as possible, collecting the necessary information in the shortest exam time. Exams that take up to 45 minutes or longer are challenging for patients and increase the chance that the patient will experience discomfort and move, causing motion artifacts and image misregistration. This is particularly problematic for the DCE T1W series set, which is typically acquired last. Motion during the DCE series set can significantly compromise kinetic evaluation, subtracted images, MIPs, and other reformatted images. When appropriately constructed and performed on modern equipment, standard diagnostic breast MRI protocols should be completed within 30 minutes.

## Coils

Per the ACR, a dedicated, bilateral breast coil is required.<sup>2</sup> Modern bilateral breast coils commonly have 7 to 16 channels to improve signal uniformity and intensity.

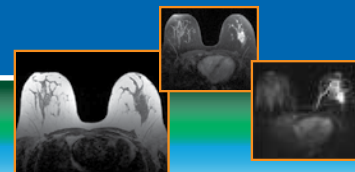
## Contrast

Currently, seven extracellular fluid (ECF) gadolinium-based contrast agents (GBCAs) are being used for breast MRI (**Table 2**). Of these contrast agents, only gadobutrol (Gadavist) has been FDA-approved specifically for use in breast MRI. The other ECF agents shown in **Table 2** are FDA-approved for use in imaging the central nervous system and other body areas/applications, but they are often used “off-label” for breast MRI.

All of the available GBCAs exhibit the same mechanism of action; they increase signal intensity of lesions against background tissue, a phenomenon known as T1-shortening. The degree to which a GBCA can cause T1-shortening is known as relaxivity ( $r_1$ ). At a given molar concentration of GBCA, a higher  $r_1$  relaxivity translates into greater T1-shortening, and subsequently a greater effect of a GBCA on lesion conspicuity and breast cancer detection.<sup>3,4</sup>

For breast MRI, both standard and high-relaxivity contrast agents should be administered at labeled doses of 0.1 millimoles per kilogram (mmol/kg) of body mass and injected at a rate of 2 milliliters per second (mL/s), followed by a 20 mL saline flush injected at the same rate. Use of a power injector to inject both the contrast agent and the saline flush is recommended.

Most of the available ECF contrast agents are formulated at a concentration of 0.5 moles/liter (or 0.5 millimoles/milliliter [mmol/mL]); only gadobutrol (Gadavist) is formulated at a higher concentration of 1.0 mmol/mL. However, the recommended GBCA doses in breast MRI are the same despite the differences in concentration: 2 mL per 10 kg of body weight for a 0.5 mmol/mL GBCA, and 1 mL per 10 kg of body weight for gadobutrol (Gadavist). Using a 150 lb (~68 kg) woman as an example, approximately 14 mL of a 0.5 mmol/mL concentration agent would be recommended, and 7 mL of the 1.0 mmol/mL concentration agent gadobutrol (Gadavist) (i.e., half the volume).

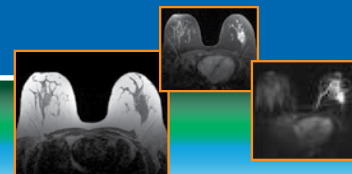


**Table 2: FDA-Approved Extracellular Gadolinium-Based Contrast Agents and Their Properties<sup>5-14</sup>**

Brand Name (Manufacturer) FDA Approval Date	Generic Name	Approved Indications	Approved Dose	Molarity (M, moles per liter)	r1 Relaxivity (mL·mmol <sup>-1</sup> ·s <sup>-1</sup> ) at 1.5T/3.0T in Plasma at 37°C
Magnevist (Bayer Healthcare) 1988	Gadopentetate dimeglumine	CNS, adults & pediatrics (≥2 years of age); Head & neck, adults & pediatrics (≥2 years of age); Body (excluding the heart), adults & pediatrics (≥2 years of age)	0.1 mmol/kg	0.5	4.25 / 3.76
ProHance (Bracco) 1992	Gadoteridol	CNS, adults & pediatrics (>2 years of age); Head and neck, adults	Adults: 0.1 mmol/kg + 2nd dose of 0.2 mmol/kg up to 30 min after 1st dose; pediatrics: 0.1 mmol/kg	0.5	4.39 / 3.46
Omniscan (GE Healthcare) 1993	Gadodiamide	CNS, adults & pediatrics (2-16 years of age); Body (excluding the heart), adults & pediatrics (2-16 years of age)	0.1 mmol/kg	0.5	4.47 / 3.89
OptiMARK (Covidien) 1999	Gadoversetamide	CNS, adults; Liver, adults	0.1 mmol/kg	0.5	4.43 / 4.24
MultiHance (Bracco) 2004	Gadobenate dimeglumine	CNS, adults & pediatrics (including term neonates); MRA in adults, to evaluate known or suspected renal or aorto-ilio-femoral occlusive vascular disease	Adults & pediatrics ≥2 years of age: 0.1 mmol/kg; pediatrics <2 years of age: 0.05-0.1 mmol/kg (ie, 0.1-0.2 mL/kg) (CNS)	0.5	6.2 / 5.37
Gadavist (Bayer Healthcare) 2011	Gadobutrol	CNS, adults & pediatrics (including term neonates); Assess presence and extent of malignant breast disease; MRA to evaluate known or suspected supra-aortic or renal artery disease in adult & pediatrics (including term neonates)	0.1 mmol/kg	1.0	4.61 / 4.46
Dotarem (Guerbet) 2013 Clariscan (GE Healthcare) 2013	Gadoterate meglumine	CNS, adults & pediatrics (including term neonates)*	0.1 mmol/kg	0.5	3.91 / 3.43

CNS = central nervous system; MRA = magnetic resonance angiography.

\*Approval for use in term neonates is limited to Dotarem. Clariscan approved for pediatric patients aged 2 to 17 years.



## Image Interpretation

Image interpretation steps include:

1. Identification of enhancing lesions separate from background parenchymal enhancement.
2. Characterization of morphologic characteristics of identified lesions according to the latest version of the *ACR Breast Imaging Reporting and Data System (BI-RADS) Atlas*.<sup>15</sup>
3. Evaluation of temporal kinetics of identified lesions according to the *ACR BI-RADS Atlas*.
4. Use of both morphology and kinetics to make a recommendation regarding level of suspicion according to the *ACR BI-RADS Atlas*.

## Computer-aided Evaluation (CAE) Systems

Several computer-aided evaluation (CAE) systems are available for breast MRI. CAE for breast MRI, unlike computer-aided detection (CAD) for mammography, does not direct the interpreting radiologist to potentially suspicious lesions; rather, it aids in evaluation of lesion kinetics and overall assessment of the degree of suspicion. CAE provides a convenient and efficient way to visually and quantitatively assess temporal kinetic information by providing color overlay maps and time-signal intensity curves of enhancing lesions.

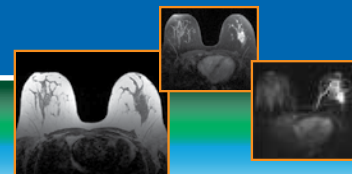
With modern CAE systems, images are sent from the MR system to the picture archiving and communication system (PACS) and the CAE system, where color overlay maps, kinetic analyses, image subtractions, and multiplanar and MIP reconstructions are performed. When the radiologist identifies a suspicious area of enhancement, the CAE software provides information on lesion size, degree of early-phase enhancement, and the signal-intensity time course including the delayed-phase enhancement pattern (persistent, plateau, wash-out), which correlates with degree of suspicion of breast cancer.<sup>16</sup>

Note that CAE systems impose a delay between receipt of images from the MR or PACS system and availability of processed results to the radiologist. Importantly, CAE-subtracted images and temporal kinetic evaluation are susceptible to patient motion between pre- and postcontrast images; if unrecognized as motion artifacts, it is possible to misinterpret displaced tissue color maps or signal-intensity time curves as enhancing lesions. All or most CAE systems have motion correction algorithms, but they are not perfect, and evaluation by the interpreting radiologist requires assessment of the pre- and postcontrast images for motion to avoid these mistakes.

Use of CAE temporal kinetic color overlay maps alone can lead to overestimation or underestimation of the degree of suspicion of a lesion due to the overlap in the kinetics of benign and malignant lesions, as well as misinterpretation of artifacts created by patient motion. For example, unrecognized motion can result in “wash-out” kinetics and overestimation of lesion suspicion, while the lack of the more concerning plateau or wash-out delayed-phase enhancement patterns on CAE can cause underestimation of the level of suspicion for small, low-grade, or non-mass-like lesions such as ductal carcinoma in situ (DCIS). If a lesion has suspicious morphologic features, the level of suspicion generated by the concerning morphologic features should not be diminished by the presence of a less suspicious temporal kinetic signal-intensity time course, such as persistent delayed-phase enhancement.

CAE color map thresholds for standard agents (such as gadopentetate dimeglumine [Magnevist]) should be set at values of 50% and 100% signal enhancement above precontrast levels, whereas a high-relaxivity agent (such as gadobenate dimeglumine [MultiHance]), may require color map thresholds to be set at 100% and 200% signal enhancement levels. Systems that allow for real-time adjustment of CAE thresholds may allow more flexibility (e.g., using several thresholds, such as 50%, 100%, 150%, and 200%). It is especially important to make the color map threshold adjustment if CAE images from an exam performed with a high-relaxivity agent are being compared to CAE images from an exam performed with a conventional-relaxivity agent in the same patient. There is usually no need to make additional adjustments to CAE thresholds when changing between breast MRI exams performed at 1.5T and 3T.





## *Tips for Maximizing Sensitivity and Specificity*

To maximize sensitivity, it is important to acquire multiphase T1W images with high spatial resolution (i.e., sub-millimeter in-plane resolution in the frequency- and phase-encoding directions) to obtain morphologic detail, including lesion shape, margin, and internal enhancement pattern. It is also important to acquire thin slices; if the slices are not sufficiently thin, there is the risk of volume-averaging small, subtle lesions with background tissue, decreasing their lesion conspicuity. In addition, the use of thin slices (nearly isotropic voxels, where the slice thickness is nearly as small as the in-plane resolution) allows image reconstruction in any plane while maintaining approximately the same spatial resolution as acquired in-plane images. On the other hand, pixel size and slice thickness should not be so small that signal-to-noise ratios suffer. Finally, radiologists should identify enhancing lesions on the early-phase postcontrast or subtracted images, where the signal difference between enhancing lesions and background parenchyma is greatest.

To maximize specificity, kinetics should be obtained with a temporal resolution of 3 minutes or less (that is, each series in the multiphase set should be acquired in 3 minutes or less). While there are studies showing that proper lesion time-intensity curve shape can be captured with 2 minute and 3 minute temporal resolution,<sup>17,18</sup> there are no data to suggest that curve shapes are captured correctly with longer acquisition times. Conversely, there is a trade-off between temporal resolution and signal-to-noise, just as there is between temporal resolution and spatial resolution.<sup>17</sup> Using very rapid acquisitions, just like using excessively small voxels, can reduce signal-to-noise ratios to the extent that enhancing lesions, especially non-mass-like lesions, are not detected. More recent advanced MRI sequences allow for faster acquisitions without traditional compromises in spatial resolution using undersampling and advanced reconstruction techniques such as view-sharing and compressed sensing. However, all of these techniques have trade-offs, and most are not routinely used in clinical practice.

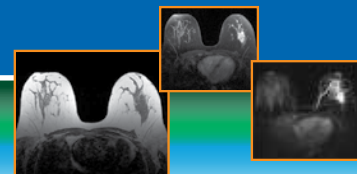
It is beneficial to evaluate the breasts in at least one additional imaging plane beyond the primary acquisition plane (e.g., if the primary image acquisition plane is axial, be sure to also evaluate sagittal reformatted images). Again, it is most beneficial to do this in the early-phase of contrast enhancement, where the contrast difference between enhancing lesions and background parenchyma is greatest. Therefore, reconstruction of images in other planes from early-phase images acquired with isotropic or nearly isotropic voxels is most beneficial for this analysis and shortens the overall scan time (instead of acquiring additional postcontrast series in additional scan planes after the multiphase T1W series has been acquired).

## *Breast MR: Practical Considerations*

There are no additional MR safety considerations specific to breast MRI; the biggest safety hazard while performing breast MR, like other MR exams, is the inadvertent introduction of ferromagnetic materials (iron-, nickel-, or cobalt-containing metals) into the scanner room. Such metals may be implanted in the patient, worn by the patient, or inadvertently brought in by the patient, someone accompanying the patient, or by a physician, technologist, or maintenance personnel. Ferromagnetic materials near the bore of the scanner are rapidly accelerated into the scanner bore and can severely injure the patient or others in the scan room. Additional considerations include burns. The MR safe practice guidelines developed by the ACR to establish industry standards for safe and responsible practices in clinical and research MR environments also apply to breast MRI.<sup>19</sup>

In addition, as for other contrast-enhanced MR exams, women undergoing breast MR exams may need to be screened for adequate renal function (glomerular filtration rate) prior to performing the breast MR exam, per institutional and ACR guidelines.<sup>20</sup>

Additional practical considerations include patient size and patient breast size. Larger patients may not fit into the scanner itself, particularly when positioned on the breast coil. Very large or very small breasts may not fit well in the breast coil, and good breast positioning, including as much breast tissue in the breast coil as possible, is important for optimal image acquisition and interpretation.<sup>21</sup> Technologists performing breast MRI should take care to ensure that as much breast tissue as possible is positioned inside the breast coils, that breast positioning is as symmetric as possible between the left and right breasts, and that the nipple is positioned centrally and symmetrically in each breast. It is particularly important to make sure that the nipple is not folded inside other breast tissue. It also is important to stabilize the breast to minimize motion, while at the same time avoiding compression and deformation of the breast. Radiologic technologists performing breast MR should be trained on proper breast positioning,<sup>21</sup> and experienced technologists and coil manufacturer applications specialists can be helpful in providing such training. In addition, the ACR Breast MRI Accreditation Program requirements for technologist experience and training should be reviewed and followed.<sup>2</sup>



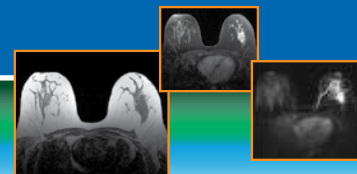
## **Abbreviated Breast MRI (AB-MR)**

AB-MR is a new protocol for screening women at elevated risk of breast cancer.<sup>22,23</sup> It is a short scanning protocol consisting of scout images, a precontrast T1W series covering both breasts, contrast injection and a brief (20-45 second) delay to permit perfusion of contrast agent, followed by an identical postcontrast series. The entire acquisition protocol should require no more than 5 minutes of scanning.<sup>24</sup> If a precontrast T2W series is acquired to assist the radiologist with differential diagnosis, it should be optimized to minimize and not excessively increase scan time. Image post-processing should include subtraction of pre- from postcontrast images and reconstruction of MIP images. Image acquisition techniques for pre- and postcontrast T1W images should follow the same optimization procedures as those used for dynamic breast MRI, with the exception that only a single postcontrast series is acquired. Initial clinical results for AB-MR show high sensitivity and specificity, comparable to those of the full dynamic protocol used for diagnostic breast MRI.<sup>22,23,25-32</sup> Further studies are underway to study the utility of AB-MR in women with dense breasts.<sup>32</sup>

## **Additional Tips for Technologists Performing Breast MRI:**

Every effort should be made to ensure the patient is comfortable in the prone positioning used for breast MRI. This includes proper head support, adequate padding between the sternal notch and the breast coil, where a large portion of the patient's weight is supported, and positioning arms and legs comfortably with pillows, as needed.

- During patient positioning, make sure that IV contrast lines remain unknicked and positioned for maximum comfort and flow at the injection site
- Make sure that the appropriate patient positioning (head-first prone or feet-first prone) is entered during patient data entry. Incorrectly entering supine instead of prone, or reversing head-first and feet-first, will reverse left and right on the images, which can lead to identification of lesions in the wrong breast during interpretation. Breast MRI patients imaged on GE (and Aurora) scanners are typically positioned feet-first prone (FFP), while patients imaged on Siemens and most other manufacturers' scanners are typically positioned head-first prone (HFP)
- Always inform the patient about the importance of not moving during scanning and not moving between pre- and postcontrast multiphase T1W series. This is best done prior to the precontrast series, rather than just prior to injection, to avoid causing the patient to startle and move between pre- and postcontrast series, which affects the registration of subtracted images. Advice about the injection is best given prior to the precontrast series
- If fat suppression is being used for the multiphase T1W images, always check precontrast images for adequate fat suppression prior to injection of contrast agent. Some sites insert a very fast "fat-sat check" precontrast series to assess fat suppression prior to the multiphase series that includes the full precontrast, injection, and postcontrast series
- Always check postcontrast images as soon as possible to confirm that contrast agent injection was successful. This is best done by comparing precontrast and postcontrast images viewed with similar window width and level settings and looking for the presence of contrast agent in the heart and internal mammary vessels. If contrast agent is not visible in postcontrast images, the patient injection site should be checked for extravasation of contrast agent into tissues surrounding the injection site, failure to inject into the patient (i.e., the contrast agent is on the table), and failure of the power injector, including loading of contrast agent and saline. If contrast agent appears not to have been injected, a second attempt at the multiphase series may be feasible; if agent was injected but does not appear on the images, the woman may need to be rescheduled for the exam. In either case, the attending radiologist should be consulted
- Checking enhancement in the heart on postcontrast images also affords the opportunity to double-check that proper patient positioning was entered by confirming that the heart is on the left side of the body, although rare exceptions to this rule do occur (about 1 in 12,000 women have dextrocardia, where their heart is on the right)
- All images should be checked for image quality and patient motion prior to termination of the exam. If image quality problems occur, the attending radiologist or interpreting radiologist should be consulted
- If problems with positioning, contrast agent administration, or image acquisitions occur, the appropriate supervising radiologist or interpreting breast MRI radiologist should be notified. Any problems or issues complicating the exam should be clearly communicated to the interpreting radiologist as soon as possible

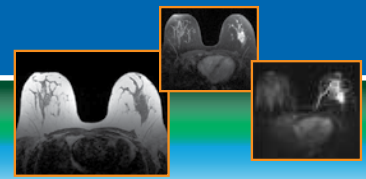


### Summary

Breast MRI is one of the most technically challenging clinical applications of MR imaging. Only with modern MR equipment, optimized breast imaging protocols, careful attention to patient comfort, patient positioning, proper administration of contrast agent and proper imaging by the MR technologist, and appropriate image display, post-processing, and interpretation by the radiologist, can the sensitivity and specificity of breast MRI for cancer be maximized.

### References

1. Rausch DR, Hendrick RE. How to optimize clinical breast MR imaging practices and techniques on your 1.5-T system. *Radiographics*. 2006;26:1469-1484.
2. Breast Magnetic Resonance Imaging (MRI) Accreditation Program Requirements. Revised October 4, 2017. <https://www.acraccreditation.org/~media/ACRAccreditation/Documents/Breast-MRI/Requirements.pdf?la=en>. Accessed November 17, 2019.
3. Hendrick RE. *Breast MRI: Fundamentals and Technical Aspects*. New York: Springer; 2008.
4. Martincich L, Faivre-Pierret M, Zechmann CM, et al. Multicenter, double-blind, randomized, intraindividual crossover comparison of gadobenate dimeglumine and gadopentetate dimeglumine for breast MR imaging (DETECT Trial). *Radiology*. 2011;258:396-408.
5. Magnevist (gadopentetate dimeglumine) injection [prescribing information]. Whippany, NJ: Bayer HealthCare Pharmaceuticals Inc.; revised July 2018. [https://www.accessdata.fda.gov/drugsatfda\\_docs/label/2018/021037s037s038lbl.pdf](https://www.accessdata.fda.gov/drugsatfda_docs/label/2018/021037s037s038lbl.pdf). Accessed November 20, 2019.
6. ProHance (gadoteridol) injection [prescribing information]. Monroe Township, NJ: Bracco Diagnostics Inc.; revised April 2018. [https://www.accessdata.fda.gov/drugsatfda\\_docs/label/2018/020131s028lbl.pdf](https://www.accessdata.fda.gov/drugsatfda_docs/label/2018/020131s028lbl.pdf). Accessed November 20, 2019.
7. Omniscan (gadodiamide) injection [prescribing information]. Marlborough, MA: GE Healthcare Inc.; revised November 11, 2019. <https://rxdruglabels.com/lib/rx/rx-meds/omniscan/>. Accessed November 20, 2019.
8. OptiMARK (gadoversetamide) injection [prescribing information]. Princeton, NJ: Guerbet LLC; revised April 2018. [https://www.accessdata.fda.gov/drugsatfda\\_docs/label/2018/020976s029lbl.pdf](https://www.accessdata.fda.gov/drugsatfda_docs/label/2018/020976s029lbl.pdf). Accessed November 20, 2019.
9. MultiHance (gadobenate dimeglumine) injection [prescribing information]. Monroe Township, NJ: Bracco Diagnostics Inc.; revised April 2018. [https://www.accessdata.fda.gov/drugsatfda\\_docs/label/2018/021357s016s017,021358s015s016lbl.pdf](https://www.accessdata.fda.gov/drugsatfda_docs/label/2018/021357s016s017,021358s015s016lbl.pdf). Accessed November 20, 2019.
10. Gadavist (gadobutrol) injection [prescribing information]. Whippany, NJ: Bayer Healthcare Pharmaceuticals Inc.; revised July 2019. [https://www.accessdata.fda.gov/drugsatfda\\_docs/label/2019/201277s017lbl.pdf](https://www.accessdata.fda.gov/drugsatfda_docs/label/2019/201277s017lbl.pdf). Accessed November 20, 2019.
11. Dotarem (gadoterate meglumine) injection [prescribing information]. Princeton, NJ: Guerbet LLC; revised April 2018. [https://www.accessdata.fda.gov/drugsatfda\\_docs/label/2018/204781s008lbl.pdf](https://www.accessdata.fda.gov/drugsatfda_docs/label/2018/204781s008lbl.pdf). Accessed November 20, 2019.
12. Clariscan (gadoterate meglumine) injection [prescribing information]. Marlborough, MA: GE Healthcare Inc.; revised November 2019. <https://www.gehealthcare.com/-mediaA4F1C1C8F50D489387BF91292DBA5629.pdf>. Accessed December 6, 2019.
13. Rohrer M, Bauer H, Mintorovitch J, Requardt M, Weinmann HJ. Comparison of magnetic properties of MRI contrast media solutions at different magnetic field strengths. *Invest Radiol*. 2005;40(11):715-724.



14. Shen Y, Goerner FL, Snyder C, et al. T1 relaxivities of gadolinium-based magnetic resonance contrast agents in human whole blood at 1.5, 3, and 7 T. *Invest Radiol*. 2015;50:330-338.
15. Morris EA, Comstock CE, Lee CH, et al. ACR BI-RADS Magnetic Resonance Imaging. In: *ACR BI-RADS Atlas, Breast Imaging Reporting and Data System*. Reston, VA: American College of Radiology; 2013.
16. Kuhl CK, Mielcarek P, Klaschik S, et al. Dynamic breast MR imaging: are signal intensity time course data useful for differential diagnosis of enhancing lesions? *Radiology*. 1999;211:101-110.
17. Kuhl CK, Schild HH, Morakkabati N. Dynamic bilateral contrast-enhanced MR imaging of the breast: trade-off between spatial and temporal resolution. *Radiology*. 2005;236:789-800.
18. Gutierrez RL, Strigel RM, Partridge SC, et al. Dynamic breast MRI: does lower temporal resolution negatively affect clinical kinetic analysis? *Am J Roentgenol*. 2012;199:703-708.
19. Expert Panel on MR Safety: Kanal E, et al. ACR guidance document on MR safe practices: 2013. *J Magn Reson Imaging*. 2013;37:501-530.
20. American College of Radiology (ACR). *ACR Manual on Contrast Media*. 2018; version 10.3, 2018. [https://www.acr.org/~media/ACR/Documents/PDF/QualitySafety/Resources/Contrast-Manual/Contrast\\_Media.pdf?la=en](https://www.acr.org/~media/ACR/Documents/PDF/QualitySafety/Resources/Contrast-Manual/Contrast_Media.pdf?la=en). Accessed November 20, 2019.
21. Yeh ED, Georgian-Smith D, Raza S, et al. Positioning in breast MR imaging to optimize image quality. *Radiographics*. 2014;34:E1-E17.
22. Kuhl CK, Schrading S, Strobel K, Schild HH, Hilgers RD, Bieling HB. Abbreviated breast magnetic resonance imaging (MRI): first postcontrast subtracted images and maximum-intensity projection—a novel approach to breast cancer screening with MRI. *J Clin Oncol*. 2014;32:2304-2310.
23. Hendrick RE. Techniques for performing abbreviated breast magnetic resonance imaging. In: Comstock CE, Kuhl CK, eds. *Abbreviated MRI of the Breast: A Practical Guide*. New York, NY: Thieme Medical Publishers, Inc.; 2018:45-64.
24. Mango VL, Morris EA, Dershaw DD, et al. Abbreviated protocol for breast MRI: are multiple sequences needed for cancer detection? *Eur J Radiol*. 2015;84:65-70.
25. Heacock L, Melsaether AN, Heller SL, et al. Evaluation of a known breast cancer using an abbreviated breast MRI protocol: correlation of imaging characteristics and pathology with lesion detection and conspicuity. *Eur J Radiol*. 2015;85:815-823.
26. Grimm LJ, Soo MS, Yoon S, Kim C, Ghate SV, Johnson KS. Abbreviated screening protocol for breast MRI: a feasibility study. *Acad Radiol*. 2015;22:1157-1162.
27. Harvey SC, Di Carlo PA, Lee B, Obadina E, Sippo D, Mullen L. An abbreviated protocol for high-risk screening breast MRI saves time and resources. *J Am Coll Radiol*. 2016;13:R74-R80.
28. Moschetta M, Telegrafo M, Rella L, Stabile Ianora A, Angelelli G. Abbreviated combined MR protocol: a new faster strategy for characterizing breast lesions. *Clin Breast Cancer*. 2016;16:207-211.
29. Oldrini G, Derraz I, Marchal F, Henrot P. Impact of an abbreviated protocol for breast MRI in diagnostic accuracy. *Diagn Interv Radiol*. 2018;24:12-16.
30. Choi BH, Choi N, Kim MY, Yang JH, Yoo YB, Jung HK. Usefulness of abbreviated breast MRI screening for women with a personal history of breast cancer. *Breast Cancer Res Treat*. 2018;167:495-502.
31. Greenwood HI. Abbreviated protocol breast MRI: the past, present, and future. *Clin Imaging*. 2019;53:169-173.
32. Kuhl CL. Abbreviated breast MRI for screening women with dense breast: the EA1141 trial. *Br J Radiol*. 2018;90:20170441.