

CANINE INSULINOMA: DIAGNOSIS, TREATMENT, & STAGING

Eliza Reiss Grant, DVM, and Kristine E. Burgess, DVM, Diplomate ACVIM (Oncology)
Tufts University

An insulinoma is a malignant pancreatic tumor that inappropriately secretes excessive insulin, resulting in profound hypoglycemia.¹

Pancreatic tumors are classified as:

- **Exocrine**, which includes adenocarcinomas of ductular or acinar origin
- **Endocrine**, which arise from the islets of Langerhans.

Insulinomas are functional neuroendocrine tumors that originate in the beta cells of the islets of Langerhans.¹

PRESENTATION

Signalment

Any breed of dog can be affected, but large breeds tend to be overrepresented.¹ While, in humans, insulinomas affect females far more frequently than males, there is no apparent sex predilection in dogs.¹⁻³ Dogs also commonly present with a malignant variant, while humans often have a benign adenoma (80%).¹ Insulinoma is rare in cats.⁴

Clinical Signs

Most affected dogs do not have abnormalities on physical examination, and early clinical signs related to the disease can be sporadic and vague.

Classically, dogs present with signs attributable to hypoglycemia, such as weakness, ataxia, extreme fatigue after exercise, and collapsing episodes. Seizures can occur later in the disease process and increase progressively in frequency and intensity over time.¹

Hypoglycemic episodes are often precipitated by exercise or fasting (increased glucose utilization) as well as by the ingestion of food (stimulation of insulin release). Intravenous or oral administration of glucose alleviates clinical signs. If prolonged seizure activity occurs, cerebral laminar necrosis can ensue.

DIAGNOSIS

Aside from a histologic confirmation of insulinoma, no currently available diagnostic test provides a definitive diagnosis of insulinoma. Existing techniques may help increase suspicion for an insulin-secreting tumor but, with most diagnostic testing, it is imperative to interpret all results in the context of the coexisting clinical signs.

Differential Diagnosis

A complete work-up, including careful patient history, physical examination, bloodwork, and diagnostic imaging tests, should be performed to rule out other causes of hypoglycemia, such as sepsis, hepatic failure, adrenal cortical insufficiency, toxin ingestion, and other forms of neoplasia.

Laboratory Tests

Blood Glucose

A simple fasting blood glucose level of less than 40 mg/dL can suggest hyperinsulinemia, although careful monitoring of a fasted dog with suspected insulinoma is strongly recommended due to high risk for seizure activity.

Insulin-to-Glucose Ratio

Additional blood analysis evaluating the amended insulin-to-glucose ratio (AIGR) may be warranted.

- This assay capitalizes on the lack of response to physiologic negative feedback inhibitory loops that decrease insulin secretion in the face of hypoglycemia in dogs with an insulinoma.
- A positive insulin-to-glucose ratio demonstrates an inappropriately elevated insulin level in the setting of hypoglycemia.¹
- Nevertheless, an elevated AIGR is neither sensitive nor specific for the diagnosis of insulinoma. The AIGR can be elevated from insulin-producing tumors other than insulinoma or normal in dogs with insulinoma.

- This test can be performed on serum samples and submitted to most large commercial laboratories.

Serum Fructosamine

Serum fructosamine can indicate insulinoma as it may be low in dogs with chronic or episodic hypoglycemia. However, this assay is not specific and should never be considered a confirmatory test.

Imaging

Radiography & Ultrasound

Thoracic radiography and abdominal ultrasound are recommended to assess for the presence of a possible pancreatic mass and associated metastatic disease (eg, lymph nodes, liver, lungs). Although abdominal ultrasound is considered a relatively insensitive and nonspecific assessment for insuli-

noma, it is recommended to rule out other causes of hypoglycemia. In addition, some insulinomas are large enough to be detected on ultrasound (**Figure 1**).

Advanced Imaging

Conventional computed tomography (CT) with contrast has an improved sensitivity of 71% for pancreatic lesions.⁵ Most recently, dual-phase CT angiography has been reported to successfully localize pancreatic lesions and stage patients before surgery (**Figure 2**).⁶

Further Diagnostics

Some insulinomas are challenging to localize even on advanced imaging, and a lack of definitive identification of the tumor on preoperative imaging should not discredit a working diagnosis of insulinoma. In some instances, an exploratory laparotomy may be recommended when there is a strong clinical suspicion for insulinoma in the absence of visible disease.

TREATMENT

Surgical Management

In patients with hypoglycemia and inappropriate insulin production, exploratory abdominal surgery is the recommended treatment. Surgical removal of the tumor:

- Provides the best chance for relief of clinical signs and the best survival times^{1,2,7}
- Allows complete staging via biopsy of regional lymph nodes and liver to determine the extent of suspected metastatic disease.

Metastatic Disease

Because dogs commonly have a malignant form of insulinoma, approximately half will have metastatic disease detected before or at the time of surgery. Nevertheless, surgery is still indicated in patients with suspected or confirmed metastatic disease because removal of metastatic disease reduces the extent of aberrant insulin secretion and may improve clinical signs.^{1,3}

Surgical Approach

Most insulinomas are solitary masses that can be detected intraoperatively with gentle palpation of the pancreas. Intraoperative ultrasound with IV 1% methylene blue has been used for additional visualization of the pancreatic lesion but is of questionable value.

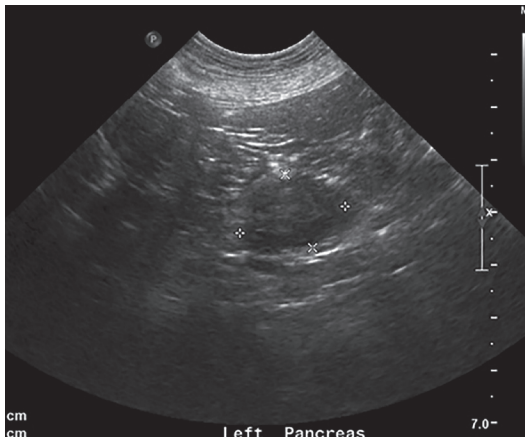

FIGURE 1. Ultrasound image of mass lesion within the left wing of the pancreas. Approximately 50% of insulinomas are not visualized by this technique.

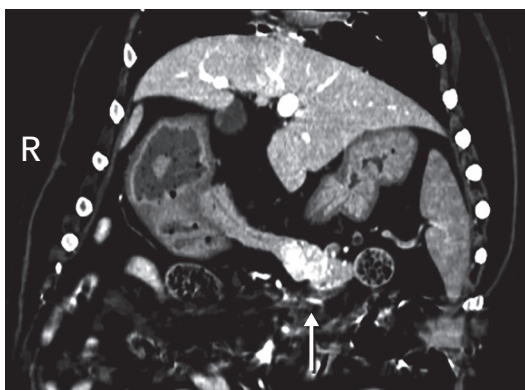


FIGURE 2. Arterial phase dorsal oblique computed tomography (CT) reconstruction (soft tissue algorithm) of a pancreatic mass (**arrow**). CT angiography is a more sensitive imaging modality for insulinoma.

Partial pancreatectomy is the preferred procedure, with pancreatitis as a possible postoperative complication. Other complications include ongoing hypoglycemia, diabetes mellitus causing hyperglycemia, and neurologic complications from historic neuroglycopenia. Those with persistent hyperglycemia after surgery should be treated as diabetic until they are no longer insulin dependent.

Stabilization

Hypoglycemic patients should be stabilized with IV dextrose supplementation. In a crisis situation, IV dextrose should be given slowly so that further insulin release is not stimulated. Glucagon, a peptide hormone produced by the pancreas, opposes the effects of insulin by raising blood glucose. It has been used to stabilize hypoglycemia in a crisis setting when given as a constant rate infusion at approximately 10 to 15 ng/kg per minute.⁸

Medical Management

Medical management of insulinoma is possible in patients:

- That are not good surgical candidates
- Whose owners are not interested in pursuing surgery

- That have persistent hypoglycemia after surgery.

This approach includes dietary management as well as medications, such as prednisone, diazoxide, and octreotide.^{1,2,7}

Dietary Management

The goal of dietary management is to maintain appropriate blood glucose levels throughout the day and avoid foods that may incite a spike in insulin release. This is achieved by feeding multiple small meals throughout the day and using foods that are high in protein, fat, and complex carbohydrates.

Oral prednisone can be used as an adjunctive therapy because glucocorticoids decrease insulin sensitivity and increase endogenous (hepatic) glucose production. Prednisone can be dosed to effect in the range of 0.5 to 4 mg/kg Q 24 H.^{1,2}

Diazoxide

Diazoxide is used in the medical management of hypoglycemia to inhibit the intracellular release of ionized calcium, thereby preventing the exocytosis release of insulin by the beta cells. It also contributes to hyperglycemia through its ability to stimulate the release of epinephrine. Diazoxide is commonly instituted in patients that do not respond to dietary management and prednisone.

INSULINOMA: Staging & Prognosis

Insulinoma is classified as:

- **Stage I:** Insulinoma confined to pancreas
- **Stage II:** Insulinoma with regional lymph node metastasis
- **Stage III:** Insulinoma with distant metastasis.

Reported insulinoma survival times are listed in the **Table**.

TABLE.

Insulinoma Survival Times Reported in the Literature: 1993 – 2013

OVERALL	MEDICAL MANAGEMENT	SURGICAL MANAGEMENT	ADJUVANT THERAPY (STREPTOZOTOCIN)
Polton et al (2007)² MST: Stage I: 785 d Stage II: 547 d Stage III: 217 d Trifonidou et al (1998)³ MST: 258 d MDFI: 244 d	Polton et al (2007)² MST: 196 d Tobin et al (1999)⁷ MST: 74 d	Polton et al (2007)² MST: 785 d Tobin et al (1999)⁷ MST: 381 d Dunn et al (1993)¹⁶ MST: 14 mo	Northrup et al (2013)¹² (all stages): MPFS: 196 d MST: 308 d Moore et al (2002)¹¹ (stage II or III) MTN: 163 d

MDFI = median disease free interval; MPFS = median progression free survival; MST = median survival time; MTN = median time of normoglycemia

The dose of diazoxide for dogs with insulinoma and refractory hypoglycemia has been reported to be 5 to 10 mg/kg PO Q 12 H.^{1,7} The ideal dose for a clinical patient can be determined on the basis of successful management of clinical signs.

Octreotide

Octreotide is also used to manage hypoglycemia in both humans and dogs with insulinoma. This somatostatin analog can be given as an SC, IM, or IV injection. Inhibition of insulin release is one of somatostatin's many physiologic actions, and scattered reports of efficacy in dogs exist in the veterinary literature.⁹

One study of 10 dogs with insulinoma demonstrated an increase in plasma glucose and decrease in plasma insulin after SC administration of octreotide, with successful binding of the canine somatostatin receptor.¹⁰ However, in a controlled study of 3 dogs that received octreotide and a placebo (physiologic saline), no significant difference in insulin or glucose concentrations was noted.⁹ One dog in the group did experience an improved blood glucose compared with placebo at 8 hours after administration of octreotide, suggesting that some patients may have a clinical benefit.⁹

Management of Metastatic Disease

Streptozotocin

The veterinary oncology literature has reported on streptozotocin as the adjuvant therapy for recurrent or metastatic insulinoma. Streptozotocin is an alkylating agent that is structurally similar to glucose and is selectively taken up by the GLUT2 transporter. This transporter is found in high levels on pancreatic beta cells, causing cytotoxicity.

While streptozotocin has not provided a statistically significant longer survival in canine patients, objective responses have been documented; in 2 patients with paraneoplastic peripheral neuropathy, neurologic signs resolved with this treatment.¹¹

Streptozotocin can be given to dogs at a dosage of 500 mg/m² every 2 to 3 weeks. Due to an elevated risk for renal tubular necrosis, saline diureses for 7 hours (3 hours before administering the drug and 2 hours after discontinuation of the drug) is recommended.

Other adverse effects of streptozotocin reported in the veterinary literature include vomiting, reversible elevations in alanine aminotransferase (with discontinuation of the drug), and diabetes mellitus. In a recent study of biweekly streptozotocin, 6 of 19 dogs developed diabetes mellitus, resulting in death or euthanasia.¹²

Tyrosine Kinase Inhibitors

Recently, there has been interest in evaluating the efficacy of tyrosine kinase inhibitors, such as toceranib phosphate (Palladia, pfizer.com), for dogs with insulinoma. This interest is based on studies evaluating sunitinib, a human multitargeted tyrosine kinase inhibitor, which has proven efficacy in phase II trials of humans with pancreatic neuroendocrine tumors.^{13,14} Anecdotally, we have experienced antitumor activity with toceranib phosphate in dogs with insulinomas in the measurable disease setting.

Toceranib phosphate is well tolerated at a dose of 2.75 mg/kg PO Q 48 H. The most common adverse effects are gastrointestinal (diarrhea, decreased appetite, nausea), with myelosuppression and proteinuria¹⁵ being less common but well-documented adverse effects.

IN SUMMARY

Insulinoma is an uncommon malignant neoplasia in dogs that can result in significant illness, seizures, and death.

- Patients often present with clinical signs attributable to hypoglycemia.
- Diagnostics should include baseline bloodwork and imaging tests to rule out other causes of hypoglycemia.



ELIZA REISS GRANT

Eliza Reiss Grant, DVM, is a medical oncology resident at Tufts Cummings School of Veterinary Medicine. She received her veterinary degree from Tufts University and completed an internship at Angell Animal Medicine Center. Her interests include canine lymphoma and tumor genomics.



KRISTINE E. BURGESS

Kristine E. Burgess, DVM, Diplomate ACVIM (Oncology), is an assistant professor in oncology at Tufts University Cummings School of Veterinary Medicine. She received her veterinary degree from Tufts University, and completed an internship at VCA West Los Angeles Animal Hospital and residency in oncology at University of Wisconsin—Madison. Dr. Burgess' interests include comparative oncology with a special interest in canine lymphoma.



- Thoracic radiography and abdominal ultrasound are recommended but are frequently unrewarding.
- Dual-phase CT angiography may be the best imaging study to diagnose insulinoma.
- Surgery is recommended and provides the best reported survival times.
- Medical management with dietary change, prednisone, diazoxide, and octreotide is possible.
- Streptozotocin is a reasonable adjuvant chemotherapy for patients with metastatic or recurrent insulinoma but is nephrotoxic, causes diabetes mellitus in some patients, and should be used with caution.
- Toleranib phosphate has not been formally studied in dogs with insulinoma but, on the basis of data in human studies, it may be an effective and well-tolerated treatment option.

AIGR = amended insulin-to-glucose ratio; CT = computed tomography

References

1. Goutal CM, Brugmann BL, Ryan KA. Insulinoma in dogs: A review. *JAAHA* 2012; 48:151-163.
2. Polton GA, White RN, Brearley MJ, Eastwood JM. Improved survival in a retrospective cohort of 28 dogs with insulinoma. *J Sm Anim Prac* 2007; 48(3):151-156.
3. Trifonidou MA, Kirpensteijn J, Robben JH. A retrospective evaluation of 51 dogs with insulinoma. *Vet Q* 1998; 20(1):S114-S115.
4. Elie MS, Zerbe CA. Insulinoma in dogs, cats and ferrets. *Comp Cont Edu Pract Vet* 1995; 17(1):51-59.
5. Robben JH, Pollak YW, Kirpensteijn J, et al. Comparison of ultrasonography, computed tomography, and single-photon emission computed tomography for the detection and localization of canine insulinoma. *J Vet Intern Med* 2005; 19:15-22.
6. Mai W, Caceres AV. Dual-phase computed tomographic angiography in three dogs with pancreatic insulinoma. *Vet Rad US* 2008; 49(2):141-148.
7. Tobin RL, Nelson RW, Lucroy MD, et al. Outcome of surgical versus medical treatment of dogs with beta cell neoplasia: 39 cases (1990-1997). *JAVMA* 1999; 215(2):226-230.
8. Fischer JR, Smith SA, Harkin KR. Glucagon constant-rate infusion: A novel strategy for the management of hyperinsulinemic-hypoglycemic crisis in the dog. *JAAHA* 2000; 36(1):27-32.
9. Simpson KW, Stepien RL, Elwood CM, et al. Evaluation of the long-acting somatostatin analogue octreotide in the management of insulinoma in three dogs. *J Sm Anim Prac* 1995; 36:161-165.
10. Robben JH, Visser-Wisselaar HA, Rutterman GR, et al. *In vitro* and *in vivo* detection of functional somatostatin receptors in canine insulinomas. *J Nuc Med* 1997; 38(7):1036-1042.
11. Moore AS, Nelson RW, Henry CJ, et al. Streptozocin for treatment of pancreatic islet cell tumors in dogs: 17 cases (1989-1999). *JAVMA* 2002; 221(6):811-818.
12. Northrup NC, Rassnick KM, Gieger TL, et al. Prospective evaluation of biweekly streptozotocin in 19 dogs with insulinoma. *J Vet Intern Med* 2013; 27(3):483-490.
13. Fjallskog MLH, Lejonklou MH, Oberg KE, et al. Expression of molecular targets for tyrosine kinase receptor antagonists in malignant endocrine pancreatic tumors. *Clin Canc Res* 2003; 9:1469-1473.
14. Papadimitrakou F, Syrigos KN. Sunitinib: A multitargeted receptor tyrosine kinase inhibitor in the era of molecular cancer therapies. *BioDrugs* 2009; 23(6):377-389.
15. Tjostheim SS, Stepien RL, Markovic LE, et al. Effects of toceranib phosphate on systolic blood pressure and proteinuria in dogs. *J Vet Intern Med* 2016 [epub ahead of print].
16. Dunn JK, Bostock DE, Herrtage ME, et al. Insulin-secreting tumours of the canine pancreas: Clinical and pathological features of 11 cases. *J Sm Anim Prac* 1993; 34:325-331.