


Capnography in critical care medicine

Case studies in capnography



Introduction

This publication is intended to illustrate the clinical utility of capnography in the Critical Care areas. The cases presented are based on actual situations in which capnography provided continuous, non-invasive information that alerted healthcare professionals to unexpected changes in a patient's metabolic, cardiopulmonary and ventilatory status.

Case study

Page

Post-op coronary artery bypass patient weaning from mechanical ventilation	1
Patient with ARDS from septic shock requiring mechanical ventilation	2
Using the PaCO ₂ – PETCO ₂ gradient to optimize PEEP in a ventilated patient with pneumonia	3
Patient requiring re-intubation following rupture of endotracheal tube cuff	4
Pediatric patient being hyperventilated for head trauma	5
Accidental patient disconnection from mechanical ventilator	6
Patient inadequately ventilated due to partial obstruction of endotracheal tube	7
Post-op open heart patient requiring mechanical ventilation	8
Patient requiring re-intubation due to respiratory failure	9
Transport of intubated patient	10
Patient with cardiopulmonary resuscitation in progress	11
Asthmatic patient in acute respiratory distress	12
Glossary of terms	13

Post-op coronary artery bypass patient weaning from mechanical ventilation

Profile:

A 56-year old post/op coronary artery bypass patient was mechanically ventilated with the following settings:

SIMV 12 BPM

VT 900 ml

PSV 7.5 cmH₂O

FiO₂ 0.4

Approximately 2 hours post admission to the Critical Care Unit, the patient was awake, alert and able to breathe spontaneously. An ABG was obtained with simultaneous readings from the capnograph and pulse oximeter. Results:

pH 7.41

PaCO₂ 39

PaO₂ 99

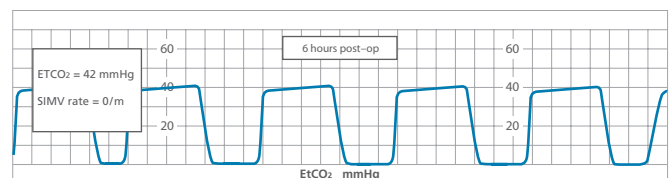
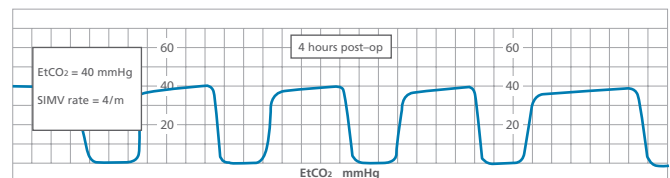
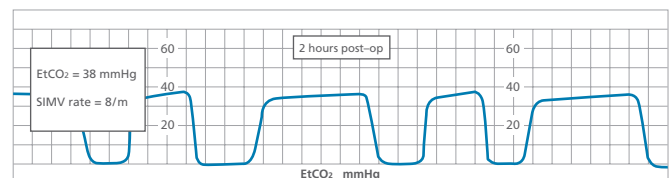
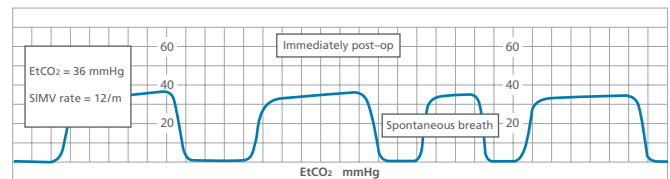
EtCO₂ 36

SpO₂ 98%

The physician ordered weaning by decreasing the SIMV rate by 2 breaths per hour while maintaining EtCO₂ between 30-45 mmHg and SpO₂ greater than 92%. Over the next several hours, the patient was successfully weaned and extubated without the need for additional ABGs.

Discussion:

Weaning from mechanical ventilation often requires multiple ABGs. ABGs are not only invasive but costly. Capnography and pulse oximetry provide an excellent adjunct to ABGs during the weaning process and are valuable tools for the clinician to alert them to changes in the patient's cardiopulmonary status.



“Therefore non-invasive monitoring may provide substantial cost savings by reducing the number of ABG’s obtained during weaning from mechanical ventilatory support.”¹

Patient with ARDS from septic shock requiring mechanical ventilation

Profile:

A 36-year old septic female was being mechanically ventilated. Chest x-ray revealed bilateral white-out consistent with ARDS. ABGs while on SIMV mode were:

pH 7.29

PaCO₂ 51

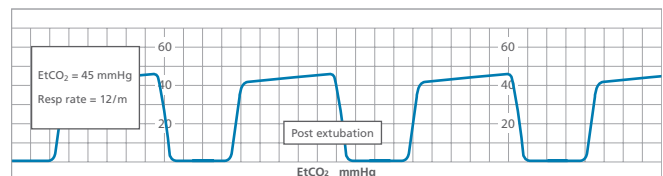
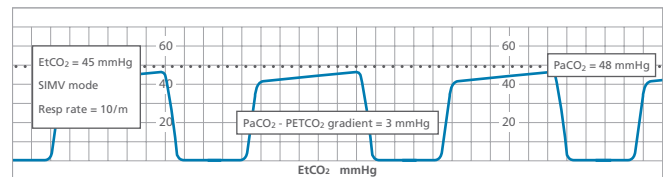
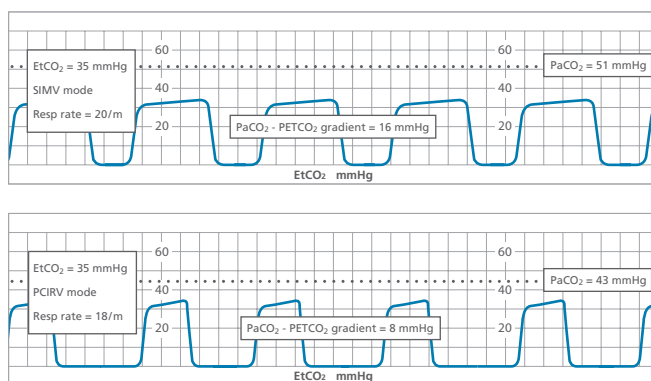
PaO₂ 56

EtCO₂ 35 mmHg

SpO₂ 87%

Arterial to EtCO₂ gradient was 16 mmHg.

The patient was then sedated and the mode of ventilation was changed to pressure control with inverse I:E (PCIRV). In addition, the patient received a course of IV antibiotics, systemic steroids and diuretic therapy. Approximately one week later, the patient's chest x-ray showed slight improvement. The arterial to EtCO₂ gradient improved to 8 mmHg. This improvement in the EtCO₂ gradient indicated the patient's level of improvement and resulted in changing the ventilator mode back to SIMV.



Over the next several days, the SIMV rate was decreased from 18 to 10 BPM. ABGs on the 15th day after admission were:

pH 7.35

PaCO₂ 48

PaO₂ 92

EtCO₂ 45 mmHg

SpO₂ 96%

These results indicated a normal arterial to EtCO₂ gradient (2-5 mmHg). Chest X-ray showed significant clearing of lung fields. The patient was subsequently weaned and extubated.

Discussion:

Capnography allowed the clinician to assess changes in the patient's cardiopulmonary status and to objectively validate the degree of ventilation/perfusion mismatch by providing EtCO₂ values to compare with ABGs. The normal arterial to EtCO₂ gradient is 2-5 mmHg. When this gradient is widened it verifies that significant V/Q mismatching is occurring. Improvement in ventilation-perfusion is verified when this gradient narrows.

“However, there is always a gradient between arterial and end tidal CO₂. The wider the gradient, the greater the ventilation-perfusion mismatch in the lung. Thus capnometry is not only an excellent monitor of breath-to-breath quality of ventilation, but the arterial-to-alveolar CO₂ gradient gives the clinician some sense of wasted ventilation caused by V/Q abnormalities.”²

Using the $\text{PaCO}_2 - \text{PETCO}_2$ gradient to optimize PEEP in a ventilated patient with pneumonia

Profile:

A 72-year old woman was admitted to the Critical Care Unit from a Skilled Nursing Facility with the diagnosis of bacterial pneumonia. Upon admission, her RR was 40 and temperature was 39° C. On 40% O_2 via simple oxygen mask, her ABGs were:

pH 7.20

PaCO_2 65

PaO_2 58

She was intubated and placed on mechanical ventilation with the following settings:

SIMV 12 BPM

VT 600 ml

PEEP 2

FiO_2 0.5

She was then placed on capnometry and a pulse oximeter. 30 minutes later, her ABGs and readings were:

pH 7.28

PaCO_2 55

PaO_2 65

EtCO_2 38 mmHg

SpO_2 85%

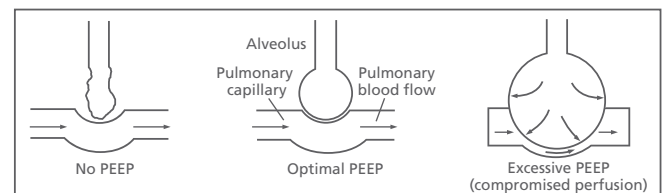
Respiratory mechanics measurements demonstrated a decreased compliance of 20 mL/cmH₂O. It was decided to treat the patient's hypoxemia by optimizing PEEP (the smallest gradient between arterial and EtCO_2 ($\text{PaCO}_2 - \text{PETCO}_2$) coincides with the level of PEEP that provides the best oxygenation with the least pulmonary shunt).

PEEP levels were increased by 2 cmH₂O over the subsequent two hours, allowing for a 30-minute stabilization period at

each increment. ABGs with the notation of EtCO_2 and SpO_2 values were noted after stabilization at each level. Results were as follows:

PEEP	$\text{PaCO}_2 - \text{PETCO}_2$	SpO_2
2 cmH ₂ O	17 mmHg	85%
4 cmH ₂ O	13 mmHg	87%
6 cmH ₂ O	10 mmHg	92%
8 cmH ₂ O	12 mmHg	86%
10 cmH ₂ O	16 mmHg	84%

The PEEP level was adjusted to 6 cmH₂O which resulted in the minimal $\text{PaCO}_2 - \text{PETCO}_2$ gradient. Over the next several days, the patient continued on mechanical ventilation. In addition, she received antibiotics and bronchopulmonary suctioning. On the 10th day following admission, she was successfully weaned from mechanical ventilation.



Discussion:

The $\text{PaCO}_2 - \text{PETCO}_2$ gradient provided a non-invasive method to titrate an appropriate level of PEEP. The smallest gradient between arterial and EtCO_2 correlates with the level of PEEP that provides the best oxygenation and least pulmonary shunt. Application of PEEP above that level produces overdistension of the alveoli causing compromised pulmonary perfusion.

“...use of the $\text{PaCO}_2 - \text{PETCO}_2$ gradient permits the rapid titration of PEEP without the need for a pulmonary artery catheter.”³

Patient requiring re-intubation following rupture of endotracheal tube cuff

Profile:

A 19-year old female involved in a motor vehicle accident sustained facial fractures and pulmonary contusions. Subsequently, she developed ARDS requiring mechanical ventilation. Initial settings were:

SIMV 10 BPM

VT 800 mL

PEEP 8

FiO₂ 0.4

Four days after admission:

VT delivered decreased from 800 mL to 550 mL

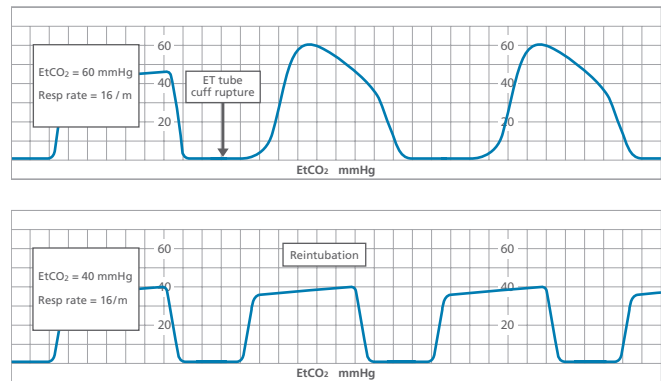
PIP decreased from 50 cmH₂O to 30 cmH₂O

EtCO₂ increased from 40 mmHg to 60 mmHg

SpO₂ decreased from 92% to 85%

Auscultation of the patient's trachea revealed a significant leak on exhalation suggesting that the ET tube cuff ruptured. It was decided to re-intubate her.

After hyperoxygenation, re-intubation was attempted, but direct visualization of the cords was obstructed by soft tissue swelling. Capnography was used to perform a blind nasal intubation with the sensor connected to the proximal end of the ET tube. The ET tube was introduced into the hypopharynx. EtCO₂ waveforms became higher and started to plateau as the larynx was approached. When the tip of the ET tube slipped behind the larynx, the capnogram immediately dropped to zero. The tube was pulled back slightly and advanced once more. Entrance of the tube into the trachea was rapidly detected as typical CO₂ waveforms were observed. The re-intubation was successful and the patient was returned to the previous ventilator settings. EtCO₂ was 40 mmHg and SpO₂, 94%.



Discussion:

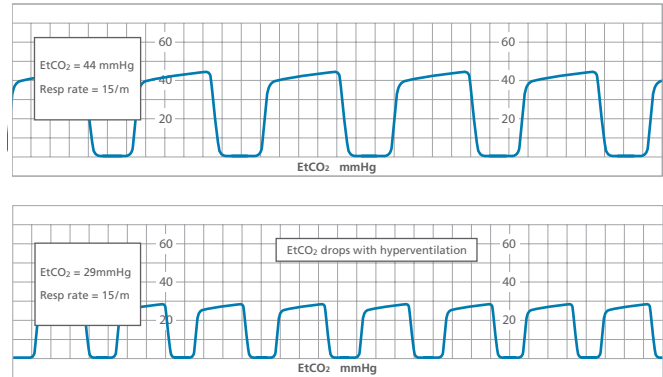
When the ET tube was passed into the nasopharynx, the capnogram and EtCO₂ values immediately registered. As the tube advanced, loss of the CO₂ waveform signified that the ET tube had passed behind the larynx. Only direct visualization and capnography have uniformly confirmed correct endotracheal tube placement in the trachea versus the esophagus.

“Thus capnography facilitates orientation during blind nasotracheal intubation and rapidly detects esophageal intubation.”⁴

Pediatric patient being hyperventilated for head trauma

Profile:

An unconscious and intubated 11-year old female was admitted to the Pediatric Critical Care Unit following a motor vehicle accident and placed on mechanical ventilation. A CT scan revealed a skull fracture with moderate cerebral edema. Capnography was initiated and showed an EtCO₂ of 44 mmHg and a RR of 15. The physician ordered an increased mechanical ventilator rate to maintain an EtCO₂ value between 25-30 mmHg.



Discussion:

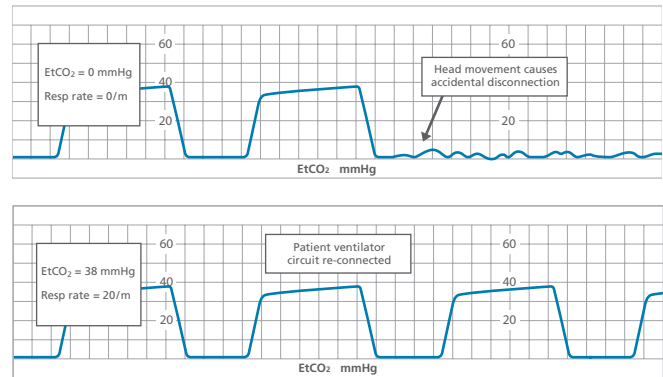
Capnography provides the clinician with a continuous assessment of the ventilator settings required to maintain a prescribed level of ventilation. As, in this instance, the PaCO₂ was to be maintained in a narrow range, EtCO₂ monitoring is considered vital in guiding the mechanical hyperventilation of patients suffering head trauma.

“Hypocapnic cerebral vasoconstriction induced by mechanical hyperventilation is essential for rapid control of elevated intracranial pressure in patients with severe head injuries. The ability to establish rapidly an appropriate degree of cerebral vasoconstriction in the setting of acute head injury depends on an accurate estimation of the minute ventilation (V) that will produce a desired PaCO₂. End Tidal (PETCO₂) monitoring offers a simple, rapid means of estimating PaCO₂.”⁵

Accidental patient disconnection from mechanical ventilator

Profile:

A 43-year old male was admitted to the Critical Care Unit with the diagnosis of status epilepticus, which required complete sedation with phenobarbital. Due to respiratory depression, the patient then needed mechanical ventilation and monitoring via capnography and oximetry. During a grand mal seizure, the patient accidentally became disconnected from the ventilator and the circuit wye settled under the patient, allowing the ventilator to generate enough pressure and volume to satisfy the set alarm conditions. However, the capnograph alarmed immediately and displayed a flat line waveform as illustrated below. The clinician was alerted to the situation, reconnected the patient to the ventilator and the capnogram returned to normal.



Discussion:

The capnograph was a useful tool in assessing changes in the patient's cardiopulmonary status and alerting the clinician to possible mechanical ventilation failures.

"CO₂ analysis in the ventilator circuit can provide a disconnection alarm that is particularly sensitive and responds rapidly."⁶

Patient inadequately ventilated due to partial obstruction of endotracheal tube

Profile:

A 45-year old male with pneumococcal pneumonia developed ARDS after admission and mechanical ventilation in the Critical Care Unit. As extremely high pressures (90 cmH₂O) were required to achieve set volume during volume ventilation, the patient was changed to PCIRV with the following settings:

Pressure 45 cmH₂O

PEEP 15 cmH₂O

I-time 60%

E-time 40%

The patient was sedated and monitored via capnography and pulse oximetry.

ABG results were obtained and correlated with capnograph and oximetry values:

pH 7.34

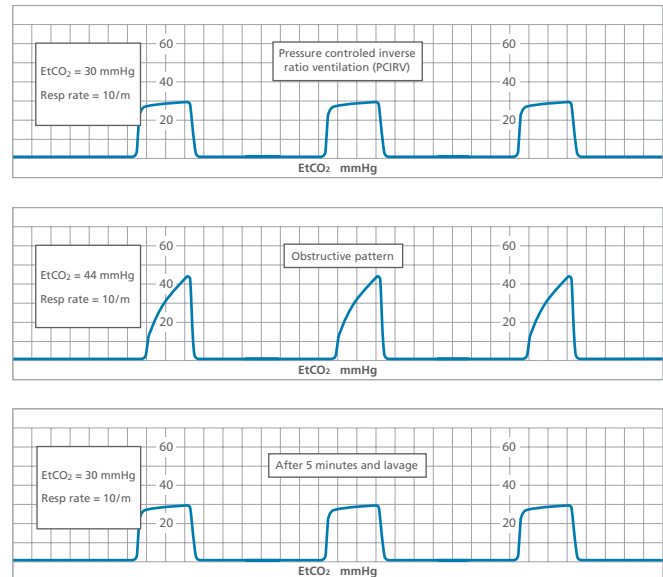
PaCO₂ 48

PaO₂ 60

EtCO₂ 30 mmHg (indicating a widened PaCO₂ - PETCO₂ gradient consistent with ARDS)

SpO₂ 87%

Several hours later, the capnograph alarmed with an EtCO₂ reading of 44 mmHg, which was significantly higher than the patient's value had been trending. The clinician was alerted and attempted to suction, however the suction catheter would not advance down the ET tube. The clinician lavaged and inspissated secretions were suctioned from the ET tube. Adequate ventilation was restored as demonstrated by the EtCO₂ returning to the patient's previously correlated (with ABGs) baseline EtCO₂.



Discussion:

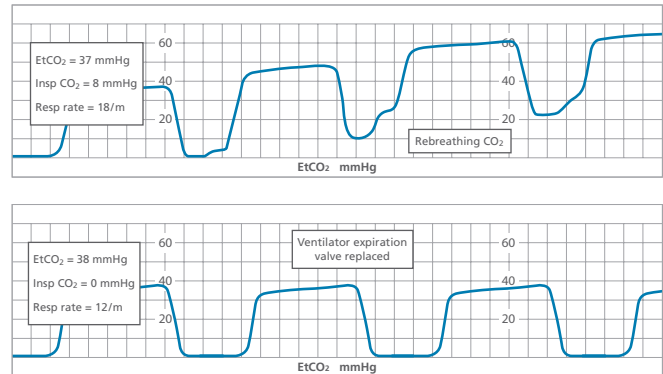
The ET tube had become partially occluded with secretions, which resulted in inadequate volumes being delivered to the patient. The capnography reading alerted the clinician and the problem was corrected before the patient decompensated. EtCO₂ monitoring is important during PCIRV in particular due to the possibility of minute-to-minute changes in VT. In addition, capnography provides a higher degree of safety for patients that require sedation and/or paralysis.

“If end tidal CO₂ is increasing, the clinician must be suspicious that tidal volume and minute volume are decreasing secondary to changes in lung compliance or airway resistance or both.”⁷

Post-op open heart patient requiring mechanical ventilation

Profile:

A 62-year old male was admitted to the Critical Care Unit after coronary artery bypass graft surgery and placed on mechanical ventilation, capnography and pulse oximetry. After a few minutes of ventilation, the clinician noted a high inspired CO_2 value and a rising baseline of the CO_2 waveform indicating the patient was rebreathing CO_2 . Upon inspection of the ventilator, the clinician discovered a defective expiratory valve and quickly replaced it. The CO_2 waveform returned to baseline, indicating that normal ventilation had been achieved.



Discussion:

Even the most sophisticated of ventilators may experience some degree of mechanical failure. The presence of inspired CO_2 on the capnograph alerted the clinician to the situation. A capnograph is an excellent monitoring tool and can often assist the clinician in detecting unexpected changes in a patient's cardiopulmonary status and/or technical failures during mechanical ventilation.

“...the PSRV was ruptured, causing loss of gas from the ventilator during both inspiration and exhalation. The ventilatory effect was a reduction of tidal volume, peak airway pressure and minute ventilation, with resulting hypercarbia.”⁸

Patient requiring re-intubation due to respiratory failure

Profile:

A 58-year old male with COPD required mechanical ventilation post-op bowel resection. On the 5th day after surgery, routine weaning parameters indicated he was ready to be weaned from mechanical ventilation. Over several hours he was weaned to a T-piece, which he tolerated well. He was subsequently extubated and placed on 2 LPM via nasal cannula.

As the patient had underlying pulmonary disease, he was continuously monitored with capnography and pulse oximetry to keep close watch on his ventilation and oxygenation. Post extubation, the capnograph sensor was connected to the patient using a specially-designed nasal cannula. ABGs were drawn:

pH 7.34

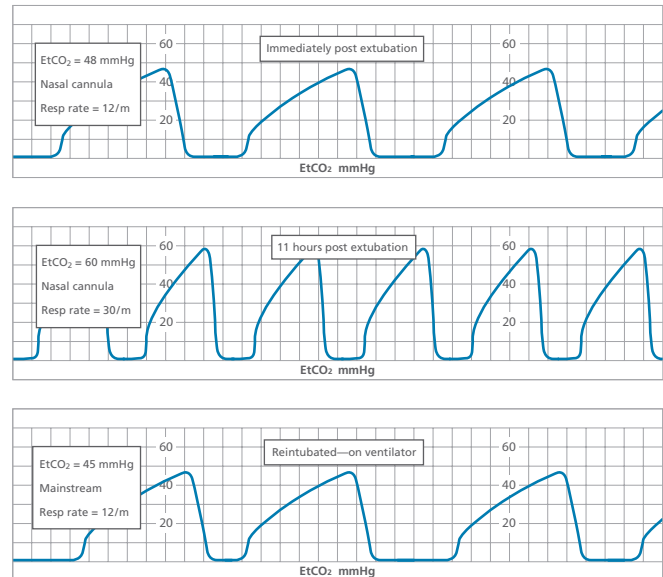
PaCO₂ 54

PaO₂

EtCO₂ 48 mmHg

SpO₂ 92%

Over the next 6 hours, the patient's RR increased to 20, but the EtCO₂ and SpO₂ remained constant. At the 8th hour post extubation, the patient's RR increased to 30. EtCO₂ began to rise. By the 11th hour, his RR was 30, EtCO₂ was 60 mmHg and his SpO₂ decreased to 87%. The patient was reintubated and returned to mechanical ventilation for weaning failure with imminent respiratory failure.



Discussion:

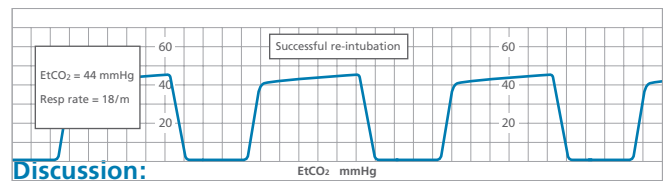
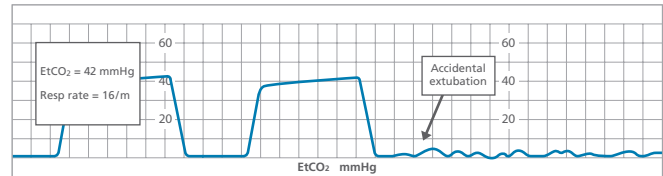
Continuous monitoring of oxygenation and ventilation with capnography and pulse oximetry allowed the immediate diagnosis of impending respiratory failure, enabling the medical staff to place the patient in a more safe, controlled environment prior to significant clinical deterioration.

“End tidal carbon dioxide measurements correlate well with PaCO₂ in non-intubated patients presenting with a variety of underlying problems. Determinations are rapid, inexpensive and non-invasive and may obviate the need for arterial blood gases in selected groups of patients.”⁹

Transport of intubated patient

Profile:

A 48-year old male with sepsis following a liver transplant was intubated and received mechanical ventilation with monitoring via capnograph and pulse oximetry. He required transport to radiology for a CT scan. The patient was ventilated manually with oxygen and transported with ECG monitoring. During transport to the CT scan suite, the capnograph tracing changed dramatically. The EtCO₂ value dropped to zero and the monitor's alarm sounded. Once alerted, the clinician checked the airway and found that the ET tube had become dislodged. The patient was successfully reintubated with confirmation of such by the appearance of a normal capnogram.



Discussion:

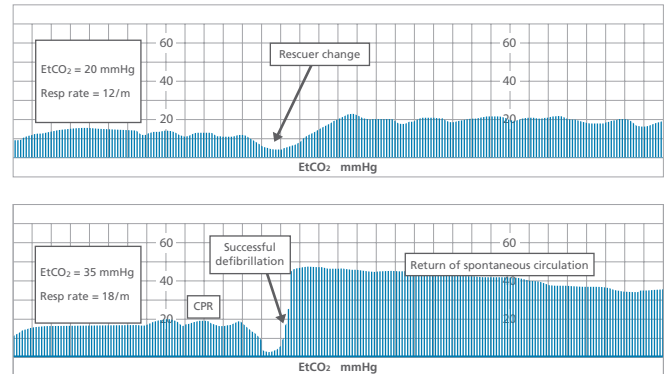
Use of capnography provided essential ventilation monitoring during this intra-facility transport. The EtCO₂ reading proved to be an outstanding tool for the assessment of airway patency and ventilation during a time when monitoring respiratory status is often difficult.

“End Tidal CO₂ monitoring may develop into the standard of care for critically ill patients both in the hospital and during transport... The monitor can assist with patient care both during mechanical and manual ventilation procedures and can assist with the verification of endotracheal tube placement.”¹⁰

Patient with cardiopulmonary resuscitation in progress

Profile:

A 62-year old male was admitted to the Critical Care Unit following an anterior myocardial infarction. Approximately one hour post-admission, he suffered a cardiopulmonary arrest. During the resuscitation efforts, the patient was ventilated/oxygenated via manual bag valve unit and subsequently intubated. ECG, mainstream capnography and pulse oximetry monitoring was initiated as well. The ECG revealed coarse ventricular fibrillation. The trended EtCO₂ values fell over time as the rescuer providing chest compressions fatigued. Following a change in rescuer, the EtCO₂ values increased due to more effective chest compressions.



Discussion:

Continuous monitoring and trended data for EtCO₂ during cardiopulmonary resuscitation provided a valuable non-invasive method of measuring the effectiveness of chest compressions. EtCO₂ correlates with cardiac output. As cardiac output falls, so does EtCO₂. When circulation returns, the EtCO₂ will immediately increase.

“...measurement of the end-tidal carbon dioxide concentration may be a practical, non-invasive method for monitoring blood flow generated by precordial compression during cardiopulmonary resuscitation and an almost immediate indicator of successful resuscitation.”¹¹

Asthmatic patient in acute respiratory distress

Profile:

A 23-year old female was admitted to the Critical Care Unit from the Emergency Department with severe respiratory distress due to asthma. Physical exam and monitoring revealed:

HR 134

BP 176/76

RR 36

Bilateral inspiratory and expiratory wheezes

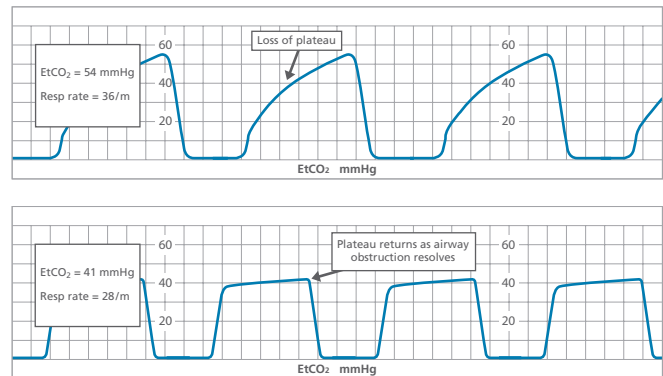
SpO₂ 91%

EtCO₂ 54

The capnograph waveform tracing displayed a loss of plateau, which is consistent with significant bronchospasm.

The patient then received low flow O₂ and nebulized albuterol sulfate. Following the bronchodilator therapy, improvement was evident as demonstrated by the capnogram although no significant change was noted in the patient's breath sounds.

Close monitoring of the patient continued. One hour after the initial bronchodilator treatment, the capnogram reverted to an obstructive pattern with an associated increase in EtCO₂. The patient was given another nebulized albuterol sulfate treatment, resulting in improved air exchange as indicated by the normal capnogram and EtCO₂ values.



Discussion:

Use of capnography in the assessment of bronchospasm provided an objective measurement of the severity of the airway obstruction. The capnogram then demonstrated effective bronchodilator therapy. Capnography has the added benefits of being non-invasive, patient effort independent and allowing measurements to be made during normal tidal breathing (unlike peak flow monitoring).

“...analysis of the capnogram’s shape is a quantitative method for evaluating the severity of bronchospasm. This ability, added to specific advantages (non-invasive, effort-independent, measurements during tidal breathing), opens new fields of application to capnography, such as measurement of bronchospasm in children...”¹²

Glossary of terms

ABG: arterial blood gas

ARDS: adult respiratory distress syndrome

BPM: breaths per minute

COPD: chronic obstructive pulmonary disease

CT: computed tomography

ECG: electrocardiogram

ET tube: endotracheal tube

EtCO₂: End tidal CO₂—the partial pressure of carbon dioxide at the end of expiration (the alveolar plateau), also referred to as PetCO₂ or PETCO₂

FiO₂: fraction of inspired oxygen

IV: intravenous

LPM: liters per minute

PaCO₂: partial pressure of carbon dioxide in arterial blood

PaO₂: partial pressure of oxygen in arterial blood

PCIRV: pressure control inverse ratio ventilation

PCV: pressure control ventilation

PEEP: positive end expiratory pressure

PIP: peak inspiratory pressure

PSV: pressure support ventilation

RR: respiratory rate

SIMV: synchronized intermittent mandatory ventilation

SpO₂: percentage of oxygen saturation in arterial blood as determined by a pulse oximeter

V/Q: ventilation to perfusion

VT: tidal volume

References

1. Safesak K., Nelson L. Cost Effectiveness of Non-invasive Monitoring During Weaning from Mechanical ventilation. *Chest*, 1992, 102: 1845.
2. Hoyt J. Mechanical Ventilation: State of the Art. *Advances in Anesthesia*, 1994, Vol. 11, Mosby Yearbook, Inc.
3. Murray J.P., Modell J.H., Gallagher T.J., Banner M.J. Titration of PEEP by the Arterial Minus End-Tidal Carbon Dioxide Gradient. *Chest*, January 1984, 85: 100-4.
4. Linko K., Paloheimo M. Capnography facilitates Blind Intubation, *Acta Anaesthesiol Belg*, June 1983, 34 (2), 117-22.
5. Karagianes T.G., Mackersie R.C. Use of End Tidal Carbon Dioxide Tension for Monitoring Induced Hypocapnia in Head Injured Patients. *Critical Care Medicine*, 1990, 18:7, 764.
6. U.S. Department of Health and Human Services. Public Health Services. Food and Drug Administration. *Increasing Early Detection of Accidental Disconnections*, June 1991.
7. Hoyt J. Mechanical Ventilation: State of the Art. *Advances in Anaesthesia*, 1994, Vol. 11, Mosby Year Book, Inc.
8. Sommer R.M., Bhalla G.S., Jackson J.M., Cohen M.I. Hypoventilation Caused by Ventilator Valve Rupture. *Anesthesia Analgesia*, 1988, 67: 999-1001.
9. Barton C.W. Correlation of End Tidal CO₂ Measurements to Arterial PaCO₂ in Non-Intubated Patients. *Annals of Emergency Medicine*, March 1994, 23:3, 562-563.
10. Morris M. Transport Considerations for the Head-Injured Patient: Are We Contributing to Secondary Injury? *The Journal of Air Medical Transport*, July 1992, 9-13.
11. Falk J.L., Rackow E.C., Weil M.H. End-tidal Carbon Dioxide Concentration During Cardiopulmonary Resuscitation. *New England Journal of Medicine*, March 10, 1988, 318(10): 607-11.
12. Smith T.C., Proops D.W., Pearman K., Hutton P. Nasal Capnography in Children: Automated Analysis Provides a Measure of Obstruction During Sleep. *Clinical Otolaryngology*, February 1993, 18:1: 69-71.

This publication is a reprint of *Capnography in Critical Care Medicine* (p/n BK1006, 04/04/03) and has been reprinted with the permission of Respironics, Inc., Wallingford, CT

© 2010 CareFusion Corporation or one of its subsidiaries. All rights reserved. RC1708 (0710/Q) L3019 Rev. B

CareFusion
Yorba Linda, CA

carefusion.com

