Primljen/ Received on: 27.09.2017.
Revidiran/ Revised on :17.10.2017.
Prihvaćen/ Accepted on :25.10.2017.

PRIKAZ SLUČAJA
CASE REPORT
doi:10.5937/asn1776772K

CEMENTO-OSIFICIRAJUĆI FIBROM MAKSILE I MAKSILARNOG SINUSA: PRIKAZ SLUČAJA I PREGLED LITERATURE

CEMENTO-OSSIFYING FIBROMA OF THE MAXILLA AND MAXILLARY SINUS: A CASE REPORT AND LITERATURE REVIEW

Dragan Krasić [1,2], Miloš Stojanović [2], Miloš Trajković [2], Staša Krasić [3]

[1] UNIVERZITET U NIŠU, MEDICINSKI FAKULTET, PREDMET MAKSILOFACIJALNA HIRURGIJA, NIŠ, SRBIJA
[2]KLINIKA ZA STOMATOLOGIJU NIŠ, ODELJENJE ZA MAKSILOFACIJALNU HIRURGIJU , NIŠ, SRBIJA
[3]UNIVERZITET U BEOGRADU, MEDICINSKI FAKULTET, BEOGRAD, SRBIJA

[1]UNIVERSITY OF NIŠ, FACULTY OF MEDICINE NIŠ, DEPARTMENT OF MAXILLOFACIAL SURGERY, NIŠ, SERBIA
[2]CLINIC OF DENTISTRY, DEPARTMENT OF MAXILLOFACIAL SURGERY, NIŠ, SERBIA
[3]UNIVERSITY OF BELGRADE, FACULTY OF MEDICINE, BELGRADE, SERBIA

Sažetak

Uvod: *Veliku grupu benignih koštanih tumora vilica predstavljaju fibro-koštani tumori. Osnovu patofiziološkog procesa ove vrste tumora predstavlja zamena normalnog koštanog tkiva fibroznim tkivom. Cemento-osificirajući fibrom (COF) pripada ovoj grupi tumora.*
Prikaz slučaja: *Predstavljen je redak slučaj COF u maksili i maksilarnom sinusu kod četrdesetogodišnjeg muškarca .U početnom stadijumu se COF razvijao asimptomatski, kao kod većine benignih tumora. U kasnijim stadijumima, zavisno od lokalizacije, pre svega, pojavili su se drugi simptomi, kao što je deformitet lica,vilica i glave, oftalmološke smetnje, parestezije zbog kompresije nerava i dr. Urađena je subtotalna maksilektomija Weber-Fergusson pristupom.*
Zaključak: *U našem prikazu slučaja predstavili smo pacijenta sa retkom lokalizacijom COF. Za postavljenje definitivne dijagnoze COF, neophodan je, pre svega, MSCT-om i angiogram. Hirurška terapija je jedina metoda lečenja. Postoperativno praćenje pacijenta je neophodno zbog mogućih recidiva ili drugih komplikacija, uz kontrolni MSCT.*

Ključne reči: *cemento-osificirajući fibrom, maksila, maksilarni sinus, maksilektomija*

Abstract

Introduction*: A large group of benign bone tumors of the jaw are fibroosseous tumors. The basis of the pathophysiological processes of this type of tumor is the replacement of normal bone tissue by fibrous tissue. The cemento-ossifying fibroma (COF) belongs to this group of tumors.*
Case report*: A rare case of COF in the maxilla end maxillary sinus in a 40-year old patient is presented. In the initial stage , COF developed asymptomatically, as most benign tumors. In later stage other symptoms appeared , first of all facial deformities of the jaw and head, ophthalmic disorders, paresthesia due to compression of the nerves, and the like. We performed subtotal maxillectomy uing the Weber-Fergusson approach.*
Conclusion: *In this case report we presented a pacient with rare localisation of COF. To set a deffinitive diagnosis of COF, a detailed clinical examination with MSCT and angiography are required. Surgical therapy is only method of treatment. Postoperative monitoring of the patient is necessary, incuding tcontrol MSCT radiography.*

Key words: *cemento-ossifying fibroma, maxilla, paranasal sinus, maxillectomy*

Address for correspondence:
Associate Professor Dragan Krasić,DDS,MSD,PhD
Clinic of Stomatology-Maxillofacial Surgery Dep.
Dr Zoran Djindjić Blvd 52 , Niš,Serbia
E-mail: drkrasic@yahoo.com

Uvod

Fibro-koštani tumori pripadaju benignim koštanim tumorima. Veoma često su zastupljeni u mandibuli i maksili. Sa patofiziološkog aspekta, kod ovih tumora, osnovu predstavlja zamena normalnog koštanog tkiva fibroznim tkivom. Cmento-osificirajući fibrom (COF) pripada ovoj grupi tumora.Prvi opis COF datira iz druge polovine 19. veka [1].

Svetska zdravstvena organizacija je 2005. godine svrstala COF u grupu benignih tumora fibro-koštanog porekla, jasno ograničenog, spore evolucije i sa dva podtipa: 1) epitelno-oskudni – jednostavni podtip i 2) epitelno-dominantni – SZO podtip [2,3]. Preko 80% COF se javlja u mandibuli. Druga po učestalosti lokalizacija je maksila, ali sa dosta manjom incidencijom. Postoje studije koje navode slučajeve COF u temporalnoj, okcipitalnoj kosti, nosnoj duplji i paranazalnim šupljinama [4]. Što se tiče životnog doba, COF je najzastupljeniji u četvrtoj deceniji života [5,6], i to sa prevalencijom kod ženskog pola u odnosu na muški (1,6:1) [7].

Klinička slika pacijenata sa COF je raznolika. U početnom stadijumu COF se razvija asimptomatski, kao većina benignih tumora. U kasnijim stadijumima, zavisno od lokalizacije, pre svega, dolazi do pojave niza simptoma, kao što su različiti deformiteti lica, vilica i glave, zapušenost nosa, razni oblici rinofaringitisa, oftalmološke smetnje, parestezije zbog kompresije nerava i dr.[8].

Postoje brojne klasifikacije COF prema različitim kriterijumima. Najprihvaćenija je klasifikacija prema kliničkoj slici na: neagresivni (konvencionalni) i agresivni (juvenilni tip) [9] . Neagresivni tip je standardni tip i ima sve prethodno navedene osobine benignog tumora. Juvenilna forma COF se odlikuje brzim rastom,velikim destruktivnim potencijalom. Najčešće se javlja kod dece uzrasta 2-15 godina, sa neznatnom dominacijom kod muškaraca[10] .

Klinička dijagnoza COF se ne moze postaviti samo kliničkim pregledom, već na osnovu anamneze, kliničkog pregleda i dodatnih radioloških procedura, uključujući OPGT, nativnu grafiju kostiju lica i vilica, CT i MRI. Zlatni standard za definitivnu dijagnozu je biopsija i patohistološki nalaz.

Diferencijalno-dijagnosički COF treba razlikovati od fibrozne displazije, cemento-fibrozne displazije i drugih tipova koštanih tumora benignog porekla i vaskularnih lezija[11].

Introduction

Fibro-osseous tumors belong to benign bone neoplasms. Very often, they appear in the mandible and maxilla. Concerning the pathophysiological aspect of this type of neoplasm, the principle process is the replacement of the normal bone tissue by fibrous tissue. The cemento-ossifying fibroma (COF) belongs to this group of tumors. The first description of the COF was in the second half of the 19th century[1].

In 2005, the World Health Organization classified COF in the group of a benign fibrous tumor of bone origin, clearly limited and with slow evolution [2,3] . Over 80% of the COFs occur in the mandible. The second frequent localization is in the maxilla. Also, some other papers described the COF in the temporal bone, occipital bone, nasal cavity, and paranasal sinuses [4]. Concerning the age, most patients present in the 4th decade of life [5,6], with the female to male ratio (1.6:1) [7].

Clinical findings in patients with COF differ. The initial stage of the COF develops asymptomatically, as most benign tumors. Later stages are determined by the tumor localization. A variety of symptoms occur, some of them being facial deformities of the jaw and head. Other symptoms include ophthalmic disorders as well as neurological ones, such as paresthesia due to the compression of the nerves [8].

In the reference literature, many classifications of COF are given, based on the various criteria. The most widely accepted classification is based on the clinical presentation: non-aggressive (conventional) and aggressive (juvenile type) [9]. The non-aggressive form is a standard type and has all characteristics of benign tumors. The juvenile form of the COF presents with rapid spread and locally destructive potential. This form most commonly occurs in children aged 5-15 years [10].

Clinical diagnosis of COF is very difficult and it consists of anamnesis, clinical examination and additional radiological procedures. These primarily include OPGT, native radiography of facial bones, and jaw CT and MRI. The gold standard for definitive diagnosis is biopsy and histopathological findings.

In the differential diagnosis, COF should be distinguished from fibrous dysplasia, cemento-fibrous dysplasia, and other types of benign bone tumors and vascular lesions [11].

Postoji velika etiopatogenetska i histološka sličnost između COF i centralno cemento-sificirajućeg fibroma, uzimajući u obzir kliničko ponašanje, radiološki nalaz, starosnu i polnu distribuciju učestalosti. Jedina razlika je histopatološka, jer u COF imamo koštano tkivo, a u drugom cementno tkivo [12].

Cilj ovoga rada bio je da se predstavi redak slučaj COF u maksili i maksilarnom sinusu kod četrdesetogodišnjeg muškarca. Pregledom dostupne literature veoma mali broj slučajeva je prikazan sa ovom lokalizacijom.

Prikaz slučaja

U leto 2008. godine u Kliniku za maksilofacijalnu hirurgiju Niš javlja se četrdesetogodišnji muškarac zbog otoka obrazne regije sa leve strane. U toku anamnestičke obrade navodi da se otok obrazne regije javio pre nekoliko godina bez subjektivnih tegoba. Godinama se postepeno uvećavao. Tek nakon dve godine se prvi put javlja lekaru, kada je upućen na maksilofacijalnu hirurgiju.

Osim bezbolnog otoka u predelu obraza levo, pacijent navodi otežano disanje na nos, posebno kroz levu nozdrvu, zatim na parestezije u predelu infraorbitalnog nerva sa leve strane, povremene otoke donjeg kapka levog oka sa sledstvenim konjuktivitisom.

Negira ranije operacije i postojanje hroničnih oboljenja.

Nakon anamnestičke obrade, urađen je klinički pregled glave, lica i vrata.

Inspekcijom se konstatuje tumefakt u obraznoj regiji levo, koji se u KK smeru pružao od nivoa mentolabijalne brazde do bukopalpebralnog sulkusa, i LL smeru od ugla usana do nivoa spoljnjeg ugla oka,veličine oko 3x4 cm. Koža je neizmenjena (slika 1).

Funkcija bulbomotora i ostala oftalmološka ispitivanja bila su u fiziološkim granicama. Ispadi u inervacionoj zoni ličnog nerva nisu bili prisutni.

Intraoralnom inspekcijom tumefakt se pružao u LL smeru od nivoa očajničke jame do tubera maksile levo, oduhvatajuću celi alveolarni nastavak i nastavljajući se put pozadi ka retromaksilarnom prostoru, potiskujući meka tkiva obraza put napred. Sluzokoža je nepromenjena.

Palpacijom se utvrdio tumefakt tvrde konzistencije, bezbolan i nepokretan. Regionalno se limfonodusi nisu palpirali.

Nalaz prednje rinoskopije ukazivao je na suženje levog zajedničkog nosnog hodnika zbog ispupčenja u predelu srednje nosne konhe.

Kao dodatne dijagnostičke procedure korišćeni su MSCT i angiografija.

Cemento-ossifying fibroma and central cemento-ossifying fibroma are very similar concerning the clinical behavior, radiographic findings, age and sex distribution frequency. The only difference is histological because the COF has the bone tissue and the other one has the cement tissue[12].

The aim of this study was to present a rare case of the COF in the maxilla and maxillary sinus in a forty-year-old man. In the review of the available literature, very few cases have been presented with this localization.

Case report

In the summer of 2008, at the Department of Maxillofacial Surgery in Nis, a forty-year-old man presented with a swollen cheek region on the left side. In the medical history, the patient stated that swelling of the cheek region had occurred a few years before without subjective complaints. Over years, the occurrence gradually augmented. Two years after he visited a doctor for the first time, who referred him to the Clinic of Maxillofacial Surgery.

Apart from a painless swelling of the left cheek, the patient mentioned difficulty breathing through the nose, especially through the left nostril, then paresthesia in the area of infraorbital nerve on the left side, occasional swelling of the lower left eyelid, with the accompanying conjunctivitis.

He denied the existence of prior surgery and chronic diseases.

After taking the medical history, the clinical examination of the head, face and neck was conducted.

Inspection indicated a tumefaction of the left buccal region, which was in the cranio-caudal direction extending from the ridge of the mentolabial sulcus to the buccopalpebral sulcus, and latero-lateral direction from the corner of the mouth to the level of an outside corner of the eye, measuring about 3x4 cm. The skin over tumefactions remained unchanged (Figure1).

Bulbar motor function and other ophthalmologic examinations were within normal limits. Excess in the distribution area of the facial nerve was not present.

Intraoral inspection showed that the tumefaction stretched in the latero-lateral direction from the level of canine cave to the left maxillary tuberosity, encompassing the entire alveolar process and continuing the path back to the retromaxillary space, pushing the soft tissues of the cheek forward.

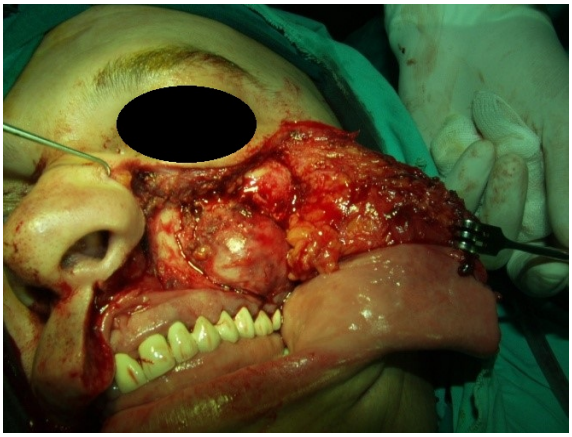

Slika 1. Intraoperativna slika
Figure 1. Intraoperative image

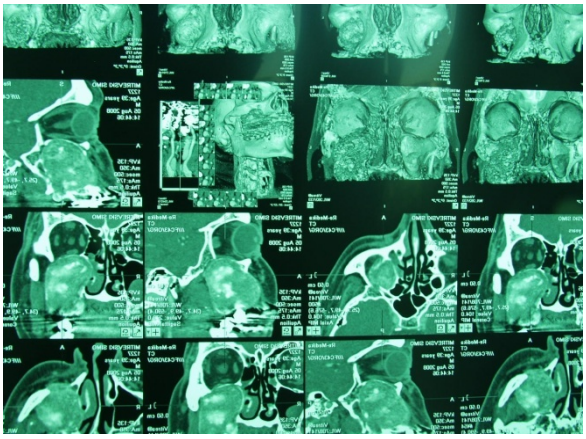

Figure 2. Preoperativni MSCT nalaz
Figure 2. Preoperative MSCT image

Nalaz MSCT je ukazivao na dobro ograničenu tumorsku masu dominantno u predelu leve maksile i levog maksilarnog sinusa, koja se u LL smeru pružala od nivoa tubera maksile do spoljnog zida nosne šupljine, praveći izbočinu u predelu srednje konhe. U KK smeru se pružao od alveolarnog nastavka maksile do na 3 mm od poda leve orbite, ne destruirajući je. U AP smeru od nivoa obrazne strukture, zahvatajući maksilu i sinus do zadnjeg zida, ne razarajući ga (slika 2).

Angiografija gornjevilične arterije je isključivala vaskularno poreklo tumefakta. Ukazivala je na patološku vaskularizaciju tumefakta iz završnih grana arterije maksilaris. Infraorbitalna arterija je bila dislocirana. Urađena je embolizacija završnih grana partikulama BEAD BLOCK-a (slika 3).

Hirurška intervencija urađena je u opštoj endotrahealnoj anesteziji. Urađena je subtotalna maksilektomija Weber-Fergusson pristupom. Intraoperativno je konstantovana tumorska formacija, koja je razarala prednji zid maksilarnog sinusa, pružajući se od očnjačke jame do tubera i neuzururajući krov iste. Uklonjen je tumefakt sa okolnim koštanim tkivom maksile i delom predela infratemporalne i pterigopalatinske lože, uz očuvanje poda orbite, bočnog zida nosne duplje, dela zadnjeg zida maksile i tubera. U defekt je plasirana jod štrajfna i prekriven mekotkivnim režnjem.

Mucosa over the tumefactions remained unchanged.
On palpation, the tumefaction was of hard consistency, painless and immobile. Regionally, lymph nodes were not palpable. Anterior rhinoscopy findings pointed to the narrowing of the left common nasal meatus due to bumps in the area of the middle nasal conchae. MSCT and angiography were employed as the additional diagnostic procedures.

MSCT findings pointed to the well-circumscribed tumor mass predominantly in the left maxilla and left maxillary sinus, which in latero-lateral direction stretched from the level of the maxillary tuberosity to the outer wall of the nasal cavity, making a bulge in the middle area of the conch. In the cranio-caudal direction, the tumefaction extended from the alveolar process of the maxilla to 3 mm from the floor of the orbits without destroying the same. In the anterior-posterior direction it stretched from the level of the buccal structure, capturing maxilla and maxillary sinus to the posterior wall, without destroying it (Figure 2). Maxillary artery angiography excluded the vascular origin of the tumefaction. It pointed to the pathological vascularization of the tumefaction by the terminal branches of the artery maxillaris. Infraorbital artery was dislocated. The terminal branches were successfully embolized with BEAD BLOCK particles (Figure 3A, 3B).

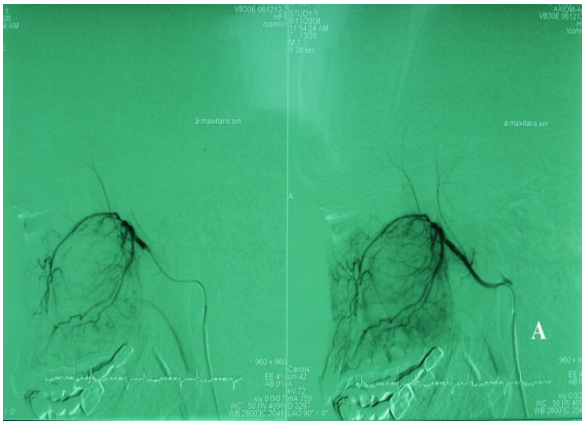

Slika 3. *A.* Maksilarna arterija pre embolizacije. *A.* Maxillary artery before embolization

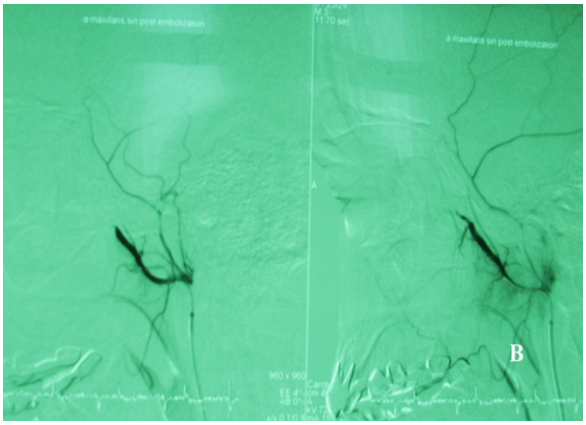

Figure 3. *B.* Maksilarna arterija posle embolizacije. *B.* Maxillary artery after embolization.

Postoperativno je ordinirana antibiotska terapija u trajanju od 7 dana.

Postoperativni tok protekao je bez kompikacija.

Ex tempore patohistološki nalaz je ukazivao na benignu tumorsku formaciju mezenhimalnog porekla.

Definitivan parafinski patohistološki nalaz je bio centralni osificirajući fibrom.

Nakon godinu dana, klinički je registrovano odsustvo recidiva (slika 4).

Petogodišnji postoperativni period protekao je bez recidiva i komplikacija. Pacijent se jednom godišnje kontroliše.

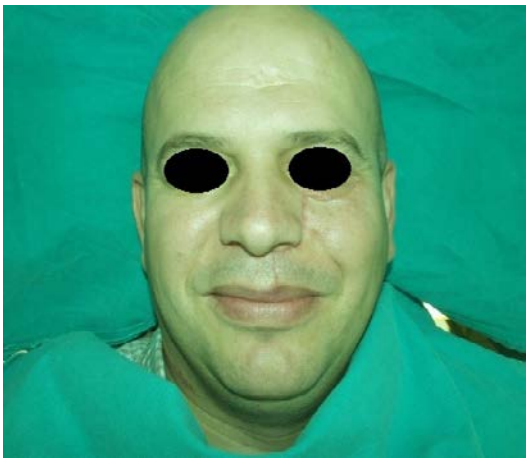

Slika 4. Slika pacijenta jednu godinu posle operacije

Figure 4. An image of the patient one year after the surgery

Surgery was done under the general endotracheal anesthesia. We performed subtotal maxillectomy with the Weber-Fergusson approach. Tumor formation was ascertained during the surgery, which destroyed the anterior wall of the maxillary sinus, stretching from the canine pit to the tuberosity, and without destroying its roof. Tumefaction, with the surrounding bone in the maxilla and part of the infratemporal and pterygopalatine lodge was removed, while preserving the orbital floor, lateral wall of the nasal cavity, part of the posterior wall of the maxilla and tubers. Iodine gauze was placed in the defect and covered with a soft tissue flap.

Administration of antibiotic therapy lasted for 7 days. The postoperative recovery went without complications. Ex tempore histopathological findings pointed to the formation of a benign tumor from the mesenchymal source. The definitive paraffin histopathological finding showed a central ossifying granuloma.

One year after surgery, there was no relapse on clinical examination (Figure 4).

Five-year postoperative period passed without recurrence and complications. The patient has annual controls.

Diskusija

Kao što je već pomenuto, veliku grupu benignih koštanih tumora čine fibro-koštani tumori. Osnovu patofiziološkog procesa ove vrste tumora predstavlja zamena normalnog koštanog tkiva fibroznim tkivom. Cemento-osificirajući fibrom (COF) pripada ovoj grupi tumora, koja još obuhvata i fibroznu displaziju, cemento-fibroznu displaziju i još nekoliko podtipova [11].

Etiologija i etiopatogeneza COF nije razjašnjena do danas. Postoje brojne teorije, ali su samo dve opšteprihvaćene. Prema jednoj, neka vrsta agensa, kao što je trauma, bakterija ili sl, dejstvujući na periodontalnu membranu, dovodi do pojave COF. Prema drugoj teroriji, neka vrsta zaostalog mezenhimalnog tkiva ili delovi periodoncijuma na iregularnom mestu dovode do pojave COF [13]. Za naš prikaz slučaja prihvatljivija je druga teorija.

Intraoperativni nalaz COF ukazivao je na solidno tumorsko tkivo biserno tamnosive boje, što je u karakteristično za većinu koštanih lezija. Histopatološka analiza COF ukazivala je na fibrozno-vezivno tkivo sa delovima koštanog tkiva, okruženo pločasto-slojevitim epitelom, što je bilo u skladu sa drugim studijama[6]. Koštano tkivo je u obliku trabekula raspoređeno u samom tumorskom tkivu, dajući specifičnu sliku samom preparatu COF [14].

Definitivna dijagnoza COF predstavlja izazov za svakoga. Diferencijalno-dijagnostički COF treba razlikovati od drugih tipova benignih koštanih tumora, pre svega, iz grupe fibro-koštanih tumora. Zatim, od malignih tumora kostiju, kao što su osteosarkomi, hondrosarkomi, planocelularni karcinomi i dr.[11], kao i od vaskularnih lezija.

Dobra ograničenost COF pomaže diferencijalnu dijagnozu na radiološkom nalazu (CT ili MRI) u odnosu na maligne entitete, pre svega, hondrosarkom i osteosarkom.

Pregledom literature, većina slučajeva COF, prema kliničkoj slici, pripada neagresivnom tipu (konvencionalnom) [9], kao što je bio i slučaj sa našim pacijentom.

Takođe, većina pacijenata sa COF pripada starosnoj grupi od 20 do 40 godina [5,6], kao što je naš pacijent. Što se tiče polne distribucije, koja je u korist žena [7], naš pacijent je bio muškog pola.

Discussion

As we mentioned before, the fibro-osseous tumors represent a group of benign bone tumors. The basic physiological process in that group of tumors is the replacement of the normal bone tissue with the fibrous tissue. Central-ossifying fibroma (COF) belongs to that group of tumors. Beside COF, that group also includes fibrous dysplasia, cemento-fibrous dysplasia and several other subtypes[11].

Etiology and etiopathogenesis of COF are still unknown. Several theories about the origin of COF have been given, but only two are accepted by most investigators. The first theory says that some kind of agent (such as trauma, bacterial infection or similar) attacks the periodontal membrane, leading to the emergence of COF. According to the second theory, some kind of residual mesenchymal tissue or periodontal tissue in irregular place leads to the COF[13]. For our case report, the second theory is acceptable.

Intraoperative finding showed a solid tumor mass, of dark gray color, which is typical of the majority of the osseous lesions. Paraffin pathohistological analysis of COF showed the fibrous tissue with parts of the osseous tissue surrounded with the squamous epithelium, and these findings are in correlation with some another studies.[6]The osseous tissue is trabecularly distributed in the tumor tissue, making a very interesting picture of COF[14]. Radiological result of the CT scan showed the area of low density with the signs of osteolysis, separated from the rest of the osseous tissue with thin membrane.

Definitive diagnosis of COF is a challenge for everyone, and the differential diagnosis of COF should exclude other types of benign bone tumors, primarily fibro-osseous tumors, then malignant bone tumors such as osteosarcoma, chondrosarcoma, squamous cell carcinoma, etc.[11], as well as the vascular lesions.

Being well circumscribed helps with making the differential diagnosis on the radiological finding (CT or MRI) and differentiation of COF from malignant tumors such as chondrosarcoma and osteosarcoma.

Po učestalosti, COF se dominantno javlja u mandibuli (preko 80%), kao što su dokazali Eversole i al.[3], dok su druge lokalizacije dosta ređe, kao što je i naš prikaz slučaja. Publikovan je veoma mali broj radova sa lokalizacijom COF u paranazalnim šupljinama.

Bez sumnje, jedini tretman COF je hirurški tretman. Drugi vidovi terapije nisu indikovani. Preporuka većine autora je kompletno uklanjanje lezije u što ranijem stadijumu bolesti, kao metod izbora.

U zavisnosti od veličine tumora, tretman može biti u vidu kiretaže ili enukleacije kod manjih lezija. Kod većih, kao što je bio slučaj i kod našeg pacijenta, hirurški tretman podrazumeva široku resekciju okolne zdrave kosti sa tumorom.

Recidivi COF su opisani u literaturi. Incidencija recidiva posle hirurškog tretmana je različita. Neki autori navode pojavu recidiva u 28% pacijenata nakon kiretaže COF [4]. Zbog moguće pojave recidiva, postoperativno praćenje je neophodno. U prvih šest meseci jednom mesečno, a kasnije na tri meseca. Kontrolni MSCT je indikovan nakon šest meseci od operacije.

U našem slučaju urađena je subtotalna maksilektomija sa COF. Postoperativni period je protekao bez komplikacija. Petogodišnji postoperativni period bez recidiva.

Postoje radovi koji opisuju pacijente sa COF koji su bez simptoma odbili hirurški tretman[14]. Njihovo stanje se prati u određenim vremenskim intervalima.

Zaključak

U našem prikazu slučaja predstavili smo pacijenta sa retkom lokalizacijom COF. Za postavljenje definitivne dijagnoze COF, neophodan je detaljan klinički pregled sa anamnestičkom obradom i dodatnim radiološkim ispitivanjem, pre svega, MSCT-om i angiografijom. Hirurška terapija je jedina metoda lečenja. Postoperativno praćenje pacijenta je neophodno zbog mogućih recidiva ili drugih komplikacija, uz kontrolni MSCT.

In the review of literature, most of the cases of COF, according to their clinical presentation, belong to the non-aggressive type (conventional)[9], as was the case with our patient.

Furthermore, the highest incidence of COF is encountered in a population of 20 - 40 years old[5,6], as was the case with our patient. Although literature data show that COF predominantly occurs in women[7], our patient was male.

By frequency, COF predominantly occurs in the mandible (over 80%) as demonstrated by Eversoleet al.[3], while other locations are less common, as presented in our case report. A very small number of articles with the localization COF in the paranasal sinuses have been published.

Undoubtedly, the only treatment of COF is a surgical treatment. Other forms of therapy are not indicated.

Depending on the size of the tumor, curettage and enucleation are the methods of choice for small lesions. For larger sizes, as was the case in our patient, surgical treatment includes wide resection of the healthy bone surrounding the tumor.

Recurrences of COF are described in literature. The incidence of recurrence after surgical treatment is different. Some authors report the occurrence of relapse in 28% of patients after curettage of COF.[3] Given the rate of relapse, postoperative follow-up is necessary - once a month in the first six months and later every three months. Control MRI is indicated six months after the operation.

In our case, subtotal maxillectomy with COF was performed. The postoperative period went without complications. Five-year postoperative period went without recurrence.

There are articles that describe patients with COF which are asymptomatic or refused surgical treatment[14]. Their condition is monitored at specific time intervals.

Conclusion

In this case report, we presented a patient with a rare localization of the COF. To set a definite diagnosis of COF, a detailed clinical examination is required, with anamnesis and additional radiologic examination, especially MRI and angiography. Surgical therapy is the only method of treatment. Postoperative monitoring of the patient is necessary, including the control MRI, due to possible recurrence or other complications.

LITERATURA / REFERENCES

1. Hamner JE, III, Scofield HH, Cornyn J. Benign fibro-osseous jaw lesions of periodontal membrane origin: an analysis of 249 cases. Cancer 1968;22(4):861–878.
2. Barnes L, Eveson JW, Reichart P, Sidransky D. Pathology and genetics of headand neck tumours.Pathology and Genetics of Head and Neck Tumours. Lyon:IARC 2005: 319–20.
3. Eversole LR, Leider AS, Nelson K. Ossifying fibroma: a clinic pathologic studyof sixty-four cases. Oral Surg Oral Med Oral Pathol 1985; 60(5): 505–11.
4. Chang CC, Hung HY, Chang JY, Yu CH, Wang YP, Liu BY, Chiang CP. Central ossifying fibroma: a clinicopathologic study of 28 cases. J Formos Med Assoc2008;107(4):288-94.
5. AlsharifMJ, SunZJ, ChenXM, WangSP, ZhaoYF. Benign fibro-osseous lesions of the jaws: a study of 127 Chinese patients and review of the literature. J SurgPathol2009;17(2):122-34.
6. Dominguete PR, Meyer TN, Alves FA, et al. Juvenile ossifying fibroma of thejaw. J Oral MaxillofacSurg 2008;46: 480–1.
7. Kansal R, Sharma A, Gaikwad N, Mahore A, AtulGoel A. Cemento-OssifyingFibroma Presenting as a Posterior Fossa Mass Lesion. Turkish Neurosurgery2010; 20(2): 265–8.
8. Mehta D, Clifton N, McClelland L, Jones NS. Paediatric fibro-osseous lesions of the nose and paranasal sinuses. J PediatrOtorhinolaryngol 2006;70(2):193-9.
9. Bal Reddy P., SridharReddy B., PrasadN., KiranG., KarthikPatlolla. CENTRAL Ossifying Fibroma of the Mandible: An Unusual Case Report.Journal of Clinical and Diagnostic Research 2012;6(3):539-541.
10. Hashmi G. Sarwar, M. K. Jindal, and Samshad Ahmad. A Case Report of Cemento-Ossifying Fibroma. J Maxillofac Oral Surg 2010;9(2): 178–181.
11. Margo CE, Ragsdale BD, Perman KI, Zimmerman LE , Sweet DE. Psammomatoid(juvenile) ossifying fibroma of the orbit. Ophthalmology 1985;92(1):150–9.
12. Kuta AJ, Macdonald W, Kaugars GE. Central cemento-ossifying fibroma of the maxilla: a review of six cases. AJNR 1995;16:1282–1286.
13. Javier SR., Javier S., Juan RB. Cemento-ossifying fibroma of the mandible: Presentation of a case and review of the literature. J ClinExp Dent 2011;3(1):66-69.
14. Ledderose GJ, Stelter K, Becker S, Leunig A. Paranasal ossifying fibroma: endoscopic resection or wait and scan. Eur Arch Otorhinolaryngol 2011; 268:999–1004.