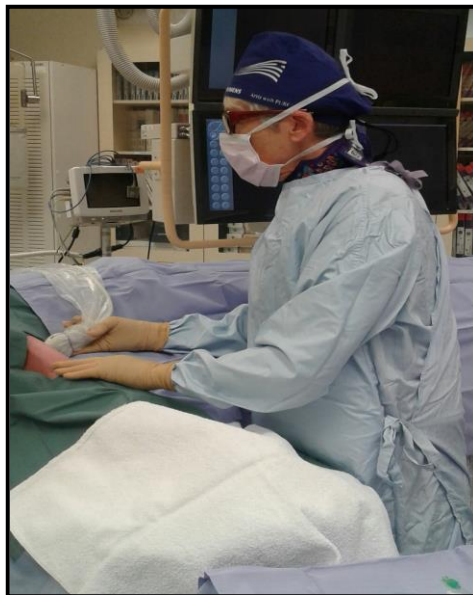

Central Venous Catheter Insertion

- **Peripherally Inserted Central Catheter (PICC)**
- **Chest Inserted Central Catheter (CICC)**
- **Tunnelled Peripherally Inserted Central Catheter (TPICC)**



An Evidence Based Training Resource Manual

For Registered Nurses

Radiology Department

Christchurch Hospital

February 2012

Reviewed and Updated February 2017

Authors:*Review date: 2018*

Philippa Francis, Clinical Manager, Radiology Department

Elizabeth Culverwell, CVAD Nurse Educator, Professional Development Unit

Reviewed by:

Janette Dallas, Nurse Manager, Professional Development Unit

Ruth Barratt, Clinical Nurse Specialist, Infection Prevention and Control

Dr Andrew Laing, Radiologist, Section Head Interventional Radiology (IR)

Victoria Whitta ACNM Radiology Department

Acknowledgements:

Stephen Cotterell RN., Radiology Department

Cleo Chisaka RN., Radiology Department

Therese Speechlay, Charge Medical Radiation Technologist

CONTENTS

INTRODUCTION	5
PROFESSIONAL ACCOUNTABILITY	6
PICC CERTIFICATION	7
LEARNING OBJECTIVES	8
<u>SECTION 1. DEFINITION PICC/MIDLINE</u>	9
PATIENT CONSENT	10-11
ANATOMY and PHYSIOLOGY	12-17
INFECTION PREVENTION and CONTROL	18-19
PRE INSERTION ASSESSMENT	20-21
Device selection	22
PREPARATION and INSERTION PROCEDURE	23-26
Interpreting chest radiographic image	27
Correct tip position	28-30
Ultrasound	31
Contrast media	32
Radiation Protection	33
Documentation	34
INSERTION COMPLICATIONS and MANAGEMENT	35
Catheter malposition	35
Vein puncture	36
Cardiac tamponade	36
Nerve injury	37
Anatomical abnormalities	37
Diabetes	37
Severe oedema	38
Lymph Vessel Puncture	38-39
Sclerosed veins	39-40
Venospasm	40
Air embolism	40
Catheter embolism	40-41
Summary	41
REFERENCES, ASSOCIATED DOCUMENTS, FURTHER READING	42-44

SECTION 2 PAEDIATRICS

Paediatric PICC Insertion	46-47
Learning objectives	48
Insertion sites –Consent	49
Catheter Selection	50
Skin Preparation, Ultrasound, Insertion	51-52
Correct Placement, Imaging	52-53
Contrast and Radiation	54
Dressing Application	54

SECTION 3 ADVANCED INSERTION SECTION - TPICC, CICC

Certification and Credentialing	58-59
Patient Selection	60
Tunnelling Procedures	60-64
Safety and Risk management	65-67
REFERENCES, ASSOCIATED DOCUMENTS	68

INTRODUCTION

The Peripherally Inserted Central Catheter (PICC), Tunnelled Peripherally Inserted Central Catheter (TPICC) and Chest Inserted Central Catheter (CICC) belongs to a group of catheters referred to as Central Venous Access Devices (CVAD). These Central Venous Catheters (CVC) are used when prolonged Intravenous (IV) therapy for the administration of multiple medications, cytotoxic agents, parenteral nutrition (PN), blood products and drawing of blood samples is required. Patient assessment and the selection of the appropriate device type is important.

PICCs, TPICCs and CICCs are invaluable for patients with multiple and complex needs, and for those who may have venous access challenges. In both the acute and community setting they provide an immediate and reliable route for intermittent and continuous intravenous administration.

PICCs are inserted under ultrasound guidance into an upper arm vein using a Seldinger technique. Tunnelled PICCs (TPICC) are tunnelled under the skin of the upper arm and into the subclavian vein or internal jugular vein. Chest Inserted Central Catheters (CICCs) are tunnelled under the skin and into the internal jugular vein.

All types of CVAD can be associated with catheter related blood stream infection (CRBSI) therefore interventions to reduce the rate of CRBSI are especially important in the insertion, management and care (Maki, Kluger, Crnich, 2006).

A safe and successful PICC, TPICC and CICC insertion is reliant on the inserter being well trained and having knowledge of a comprehensive assessment process, anatomy and physiology, documentation process and risk management.(Alexandrou et al 2014)

PROFESSIONAL ACCOUNTABILITY

Registered Nurses (RN) must meet the standards outlined in the 'Competencies' for entry to the Register of Comprehensive Nurses (Nursing Council of New Zealand [NCNZ], 2000). This applies to all nurses currently practicing.

Definition: Competence is the combination of skills, knowledge, attitudes, values and abilities that underpin effective performance as a nurse (NCNZ, 2000)

With increased scope of practice comes increased professional accountability established through the competencies described below:

- Demonstrates initial and ongoing knowledge and skills for specific expanded practice role/activities through postgraduate education, clinical training and competence assessment.
- Participates in the evaluation of the outcomes of expanded practice, e.g. case review, clinical audit, multidisciplinary peer review.
- Integrates and evaluates knowledge and resources from different disciplines and health-care teams to effectively meet the health care needs of individuals and groups.

Nurses who are practising in an expanded scope are expected to declare this when they apply for the Annual Practising Certificate and to demonstrate and document how they meet these competencies. They will be assessed as part of a professional development employer's credentialing programme and as part of the Council's recertification audit.

An expert nurse is one who works within a specific area of practice incorporating advanced knowledge and skills.

The pre-requisites for Registered Nurses who wish to be instructed in PICC, TPICC and CICC** insertion are:

1. Work in radiology
2. Have achieved certification in venepuncture, peripheral cannulation and CVAD
3. Are considered by their peers as an expert in peripheral cannulation
4. Have 2 years experience in the management and care of central lines
5. Be competent working in the Interventional Radiology (IR) suite.
6. PDRP Proficient level or above
7. Nurses advancing on to TPICC and CICC insertion are recommended by their CNM

SECTION 1

PERIPHERALLY INSERTED CENTRAL CATHETER (PICC) INSERTION CERTIFICATION

The inserting of PICCs requires expert knowledge and skill and is described as advanced practice for Registered Nurses.

Components of PICC Insertion Certification:

1. Current Peripheral IV Cannulation certification
2. Current CVAD certification (non Implanted Devices)
3. PICC Nurse Insertion certification which includes Practical Skills Assessment

Instructions for PICC Insertion Certification:

1. Complete the PICC Insertion Package
2. Complete the Theory Test (100% pass is required)
3. Insert seven PICCs under the supervision and instruction of a certified PICC Nurse Inserter assessor.
4. Complete the Practical Skills Assessment component by performing an additional three PICC insertions under observation of the PICC Nurse Insertion assessor.
5. On completion of the PICC Nurse Inserters' Certification the evidence is sent by the Radiology CNM to the Professional Development Unit (PDU) and the nurse's name is entered onto the CDHB PICC Nurses Inserters Competency data base. Eight hours for professional development will be credited and be entered onto the RN's individual training data base
6. Re-certification is required every three years which includes one observed PICC insertion. Recertification is required every three years for RNs inserting TPICC, CICC with one observed insertion required. This process will be managed by the Charge Nurse Manager Radiology. Four hours for Professional development will be credited and entered onto the RN's individual training data base

LEARNING OBJECTIVES

This comprehensive Self directed Learning Package is designed to assist the RN to develop critical thinking skills and demonstrate knowledge in the assessment and insertion of PICCs and Peripheral Midline Catheters.

At the completion of the PICC Nurse Insertion competency the RN should be able to:

- Describe patient assessment and consent process
- Select the appropriate PICC/Midline catheter for insertion
- Describe the anatomy and physiology of veins in relation to the insertion of a PICC/Midline catheter
- Describe factors affecting blood flow and the impact on PICC line placement
- Identify and select an appropriate vein for insertion in the upper arm
- Describe the principles of infection prevention and control
- Describe Maximal Sterile Barrier (MSB) in relation to PICC/Midline insertion
- Demonstrate knowledge in the use of the ultrasound probe and fluoroscopy
- Demonstrate correct technique for accessing the selected vein and inserting the catheter
- Demonstrate knowledge of correct catheter tip position on X-ray using the correct landmarks of the heart, carina and 4th rib
- Identify complications and describe prevention and intervention of each
- Demonstrate correct dressing and securement
- Discuss contra indications of PICC insertion
- Discuss reasons for insertion
- Describe accurate documentation
- Participate in quality assurance initiatives and audit of PICC insertions.

Throughout this package are ‘ALERTS’ ‘ACTIONS’ and ‘FURTHER READING’



This symbol indicates ‘important alerts’



This symbol indicates ‘for further reading’

ACTION

This symbol indicates ‘important actions’

DEFINITION OF A PICC

PERIPHERALLY INSERTED CENTRAL CATHETER:

A Peripherally Inserted Central Catheter (PICC) is described as a central line that is inserted into a peripheral vein in the upper arm and advanced along the vein until the tip resides at the cavoatrial junction (CAJ). The preferred vein of choice is the right basilic because it is larger, straighter and offers a less tortuous route to the SVC (Standards for Infusion Therapy 2016).

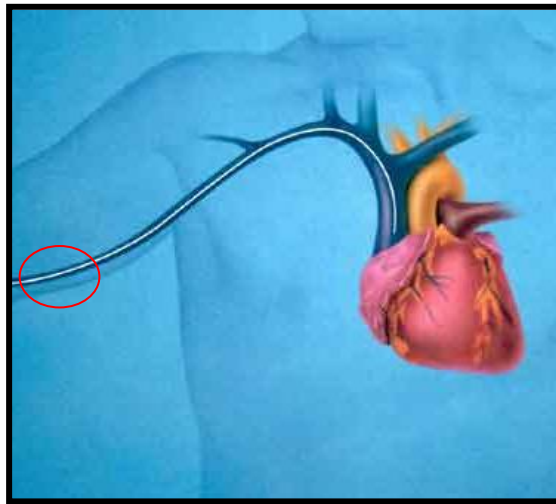


Figure: 1

Source: unknown

PATIENT CONSENT

Obtaining Informed Consent

The CDHB Policy provides a framework that describes recommended best practice in all situations that may require informed consent. All staff must ensure they practice within this frame work (Volume 11 Clinical [Informed Consent](#)). Informed consent is defined as the process whereby someone who has the capacity/competence to consent, having been given sufficient information, arrives at a reasonable decision as to whether or not to agree to a proposed therapy or procedure.

Consent may be given orally or in writing depending upon a number of issues (Refer to page 14 [Vol 11](#)). Informed consent is not the act of filling out forms, but rather a process of exchange of information so that an informed decision can be made.

The patient has the right to be accurately and adequately informed about a proposed procedure or treatment and to agree or refuse to have that procedure or treatment. All health professionals have a responsibility to inform patients about a proposed procedure and to gain consent for that procedure. Where difficult situations arise, advice should be sought by the health professional from their clinical director and/or Medical Advisor.

ACTION:

Ensure patient receives the Patient Information Pamphlet on PICC insertion.



Read the section on Informed Clinical Consent found in – [Vol 11](#) pages 10-14

Patient Consent Continued:

Use the following anagram '**BITTEM**' as a quick reference guide to describe or identify risk to patient when obtaining patient consent for a PICC insertion.

Bleeding – accidental arterial puncture, venous puncture site may ooze post insertion; instruct patient to keep the arm still for an hour post insertion

Infection – Clean arm and use MSB draping to reduce risks of infection during insertion. Always use effective hand hygiene before touching the PICC

Thrombus – in vein and PICC lumen can occur. Report any swelling in hands or arm

Tip malposition – using fluoroscopy guidance during insertion, and documenting the external measurement of PICC. If excessive vomiting or coughing occurs an X-ray to check position of PICC may be required

Embolus – to prevent air or catheter embolus secure catheter connections securely and remove air from the lines

Mechanical phlebitis – minimize trauma during insertion. Reduce overuse of arm

ACTION: Use this anagram as a prompt when consenting the patient

ANATOMY AND PHYSIOLOGY

Knowledge of anatomy and physiology, the principles of blood flow along with careful assessment of the patient prior to attempting catheter placement is essential for ensuring successful insertion of a PICC or Midline catheter. The PICC inserter needs to know how to identify the carina, heart border and rib spaces and know their significance. Figure 3 and 4 shows the major veins of the central vasculature where PICCs are placed.

All CVADs have the potential to become displaced although displacement is more likely to be seen with PICCs. This is due in part to their smaller diameter. The tip can migrate or become mal positioned in the following veins:

1. Internal jugular
2. Contra lateral brachiocephalic
3. Azygos
4. Migration into the atrium and ventricle

Action: Locate the above sites on figures 3 & 4

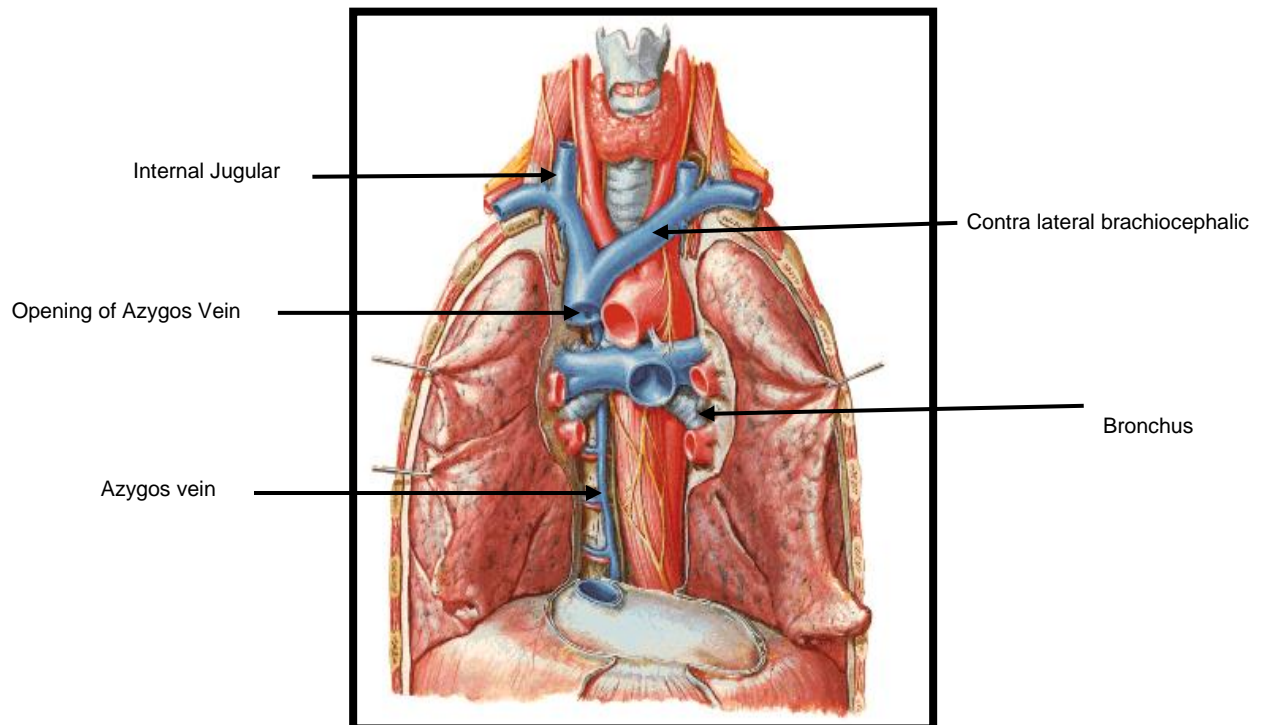


Figure: 3. Major Central Veins

Source: Medical Illustrations, Christchurch Hospital

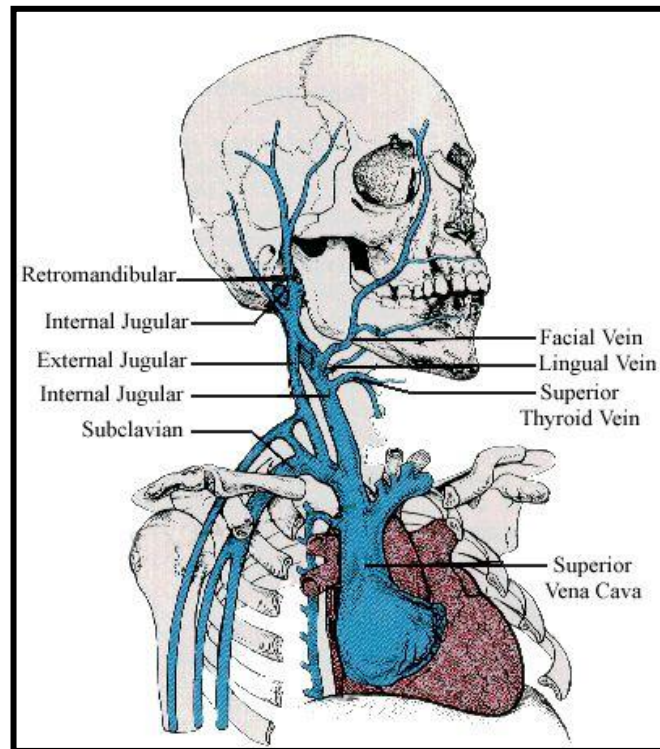


Figure: 4.

Source: unknown

Choice of Vein for Insertion

Examine both arms using a tourniquet to identify the largest vein on ultrasound. The right basilic vein is the vein of choice however other factors can dictate the vein and arm used for example a patient who has had a mastectomy with node clearance. For further information on ultrasound refer to the section on Ultrasound in this document.

The Basilic and Brachial veins

The median basilic vein is the vein of choice for PICC insertions owing to its larger size, straighter course for catheter advancement and improved haemodilution capability (SIT 2016). The basilic vein begins in the ulnar area (inner aspect) of the forearm, runs along the posterior, medial surface (back of the arm) and then curves towards the antecubital region, where it is joined by the median cubital vein. It then progresses straight up the upper arm for approximately 5–8 cm and enters the deep tissues. It ascends medially to form the axillary vein. Brachial veins are located deep in the arm alongside the brachial artery and nerve and are slightly smaller than the basilic. Ultrasound is promoted as best practice to locate and access them. (Standards for Infusion Therapy 2016).

The Median Cubital vein

The median cubital vein ascends from just below the middle of the antecubital region and divides into two vessels one joins the basilic and the other the cephalic vein. The median cubital vein is commonly used for blood sampling owing to its size and ease of access. It is generally not used for PICC

insertion because of the site of insertion (constant bending of the arm) which can give rise to complications such as mechanical phlebitis.

The Cephalic vein

The cephalic vein begins in the radial side (thumb side) of the hand and ascends along the outer region of the forearm into the antecubital region, where it forms a junction with the axillary vein. This vein is usually more accessible than the basilic but its size and the sharp angle where it joins with the subclavian vein make it more difficult to advance the catheter. It therefore presents a greater potential for catheter tip malposition (Hadaway 2010)

Valves

Valves are structures within the lumen of the vein which are formed by the endothelial lining of the Tunica Intima. Venous valves appear as bumps and are usually found at vein bifurcation. They are predominantly found in large veins of the extremities, refer to figure 5. There are approximately 40 venous valves between the hand and the distal end of the axillary vein. Larger veins of the central vasculature do not have valves.

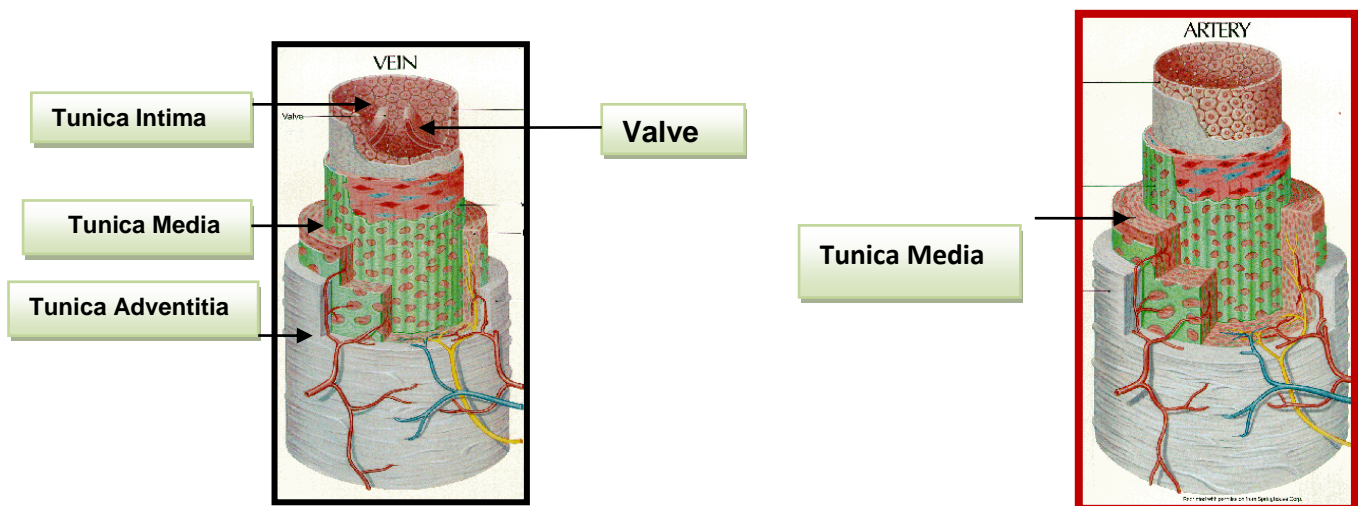


Figure: 5&6.

Source: Johnson & Johnson Medical



The tunica media is the muscle layer of the vein. Veins have a thinner muscle layer than an artery. Veins are compressible due to less intra luminal pressure, therefore when compressing the vessels under ultrasound the vein flattens where as the artery does not. This allows the clinician to distinguish between the pulsating artery and compressed vein. A thrombosed vein is very hard to compress due to stenosis.

Trauma to the vein during insertion

When the Tunica Intima is damaged, bleeding occurs into the interstitial compartments of the basement membrane and the Tunic Adventitia, which is rich in nerves and provides the pain pathway.

One or all three layers can be affected giving rise to phlebitis. PICCs are most affected by mechanical phlebitis. Mechanical phlebitis occurs following a difficult insertion or when the PICC is not secured well causing the PICC to move within the peripheral vein causing irritation to the vein intima. This is often referred to as 'pistoning' or moving back and forth.

In addition overuse of the arm where the PICC is in-dwelling can cause the muscles to contract compressing on the vein resulting in irritation to the vein wall giving rise to mechanical phlebitis.

Phlebitis is an inflammatory process of the intima of the vein, as a result of irritation to the endothelial cells (refer figure 7). It is classified according to its causative factors. The four causative factors are:

1. Chemical
2. Mechanical
3. Bacterial
4. Post infusion related to type of solution

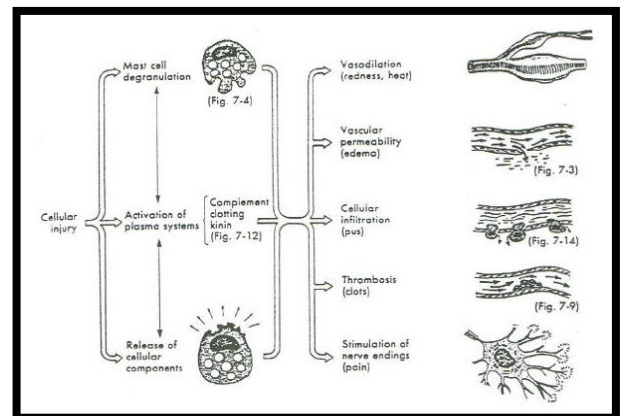


Figure: 7

Source: Johnson & Johnson Medical

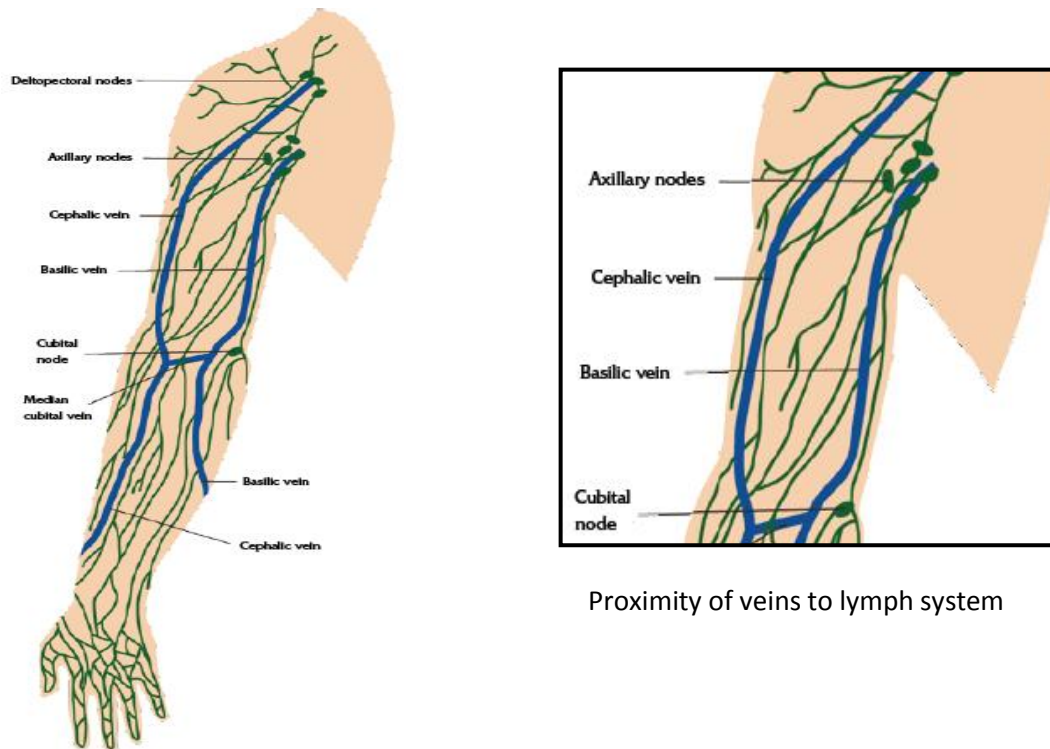
Trauma to the lymph system during insertion

The lymphatic system is an essential component of the immune system. A vast network of lymphatic vessels collects excess fluid from the cells and subcutaneous tissue in order to minimise fluid accumulation. Lymph is a watery fluid derived from plasma. It is transported in one direction towards the heart via the lymph system.

In the arm, the main lymph nodes are the superficial supratrochlear gland above the antecubital fossa and the deep glands of the axilla. Both are responsible for lymph drainage of the arm.

A network of lymph vessels is responsible for the transportation of lymph fluid between the glands.

The close proximity of lymph vessels to the veins used to place PICCs in the upper arm varies from one individual to another, so it is impossible to predict their location in relation to the vein.



Physiology of blood and blood flow rates

PICCs are inserted into an appropriate vein and advanced along the venous system until the catheter tip reaches its destination at the cavoatrial junction (CAJ). The superior vena cava is on average 20mm in diameter and has a high blood flow of approximately 2000mL/min, far greater than in a peripheral vein (refer to table 1).

This means that irritant drugs and fluids, those solutions with extremes of pH or osmolality can be infused without damaging the SVC vein wall due to increased haemodilution. Therefore when you perform a patient assessment you need knowledge of:

- Blood viscosity
 - Results in resistance to flow when pressure is applied.
 - A connection between phlebitis development and elevated haemoglobin levels has been identified.
 - Higher haemoglobin levels produce greater rates of phlebitis due to slower blood flow reducing dilution of irritating medications (Infusion Therapy Standards 2016)
- Blood osmolality
 - Reflects the potential for water movement and water distribution between and within body fluid compartments.
- Blood pH
 - The body continually produces acids that are then neutralised and excreted to maintain homeostasis.
- Coagulation
 - The first stage of clotting process begins immediately after vessel injury when smooth muscle in the vessel wall contracts and reduces the blood flow from the vessel opening.
 - The response of the smooth muscle comes from nerve reflexes and thromboxane released by platelets. A greater degree of trauma produces a greater vasospasm.

VEIN FLOW RATES

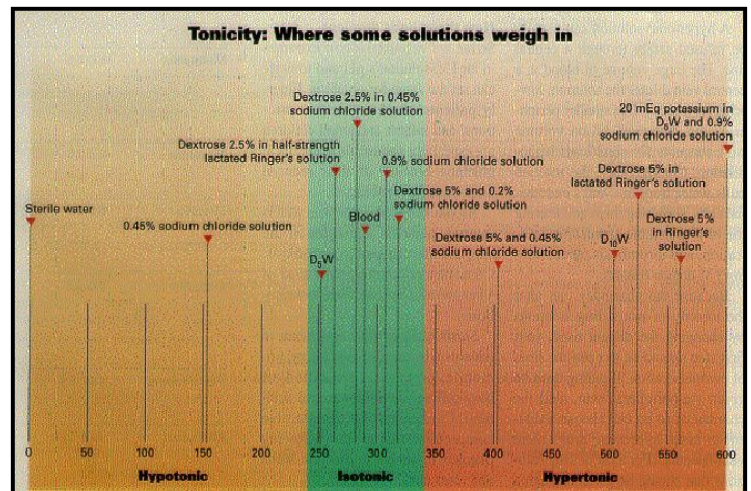
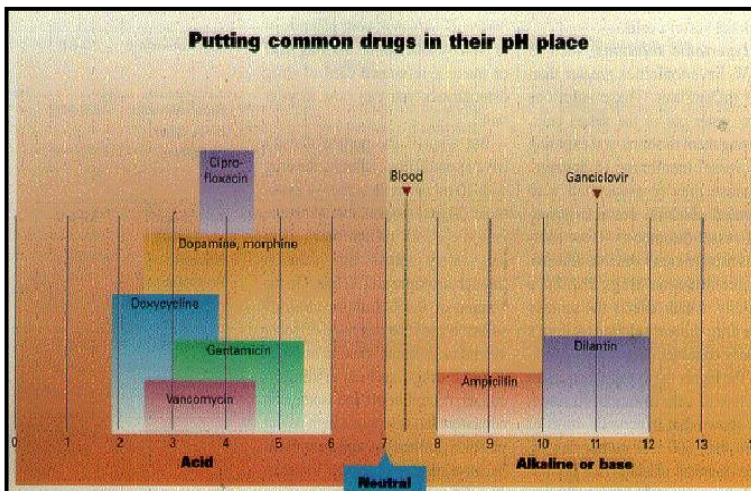
VEIN	DIAMETER	FLOW RATE	LENGTH
Cephalic	6mm	40-60ml/min	38cm
Basilic	8mm	60-95ml/min	24cm
Axillary	16mm		13cm
Subclavian	19mm	150ml/min	2.5cm
Innominate	19mm	800ml/min	6cm
Superior Vena Cava	20mm	2000ml/min	7cm

Table 1.

(Terry,1995)



It is important to have knowledge of the flow rates and diameter of veins to determine if the prescribed medication/fluids are suitable if a PICC cannot be advanced through to the SVC and is left in the subclavian vein. or becomes a Midline catheter. If medications are irritant, have extremes of pH and osmolality the vein wall can be damaged giving rise to chemical phlebitis which can then lead on to thrombo phlebitis and thrombosis.



 For further reading on Preventing Chemical Phlebitis refer to K Kokotis in 'For Further Reading' section.

INFECTION PREVENTION AND CONTROL

Maximal sterile barrier precautions (MSB) should be used to reduce the chance of catheter contamination and subsequent CRBSI. For the nurse inserting a PICC/Midline catheter and for those assisting in the procedure, maximal sterile barrier precautions means strict compliance with hand hygiene, mask, hat and sterile gown and gloves. For the patient, applying maximal sterile barrier precautions means covering the patient with a large sterile drape, with a small opening for the site of insertion (Centres for Disease Control, 2015; SIT 2016; Institute for Healthcare Improvement, 2008).

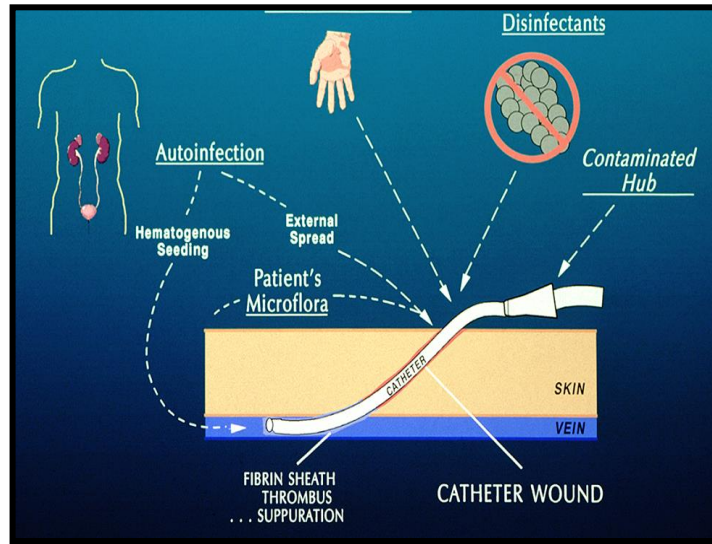
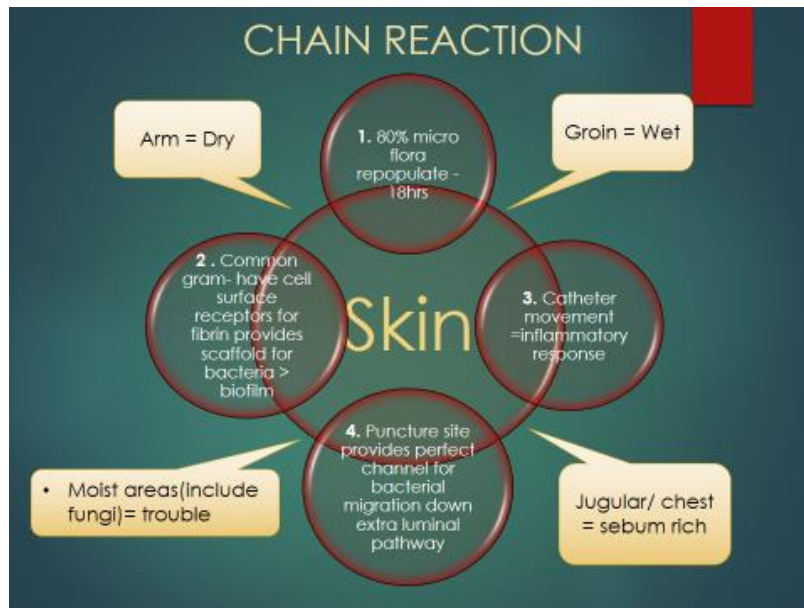


Figure: 8.

Source: Unknown



 **85% OF BACTERIA FOUND ON THE SKIN ARE RESPONSIBLE FOR CRBSI** (Maki, Kluger, Crinch 2006).

Care Bundles

An evidence-based approach underlies the strategies for the prevention of CRBSI. Interventions are based on the concept of 'bundles' of care components which incorporate individual practices that together result in greater improvements than when used individually. There are two care bundles of components aimed at the prevention of CRBSI (Institute for Healthcare Improvement, 2008). The Health Quality and Safety Commission NZ are currently running a national collaborative in the intensive care units to prevent Central Line Associated Bacteraemia. They are using bundles of care for both insertion and maintenance. They aim to extend this to all inserters of CVADs in the future.

Application of the '5 Moments for hand hygiene' should be incorporated into the insertion process.

Moment 1: Before Touching a Patient

Moment 2: Before a Procedure / Aseptic technique

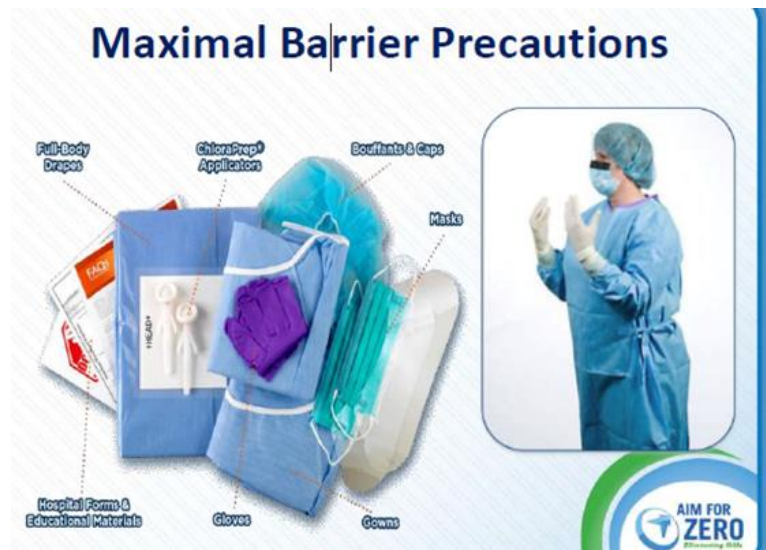Moment 3: After a Procedure or Body Fluid Exposure Risk

Moment 4: After Touching a Patient

Moment 5: After contact with patient surroundings

CVAD insertion bundle

- Hand hygiene
- Maximal barrier precautions
 - hat,
 - mask,
 - sterile gloves
 - gown for inserter
 - large sterile drape
- Chlorhexidine 2% & 70% alcohol skin antiseptics
- Optimal catheter site selection
- Use of ultrasound guidance



CVAD maintenance bundle

- Daily review and documentation of line necessity and prompt removal of unnecessary lines
- Hand hygiene
- Dedicated lumen for Parenteral Nutrition (PN). This is the white lumen of a multiple lumen catheter
 - Access the CVAD lumens aseptically using vigorous friction and 70% alcohol and 2% chlorhexidine wipes prior to access
 - Allow to dry
 - Ensure patency is maintained by flushing all lumens
 - Use positive displacement devices
 - Daily review and documentation of entry & exit site and the surrounding area for signs of infection

PRE INSERTION ASSESSMENT

A thorough and robust assessment process is vital prior to insertion of a PICC/midline catheter. It is important to ensure that contraindications to insertion are identified early and that a comprehensive history is obtained.

Indications for PICC insertion:

- Long term treatment protocols which include irritant and vesicant drugs, medication with extremes of pH and osmolality, cytotoxic and biotherapies and parenteral nutrition.
- Refer to the Notes On Injectable Drugs (NOID) to ascertain medication properties and recommended methods of administration [Notes of injectable drugs hyperlink](#)
- Blood products administration
- Blood sampling
- Poor or limited venous access

Contraindications and Considerations for PICC insertion:

Persistent Vomiting /coughing

Situations which cause changes in inter thoracic pressure leading to catheter mal position, catheter erosion or cardiac tamponade. A comprehensive patient history is important to ensure potential complications are avoided.

Past Irradiation of the Site

If the skin of the prospective insertion site has been exposed to radiation as part of the patient's treatment this can compromise the skin integrity making it unsuitable for a PICC insertion.

Patient Life style / non compliance

Where the patient's life style or their non compliance with the device can lead to catheter failure and premature removal.

Skin Infection

A skin infection at the proposed insertion site. Any bacteria that are on the skin can easily be introduced into the line and cause a septic infection for the patient. It is better to find another site at which to insert a line to avoid skin that already has a bacterial problem.

Known Central Vascular Occlusions/ Trauma to upper chest or arm

Anything that may impede the easy feeding of the line into the central venous space is a contraindication for a PICC. For instance, if the vein is thrombosed or if the patient has an indwelling pacemaker, a PICC cannot be inserted on the side in which the pacemaker is resident as it would interfere with the insertion of the line and perhaps the functioning of the pacemaker. Anything else that occludes the vasculature is also a contraindication as is any malformation of the heart that may have required surgery.

Dialysis Fistula

A dialysis fistula in the intended arm for the PICC is a contraindication; due to the rerouting of the vasculature of the arm. A possible contraindication is in patients who have end-stage renal disease, as the upper extremity may need to be preserved for future fistula usage; it is important to weigh the risks versus the benefits in such cases.

Mastectomy and Lymphoedema

A PICC line cannot be inserted in the arm on the side on which a female has had a radical mastectomy with lymph node dissection, as the lymph system is faulty and unable to drain, so inserting a PICC may lead to further complications. Consider using a TPICC or CICC.

Sepsis

If a patient has a bacterial sepsis, a PICC should not be inserted until the blood cultures come back negative. This is to minimize the risk for further infection and attendant complications. However the PICC insertion should be re-evaluated and discussed with the patient's team based on the urgency for central line access.

Patient Assessment for PICC Insertion:

- Current diagnosis and past history
- Hydration status
- Underlying medical conditions e.g. heart disease, diabetes, atherosclerosis, hypertension
- Previous surgical procedures especially on the side of the PICC insertion
- Previous Central line /PICC /Midline insertion history
- Current medications e.g. warfarin, steroids, diabetic medications
- Physical restrictions or contra indications e.g. CVA, mastectomy
- Ability to self care (if managing the PICC in the home setting)



Consultation with the patient's medical team is necessary

Device Selection Algorithm

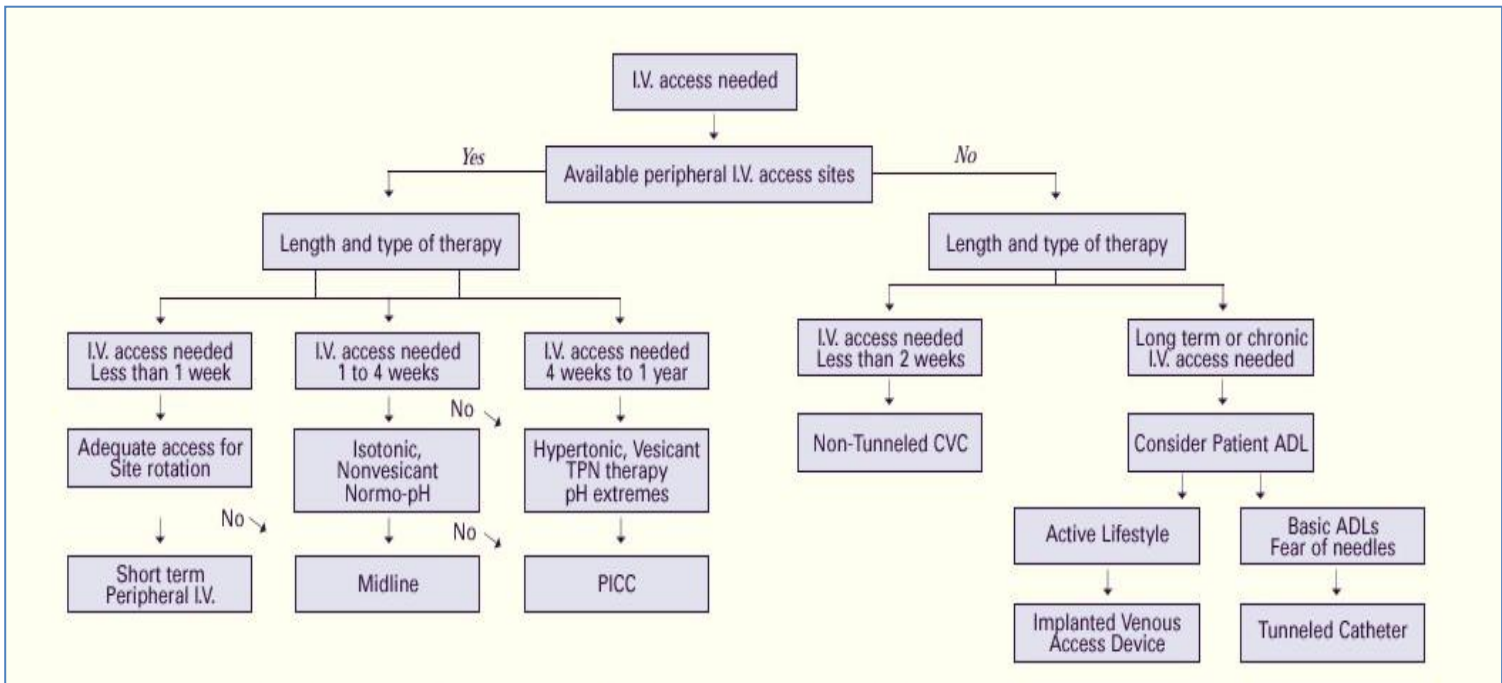


Figure: 9 Device Selection Algorithm

Source: Johnson and Johnson Medical



This algorithm is a tool to assist with the appropriate catheter selection. Consideration must be given to the type of infusates to be administered, specific IV protocols, the length of dwell; underlying conditions such as the immune status and the clinician’s recommended catheter type i.e. double lumen access.

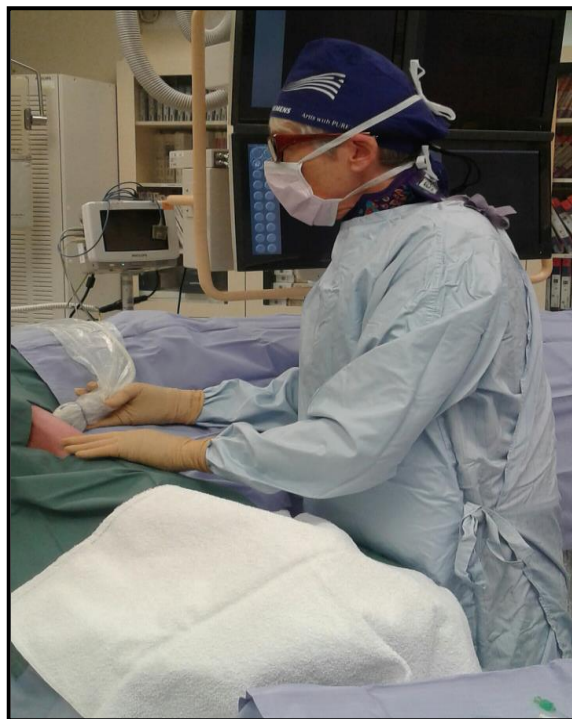
CATHETER TYPE	SIZE	MATERIAL	INTERNAL LUMEN SIZE
Power PICC Single lumen	20g /3fr	Polyurethane	0.3mL
Power PICC Single Lumen	18g / 4fr	Polyurethane	0.8mL
Power PICC Double lumen	16g / 5fr	Polyurethane	0.8mL

Table: 2.

PREPARATION AND INSERTION PROCEDURE

Preparation for PICC Insertion

1. Verify authorized prescriber's order on requisition
2. Patient consent and education with family/whanau involvement
3. Patient assessment.
4. Perform hand hygiene and prepare patient.
5. Remove any excess hair from the skin using clippers
6. Position patient on table in supine position
7. Wash the arm
8. Prepare the room and equipment for insertion



Preparation of patient for a PICC insertion

Source: Original

The Insertion Procedure for a PICC

1. Perform hand hygiene using antimicrobial liquid soap or alcohol hand gel
2. Clean the skin of the upper arm to be accessed using a chlorhexidine 2% liquid soap and dry area
3. Don in this order hat, mask, surgical scrub, gown up and double glove
4. Prepare equipment for procedure
5. Prepare the skin with 2% chlorhexidine and 70% alcohol using vigorous friction. Allow to dry
6. Drape the patient using sterile drapes
7. Apply tourniquet
8. Drape ultrasound machine and apply gel to probe
9. Remove outer gloves
10. Access vein using ultrasound and Seldinger technique and insert guide wire when blood appears from needle hub
11. Remove needle over wire
12. Release tourniquet
13. Place peel-a-way introducer into vein by threading over guide wire
14. If the PICC is trimmed refer to page 25
15. Remove guide wire and dilator leaving peel-a-way in vein
16. Thread catheter into vein through the peel-a-way 10 to 20cms, then continue to advance slowly using image intensifier guidance until the catheter tip is in position
17. Confirm PICC tip is at cavoatrial junction using radiographic image intensifier
18. Check PICC measurements and document on CVAD Insertion Form
19. Remove peel-a-way, check for blood return and that the catheter flushes well
20. Clean site.
21. *PICC Securement using surgical adhesive:*
 - a. When bleeding has stopped apply surgical adhesive to the insertion site and for 2cms from the insertion site under the PICC. Hold PICC on the adhesive until bonding has occurred and the adhesive is set.
 - b. If a SecurAcath is the appropriate choice, dilate the insertion site and place the device and position the PICC according to the manufacturer's instructions. Apply surgical adhesive around the insertion site for haemostasis.
22. Dispose of equipment as per best practice and protocols
23. Remove gloves and perform hand hygiene
24. Complete all documentation - Refer to documentation section page 26
25. Give patient all information cards, booklets and documentation
26. Assess patient is stable and there is no bleeding before they leave Interventional Radiology (IR)

Measure vessel diameter; catheter to vein ration of 45% or less

TECHNIQUE FOR TRIMMING A PICC

No 14

- a) Remove introducing guidewire and introduce measuring wire into dilator
- b) Using Image Intensifier guide measuring wire until tip is at cavoatrial junction
- c) Measure with measuring tape provided in the pack. Line the 60cm mark on the tape with the 60cm mark on the measuring wire
- d) Measure to the insertion site on the skin. Add 4cm (for external measurement). Confirm measurement with the MIT involved in the case
- e) Once the MIT and nurse agree on the measurements, MIT and nurse check and confirm measurements on PICC. Trim the PICC
- f) Flush the PICC with normal saline
- g) Remove the dilator from the peel-away sheath over the wire
- h) Introduce the PICC over the measuring wire. DO NOT advance the wire while introducing the PICC
- i) Use Image Intensifier when advancing the PICC over the wire
- j) When there is 4cm of PICC external on the arm remove the measuring wire, split the peel-away and remove without moving the PICC
- k) Confirm PICC tip is at cavoatrial junction using radiographic image intensifier

 For further reading click here: Picc Line Nursing.com

PICC STABILIZATION:

PICC securement provides a safe environment for both the patient and the nurse. Successful securement protects the catheter from several sources of failure until the end of therapy by preventing movement during all phases of care.

PICC Movement causes:

1. Vein trauma
2. Bacterial migration
3. Distal tip migration
4. Loss of dressing integrity
5. Total dislodgement.

PICC movement results in:

1. Extra luminal catheter related blood stream infection
2. Venous thrombosis
3. Delayed treatments
4. Catheter replacement
5. Life threatening patient outcomes
6. Increased cost

Selection Criteria for appropriate PICC securement:

Surgical adhesive is effect for:

- PICCs required for 2 and up to 6 weeks
- No history of migration or factors require the patient to have a more secure method.

SecurAcath (subcutaneous sutureless securement device) is used for:

- PICCs that are required for 8 weeks or longer
- Patient has a history of PICC migration
- Compromised upper arm vascular access
- Irritant contact dermatitis
- Patients in shared care (hospital and community providers)

TIPS FOR READING THE CHEST RADIOGRAPHIC IMAGE

PICC tip location with the greatest safety profile is the cavoatrial junction

- 1) If the tip overlies the right main bronchus, the tip is in the SVC below the azygos vein
- 2) This can be located between the 2nd and 5th intercostals space
- 3) It is easier to locate the catheter at the clavicle and follow it to the tip than to locate the catheter in the chest region of the film
- 4) A non portable x-ray will give better quality if fluoroscopy is unavailable
- 5) If the film is portable and the patient large, have the MRT over penetrate the film. This will make the catheter more visible but these films cannot be used to check lung fields.

Source: Infusion Therapy Standards 2016

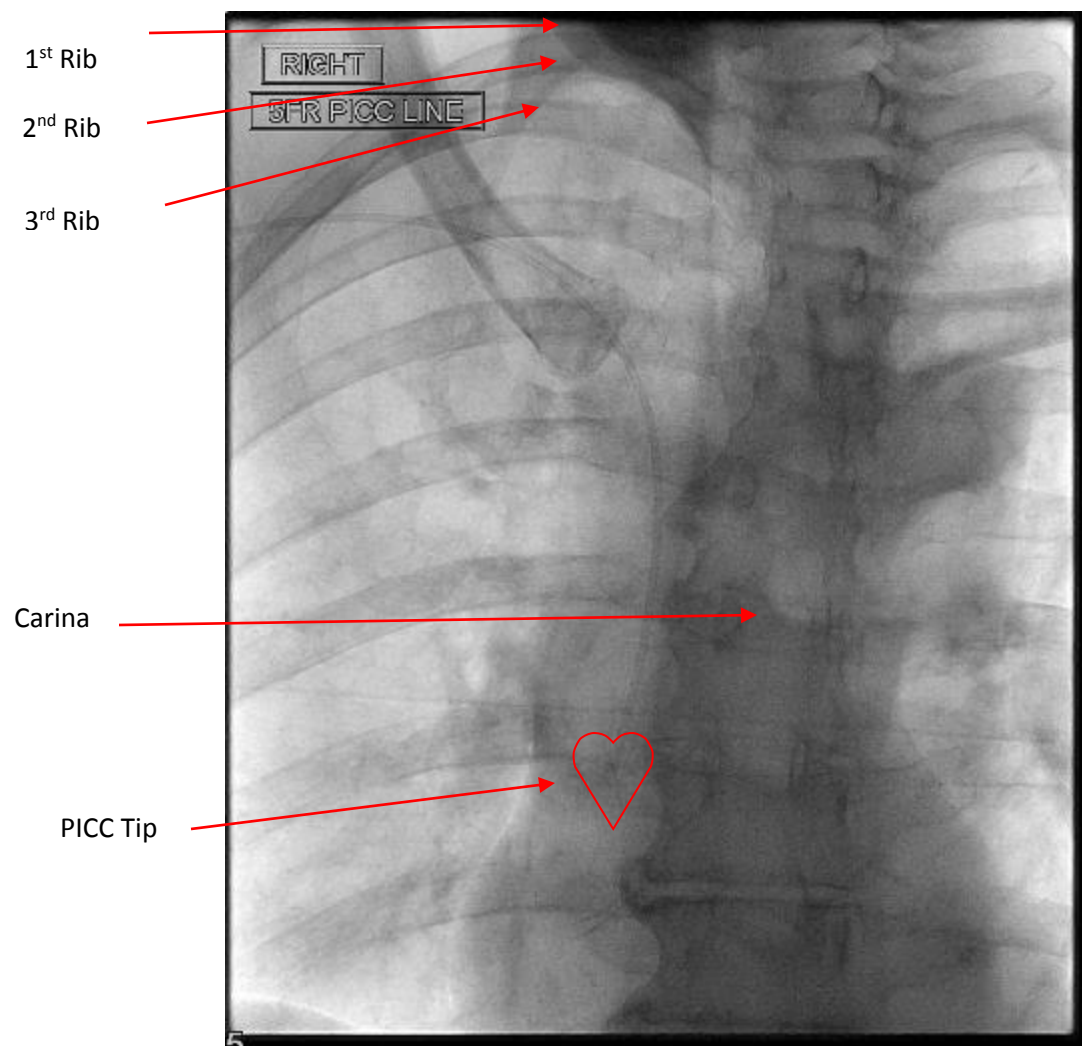


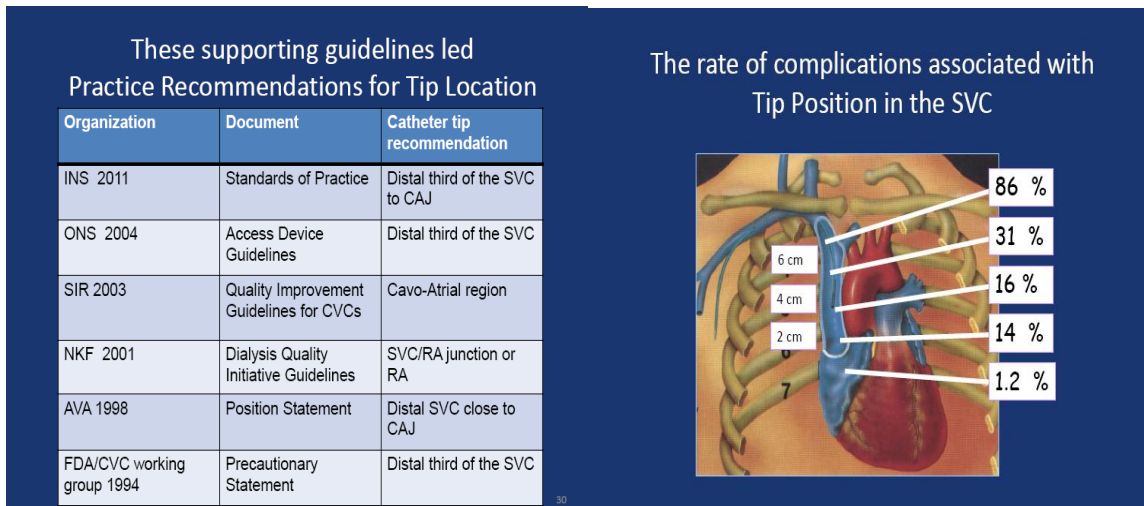
Figure: 10.

Source: Original

CORRECT PICC TIP POSITION

Most consensus guidelines agree optimal tip position of the PICC tip should sit in the lower SVC to the right cavoatrial junction, parallel to the vessel wall. (Standards of Infusion Therapy 2016) Recent guidelines published in 2013 suggest that in infants and older children the tip should lie in the distal SVC or right atrium. In premature infants earlier papers suggest the tip should lie 5-10 mm outside the cardiac chambers.

This distal position minimises the risk of catheter related complications associated with more proximal positions.



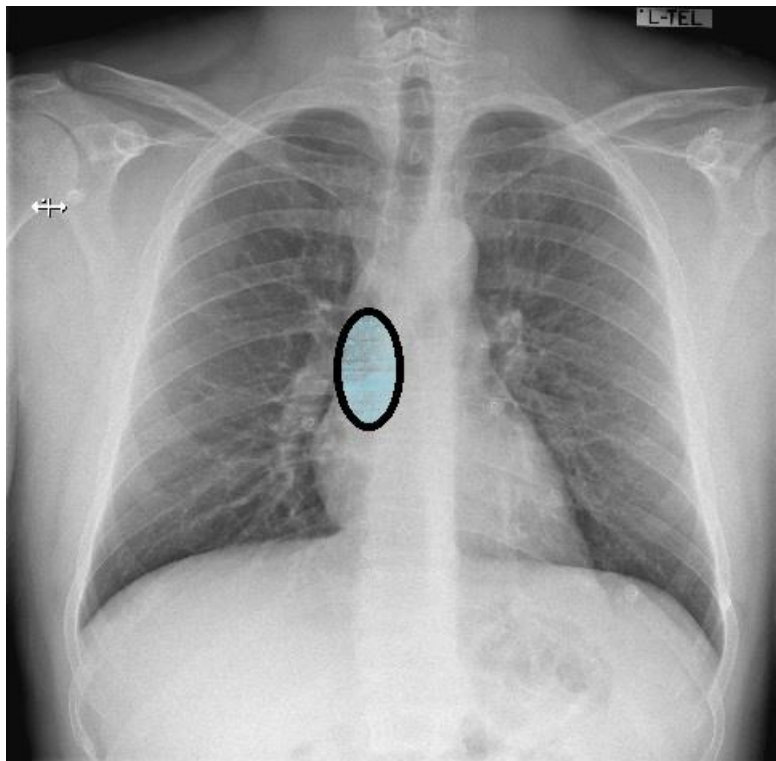
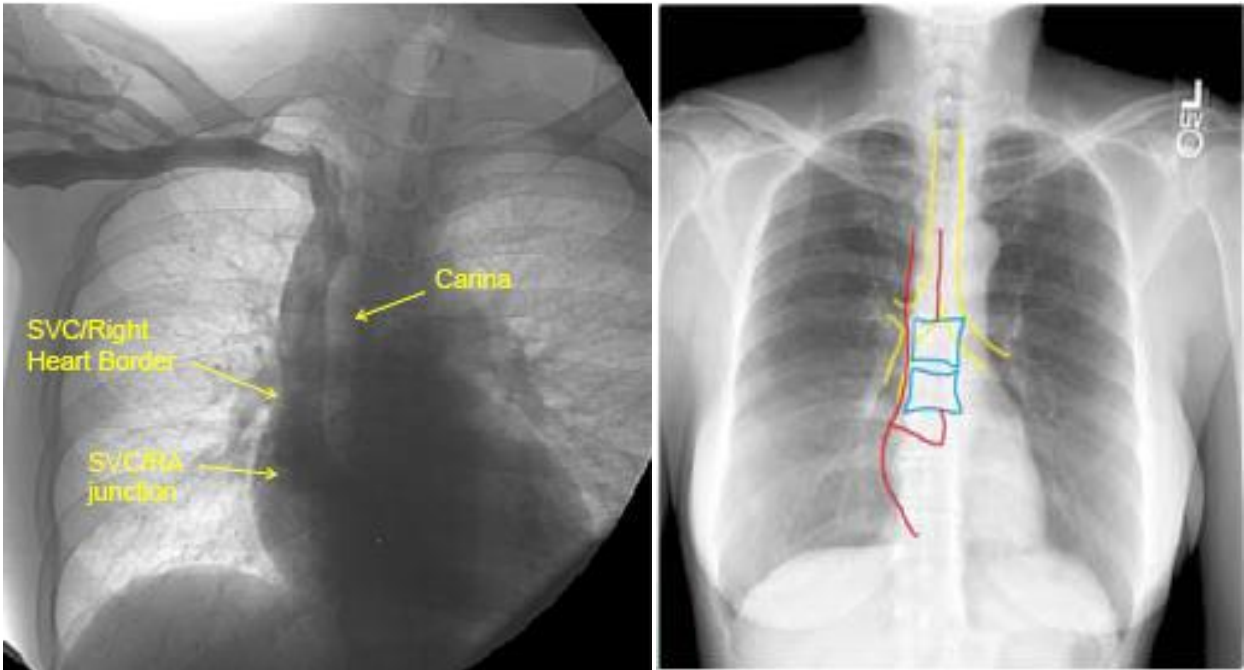
Tip position is influenced by positioning of the arm. Adduction of the arm will cause a line placed via the basilic or axillary vein to migrate towards the heart and a line via the cephalic vein to migrate away. Interventional radiology inserted PICC's on paediatric patients have images taken with the tip position documented on adduction and abduction of the arm at the time of insertion and these should be available for comparison.

Chest x-rays taken to check PICC position should be performed with the arms at the patient's side. If the tip position is not adequately identified on a PA or AP chest a shallow right posterior oblique radiograph may be helpful.

Based on the consensus guidelines a satisfactory tip position on a plain radiograph is between the carina and the SVC/ CAJ. The SVC/CAJ sits approximately 2 vertebral levels below the carina. (See images)

The SVC/right heart border is not an accurate indicator of the SVC/CAJ but if the carina is obscured the junction sits 10-20 mm below this border in most instances. Other bony landmarks such as the 6th vertebral body or anterior 3rd/4th rib space are less accurate.

If there is ongoing difficulty in determining satisfactory PICC position fluoroscopy with contrast or ultrasound can be performed.



Blue oval indicates optimal tip position according to consensus guidelines.

Central venous catheter tips should be positioned in the SVC/CAJ, therefore allowing the tip to lie parallel to, and not impinge on the vein wall. Contact to the tunica intima disrupts endothelial cells and increases complication rates such as thrombosis (Murray, Precious, Alikhan 2013; Journal of Clinical Oncology 2013; Maneval, Clemence 2014; UK Vessel Health and Preservation Framework 2016; Pettit & Wyckoff, 2007;). This is best obtained through a right arm insertion site. PICC's have the potential to migrate into the right atrium with arm movement.

When the arm is adducted catheters inserted in the basilic and axillary veins move towards the heart. On abduction the catheter moves away from the heart, significantly altering the position of the catheter tip. This movement may cause myocardial perforation, and place the patient at risk of pericardial effusion or cardiac tamponade.

Catheter migration is a common problem reported in PICC's in Paediatric and neonates (Nadrou et al., 2002). No force is placed on any catheter or wire that does not travel smoothly along the vessel. If resistance is felt the guide wire can be replaced with an angled glide wire (Dubois, 1997). Continuous fluoroscopy is used at this stage to ensure the wire advances to the correct position and does not enter the heart as it will cause cardiac arrhythmias.

Bibliography

1. Peripherally inserted central catheters in infants and children- indications, techniques, complications and clinical recommendations. *Acta Anaestheiol Scand* 2013; 57:278-287
2. Are supine chest and abdominal radiographs the best way to confirm PICC placement in neonates? *Neonatal Network* 2010; 1 :23-35
3. Safe placement of central venous catheters: where should the tip of the catheter lie? *British Journal of Anaesthesia* 2000: 188-190.
4. Evidenced based consensus on the insertion of central venous access devices: definition of minimal requirements for training. *British Journal of Anaesthesia* 2013; 110 (3):347-56
5. CT angiography of the superior vena cava: normative values and implications for central venous catheter position. *JVIR* 2008; 19 (3):359-65
6. Optimising patient positioning for PICC tip determination. *Emergency Radiology* 2004; 10(4):186-9.
7. Silicone venous access devices positioned with their tips high in the superior vena cava are more likely to malfunction. *AM J Surg* 1999; 178 (1):38-41

Ultrasound Guidance

Ultrasound guidance has increased the success rate and minimized complications related to insertions of PICC's. Ultrasounding the patient's upper arm allows the inserter to clearly visualize the vein, artery and surrounding anatomy. It also assists to identify problems such as stenosis or thrombosis of the vein (Moureau, 2003, Simcock, 2008).

Ultrasound guidance ensures correct catheter placement, minimising complications such as arterial puncture, mechanical phlebitis, infection and thrombosis and creates reliable access for patients with veins that are difficult to access.

The ultrasound probe (transducer) is placed on the arm so that a transverse view of the vein is obtained (refer figure 11). This view enhances the imaging so that the insertion of the micro puncture needle can be guided into the vein. Once the vein is entered blood will appear at the hub of the needle. Then the micro puncture guidewire can be introduced through the needle into the lumen of the vein. If any resistance occurs, the wire and needle should be withdrawn and the vein re-punctured at another site.

Fluoroscopy is used to observe the passage of the catheter as it is passed along the vein. It visually identifies if the catheter becomes malpositioned and alerts the inserter to take appropriate action.

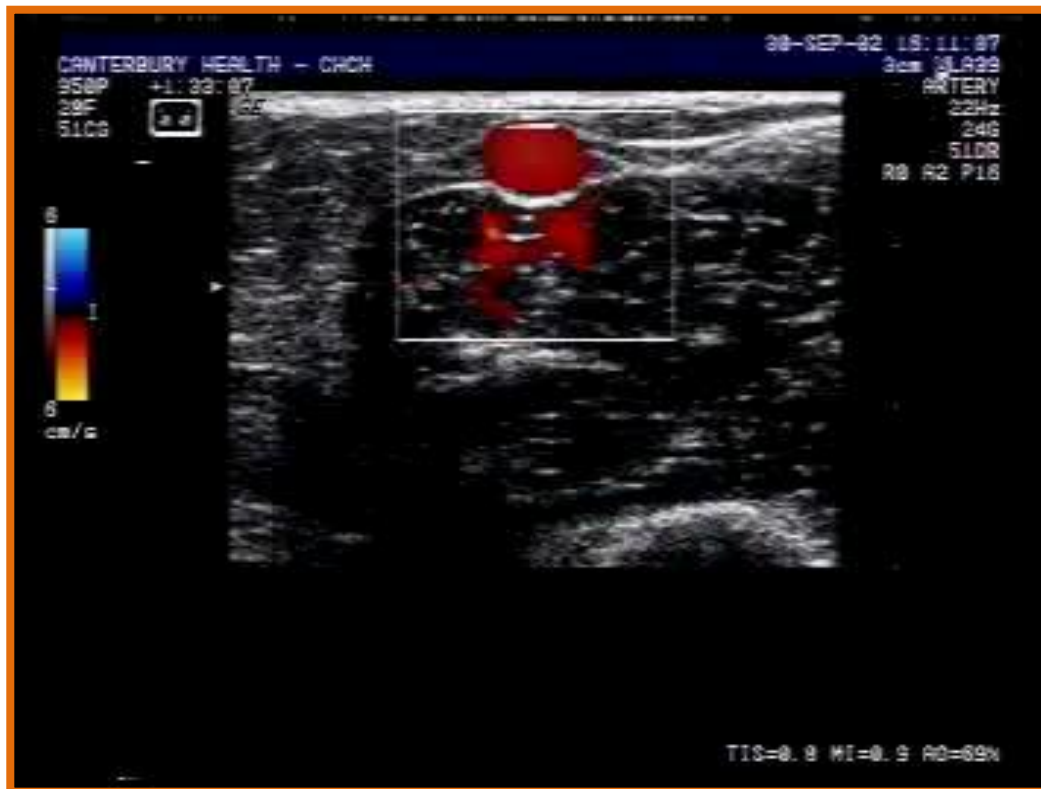

Figure: 11

Source: Original

Contrast Media

Contrast Media is an iodine based contrast used to outline vessels in interventional and diagnostic Radiology. It has mild vesicant properties and can therefore cause tissue necrosis if it extravasates into the tissues. Contradictions to its use are known allergy to contrast and inadequate renal function as per the Christchurch Radiology Services protocols. Contrast media is used to outline the venous anatomy while advancing the catheter if difficulty is experienced.

Contrast allows a detailed view of the vein's pathway and any obstructions or abnormalities so that a decision can be made regarding the accessed vein's suitability for PICC placement. If there is an adequate pathway through the vein to the SVC a roadmap can be taken and a glide wire used to place the PICC successfully.

Before a PICC nurse inserter can use contrast media during an insertion they must first confirm the administration with a Radiologist, explain the situation to the patient and obtain verbal consent. The use of contrast media in patients with pre existing renal dysfunction can lead to significant contrast induced nephropathy.

Where the patient's serum creatinine level is within normal range (<1.5mg/dl) IV contrast media is not contraindicated. Serum creatinine should be monitored before administration, and metformin should be stopped at the time of the administration of CM, and should not be recommenced for 48 hours following (Thomsen, 2006). Where a maximum of 10mL contrast media is administered there is zero risk associated with its use.

If the venous anatomy will not allow for the advancement of the PICC then a decision, in consultation with the Radiologist, will be made to:

1. Change arms
2. Abandon the procedure and discuss alternative venous access with the team. i.e CICC.

ACTION:

- Contrast media will only be given when medical assistance is immediately available, in case of adverse reaction.
- IV contrast will be administered using equipment appropriate for particular examination and area of the department it is being given in.
(Ref. Controlled Document CT Procedures & Protocols Contrast Medium 2012, pages 7-9)



RADIATION PROTECTION:

PICC's are inserted in the radiology room with an Image Intensifier, so that fluoroscopy guidance can be used to follow the advancement of the catheter to confirm the final position of the catheter tip.

Organizational policies and procedures must account for radiation protection and authorised personnel who will operate the fluoroscopy equipment.

It is not within the scope of practice for a Registered Nurse at CDHB to operate fluoroscopy or radiographic equipment, therefore a registered Medical Radiation Technologist (MRT) must be present for all imaging of the procedure.

The PICC nurse inserter must have knowledge of hospital and department policies and procedures regarding radiation protection and safety. Therefore it is mandatory to be familiar with the following documents:

- Radiology Department Safety Protocol Manual.
- NRL C5 code 1994, Code of Safe Practice for the use of X-Rays in Medical Diagnosis
- Working with X-rays in IR

Documentation

Clinical effectiveness is about doing the 'right thing in the right way and at the right time for the patient (Royal College of Nursing, 2006).

The importance of central line assessment and documentation of findings is often overlooked and can lead to complications which can be avoidable. Effective documentation is an integral part of good patient care (INS, 2010). Documentation provides a pathway to continuity of care. Each point of care reveals the patient's clinical picture; therefore documentation should be accurate and include the following:

1. Completed requisition for PICC
2. Accurate documentation of procedure in clinical notes
3. Complete the CVAD Insertion Form and place photocopy in Interventional Radiology(IR) PICC folder
4. IR Register and audit book entry
5. X-ray to be placed on Picture Archiving Communication System (PACS)
6. Complete all electronic entries - Concerto
7. Ensure patient has all appropriate documentation on discharge from Radiology.

INSERTION COMPLICATIONS and MANAGEMENT

PICC insertion complications can occur at any time and be related to many disease processes. Patient-related complications include anatomical abnormalities, heart arrhythmias, behavioral issues such as those encountered when working with the elderly patient with dementia.

Mechanical issues such as machine malfunctions, inability to access vein, inability to thread either the guide wire or catheter, malpositioning into the internal jugular vein, atrium or another vein in the upper thorax region may occur.

Dealing with complications during insertion of a PICC demands knowledge and skill. Therefore a robust PICC nurse insertion programme is essential.

PICC MALPOSITION

PICCs can often malposition into the following veins during insertion:

- Jugular vein
- Brachiocephalic vein
- Azygos vein

Causes of PICC malposition:

- This can be due to blood flow, patient diagnosis
- Vascular irregularities or the patient's position during insertion
- Changes of pressure inside the chest i.e. from vomiting, coughing, constipation, mechanical ventilation
- Ineffective PICC securement methods

Management of PICC Malposition: This involves the following;

- The use of a glide wire effectively repositions the PICC
- The use of a contrast media study of the veins to map their path can be carried out
- Having the patient turn their head towards insertion side can help prevent the catheter entering other veins e.g. jugular
- Asking patient to hold their breath in full inspiration to increase intra thoracic pressure can sometimes facilitate the insertion
- If the PICC is suspected to have travelled into the azygos a lateral projection is required to ascertain this
- Effective PICC securement method

VEIN PUNCTURE

Guide wires can puncture the vasculature during insertion and when advancing the guide wire.

- Arterial puncture can occur when the artery lies close to the vein. This can be avoided by using ultrasound. When an inadvertent arterial puncture is suspected immediate intervention is necessary. Notify the Radiologist who will initiate a contrast study to confirm which vessel has been punctured. If an artery has been punctured the procedure must be stopped and the access needle and sheath removed. Apply pressure to the insertion sites for 10 minutes and document the incident in the clinical notes.

ACTION: IMMEDIATE INTERVENTION IS NECESSARY FOR THIS COMPLICATION.

CARDIAC TAMPONADE

Cardiac tamponade, in relation to central venous access devices, is where the intra pericardial segment of the SVC, right atrium or ventricle wall is perforated due to erosion by the CVAD tip. This perforation allows excess fluid to collect between the pericardium and the heart. The fluid causes compression of the heart and prevents the heart from pumping normally (Forauer, 2007).

Signs and Symptoms of cardiac tamponade:

- Unexplained hypotension
- Arrhythmia
- Chest tightness
- Shortness of breath



THIS IS A MEDICAL EMERGENCY

Management of cardiac tamponade:

- An emergency echocardiogram will be required to diagnose cardiac tamponade
- Signs and symptoms should prompt immediate treatment to relieve cardiac compression
- Position the patient in left lateral trendelenburg
- Administer oxygen
- Call for assistance

Prevention of cardiac tamponade requires that:

- Catheters are made of more flexible material
- The guidewire must be removed completely before trimming the catheter
- The tip of the CVAD to be placed above the pericardium reflection to avoid cardiac perforation
- If fluoroscopy not used heart monitoring can be achieved by ECG
- Accurate assessment of the patient post insertion to ensure appropriate action is taken if tamponade indicated
- Accurate documentation is undertaken.

NERVE INJURY

Nerve injury and irritation can be avoided when the patient is alert to signs and symptoms and is able to report to the PICC inserter during placement of the PICC.

Signs and symptoms of nerve injury:

- Tingling
- Numbness
- Weakness of hand or arm (rare event)

Management of nerve injury:

- If the nerve is stimulated with the needle and pain occurs, needle should be removed and the access site changed
- Explain to patient that the tingling and numbness that occurs will subside
- If any weakness occurs remove needle or catheter immediately

ANATOMICAL ABNORMALITIES

When there are anatomical abnormalities or vein stenosis a PICC can retract on itself or enter a collateral vessel which is sometimes difficult to correct.

Management of anatomical abnormalities:

- The use of ultrasound and fluoroscopy during PICC placement has simplified the process, decreasing the number of x-rays required after the PICC has been inserted. Consider alternative insertion sites and catheters i.e. CICC / TFC

DIABETES

Inserting a guide wire through the tunica intima of a patient with diabetes is often difficult. This is due to the prolonged and chronic irritation that high blood sugars can have on the endothelial cells that line the tunica intima. This causes chronic inflammation resulting in atherosclerosis (INS, 2010; Baktiroglu, Yanar, Ozata, Oner, Ercan 2016)).

Management of PICC insertion and the patient with diabetes:

- Thorough patient assessment prior to the PICC insertion
- Handle the introducer and guide wire gently when accessing the vein
- Discuss any concerns around the blood glucose results with the Medical staff
- Diabetes is a risk factor for infection

SEVERE OEDEMA OF UPPER ARM

Patients that have severe oedema of the arm may present on the ultra sound of the upper arm as 'cloudy picture' (INS, 2010).

Causes of severe oedema of the upper arm:

- Disturbances of blood and lymph flow
- Lymphoedema
- Venous insufficiency e.g. cardiac and peripheral vascular disease
- Obstructed blood flow through the arm
- Nephrotic syndrome
- Infection due to viruses, bacteria, protozoa and fungi
- Fluid overload, fluid retention

Management of PICC insertion of an oedematous arm:

- The use of ultrasound provides a reliable means of identifying and guiding the needle to access the vein.
- When patients are referred to IR for a PICC insertion presenting with any of the above causative factors, PICC insertion will be carried out based on the need for urgent venous access to facilitate treatment. Consider a CICC.

LYMPH VESSEL PUNCTURE

Cause of lymph fluid drainage from the insertion site:

- A lymph structure is penetrated during placement. It will not necessarily be recognised immediately because of the swift action of a small bore-needle into the vein where blood return is the dominant flow.
- A lymph structure has been inadvertently punctured during insertion. It will lead to the formation of a channel between the lymph structure and the PICC exit site creating a passage for lymph fluid to drain from the vessel towards the exit site.


Symptoms of a punctured lymph structure:

- Serous fluid leaking from the insertion site of the PICC
- The fluid may be slightly blood- stained or straw coloured similar to plasma
- There are no signs of infection, redness, swelling or pain
- The exudate may be minimal if a smaller vessel has been punctured or more substantial if the supratrochlear gland is punctured

Management of a punctured lymph vessel:

- There are no clear guidelines available however management will be dependent of the amount of lymph drainage from the PICC insertion site.
- Excessive drainage may necessitate PICC removal especially where there is a potential for PICC migration
- If the lymph drainage is not excessive then it is suggested a 'watch and wait' approach is an appropriate strategy with monitoring of the drainage
- If symptoms last beyond 2 weeks or there is an increase of drainage the PICC should be removed.(Hughes 2013)

ACTION POINT: A consequence of excessive lymph drainage around the exit is erythaema, and excoriation of the skin due to the corrosive effects of the fluid pooling under the dressing. Consider using a hydrocolloid dressing such a Mepitel film to shield the skin from the fluid.

 **Key points:**

- PICC placement in the upper arm seems to have led to an increase in lymph vessel puncture
- Lymphatic puncture is more common with ultrasound due to increased subcutaneous and muscle tissue between the placement site and vein
- Lymph vessels lie in a network in the arm to allow transportation and drainage of lymph fluid
- Amount of fluid discharge from the exit site determines the management of the drainage

SCLEROSED VEINS

When placing a PICC in a patient with sclerosed veins, there may be difficulty in advancing the guide wire.

Management of complications related to sclerosed veins:

- Avoiding any veins diagnosed with suspected sclerosis as seen on ultrasound
- Handling the guide wire gently
- Do not force the guide wire in or out of the needle or vein
- Repositioning the dilator/introducer and re attempting to thread guide wire

VENOSPASM

Venospasm can occur if the patient is anxious or tense or if the PICC is forcefully inserted or passed quickly along the vein. Venospasm makes it difficult to pass the catheter through the vein and will cause damage to the tunica intima. Bleeding and mechanical phlebitis can result.

Management of venospasm:

- Avoid the problem by pausing and waiting before reattempting insertion
- Insert the PICC slowly

- Place heat packs underneath the arm and axillary region, under the sterile drapes, if venospasm is suspected. This action will aid vasodilatation and relaxation of the tunica media

AIR EMBOLISM

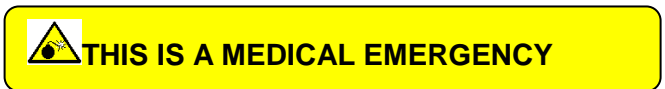Air embolism is caused by the entry of air into the vascular system creating an intracardiac airlock at the pulmonic valve which prevents the ejection of blood from the right side of the heart.

Causes of air embolism include:

- Catheter fracture
- Inadequate priming of the PICC/Midline prior to insertion
- Deep inspiration during CVAD removal or access device removal (Mirski, et al., 2007).

Signs and Symptoms of air embolism:

- Hypoxia and gasp reflex
- Hypotension
- Pallor
- Palpitations and arrhythmias
- Chest and shoulder pain
- Loss of consciousness
- Distinctive 'mill wheel' murmur (churning sound) (Peter & Saxman, 2003) is heard over the precordium caused by right atrial and right ventricular outflow obstruction.



Management of air embolism:

- Position the patient in left lateral Trendelenburg
- Administer oxygen
- Call for assistance. Hyperbaric treatment may be necessary

CATHETER EMBOLUS

1. Catheter embolism is a rare complication associated with catheters. If the tip of the catheter is sheared off, it may potentially embolise and travel to the lungs. This sequence of events occurs when the guide wire is withdrawn from the catheter and then reinserted or it punctures the wall of the catheter shearing off (Surov, et.al. 2006).
2. 'Pinch off Syndrome' is a significant complication involving CVADs and is often unrecognized. It occurs when a CVAD is inserted or passes through the subclavian vein and is compressed by the clavicle and first rib (refer figure 12).

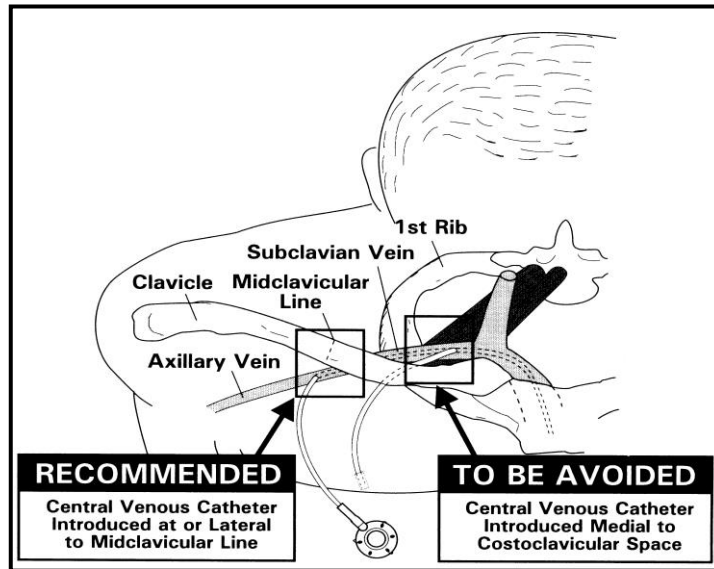


Figure: 12

Source: unknown

Catheter compression causes intermittent or permanent catheter obstruction and can result in the catheter tearing, transection and catheter embolus. Emboli travel most often to the right side of the heart or pulmonary artery (Masoorli, 2002; Mirza, et al., 2004). Catheter embolism may require fluoroscopic catheterization and retrieval of the catheter emboli.

Summary

Technological advantages in PICC insertion and the application of evidence-based practice for the insertion of PICCs have greatly improved outcomes for the patient.

Complications of PICC insertion are greatly reduced when robust education programmes are introduced.

Risk management and quality improvement should be used as a tool to recognize areas for improvement. Records must be kept regarding incidence of insertion complications, interventions and outcomes. Outcomes should be established that are based on evidence-based interventions.

The nurse placing a PICC must be knowledgeable about the risks involved with PICC insertion and must be able to implement measures to prevent their occurrence.

REFERENCES

Amerasekers, S.S.H., Jones, C.M., Patel, R., & Cleaseby, M.J. (2009). Imaging of the complications of Peripherally inserted central catheters. *Clinical Radiology*, 64,832-840

Baktiroglu,S., et al.(2016). Arterial disease and vascular access in diabetic patients. *Journal of Vascular Access*; 17(suppl 1):569-571

Burns D (2005). Clinical investigation: retrospective analysis, the Vanderbilt PICC service: Programme, procedural and patient outcomes successes, *JAVA* 10(4):1-10.

Centres for Disease Control.(2015). Guidelines for the prevention of intravascular catheter related infections. *Morbidity & Mortality Weekly Report*, 51(RR10):1-32.

Clemence,B.J., Maneval,E.M. 2014 Risk factors associated with catheter –related upper arm extremity deep vein thrombosis in patients with Peripherally Inserted Central Venous catheters. Part 1. *Infusion Nurses Society 2014. Vol 37.No 3*

Davis, K.A. (2008). Assessing procedural and clinical data plus electrocardiographic guidance greatly reduce the need for routine chest radiography after central line placement. *Journal of Trauma* 64(2):542.

Forauer, A.R. (2007).Pericardial tamponade in patients with central venous catheters. *Journal of Infusion Nursing*, 30(3):161-167.

Hadaway, L. (2005).Reopen the pipeline. *Nursing* 2005, 35(8).

Hadaway, L.C. (2010) Anatomy and physiology related to infusion therapy, in *Infusion Nursing: An Evidence-Based Approach*, 3rd edn (eds M. Alexander, A. Corrigan, L. Gorski et al.). Saunders Elsevier, St Louis, MO, pp.139–177.

Hadaway, L. Retrieved 3 March, 2012 from <http://www.hadawayassociates.com/expInfusion.htm>

Hallam,C., et al. (2016) Development of the UK Vessel health and Preservation 9VHP) framework: a multi-organisational collaborative. *.Journal of Infection Prevention*

Murray,M., Precious,E.,Alikhan,R. Catheter –related thrombosis in cancer patients(2013) *British Journal o Haematology* 162,748-757

Hughes, M.E. (2013). Peripherally inserted central catheters – ‘a serous’ complication. *British Journal of Nursing*, 2013(IV Supplement), Vol 22.No 10

Infusion Nurses Society. (2010). *Infusion nursing: Evidence –based approach*. 3rd Edition. Saunders: Massachusetts, USA.

Health Quality & Safety Commission New Zealand. Retrieved 3 March 2012 from <http://www.hqsc.govt.nz>

Infusion Nurses Society. (2016). *Infusion Therapy Standards of Practice*. Vol 39, No.1S. ISSN 1533 1458

Institute for Healthcare Improvement. (2008). *5 million lives campaign. Getting started kit: Prevent central line infections how to guide*, Cambridge, MA. Retrieved 3 march 2012 from <http://www.ihl.org/IHI/Programs/Campaign/CentralLineInfection.htm>

Johnson & Johnson Medical Continuing Education. (1998). Sydney: Australia.

Maki, D.G., Kluger, D.M., & Crnich, C.J. (2006). The risk of blood stream infection in adults with different intravascular devices: A systematic review of 200 published prospective studies. *Mayo Clinical Protocol*, 81:1159-1171.

- Masoorli, S. (2002). Getting a line on CVAD: Central vascular access devices. *Nursing*. 32(4)36-45.
- Medical Illustrations Department (2009) Christchurch Hospital, Christchurch: NZ
- Moureau, N.L. (2003). Using ultra sound to guide PICC insertion. *Nursing*, 33 (12), 20.
- Mirski, M.A., Lele, A.V., & Fitzsimmons, L. et al: (2007) Diagnosis and treatment of vascular air embolism, *Anesthesiology* 106 (1):164-177
- Mirza, B., Vanek, V.W., & Kupensky, D.T. (2004). Pinch - off syndrome: Case report and collective review of the literature. *American Surgery*, 70(7):635-644.
- Murray, M., Precious, E., Alikhan, R. Catheter –related thrombosis in cancer patients (2013) *British Journal of Haematology* 162, 748-757
- Nursing Council of New Zealand. (2000). Competencies for Registered Nurses: 32.
- Peter, D.A., & Saxman, C. (2003). Preventing air embolism when removing CVC's: An evidence-based approach to changing practice. *Medsurg Nurs*, 12(4):223-228.
- Royal College of Nursing. (2010). Standards of Infusion Therapy. London: RCN. England.
- Shiffer, C., A. et al. (2013) Central Venous Catheter care for Patients with cancer: *American Society of Clinical Oncology Clinical Practice Guidelines*.
- Simcock, L. (2008). No Going Back: Advantages of Ultrasound-Guided Upper Arm PICC Placement. *JAVA*, Vol 13 No 4
- Surov, A., Jordan, K., & Buerke, M., et. al: (2006) Atypical pulmonary symbolism of port catheter fragments in oncology patients, *Support Care Cancer* 14:479-483
- Terry, J. (Ed). (1995). *Intravenous Therapy: Clinical principles and practice*. W B Saunders Co: Massachusetts, USA.
- Thomsen, H.S. (2006). European society of urogenital radiology (ESUR). Guidelines on the safe use of iodinated contrast media. *European Journal of Radiology*, 60, 307-313. Elsevier.



FOR FURTHER READING:

- Burns D: (2005) Clinical investigation: retrospective analysis, the Vanderbilt PICC service: programme, procedural and patient outcomes successes, *JAVA* 10(4):1-10.
- Blackburn, P., L., Macklin, J. (2015) Central Venous Catheter Securement: Using the HealthCare and Technology Synergy Model to take a closer look. *JAVA*, Vol 20: No 1
- Informed Patient Consent Manual Volume 11 online document [Informed Consent Manual hyperlink](#)
- Justice, C. (2003). Diabetes medication update. *Journal of Radiology Nursing*, 23, 19, 20.
- Kokotis, K., (November). Preventing chemical phlebitis. *Nursing* 98.
- Note on Injectable Drugs (NOID). Available in hospital departments [Notes of injectable drugs hyperlink](#)
- Penel, J., Neu, J.C., Clisant, S., Hoppe, S., Devos, P., & Yazdanpanah, Y. (2007). Risk factors for early catheter related infections in cancer patients. *Cancer*, 110:1586-1592.
- Wilbeck, J., Murphy, M., Heath, J., & Thompson-Smith, C. (2011). Evaluation methods for the assessment of acute care nurse practitioner inserted central lines: Evidence-based strategies for practice, *JAVA*, Vol 16 No 4.

ASSOCIATED DOCUMENTS:

Adult Central Venous Access Device Insertion Record Form C240189

CDHB CVAD Resource Book (2016)

Radiology Nurses Sterile set-up Manual available in Radiology department

Radiology Nurses Protocol Manual available in Radiology department

Radiology Department Controlled Document CT Procedures & Protocols 2012

Volume 12 Fluid and Medication Manual 2012 on line document [Vol 12 hyperlink](#)

Volume 10 Infection Prevention and Control Manual 2012 [Vol 10 hyperlink](#)

Volume 11 Policy Informed Consent Manual [Vol 11 hyperlink](#)

SECTION 2

Paediatric Peripherally Inserted Central Catheter Insertion



PAEDIATRIC PICC INSERTION

INTRODUCTION

This section on PICC competencies covers the insertion of Paediatric PICC's. Paediatric PICC insertion is an additional competency and is not expected of all PICC nurse inserters in Radiology. Following completion of the Adult PICC Self learning pack and the subsequent development of these skills the Nurse can progress to become a Paediatric PICC line inserter. Paediatric PICC nurse inserters will be selected based on prior clinical experience, and require further education along with completion of ten successful insertions under supervision in the clinical setting. Paediatric PICC line insertions are achieved in a monitored, controlled environment with an Interventional Radiologist on site (Gamulka, Mendoza & Connolly, 2005).

The insertion of Paediatric PICC's requires knowledge of the differences between the adult and paediatric anatomy and expert technical skills to ensure a consented, safe, aseptic and correctly placed PICC catheter in a child. In children expert venepuncture is considered to be a significant predictor of a successful PICC line insertion (Pettit & Wyckoff, 2007).

Paediatric PICC's are considered for children from the age of 0 to 16 years of age. Paediatric PICC insertions have the potential to be more difficult than adults, even though the veins are similar in location; the child's body and size of their veins are smaller (Frey, 2001).

The insertion procedure involves a number of stages that are different from that of the adult insertion. PICC insertion may be performed under a general anaesthetic or oral sedation. The immobility of the patient contributes greatly to the success of the procedure. Therefore it is important to ensure the correct type of anaesthetic or sedation is chosen.

ACTION:

- For patients receiving oral sedation refer to radiology Nurses Manual policy and procedures for Paediatric Sedation.
- For patients receiving GA refer to CDHB policy and procedures for Paediatric GA.

PERIPHERALLY INSERTED CENTRAL CATHETER (PICC) INSERTION CERTIFICATION FOR PAEDIATRICS

The pre-requisites, for Registered Nurses who wish to be instructed in Paediatric PICC insertion, are:

1. Hold a current PICC Nurse inserter competency IVTC18 P
2. Demonstrate expert skills in the insertion of Adult PICC's
3. Be recommended and endorsed by the Radiology CNM

Components of PICC Insertion Certification:

4. Peripheral IV Cannulation certification
5. CVAD certification (non Implanted Devices)
6. PICC Nurse inserter competency IVTC 18 P
7. Paediatric PICC Nurse Insertion certification which includes Practical Skills Assessment

Instructions for PICC Insertion Certification:

7. Complete the Paediatric PICC Insertion Package
8. Complete the Theory Test (100% pass is required)
9. Insert ten PICCs under the supervision and instruction of a certified Paediatric PICC Nurse Inserter assessor
10. Perform an additional three Paediatric PICC insertions under observation of the PICC nurse insertion assessor to complete the Practical Skills Assessment component
11. On completion of the Paediatric PICC Nurse Inserters practical assessment all relevant documentation is sent to the Professional Development Unit (PDU) by the Radiology CNM. The nurse's name is entered onto the CDHB PICC Nurses Inserters Competency training data base and four hours for professional development is given.
12. Re-certification is required every three years. This process will be managed by the Charge Nurse Manager Radiology. Four hours for Professional development will be credited to the RN and entered onto their individual training data base

LEARNING OBJECTIVES

This comprehensive Self directed Learning Package is designed to assist the RN to develop critical thinking skills and demonstrate knowledge in the assessment and insertion of Paediatric PICCs and Peripheral Midline Catheters.

At the completion of the Paediatric PICC Nurse Insertion competency the RN should be able to:

- Describe patient assessment and consent process
- Select the appropriate PICC or Peripheral Midline catheter for insertion
- Describe the anatomy and physiology of blood flow in relation to the insertion of a PICC/Midline catheter
- Describe preferred skin disinfectant in relation to Paediatric PICC/Midline insertion
- Demonstrate knowledge in the use of the ultrasound probe and fluoroscopy
- Demonstrate correct technique for accessing the selected vein and inserting the catheter
- Demonstrate correct techniques in catheter trimming
- Demonstrate knowledge of correct catheter tip position on X-ray and describe abduction and adduction
- Identify complications and describe prevention and intervention of each
- Demonstrate correct dressing and securement
- Describe accurate documentation
- Participate in quality assurance initiatives and audit of PICC insertions

Throughout this package are ‘ALERTS’ and ‘FURTHER READING’



This symbol indicates ‘important alerts’



This symbol indicates ‘for further reading’

ACTION

This symbol indicates ‘important actions’

PAEDIATRIC PICC INSERTION TIP SITES (in blue)

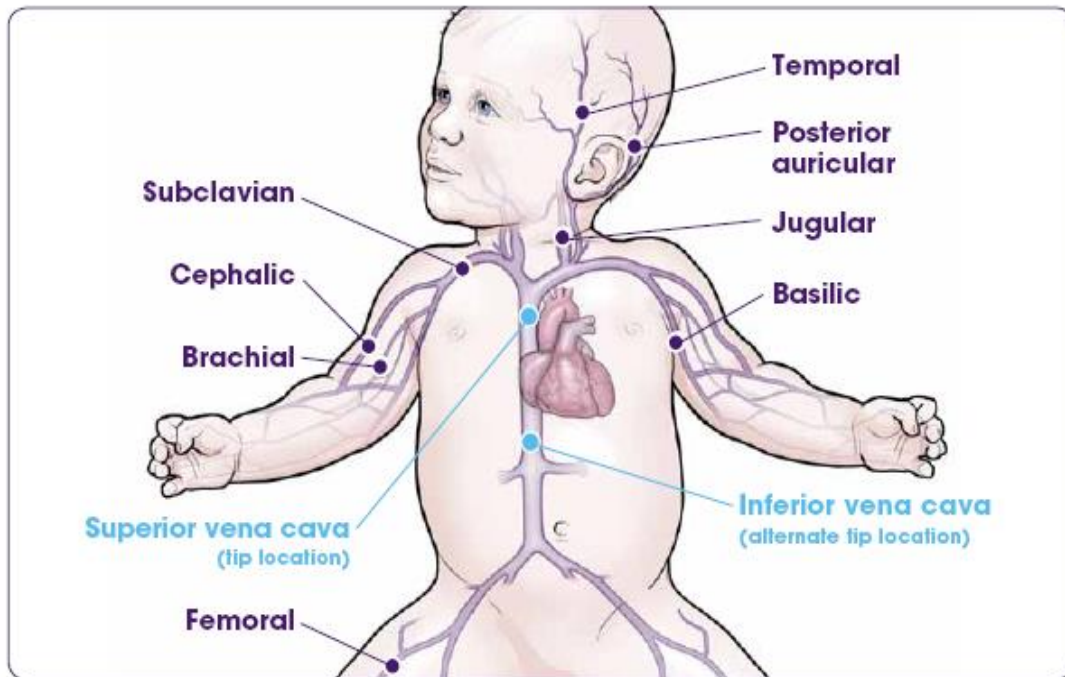


Figure: 13. Source: Unknown

Consent

The procedure, its risks, benefits and alternative treatments will be discussed with the child's parents and an agreement to consent is obtained (Pettit & Wyckoff, 2007). At Christchurch Hospital this is done by the Paediatric Team, before the child is transferred to Radiology. The nurse performing the procedure will meet with the parents and review the insertion procedure, and ensure the consent has been obtained. Assessment of the child is important prior to the procedure as not all children are suitable for PICC insertions (Pettit & Wyckoff, 2007).

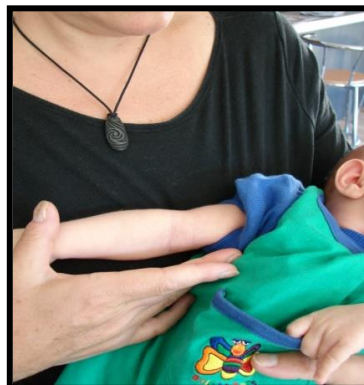

Figure: 14. Source: unknown

Selection

It is important to select the correct catheter for insertion (Donaldson et al.1995). When short to medium vascular access is required a PICC is an ideal alternative to other surgically inserted ports or catheters in the paediatric population.(Gamulka, Mendoza and Connolly 2005) state that midline catheters are not suitable for the paediatric population as it limits the types of therapies that can be administered without complications. It is important to select the correct catheter to insert (Donaldson et al., 1995). When choosing the catheter, additional factors to consider are; age, size of the child, developmental growth, level of activity and sense of body image (Frey 2001).

Catheter Preparation

Before the catheter is inserted a measurement is taken from the anti cubical fossa to the lower third of the Superior Vena Cava (SVC). Excess catheter is trimmed following manufacturer's instructions.

Trimming the catheter to the correct size prior to insertion is important. Always ensure the preloaded **wire is removed completely before trimming the catheter**. The catheter is cut with the guillotine provided. The wire is then carefully replaced to ensure the wire sits just inside the catheter tip. This is to ensure the inner wire is not severed and fragments dislodged. After trimming flush the catheter with 2-3mls of Sodium Chloride 0.9% to remove air and any internal fragments within the lumen.

If a PICC set is provided with a measuring wire, follow the manufacturer's instructions.

Potential risks when trimming the catheter:

1. Trimming the catheter too short
2. Fragments remaining on the trimmed catheter end
3. Depending on catheter and trimming method, creating an irregular catheter tip (Pettit & Wyckoff, 2007).



Tip should be squarely cut to resemble the original tip.


Always ensure the preloaded wire is removed completely before trimming the catheter.

Skin Preparation

Paediatric PICC's pose the same risk of infection as adult catheters. The use of chlorhexidine sponges and solutions, combined with MSB draping, disinfection of ports before use and insertions by specialised teams, all reduce the risk of infection in PICC insertions (Levy et al., 2005).

As with adults the child's arm is cleaned with 2% chlorhexidine and 70% alcohol from axilla to hand then covered using a sterile drape to provide MSB precautions (Pettit & Wyckoff, 2007).

In infants with very low birth weight caution needs to be taken when using alcohol and aqueous solutions. It has been known to cause skin breakdown and erythaema. If povidine iodine is used it must be removed immediately following the procedure to prevent potential absorption, skin damage and risk of hypothyroidism. Consideration should also be given to the type of sterile gloves used as Latex gloves can lead to a latex reaction in infants (Nann, 2003).

 Neonates require an antimicrobial solution that does not contain alcohol

Anatomical Identification on Ultra Sound

When selecting a vein suitable for catheter insertion, the vein needs to be large enough to accommodate the introducer and the catheter. The axillary vein is large and the benefits are easy cannulation and advancement of the catheter, however it poses the risk of arterial puncture due to its close proximity to the axillary artery (Pettit & Wyckoff, 2007).

The basilic vein is the vein of choice. It is considered that there is less endothelial cell damage due to greater haemodilution between the catheter and vessel wall (Donaldson et al., 1995; Nichols & Doellman, 2007; Pettit & Wyckoff, 2007). The vein is accessed between the elbow and the axilla. Before tightening the tourniquet, the vessels are viewed with the ultra sound probe, to differentiate the vein from the artery. In infants if the tourniquet is applied too tightly arterial blood pressure may be exceeded and the artery can be difficult to identify. Coloured flow Doppler may also be used to distinguish between the two vessels (Donaldson et al.1995).

Insertion

Due to the elasticity of the skin it is necessary to make a small nick in the skin prior to the insertion of the introducer needle. The puncture site needs to be gradually dilated before the catheter is advanced along the vein (Dubois et al., 1997).

Two techniques have been adapted to access the vein. The use of a 23 gauge Angiocath allows the inserter to access smaller veins in younger children, where as the introducer needle in the PICC set is used for the older child.

Ultrasound guidance is recognised as best practice. Venous spasm can occur therefore careful advancement of the guide wire ensures the potential puncturing of the vein is minimised and/or recognised early. It is important to not force the guide wire or catheter through the vein if spasm occurs. Damage to the tunica intima disrupts endothelial cells and increases complication rates such as thrombosis (Racadio et al., 2001). If an arterial puncture is suspected stop the procedure immediately and review the situation.

Paediatric PICC placement under fluoroscopy guidance in Interventional Radiology offers several advantages such as immediate tip manipulation to the correct central position. It is important to commence fluoroscopy guidance after advancing the catheter 5 to 10cms in all paediatric patients. Preventing delays in treatment and ensuring a high insertion success rate (Fricke et al., 2005; Pettit & Wyckoff, 2007). Catheter migration is a common problem reported in PICC's in Paediatric and neonates (Nadroo et al., 2002).

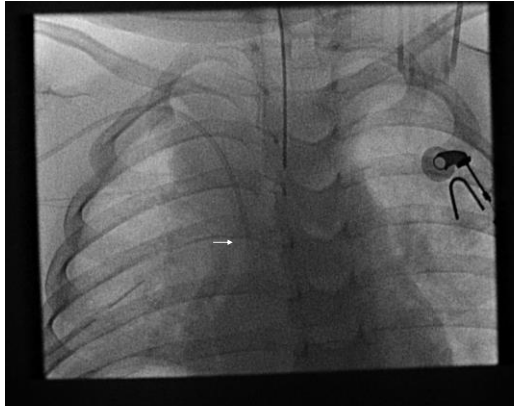
Correct Placement of PICC

Central venous catheter tips should be positioned in the SVC, therefore allowing the tip to lie parallel to, and not impinge on the vein wall. Contact to the tunica intima disrupts endothelial cells and increases complication rates such as thrombosis (Gamulka, Mendoza & Connolly, 2005; Pettit & Wyckoff, 2007; Racadio et al., 2001). This is best obtained through a right arm insertion site. PICC's have the potential to migrate into the right atrium with arm movement.

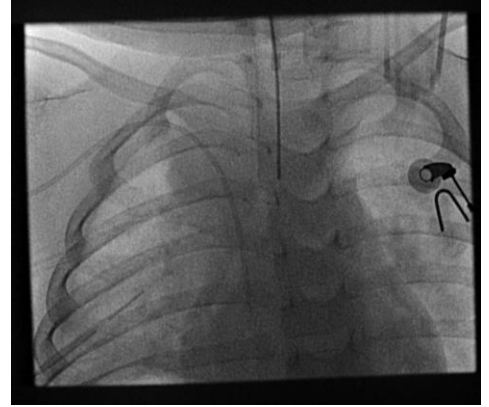
When the arm is adducted catheters inserted in the basilic and axillary veins move towards the heart. On abduction the catheter moves away from the heart, significantly altering the position of the catheter tip. This movement may cause myocardial perforation, and place the patient at risk of pericardial effusion or cardiac tamponade.

Catheter migration is a common problem reported in PICC's in Paediatric and neonates (Nadroo et al., 2002). No force is placed on any catheter or wire that does not travel smoothly along the vessel. If resistance is felt the guide wire can be replaced with an angled glide wire (Dubois, 1997). Continuous fluoroscopy is used at this stage to ensure the wire advances to the correct position and does not enter the heart as it will cause cardiac arrhythmias.

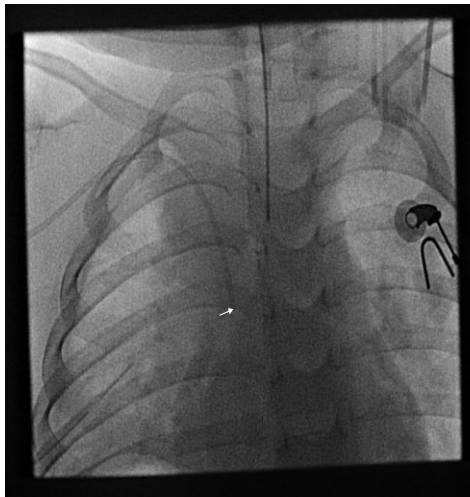
CORRECT PLACEMENT IN SVC



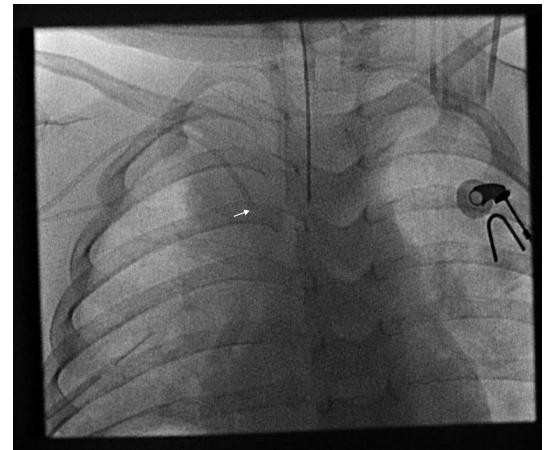
Normal position in SVC



Position on adduction



Normal position in SVC



Position on abduction

Imaging

Following insertion radiographic images of abduction and adduction of the catheter in its final position are taken and documented. This ensures that the PICC's tip is at the optimum position following insert.

Other images related to the procedure will be taken also e.g. images requiring contrast media

Contrast Administration

Contrast media may be required to document cases of vasospasm or vein narrowing due to previous catheter insertions. The policy and procedures to ensuring dose does not exceed more than 2mls/kilo must be followed.

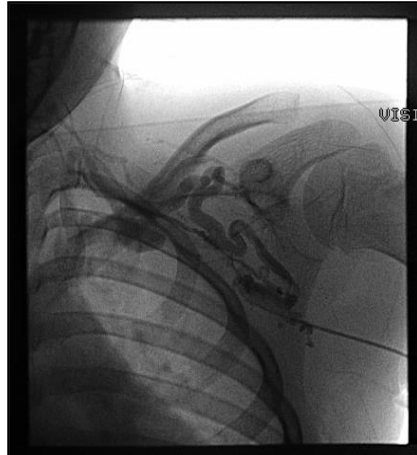


Image showing contrast media. Source: Original

Radiation Dose

The risk of radiation exposure is higher in children than adults. This is due to higher water content and increased cell division. The principles of ALARA (as low as reasonably achievable) should apply when imaging of paediatric patients occur. Selection of the appropriate procedure, using the shortest possible imaging times, ensures that no additional images are required and by having the child lying still all contribute to reducing radiation dose.

Dressing Application

As per paediatric dressing policy (Paediatric PICC/Midline form C270049) a paediatric Biopatch® is placed over the insertion site and the catheter secured with steri-strips and bio-occlusive dressing. It is important to ensure that the entire dressing and bandage are not too tight as to impede blood supply in the arm.

PICC insertion, maintenance and care is documented on the Paediatric PICC Line Insertion Form C270049.

REFERENCES:

- Donaldson, J.S., Morello, F.P., Junewick, J.J., O'CDonovan, J.C., & Lim-Dunham, J. (1995). Peripherally inserted central catheters: US-guided vascular access in paediatric patients. *Radiology*, *197*, 542-544.
- Dubois, J., Garel, L., Tapiero, B., Dube, J., Laframboise, S., & Michele, D. (1997). Peripherally inserted central catheters in infants and children. *Radiology*, *204*, 622-626.
- Frey, A.M. (2001). Intravenous therapy in children. In: Hankins, J., Lonsway, R.A.W., Hedrick, C., & Perdue, M., eds. *Infusion Therapy in Clinical Practice*. 2nd ed. Philadelphia, PA: WB Saunders; 2001:561-591.
- Fricke, B.L., Racadio, J.M., Duckworth, T., Donnelly, L.F., Tamer, R.M., & Johnson, N.D. (2005). Placement of peripherally inserted central catheters without fluoroscopy in children: Initial catheter tip position. *Radiology*, *234*, 887-892.
- Hughes, M.E., (2013). Peripherally inserted central catheters-a 'serous' complication. *British Journal of Nursing*, *2013 (I V Supplement)*, *Vol22, No19*
- Levy, L., Katz, J., Solter, E., Samra, Z., Vidne, B., Brik, E., Ashkenazi, S., & Dagan, O. (2005). Chlorhexidine-impregnated dressing for prevention of colonisation of central venous catheters in infants and children. *The Pediatric Infectious Disease Journal*, *24*(8) 676-679.
- Nadroo, A.M., Glass, R.B., J. Lin., Green, R.S., & Holzman, I.R. (2002). Changes in extremity position cause migration of peripherally inserted central catheters in neonates. *Paediatrics* *110*(1), 131-136.
- Paul, B., & Czajka, C. (2006) Pediatric: Nurse-placed peripherally inserted central catheters in an interventional radiology setting improves outcomes. *Journal of Radiology Nursing*, September *25*(3), 94.
- Racadio, J.M., Doellman, D.A., Johnson, N.D., Bean, J.A., & Jacob, B.R. (2001). Paediatric Peripherally inserted central catheters: Complications rates to catheter tip location. *Paediatrics* *107*(2). Retrieved November 18, 2007, from www.paediatric.org/crg/content/full/107/2/e28.

Standards for Infusion Therapy (2016)

ASSOCIATED DOCUMENTS

CDHB Policy and Procedure Manual Paediatric undergoing GA

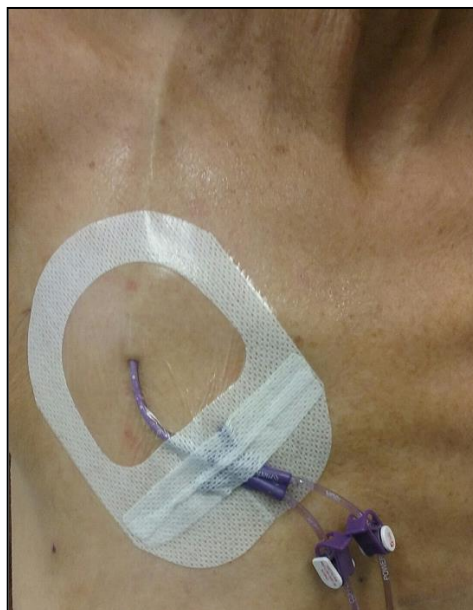CDHB Child Health video on PICC insertion Internet

Volume 12 Fluid and Medication Manual 2012 on line document [Vol 12 hyperlink](#)

SECTION 3

ADVANCED PRACTICE

- Tunnelled Peripherally Inserted Central Catheter (TPICC)
- Chest Inserted Central Catheter (CICC)
- Tunnelled Femoral Catheter (TFC)



Tunnelled Central Venous Catheters

INTRODUCTION

This section covers the procedure of tunnelling central venous catheters (CVC). The procedure of tunneling a CVC requires advanced knowledge and skill and is not expected of all nurses who insert PICCs in Radiology. Both Adult and Paediatric insertion competencies are a pre requisite.

Nurses are required to undergo training and supervision under the guidance of an Interventional Radiologist. Following initial training a collaborative discussion will be initiated involving the key clinical personnel i.e. CNM, Interventional Radiologist and the expert vascular access nurse. The standard required to achieve the competency for advanced practice tunnelling of central venous catheters will be endorsed on agreement of all three clinical personnel.

Central tunnelled catheters have greater stability when compared to non tunnelled catheters. It allows PICC use in situations where tunnelled catheters are explicitly recommended for example in bone marrow transplant patients (British Committee for Standards in Haematology). Tunnelling catheters reduces the risk of vein thrombosis. Where a cuffed catheter is used it provides for a longer dwell time and increases the catheter stability making it less prone to migration. The cuff also prevents bacteria from entering the extra luminal pathway. Tunnelling of PICCs have been extensively used in recent years by several clinical groups around the world e.g. Italy, USA, UK, Spain. Tunnelled jugular small-bore central catheters (CICC) are a vein-preserving alternative to PICCs (Trerotola 1999). Tunnelling is technically easy and safe for both the clinician and the patient. Tunnelling PICCs and CICCs has become the new frontier of the expansion of nurses' competence in central venous access. The 2011 position paper developed by the Association of Vascular Access (AVA) state: "the internal jugular veins may be considered peripheral approach for vascular access, and are thus acceptable for cannulation by appropriately credentialed registered nurses" The document states that "PICC placement in the external jugular vein is not recommended as an option, due to the high risk of complications because of the small size of the vessel and its tortuosity".

Tunnelled PICCs (TPICC), Chest Inserted Central Catheters (CICC) Tunnelled Femoral CVC (TFC) fall into the category of 'Off-Label' (Pittiruti 2014). The 'Off-Label use of PICCs' is an appropriate definition of terminology for this group of catheters (Pittiruti 2014). There are three different aspect:

- Atypical or 'off label' techniques of insertion
- Atypical or 'off label' sites of insertion
- Atypical or 'off label' indications for use

The technique of placement follows the same procedure as for other central venous catheter insertions. The Zone Insertion Method described by Dawson is used to identify the ideal area for the exit site (refer to figure 1)

International data demonstrates low complication rates for a hospital-wide service delivered by advanced practice nurses with results suggesting that a centrally based service with specifically trained operators can be beneficial by potentially improving patient safety and promoting organizational efficiency (Alexandrou et al 2014)

CERTIFICATION PROCESS

- ◆ TUNNELLED PERIPHERALLY INSERTED CENTRAL CATHETER (TPICC)
- ◆ CHEST INSERTED CENTRAL CATHETER (CICC)
- ◆ TUNNELLED FEMORAL CATHETERS (TFC)

The inserting of TPICC, TFCs and CICC central venous catheters requires expert knowledge and skill and is described as advanced practice for Radiology Registered Nurses.

Components of Certification:

1. Current Peripheral IV Cannulation certification
2. Current CVAD certification
3. PICC Insertion certification and credentialing
4. Paediatric PICC insertion certification and credentialing

Instructions for Certification:

1. Written assessment of advanced specialist / expert knowledge development and clinical decision-making regarding patient selection. Critical analyse and reflection response to complex and unpredictable clinical scenarios (refer to template page 58).
2. Complete the Practical Skills Assessment component by performing tunnelling procedures under the Interventional Radiologist's guidance.
3. On completion of the clinical endorsement the evidence is sent by the Radiology CNM to the Professional Development Unit (PDU) and the nurse's name is entered onto the CDHB data base as IVTC19AP(Advanced Practice) Eight hours for professional development will be credited.

Certification for Insertion of Tunnelled Central Venous Catheters (*Print off this page and complete*)

APPLICANT NAME:

1. Advanced specialist /expert knowledge development and clinical decision making regarding patient selection.

2. Written Assessment

3. Critically analyses and reflect on an unpredictable an complex clinical scenario

Applicant's comments:

CATHETER SELECTION – SITE SELECTION

Central Venous catheters used for the purpose of tunnelling may come with or without a cuff. They may be power injectable or non-power injectable. The diameter and condition of the selected vein will dictate the size of the catheter to be tunnelled.

The location for the exit site of a central venous catheter is of paramount importance in terms of risk of infection, local thrombosis and migration. Tunnelling is a powerful tool for selecting the most appropriate exit site. Tunnelling protects extra luminal contamination and reduces the risk of catheter related blood stream infection (CRBSI).

Central venous catheters may be tunnelled in the upper arm (TPICC), the upper chest (CICC) or the lower abdominal wall and into the femoral vein.

Having a peripheral tunnelled catheter allows the patient greater comfort, with less risk of catheter dislodgement.

UPPER ARM TUNNELLING:

Tunnelling a PICC into the axillary vein or in infra-clavicular area is usually indicated in adult patients who have specific bilateral contraindications to the cannulation of veins in the upper arm.

The indication for tunnelling is the use of an ideal vein in terms of diameter and ease of approach in Dawson's yellow zone. (Refer figure 1).

The length of tunnel must be long enough to get the exit site inside Dawson's green zone.

USING THE ZONE INSERTION METHOD:

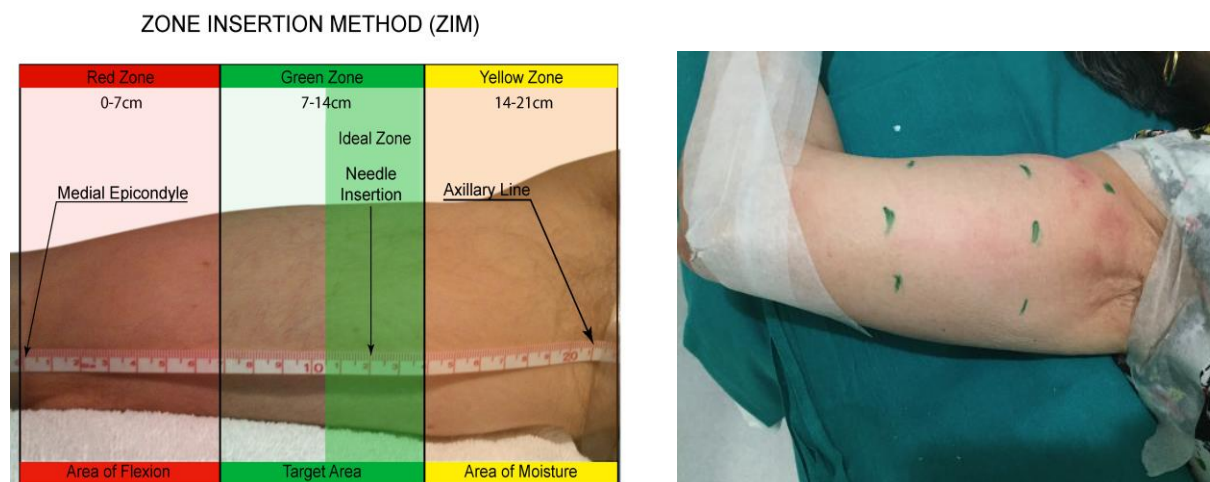


Figure 1 Source: Dawson's Zone Method

CHEST TUNNELLING OF A CATHETER: Where ultrasound and fluoroscopy guidance is used to place tunneled catheters into the internal jugular vein the risks have been low with reported less trauma and subsequent stenosis than may occur with non-guided techniques. (Sasadeusz et al 1999) Placement of a catheter in the internal jugular vein shares the same indications of placement for the axillary vein. The exit site may be in the supraclavicular fossa. (Refer figure 2). This however is less comfortable and less desirable than using the low approach with the exit site in the infra-clavicular area (Pittiruti 2014).

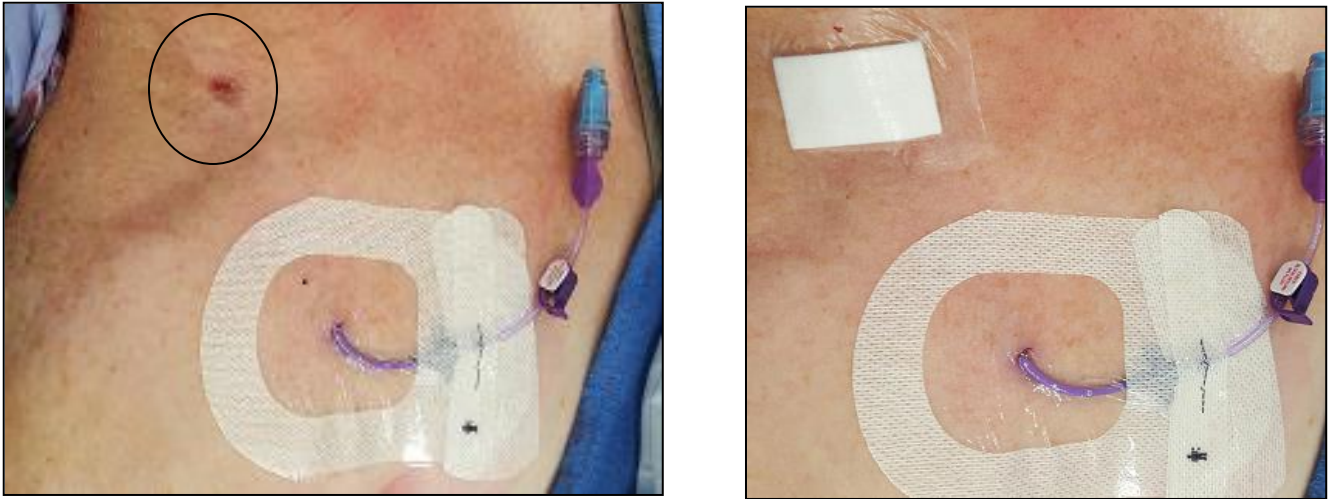
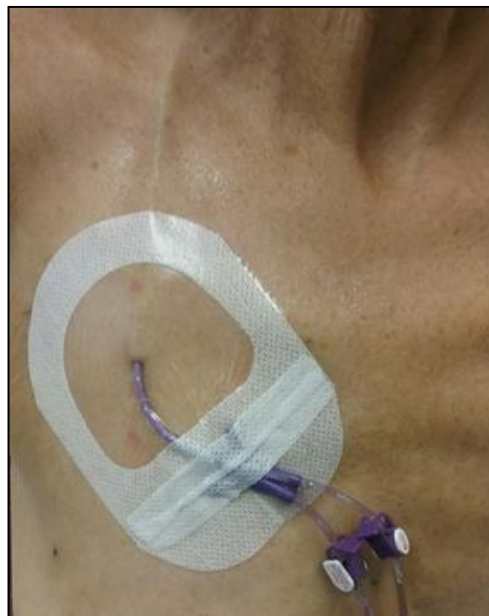

Fig.2 CICC inserted in the internal jugular vein (low approach) and tunneled to the infra-clavicular area. **Source:** Original



TUNNELLED FEMORAL CVC (TFC): Indication for this access is the presence of an obstruction of the superior vena cava or both of the brachiocephalic veins (SVC syndrome) which implies the impossibility of using brachial, basilic, axillary, internal and external jugular, subclavian, cephalic, brachiocephalic to achieve central venous access.

Whilst the inferior vena cava (IVC) is not considered a central location i.e. Lower third of the SVC according to guidelines, there is a consensus that a catheter whose tip is in the middle part of the IVC (above the iliac junction and below the renal veins) can be safely used for any kind of intravenous infusion. (Pittiruti et al 2009).

With regard to the insertion technique tunnelling is mandatory, since the exit site at the groin is associated with very high risk of infection due to extra luminal contamination. The exit site is on the abdominal area in the para umbilical region. (Refer figure 3).

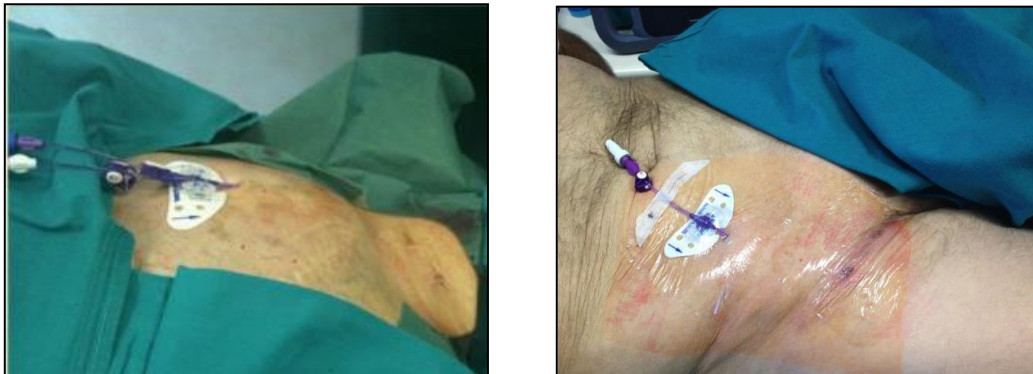

Fig 3. Catheter tunneled into the femoral vein with the exit site on the abdominal wall. **Source:** M. Pittiruti

Internal Jugular Vein (Performed under Radiology guidance)

Placement of a CICC in the internal jugular vein is feasible in both children and adults

The same indications for placement apply as if inserting into the axillary vein (i.e. local bilateral contraindications to brachial or basilic cannulation) are the same but it is associated with an exit site in the supraclavicular fossa which is less comfortable.

The “off-label” use of PICCs is becoming increasingly popular and it represents the new frontier of the expansion of nurses’ competence in central venous access.

1. The technique of CICC placement follows the same procedure as other central accesses
2. Ultrasound study of the central veins is necessary before starting the procedure (so-called RaCeVA = Rapid Central Vein Assessment)
3. Ultrasound-guided puncture and cannulation is performed with visualization of the internal jugular vein in short axis and “in-plane” venepuncture
4. Modified Seldinger technique is employed using the micro-introducer-dilator
5. Verification of the correct location of the tip is by fluoroscopy guidance
6. Sutureless stabilization of the catheter at the exit site is by using surgical glue and dressing securement
7. Tunnelization may be an option, especially in children so that the catheter exit site is below the clavicle(Fig 2 page 59)

Subclavian Vein (Performed under Radiology guidance)

PICC placement in the subclavian vein is feasible, but quite uncommon.

1. Ultrasound guided puncture and cannulation may be performed almost exclusively by a supraclavicular approach, since the subclavian can be clearly visualized by ultrasound only by this route.
2. The procedure might have indications in adult patients with local bilateral contraindication to PICC placement in the arm and whose internal jugular, brachiocephalic, and axillary vein may appear hard to cannulate even with ultrasound guidance.

Brachiocephalic Vein (Performed under Radiology Guidance)

Ultrasound-guided CICC placement into the brachiocephalic vein may be regarded as the first option for ultrasound-guided central venous access in neonates and small infants, as well as in children with contraindication to PICC placement in the arm (M. Pittiruti)

Femoral Vein

PICCs are the ideal venous access device for a non-emergent access to the inferior vena cava. The indication for using this access is the presence of an obstruction of the superior vena cava or of both brachiocephalic veins (called superior vena cava syndrome), which eliminates the use any of the following veins (brachial, basilic, axillary, internal and external jugular, subclavian, cephalic, brachiocephalic) for achieving a central venous access.

The position of the tip inside the inferior vena cava is not considered central location, the 'central' location being the lower third of the SVC or the upper portion of the right atrium, according to most guidelines however, there is wide consensus that a catheter whose tip is in the mid portion of the inferior vena cava (above the iliac junction and below the renal veins) can be safely used for any kind of intravenous infusion.

PICCs are suitable for this type of procedure, since their considerable length (50–60 cm) is very appropriate for the catheter length required when tunnelling into the femoral vein (at least 30 cm of intravascular length + at least 15–20 cm of tunnelization)

If a cuffed PICC is used the cuff should be positioned at no less than 2 cm from the exit site. Tunnelled cuffed catheters increase the expected dwell time where specifically indicated for long term use

1. The tunnelling insertion technique is mandatory, since the exit site at the groin is associated with a very high risk of infection due to extra luminal contamination.
2. The exit site is usually planned in the abdominal area (i.e. in the para umbilical region or in the iliac fossa: upward tunnelization) or sometimes close to the knee (downward tunnelization).
3. The procedure is simple and is not associated with any relevant risk. (Figs.3 page 59)
4. Ultrasound scan both groins, to decide the best femoral vein (the catheter can be inserted either on the right or on the left side, with no differences in terms of expected complication)

5. Ultrasound-guided puncture and cannulation of the femoral vein is performed (visualization in short axis, 'out-of-plane' puncture)
6. Insert the micro-introducer-dilator
7. Trim the catheter to the desired length.
8. Anterograde tunnelization: after administration of the local anaesthetic, the catheter is threaded through the tissues using a tunneller and then inserted into the micro-introducer.
9. Close all incisions with cyanoacrylate glue
10. Secure the catheter by application of a dressing and in addition a sutureless device

Saphenous Vein

PICCs can also be inserted in the saphenous vein, which can be easily cannulated by ultrasound guidance in adults. However the high risk of venous thrombosis is most likely to occur when this vein is cannulated making this a very unusual procedure.

In children, the saphenous vein diameter is too small therefore it is unsuitable to use.

INSERTION COMPLICATIONS AND RISK MANAGEMENT

Catheter insertion site selection should be based on clinical need and practitioner judgment, experience and skill. In adults, the selection of an upper body insertion site should be considered to minimize the risk of thrombotic complications.

Complications relating to the insertion of central venous access devices such as vessel erosion, thrombosis and infection are addressed in section one and two of this document.

Additional risks relating to complications surrounding Internal Jugular (IJ) puncture for the placement of a tunnelled catheter are internal carotid artery (ICA) puncture, subclavian artery puncture (SA), Horner's syndrome, Pneumothorax

Internal Carotid Puncture

This may occur when ultrasound is not used to locate the Internal Jugular vein resulting in unintended cannulation of an arterial vessel.

- ◆ The use of large bore catheters are a contributing factor.
- ◆ Where small bore 6Fr Chest Inserted Central Catheters (CICCs) are placed a micro puncture set is used causing minimal trauma and less likelihood of arterial puncture

Subclavian Artery Puncture

Perforation of the subclavian artery may occur during the tunnelling procedure if the tip of the tunneller is facing downward and inadvertently travels under the clavicle puncturing the artery.

- ◆ Correct position of the tunneller tip, tunnelling over the top of the clavicle and the use of ultrasound for vein identification is critical.

Horner's Syndrome

This rare complication is caused by direct injury to the sympathetic trunk following internal jugular vein cannulation. (Dogan et al 2005)

- ◆ Ultrasound is highly recommended when puncturing the internal jugular vein to avoid injury to the sympathetic nerve pathway.

Management of Arterial Trauma or Injury

Where unintended cannulation of an arterial vessel with a tunneller, dilator or large- bore catheter occurs the tunneller, dilator or catheter should be left in place and an interventional radiologist or vascular surgeon should be consulted immediately. Further intervention needs to be evaluated and a treatment plan executed. (American Society of Anaesthesiologists Practice Guidelines 2012)

Prevention of Mechanical Trauma or Injury

Interventions intended to prevent mechanical trauma or vessel injury associated with central venous access include :(American Society of Anaesthesiologists Practice Guidelines 2012)

1. Catheter selection and gauge /size-selecting the smallest size where appropriate
2. Insertion site selection
3. Positioning of the patient for needle insertion and catheter placement
4. Using ultrasound imaging for the purpose of prepuncture vessel localization
5. Needle insertion and catheter placement using ultrasound guidance of the needle into its intended venous location
6. Monitoring of needle, guidewire and catheter placement

7. Verification of placement within the venous location. Including ultrasound guidance this may include
 - a. Manometry
 - b. Pressure waveform analysis
 - c. Venous blood gas
 - d. Fluoroscopy
 - e. Continuous ECG
 - f. Transeosophageal echocardiograph
 - g. Chest radiography

Pneumothorax

Is described as an abnormal collection of air or gas in the pleural space that causes an uncoupling of the lung from the chest wall. Physical trauma may be caused during the insertion of a central venous catheter. Pneumothorax is the one of the most frequent mechanical complications during central venous catheter (CVC) insertion. Subclavian vein insertion (SCV) has been reported to have a higher incidence of pneumothorax than internal jugular vein (IJV) insertion. Subclavian catheterization is more likely than internal jugular catheterization to be complicated by pneumothorax and haemothorax

- ◆ Catheter-related factors:
 - Site chosen for CVC insertion
 - Catheter type/size
- ◆ Clinical factors:
 - Experience of the clinician inserting the CVC
 - Previous catheterizations
 - Catheterization attempts
 - Emergency or elective situations
- ◆ Symptoms include chest pain that usually has a sudden onset. The pain is sharp and may lead to feelings of tightness in the chest. Shortness of breath, rapid heart rate, rapid breathing,

Prevention of Pneumothorax

1. The use of ultrasound guidance has been referred to as a method for reducing the risk of mechanical complications during insertion of CVC.
2. Imaging of the target vein by ultrasound prior to catheter insertion is clinically useful to confirm the presence of a target vein of adequate size for cannulation, because nearly 10% of patients have abnormal venous anatomy, including the absence of the vein of interest
3. There is a broad consensus and an extensive body of evidence-based literature demonstrating that real-time ultrasound-guided CVC placement is associated with fewer overall and specific complications, improved catheter insertion success and reduced costs. (Troianos et al 2011) Reports of the advantages of US guided insertion method over the anatomic landmark method support the findings of risk reduction and improved insertion success for all access sites and in different settings.
4. The gap between experienced and inexperienced operators has been reported to disappear when Ultra Sound assisted-insertion (UAI) is used.

Management of Pneumothorax

- ◆ Chest X-ray immediately following suspected pneumothorax is carried out to detect this complication. Treatment is determined by the severity of symptoms and indicators.(J Am Soc Echocardiogr. 2011)
- ◆ Small spontaneous pneumothoraxes do not always require treatment, as they are unlikely to proceed to respiratory failure or tension pneumothorax, and generally resolve spontaneously.
- ◆ This approach is most appropriate if the estimated size of the pneumothorax is small (defined as <50% of the volume of the haemothorax), there is no breathlessness and there is no underlying lung disease
- ◆ For pneumothoraxes 30% or smaller, in asymptomatic patients, in whom there was no difficulty with CVC insertion, a trial of observation is appropriate. Inspiration/expiration chest X-Ray is performed four hours later, followed by a chest X-ray performed 24 hours later should be obtained to assess the stability of pneumothorax. If the pneumothorax enlarges and the patient develops symptoms a small pigtail catheter with a Heimlich valve can be inserted on an outpatient basis. (Laronga 2000)

REFERENCES

- American Society of Anaesthesiologists. Practice Guidelines for Central Venous Access (2012) Task Force Report on Central Venous Access. *Anaesthesiology*, V 116.No 3
- AVA – Association for Vascular Access (2011) Position statement: cannulation of the external and internal jugular veins by registered nurses and other qualified healthcare professionals. Approved by AVA Board of directors, 14 July 2011. <http://www.avainfo.org/website/download.asp?id=280291>
- Benton,S.(2001) Training Nurses to place tunnelled central venous catheters. *Nursing Times.Net* retrieved from <http://www.nursingtimes.net/training-nurses-to-place-tunnelled-central-venous-catheters/197709.article>
- Chopra V, et. al. (2015) The Michigan Appropriateness Guide for Intravascular Catheters (MAGIC): Results from a Multispecialty Panel Using the RAND/UCLA Appropriateness Method. *Annals of Internal Medicine*; Vol.163 No.6 (Suppliment. 15 September 2015)
- Dogan E, Erkoc R, Sayarlioglu H, Etlik O, Uzun K.(2005)A rare complication of internal jugular vein cannulation: Horner;s Syndrome. *Eur J Gen Med*; 2(4):167-169
- Dawson RB (2011). PICC Zone Insertion Method: a systematic approach to determine the ideal insertion site for PICCs in the upper arm. *JAVA* 16(3):156–165
- Guidelines for performing ultrasound guided vascular cannulation: recommendations of the *American Society of Echocardiography and the Society of Cardiovascular Anesthesiologists*.
- Troianos CA, Hartman GS, Glas KE, Skubas NJ, Eberhardt RT, Walker JD, Reeves ST,(2011) Councils on Intraoperative Echocardiography and Vascular Ultrasound of the American Society of Echocardiography. *J Am Soc Echocardiogr*. 2011 Dec; 24(12):1291-318.
- Infusion Therapy Standards of Practice (2016). The role of the registered nurse in the insertion of external jugular peripherally inserted central catheters and external jugular peripheral intravenous catheters. Vol39,No1S
- Lamperti M, Pittiruti M (2013). Difficult peripheral veins: turn on the lights. *Br J Anaesth* 110(6):888–891
- Laronga C, Meric F, Truong MT, Mayfield C, Mansfield P.(2000) A treatment algorithm for pneumothoraces complicating central venous catheter insertion. *Am J Surg*. 2000 Dec; 180(6):523-6; discussion 526-7.
- Moureau N, Lamperti M, Kelly L. J, Dawson R., Elbarbary M., A. van Boxtel J. H. Pittiruti M.(2013) Evidence-based consensus on the insertion of central venous access devices: definition of minimal requirement for training. *British Journal of Anaesthesia* 110 (3): 347–56
- Pittiruti M, Emoli A (2012). Tunnelling a PICC: when? Abstract presented at the 2012 WoCoVA World conference on Vascular Access, Amsterdam, 26–29 June 2012
- Pittiruti M, Hamilton H ,Biffi R, MacFie J, Pertkiewicz M.(2009) ESPEN Guidelines on Parenteral Nutrition: central venous catheters (access, care, diagnosis and therapy of complications) *Clin Nutr* 28(4):365-377
- Sasadeusz K,Trerotola Shah H,Namyslowski J,Johnson M,Moresco K,Patel N.(1999) Tunnelled Jugular Small-Bore Central Catheters as an Alternative to Peripherally Inserted Central catheters for Intermediate-Term Venous Access in Patients with Haemodialysis and Chronic Renal Insufficiency. *Radiology* 1999; 213:303-306
- Selby JB, Cohn DJ, Koenig G,(2001) Peripherally inserted tunnelled catheters: a new option for venous access. *Min Invas Ther & Allied Technol* 2001;10(4/5)231-234
- Tsotsolis N, Tsirgogianni K, Kioumis I, et al. Pneumothorax as a complication of central venous catheter insertion. *Annals of Translational Medicine*. 2015; 3(3).
- Hind D, Calvert N, McWilliams R, Davidson A, Paisley S, Beverley C, Thomas S.(2003) *BMJ*. 2003 Aug 16; 327(7411):361.Ultrasonic locating devices for central venous cannulation: meta-analysis. (2003)