
CHAPTER 1

Overview of Skin Issues Related to the Oncology Patient

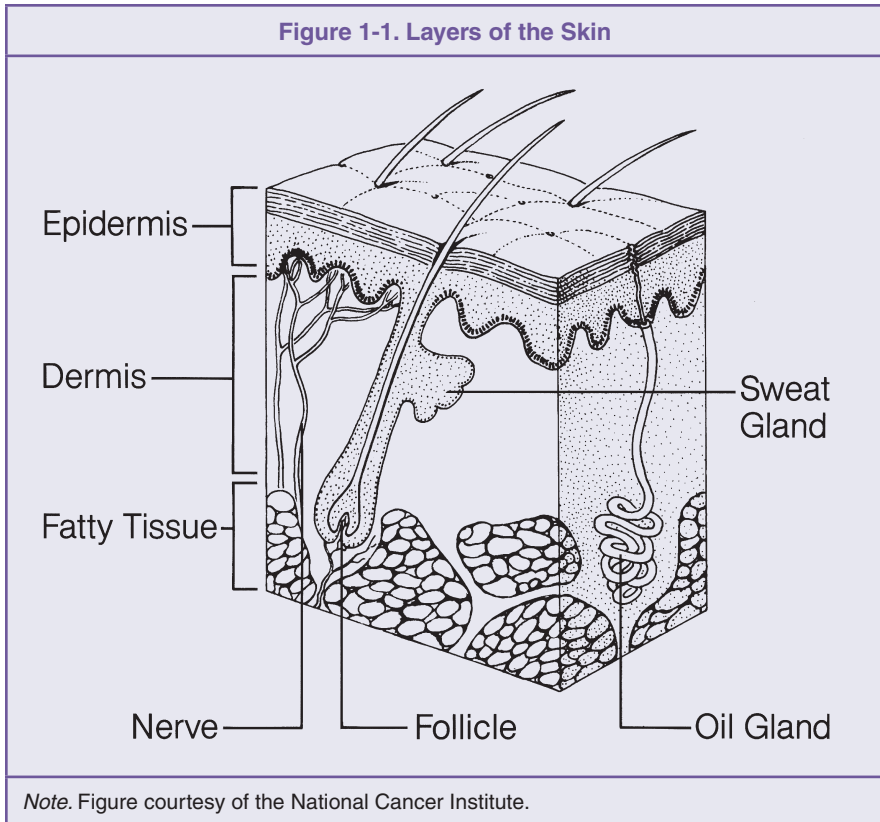
William P. Hogle, RN, MSN, OCN®

Introduction

The skin acts as a tough exterior barrier of protection; it is essentially the body's first line of defense. It also serves as a host to numerous microorganisms and is reactive to innumerable external stimuli, including stress. As a result, patients frequently ask healthcare professionals to assess some variation of rash, abrasion, excoriation, ulceration, pruritus, or inflammatory cutaneous reaction. These common and often benign complaints occur with a high degree of frequency among the general population. When these same complaints occur among patients with cancer, oncology practitioners have much to consider in terms of the cause (treatment-related or from other factors), comorbid conditions, and the potential impact any intervention may have on the reaction. The purpose of this chapter is to provide basic background knowledge about the integumentary system and surrounding soft tissues, as well as a basic understanding of normal tissue healing. A general overview of evidence-based risk factors for poor wound healing is provided, and a brief review of the paradigm of support for wound healing is explored.

On a large scale, the integumentary system consists of skin, sweat and sebaceous glands, hair follicles, and nails. Together, these components function to protect, moderate temperature, and excrete waste. On a smaller scale, the integumentary system consists of water molecules, proteins, lipids, and numerous minerals and chemical components. Skin, the primary component of the integumentary system, is the largest organ of the human body. Often taken for granted, the skin is pliable and water resistant. In an average adult, skin weighs 9–11 pounds and accounts for approximately 7% of total body

weight. Skin varies in thickness from 0.05 mm (eyelids) up to 4 mm or more (soles and palms). The skin is divided into three layers: the epidermis, the dermis, and the subcutaneous tissue, also referred to as the hypodermis (Marieb, 2001) (see Figure 1-1).



Epidermis

The *epidermis* is the outermost portion of the skin and is a stratified squamous epithelium. Throughout the epidermis, typically four different cell types can be found: *melanocytes*, which synthesize pigment; *Langerhans cells*, which help to activate the immune system; *Merkel cells*, which perform sensory functions; and *keratinocytes*, which gradually mature to serve as the outermost layer of skin. Variations in total skin thickness are determined by the thickness of the epidermis in a given area. Thicker skin consists of all five layers of the epidermis: stratum basale, stratum spinosum, stratum granulosum, stratum lucidum, and stratum corneum. Thinner skin consists of the same layers except

for the stratum lucidum, although each layer has less volume (Marieb, 2001; Shier, Butler, & Lewis, 2004).

Stratum Basale

The *stratum basale* is the deepest of all epidermal layers and is attached to the dermis in an uneven, almost wave-like, fashion. This layer consists of the youngest of keratinocytes, which are constantly undergoing rapid division. Melanocytes and Merkel cells also can be seen in the stratum basale. From this layer, keratinocytes continually work their way up to the skin surface while undergoing gradual changes through each successive layer of the epidermis (Shier et al., 2004).

Stratum Spinosum

The *stratum spinosum* consists of web-like filaments that are made up of tension-resisting bundles of pre-keratin filaments. At this level, keratinocytes are flatter than in the stratum basale, are irregular in shape, and are sometimes referred to as *prickle cells*. Melanin and Langerhans cells are abundant in this layer (Shier et al., 2004).

Stratum Granulosum

In the *stratum granulosum*, keratinocytes continue to surface while undergoing further visual change by flattening and acquiring properties that aid in their ability to retain fluid. Glycolipids are acquired by the keratinocyte, and their plasma membrane thickens so as to become more resilient to everyday use and exposure. At this level, the keratinocyte begins to grow beyond capillary extension and begins to die (Shier et al., 2004).

Stratum Lucidum

The *stratum lucidum* is a layer that consists of clear, flat, dead keratinocytes and is seen in the thickened skin of the palms and soles.

Stratum Corneum

The *stratum corneum*, also referred to as the horny layer, makes up approximately 75% of the epidermal thickness and is the outermost layer of the epidermis. At this layer, hardened keratinocytes protect against physical assault, and glycolipids between each cell act to waterproof the entire body (Shier et al., 2004).

Dermis

The *dermis* is the second major skin layer and consists of strong, flexible connective tissue. This layer is made up of a semifluid matrix, which is

heavily embedded with collagen, elastin, and reticular fibers. Cells most frequently seen in the dermis are similar to those seen in other connective tissue and include fibroblasts, mast cells, and leukocytes. The dermis also contains numerous nerve fibers and appendages of the integumentary system, such as sweat and sebaceous glands and hair follicles. The dermis consists of two layers, the papillary layer and the reticular layer. Together, these layers act to bind the epidermis to the underlying tissue (Marieb, 2001; Shier et al., 2004).

Papillary Layer

The *papillary layer* of the dermis is a thin superficial layer of connective tissue that contains collagen and elastin fibers and a rich supply of blood vessels. It also contains a number of nerve fibers that are sensitive to light touch (*Meissner corpuscles*) and heavier pressure (*Pacinian corpuscles*), whereas others are sensitive to temperature. Here, dermal ridge patterns begin to form that give way to epidermal ridges, which are one's finger, palm, toe, and sole prints. These epidermal ridges allow people to grip surfaces by means of increased friction (Shier et al., 2004).

Reticular Layer

The deeper *reticular layer* accounts for most of the thickness of the dermis. It consists of dense connective tissue and dense collagen fibers. These collagen fibers provide strength and resiliency to the skin, allowing it to prevent many scrapes and cuts from penetrating into deeper skin and body tissues.

Subcutaneous Layer

The *subcutaneous layer* of skin lies beneath the dermis and consists largely of loose connective and adipose tissue. This layer functions mainly as a heat insulator, keeping heat inside and retarding excessive heat from outside the body. The amount of adipose tissue varies from one person to the next, as does the amount found in different portions of the body. Adipose tissue is thicker in the abdominal region and essentially nonexistent in the eyelids. An individual's nutritional status also influences the amount of adipose tissue found throughout the body (Shier et al., 2004).

Accessory Organs of the Skin

Along with the skin itself, the integumentary system contains a number of accessory organs, sometimes referred to as skin appendages, including sweat and sebaceous glands, hair and hair follicles, and nails.

Sweat Glands

Sweat glands, also referred to as *sudoriferous* glands, can be found in all regions of the body. Some sweat glands, apocrine glands, respond to emotional stress and sexual stimulation. They become active during puberty and are most abundant in the axillary regions, in the groin, and around the nipples. They are usually associated with hair follicles. Other sweat glands, the *eccrine* glands, respond to elevated body temperature from environmental heat or physical exercise. These glands are not associated with hair follicles and are common on the forehead, neck, and back. Fluid secreted by sweat glands is carried to the surface of the skin through the pores. Sweat contains body salts, urea, and uric acid. Thus, the sweat glands function, to a small degree, to remove waste from the body (Shier et al., 2004).

Sebaceous Glands

Sebaceous glands, also referred to as *oil glands*, are found throughout the skin, except on the palms and soles. These glands produce globules of fatty material that accumulate, causing cells to swell and burst. The resulting mixture of cellular debris and fatty material is called *sebum*. When sebum is excreted through hair follicles, as it often is, it helps to maintain pliability and waterproof ability of hair and skin. Sebum sometimes is excreted directly to the skin surface, such as from the lips, corners of the mouth, or external reproductive organs (Shier et al., 2004).

Hair and Hair Follicles

Hair is present on all surface areas of the skin except the palms, soles, lips, nipples, and various parts of the external reproductive organs. Hair may appear very fine and less obvious or rather coarse and apparent. Each hair develops from a group of epidermal cells at the base of a tube-like depression called a *hair follicle*. The hair follicle extends from the surface into the dermis and may pass into the subcutaneous layer. Epidermal cells at the follicle's base receive nourishment from dermal blood vessels. As these epidermal cells grow and divide, older cells are pushed toward the surface, thus becoming keratinized, and die. Therefore, hair is actually composed of dead epidermal cells. Hair color is determined by the pigment produced by epidermal melanocytes at the base of the hair follicles. Dark hair contains an abundance of melanin, whereas blond hair contains an intermediate amount. Albino hair is absent of any pigment, and red hair contains iron pigment, or *trichosiderin*. A mixture of pigmented and unpigmented hair usually results in the appearance of gray hair (Shier et al., 2004).

Nails

Nails are protective coverings on the ends of the fingers and toes. Each nail consists of a *nail plate* that overlies a surface of skin known as the *nail bed*. The nail plate is produced by specialized epithelial cells that are continuous with the epithelium of the skin. The *lunula* is the whitish half-moon-shaped region

at the base of each nail plate and is the most active region in terms of growth. The epithelial cells of the nail undergo heavy keratinization as they grow forward, thus giving the nail a hardened horn-like consistency. Nails are useful for scratching and aid in picking up small objects (Shier et al., 2004).

Soft Tissue

In humans, as in all complex organisms, cells are organized into layers or groups called *tissues*. *Soft tissue* is a term that can be used to describe muscle and fascia, or it can be used in a broader sense to include multiple different types of tissues, including but not limited to skin. Although the cells of different tissues vary in size, shape, arrangement, and function, those within a particular tissue are rather similar. The tissues of the human body include the following four major classifications:

- Epithelial tissue
- Connective tissue
- Muscle tissue
- Nervous tissue.

Epithelial Tissue

Epithelial tissue consists mostly of epithelial cells, which were discussed throughout the previous section. Epithelial tissue is widespread and essentially covers all body surfaces. It is the major tissue of the glands. The underside of the epithelial tissue is anchored to connective tissue by a thin, non-living layer called the *basement membrane*. Generally, epithelial tissue lacks blood vessels and is nourished by underlying connective tissue. Although the cells of some tissues have limited abilities to reproduce, epithelial cells reproduce readily. Thus, injuries to the skin and lining of the gastrointestinal tract heal relatively quickly, as epithelial tissue is quite abundant in these areas. Epithelial tissues are classified according to shape, arrangement, and function (Shier et al., 2004) (see Table 1-1).

- *Simple*: Composed of single layers of cells
- *Stratified*: Those with many layers of cells
- *Squamous*: Those with thin, flattened cells
- *Cuboidal*: Those with cube-like cells
- *Columnar*: Those with elongated cells.

In addition, glandular tissue, or *glandular epithelium*, is also a type of epithelial tissue that is composed of specialized cells that produce and secrete various substances into ducts or body fluids. These glandular cells usually are found in columnar or cuboidal epithelium. Glands that secrete into ducts that open onto an internal or external surface are called *exocrine* glands, and glands that secrete into tissue or blood are called *endocrine* glands.

Table 1-1. Types of Epithelial Tissue

| Type | Description | Function | Location |
|--------------------------------------|---|---|---|
| Simple squamous epithelium | Single layer, flattened cells | Filtration, diffusion, osmosis, covers surface | Alveoli, capillary walls, linings of blood and lymph vessels |
| Simple cuboidal epithelium | Single layer, cube-shaped cells | Secretion, absorption | Surface of ovaries, linings of kidney tubules, and linings of ducts of certain glands |
| Simple columnar epithelium | Single layer, elongated cells | Protection, secretion, absorption | Linings of uterus, stomach, and intestines |
| Pseudostratified columnar epithelium | Single layer, elongated cells | Protection, secretion, movement of mucus and substances | Linings of respiratory passages |
| Stratified squamous epithelium | Many layers, top cells flattened | Protection | Outer layer of skin, linings of oral cavity, throat, vagina, anal canal |
| Stratified cuboidal epithelium | 2–3 layers, cube-shaped cells | Protection | Lining of the larger ducts of the mammary glands, sweat glands, salivary glands, and the pancreas |
| Stratified columnar epithelium | Top layer of elongated cells, lower layers of cube-shaped cells | Protection, secretion | Vas deferens, part of the male urethra, parts of the pharynx |
| Transitional epithelium | Many layers of cube-shaped and elongated cells | Distensibility, protection | Inner lining of urinary bladder, and linings of ureters and part of urethra |
| Glandular epithelium | Unicellular or multicellular | Secretion | Salivary glands, sweat glands, endocrine glands |

Note. From *Hole's Human Anatomy and Physiology* (10th ed., p. 141), by D. Shier, J. Butler, and R. Lewis, 2004, Boston: McGraw-Hill. Copyright 2004 by McGraw-Hill. Reprinted with permission.

Connective Tissue

Connective tissues are present in all parts of the body and act to bind structures together, provide support and protection, store fat, produce blood cells, and assist in repair of damaged tissue. Connective tissues have an abundance of intercellular matrix that consists of fibers and a ground substance whose consistency varies from fluid to semisolid or solid. Some connective tissues, such as bone and cartilage, are quite rigid. Loose, adipose, and fibrous connective tissues are much more flexible (see Table 1-2). Another connective tissue, blood, is mostly liquid in form and sometimes referred to as reticuloendothelial tissue. It is composed of a variety of specialized cells that are widely scattered throughout the body. Although a variety of cells can be found in the more flexible and rigid types of connective tissue, such tissues routinely consist of fibroblasts, macrophages, and mast cells. Other types of white blood cells may be present as well; however, this usually is in response to some type of infection in a particular area (Shier et al., 2004).

Muscle Tissue

Muscle tissues are contractile and consist of fibers that can change shape by becoming shorter and thicker. As muscle fibers contract, they pull at their attached ends, resulting in body movement. The three types of muscle tissue are

- Skeletal
- Smooth
- Cardiac.

Skeletal muscles are attached to bones and can be controlled by conscious effort and therefore are called *voluntary muscles*. These types of muscle are striated in appearance and are responsible for all movements of the head, trunk, and limbs, as well as for chewing, swallowing, and breathing. Smooth muscles are not striated and cannot be stimulated to contract through conscious effort. Smooth muscle tissue is found in the walls of hollow organs and is responsible for moving matter such as blood, digested matter, or urinary waste through a particular part of the body. *Cardiac* muscle tissue is striated and is found only in the heart. It is controlled involuntarily and can continue to function without being stimulated by nerve impulses. This type of muscle tissue makes up the bulk of the heart and is responsible for pumping blood through the heart chambers and into the blood vessels (Shier et al., 2004).

Nervous Tissue

Nervous tissue consists of *neurons*, which are considered highly specialized body cells. Neurons are very sensitive to changes in their environment and respond by transmitting nerve impulses to other neurons or to muscles and glands. Their role is to coordinate and regulate many body functions. In addition to neurons, *neuroglial* cells are present in nervous tissue. These cells bind and support the components of nervous tissue that are active during phago-

Table 1-2. Types of Connective Tissue

| Type | Description | Function | Location |
|-----------------------------|-------------------------------------|--|--|
| Loose connective tissue | Cells in fluid-gel matrix | Binds organs together, holds tissue fluids | Beneath the skin, between muscles, beneath most epithelial tissues |
| Adipose tissue | Cells in fluid-gel matrix | Protection, insulation, and storage of fat | Beneath the skin, around the kidneys, behind the eyes, on the surface of the heart |
| Reticular connective tissue | Cells in fluid-gel matrix | Support | Walls of liver, spleen, and lymphatic organs |
| Dense connective tissue | Cells in fluid-gel matrix | Binds organs together | Tendons, ligaments, dermis |
| Elastic connective tissue | Cells in fluid-gel matrix | Provision of elastic quality | Connecting parts of spinal column, in walls of arteries and airways |
| Hyaline cartilage | Cells in solid-gel matrix | Support, protection, provision of framework | Ends of bones, nose, and rings in walls of respiratory passages |
| Elastic cartilage | Cells in solid-gel matrix | Support, protection, provision of flexible framework | Framework of external ear and part of larynx |
| Fibrocartilage | Cells in solid-gel matrix | Support, protection, absorption of shock | Between bony parts of spinal column, parts of pelvic girdle, and knee |
| Bone | Cells in solid matrix | Support, protection, provision of framework | Bones of skeleton, middle ear |
| Blood | Cells and platelets in fluid matrix | Transportation of gases, defense against disease, clotting | Throughout the body within a closed system of blood vessels and heart chambers |

Note. From *Hole's Human Anatomy and Physiology* (10th ed., p. 150), by D. Shier, J. Butler, and R. Lewis, 2004, Boston: McGraw-Hill. Copyright 2004 by McGraw-Hill. Reprinted with permission.

cytosis and help to supply nourishment to neurons by connecting them to blood vessels. Nervous tissue is only found in the brain, spinal cord, and peripheral nerves (Shier et al., 2004).

Epithelial Tissue Reproduction

The cells of the four types of tissue previously described vary greatly in their abilities to reproduce. Epithelial cells, found in the skin and digestive tract, and connective tissue cells, found in the blood and bone marrow, continuously reproduce. However, striated, cardiac muscle, and nerve cells show little propensity to reproduce after becoming differentiated. Fibroblasts, found primarily in connective tissue, respond rapidly to injuries and are the principal agents of repair. In tissues where fibroblasts are limited, such as cardiac and nerve, healing from assault or degeneration is absent or limited at best.

The Healing Process

Few organs in the body can regenerate and self-heal to the extent that skin can. Normal skin and wound healing in an individual without risk factors for altered wound healing occurs in a series of distinct phases. The time it takes for healing to occur varies widely from person to person. Additionally, all wounds, even if on the same person, do not heal at the same rate. Therefore, predictions as to how long a wound will take to heal in a person without comorbidities are based on knowledge of the skin and wound healing process and clinical experience. A number of conditions can affect wound healing, many of which are described later in this chapter. The process by which damaged skin heals depends largely on the extent of the injury. If a break in the skin is shallow, epithelial cells along its margin are stimulated to reproduce more rapidly than usual, and the newly formed cells simply fill in the defect. If the injury extends into the dermis or subcutaneous layer, then a more intricately detailed and systematic approach to healing occurs (McNees, 2006).

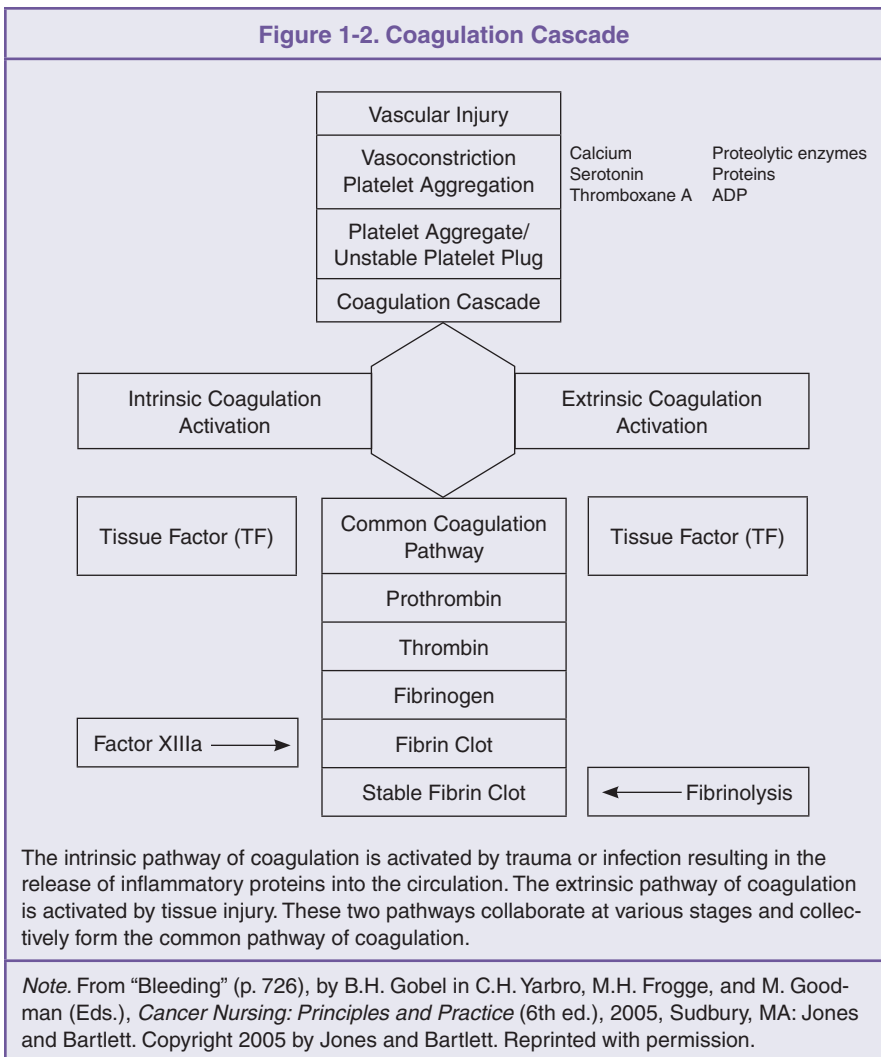
Healing is a natural restorative response to tissue injury. Wound healing has three distinct and highly complex phases, although some literature has described models with four or five phases. This three-phase description combines most of the actions that are addressed in lengthier models:

- Hemostatic/inflammatory phase
- Fibroblastic or proliferation/granulation phase
- Maturation or remodeling phase.

Hemostatic Phase

During the hemostatic phase, the body is essentially attempting to stop or minimize external bleeding while mobilizing agents necessary for later wound healing. Platelets and the agents they secrete are most active dur-

ing this phase. Platelets begin to clump or accumulate so as to form a clot that acts to seal any nearby bleeding vessels. In addition, as platelets congregate, they secrete substances that aid in the production of *thrombin*, which, in turn, stimulates *fibrin* production. Fibrin then forms a mesh-like structure that works with the actual clot formation to solidify a hemostatic plug at the site of injury. An increased accumulation of prostaglandins, histamine, and vasoactive agents further aids hemostasis. Essentially, enzymes and coagulation factors are stimulated in a sequential manner so as to activate what is referred to as the *coagulation cascade* (see Figure 1-2). A number of inhibitors and control mechanisms keep the clotting reaction local-



ized to the site of injury. When these control mechanisms fail, coagulopathy occurs, including thrombocytopenia and disseminated intravascular coagulation (McNees, 2006).

The hemostasis phase of healing also includes an accumulation of leukocytes and monocytes, which is needed to mount an immune response against any invasive pathogen. Thus, the initiation of a humoral immune response takes place during this first phase of wound healing.

Fibroblastic Phase

During the fibroblastic phase, existing fibroblasts are mobilized and their proliferation increases so as to synthesize collagen production. *Fibroblasts*, the most common cell in connective tissue, produce fibers of protein; one such protein is *collagen*. Collagen fibers are only slightly elastic and occur in bundles. Collagen is essential for strengthening the wound site. Fibroblasts also initiate the production of *granulation* tissue, which is vascular connective tissue. This is the initial process of reestablishing microcirculation to a wound to supply needed oxygen and nutrients while removing waste and debris (McNees, 2006; Romo, Pearson, Yalamanchili, & Zoumalan, 2008).

Maturation Phase

The *maturation*, or *remodeling*, phase is the final and most time-intensive phase of the healing process. During maturation, successive collagen replacement occurs many times over. With each successive replacement, the previously damaged tissue is essentially attempting to become successful clones of the cells that were in place prior to any injury. After each replacement, the general appearance improves, and a scar may appear at the site of injury. Additional collagen replacements result in further visual improvements and softening of scar tissue. A scar can form wherever a wound or ulceration has occurred. The scarred epidermis is thin and generally without normal skin lines. If an overgrowth of collagen fibers and capillaries occurs, a *keloid* or *hypertrophic* scar may result. Keloids differ from normal scars in that they tend to increase in dimension over time, grow beyond the border of the original wound, and do not spontaneously regress. Keloids can result in numbness, tingling, itching, pain, and deformity (Robbins, 2007). Hypertrophic scars stay within the original borders of injury and usually resolve spontaneously. Little is known as to the complete etiology of keloids and hypertrophic scars. Abnormalities associated with these irregularities include the following (Romo et al., 2008):

- Abnormal cell migration
- Proliferation
- Inflammation
- Synthesis and secretion of extracellular matrix proteins and cytokines.

If skin loss from a cut, deep abrasion, or burn has occurred, the process of healing previously described involves two other elements: re-epithelializa-

tion and wound contracture. Normally, when skin has been removed, epithelial cells migrate across the surface area of the wound. This process begins at the wound edges. If a wound edge is compromised by tissue sloughing or by means of a burn, re-epithelialization can be very slow to occur. In these cases, flaps or grafts may be necessary to close an open wound. Wound contracture, although not dependent on collagen synthesis, occurs at the same time during the fibroblastic phase of healing. *Wound contracture* is defined as the centripetal movement of wound edges that facilitates closure of the wound defect. Maximal wound contraction occurs 5–15 days from initial injury (Romo et al., 2008).

Skin Burns

Depending on its severity, a skin burn can be traumatic and even life threatening. A skin burn does not necessarily result in a break in the integrity of the skin. In such cases, healing occurs through a gradual process of basal and epithelial cell replacement. The erythema initially seen in a burn or burn-like reaction usually is transient and the result of capillary dilation and increased vascular permeability. Subsequent redness from a minor burn is caused by a release of histamine from damaged cells (Sparks, 2007). Other reactions resulting from mild to moderate burns, such as hypo- or hyperpigmentation, desquamation, and fibrosis, are typical reactions to radiation therapy and are covered in Chapter 6.

A burn can result from

- Ultraviolet radiation damage (including solar exposure)
- High-energy x-rays or gamma rays (from megavoltage radiation therapy)
- Thermal damage (fires or exposure to extremely hot surface or liquids)
- Chemical damage (when chemical compounds interact with the skin surface)
- Electrical damage (including electrical accidents and lightning strikes)
- Friction or abrasion.

As with other types of injuries, the skin's response to a burn depends on the amount of damage it sustains. For the purpose of description and treatment, burns are classified according to the depth of tissue damage, regardless of the cause (Johnson & Richard, 2003).

Superficial Burn

Previously characterized as a first-degree burn, a *superficial burn* exists when the skin is only lightly burned. The area of injury may simply become warm and erythematous as dermal capillaries are dilated and histamine is released. Over time, the surface layer of the skin may shed. Superficial burns are considered the least serious of all burns, affect only the epidermis, and usually require little or no treatment. Excessive unprotected sun exposure usually

results in a superficial burn to the skin. Long-term tissue damage is rare and usually consists of permanent hypo- or hyperpigmentation (Johnson & Richard, 2003; Morgan, Bledsoe, & Barker, 2000).

Superficial Partial-Thickness Burn

Previously characterized as a second-degree burn, a *partial-thickness burn* involves injury to the epidermis and part of the dermal layer of skin. Partial-thickness burns become intensely erythematous and are characterized by the appearance of blisters caused by fluid escaping from dermal capillaries, which accumulates beneath the outer layers of epidermal cells. When pressure is applied to the reddened area, the area will blanch but will demonstrate a rapid capillary refill upon release of the pressure. Edema may or may not be present, and the site of injury frequently is painful. Recovery from partial-thickness burns usually is complete, and scar tissue typically does not result unless infection occurs. Permanent hypo- or hyperpigmentation may result from a partial-thickness burn (Johnson & Richard, 2003; Morgan et al., 2000).

Deep Partial-Thickness Burn

As with a superficial partial-thickness burn, damage from a deep partial-thickness burn extends beyond the epidermis and into the reticular layer of the dermis. These burns present as mixed erythema/waxy white in appearance. Areas of redness may continue to blanch when pressure is applied, as capillary refill may be absent or sluggish when pressure is released. Blisters usually are absent, although the exposed surface of the wound is likely to appear wet or moist. Edema frequently is present, and sensation is altered with this type of injury (Johnson & Richard, 2003).

Full-Thickness Burn

Previously characterized as third-degree burns, *full-thickness burns* destroy the full thickness of the skin and may also damage subcutaneous and underlying tissues (including muscle and bone). A full-thickness burn affects every body system and organ. This type of burn can be completely painless because nerve tract and nerve endings may be totally burned away. The burn site appears white or charred, and ulceration often occurs as a result of such a serious assault to the skin's integrity. Repair of full-thickness burns often involves skin grafts transplanted from another area of one's body, called an *autograft*, or from a cadaveric donor or synthesized skin substitute, called a *homograft*. Permanent scarring, nerve damage, and contracture are not unusual following full-thickness burns. Patients with full-thickness burns are at risk for overriding sepsis, require aggressive medical support, and often undergo multiple reconstructive surgical procedures (Balasubramani, Kumar, & Babu, 2001; Johnson & Richard, 2003).

Impaired Skin and Wound Healing During Cancer Treatment

Patients receiving cancer treatment are at risk for altered skin integrity. Skin reactions are generally categorized as acute or chronic. *Acute* skin reactions from cancer treatment can be caused or exacerbated primarily as a result of three variables: patient-specific factors, treatment-related factors, and presence of chronic systemic or comorbid disease. *Chronic* skin reactions usually result in an altered appearance and are not typically a disruption of the skin integrity per se; exceptions might include chronic nonhealing wounds present before the initiation of treatment. In the presence of impaired vascularity, peripheral neuropathy, or preexisting collagen vascular disease, wounds can become chronic in nature and represent a significant challenge to the caregiver and patient. The presence of multiple variables will obviously increase one's likelihood for developing a disruption in skin integrity during cancer therapy. Therefore, careful assessment before initiation of treatment is important.

Patient-Related Factors

Patient-related factors that affect skin reactions include age (older patients are at increased risk), compromised nutritional status, low performance status, anatomic location of treatment area (skin folds and body contour, especially with radiation therapy), degree of previous sun or radiation exposure, smoking, and one's individual degree of sensitivity to chemotherapy or radiation therapy (Maher, 2005; Pearce, 2005; Porock, Kristjanson, Nikoletti, Cameron, & Pedler, 1998). Patient-specific factors that influence skin and wound care are addressed in greater detail later in this chapter.

Treatment-Related Factors

At times, modalities used to treat malignancy can actually cause or impact the degree of disruption in one's skin integrity. Most chemotherapeutic toxicity profiles include the potential for some type of cutaneous reaction, including

- Pruritus
- General erythematous rash
- Hyperpigmentation
- Photosensitivity
- Alopecia
- Nail changes.

More serious reactions include urticaria, a sign of cutaneous hypersensitivity reaction, and *acral erythema*, also known as *palmar-plantar erythrodysesthesia* (hand-foot syndrome). Acral erythema is painful scaling and sloughing, along with erythema, of the palms and soles, followed by desquamation and reepithelialization of the skin (Camp-Sorrell, 2005). It is believed that acral erythe-

ma is a result of direct toxic effect on the epidermis and dermal vasculature or possibly an accumulation of chemotherapeutic agent in the eccrine glands, which are present in the palms and soles (Eich, Scharffetter-Kochanek, Eich, Tancheva-Poor, & Krieg, 2002; Remlinger, 2003). Monoclonal antibodies that act as epidermal growth factor receptor (EGFR) inhibitors have been associated with skin toxicities, including acneform rash, folliculitis, skin dryness, pruritus, fissuring, and nail changes. The etiology of skin toxicity associated with the administration of EGFR inhibitors is unclear, but preclinical studies have demonstrated that it results from EGFR expression in normal skin (Perez-Soler & Saltz, 2005). The incidence of rash reported in numerous studies of EGFR inhibitors ranges from 37%–90% and is typically mild to moderate (grade 1 or 2), with severe (grade 3 or 4) rash uncommon (Oishi, 2008).

Some chemotherapeutic agents (5-fluorouracil, methotrexate, paclitaxel, and doxorubicin) and monoclonal antibodies, when given concurrently with radiation therapy, act synergistically. These agents may increase the severity of radiation skin reactions, cause them to occur at a lower dose of radiation, and possibly prolong the reaction (Maher, 2005; Oishi, 2008; Sparks, 2007).

Radiation therapy is known to cause a number of temporary skin reactions, including erythema, pruritus, and dry or moist desquamation. More permanent yet less common skin effects from radiation include the following (Chiao & Lee, 2005; D’Haese et al., 2005; Haas, 2005; Porock & Kristjanson, 1999):

- Fibrosis
- Telangiectasia
- Ulceration
- Necrosis.

Ionizing radiation inhibits the mitotic ability of stem cells within the basal layer, thus preventing the process of repopulation and weakening the integrity of the skin (Archambeau, Pezner, & Wasserman, 1995). The severity of skin reactions from radiation therapy is influenced by the

- Dose delivered with each treatment (fraction)
- Total cumulative dose
- Volume of tissue treated
- Type of radiation used (electrons and lower-energy photons produce higher skin doses and, thus, increased risk for skin reactions)
- Use of bolus material on the skin itself, which increases the total dose (D’Haese et al.; Haas; Porock et al., 1998).

Normal anatomic skinfolds in areas such as the axilla, inframammary region, groin, and perineum are at increased risk for adverse skin reactions secondary to radiation therapy (Haas). Obese patients are at even greater risk because obesity usually results in larger skinfold areas, which are more prone to increased moisture and friction.

Patients may experience *radiation recall*, which is an inflammatory skin reaction at a previously irradiated site subsequent to the administration of a number of pharmacologic agents, including anthracyclines, alkylating agents, antimetabolites, and taxanes. Such a reaction can occur days to years following

radiation. The precise mechanism of action for radiation recall is poorly understood. Skin reactions commonly seen with radiation recall are erythema, maculopapular eruptions, vesicle formation, and desquamation of the affected areas. The reactions can range from mild rash to severe skin necrosis (Azria et al., 2005; Sparks, 2007).

Chronic Disease

Patients with cancer also may be affected by one or many states of chronic disease. Because of the very nature of chronic disease, its impact is eventually manifested in every body system. Although epidermal and dermal changes may take longer to occur, they can develop into alterations ranging from pruritus, erythema, or edema to discomfort, formation of lesions, cellulitis, or chronic ulceration. The following is a brief review of selected disease states and conditions and the effects they have on the integumentary system. For a more thorough and detailed review of how chronic, systemic, and infectious skin diseases affect the integumentary system, refer to Chapters 9 and 10.

Cardiovascular disease is a serious and complex state that can encompass a wide variety of systemic disorders. Peripheral obstructive arterial and venous conditions can result in increased intravascular pressure and reduced blood flow, or *stasis*. Stasis then may lead to vascular leak syndrome and possibly skin ulceration and thrombosis. Signs of decreased vascular flow include

- Skin discoloration
- Hyperpigmentation
- Pain
- Neuropathy
- Cyanosis.

Patients who have arterial stenosis or occlusion may develop *critical limb ischemia* (CLI), which occurs when basal requirements for tissue oxygenation cannot be met. Patients with diabetes mellitus are known to have diffuse and sometimes severe CLI. Ischemic ulcers, characteristic of CLI, are very painful and usually appear at the end of one's toes or over a bony prominence. Gangrene can result in end-stage CLI. These patients require aggressive debridement, antimicrobial therapy, and revascularization. Patients with venous insufficiency may develop ulcers from mechanisms similar to arterial insufficiency: increased pressure, leading to edema and tissue necrosis. *Stasis dermatitis* is a common dermatologic finding in patients with congestive heart failure (CHF). Dysfunction of the deep peripheral venous system, caused by CHF, leads to venous stasis and edema. Continued pressure from edema causes reduced oxygenation of the surrounding tissues and overlying skin. The result is localized pigmentation changes of the skin and possibly venous stasis ulceration (Englert, 2003; Jaff, 2001).

Lymphedema, whether primary or secondary in nature, is defined as chronic swelling caused by impairment in the lymphatic system drainage. When

an obstruction develops in the lymphatic system, the flow of lymphatic fluid is circumvented into the surrounding interstitial tissue, thus causing an accumulation of a highly concentrated, protein-filled fluid in an area distal to the blockage. The fluid accumulation results in inflammation leading to skin changes and fibrosis. Skin affected by stage II or III lymphedema may leak or ooze fluid and is at increased risk for cellulitis, infection, or ulceration (Holcomb, 2006; Lawenda, Mondry, & Johnstone, 2009; Marrs, 2007). For more information about the stages of lymphedema, see Table 1-3.

Some pulmonary diseases can have cutaneous manifestations. These usually are not seen as primary characteristics of respiratory illness, and diagnosis typically is made long before symptoms are present. *Erythema multiforme* and *erythema nodosum* can be seen in bacterial pneumonia and sarcoidosis, respectively. Papules and skin nodules may be present in cases of bronchogenic carcinoma, and patients with tuberculosis may develop destructive skin lesions known as *lupus vulgaris* (Murray, 2000).

Chronic renal disease often results in varying degrees of pruritus, muscle weakness, and spontaneous tendon rupture. Pruritus in these patients is believed to be a result of high systemic levels of calcium and phosphorus (Martin, Gonzalez, & Slatopolsky, 2004). Other bone and soft-tissue disorders, such as erosive arthritis, joint effusions, and amyloidosis, also may exist in this patient population. In many cases, a parathyroidectomy can correct these abnormalities (Martin et al.). Another dermatologic effect of renal disease reported in up to 40% of patients is a condition known as *half-and-half nails* (HHNs).

Table 1-3. Stages of Lymphedema

| Stage | Characteristics | Assessment Parameters |
|---|--|--|
| Stage 0 Latency stage | Subclinical in nature | Asymptomatic, or mild heaviness of limb |
| Stage I Reversible lymphedema | Soft and pitting in nature without fibrosis | Prolonged elevation can lead to complete resolution. |
| Stage II Spontaneously irreversible lymphedema | Intradermal fibrosis, decreased suppleness, and decreased ability to pit, although pitting is possible. | Not reversible with elevation; skin on back of fingers and toes cannot be lifted or is lifted with difficulty. Pitting, if present, is measured on a 0–3+ scale. |
| Stage III Lymphostatic elephantiasis | Increase in severity of fibrosis and tissue volume; formation of cysts, fistulas, and papillomas more likely; adipose tissue can replace fluid in limbs. | As above in stage II, and skinfolds at wrist and ankles deepen. |

Note. Based on information from Lawenda et al., 2009.

Characterized by a dark distal band that occupies 20%–60% of the nail bed and by a white proximal band, HHNs typically disappear after successful renal transplantation. Pathophysiology for this condition is related to the proximal half of the nail appearing white because of edema associated with a dilated capillary network and the other half of the nail bed appearing normal (Headley & Wall, 2002; Martin et al.).

Patients with chronic liver disease may develop skin reactions. Palmar erythema is seen in 23% of patients with liver cirrhosis and is caused by abnormally high levels of serum estradiol, which typically is metabolized by the liver (Serrao, Zirwas, & English, 2007). Another cutaneous manifestation of chronic liver disease, spider angioma, also is believed to result from elevated serum estradiol levels. Spider angiomas usually appear on the trunk and consist of a central arteriole from which radiate numerous small branching vessels. Pruritus is another fairly common symptom of hepatobiliary disease. It may or may not be associated with jaundice. It is believed that pruritus is caused by a build-up of bile acid and its derivatives (Khopkar & Pande, 2007). Jaundice can occur when the liver is stressed or damaged from either acute injury or chronic disease, such as hepatitis or cirrhosis. Jaundice results when bilirubin is produced in excess or when the liver is unable to excrete circulating bilirubin into the intestinal tract. As a result, bilirubin continues to circulate throughout the body and eventually is deposited into tissue and skin.

Autoimmune disorders such as systemic lupus erythematosus (SLE) and rheumatoid arthritis also can affect overall skin, joint, and soft-tissue health. Symptoms from autoimmune disease may vary over time and from patient to patient. Inflammation resulting from the autoimmune response leads to arthralgia and swollen joints. The dermatologic manifestations of SLE include (Myers & Allen, 2001)

- Butterfly rash
- Photosensitivity
- Mucosal ulcers
- Alopecia
- Pruritus
- Bruising.

Although not a disease state but rather a symptom of many disease states, peripheral neuropathy can predispose one to skin ulceration. Peripheral neuropathy is the end result of peripheral, motor, sensory, and autonomic neuron damage. Peripheral neuropathy can be categorized into three different types. The first is acquired—caused by environmental factors such as illness (including diabetes, renal disease, and nutritional deficiencies), infection, trauma, or chemical absorption, including chemotherapy-induced. The other two types are hereditary and idiopathic. The chemotherapeutic agents most frequently associated with peripheral neuropathy are platinum compounds, taxanes, vinca alkaloids, thalidomide, and bortezomib. Peripheral neuropathy can progress to *polyneuropathy* when numerous peripheral nerves become damaged or malfunction. Patients with chronic

polyneuropathy may lose the ability to sense temperature and pain, often resulting in thermal burns or open wounds from prolonged pressure or friction (Cavaletti & Zanna, 2002; Visovsky, Collins, Abbott, Aschenbrenner, & Hart, 2007).

Patients with diabetes mellitus, in addition to having peripheral neuropathy, are at further risk for wound ulceration caused by atherosclerosis of the arteries and capillary system. Atherosclerosis prevents adequate transfer of oxygen and nutrients between the vascular system and surrounding tissues, leading to an ischemic state, which increases the likelihood of tissue breakdown. Patients with diabetes also frequently have inadequate collateral circulation to compensate for existing diseased vasculature (Mousley, 2007).

Impaired Wound Healing in Non-Comorbid Disease

In addition to comorbid disease, a number of variables influence one's ability to heal. These variables include those on which one can exert influence, such as nutrition, tobacco use, and, to some degree, body type and psychological distress. Other variables that are not completely within one's control but can certainly influence overall skin health and ability to heal include age, immune response, and the presence of foreign matter.

Age

With advanced age come increased chances of developing diabetes, cardiovascular disease, rheumatoid arthritis, and a number of other medical ailments that leave one susceptible to altered skin and delayed wound healing. In addition, as age increases, physical changes occur in the structure of the dermis and at the dermal-epidermal junction. These changes alter the appearance of the skin and predispose one to partial-thickness skin injuries, such as lateral skin tears (Gosain & DiPietro, 2004). Aging also results in a gradual decrease in the production of collagen and elastin, resulting in fine wrinkles, thinning of the skin, and loss of underlying fat (Pittman, 2007). Lastly, the three phases of healing, as previously discussed in this chapter, exhibit characteristic changes with aging. Decreased levels of growth factors, diminished cell proliferation and migration, and diminished extracellular matrix secretion have been demonstrated (Gosain & DiPietro). Detailed information regarding skin and healing issues in older adult patients with cancer can be found in Chapter 15.

Nutrition

Individuals with certain types of cancer are at increased risk for malnutrition. Those with Hodgkin lymphoma and cancers of the upper respiratory and digestive tracts are at increased risk for weight loss and malnutrition

from disease state, mechanical obstruction, and physiologic dysfunction resulting from local tumor progression (Bloch & Charuhas, 2002). Additionally, all cancer therapies can cause nutritional deficiencies, the degree of which depends on the area of treatment, type of treatment, number of therapeutic modalities utilized, dosage of therapy, and length of treatment (Cunningham & Huhmann, 2005).

Nutrition has long been examined as a variable in postoperative wound healing. A significant amount of literature supports this, with numerous studies reporting on the negative effects of poor nutrition, or malnourishment, in patients who have undergone dental, orthopedic, and amputation procedures. In many cases, patients with decreased serum albumin levels, or those categorized as malnourished, did not fare as well when compared to nonmalnourished patients with regard to postamputation wounds and fractured hips (Foster, Heppenstall, Friedenber, & Hozack, 1990; Kay, Moreland, & Schmitter, 1987; Marin, Salido, Lopez, & Silva, 2002; Pedersen & Pedersen, 1992). For detailed information about nutrition and its impact on wound healing, refer to Chapter 13.

Smoking

The significance of smoking relates to the reduced ability of cells to reoxygenate during cancer treatment, as well as the adverse effects of nicotine on wound healing and cutaneous vasoconstriction (Wells & MacBride, 2003). Smoking has long been associated with a number of dermatologic conditions, such as poor wound healing, premature skin aging, squamous cell carcinoma, melanoma, oral cancer, psoriasis, and hair loss. Smoking also has an impact on the skin lesions observed in patients with diabetes and lupus. In vitro studies suggest that tobacco smoke impairs the production of collagen and increases the production of tropoelastin and matrix metalloproteinases, which degrade matrix proteins (Freiman, Bird, Metelitsa, Barankin, & Lauzon, 2004; Morita, 2007). Numerous studies have suggested a link between smoking and poor wound healing in the postoperative setting. Recently, Artioukh, Smith, and Gokul (2007) identified smoking as a risk factor for impaired perineal wound healing following resection for rectal carcinoma. Furthermore, patients who smoked while undergoing hyperbaric oxygen therapy for chronic wounds had a poor response, despite receiving treatment known to improve the healing potential of chronic wounds (Oubre, Roy, Toner, & Kalns, 2007).

Body Type

Obesity has been cited as a risk factor for many diseases and is known to increase the rate of complications following surgery. Obese patients are at risk for impaired mobility, which directly affects the likelihood of developing pressure ulcers. With extreme obesity comes the risk of lower extremity edema, thromboembolic disease, skin compression, fungal infections, and venous stasis ulcers (Gates, Davis, & Evans, 2005). Surgical wounds are more prone

to dehiscence and evisceration in obese patients because of increased tension on the edges of the fascia at the time of wound closure (Hahler, 2006). Derzie, Silvestri, Liriano, and Benotti (2000) reported a 15% postoperative complication rate among morbidly obese patients, including seroma formation, wound dehiscence, and wound infections. Obese patients were found to have higher rates of complications including flap loss, hematoma, delayed wound healing, and donor site hernia when compared to normal weight or overweight patients following transverse rectus abdominis myocutaneous flap reconstructions (Spear, Ducic, Cuoco, & Taylor, 2007).

Emaciated or extremely thin patients are also at risk for skin alterations or impaired wound healing. This may be partly because these individuals are malnourished and thus are at increased risk for a number of systemic complications. In addition, immobile patients with little or no body weight are at increased risk for pressure ulcers, particularly near a bony prominence.

Patients who have a stoma are at risk for skin excoriation or localized infection, usually candidal in nature. Factors leading to skin alterations secondary to stoma include improper anatomic location, appliance failure, or poor stoma care. A stoma should be constructed so that it is visible to the patient and located away from the umbilicus, skin creases, scars, and bony prominences. Areas damaged by radiation therapy or altered by skin grafts should be avoided. Localized skin irritations around the stoma can result from prolonged contact with fecal or urinary waste or from an allergic reaction to a portion of the appliance itself. Local skin care and patient or caregiver education usually resolve problems with ill-fitting appliances and poor hygiene practices (Lavery & Erwin-Toth, 2004; Minkes, McLean, Mazziotti, & Langer, 2008).

Infection/Immune Response

Open skin wounds do not have the protective defense mechanisms of intact skin, and all are colonized with microbial organisms. *Wound contamination* is defined as the presence of nonreplicating organisms within that wound. *Colonization* is defined as the presence of replicating microorganisms adherent to the wound in the absence of tissue damage. Colonization alone does not interfere with the wound healing process. In fact, chronic wounds support the existence of a diverse microbial flora. Subinfective levels of bacteria within a wound are important in determining the degree of inflammation and appear to accelerate wound healing and formation of granulation tissue, with increased infiltration of neutrophils, monocytes, and macrophages. Inflammation is a normal component of the immune response. However, an excessive inflammatory response can prolong the repair and healing process. A number of variables have been shown to influence whether colonizing wounds progress to wound infection and subsequently delay healing. These variables include the following (Bucknall, 1980; Davies et al., 2007; Dow, Browne, & Sib-

bald, 1999; Edwards & Harding, 2004; Konturek et al., 2001; Laato, Niinikoski, Lundberg, & Gerdin, 1988; Wysocki, 2002):

- Present bacteria level less than 10^5 per gram of tissue
- Virulence and pathogenicity of the organism
- Presence of four or more bacterial species in a given wound
- Ability of the host to mount an effective immune response.

The ability to mount an immune response is a key issue to the oncology patient population. Neutropenia and neutrophil dysfunction in conjunction with radiation therapy, steroids, and microvascular disease are found to predispose patients with cancer to bacterial infection and have been associated with delayed wound healing (Meuli et al., 2001). Many of the treatment regimens used in oncology can cause mild to severe neutropenia. A number of studies have examined rates of infection among neutropenic patients. Elihu and Gollin (2007) conducted a retrospective review of children with low absolute neutrophil counts and patients who had a central venous catheter inserted. This study reported that placement of a central venous catheter in neutropenic children was associated with substantial infectious morbidity and one death. However, a review of 18 published series in adults showed that neutropenia on the day of catheter insertion was not associated with infectious complications (Press, Ramsey, Larson, Fefer, & Hickman, 1984). This is contrary to the findings by Howell, Walters, Donowitz, and Farr (1995), who concluded that neutropenia was an independent risk factor for infection related to long-dwelling tunneled central venous catheters.

Marin et al. (2002) looked at patients outside of the oncology realm and examined those receiving a hip or knee prosthetic. The researchers reported that the patient's preoperative lymphocyte count (when less than 1,500 cells/mm³) was associated with a delay in postoperative wound healing.

Psychological Distress

Stress has a documented influence on the immune system. Chronic stress, in general, has immunosuppressive effects, whereas acute stress has stimulatory effects on immune function (Bauer-Wu & Post-White, 2005). People undergoing treatment for cancer not only have an altered immune system, but they often are also subject to feelings of psychological distress. Psychological stressors are experienced along the continuum of cancer, beginning prior to diagnosis, continuing through primary prevention activities to tertiary care strategies related to treatment, survivorship, and palliative care (Zichi-Cohen & Carlson, 2005). Studies performed outside the oncology population have demonstrated that acute psychological stress delays skin barrier function, recovery, and healing (Altemus, Rao, Dhabhar, Ding, & Granstein, 2001; Garg et al., 2001; Robles, 2007). Furthermore, depressive symptoms were also predictive of delayed mucosal wound healing in healthy young adults (Bosch, Engeland, Cacioppo, & Marucha, 2007). A detailed review of how psychological distress affects skin and wound healing is provided in Chapter 12.

Foreign Matter

Any material foreign to the body, once impregnated or retained within, can cause an acute reaction resulting in local and potentially systemic complications. If not removed, foreign objects can cause prolonged inflammation, infection, ulceration, fistula, and possibly necrosis. Foreign objects can include

- Debris (e.g., gravel, wood, glass) or shrapnel from a traumatic injury
- Ingestion of nonfood materials (e.g., magnets, coins, pins, small toys)
- A retained object from a surgical procedure (e.g., sponge, needles, instruments).

The medical literature is scattered with reports of retained surgical material from days, months, and even years after one's original date of surgery. Although many of these cases do not necessarily result in complications, some have resulted in nonhealing fistulous wounds, hematomas, obstructions, and abscess formation (Abdul-Karim, Benevenia, Pathria, & Makely, 1992; Gencosmanoglu & Inceoglu, 2003; Lone, Bhat, Tak, & Garcoo, 2005).

Occasionally, a foreign body such as a subcutaneous port, defibrillator, or pacemaker placed for therapeutic purposes may result in skin erosion or fistula tract formation (Camp-Sorrell, 2004; Kolker, Redstone, & Tutela, 2007; Nathan, Piccione, Kumar, Attanasio, & Schaer, 2006). Implantable subcutaneous ports, placed in the subclavicular area or in the arm used for chemotherapy administration and venous access, are known to erode through the skin surface. The incidence of this occurring is quite low, with only a handful of anecdotal cases reported (Almhanna, Pelley, Budd, Davidson, & Moore, 2008; Camp-Sorrell, 2004; Lersch et al., 1999). Port erosion can occur as a result of wound dehiscence, repeated access in the same location, loss of viable tissue over the portal body, and poor healing of the wound insertion site. In addition, the frequent use of topical anesthetic sprays, such as ethyl chloride, can be a cause of skin breakdown (Beheshti et al., 1998; Camp-Sorrell, 1992; Lersch et al.; Moureau & Zonderman, 2000; Whitman, 1996).

Paradigm of Support for Wound Healing

As with any adverse or damaging effect, an underlying cause must be recognized and stopped before complete repair and healing can begin. The medical literature has identified a number of factors that inhibit wound healing. Most are in some way related to external trauma (including radiation or chemical burns) or pressure, vascular insufficiency, infection, comorbid disease, or adverse effects of medication or treatment. It is perceivable that removal of the causative factor may not always be possible (e.g., with permanent edema, chronic disease, incurable malignancy) and, thus, complete healing may never occur or may occur on a very gradual basis over a prolonged period of time. However, in most cases, even chronic wounds can be healed given adequate nutrition and aggressive intervention.

Keast and Orsted (1998) proposed the following three fundamental principles that underlie wound care:

- Identification and, if possible, control of underlying causes
- Support of patient-centered concerns
- Optimization of local wound care.

The identification and control of underlying causes is relatively self-explanatory and includes removing environmental causes of injury and minimizing the impact of comorbid factors. Support of patient-centered concerns entails including patients in the plan of care and gaining their support for that plan and each specific intervention. It also means being cognizant of any quality-of-life issues that may exist, such as difficulty with transportation for clinic visits, financial burdens, or acute or chronic pain that can affect one's degree of fatigue, compliance, and, possibly, nutritional status. Consideration should be given to any cultural influences that may affect wound care and management. Optimization of local wound care involves appropriate utilization of myriad medications, dressings, and treatment techniques that exist. For specific interventions and wound care products, see Chapters 5 and 11.

McNees (2006) suggested the following five basic factors that guide the wound management process.

- If indicated, gentle cleansing of the wound using products supported by evidence-based research. Specific products known to impede wound healing should be avoided.
- If necrotic tissue is present, debridement by autolytic, enzymatic, or surgical means is to be strongly considered. *Autolytic debridement* involves the degradation and dissipation of devitalized tissues by using naturally occurring body fluids and enzymes from within the wound itself. This method requires a moist wound environment, thus often requiring some type of primary or cover dressing over the existing wound. *Enzymatic debridement* involves the addition of selective enzymes to the wound so as to expedite debridement. *Surgical debridement* involves the expeditious and manual surgical removal of devitalized tissue. When necrotic tissue is infected, surgical debridement should be a strong consideration.
- Caregivers should assess for factors that might impede or prevent healing, such as tunneled sinus tracts or calloused or rolled wound edges.
- If a wound cavity exists, the defect should be filled with a primary dressing including foam, hydrofibers, or gels, depending on the indication for each.
- Wounds should be covered, regardless of whether a cavity is present. Most wounds can be adequately covered with a moisture-retentive dressing. Highly exudative wounds may necessitate an absorbent dressing.

More recently Knox, Datiashvili, and Granick (2007) proposed that two parallel yet divergent management systems for chronic wounds have evolved. The medical approach uses a variety of dressings, topical enzymes, and local and systemic medications, including antibiotics, to promote healing by secondary intention or by optimizing the wound for subsequent surgical reconstruction. Medical management consists of using debridement techniques

similar to those described by McNees (2006) as well as mechanical debridement or biologic therapy. Mechanical debridement includes the use of traditional wet-to-dry gauze dressings to essentially tear necrotic tissue from the wound, which, at times, can be quite painful. Furthermore, this technique randomly removes areas of necrotic tissue as well as tissue needed for granulation, thus resulting in tissue reinjury. Additionally, maintenance of a traditional moist gauze dressing requires changing it two to three times daily. Lawrence (1994) demonstrated that bacteria were capable of infiltrating up to 64 layers of gauze. Thus, the efficacy of mechanical debridement via dressing changes has been questioned.

Biologic therapy involves application of blow-fly maggots (*Phaenicia sericata*) directly to the wound surface. This type of intervention can be an effective debridement method, especially for patients whose medical comorbidities preclude surgical intervention. Maggots secrete an enzyme that acts to dissolve necrotic tissue into a nutrient-rich food source while sparing normal, healthy tissue. The debridement process itself is painless, but some patients feel the movement of the larvae. Although effective, the use of maggots for wound debridement and subsequent healing has a powerful psychosocial effect on some and therefore may not be utilized (Attinger et al., 2006; Courtenay, Church, & Ryan, 2000; Knox et al., 2007).

The surgical management of chronic wounds, as proposed by Knox et al. (2007), has remained the gold standard. Early surgical intervention is used to prepare the wound for reconstruction in a timely manner while promoting the healing process. Surgical debridement is the most efficient means of wound bed preparation by minimizing the bioburden of the wound. Necrotic tissue serves as a substrate for bacteria, which compete for the same nutrients and oxygen required for wound healing. Therefore, it is imperative that necrotic, insensate, nonblanching, nonbleeding skin be excised without delay. Such tissue is continually removed until definitive bleeding occurs from within the dermis. Subcutaneous tissue should be removed until shiny yellow fat is present. Once the wound bed is sufficiently prepared through surgical debridement, further healing can proceed by means of topical therapy with dressings or negative pressure therapy. The ultimate form of surgical debridement, amputation, is reserved for digits and limbs that are no longer viable or not functionally salvageable (Barrett & Herndon, 2003; Knox et al.).

The medical and nursing literature contains numerous proposals for chronic and acute wound management and countless anecdotal reports of wound care techniques, dressings, and topical therapy. Unfortunately, significant variations regarding chronic wound management, despite evidence-based recommendations, have been reported (Jones, Fennie, & Lenihan, 2007). Upon a general review of the wound management literature, consistent themes emerge and include some or all of the following.

- Cleansing of an open wound and, if necessary, removal of any foreign bodies present within
- Use of topical and/or systemic antibiotics

- Pain management
- Debridement of excessive amounts of necrotic, nonviable tissue
- Use of supportive topical therapy, including suspensions, colloids, and gelatinous agents that assist in the healing and debridement process
- Use of moisture-retentive dressings to contain most wounds that are not heavily exudative
- Use of vacuum-assisted closure technology
- Compression therapy, if appropriate
- Improved nutritional intake

Evidence-based complementary and alternative therapies also deserve consideration, as well as novel approaches, such as the use of growth factors and stem cells. However, caregivers must use extreme caution if implementing these interventions in the oncology patient population. For specialized wound management, interventions such as radiation therapy, topical chemotherapy, phototherapy, and hyperbaric oxygenation are available.

Conclusion

The skin, its accessory organs, and the soft tissue beneath its surface comprise a detailed and interrelated network that serves to protect, regulate, and support humans throughout the life span. Under normal, healthy conditions, the skin has an amazing ability to heal and regenerate. The healing process is a complex mechanism that involves hemostasis and the initiation of an immune response, collagen synthesis and the production of granulation tissue, and maturation or remodeling of the area of injury. Interventions for acute and chronic wound management are meant to supplement or expedite the normal healing process. Comorbid disease, individual risk factors, or treatment for malignancy can compromise normal healing. At times, this may result in infection, radical surgical intervention, or the need for chronic wound management.

Chronic wound care can result in significant anxiety for patients and caregivers. In addition to concerns for the patient's obvious physical state of health, provisions must be made for ongoing medical and nursing support, such as outpatient or home care, and for financial aspects related to chronic wound management, such as medical care, supplies, and lost wages. Depending on the type and severity of the wound, psychosocial issues may arise related to feeling ill, disabled, isolated, or disfigured or having a highly odiferous wound. In such cases, the multidisciplinary team caring for this patient population should involve behavioral medicine and social services.

Just as every patient is an individual with an individualized plan of care, so too are skin ailments and chronic nonhealing wounds. Careful assessment is important to ascertain contributing factors to the patient's condition such as comorbid disease, the type of treatment received, or patient-specific considerations, such as the location of one's stoma, surgical wound, skin crease or fold, or position of an implantable device. Patients and practitioners should

agree upon an individualized treatment plan in an effort to achieve maximal healing potential. In some cases, this may require allowing the patient's skin or wound to gradually heal itself or preparing the site for intensive surgical and medical intervention.

References

- Abdul-Karim, F.W., Benevenia, J., Pathria, M.N., & Makley, J.T. (1992). Case report 736: Retained surgical sponge (gossypiboma) with a foreign body reaction and remote and organizing hematoma. *Skeletal Radiology*, *21*(7), 466–469.
- Almhanna, K., Pelley, R.J., Budd, G.T., Davidson, J., & Moore, H.C. (2008). Subcutaneous implantable venous access device erosion through the skin in patients treated with anti-vascular endothelial growth factor therapy: A case series. *Anticancer Drugs*, *19*(2), 217–219.
- Altemus, M., Rao, B., Dhabhar, F.S., Ding, W., & Granstein, R.D. (2001). Stress-induced changes in skin barrier function in healthy women. *Journal of Investigations in Dermatology*, *117*(2), 309–317.
- Archambeau, J.O., Pezner, R., & Wasserman, T. (1995). Pathophysiology of irradiated skin. *International Journal of Radiation Oncology, Biology, Physics*, *31*(5), 1171–1185.
- Artioukh, D.Y., Smith, R.A., & Gokul, K. (2007). Risk factors for impaired healing of the perineal wound after abdominoperineal resection of rectum for carcinoma. *Colorectal Disease*, *9*(4), 362–367.
- Attinger, C.E., Janis, J.E., Steinberg, J., Schwartz, J., Al-Attar, A., & Couch, K. (2006). Clinical approach to wounds: Debridement and wound bed preparation including the use of dressing and wound healing adjuvants. *Plastic and Reconstructive Surgery*, *117*(Suppl. 7), 72S–109S.
- Azria, D., Magne, N., Zouhair, A., Castadot, P., Culine, S., Ychou, M., et al. (2005). Radiation recall: A well recognized but neglected phenomenon. *Cancer Treatment Reviews*, *31*(7), 555–570.
- Balasubramani, M., Kumar, T.R., & Babu, M. (2001). Skin substitutes: A review. *Burns*, *27*(5), 534–544.
- Barrett, J.P., & Herndon, D.N. (2003). Effect of burn wound excision on bacterial colonization and invasion. *Plastic and Reconstructive Surgery*, *111*(2), 751–752.
- Bauer-Wu, S.M., & Post-White, J. (2005). Immunology. In C.H. Yarbro, M.H. Frogge, & M. Goodman (Eds.), *Cancer nursing: Principles and practice* (6th ed., pp. 26–39). Sudbury, MA: Jones and Bartlett.
- Beheshti, M.V., Protzer, W.R., Tomlinson, T.L., Martinek, E., Baatz, L.A., & Collins, M.S. (1998). Long-term results of radiologic placement of a central venous access device. *American Journal of Roentgenology*, *170*(3), 731–734.
- Bloch, A., & Charuhas, P. (2002). Cancer and cancer therapy. In M.M. Gottschlich (Ed.), *The science and practice of nutrition support: A case-based core curriculum* (pp. 643–661). Dubuque, IA: Kendall/Hunt.
- Bosch, J.A., Engeland, C.G., Cacioppo, J.T., & Marucha, P.T. (2007). Depressive symptoms predict mucosal wound healing. *Psychosomatic Medicine*, *69*(7), 597–605.
- Bucknall, T.E. (1980). The effect of local infection upon wound healing: An experimental study. *British Journal of Surgery*, *67*(12), 851–855.
- Camp-Sorrell, D. (1992). Implantable ports: Everything you always wanted to know. *Journal of Intravenous Nursing*, *15*(5), 262–273.
- Camp-Sorrell, D. (2004). Implanted ports: Skin erosion. *Clinical Journal of Oncology Nursing*, *8*(3), 309–310.
- Camp-Sorrell, D. (2005). Chemotherapy toxicities and management. In C.H. Yarbro, M.H. Frogge, & M. Goodman (Eds.), *Cancer nursing: Principles and practice* (6th ed., pp. 412–457). Sudbury, MA: Jones and Bartlett.

- Cavaletti, G., & Zanna, C. (2002). Current status and future prospects for the treatment of chemotherapy-induced peripheral neurotoxicity. *European Journal of Cancer*, 38(14), 1832–1837.
- Chiao, T.B., & Lee, A.J. (2005). Role of pentoxifylline and vitamin E in attenuation of radiation induced fibrosis. *Annals of Pharmacotherapy*, 39(3), 516–521.
- Courtenay, M., Church, J.C., & Ryan, T.J. (2000). Larva therapy in wound management. *Journal of the Royal Society of Medicine*, 93(2), 72–74.
- Cunningham, R.S., & Huhmann, M.B. (2005). Nutritional disturbances. In C.H. Yarbro, M.H. Frogge, & M. Goodman (Eds.), *Cancer nursing: Principles and practice* (6th ed., pp. 761–790). Sudbury, MA: Jones and Bartlett.
- Davies, C.E., Hill, K.E., Newcombe, R.G., Stephen, P., Wilson, M.J., Harding, K.G., et al. (2007). A prospective study of the microbiology of chronic venous leg ulcers to reevaluate the clinical predictive value of tissue biopsies and swabs. *Wound Repair and Regeneration*, 15(1), 17–22.
- Derzie, A.J., Silvestri, F., Liriano, E., & Benotti, P. (2000). Wound closure technique and acute wound complications in gastric bypass surgery for morbid obesity: A prospective randomized trial. *Journal of the American College of Surgeons*, 191(3), 238–243.
- D’Haese, S., Bate, R., Claes, S., Boone, A., Vanvoorden, V., & Efficace, F. (2005). Management of skin reactions during radiotherapy: A study of nursing practice. *European Journal of Cancer Care*, 14(1), 28–42.
- Dow, G., Browne, A., & Sibbald, R.G. (1999). Infection in chronic wounds: Controversies in diagnosis and treatment. *Ostomy/Wound Management*, 45(8), 23–40.
- Edwards, R., & Harding, K.G. (2004). Bacteria and wound healing. *Current Opinion in Infectious Disease*, 17(2), 91–96.
- Eich, D., Scharffetter-Kochanek, K., Eich, H.T., Tantcheva-Poor, I., & Krieg, T. (2002). Acral erythrodysesthesia syndrome caused by intravenous infusion of docetaxel in breast cancer. *American Journal of Clinical Oncology*, 25(6), 599–602.
- Elihu, A., & Gollin, G. (2007). Complications of implanted central venous catheters in neutropenic children. *American Surgeon*, 73(10), 1079–1082.
- Englert, K. (2003). Stasis dermatitis in the patient with CHF. *Dermatology Nursing*, 15(6), 552.
- Foster, M.R., Heppenstall, R.B., Friedenber, Z.B., & Hozack, W.J. (1990). A prospective assessment of nutritional status and complications in patients with fractures of the hip. *Journal of Orthopedic Trauma*, 4(1), 49–57.
- Freiman, A., Bird, G., Metelitsa, A.I., Barankin, B., & Lauzon, G.J. (2004). Cutaneous effects of smoking. *Journal of Cutaneous Medicine and Surgery*, 8(6), 415–423.
- Garg, A., Chren, M., Sands, L.P., Matsui, M.S., Marenus, K.D., Feingold, K.R., et al. (2001). Psychosocial stress perturbs epidermal permeability barrier homeostasis. *Archives of Dermatology*, 137(1), 53–59.
- Gates, J., Davis, J.M., & Evans, E. (2005). Venous stasis ulcers in the patient who is obese. *Journal of Wound, Ostomy, and Continence Nursing*, 32(6), 421–426.
- Gencosmanoglu, R., & Inceoglu, R. (2003, September 8). An unusual case of small bowel obstruction: Gossypiboma-case report. *BMC Surgery*, 3, 6.
- Gosain, A., & DiPietro, L.A. (2004). Aging and wound healing. *World Journal of Surgery*, 28(3), 321–326.
- Haas, M.L. (2005). Skin reactions. In D.W. Bruner, M.L. Haas, & T.K. Gosselin-Acomb (Eds.), *Manual for radiation oncology nursing practice and education* (3rd ed., pp. 49–52). Pittsburgh, PA: Oncology Nursing Society.
- Hahler, B. (2006). An overview of dermatological conditions commonly associated with the obese patient. *Ostomy/Wound Management*, 52(6), 34–36, 38, 40.
- Headley, C.M., & Wall, B. (2002). ESRD-associated cutaneous manifestations in a hemodialysis population. *Journal of Nephrology Nursing*, 29(6), 525–527, 531–539.
- Holcomb, S.S. (2006). Identification and treatment of different types of lymphedema. *Advances in Skin and Wound Care*, 19(2), 103–108.
- Howell, P.B., Walters, P.E., Donowitz, G.R., & Farr, B.M. (1995). Risk factors for infection of adult patients with cancer who have tunneled central venous catheters. *Cancer*, 15(6), 1367–1375.

- Jaff, M.R. (2001). Severe peripheral arterial disease and critical limb ischemia: Incidence, pathophysiology, presentation, methods of diagnosis. In A.T. Hirsch (Ed.), *Primary care series: Peripheral arterial disease and intermittent claudication* (pp. 53–58). Bridgewater, NJ: Excerpta Medica.
- Johnson, R.M., & Richard, R. (2003). Partial-thickness burns: Identification and management. *Advances in Skin and Wound Care*, 16(4), 178–189.
- Jones, K.R., Fennie, K., & Lenihan, A. (2007). Evidence-based management of chronic wounds. *Advances in Skin and Wound Care*, 20(11), 591–600.
- Kay, S.P., Moreland, J.R., & Schmitter, E. (1987, April). Nutritional status and wound healing in lower extremity amputations. *Clinical Orthopaedics and Related Research*, 217, 253–256.
- Keast, D.H., & Orsted, H. (1998). The basic principles of wound care. *Ostomy/Wound Management*, 44(8), 24–31.
- Khopkar, U., & Pande, S. (2007). Etiopathogenesis of pruritus due to systemic causes. *Indian Journal of Dermatology, Venereology, and Leprology*, 73(4), 215–217.
- Knox, K.R., Datiashvili, R.O., & Granick, M.S. (2007). Surgical wound bed preparation of chronic and acute wounds. *Clinics in Plastic Surgery*, 34(4), 633–641.
- Kolker, A.R., Redstone, J.S., & Tutela, J.P. (2007). Salvage of exposed implantable cardiac electrical devices and lead systems with pocket change and local flap coverage. *Annals of Plastic Surgery*, 59(1), 26–29.
- Konturek, P.C., Brzozowski, T., Konturek, S.J., Kwicien, S., Dembinski, A., & Hahn, E.G. (2001). Influence of bacterial lipopolysaccharide on healing of chronic experimental ulcer in rat. *Scandinavian Journal of Gastroenterology*, 36(12), 1239–1247.
- Laato, M., Niinikoski, J., Lundberg, C., & Gerdin, B. (1988). Inflammatory reaction and blood flow in experimental wounds inoculated with *Staphylococcus aureus*. *European Surgical Research*, 20(1), 33–38.
- Lavery, I.C., & Erwin-Toth, P. (2004). Stoma therapy. In A.A. Cataldo & J.M. MacKeigan (Eds.), *Intestinal stomas: Principles, techniques, and management* (2nd ed., pp. 65–90). New York: Marcel Dekker.
- Lawenda, B.D., Mondry, T.E., & Johnstone, P.A. (2009). Lymphedema: A primer on the identification and management of a chronic condition in oncologic treatment. *CA: A Cancer Journal for Clinicians*, 59(1), 8–24.
- Lawrence, J.C. (1994). Dressings and wound infection. *American Journal of Surgery*, 167(Suppl. 1A), 21S–24S.
- Lersch, C., Eckel, F., Sader, R., Paschalidis, M., Zeilhofer, F., Schulte-Frohlinde, E., et al. (1999). Initial experience with Healthport miniMax[®] and other peripheral arm ports in patients with advanced gastrointestinal malignancy. *Oncology*, 57(4), 269–275.
- Lone, G.N., Bhat, A.H., Tak, M.Y., & Garcoo, S.A. (2005). Transdiaphragmatic migration of forgotten gauze sponge: An unreported entity of lung abscess. *European Journal of Cardiothoracic Surgery*, 28(2), 355–357.
- Maher, K.E. (2005). Radiation therapy: Toxicities and management. In C.H. Yarbro, M.H. Frogge, & M. Goodman (Eds.), *Cancer nursing: Principles and practice* (6th ed., pp. 283–314). Sudbury, MA: Jones and Bartlett.
- Marieb, E.N. (2001). *Human anatomy and physiology* (5th ed.). San Francisco: Benjamin Cummings.
- Marin, L.A., Salido, J.A., Lopez, A., & Silva, A. (2002). Preoperative nutritional evaluation as a prognostic tool for wound healing. *Acta Orthopaedica Scandinavica*, 73(1), 2–5.
- Marrs, J. (2007). Lymphedema and implications for oncology nursing practice. *Clinical Journal of Oncology Nursing*, 11(1), 19–21.
- Martin, K.J., Gonzalez, E.A., & Slatopolsky E. (2004). Renal osteodystrophy. In B.M. Brenner (Ed.), *Brenner & Rector's the kidney* (7th ed., Vol. 2, pp. 2255–2304). Philadelphia: Saunders.
- McNees, P. (2006). Skin and wound assessment and care in oncology. *Seminars in Oncology Nursing*, 22(3), 130–143.

- Meuli, M., Liu, Y., Liggitt, D., Kashani-Sabet, M., Knauer, S., Meuli-Simmen, C., et al. (2001). Efficient gene expression in skin wound sites following local plasmid injection. *Journal of Investigative Dermatology*, *116*(1), 131–135.
- Minkes, R.K., McLean, S.E., Mazziotti, M.V., & Langer, J.C. (2008, October). *Stomas of the small and large intestine*. Retrieved February 5, 2009, from <http://www.emedicine.com/ped/topic2994.htm>
- Morgan, E.D., Bledsoe, S.C., & Barker, J. (2000). Ambulatory management of burns. *American Family Physician*, *62*(9), 2015–2026, 2029–2030, 2032.
- Morita, A. (2007). Tobacco smoke causes premature skin aging. *Journal of Dermatology Science*, *48*(3), 169–175.
- Moureau, N., & Zonderman, A. (2000). Does it always have to hurt? Premedications for adults and children for use with intravenous therapy. *Journal of Intravenous Nursing*, *23*(4), 213–219.
- Mousley, M. (2007). Understanding diabetic foot ulcers. 1: Pathophysiology. *Nursing Times*, *103*(31), 28–29.
- Murray, J.F. (2000). History and physical examination. In J.F. Murray & J.A. Nadel (Eds.), *Textbook of respiratory medicine* (3rd ed., Vol. 1, pp. 585–605). Philadelphia: Saunders.
- Myers, S.A., & Allen, M.H. (2001). Cutaneous manifestations of lupus: Can you recognize them all? *Women's Health in Primary Care*, *4*(1), 71–83.
- Nathan, S., Piccione, W., Kumar, A., Attanasio, S., & Schaefer, G.L. (2006). Erosion of an extrapericardial implantable cardioverter defibrillator patch through the gastric fundus with fistulous tract formation. *Cardiology Review*, *14*(6), e21–e23.
- Oishi, K. (2008). Clinical approaches to minimize rash associated with EGFR inhibitors. *Oncology Nursing Forum*, *35*(1), 103–111.
- Oubre, C.M., Roy, A., Toner, C., & Kalns, J. (2007). Retrospective study of factors affecting non-healing of wounds during hyperbaric oxygen therapy. *Journal of Wound Care*, *16*(6), 245–250.
- Pearce, J.D. (2005). Alterations in mobility, skin integrity, and neurologic status. In J.K. Itano & K.N. Taoka (Eds.), *Core curriculum for oncology nursing* (4th ed., pp. 245–258). St. Louis, MO: Elsevier Saunders.
- Pedersen, N.W., & Pedersen, D. (1992). Nutrition as a prognostic indicator in amputations. A prospective study of 47 cases. *Acta Orthopaedica Scandinavica*, *63*(6), 675–678.
- Perez-Soler, R., & Saltz, L. (2005). Cutaneous adverse effects with HER1/EGFR-targeted agents: Is there a silver lining? *Journal of Clinical Oncology*, *23*(22), 5235–5246.
- Pittman, J. (2007). Effect of aging on wound healing. *Journal of Wound, Ostomy, and Continence Nursing*, *34*(4), 412–415.
- Porock, D., & Kristjanson, L. (1999). Skin reactions during radiotherapy for breast cancer: The use and impact of topical agents and dressings. *European Journal of Cancer Care*, *8*(3), 143–153.
- Porock, D., Kristjanson, L., Nikolett, S., Cameron, F., & Pedler, P. (1998). Predicting the severity of radiation skin reactions in women with breast cancer. *Oncology Nursing Forum*, *25*(6), 1019–1029.
- Press, O.W., Ramsey, P.G., Larson, E.B., Fefer, A., & Hickman, R.O. (1984). Hickman catheter infections in patients with malignancies. *Medicine*, *63*(4), 189–200.
- Remlinger, K.A. (2003). Cutaneous reactions to chemotherapy drugs. *Archives of Dermatology*, *139*(1), 77–81.
- Robbins, M.A. (2007). Nonmalignant tumors. In M.L. Haas, W.P. Hogle, G.J. Moore-Higgs, & T.K. Gosselin-Acomb (Eds.), *Radiation therapy: A guide to patient care* (pp. 319–324). St. Louis, MO: Mosby.
- Robles, T. (2007). Stress, social support, and delayed skin barrier recovery. *Psychosomatic Medicine*, *69*(8), 807–815.
- Romo, T., III, Pearson, J.M., Yalanchili, H., & Zoumalan, R.A. (2008, February 18). *Wound healing. skin*. Retrieved February 5, 2009, from <http://www.emedicine.com/ent/topic13.htm>

- Serrao, R., Zirwas, M., & English, J.C. (2007). Palmar erythema. *American Journal of Clinical Dermatology*, 8(6), 347–356.
- Shier, D., Butler, J., & Lewis, R. (2004). *Hole's human anatomy and physiology* (10th ed.). Boston: McGraw-Hill.
- Sparks, S.G. (2007). Radiodermatitis. In M.L. Haas, W.P. Hogle, G.J. Moore-Higgs, & T.K. Gosselin-Acomb (Eds.), *Radiation therapy: A guide to patient care* (pp. 511–522). St. Louis, MO: Mosby.
- Spear, S.L., Ducic, I., Cuoco, F., & Taylor, N. (2007). Effect of obesity on flap and donor-site complications in pedicled TRAM flap breast reconstruction. *Plastic and Reconstructive Surgery*, 119(3), 788–795.
- Visovsky, C., Collins, M., Abbott, L., Aschenbrenner, J., & Hart, C. (2007). Putting evidence into practice: Evidence-based interventions for chemotherapy-induced peripheral neuropathy. *Clinical Journal of Oncology Nursing*, 11(6), 901–913.
- Wells, M., & MacBride, S. (2003). Radiation skin reactions. In S. Faithful & M. Wells (Eds.), *Supportive care in radiotherapy* (pp. 135–159). Edinburgh, United Kingdom: Churchill Livingstone.
- Whitman, E. (1996). Complications associated with the use of central venous access devices. *Current Problems in Surgery*, 33(4), 311–378.
- Wysocki, A.B. (2002). Evaluating and managing open skin wounds: Colonization versus infection. *AACN Clinical Issues*, 13(3), 382–397.
- Zichi-Cohen, M., & Carlson, E. (2005). Cancer-related distress. In C.H. Yarbro, M.H. Frogge, & M. Goodman (Eds.), *Cancer nursing: Principles and practice* (6th ed., pp. 623–638). Sudbury, MA: Jones and Bartlett.