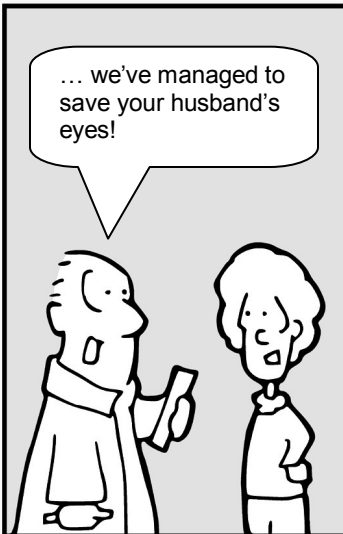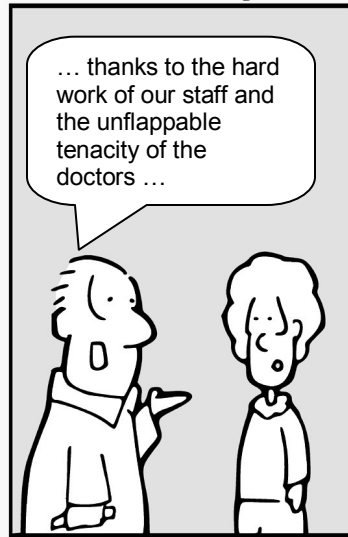

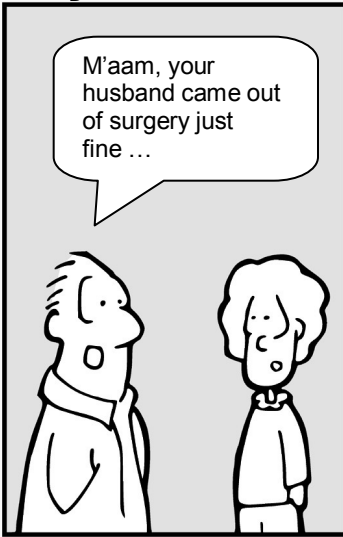
## Chapter 2

# Eye Anatomy

**The Eyes Have It**

**by Tim Root**



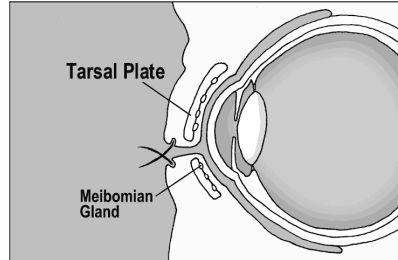
# Basic Eye Anatomy

by Tim Root, M.D.

Before discussing conditions affecting the eye, we need to review some basic eye anatomy. Anatomy can be a painful subject for some (personally, I hated anatomy in medical school), so I'm going to keep this simple. Let us start from the outside and work our way toward the back of the eye.

## Eyelids

The eyelids protect and help lubricate the eyes. The eyelid skin itself is very thin, containing no subcutaneous fat, and is supported by a **tarsal plate**. This tarsal plate is a fibrous layer that gives the lids shape, strength, and a place for muscles to attach.



Underneath and within the tarsal plate lie **meibomian glands**. These glands secrete oil into the tear film that keeps the tears from evaporating too quickly. Meibomian glands may become inflamed and swell into a granulomatous **chalazion** that needs to be excised. Don't confuse a chalazion with a sty. A **stye** is a pimple-like infection of a sebaceous gland or eyelash follicle, similar to a pimple, and is superficial to the tarsal plate. Styes are painful, while deeper chalazions are not.

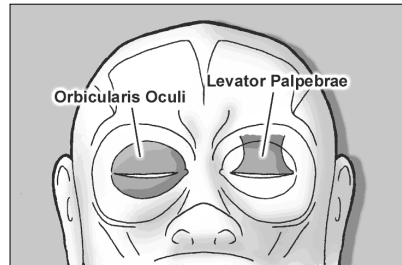
## Famous Quotes

You can't depend on your eyes when your imagination is out of focus.

*Mark Twain*

## Eyelid Movement

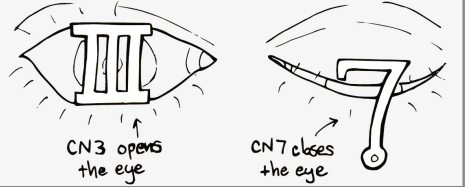
Two muscles are responsible for eyelid movement. The **orbicularis oculi** closes the eyelids and is innervated by cranial nerve 7. Patients with a facial nerve paralysis, such as with Bell's Palsy, can't close their eye and their eyelids may need to be patched (or sutured closed) to protect the cornea from exposure. The **levator palpebrae** opens the eye and is innervated by CN3. Oculomotor nerve (CN3) palsy is a major cause of ptosis



(drooping of the eye). In fact, a common surgical treatment for ptosis involves shortening the levator tendon to open up the eye.

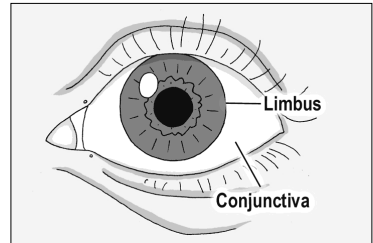
## Mnemonic

CN 3 opens the eye like a pillar  
CN 7 closes like a fish-hook



## Conjunctiva

The conjunctiva is a mucus membrane that covers the front of the eyeball. When you examine the “white part” of a patient’s eyes, you’re actually looking through the semi-transparent conjunctiva to the white sclera of the eyeball underneath. The conjunctiva starts at the edge of the cornea (this location is called the **limbus**). It then flows back behind the eye, loops forward, and forms the inside surface of the eyelids. The continuity of this conjunctiva is important, as it keeps objects like eyelashes and your contact lens from sliding back behind your eyeball. The conjunctiva is also lax enough to allow your eyes to move freely. When people get conjunctivitis, or “pink eye,” this is the tissue layer affected.

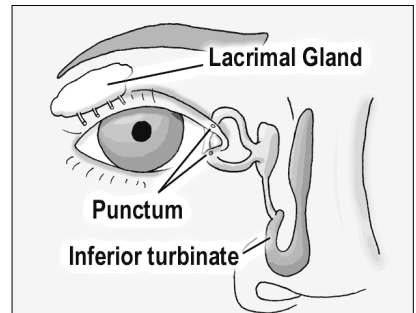


## Fun Fact

There is a thickened fold of conjunctiva called the semilunar fold that is located at the medial canthus ... it is a homolog of the nictitating membrane seen on sharks.

## Tear Production and Drainage

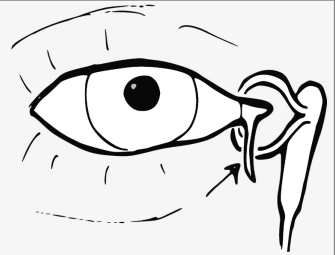
The majority of tears are produced by accessory tear glands located within the eyelid and conjunctiva. The lacrimal gland itself is really only responsible for reflexive tearing. Tears flow down the front of the eye and drain out small pores, called **lacrimal punctum**, which arise on the medial lids. These punctual holes are small, but can be seen with the naked eye.



After entering the puncta, tears flow down the lacrimal tubing and eventually drain into the nose at the inferior turbinate. This drainage pathway explains why you get a runny nose when you cry. In 2-5% of newborns, the drainage valve within the nose isn't patent at birth, leading to excessive tearing. Fortunately, this often resolves on its own, but sometimes we need to force open the nasolacrimal duct with a metal probe.

## Eyelid Lacerations

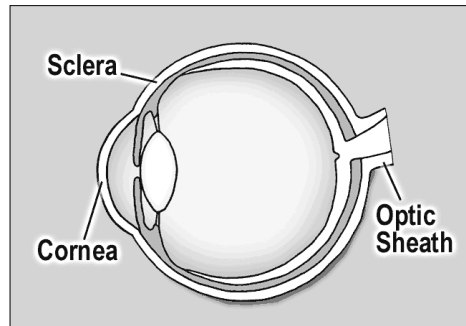
Most lacerations through the eyelid can be easily reapproximated and repaired. However, if a laceration occurs in the nasal quadrant of the lid you have to worry about compromising the canalicular tear-drainage pathway. Canalicular lacerations require cannulation with a silicone tube to maintain patency until the tissue has healed.



**Warning:** Drug absorption through the nasal mucosa can be profound as this is a direct route to the circulatory system and entirely skips liver metabolism. Eyedrops meant for local effect, such as beta-blockers, can have impressive systemic side effects when absorbed through the nose. Patients can decrease nasal drainage by squeezing the medial canthus after putting in eyedrops. They should also close their eyes for a few minutes afterwards because blinking acts as a tear pumping mechanism.

### The Eyeball:

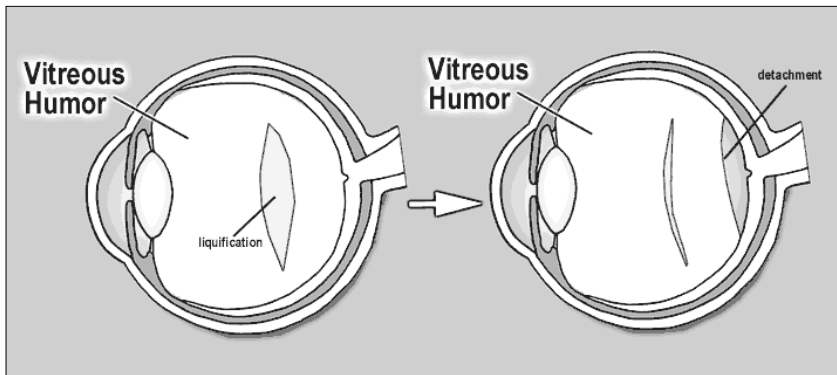
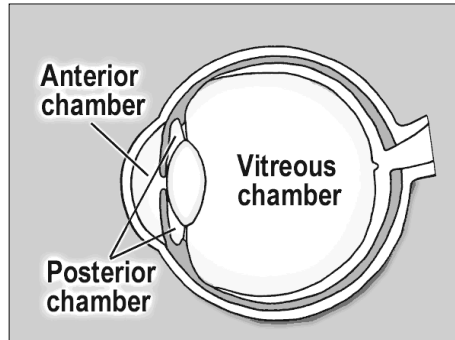
The eyeball itself is an amazing structure. It is only one inch in diameter, roughly the size of a ping-pong ball, and is a direct extension of the brain. The optic nerve is the only nerve in the body that we can actually see (using our ophthalmoscope) *in vivo*.



The outer wall of the eye is called the **sclera**. The sclera is white, fibrous, composed of collagen, and is actually continuous with the clear cornea anteriorly. In fact, you can think of the cornea as an extension of the sclera as they look similar under the microscope. The cornea is clear, however, because it is relatively dehydrated. At the back of the eye, the sclera forms the optic sheath encircling the optic nerve.

The eyeball is divided into three chambers, not two as you might expect. The **anterior chamber** lies between the cornea and the iris, the **posterior chamber** between the iris and the lens, and the **vitreous chamber** extends from the lens back to the retina.

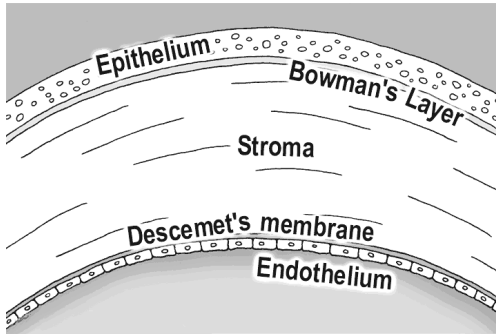
The eye is also filled with two different fluids. **Vitreous humor** fills the back vitreous chamber. It is a gel-suspension with a consistency similar to Jell-O. With age and certain degenerative conditions, areas of the vitreous can liquefy. When this occurs, the vitreous can fall in upon itself – usually a harmless event called a PVD (posterior vitreous detachment). However, this normally benign vitreous detachment can sometimes tug on the retina and create small retinal tears.



**Aqueous humor** fills the anterior and posterior chambers. This is a watery solution with a high nutrient component that supports the avascular cornea and lens. Aqueous is continuously produced in the posterior chamber, flowing forward through the pupil into the anterior chamber, where it drains back into the venous circulation via the Canal of Schlemm. We'll discuss the aqueous pathway in greater detail in the glaucoma chapter.

### The Cornea:

The **cornea** is the clear front surface of the eye. The cornea-air interface actually provides the majority of the eye's refractive power. The cornea is avascular and gets its nutrition from tears on the outside, aqueous fluid on the inside, and from blood vessels located at the peripheral limbus.



On cross section, the cornea contains five distinct layers. The outside surface layer is composed of epithelial cells that are easily abraded. Though epithelial injuries are painful, this layer heals quickly and typically does not scar. Under this lies Bowman's layer and then the stroma. The corneal stroma makes up 90% of the corneal thickness, and if the stroma is damaged this can lead to scar formation. The next layer is Descemet's membrane, which is really the basal lamina of the endothelium, the final inner layer.

The inner endothelium is only one cell layer thick and works as a pump to keep the cornea dehydrated. If the endothelium becomes damaged (during surgery or by degenerative diseases) aqueous fluid can flow unhindered into the stroma and cloud up the cornea with edema. Endothelial cell count is very important as these cells don't regenerate when destroyed – the surviving endothelial cells just get bigger and spread out. If the cell count gets too low, the endothelial pump can't keep up and the cornea swells with water, possibly necessitating a corneal transplant to regain vision.

## Mnemonic

To help you remember the corneal layers, you might use this trick:

**D**ecemet's membrane is **D**eep while  
**B**owman's layer is high up in the **B**ell tower

## The Uvea:

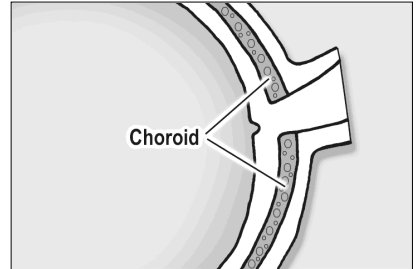
The iris, ciliary body, and the choroid plexus are all continuous with each other and are collectively called the **uvea**. This is an important term, as many people can present with painful "uveitis" - spontaneously or in association with rheumatologic diseases.

The **iris** is the colored part of the eye and its primary function is to control the amount of light hitting the retina. Sympathetic stimulation of the pupil leads to pupil dilation and parasympathetic stimulation leads to constriction. In other words, if you see a bear in the woods, your sympathetics kick in, and your eyes dilate so you can see as much as possible as you run away. I'll be

using this mnemonic/metaphor many times throughout this book to help you remember this concept.

The inner iris flows back and becomes the **ciliary body**. The ciliary body has two functions: it secretes aqueous fluid and it controls the shape of the lens. The ciliary body contains sphincter muscles that change the lens shape by relaxing the zonular fibers that tether to the lens capsule.

The **choroid** is a bed of blood vessels that lie right under the retina. The choroid supplies nutrition to the outer one-third of the retina which includes the rod and cone photoreceptors. Retinal detachments can separate the retina from the nutritious choroid, which is disastrous for the photoreceptors as they quickly die without this nourishment.



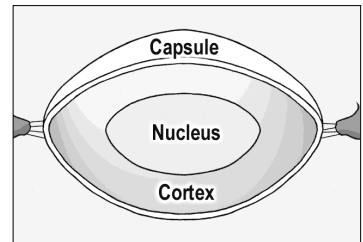
## Fun Fact

An ostrich's eye is larger than its brain.

## Lens:

The lens is a magnifying glass inside our eye that helps focus light. The lens sits behind the iris and is unique in that it doesn't have any innervation or vascularization. It gets its nourishment entirely from nutrients floating in the aqueous fluid. The lens also has the highest protein concentration of any tissue in the body (65% water, 35% protein).

Though the lens may look solid, it actually has three layers in a configuration similar to a peanut M&M. The outer layer is called the **capsule**. The capsule is thin with a consistency of saran wrap and holds the rest of the lens in place. The middle layer is called the **cortex**, while the central layer is the hard **nucleus**. Cataracts are described by where they occur - such as nuclear cataracts, cortical cataracts, and subcapsular cataracts. With cataract surgery the outer capsule is left behind and the artificial lens is placed inside this supporting bag.



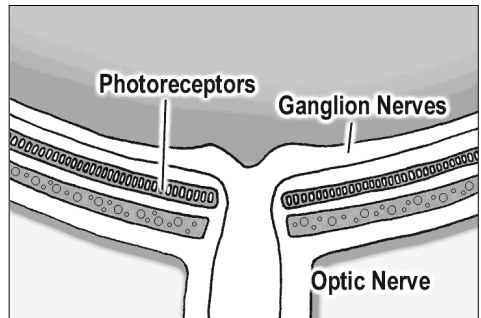
The capsule is held in place by suspensory ligaments called **zonules** that insert around the periphery and connect to the muscular ciliary body. Contraction of the ciliary muscle causes the zonule ligaments to *relax* (think

about that for a minute), allowing the lens to become rounder and increase its refracting power for close-up reading.

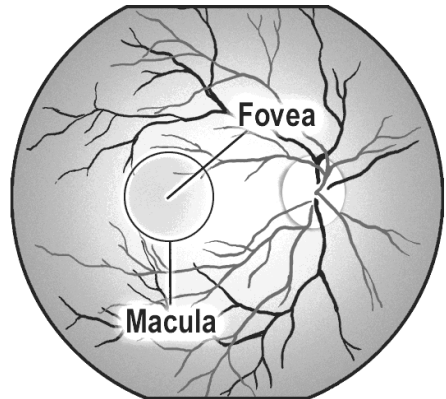
In children the lens is soft, but with age the lens hardens and becomes less pliable. After age 40 the lens starts having difficulty "rounding out" and people have problems focusing on near objects. This process is called presbyopia. Almost everyone over 50 needs reading glasses because of this hardening of the lens.

### The Retina:

The **retina** is the sensory portion of the eye and contains layers of photoreceptors, nerves, and supporting cells. Histologically, many cell layers can be seen, but they are not worth memorizing at this point. The important ones include the photoreceptor layer, which is located further out (towards the periphery), and the ganglion nerve layer which lies most inward (toward the vitreous). The key point here is that for light to reach the photoreceptor it has to pass through many layers. After light reaches the photoreceptors the visual signal propagates back up to the ganglion nerves. These ganglion nerves, in turn, course along the surface of the retina toward the optic disk and form the optic nerve running to the brain.



The **macula** is the pigmented area of the retina that is responsible for central vision. Within the central macula lies the **fovea**, which is a small pit that is involved with extreme central vision. The fovea is very thin and derives its nutrition entirely from the underlying choroid, making it especially susceptible to injury during retinal detachments.



The optic disk is the entry and exit point of the eye. The central retinal artery and vein pass through here, along with the the ganglion nerves that form the optic nerve. A physiologic divot or "cup" can be found here that will become important when we talk about glaucoma.

### The Orbital Walls:

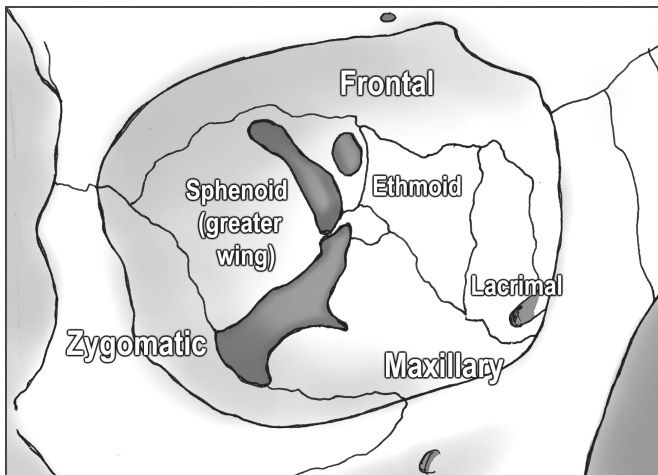
Seven different bones form the orbital walls. Don't be intimidated by this complexity, however, as these bones are not that confusing when you break them down. For example, the roof of the orbit is a continuation of the frontal



bone, the zygomatic bone forms the strong lateral wall, while the maxillary bone creates the orbital floor. This makes sense, and you could probably guess these bones from the surrounding anatomy.

The medial wall is a little more complex, however, but is mainly formed by the lacrimal bone (the lacrimal sac drains tears through this bone into the nose) and the ethmoid bone. The thinnest area in the orbit is a part of the ethmoid bone called the **lamina papyracea**. Sinus infections can erode through this “paper-thin wall” into the orbital cavity and create a dangerous orbital cellulitis.

Despite the fragility of the medial wall, it is well buttressed by surrounding bones and rarely fractures. The orbital *floor*, however, breaks most often during blunt trauma. The maxillary bone fractures downward and the orbital contents can herniate down into the underlying maxillary sinus. This is called a “blowout fracture” and can present with enophthalmia (a sunken-in eyeball) and problems with eye-movements from entrapment of the inferior rectus muscle. We’ll discuss blow-out fractures in more detail in the trauma chapter.



The back of the orbit is formed by the greater wing of the sphenoid bone, with the “lesser wing” surrounding the optic canal. There’s also a little palatine bone back there in the middle, but don’t worry about that one!

### **The Apex: Entrance into the Orbit**

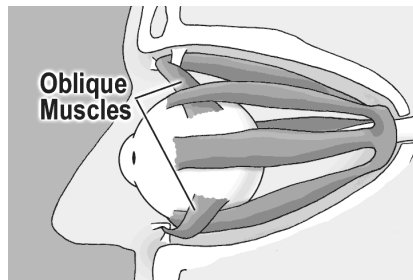
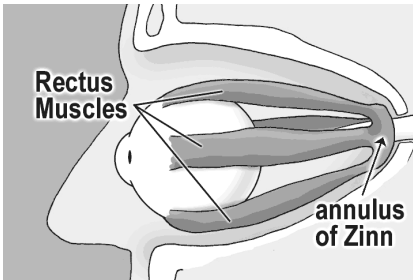
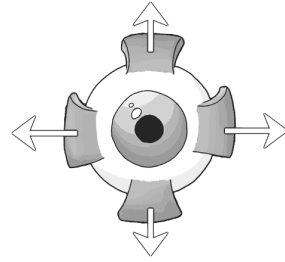
The orbital apex is the entry point for all the nerves and vessels supplying the orbit. The superior orbital fissure lies between the wings of the sphenoid bones, through which many vessels and nerves pass into the orbit.

The “Annulus of Zinn,” a muscular band that serves as the insertion point for most of the ocular muscles, rests on top of the superior orbital fissure. The four rectus muscles attach to the annulus and the optic nerve passes right through the middle.

## Eye Muscles:

Four **rectus muscles** control each eye. These muscles insert at the sclera, behind the limbus, and each pull the eye in the direction of their attachment.

The superior, medial, and inferior rectus muscles are all controlled by the oculomotor nerve (III). The lateral rectus, however, is controlled by the abducens (VI) nerve, which makes sense as the lateral rectus “abducts” the eye.



The remaining two eye muscles are the superior and inferior **oblique muscles**. The superior oblique also originates in the posterior orbit, but courses nasally until it reaches the trochlea (or "pulley") before inserting onto the eye. The inferior oblique originates from the orbital floor and inserts behind the globe near the macula. Because of these posterior insertions, the oblique muscles are primarily responsible for intorsion and extorsion (rotation of the eye sideways), though they also contribute some vertical gaze action.

Confused yet? Don't kill yourself learning the action of the oblique muscles or nerve innervation as we'll discuss these topics in greater detail in the neurology chapter.

## Summary:

That was a ton of anatomy and your head must be spinning by now! There is much more anatomy we could cover, but let's hold off and discuss more detailed anatomy in future chapters as they become relevant.

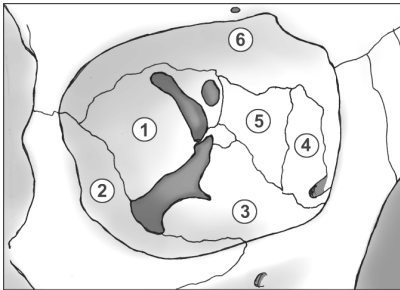
# Pimp Questions

## 1. Why don't objects like contact lens and eyelashes get stuck behind the eye?

Because the conjunctiva covering the front of the eye loops forward and covers the inside of the eyelids as well.

## 2. How many chambers are there in the eyeball?

Three, actually. The anterior chamber sits in front of the iris, the posterior chamber between the iris and the lens, and the vitreous chamber lies behind the lens filling most of the eye.



## 3. Name each of the numbered bones.

*Which bone is thinnest?*

*Which is most likely to fracture after blunt injury?*

*Which is most likely to erode from sinus infections?*

The bones are: (1)Sphenoid (2)Zygomatic (3)Maxilla (4)Lacrimal (5)Ethmoid (6)Frontal. The ethmoid is the thinnest bone and most likely to perforate from an eroding sinus infection (this happens mostly in kids). The maxillary floor is most likely to fracture from blunt injury.

## 3. What is the uvea? What eye structures compose it?

The uvea comprises the iris, ciliary body, and the choroid. They are all connected to each other and are histologically similar. Patients can present with a painful “uveitis,” an inflammation of the uvea, often secondary to rheumatological/inflammatory conditions like sarcoidosis.

## 4. Where does the retina get its nutrition supply?

The inner two thirds of the retina (inner implies toward the center of the eyeball) gets its nutrition from the retinal vessels. The outer third (which includes the photoreceptors) is nourished by the underlying choroid plexus. A retinal detachment, which separates the retina from the choroid, is particularly dangerous for the photoreceptors. This is especially true for detachments involving the macula as the thin macula gets its blood supply primarily from the underlying choroid.

**5. When the ciliary body contracts, how does the lens change shape (does it get rounder or flatter)?**

The ciliary body is a round, spincter-like muscle, so when it contracts the zonules actually *relax*, allowing the lens to relax and become rounder. With age, the lens hardens and has a hard time relaxing no matter how hard the ciliary muscle contracts. This aging process is called presbyopia. We're going to review this again in the cataract chapter.

**6. Which extraocular muscle doesn't originate at the orbital apex?**

Unlike the other muscles, the inferior oblique originates from the orbital floor before inserting on the back of the globe near the macula.

**7. Which full-thickness eyelid laceration is more dangerous - medial or lateral lacerations? Why?**

You worry about the canalicular tear-drainage system involvement with medial lacerations. You want to repair this system as soon as possible, to avoid chronic epiphora.

**8. How many layers are there in the cornea? Can you name them?**

There are five: the superficial Epithelium, Bowman's layer, Stroma, Decemet's membrane, and the inner Endothelium.

**9. How does the water content of the cornea differ from the rest of the eye?**

The cornea is relatively dehydrated, which helps with clarity. If water gets into the cornea, via a disrupted endothelium or a high pressure gradient from acute glaucoma, the cornea turns hazy and white.

**10. A pseudophakic (i.e., implanted lens) patient is found to have excellent far vision, but reading is terrible. What's going on?**

As we get older, our natural lens hardens and does not change shape very well, making it hard to accommodate and see near objects. This phenomenon is called presbyopia and is a normal finding in people over 40 years of age. A prosthetic lens is not able to change shape at all, so *all* patients (including small children) with implanted plastic lenses require reading glasses to read.