

Chest Mobilization Techniques for Improving Ventilation and Gas Exchange in Chronic Lung Disease

Donrawee Leelarungrayub
*Department of Physical Therapy,
Faculty of Associated Medical Sciences, Chiang Mai University
Thailand*

1. Introduction

The clinical treatment and rehabilitation of chronic lung disease such as Chronic Obstructive Pulmonary Disease (COPD) is very challenging, as the chronic and irreversible condition of the lung, and poor quality of life, causes great difficulty to the protocol for intervention or rehabilitation. Most of the problems are, for example, air trapping and destroyed parenchymal lung, which cause chest wall abnormalities and respiratory muscle dysfunction that relate to dyspnea and decreased exercise tolerance (ATS/ERS 2006). Many intergrated problems such as increased airflow resistance, impaired central drive, hypoxemia, or hyperinflation result in respiratory muscle dysfunction, for instance, lack of strength, low endurance level, and early fatigue. Lung hyperinflation in COPD increases the volume of air remaining in the lung and reduces elastic recoil, thus giving rise to air trapping, which results in alveolar hypoventilation (Ferguson 2006). Thus, poor biomechanic chest movement and weak respiratory muscles affect respiratory ventilation (Jones & Moffatt, 2002). Furthermore, in COPD, the combination of V/Q mismatch, diffusion limitation, shunt and hypoventilation or hyperventilation is presented commonly, which leads to gas exchange impairment (West 2003). To solve inefficient ventilation from thoracic pump dysfunction, thoracic mobility exercise or mobilization techniques can be performed (Rodrigues & Watchie, 2010). Chest mobilization is one of many techniques and very important in conventional chest physical therapy for increasing chest wall mobility and improving ventilation (Jennifer & Prasad, 2008). Either passive or active chest mobilizations help to increase chest wall mobility, flexibility, and thoracic compliance. The mechanism of this technique increases the length of the intercostal muscles and therefore helps in performing effective muscle contraction. The techniques of chest mobilization are composed of rib torsion, lateral stretching, back extension, lateral bending, trunk rotation, etc. This improves the biomechanics of chest movement by enhancing direction of anterior-upward of upper costal and later outward of lower costal movement, including downward of diaphragm directions. Maximal relaxed recoiling of the chest wall helps in achieving effective contraction of each intercostal muscle. Thus, chest mobilization using breathing, respiratory muscle exercise or function training allows clinical benefit in chronic lung disease, especially COPD with lung hyperinflation or barrel-shaped chest (Jones & Moffat,

2002). Therefore, the technique of chest mobilization helps in chest wall flexibility, respiratory muscle function and ventilatory pumping, and results from this relieve both dyspnea symptoms and accessory muscle use. This technique is still controversial because it lacks clinical evidence, but it does show clinical benefit, especially in COPD by improving pulmonary function, breathing pattern and weaning from a ventilator.

2. Biomechanics of chest movement and thoracic spine

Movement of the thorax is like the pump-handle pattern (Hammon, 1978). Movement of the chest wall is a complex function within the rib cage, sternum, thoracic vertebra, and muscles. Basic observation reveals chest configuration for abnormality of the spine or chest shape, for example, scoliosis, kyphoscoliosis, barrel, or pectus excavatum (Bates, 1987). Normally, in all joint movement at the end of expiration, the intercostal muscles are at a suitable length before contraction during inspiration.

In assessment, chest stiffness may be caused by muscle structure being applied directly in the supine, side lying or sitting position. Stretching the rib cage, rotating the trunk or lateral flexion of the trunk can be evaluated. Furthermore, suitable lengthening of soft tissue around the chest wall and respiratory muscles is related to the efficiency of contraction force and chest movement. In the case of emphysematus lung or air trapping in COPD, abnormal chest configuration and reduced chest movement with shortened muscle length and weakness are experienced (Malasanos et al., 1990).

Finally, increasing chest movement with stronger contraction of respiratory muscles can help in gaining lung volume, breathing control and coughing efficiency, and reducing symptoms by improving aerobic capacity, endurance, functional ability, and quality of life.

2.1 Functional movement

The thoracic cage is composed of three parts: thoracic spine, ribs, and sternum, which connect to costovertebral and condrosternal joints, and so movement occurs in three dimensions; transverse, antero-posterior and vertical directions (Landel et al., 2005). True ribs (2nd to 8th rib) move more flexibly because of no clavicle obstruction, whereas the 11th and 12th ribs connect to the cartilage, therefore causing less freedom to move.

1. Flexion and extension

The basic structure of the costovertebral joint comprises both the angle and neck articulation of the rib with the spine, and is attached to costotransverse and radiate ligaments. In the direction of thorax flexion (Grant, 2001), there is anterior sagittal rotation, when the costovertebral joint moves as anterior gliding that slightly rotates, whereas downward rotation and gliding occur during extension. The lower thoracic spine moves more freely than the upper one. The sternum is composed of the manubrium, body, and xiphoid process, and is anterior with upward expansion when breathing deeply. In fact, when it comes to movement, the manubrium is somewhat fixed to the first rib, whereas the body is more flexible around the 2nd to 7th rib. Thus, movement of the sternum looks like a hinge joint during deep inspiratory and relaxed expiratory phases. For extension, the extensor muscle group is the most active, with a motion range of

approximately 20-25 degrees. Thorax extension presents the opposite movement to flexion, with backward sagittal rotation by posterior translation and slight distraction of the spine (Neumann, 2002).

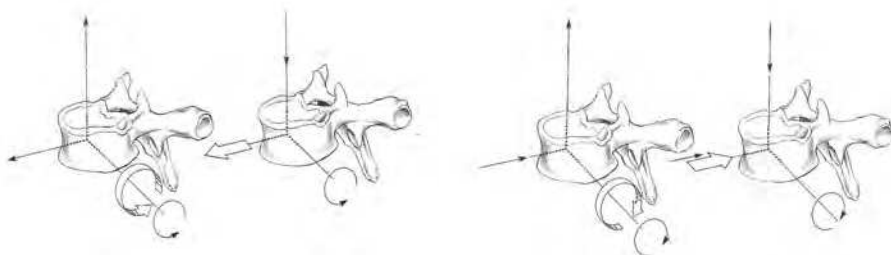


Fig. 1. Anterior rotation of the spine during flexion, and posterior rotation during extension. (Grant, 2001; Lee, 2002)

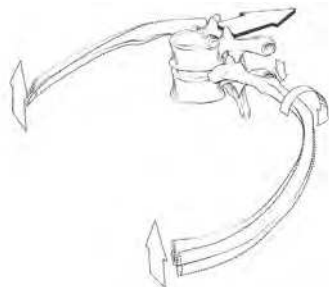


Fig. 2. Extension of the thorax; showing the movement in superior upward and posterior gliding of the costotransverse joint. (Grant, 2001; Lee, 2002)

2. Lateral flexion

In flexion direction, the thoracic body rotates slightly on the flexion side, while the posterior rotates in the opposite direction so that the costovertebral joint is opened and inferior

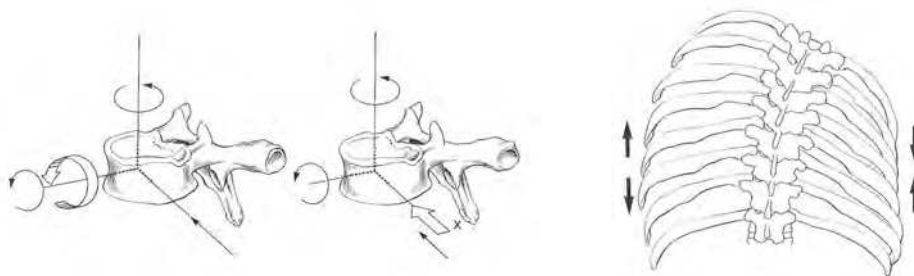


Fig. 3. Biomechanics of lateral flexion to the right; showing the movement of thoracic body and costovertebral joint on both sides. (Grant, 2001; Lee, 2002)

gliding occurs to increase rib space. Mobility of the thorax on flexion, either to the right or left, is found more in lower than upper thoracic parts. Thus, stretching of the lower thorax is rather more successful than that of the upper part. A normal range of motion is approximately 45 degrees: 25 degrees at the thorax and 20 degrees at the lumbar spines. During flexion to the left, the inferior facet of T6 on the left side moves above the superior facet of the T7 spine. In thorax movement, lateral flexion directly affects the rib space in both approximation and stretch away (Figure 3), which results in the transverse process, when the head of the rib glides in the opposite direction (Figure 4).

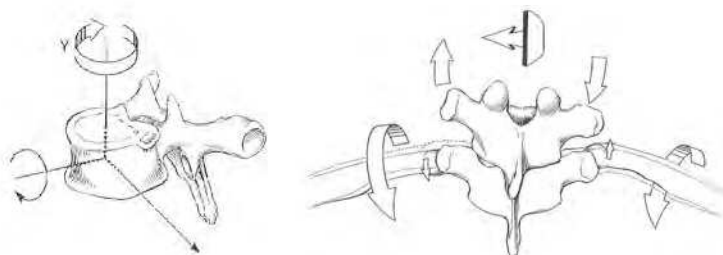


Fig. 4. Rotation of the trunk and thorax, with rib cage and costovertebral joint movement. (Grant, 2001; Lee, 2002)

3. Trunk rotation

Trunk rotation is a complex movement that involves many joints. For example, during rotation to the three left events are shown as; 1) rib rotation with costotransverse posterior gliding on the rotating side, whereas anterior rotation of the rib and gliding are on the opposite side, 2) thoracic body that is elevated and depressed in each segment, and 3) vertical asymmetrical torsion. Upper thoracic spine can move like pure axial rotation as well as thoracolumbar and cervicothoracic rotation. However, sometimes movement of the upper and lower thoracic spines also co-move with lateral flexion or rotation. Thus, articular facet between high and low spines is a sliding movement (Grant, 2001; Lee, 2002).

In conclusion, the chest wall, which is composed of spine, sternum, and ribs, moves in synchronization, no matter whether it is lateral flexion, flexion, extension, or rotation. However, the quality of movement affects individual direction because the costovertebral joint makes contact with the vertebral body, so that lateral expansion is affected more than anterior movement. Whereas, the 2nd to 8th ribs connect to the sternum anteriorly, thus expanding the chest in an anterior direction with pumping handle or anterior and superior motion, as well as bucket handle with lateral and superior motion (Norkin & Levangie, 1992) that occur in regular breathing (Greenman, 1996).

The chest mobilization technique is preferred in cases of COPD or chronic lung disease, with the basic theory of mainly improving ventilation. In addition, aging, prolonged use of a ventilator and chronic illness with neuromuscular dysfunction also concern chest wall mobility.

Rib torsion, passive stretching, trunk rotation, back extension, lateral flexion and thoracic mobilization are practiced to improve chest flexibility.

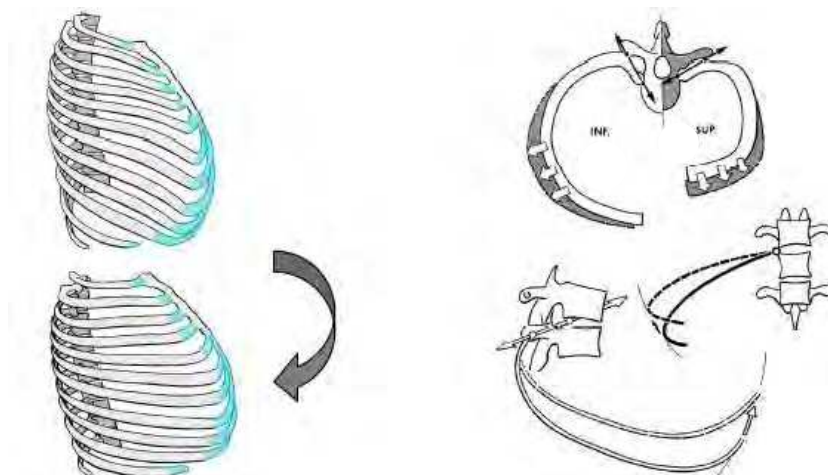


Fig. 5. Pump-Bucket pattern of chest movement. (Greenman, 1996)

3.1 Soft tissue flexibility

The theory of Laplace's law suggests that the length of muscle relates to the maximal force of either diaphragm or intercostal muscles, which affect ventilation in the lung (Kisner et al., 1996; Grossman et al., 1982). Previous evidence showed that stretching the anterior deltoid and pectoralis major muscles, including the sternocleidomastoid, scalenes, upper and middle fibers of trapezius, levator scapulae, etc., can increase vital capacity (Putt & Paratz, 1996). In the case of a patient with COPD, the lower diaphragm is depressed horizontally in a contracted length, thus, the resting length is insufficient for contraction. Tachypnea and dyspnea is then a common sign (Cane, 1992). This phenomenon still presents in patients who use a mechanical ventilator for a long period of time (Guerin, 1993). Muscle around the chest wall can be divided into two dimensions; anteriorly with pectoralis major and internal or external intercostal muscles; and posteriorly with erector spinae, latissimus dorsi, serratus posterior superior or serratus posterior inferior muscles, which are important for lung ventilation (Kacmarek et al., 2005). Thus, retraction or spasm of these soft tissues, or muscles, limits chest expansion.

Impairment or disease relates to ineffective chest wall movement

1. Scoliosis or kyphosis (Leong et al., 1999)
2. Osteoporosis or ankylosing spondylitis (Neill et al., 2005)
3. Nerve injury as spinal cord injury (Baydur et al., 2001)
4. Skin disease such as scleroderma, multiple sclerosis etc. (Woo et al., 2007)
5. Myofascial pain or chest pain (Wise et al., 1992)
6. Post thoracic surgery for lung or heart operation (Macciarini et al., 1999)
7. Prolonged use of a mechanical ventilator (Gillespie et al., 1985)
8. Chronic lung disease or pneumonia (Hoare & Lim, 2006)
9. Prolonged bed rest (Suesada et al., 2007) or aging (Chaunчайyakul et al., 2004)
10. Other factors; pain, posture, diaphragm dysfunction (Vibek, 1991).

4. Physical examination and outcomes

Observation of respiratory symptoms and chest wall mobility

General screening of respiratory problems can be assessed from the signs or symptoms of respiratory depression such as tachypnea, use of accessory muscles, abnormal breathing pattern, cyanosis, nasal flaring etc. which refer to hard work in breathing (Irwin & Tecklin, 1995).

Normal shape of the chest can be observed by the diameter of anterior and lateral views, where the ratio of diameter between anterior and lateral measurement should be more than 1.0. However, in the case of COPD, this ratio may be less than 1.0 and the shape is called barrel chest (Jardins & Tietsort, 1997). In COPD, the barrel chest is shown simply from intrapulmonary air trapping or emphysema, which depresses the diaphragm downward and intercostal outward in a shortened position. The shortening of muscle length before inspiration causes insufficient contractile force. Shortness of breath and decreased chest expansion can be observed clinically. Finally, aggressive dyspnea and low ventilation induce physical deconditioning via low exercise performance (Celli, 2000).

Dyspnea intensity is quantified most easily by using the modified Brog (0-10) category ratio scale (Borg, 1982). This tool evaluates also within other protocols such as the Medical Research Council (MRC) scale, New York Heart Association (NYHA) scale, London Chest Activity of Daily Living scale and Pulmonary Functional Status and Dyspnea Questionnaire (Meek, 2004). Many reports and studies used a Brog scale for identification the dyspnea symptoms and interprets the effectiveness of program.

Palpation on chest expansion

Evaluation of chest expansion is very comfortable for the clinician. Various protocols such as the three levels of upper, middle, and lower lobes (Cherniack, 1983) can be performed manually. Circumferential change from full expiration to maximal inspiration at supine position can be applied with a tape at the axilla (upper lung) and xiphoid (lower lung) levels, as suggested by previous reports (Carlson, 1973), and this protocol has shown good reliability (Lapier et al., 2000). For example, $3 \frac{1}{4}$ inches $\pm \frac{1}{4}$ inch could be increased at the axillary level of 20-to 30-year old women (Carlson, 1973). Another level that can be measured to present chest expansion by tape is the 4th intercostal rib space (Fisher et al., 1990). Furthermore, the chest caliper is a new tool that can be used to evaluate chest expansion. Previous evidence has shown that application of the chest caliper enables measurement of thoracic diameters at rest and during activity, but it could not refer to the normal data for chest expansion (Davis & Troup, 1966).

Original palpable examination is of chest expansion in the respiratory system, and less expansion may reflect intrapulmonary lesion such as secretion obstruction or atelectasis. Sometimes, incomplete recoiling from expiration results in many issues such as mass, emphysema, or air trapping. Although, no scientific data have shown normal length of complete recoiling in chest expiration, clinical experience can adjust muscle tightness or shortening around the chest wall. Palpation of the chest wall for flexibility can be evaluated in sitting, side lying, supine, or prone position. Conventional chest movement can be performed with manual evaluation.

Upper costal chest expansion (Figure 6)

- Position:** Sitting.
- Handling:** All finger tips are placed at the upper trapezius with whole plamar on the upper chest above the 4th rib at the mid clavicle line, and the tips of both thumbs close to the midline at the mid-sternum line.
- Command:** Gentle compression and order the subject to breathe in deeply and release following chest expansion.
- Results:** Approximate calculation of different distances between the tips of thumbs in centimeters (cm) before an after full inspiration.
- Direction:** Upper costal expansion should be upward with anterior expansion.

Middle costal chest expansion (Figure 6)

- Position:** Sitting or lying supine.
- Handling:** All finger tips placed at the posterior axillary line with tips of both thumbs close to the horizontal mid line. The whole plamar should be placed on the middle chest area (4th to 6th rib anteriorly at the mid-clavicle line).
- Command:** Gentle compression and order the subject to breathe in deeply and release following chest expansion.
- Results:** Approximate calculation of different distances between the tips of thumbs in centimeters (cm) before an after full inspiration.
- Direction:** Middle chest expansion should be outward and slightly up ward.

Lower costal chest expansion (Figure 6)

- Position:** Sitting.
- Handling:** All finger tips placed at the anterior axillary line with tips of both thumbs close to the horizontal mid line. The whole plamar placed on the lower chest area (below the scapular line and not lower than the 10th rib posteriorly).
- Command:** Gentle compression and order the subject to breathe in deeply and release following chest expansion.
- Results:** Approximate calculation of different distance between the tips of thumbs in centimeters (cm) before an after full inspiration.
- Direction:** Lower costal expansion should be outward.

Sternocostal Movement Evaluation (Figure 6)

- Position:** Sitting
- Handling:** Palm placed to cover all sternum (head and body).
- Command:** Gentle compression and order the subject to breathe deeply.
- Result:** Anterior expansion during sternum expansion, then upward expansion during sternum (head part) movement.

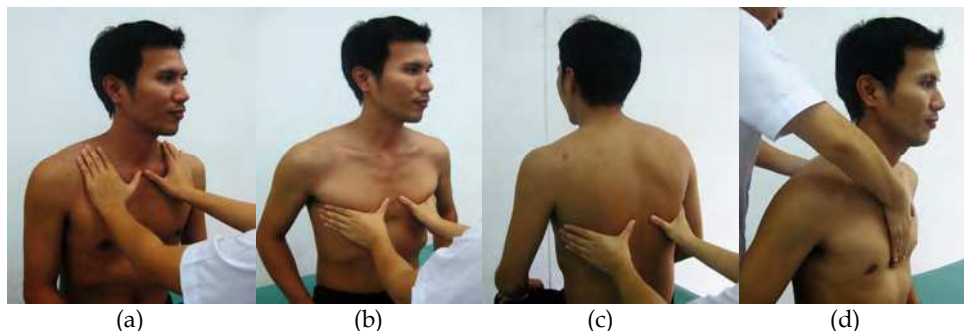


Fig. 6. Three levels of manual evaluation for upper (above the 4th rib anteriorly) (a), middle (between the 4th and 6th ribs anteriorly) (b), lower lung expansion (below the scapulae and above the 12th thoracic vertebrae, posteriorly) (c), and sternum flexibility (d).

Tape and Caliper Evaluation (Fisher et al., 1990; Carlson, 1973)(Figure 7)

Both of these methods can be applied in a sitting position, which is better than lying supine. From the author's experience, the three levels: upper, middle and lower, can be measured at the axillary, nipple line, and xiphoid process. The latest report on measuring the thoracic excursion or expansion was carried out by Bockenbauer and coworker (2007) (Bockenbauer et al., 2007). It suggests anatomic landmarks on the chest wall as follows;

Upper thoracic expansion is seen as the third intercostal space at the midclavicular line and the fifth thoracic spineous process.

Lower thoracic expansion is seen at the tip of the xiphoid process and the 10th thoracic spineous process.

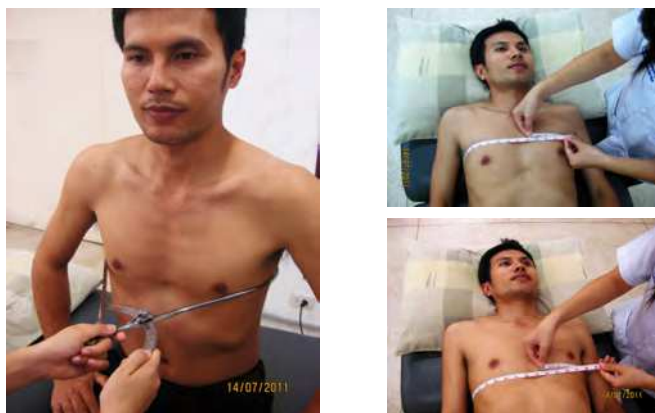

Fig. 7. Application of cloth tape for measuring the upper (right above), lower (right below) thoracic expansion and hand position, and use of the caliper to measure chest expansion (left).

The cloth tape method has been modified by placing the circumference on the specific landmarks transversely and measuring the different changes between full expiration and full

inspiration. Although results were studied in 9 healthy subjects, the mean of upper and lower expansion ranged from 1.0 to 7.0 cm, and 1.5 to 7.98 cm, respectively. For the chest caliper, there was no report or data for the range of normal chest expansion.

Thoracic Flexibility Evaluation (Figure 8)

The thoracic or chest wall flexibility is not determined or evaluated exactly for standard value or comparison between healthy and chronically ill subjects. Thus, many practitioners make decisions individually from clinical experience. Thoracic or chest wall flexibility can be evaluated by many procedures in different positions.

In supine or side lying positions, the examiner can evaluate in various directions, but the result is concerned with the lateral intercostal part.

- A. Position: Supine with head supported with or without a pillow at the mid-thorax (Figure 8)
- Handling: Two hands on the lateral lower chest (6th to 8th rib at the mid -axillary line).
- Direction: 1. Hemi-cross counterpressure.
2. Hemi-caudal stretching force.
3. Bilateral-caudal stretching force.
- B. Position: Side lying position with or without a pillow in the mid-thorax, combined with hand elevation (Figure 8)
- Handling: Two hands on the lateral lower chest (6th to 8th rib at the mid axillary line). One hand holding the subject's hand and the other on the lateral lower chest.
- Direction: Hemi-caudal stretching force with two hands, and opposite and cephalic stretching.
- C. Position: Sitting position without support (Figure 9)
Sternum movement and upper chest expansion
Trunk rotation test
Lateral bending test or anteroposterior flexion test
Trunk flexion and extension test.

Chest X-ray film: Evaluation of lung volume from a chest X-ray (CXR) film is measured possibly from previous evidence of using manual illustration for free hand tracing (May et al., 2009) or calculating total lung capacity from the thoracic roentgen image (Dieterich et al., 1990). In fact, improvement of air entry or volume can be observed from clinically increasing the dark field on the film. In COPD, silhouette sign and secretion retention are identified commonly, including atelectasis from a secretion block (Reid & Chung, 2004), which is the main problem in decreasing lung volume or resorptive atelectasis (Harden, 2009). Thus, the effectiveness of chest mobilization to improve lung ventilation can be reassessed by increasing the aerated areas or resolving the lung collapse on the chest film.

Dynamic lung ventilation: In the case of lung volume evaluation, functional residual capacity (FRC), tidal volume (V_t) and forced vital capacity (FVC) from the pulmonary function test are challenging outcomes (Dexter, 2010). FRC decreases when there is an

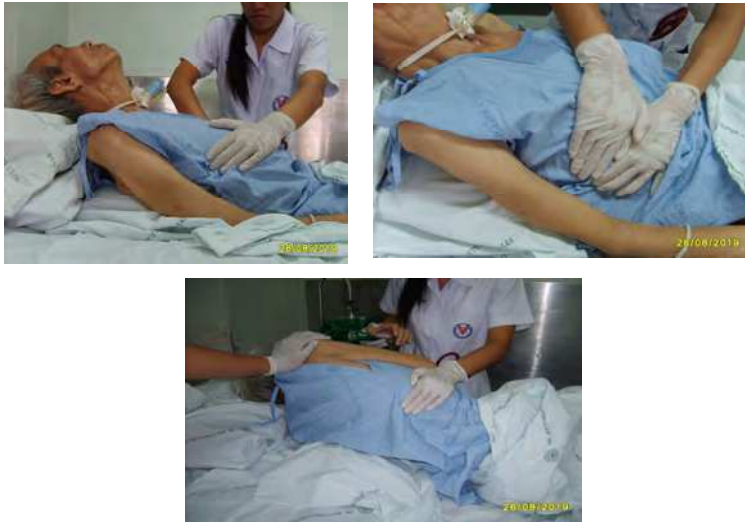

Fig. 8. Rib torsion (right above) and trunk extension (left above) and lateral stretching technique (below). (Leelarungrayub et al., 2009)

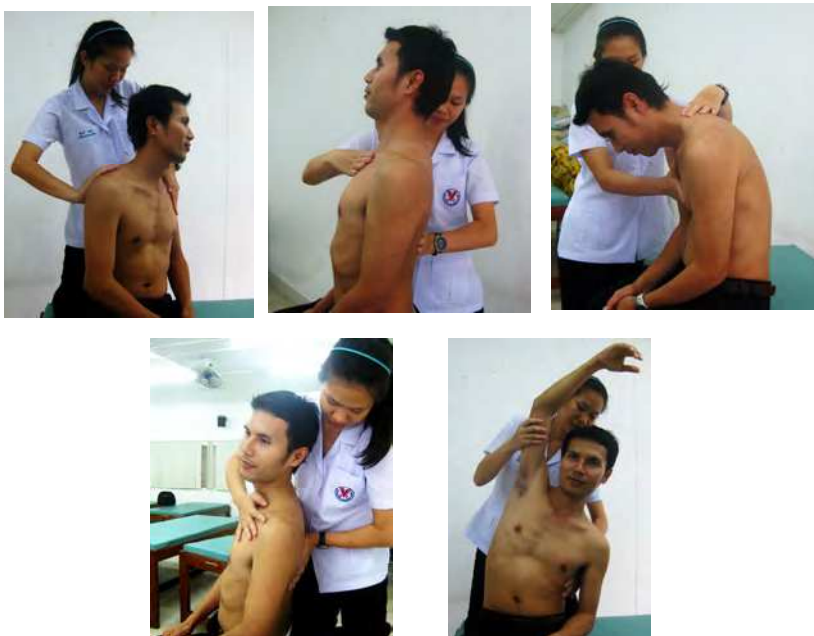

Fig. 9. Functional trunk test as flexion (right above), extension (middle above), rotation(left above), lateral flexion(right below), combined extension, and rotation tests (left below).

imbalance between the lungs and chest wall. Both atelectasis and kyphoscoliosis from abnormal posture affect the elastic recoil of the chest. A barrel chest affects the muscle length of the chest wall or diaphragm by either increasing or decreasing it, and a reduction in force results, which reduces vital capacity (VC) (Henderson & Clotworthy, 2009). In the case of a patient who used a ventilator, improvement in lung volume or ventilation can be evaluated from tidal volume (V_t), expiratory tidal volume (ETV), or minute ventilation (VE). In the early exacerbation stage, evaluation of lung volume is difficult because of dynamic hyperinflation, but if the patient is on a ventilator with SMIV or CPAP modes, minute ventilation (VE) and FRC is very easy to measure (Vines, 2010). Finally, the weaning time from a ventilator is the final outcome that presents the improvement clinically.

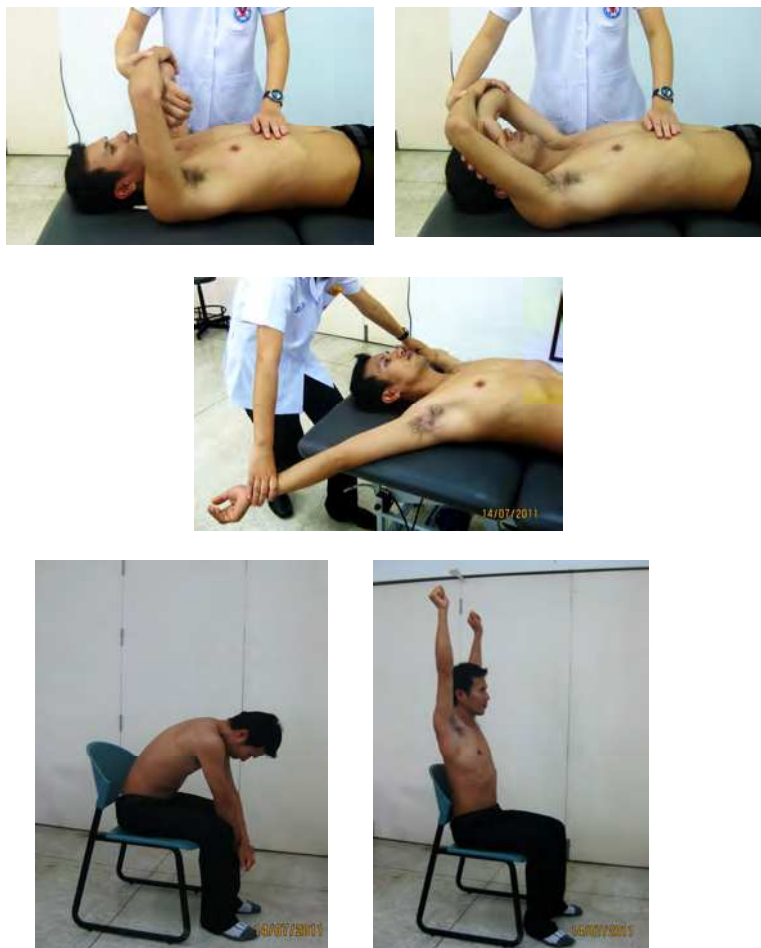


Fig. 10. Passive stretching of the pectoralis major (above and middle) and active stretching of the pectoralis muscles with inspiration with exhalation during flexion and breathing in during extension (below).

From the overall outcomes, chest expansion, dyspnea, chest radiography, and dynamic lung ventilation are most important in representing the effectiveness of a technique. Other parameters can be evaluated such as breathing pattern, respiratory rate, oxygen saturation, etc., and respiratory muscle strength if protocol training is included.

5. Chest mobilization techniques

Chest mobilization techniques are the original protocol used in chronic lung disease, which has the tendency to cause poor posture, rigidity, or lack of thoracic spine and rib cage movement (Vibekk, 1991). These techniques are divided into passive and active chest mobilization, which depends on the patient's condition. In the case of an unconscious patient, as seen in an intensive care unit (ICU) where prolonged treatment is carried out with or without ventilator support, the “**Passive Chest Mobilization Technique**” can be performed on the chest wall by a therapist. Whereas, in the case of a patient in recovery or good condition, the “**Active Chest Mobilization Technique**” can be performed. In some general practices, patients who have just recovered can have modified Active-Passive Chest Mobilization to improve flexibility of the chest wall. The aim of these techniques is to improve thoracic mobility at the upper, middle or lower parts of the chest. Furthermore, these techniques need to be selected carefully to minimize dyspnea, and they should be applied in sitting, sitting leaning forward or high side lying positions (Lee, 2002; Rodrigues & Watchie, 2010).

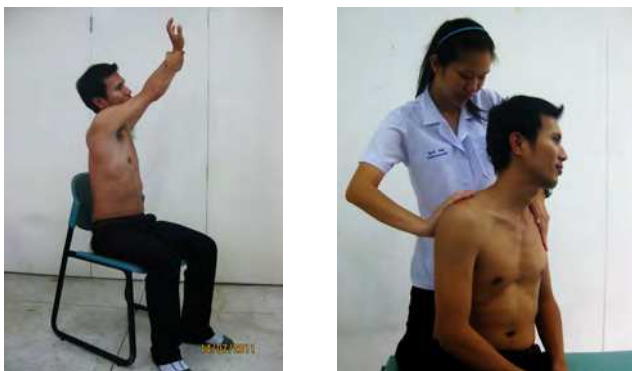

Fig. 11. Chest Mobilization Techniques for improving thoracic mobility at the postero-lateral parts (trunk rotation) (Vibekk, 1991) by active and passive trunk rotation on both sides. Exhalation in a forward position is carried out at the beginning of flexion, and rotation of the left side is performed laterally with inspiration. However, an exhalation phase is carried out during passive trunk rotation.

5.1 Antero-posterior upper costal chest wall mobilization

The original technique is similar to the previously mentioned protocol (Frownfelter, 1987). This pattern is suitable for giving benefit in cases of shortening pectoralis muscles. Some evidence has shown that winging and trunk rotation can improve vital capacity (Pryor et al., 2000). The benefits of this pattern improve both ventilation in upper lobes of boths and also stretches the pectoralis muscle that may tight.

5.2 Postero-lateral chest wall mobilization

This technique has many procedures such as trunk torsion, rotation, and lateral bending (Frownfelter, 1987). It not only affects the ribs and tissue, but also moves the costovertebral and facet joints. This pattern is very useful in order to improve the ventilation around in the lower lobe of both lungs.

5.3 Lateral chest wall mobilization (Figure 12)

This technique can be applied in cases of unconsciousness and good consciousness. This part can be mobilized either by therapist likes lateral flexion on the bed, or rib torsion. Other procedures can be performed by passive stretching in sitting position. The last choice that is very strong and give the best result in order to stretching by side lying on the pillow and passive stretching. This pattern helps to improve the chest wall flexibility around the lower thoracic and improves the ventilation in both lower lungs. Sometime, lateral chesl wall stretching effects to the thoracic joints either sterocostal or costovertebral joints.

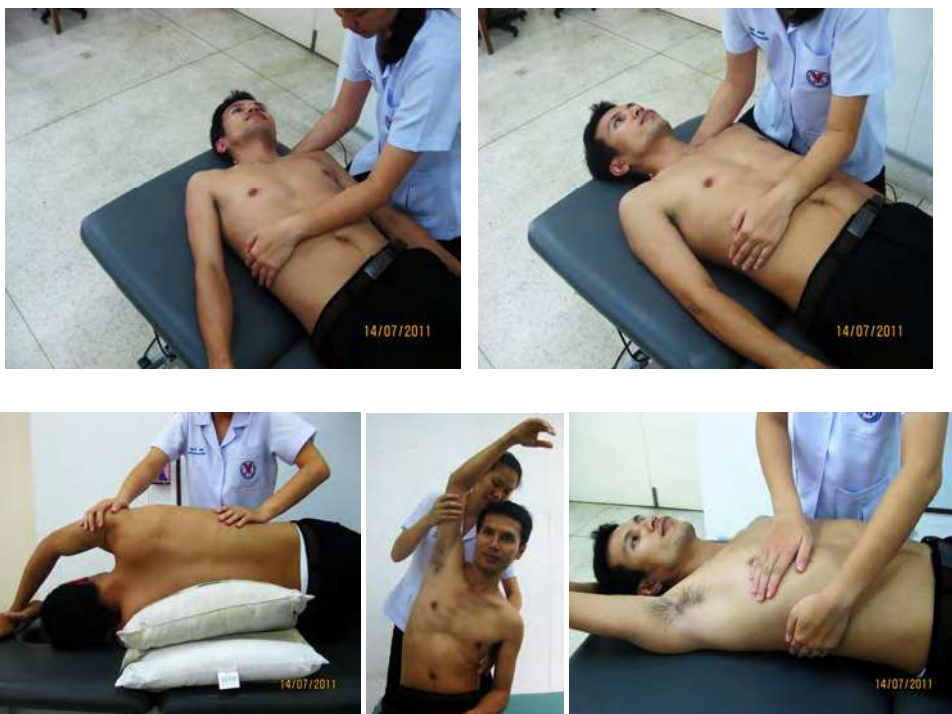

Fig. 12. Chest Mobilization Techniques for improving lateral thoracic mobility; Passive lateral flexion (above), passive rib torsion (right below) (Wetzel et al., 1995), and trunk flexion (middle below), including passive lateral flexion in side lying position on the pillows (left below)

5.4 Thoracic joint mobilization (Figure 13)

From the biomechanics of chest movement, vertebral joints connect to the ribs and sternum with a complex unit that promotes chest expansion. Although this movement is very hard to observe, it also is very effective for ventilation. Therefore, this joint movement is promoted for improving ventilation (Vibekk, 1991).

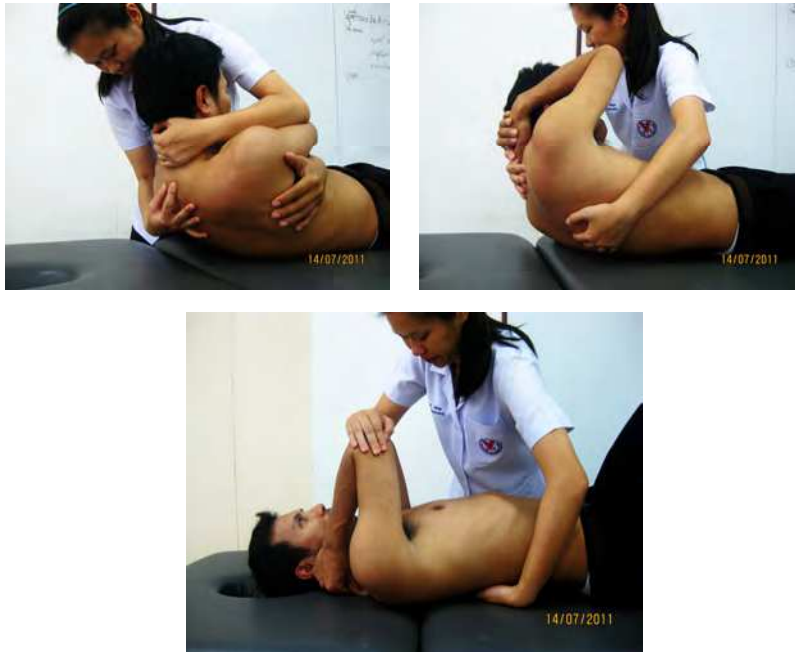

Fig. 13. Mobilization of the facet joint by flexion and extension (Vibekk, 1991), direct rib stretching at the supine lying (left above), facet joint (right above), and costovertebral joint (below).

6. Indication and contra-indication of chest mobilization techniques

There has been no information on the indication for chest mobilization before, which gives a tendency for limitation of chest movement; either structurally or physiologically. However, this technique can be used for various conditions such as COPD, prolonged bed rest, abnormal spine, deconditioning and aging.

The contra-indications for using this method are listed (Viekk, 1991) below:

- Severe and unstable rib fracture
- Metastasis bone cancer
- Tuberculosis spondylitis
- Severe osteoporosis
- Herination
- Severe pain
- Unstable vital signs

7. Clinical analysis on the effectiveness of programs

The clinical procedure for representing the efficiency of this treatment is very difficult because of the low number of cases. Representation of improvement using statistical analysis is limited by either parametric or non-parametric evaluation. In clinical rehabilitation, matching age and disease condition to set up a control or treated group is very difficult. Furthermore, presentation of a positive outcome in clinical improvement is very important.

Many reports of case studies from rehabilitation have shown results with explanations such as postural restoration from physical therapy (Spence, 2008). However, an interesting procedure for evaluating a single system was designed by Bloom and Fischer (1982). This system was designed basically to involve an individual or a single system by repeatedly taking recordings of dependent variables (Ottenbacher, 1986). The components of this design are composed of only sequential application and withdrawal or variation of intervention, with the use of frequent and repeated measures. Thus, this design is not a fixed procedure and can be applied in various study proposals.

The design of a case study has many models; A-B, A-B-A, A-B-A-B, and B-A-B, where A is the baseline period and B the treatment period. There is also an A-B-C model for use in different treatments. Various repeated data recordings are performed in each period, and more than 4 are enough for clinical analysis when a Bloom Table is used. Clinical explanation can be presented by visual inspection and raw data analysis. A simple line graph is an easy procedure for presenting the changes and tendency in each period. Improvement or deteriorious results in pre-treatment, during treatment or post-treatment can be explained from a changing or trend line. In addition, comparison of mean levels in each period is also a very important evaluation. Statistical analysis of this system can be performed using the Bloom Table (Bloom, 1975), which observes the proportion during baseline and number of treatments above or below the celeration line. Important analysis of data in each period involves changes in all parameters that must evaluate autocorrelation, which helps to separate changes between condition and treatment. Other procedures that present the statistical difference between baseline and treatment use the two standard deviation band method and C-statistic (Ottenbacher, 1986). Some researches have used this design such as the study of Cleland and Palmer (2004), who showed the effectiveness of manual physical therapy, therapeutic exercise, and patient education on bilateral disc displacement in a single-case A1 (control period) -B (intervention period) -A2 (withdrawal of the intervention) design, and also presented the results by visual analog scale and the two standard deviation band method (Cleland & Palmer, 2004). Overall, representation of effective rehabilitation or treatment in rare or few cases can be performed with a single case design.

8. Clinical implementation

Case 1: Chest mobilization treatment in the sub-acute stage

Illness history and medical treatment: A sixty years old man, diagnosed with aspirated pneumonia and underlying cysticercosis from obstructive hydrocephalus, was admitted to hospital with respiratory failure. A physician treated him with tracheostomy and on a ventilator (tidal volume = 450 mL, I:E = 2.1, and respiratory rate = 16 bpm). A hematology

test showed low haemoglobin (8.9 g/dL) and haematocrite (27.7%), and the chemistry lab test showed hyponatremia and hypoglycemia.

Chest X-ray: Interstitial infiltration of the left and right upper lobe (Figure 14).

Physical examination: A thin man, with general muscle atrophy, moderate dyspnea, use of accessory muscles during inspiration, decreased chest expansion on the left more than right side, dullness at the left lung, decrease of air entry with bronchovesicular breath sound and coarse crepitation in both lungs (Figure 14 right)

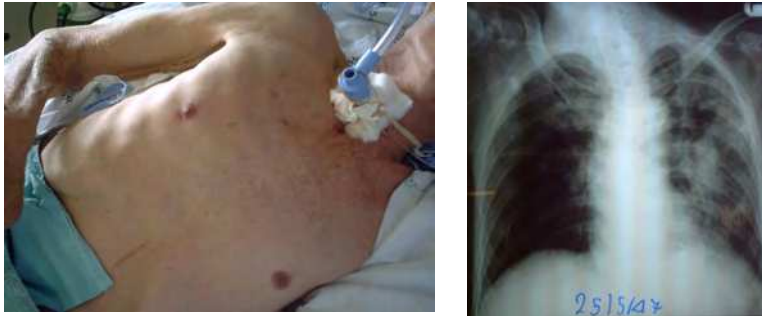

Fig. 14. Chest radiograph before treatment showing infiltration in the left lung and upper area of the right upper lobe (right), and general configuration of the chest wall showing very tight or stiff movement (left).

Treatment: Passive rib torsion at the left lung was added to the general chest physical therapy program; postural drainage, percussion, and breathing exercise (Figure 15) twice daily for 7 days.

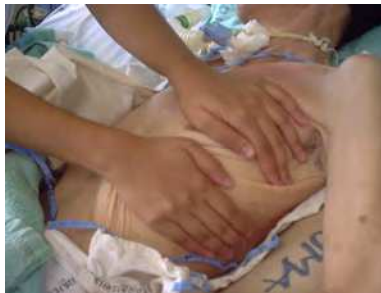

Fig. 15. Passive rib torsion at the left chest wall 10 times per session during ventilation.

Progression: After treatment, repeated chest radiography showed improvement of aeration and less infiltration in the left lung (Figure 16). Medical treatment could stop using a ventilator to supplement oxygen at 10 Lpm, with a T-piece for 1 hr alternately in a 4 hr period, because hypoglycemia, hyponatremia and malnutrition, dyspnea and use of some accessory muscles were present.

Remaining problems: General weakness, ineffective breathing, shortness of breath, minimized chest expansion and stiffness, and air entry reduction without crepitation.

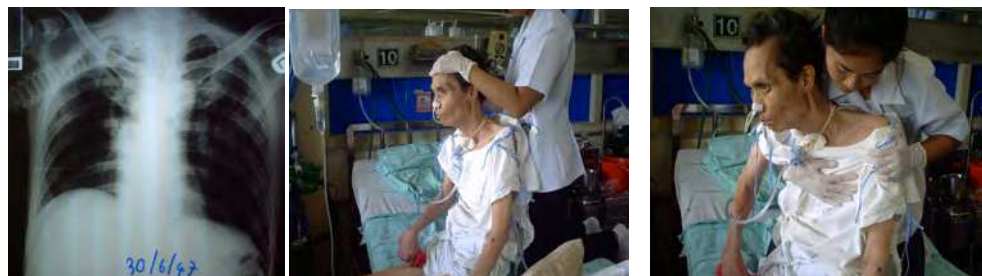

Fig. 16. Chest radiograph after 7 days of treatment (left) and Chest mobilization in sitting position with sternum compression, trunk extension and rotation (middle and right).

Progressive treatment: Passive chest mobilization in a sitting position by stimulating chest expansion in an antero-posterior direction with sternum compression, back extension and trunk rotation.

Final outcomes: In this case, chest mobilization in antero-posterior direction or stimulated sternum movement increased chest expansion by evaluating the expiratory tidal volume (TVE), tidal volume, and SpO₂. Patients who have stopped using a ventilator and are only on an O₂ with T-piece can be discharged from hospital after 2 weeks treatment with chest mobilization. However, there is more intensive treatment such as sitting, standing and walking training, and weight training to increase the upper and lower limbs' strength.

Case 2: Chest mobilization treatment in the acute stage

History of illness and medical treatment: A sixty-three years old man was diagnosed with chronic lung disease, pneumonia and sepsis. A physician treated him with an orotracheal tube on a ventilator (Pressure support= 12 cmH₂O, O₂ = 35%, VTE = 150 mL). Blood gas results showed respiratory acidosis and moderate hypoxia with metabolic compensation. Medical problems after treatment were prolonged use of a ventilator (for one month), with recurrent infection and pneumothorax at the right lung, which was resolved by intercostal drainage (ICD). Then, the medical program for weaning off the ventilator was unsuccessful.

Chest X-ray: Left lung atelectasis and pneumothorax at the right lung with ICD (Figure 17 left)

Physical examination: A thin man was using a ventilator and presenting general weakness, muscle atrophy and malnutrition. He produced very little chest expansion on either side. Dullness presented at the left lung and hyperresonance at the right one.

Treatment: Initially, an upright position was combined with a chest mobilization technique on the left chest wall, and percussion to remove secretion was performed 3 times daily.

Progression: After 3 days of treatment, chest radiography was evaluated repeatedly (Figure 17), showing improvement of aeration in the left lung, but atelectasis at the lower lung. The physician could not reduce pressure support while the patient was on the ventilator, but the expiratory tidal volume improved from 155 to 366 mL and an ICD was removed successfully. Unfortunately, remaining problems presented because of respiratory muscle weakness, and malnutrition, and the final goal of stopping the ventilator still had to be reached.

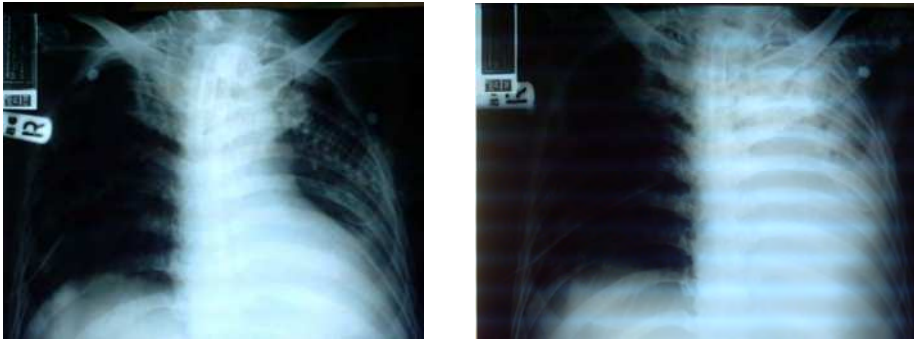


Fig. 17. Chest radiograph showing atelectasis of the left lung, and pneumothorax at the right lung with ICD before treatment (right) and after 3 days of treatment showing improvement of aeration in the left lung with atelectasis of the left lower lobe (left).

Progressive treatment: An extensive program was carried out from previous treatment with passive chest mobilization in supine position because of weakness. Passive pectoralis muscle and breathing exercise were performed combined with diaphragmatic and intercostal muscle contraction by relearning.

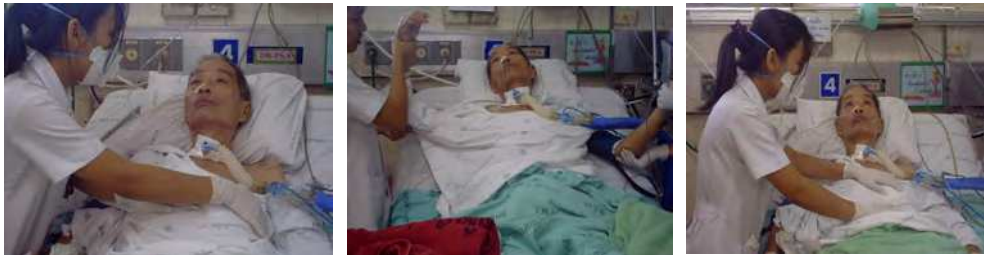

Fig. 18. Passive chest mobilization being combined with breathing exercise of the intercostal and diaphragmatic muscles.

Final outcomes: For this case in the ICU stage, benefits of chest mobilization presented improvement of ventilation at the left lung, and more advantageous treatment was shown when combining other techniques such as breathing exercise with intercostal muscle and diaphragm relearning. However, treatment was unsuccessful in other factors such as pneumothorax, malnutrition and the patient's overall condition.

Case 3: Chest mobilization treatment in the chronic stage

Illness history and medical treatment: A sixty years old man was diagnosed with stable COPD and acute exacerbation because of prolonged use of a ventilator, no rehabilitation for 3 months, and unsuccessful weaning from the ventilator with recurrent infection and much secretion. Ventilator mode was maintained with pressure control (pressure support = 25 cmH₂O, rate = 15 bpm, I:E = 1:2, FiO₂ = 0.45, and PEEP =10 cmH₂O. Blood gas showed moderate hypoxemia (PaO₂ = 85 mmHg) with hypercapnea (PaCO₂ = 55 mmHg) and completed compensation. Berodual forth for preventing bronchospasm and Fluimucil A600 for diluting the secretion were administered routinely.

Chest X-ray: CXR shows specific atelectasis at the right lower lobe and hyperaerotion in the left lung before treatment (Figure 19 left).

Physical examination: A thin man using a ventilator presented with muscle weakness, atrophy and malnutrition. BMI was 13.5 kg/m². Chest expansion was very small on both sides. Dullness presented in the left lung and hyperresonance at the right lung.

Treatment: For general chest physical therapy with postural drainage, percussion and breathing exercises were carried out in the ward, such as upright position combined with a chest mobilization technique and compression on sternum, and trunk rotation was used to improve chest wall flexibility. An additional program of passive rib torsion, trunk extension and lateral stretching on a pillow was carried out as well. All programs were performed 3 times daily (Figure 19 middle and right).

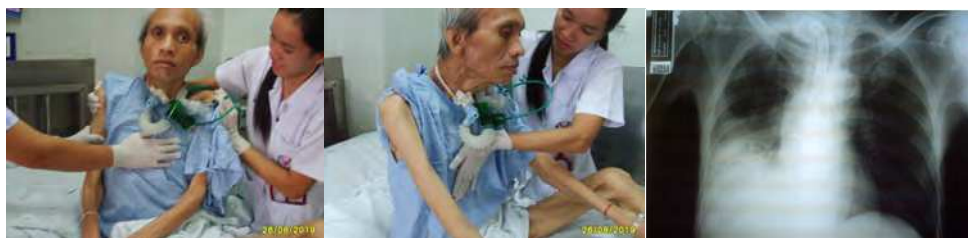

Fig. 19. Chest radiograph showing atelectasis of the right lower lobe and hyperaerotion in the left lung before treatment (right), Chest mobilization being performed with compression on sternum, trunk rotation of both sides, sternum and trunk rotation of both sides (middle and left) (Leelarungrayub et al., 2009).

Clinical evaluation: Efficiency of treatment was monitored using various parameters such as expiratory tidal volume, chest expansion at the mid axillary line with a tape and dyspnea, and followed up by CXR after treatment. This effective treatment used the single-case research design with the A (Pre-CPT), B (CPT treatment), and A (Post-CPT) model for 7 day periods.

Results (Figure 20): A 7 day control period (Pre-CPT) showed low expiratory tidal volume (ETV) (mean = 195± 30 mL) and chest expansion (mean = 2.1± 0.54 cm), and during the 7 days of treatment (CPT) benefits were shown by increased mean of ETV (260±49 mL) and chest expansion (3.6±0.22 cm). The dyspnea score was reduced from 6.4±1.14 to 4.4± 0.54. Statistical comparison using the Bloom Table showed significant changes in ETV, with 5 points, 4 points, and all points above the trend line from a Pre-CPT period. However, the Post-CPT and ETV showed deteriorious effects when treatment was stopped and all points went below the trend line, except for the dyspnea score and chest expansion, which maintained the same level. In both the Pre-CPT and CPT period, all data showed non-significant results of autocorrelation, which meant that the changes in each period did not come from disease progression, especially during treatment (CPT).

Clinical implementation: The chest mobilization technique is very important for improving ventilation and gas exchange in cases that are measured by lung volume and chest expansion, including dyspnea. In figure 20 shows the significant changes of this technique by increasing in a mean of all paparameter when compared to the before treatment of

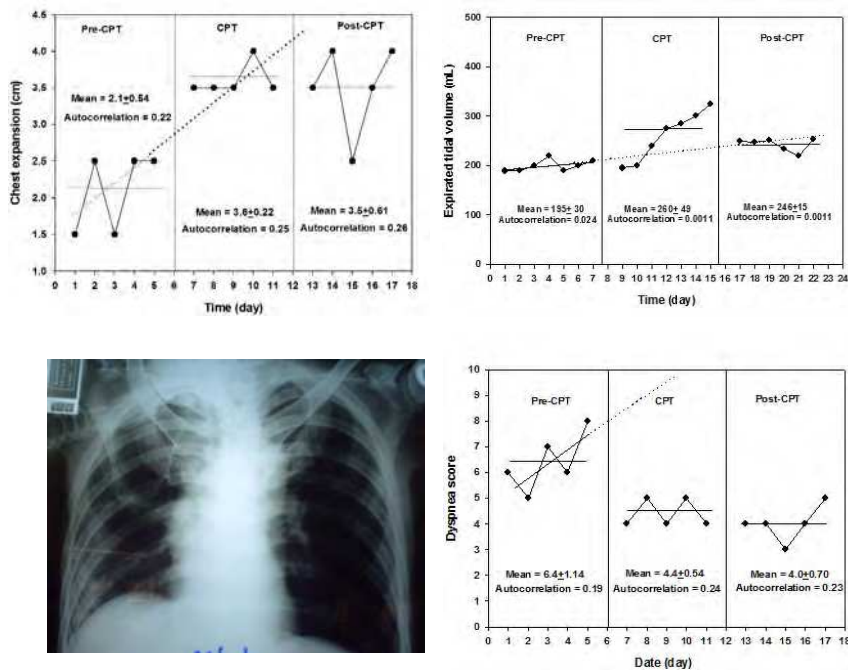


Fig. 20. Visual analog graphs of expired tidal volume (ETV) (right above), chest expansion (left above), dyspnea score (right below) with their autocorrelation with trend lines, and CXR showed an improvement of aeration in the right lower lobe on the 7th day of treatment (left below). (Leelaraungrayub et al., 2009)

baseline. Expirated tidal volume and chest expansion were significant difference, and dyspnea score reduced. Moreover, chest radiography of post-treatment showed increasing in the lung volume and less infiltration.

9. Conclusion

Chest mobilization techniques are very useful in clinical practice for improving lung ventilation and gas exchange. They also can be applied in various cases, for example, chronic obstructive pulmonary disease (COPD), pneumonia, chronic illness from stroke, spinal injury, prolonged use of a ventilator, etc. These techniques can be applied with others such as breathing exercise, cough training, or exercise in regular pulmonary rehabilitation. Before and after intervention, assessments of observations, palpation or chest expansion measurement, including X-ray recheck and lung function test, are very important for confirmation of clinical improvement with a single case research design. Improvement of ventilation and gas exchange is very important in gaining health status or quality of life in ICU, or sub-acute or chronic stages. Efficiency of aerobic capacity directs the function and physical performance in daily life. However, this chapter is an example of interesting theory that needs more study to confirm its results. It is hoped that there will be more reports or wider application of chest mobilization in hospitals and communities for improving health status and pulmonary rehabilitation.

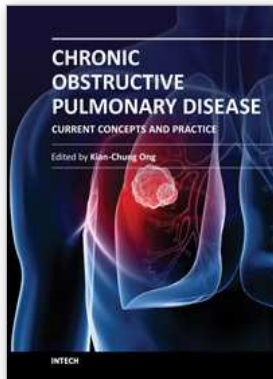
10. References

- American Thoracic Society/European Respiratory Society Statement on Pulmonary Rehabilitation. (2006). *American journal of respiratory and critical care medicine*, Vol.170, pp. 1390-1413, ISSN 1535-4970.
- Bates, B. (1987). *A guide to physical examination and history taking*. 4th edition, Lippincott. ISBN 0397546238, Philadelphia.
- Baydur, A.; Adkins, R.H. & Milic-Emili, J. (2001). Lung mechanics in individuals with spinal cord injury: effects of injury level and posture. *Journal of Applied Physiology*, Vol.90, No.2, pp. 405-411, ISSN 8750-7587.
- Bloom, M, & Fischer, J. (1982). *Social service: Evaluation research (Social action programs); evaluation*, Prentice-Hall, ISBN 0132923181, New Jersey.
- Bloom, M. (1975). *The paradox of helping: Introduction to the philosophy of scientific practice*, John Wiley & Sons, Inc, ISBN-10: 0023108908, New Jersey.
- Bockenbauer, S.E.; Chen, H.; Julliard, K.N. & Weedon, J. (2007). Measuring thoracic excursion: Reliability of the cloth tape measure technique, *Journal of the American osteopathic association*, Vol.107, No.5, pp.191-196. ISSN 0098-6151.
- Brog, G.A.V. (1982). Psychophysical basis of perceived exertion, *Medicine and science in sports and exercise*, Vol.14, pp.377-381, ISSN 0195-9131.
- Cane, L.D. (1992). Functional anatomy and physiology of ventilation In: *Pulmonary management in physical therapy*. Zada CC, (Ed), Churchill livingstone, pp.13-18, ISBN 0443087415, Tokyo.
- Carlson, B. (1973). Normal chest excursion. *Physical Therapy*, Vol.53, No.1, pp. 10- 14, ISSN ISSN 0031-9023.
- Celli, B.R. (2000). Exercise in the rehabilitation of patients with respiratory disease, In: *Pulmonary rehabilitation. Guideline to success*, Hodgkin, J.E., Celli, B.R., Connors, G.L (Eds). Lippincott, Williams&Wilkins, pp.156-157. ISBN 9780781719896, Philadelphia.
- Chaunчайyakul, R.; Groeller, H.; Clarke, J.R. & Taylor, N.A.S. (2004). The impact of aging and habitual physical activity on static respiratory work at rest and during exercise. *American Journal of Physiology Lung Cellular and Molecular Physiology*, Vol.287, pp.L1098-L1106, ISSN 1040-0605.
- Cherniack, R.M. & Cherniack, L. (1983). *Respiration in health and disease*, 3th edition, WB. Saunders, pp. 311-316, ISBN 0721625274, Philadelphia.
- Cleland, J. & Palmer, J. (2004). Effectiveness of manual physical therapy, therapeutic exercise, and patient education on bilateral disc displacement without reduction-of the temporomandibular joint: a single-case design, *Journal of Orthopaedic Sports Physical Therapy*, Vol.34, pp.535-548, ISSN 0190-0611.
- Davis, P.R. & Troup, J.D.G. (1966). Human thoracic diameters at rest and during activity. *Journal of Anatomy*, Vol.100, pp.387-410, ISSN 0021-8782.
- Dexter, J.R. (2010). Pulmonary function test. In: *Clinical assessment in respiratory care*, Wilkins, R.L., Dexter, J.R., Heuer, A.J, (Eds). 6th edition. pp. 166-175, St. Louis, ISBN 978-1-4160-5923-3, Missouri.
- Dieterich, W.R. & Schneider, W.D. (1990). Determination of total lung capacity from the thoracic roentgen image, *Zeitschrift fur erkrankungen der atmungsorgane*, Vol.174, pp.67-72, ISSN 0303-657x.

- Ferguson, G.T. (2006). Why does the lung hyperinflate?. *Proceedings of the American Thoracic Society*, Vol.3, pp.176-179, ISSN 1546-3222.
- Fisher, L.R.; Cawley, M.I.D. & Holgate, S.T. (1990). Relation between chest expansion, pulmonary function, and exercise tolerance in patients with ankylosing spondylitis, *Annals of the Rheumatic disease*, Vol.49, pp.921-925, ISSN 00034967.
- Frownfelter, D.(1987). *Chest Physical therapy and pulmonary rehabilitation*, 2nd edition, pp. 170-177, Year book medical publishers, ISBN 0-8151-3340-5, Chicago.
- Gillespie, D.J.; Hyatt, R.E. & Schroeder, M.A. (1985). Effect of ventilation by high-frequency oscillation on lung and chest wall mechanics in the dog, *Lung*, Vol.163, pp.317-325. ISSN 0341-2040.
- Grant, R. (2001). *Physical therapy of the cervical and thoracic spine*, 3rd edition, Churchill Livingstone, pp. 45-60, ISBN 0-443-07155-1, New York.
- Greenman, P. (1996). *Principles of manual medicine*, 2nd edition, Williams & Wilkins, ISBN 0683035584, Baltimore.
- Grossman, M.; Sahrman, S. & Rose, S. (1982). Review of length-associated changes in muscle, *Physical Therapy*, Vol.62, pp.1799-1808, ISSN 0031-9023.
- Guerin, C.; Coussa, M.L.; Eissa, N.T.; Corbeil, C.; Chasse, M.; Braidy, J.; Matar, N. & Milic-Emili, L. (1993). Lung and chest wall mechanic in mechanically ventilated COPD patients. *Journal of Applied Physiology*, Vol.74, pp.1570-1580, ISSN 8750-7587.
- Hammon, L. (1978). Review of respiratory anatomy, In: *Chest physical therapy and pulmonary rehabilitation*. Frownfelter, D.L (Ed), Year Book Medical Publishers, Inc. pp.3-18, ISBN 0815132964, London.
- Harden, S. (2009). Chest X-ray interpretation, In: *Respiratory Physiotherapy*, 2nd edition, Harden, B., Cross, J., Broad, M.A., Quint, M., Ritson, P., Thomas, S, (Eds). pp.51-59, Churchill Livingstone, ISBN 978-0-7020-3003-1, Toronto.
- Henderson, B. & Clotworthy, N. (2009). The management of volume loss, In: *Respiratory Physiotherapy*, 2nd edition, Harden, B., Cross, J., Broad, M.A., Quint, M., Ritson, P., Thomas, S., (Eds), Churchill Livingstone, pp.83-91, ISBN 9780080449852, Toronto.
- Hoare, Z. & Lim, S. (2006). Pneumonia: update on diagnosis and management. *British Medical Journal*, Vol.332, pp.1077-1079, ISSN 0959-8138.
- Irwin, S. & Tecklin, J.S. (1995). *Cardiopulmonary physical therapy*, 3rd edition, Mosby, ISBN 080162908x, Toronto.
- Jardins, T.D. & Tietsort, J.A. (1997). Assessment skills core to practitioner success, In: *Respiratory care*, 4th edition, Burton, G.E., Hodgkin, J.E., Ward, J.J., (Eds), Lippincott Raven, p.168-200, ISBN 1-56238-545-3, Philadelphia.
- Jennifer, A. & Prasad, S.A. (2008). Physiotherapy techniques, In: *Physiotherapy for respiratory and cardiac problems*, 4th ed, Pryor, J.A., Prasad, S.A (Eds), pp. 188-190, Churchill Livingstone, ISBN 9780080449852, Toronto.
- Jones, M. & Moffatt, F. (2002). *Cardiopulmonary physiotherapy*. BIOS Scientific publishers limited, ISBN 1-85996-297-1, Guildford.
- Kacmarek, R.M.; Dimas, S. & Mack, C.W. (2005). *The essentials of respiratory care*, 4th edition, Elsevier Mosby, pp.92-94, ISBN 0323027008, Missouri.
- Kisner, C. & Colby, L.A. (1996). *Therapeutic exercise: foundations and technique*, 3rd edition, FA Davis Company, pp.143-182, ISBN 0-683-04576-8, Philadelphia.

- Landel, R.; Hall, C.; Moffat, M. & Smith, S.R.(2005). The thoracic spine, In: *Therapeutic exercise*. 2nd edition, Hall, C.M.,& Brody, L.T (Eds), Lippincott, Williams&Wilkins, pp. 610-615, ISBN 0-397-55260-2, Philadelphia.
- LaPier, T.K.; Cook, A.; Droege, K.; Oliverson, R.; Rulon, R.; Stuhr, E.; Yates, D. & Devine, N.(2000). Intertester and Intratester Reliability of chest excursion measurements in subjects without impairment. *Cardiopulmonary Physical Therapy Journal*, Vol.11, No.3, pp.94-98, ISSN 1541-7891.
- Lee, D. (2002). Biomechanics of the thorax, In: *Physical therapy of the cervical and thoracic spine*. 3rd edition, Grant R (Ed), Churchill Livingstone, pp. 45-60, ISBN 0443065640, Philadelphia.
- Leelarungrayub, D.; Pothongsunan, P.; Yankai, A. & Pratanaphon, S (2009). Acute clinical benefits of chest wall-stretching exercise on expired tidal volume, dyspnea and chest expansion in a patient with chronic obstructive pulmonary disease, *Journal of Bodywork and Movement Therapies*, Vol.13, pp.338-343, ISSN 1360-8592.
- Leong, J.C., Lu, W.W., Luk, K.D., Karlberg, E.M. (1999). Kinematics of the chest cage and spine during breathing in healthy individuals and in patients with adolescent idiopathic scoliosis, *Spine*, Vol. 24, pp.1310-1315, ISSN 0887-9869.
- Lin, K.C.; Dizner-Golab, A.; Thurer, R.L. & Loring, S.H. (2004). Mediastinal and chest wall limitations to asymmetry of lung inflation, *Journal of Applied Physiology*, Vol.96, No.3, pp. 999-1004, ISSN 8750-7587.
- Macciarini, P.; Ladurie, F.L.R.; Cerrina, J.; Fadel, E.; Chpelier, A. & Philippe, D. (1999). Clamshell or sternotomy for double lung or heart-lung transplantation?, *European Journal of Cardiothoracic Surgery*, Vol.15, pp.333-339, ISSN 1010-7940.
- Malasanos, L.; Barkauskas, V. & Stoltenberg-Allen, K. (1990). *Health assessment*, 4th edition, St.Louis: Mosby, ISBN 0801604788, Toronto.
- May, C.; Prendergast, M.; Salman, S.; Rafferty, G.F. & Greenough, A. (2009). Chest radiograph thoracic areas and lung volumes in infants developing bronchopulmonary dysplasia, *Pediatric pulmonology*, Vol.4, pp80-85, ISSN 1099-0496.
- Meek, P.M. (2004). Measurement of dyspnea in chronic obstructive pulmonary disease, *Chronic respiratory disease*. Vol.1, pp.29-37, ISSN 1479-9723.
- Neill, T.W.; Prouse, P. & Bhalla, A.K. (2005). Ankylosing spondylitis associated with osteoporosis and vertebral deformity, *Clinical Rheumatology*, Vol.13, pp.113-114, ISSN 1434-9949.
- Neumann, D.A. (2002). Kinesiology of the musculoskeletal system, In: *Foundations for physical rehabilitation*, Mosby, pp. 288-300, ISBN 0815163495, London.
- Norkin, C.C. & Levangie, P.K. (1992). *Joint structure and function; A comprehensive analysis*, 2nd edition, FA Davis, ISBN 9780803623620, Philadelphia.
- Ottenbacher, K.J. (1986). *Evaluating clinical change: strategies for occupational and physical therapy*, Williams&Wilkins, ISBN 0-683-06659-5, Sydney.
- Pryor, J.A.; Webber, B.A.; Bethune, D.; Howarth, A.; Potter, H.M. & Tagg, L. (2000) Physiotherapy techniques, In: *Physiotherapy for respiratory and cardiac problems*,. 3rd edition, Pryor, J.A., Prasad, S.A, (Eds). pp.165-167, Churchill livingstone. ISBN 9780080449852, Toronto.
- Putt, M.T. & Paratz, J.D. (1996). The effect of stretching pectoralis major and anterior deltoid muscles on the restrictive component of chronic airflow limitation In: *Proceedings of*

- the National Physiotherapy Conference*, Brisbane, Queensland, Australian Physiotherapy Association, Australia.
- Reid, W.D. & Chung, F. (2004). Chest radiology In: *Clinical management notes and case histories in Cardiopulmonary physical therapy*. pp.31-36. Slack Incorporated, ISBN 1-55642-568-6, New Jersey.
- Rodrigues, J. & Watchie, J. (2010). Cardiovascular and pulmonary physical therapy treatment, In: *Cardiovascular and pulmonary physical therapy, A clinical Manual*. Watchie, J (Ed), 2nd edition, pp. 319-322, Saunders, ISBN 978-0-7216-0646-0, Missouri.
- Spence, H. (2008). Case study report: postural restoration: an effective physical therapy approach to patient treatment, *Techniques in regional anesthesia and pain management*. Vol.12, pp.102-104, ISSN 1084208x.
- Suesada, M.M.; Martins, M.A. & Carvalho, C.R.F. (2007). Effect of short-term hospitalization on functional capacity in patients not restricted to bed. *American Journal of Physical Medicine Rehabilitation*, Vol.86, pp.455-462, ISSN 1537-7385.
- Vibek, P. (1991) Chest mobilization and respiratory function, In: *Respiratory care*, Pryor, J.A, (Ed). pp.103-119, Churchill livingstone. ISBN 0-443-03611, Tokyo.
- Vines, D.L. (2010). Respiratory monitoring in the intensive care unit, In: *Clinical assessment in respiratory care*, Wilkins, R.L., Dexter, J.R., Heuer, A.J, (Eds). 6th edition. pp. 286-291, St. Louis, ISBN 978-1-4160-5923-3, Missouri.
- West, J.B. (2003). *Pulmonary pathophysiology-the essential*, 6th edition, Lippincott Williams & Wilkins, ISBN-13: 978-0683307344 Baltimore.
- Wetzel, J.L.; Lunsford, B.R.; Peterson, M.J. & Alvarez, S.E. (1995). Respiratory Rehabilitation of the patients with a spinal cord injury, In: *Cardiopulmonary rehabilitation*, 3rd ed, Irwin, S., Tecklin, J.S (Eds), p.596, Mosby, ISBN 0-8016-7926-5, Wiesbaden.
- Wise, C.M.; Semble, E.L. & Dalton, C.B. (1992). Musculoskeletal chest wall syndromes in patients with noncardiac chest pain: a study of 100 patients, *Archives of Physical Medicine and Rehabilitation*, Vol.73, pp.147-149, ISSN 0003-9993
- Woo, P.; Laxer, R.M. & Sherry, D.D. (2007). Scleroderma, In: *Pediatric rheumatology in clinical practice*, Springer, pp. 77-89, ISBN 978-1-84628-420-5, London.



Chronic Obstructive Pulmonary Disease - Current Concepts and Practice

Edited by Dr. Kian-Chung Ong

ISBN 978-953-51-0163-5

Hard cover, 474 pages

Publisher InTech

Published online 02, March, 2012

Published in print edition March, 2012

A decade or so ago, many clinicians were described as having an unnecessarily 'nihilistic' view of COPD. This has certainly changed over the years... This open access book on COPD provides a platform for scientists and clinicians from around the world to present their knowledge of the disease and up-to-date scientific findings, and avails the reader to a multitude of topics: from recent discoveries in the basic sciences to state-of-the-art interventions on COPD. Management of patients with COPD challenges the whole gamut of Respiratory Medicine - necessarily pushing frontiers in pulmonary function (and exercise) testing, radiologic imaging, pharmaceuticals, chest physiotherapy, intensive care with respiratory therapy, bronchology and thoracic surgery. In addition, multi-disciplinary inputs from other specialty fields such as cardiology, neuro-psychiatry, geriatric medicine and palliative care are often necessary for the comprehensive management of COPD. The recent progress and a multi-disciplinary approach in dealing with COPD certainly bode well for the future. Nonetheless, the final goal and ultimate outcome is in improving the health status and survival of patients with COPD.

How to reference

In order to correctly reference this scholarly work, feel free to copy and paste the following:

Donrawee Leelarungrayub (2012). Chest Mobilization Techniques for Improving Ventilation and Gas Exchange in Chronic Lung Disease, *Chronic Obstructive Pulmonary Disease - Current Concepts and Practice*, Dr. Kian-Chung Ong (Ed.), ISBN: 978-953-51-0163-5, InTech, Available from:

<http://www.intechopen.com/books/chronic-obstructive-pulmonary-disease-current-concepts-and-practice/chest-mobilization-techniques-for-improving-ventilation-and-gas-exchange-in-chronic-lung-disease>

INTECH
open science | open minds

InTech Europe

University Campus STeP Ri
Slavka Krautzeka 83/A
51000 Rijeka, Croatia
Phone: +385 (51) 770 447
Fax: +385 (51) 686 166
www.intechopen.com

InTech China

Unit 405, Office Block, Hotel Equatorial Shanghai
No.65, Yan An Road (West), Shanghai, 200040, China
中国上海市延安西路65号上海国际贵都大饭店办公楼405单元
Phone: +86-21-62489820
Fax: +86-21-62489821

© 2012 The Author(s). Licensee IntechOpen. This is an open access article distributed under the terms of the [Creative Commons Attribution 3.0 License](#), which permits unrestricted use, distribution, and reproduction in any medium, provided the original work is properly cited.