

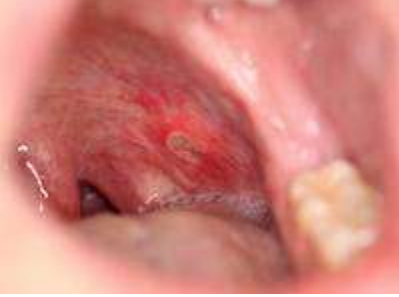Supportive module 2: Basics of diagnosis, treatment and prevention of major gastroenterological diseases

# Chronic Disease of the Small Intestine: Crohn's disease, Celiac disease

LECTURE IN INTERNAL MEDICINE FOR IV COURSE STUDENTS

M. Yabluchansky, L. Bogun, L. Martymianova, O. Bychkova, N. Lysenko, M. Brynza  
V.N. Karazin National University Medical School' Internal Medicine Dept.





# US MLE TEST

A 32-year-old man presents to his primary care doctor with the concern of fatigue and pain upon defecation. He denies any diarrhea or constipation, but notes that for the last two months he is having pain with passing stool. He notes a similar episode that occurred approximately one year ago. On exam, you note a horizontal anal fissure. Exam of his oral cavity is shown in Image A. Which of the following is the most appropriate step in management?

1. Reassurance that these lesions are self-limited,
2. Lateral internal sphincterotomy,
3. Upper and lower endoscopy,
4. Topical steroid ointment ,
5. HIV testing .

# US MLE TEST EXPLANATION

The correct answer is 3. The combination of an anal fissure in an aberrant location with aphthous ulcers in the oral mucosa is very suspicious for Crohns disease. The diagnosis is made by noting focal, asymmetric, transmural, or granulomatous features on endoscopy, radiography, and pathology, which can be acquired by upper and lower endoscopy.

Incorrect Answers:

1: This patient is likely suffering from Crohns disease, a chronic disease without curative therapy with a variable course, 2: A lateral internal sphincterotomy is used in the management of patients with recurrent or chronic idiopathic anal fissures, 4: Topical steroid ointment has no role in the treatment of aphthous ulcers or anal fissures, 5: While oral lesions can be suggesting an immunocompromised state, the more commonly seen manifestations are oral candidiasis or HSV or CMV esophagitis.

# Definition

Crohn's disease, Celiac disease 1

- Crohn's disease encompasses a multisystem group of autoimmune inflammatory disorders with specific clinical and pathological features characterized by focal, asymmetric, transmural, and, occasionally, granulomatous inflammation primarily affecting the gastrointestinal tract

# Definition

Crohn's disease, Celiac disease 2

- Celiac disease (gluten-sensitive enteropathy) is an autoimmune inflammatory disorder of the small intestine that is precipitated by the ingestion of gluten, a component of wheat protein, in genetically susceptible persons and it is the result of the interaction between genetic and environmental factors.

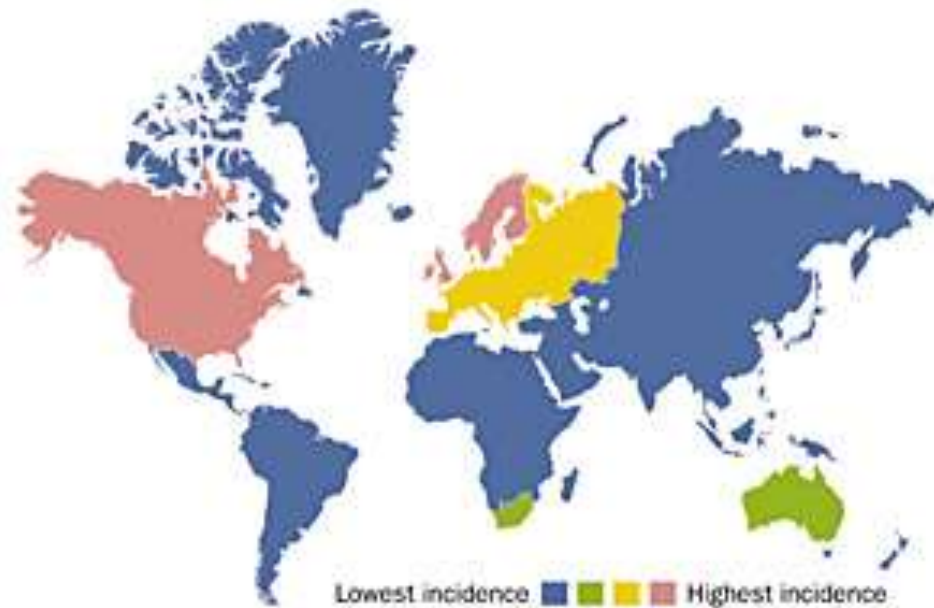# Epidemiology

## Crohn's disease, Celiac disease

- Crohn's disease with potential for systemic and extraintestinal complications can affect any age group, but the onset (diagnosis) is most common in the second and third decades; the incidence and prevalence in developed countries estimated to be 5/100,000 and 50/100,000, respectively.
- The prevalence of celiac disease is approximately one case per 250 persons.

# Epidemiology

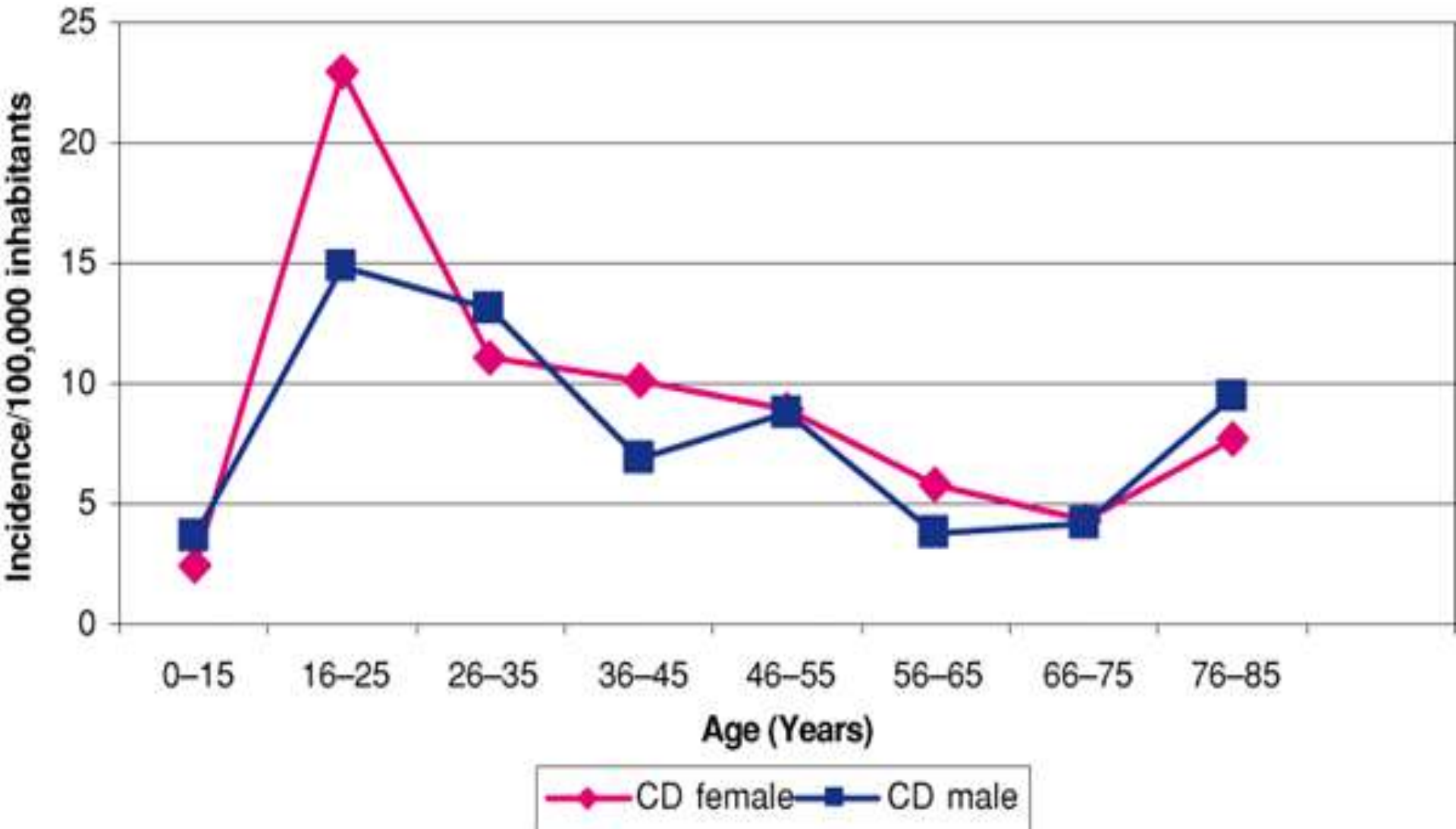
## Geographic Distribution of Crohn's disease





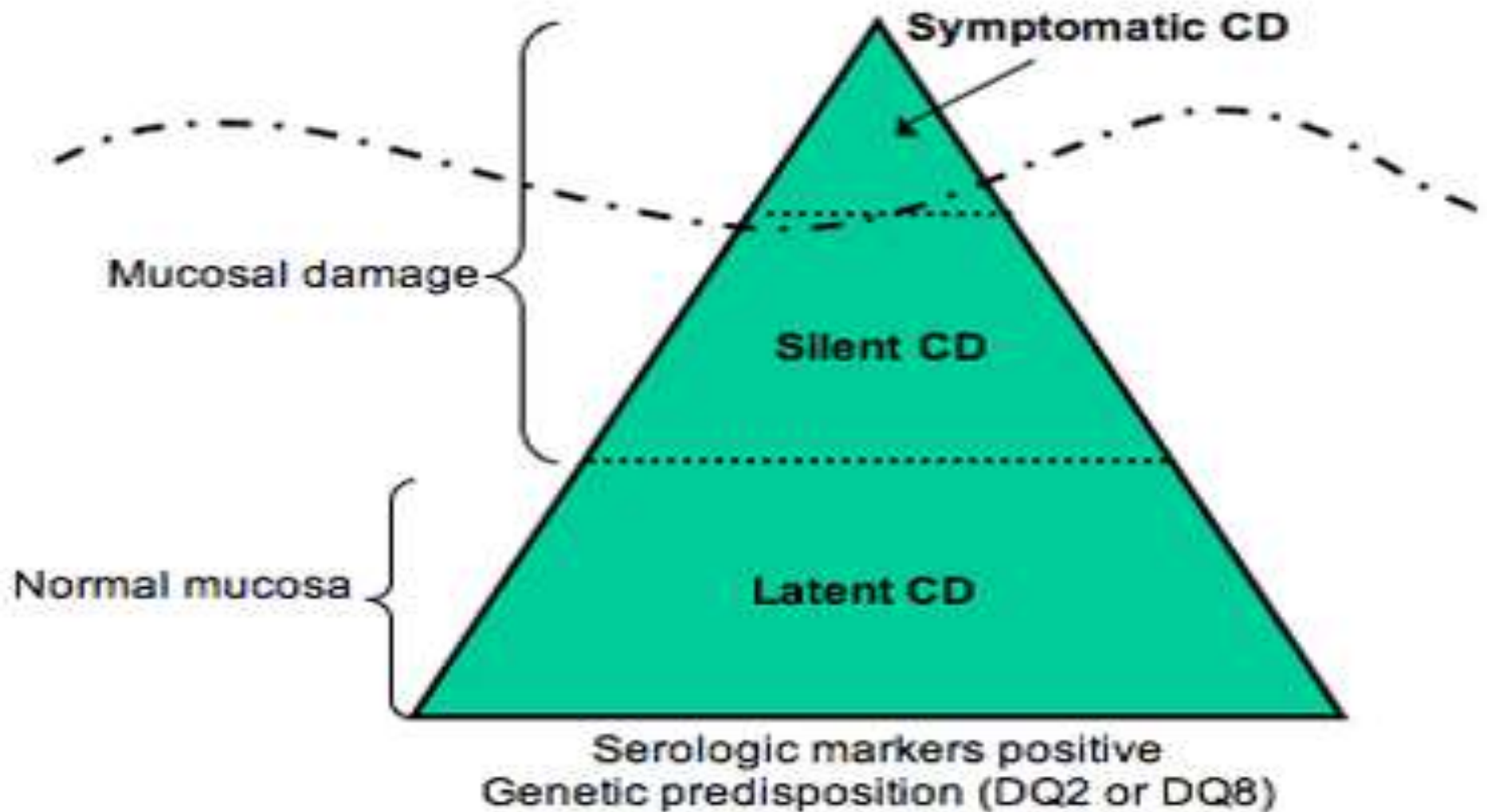
# Epidemiology

## Aged distribution of Crohn's disease



# Epidemiology

## The Celiac Disease Iceberg



# Risk Factors & Etiology

Crohn's disease, Celiac disease 1

- The causes of Crohn's disease are not known, and a malfunctioning immune system, genetics, and environment may all play a part; risk factors may include (young) age, ethnicity (whites and Jews), family history (1 in 5 people with Crohn's disease has a family member with the disease), cigarette smoking, nonsteroidal anti-inflammatory medications, life in an urban area or in an industrialized country;

# Risk Factors & Etiology

Crohn's disease, Celiac disease 2

- The cause for celiac disease is unknown, and people of European descent and those with other autoimmune disorders are at increased risk for its developing; among genetic risk factors, the strongest association is with the HLA class II DQ region; nevertheless at least 39 non-HLA loci are associated with disease; gluten is the main trigger of the disease; a role for infectious agents and microbiota composition in disease development has also been proposed.

# Mechanism

## Crohn's disease 1

### Key Players

- Genetics (Crohn's disease is genetically linked to celiac disease)
- Environmental factors (the increased incidence of Crohn's in the industrialized world indicates an environmental component)

# Mechanism

## Crohn's disease 2

- Immunobiology:
  - Microbiota (a causal role for *Mycobacterium avium* subspecies *paratuberculosis*)
  - Intestinal barrier
  - Microbial sensing, innate immunity, and autophagy
  - Adaptive immunity (Crohn's disease is a primary T cell autoimmune disorder and results from an impaired innate immunity) and leucocyte migration.

# Mechanism

## Crohn's disease 3

- Chronic inflammation from T-cell activation leading to tissue injury is implicated in the pathogenesis of Crohn disease
- The initial lesion starts as a focal inflammatory infiltrate around the crypts, followed by ulceration of superficial mucosa
- Inflammatory cells invade the deep mucosal layers and, in that process, begin to organize into noncaseating granulomas

# Mechanism

## Crohn's disease 4

- The granulomas extend through all layers of the intestinal wall and into the mesentery and the regional lymph nodes
- Neutrophil infiltration into the crypts forms crypt abscesses, leading to destruction of the crypt and atrophy of the colon
- Transmural inflammation results in thickening of the bowel wall and narrowing of the lumen



# Mechanism

## Crohn's disease 5

- Ulcerations are common and are often seen on a background of normal mucosa
- As disease progresses, it is complicated by obstruction or deep ulceration leading to fistulization by way of the sinus tracts penetrating the serosa, microperforation, abscess formation, and malabsorption

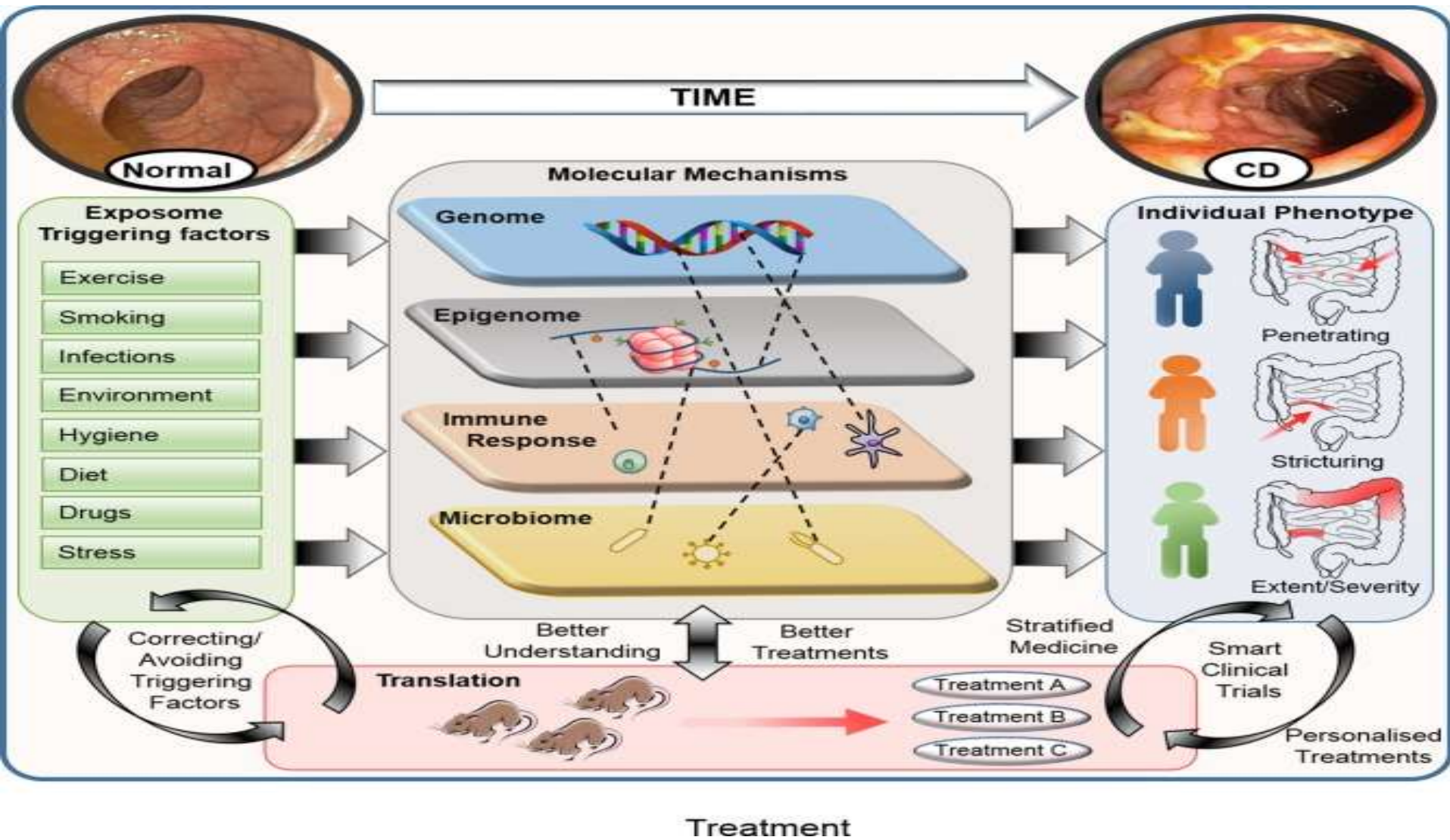
# Mechanism

## Crohn's disease 6

- Obstruction is intermittent and can often be reversed by means of conservative measures and anti-inflammatory agents but with further disease progression becomes chronic because of fibrotic scarring, luminal narrowing, and stricture formation
- Serosal inflammation causes adhesions; thus, free perforations are less common in Crohn disease than in other inflammatory bowel conditions.

# Mechanism

## Factors contributing to Crohn's disease



# US MLE TEST

A 34-year-old male with a history of Crohn's disease presents with recent onset periumbilical abdominal pain, weight loss, and fever. On physical exam he is noted to have a palpable abdominal mass in the right lower quadrant. What is the appropriate next step in management? \_

1. Administration of corticosteroids,
2. Administration of methotrexate or azathioprine,
3. Abdominal plain film,
4. Abdominal CT,
5. Surgical consult.

# US MLE TEST EXPLANATION

The correct answer is 4. In a patient with Crohn's disease a palpable mass is concerning for an abdominal abscess and computed tomography (CT) is the diagnostic test of choice.

Incorrect Answers:

1: Corticosteroids are an effective therapy for Crohn's exacerbations, but would be dangerous to give in the setting of an intra-abdominal abscess.

2: Immunosuppressants are used to induce remission in Crohn's disease but would also be dangerous to administer in the setting of an intra-abdominal abscess.

3: An abdominal plain film would be unable to either diagnose or rule out an intra-abdominal abscess.

5: A surgical consult would only be required if the abscess were diagnosed by CT. Moreover, requesting a consult is almost never the answer on NBME exams.

# Mechanism

## Celiac disease 1

- Celiac disease results from genetic abnormal immune response to gluten that leads to local activation of immune system
- As a result of immunological reactions with significant role of T lymphocytes (non proliferative activation of lamina propria CD4+ lymphocytes and proliferative activation of intra-epithelial TcR alpha/beta CD8+ and TcR gamma/delta lymphocytes ) the inflammatory process with typical histopathological lesions develops

# Mechanism

## Celiac disease 2

- In immunological reaction to gluten besides T lymphocytes other cells are involved (lymphocytes B, natural killer cells (NK), neutrophils, eosinophils, macrophages, mastocytes)
- This intense local inflammatory reaction produces the villous flattening characteristic of gluten-sensitive enteropathy

# Mechanism

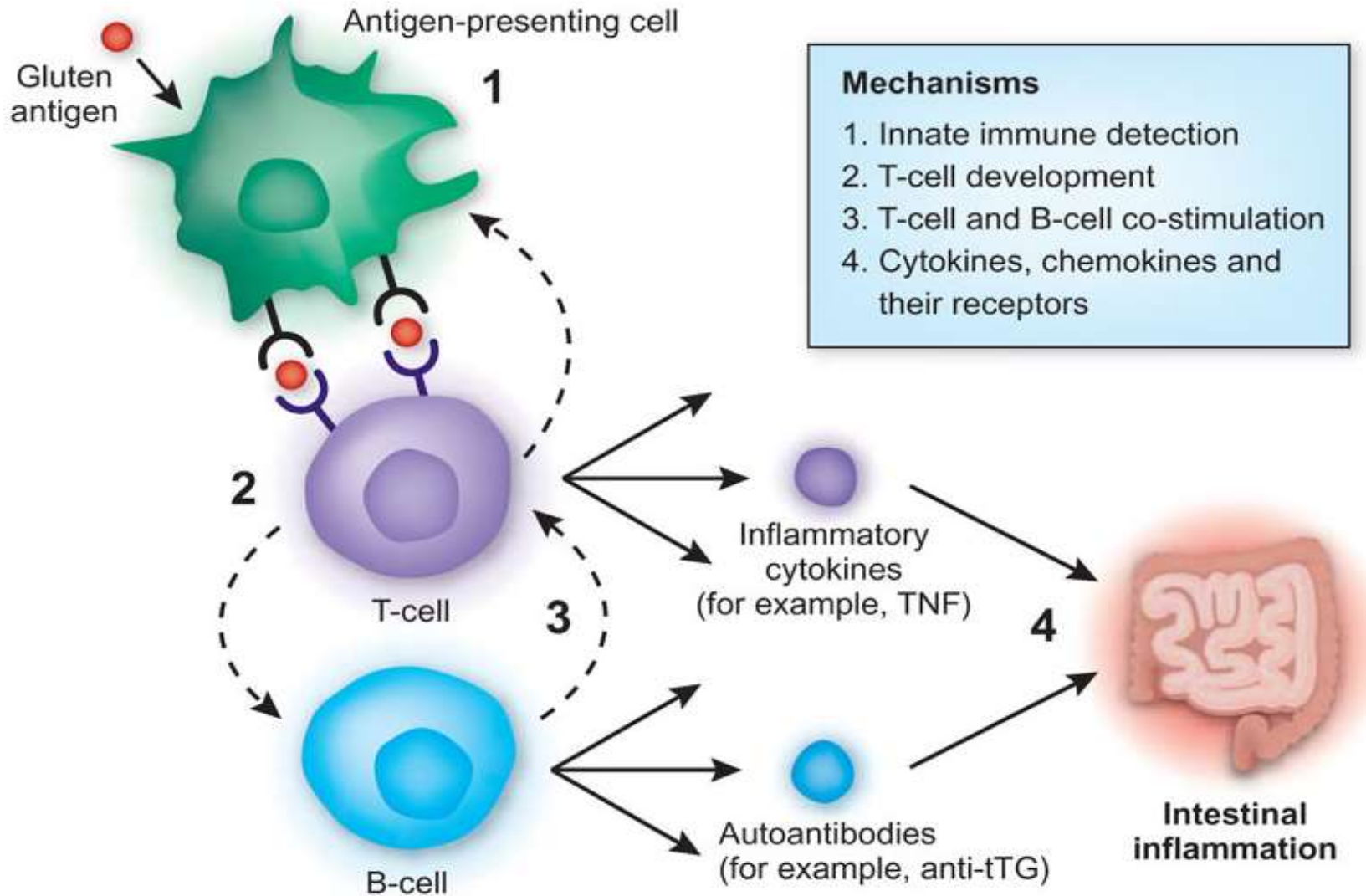
## Celiac disease 2

- Malabsorption of micronutrients (e.g., vitamins and minerals) and macronutrients (e.g., protein, carbohydrate, fat) follows
- Small-bowel involvement is most prominent proximally and may be “patchy,” especially in patients with “silent” celiac disease (i.e., minimal or no symptoms) and those with dermatitis herpetiformis
- About 95% of patients with celiac disease exhibit specific Human Leukocyte Antigen (HLA) class II alleles DQA1\*0501 and DQB1\*0201
- Patients with type 1 diabetes, autoimmune thyroid disease, Sjögren's syndrome, primary biliary cirrhosis, Addison's disease, systemic lupus erythematosus, selective IgA deficiency, and alopecia areata may also exhibit similar genotypes and are at risk for gluten-sensitive enteropathy.



# Mechanism

## Genetic Pathways of Celiac disease



# US MLE TEST

A 22-year-old Caucasian female presents with severe right lower quadrant pain, malaise, and diarrhea. The physician performs an endoscopy and finds disease involvement in the terminal ileum, noting that the disease process is patchy with normal intervening mucosa. The entire wall of the region is thickened and inflamed, which may directly lead to formation of:

1. Fistulas,
2. Toxic megacolon,
3. Widening of the intestinal lumen,
4. Plummer-Vinson syndrome,
5. Paneth cell metaplasia.

# US MLE TEST EXPLANATION

The correct answer is 1. Fistulas due to transmural inflammation are a common feature of Crohn's disease. Involvement may be throughout the gastrointestinal system but commonly near the terminal ileum. Common symptoms include malaise, diarrhea, weight loss, and abdominal discomfort.

Incorrect Answers:

2: Toxic megacolon would be more consistent with ulcerative colitis

3: Stricture formation (narrowing of the lumen), not widening of the lumen, is more consistent with Crohn's disease.

4: Plummer-Vinson syndrome (esophageal webs, iron-deficiency, and glottitis) is not consistent with Crohn's disease.

5: Though paneth cell metaplasia can occur in Crohn's disease, it is not a direct consequence of transmural thickening.

# Classification

## International Classification of Diseases


XI Diseases of the digestive

K50-K52 Noninfective enteritis and colitis

K50.0 Crohn disease of small intestine

K90-K93 Other diseases of the digestive system

K90.0 Celiac disease



# Classification

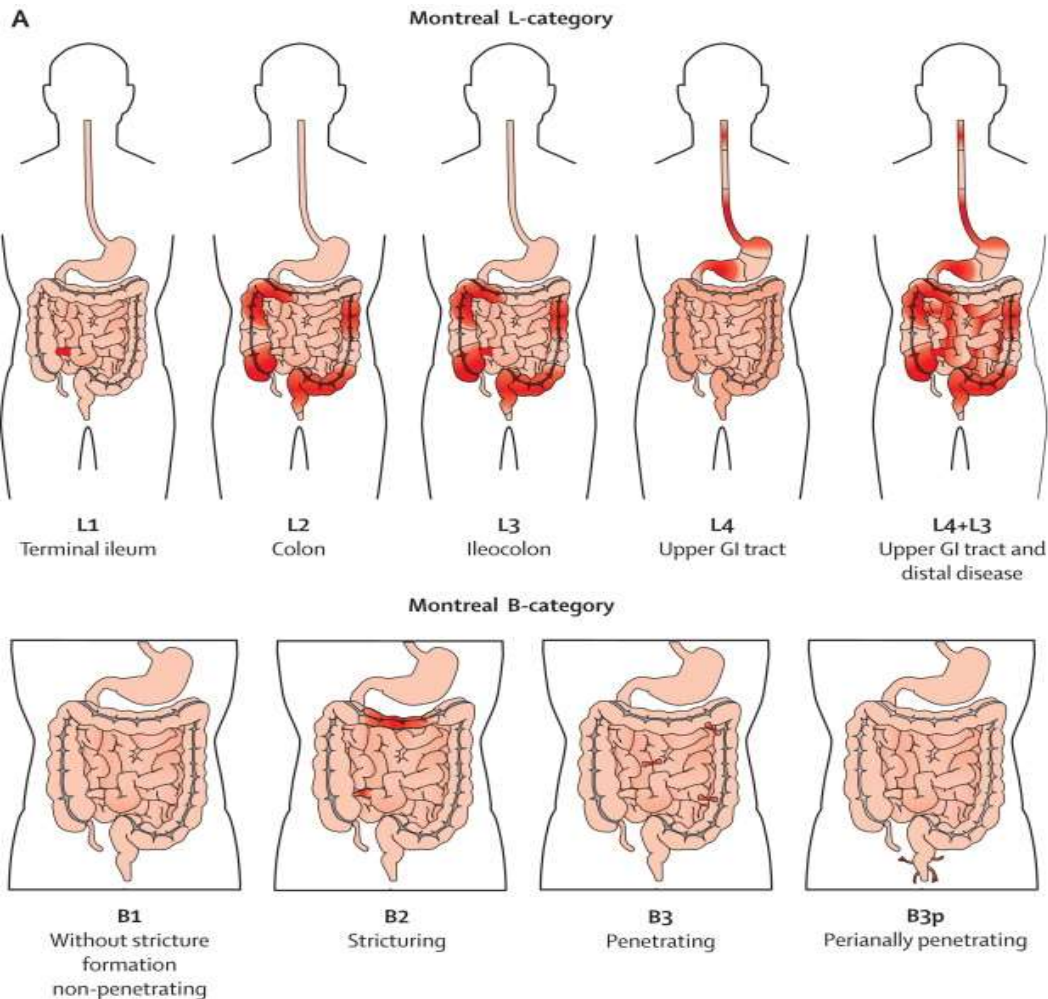
## Vienna and Montreal classification for Crohn's disease

	Vienna (1998)	Montreal (2005)
Age at diagnosis	A1 below 40 y	A1 below 16 y
	A2 above 40 y	A2 between 17 and 40 y
		A3 above 40 y
Location	L1 ileal	L1 ileal
	L2 colonic	L2 colonic
	L3 ileocolonic	L3 ileocolonic
	L4 upper	L4 isolated upper disease
Behaviour	B1 non-stricturing, non-penetrating	B1 non-stricturing, non-penetrating
	B2 stricturing	B2 structuring
	B3 penetrating	B3 penetrating
		p perianal disease modifier

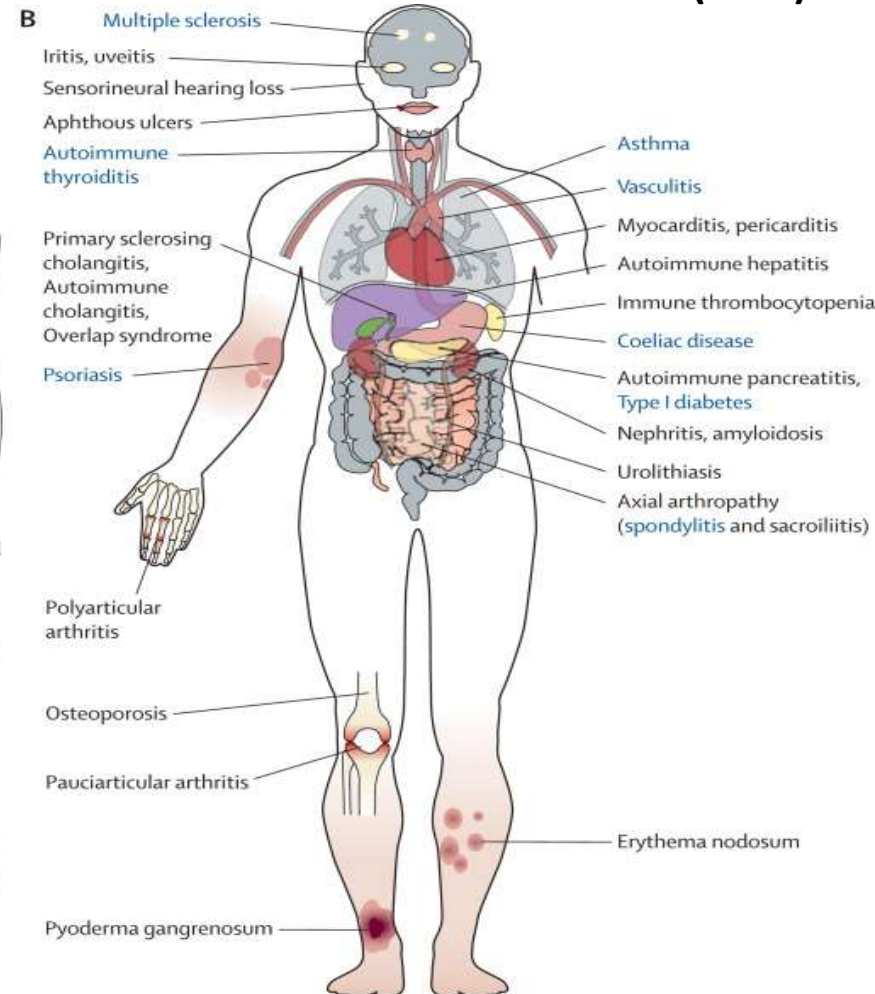
# Classification

## Phenotype of Crohn's disease

### Montreal classification



### Major extraintestinal manifestations and associated autoimmune disorders (blue)





# Classification

## The Crohn's Disease Activity

<b>Classification</b>	<b>Patient Activity and Common Characteristics</b>
Mild-to-moderate	Patient tolerates oral alimentation without dehydration, abdominal pain, obstruction, toxicity, or weight loss >10%
Moderate-to-severe	Patient nonresponsive to treatment of mild-to-moderate disease; has fever, weight loss, abdominal pain, nausea and vomiting (without obstructive findings), or significant anemia
Severe-fulminant	Patient receiving steroids and experiencing persistent symptoms; presents with high fever, significant weight loss, persistent vomiting, intestinal obstruction, rebound tenderness, cachexia, or abscess formation
Remission	Patient asymptomatic, no inflammatory complications, or response to acute medical intervention (CDAI <150).

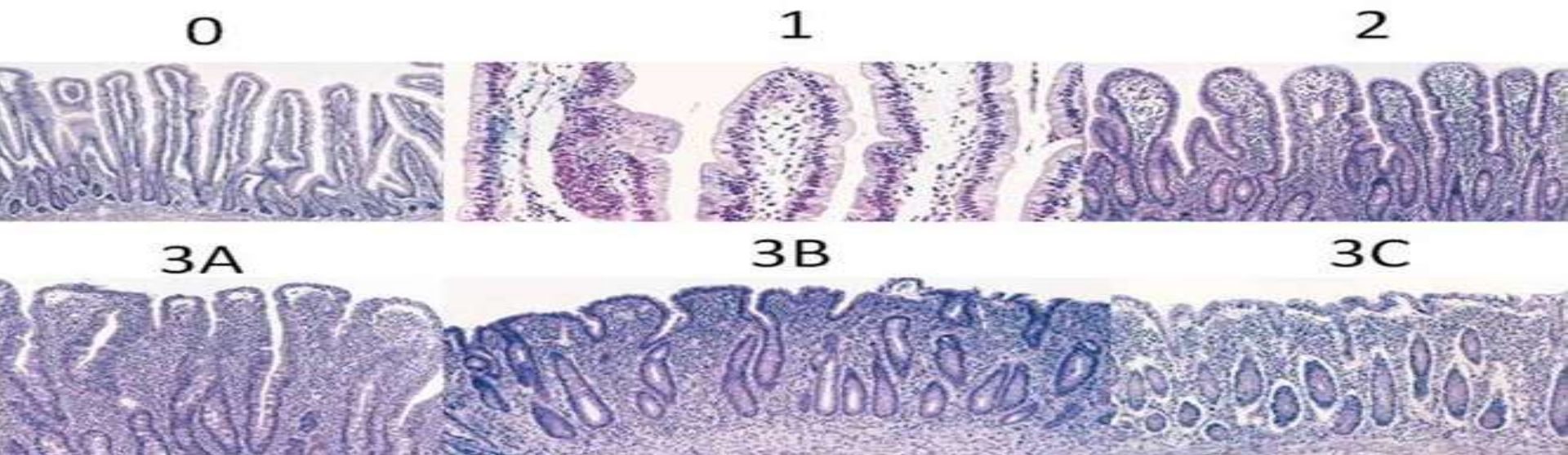
*CDAI: Crohn's Disease Activity Index. Source: References 19, 20.*

# Classification

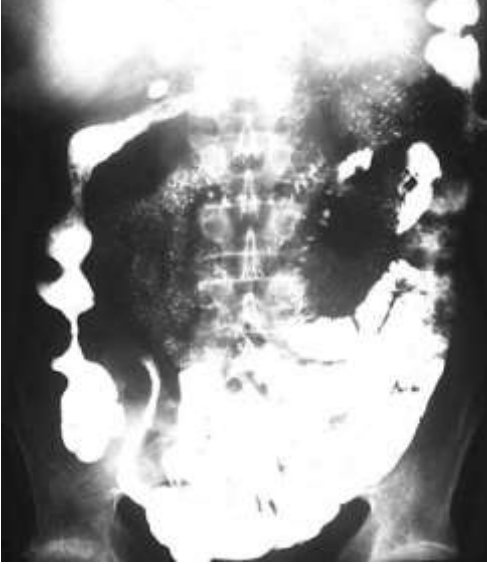## Marsh Grading of Celiac Disease

### Marsh grade

- |    |   |
|----|---|
| 0  | Normal mucosa   |
| 1  | Increased number of intraepithelial lymphocytes, usually exceeding 20 per 100 enterocytes |
| 2  | Proliferation of the crypts of Lieberkuhn   |
| 3  | Variable villous atrophy  |
| 3a | Partial villous atrophy   |
| 3b | Subtotal villous atrophy  |
| 3c | Total villous atrophy   |
| 4  | Hypoplasia of the small bowel architecture  |







# USMLE TEST

A 28-year-old Caucasian woman with a 10 pack-year history of smoking presents with diarrhea and right, lower quadrant colicky pain. You note tender, red nodules on her shins. Radiograph imaging after barium study is shown in Figure A. What is the most likely diagnosis?

1. Ulcerative colitis,
2. Irritable bowel syndrome,
3. Celiac disease,
4. Hirschsprung disease,
5. Crohn's disease.

# US MLE TEST EXPLANATION

The correct answer is 5. The clinical scenario and radiograph findings are consistent with Crohn's disease. Crohn's disease is a subtype of inflammatory bowel disease due to an inappropriate immune response against intestinal bacteria. In contrast to ulcerative colitis, Crohn's affects the entire length of the GI tract and the GI wall in its entirety. Fistula and stricture formation lead to the obstructive symptoms of colicky pain and the characteristic "string" sign on barium swallow.

Incorrect Answers:

1: Ulcerative colitis involves only the colon and has a characteristic "lead pipe" appearance on radiography, 2: Irritable bowel syndrome is defined by chronic cycling abdominal pain without any structural abnormalities, 3: Celiac disease is an autoimmune reaction against gliadin in wheat that causes malabsorption, 4: In Hirschsprung disease, failed neural crest cell migration results in an aganglionic distal colon that cannot relax.

# Signs and Symptoms

## Crohn's disease 1

- The characteristic presentation is abdominal pain and diarrhea, which may be complicated by intestinal fistulization or obstruction
- Other signs and symptoms of Crohn disease may include rectal bleeding; fever; weight loss, anorexia; nausea, vomiting; malnutrition, vitamin deficiencies; generalized fatigability; bone loss

# Signs and Symptoms

## Crohn's disease 2

- Psychosocial issues (e.g., depression, anxiety, and coping difficulty); pediatric patients may also experience psychological issues regarding quality of life and body image
- Growth failure in pediatric patients: may precede gastrointestinal symptoms by years.

# Signs and Symptoms

## Celiac Disease 1

- In infancy disease manifests as failure to thrive, diarrhea, abdominal distention, and developmental delay
- In adults, gastrointestinal tract involvement may manifest as diarrhea, constipation, or other symptoms of malabsorption (bloating, flatus, or belching)

# Signs and Symptoms

## Celiac Disease 2

- Fatigue, depression, fibromyalgia-like symptoms, aphthous stomatitis, bone pain, dyspepsia, gastroesophageal reflux, etc.
- Women comprise approximately 75 % of newly diagnosed disease cases and tend to have more clinically conspicuous disease.

# History

## Crohn's disease 1

- Patients with suspected Crohn disease should be evaluated initially by their primary care team, and symptoms should be elicited in detail
- Obtain a complete medical, surgical, social, and family history, and perform a detailed review of systems

# History

## Crohn's disease 2

- Preliminary laboratory data (e.g., inflammatory and anemia markers) may be helpful
- If Crohn disease is suspected, the patient should be promptly referred to a gastroenterologist for consultation.



# History

## Celiac Disease 1

- The manifestations of untreated celiac disease can be divided into gastrointestinal symptoms and extraintestinal symptoms
- Gastrointestinal symptoms include diarrhea due to maldigestion and malabsorption of nutrients (watery or semifformed stools, steatorrhea, flatulence, borborygmus, weight loss, weakness and fatigue, severe abdominal pain)

# History

## Celiac Disease 2

- Extraintestinal symptoms include anemia, a bleeding diathesis, osteopenia and osteoporosis, neurologic symptoms (motor weakness, paresthesias with sensory loss, and ataxia), skin disorders (including dermatitis herpetiformis), hormonal disorders (amenorrhea, delayed menarche, and infertility in women and impotence and infertility in men).

# US MLE TEST

A 27-year-old female has a history of periodic bloody diarrhea over several years. Colonoscopy shows rectosigmoid inflammation, and the patient complains of joint pain in her knees and ankles. You suspect inflammatory bowel disease. Which of the following would suggest a diagnosis of Crohn's disease:

1. Left lower quadrant pain,
2. Jaundice,
3. Loss of large bowel haustra,
4. Mucosal and submucosal ulcerations,
5. Perianal fistula.

# US MLE TEST EXPLANATION

The correct answer is 5. Fistulas between the bowel and several structures, including perianal skin, the bladder, other parts of the bowel, and the vagina, are features of Crohn's disease rather than ulcerative colitis.

Incorrect Answers:

1: Left lower quadrant pain may be present in both ulcerative colitis and Crohn's disease, 2: Both Crohn's disease and ulcerative colitis can cause biliary obstruction and jaundice. Biliary obstruction in ulcerative colitis is linked to primary sclerosing cholangitis, 3: Loss of large bowel haustra is a feature of ulcerative colitis, 4: Mucosal and submucosal ulcerations are present in ulcerative colitis. Transmural lesions are a marker for Crohn's disease.

# Physical Exam

## Crohn's disease 1

- Vital signs are usually normal, though tachycardia may be present in anemic or dehydrated patients
- Chronic intermittent fever is a common presenting sign
- Abdominal findings may vary from normal to those of an acute abdomen

# Physical Exam

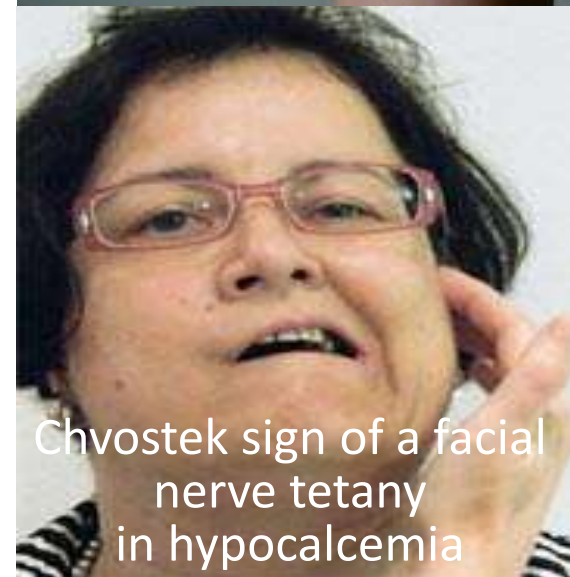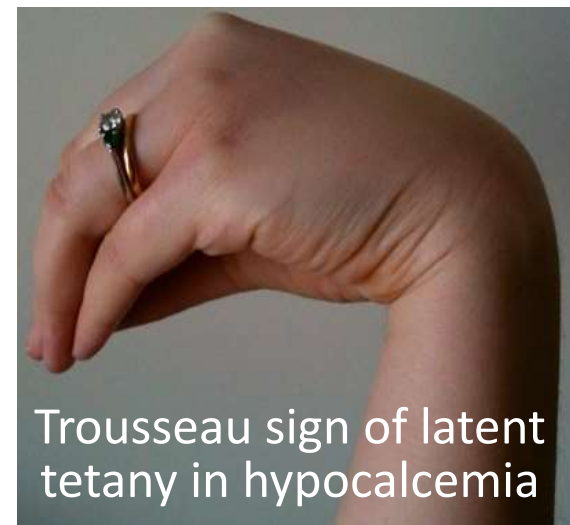## Crohn's disease 2

- In addition to local complications, various extraintestinal manifestations may be associated with Crohn disease, usually involving the skin, joints, mouth, eyes, liver, or bile ducts.

# Physical Exam

## Celiac Disease 1

- A protuberant and tympanic abdomen due to distention of intestinal loops with fluids and gas
- Weight loss, including muscle wasting or loose skin folds
- Orthostatic hypotension
- Peripheral edema



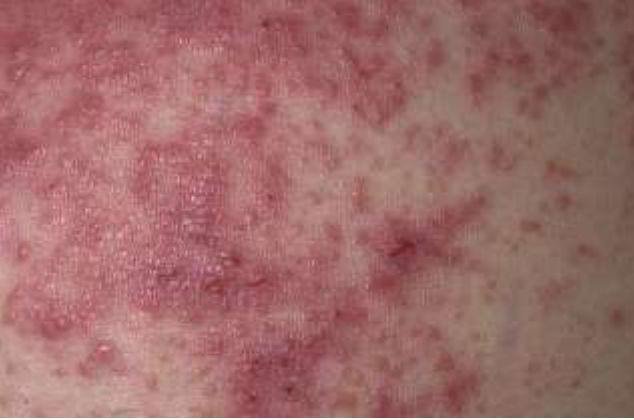# Physical Exam

## Celiac Disease 2

- Ecchymoses
- Hyperkeratosis or dermatitis herpetiformis
- Cheilosis and glossitis
- Peripheral neuropathy
- Chvostek sign or Trousseau sign.







## US MLE TEST

A 17-year-old male presents to his primary doctor complaining about an extremely itchy rash on his elbows and other extensor surfaces. This rash is shown in Figure A. Given the clinical associations of this rash, what other disease must be considered in this patient?

1. Crohn disease,
2. Ulcerative colitis,
3. Celiac disease,
4. Juvenile rheumatoid arthritis,
5. Systemic lupus erythematosus.

# US MLE TEST EXPLANATION

The correct answer is 3. The dermatologic lesion pictured is most consistent with dermatitis herpetiformis (DH). DH is associated with gluten sensitivity, and is a skin manifestation of celiac disease.

Incorrect Answers:

1: Crohn's disease is associated with erythema nodosum, 2: Ulcerative colitis is associated with pyoderma gangrenosum, 4: Juvenile rheumatoid arthritis, Still's disease, is associated with a salmon-pink macular rash usually on the trunk, 5: Patients with SLE may have a number of different skin conditions. A commonly tested rash is the "butterfly" or malar rash on their face.

# Complications

## Crohn's disease 1

- The major significant complications include intestine obstruction, abscesses, free perforation and hemorrhage, which in rare cases may be fatal
- Obstruction occurs from strictures or adhesions that narrow the lumen, blocking the passage of the intestinal contents

# Complications

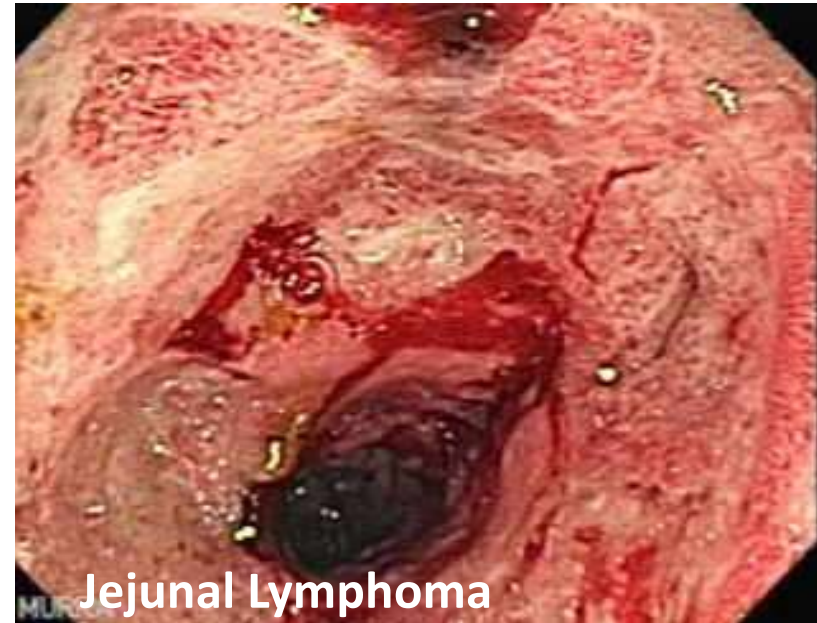
## Crohn's disease 2

- A fistulae develop between two loops of bowel, between the bowel and bladder, between the bowel and vagina, and between the bowel and skin
- Abscesses are walled off concentrations of infection, which can occur in the abdomen or in the perianal area
- Crohn's disease also increases the risk of cancer in the area of inflammation.

# Complications

## Celiac Disease

- Iron deficiency
- Lower prevalence of sexual satisfaction
- Osteoporosis
- Malignancy (lymphomas, carcinomas)



# Diagnosis

## Examination for Crohn's disease 1

- Vital signs: normal, but possible presence of tachycardia in anemic or dehydrated patients; possible chronic intermittent fever
- Gastrointestinal: may vary from normal to those of an acute abdomen
- Genitourinary: may include presence of skin tags, fistulae, ulcers, abscesses, and scarring in the perianal region; nephrolithiasis, hydronephrosis, and enterovesical fistulae

# Diagnosis

## Examination for Crohn's disease 2

- Musculoskeletal: possible arthritis and arthralgia
- Dermatologic: may show pallor or jaundice, mucocutaneous or aphthous ulcers, erythema nodosum, and pyoderma gangrenosum
- Ophthalmologic: may reveal episcleritis; possible uveitis
- Growth delay: decreased growth velocity (eg, height), pubertal delay
- Hematologic: hypercoagulable state.

# Diagnosis

## Laboratory Tests, Imaging studies and Procedures in Crohn's disease 1

- Routine laboratory studies include CBC count, chemistry panel, liver function tests, inflammatory markers, stool studies, serologic tests; they may be used as surrogate markers for inflammation and nutritional status and to screen for deficiencies of vitamins and minerals



# Diagnosis

## Laboratory Tests, Imaging studies and Procedures in Crohn's disease 2

- Imaging studies include plain abdominal radiography, barium contrast studies, computed tomography (CT) and magnetic resonance imaging (MRI), nuclear imaging, fluorine-18-2-fluoro-2-deoxy-D-glucose scanning combined with positron emission tomography, etc.

# Diagnosis

## Laboratory Tests, Imaging studies and Procedures in Crohn's disease 3

- Procedures include endoscopic visualization and biopsy, colonoscopy, ileocolonoscopy, small bowel enteroscopy, interventional radiology.

# Diagnosis

## Blood Tests in Crohn's disease 1

- CBC may reveal anemia, which is caused by blood loss leading to iron deficiency or by vitamin B12 deficiency, caused by ileal disease impairing vitamin B12 absorption
- Serum iron, total iron binding capacity and transferrin saturation may be more easily interpreted in inflammation
- Erythrocyte sedimentation rate (ESR) and C-reactive protein help assess the degree of inflammation

# Diagnosis

## Blood Tests in Crohn's disease 2

- Testing for *Saccharomyces cerevisiae* antibodies (ASCA) and antineutrophil cytoplasmic antibodies (ANCA) help differentiate Crohn's disease from ulcerative colitis
- Low serum levels of vitamin D are associated with Crohn's disease
- Increasing levels of antilaminaribioside, antichitobioside, etc. may aid in the prognosis of Crohn's disease.

# US MLE TEST

A 17-year-old male presents to his primary doctor complaining about an extremely itchy rash on his elbows and other extensor surfaces. This rash is shown in Figure A. Given the clinical associations of this rash, what other disease must be considered in this patient?

1. Crohn disease,
2. Ulcerative colitis,
3. Celiac disease,
4. Juvenile rheumatoid arthritis,
5. Systemic lupus erythematosus.

# US MLE TEST EXPLANATION

The correct answer is 3. The dermatologic lesion pictured is most consistent with dermatitis herpetiformis (DH). DH is associated with gluten sensitivity, and is a skin manifestation of celiac disease.

Incorrect Answers:

1: Crohn's disease is associated with erythema nodosum, 2: Ulcerative colitis is associated with pyoderma gangrenosum, 4: Juvenile rheumatoid arthritis, Still's disease, is associated with a salmon-pink macular rash usually on the trunk, 5: Patients with SLE may have a number of different skin conditions. A commonly tested rash is the "butterfly" or malar rash on their face.

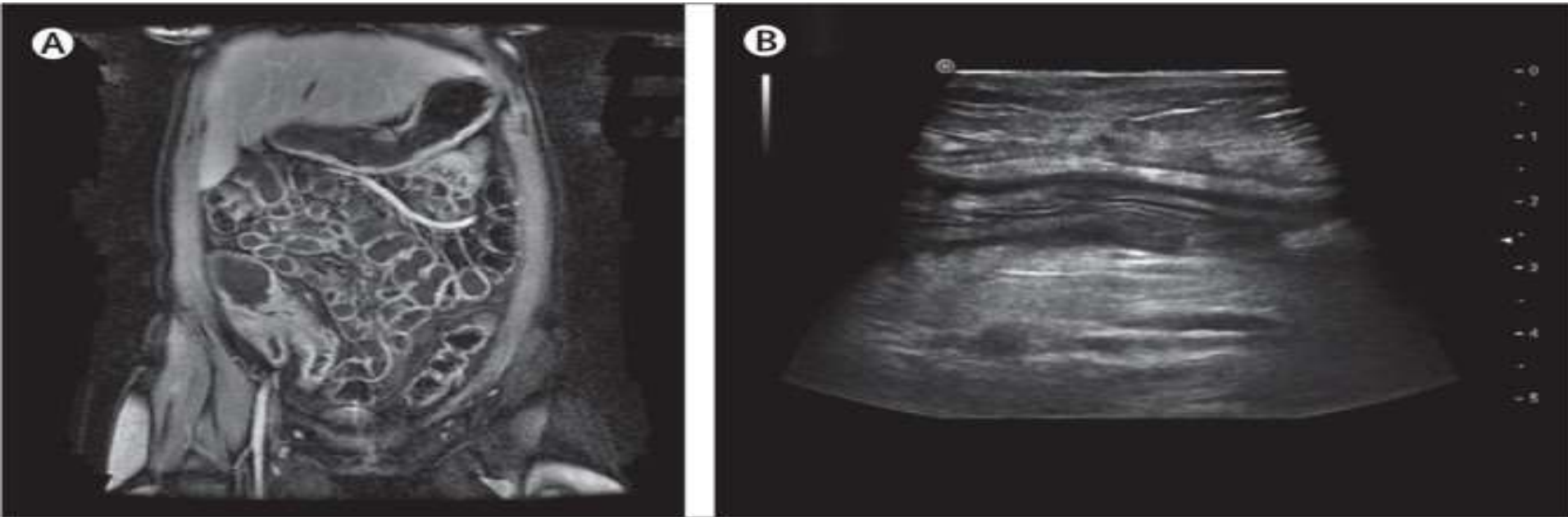
# Diagnosis

## Ordinary Findings in Crohn's disease

Terminal ileum involvement	Commonly
Colon involvement	Usually
Rectum involvement	Seldom
Bile duct involvement	No increase in rate of primary sclerosing cholangitis
Distribution of disease	Patchy areas of inflammation (skip lesions)
Endoscopy	Deep geographic and serpiginous (snake-like) ulcers
Depth of inflammation	May be transmural, deep into tissues
Stenosis	Common
Granulomas on biopsy	May have non-necrotizing non-peri-intestinal cryptgranulomas

# Diagnosis

## Stenosis in Crohn's disease

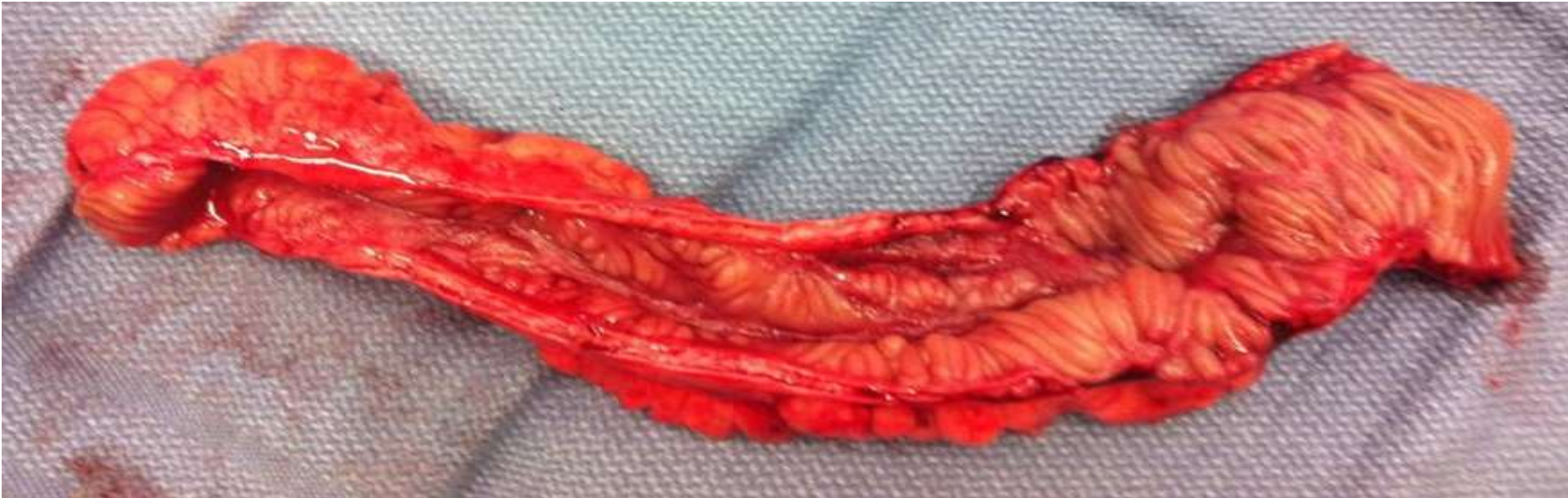

(A) MR enterography of Crohn's disease restricted to the terminal ileum (Montreal category L1) with inflammatory stenosis. (B) Ultrasound image of an intestinal stenosis in Crohn's disease.



# Diagnosis

## Ileal Crohn's disease



Resected ileum for a person with Crohn's disease.

# Diagnosis

## Serologic Tests in Celiac Disease

<i>ANTIBODY TEST</i>	<i>SENSITIVITY (%)</i>	<i>SPECIFICITY (%)</i>	<i>TIME COURSE</i>
IgA antiendomysial antibody	85 to 100	96 to 100	Antibody disappears within several months after institution of gluten-free diet.
IgA antitransglutaminase antibody	95	90	Limited data; correlated with IgA antiendomysial antibody in studies
IgA antigliadin antibody	53 to 100	65 to 100	More persistent than IgA antiendomysial antibody; may persist for 6 months or longer
IgG antigliadin antibody	57 to 100	42 to 98	Most persistent; may be detectable up to 12 months after institution of gluten-free diet  False-positive tests reported in patients with Crohn's disease, wheat-protein allergy, and postdiarrhea states

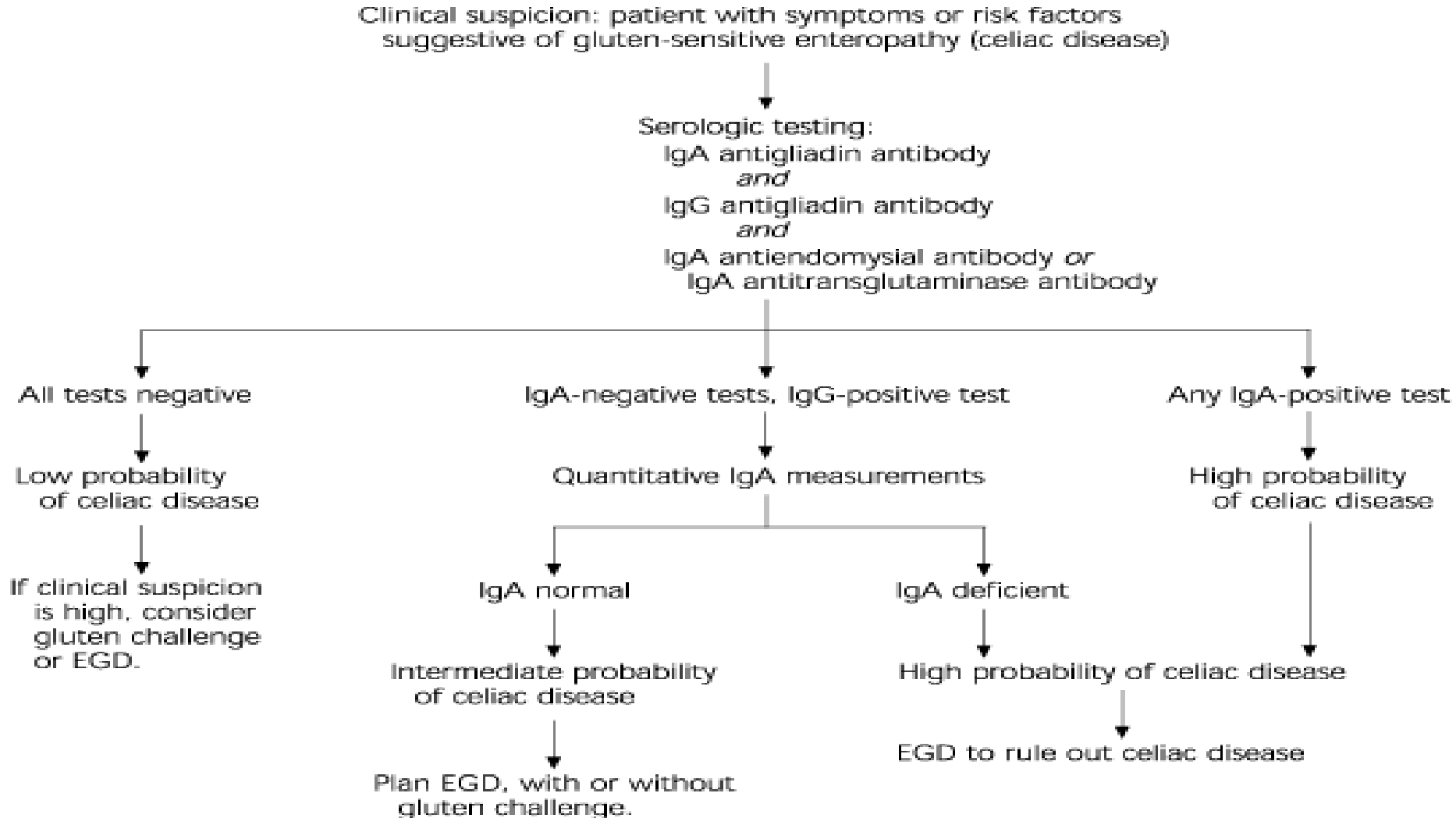
# Diagnosis

## Abnormal Laboratory Findings in Celiac Disease

<i>LABORATORY FINDING</i>	<i>PATHOPHYSIOLOGY</i>
Anemia	Iron deficiency; vitamin B <sub>12</sub> and/or folate deficiency
Elevated alkaline phosphatase level	Osteoporosis, osteomalacia
Elevated aspartate transaminase and alanine transaminase levels	Minimal elevation common in celiac disease; presumably autoimmune
Decreased albumin level	Malnutrition
Elevated calcium level, decreased phosphate level	Vitamin D deficiency, secondary hyperparathyroidism
Thrombocytosis, leukocytosis	General inflammatory reaction
Coagulopathy	Decreased vitamin K absorption
Low high-density and low-density lipoprotein cholesterol levels	Decreased fat absorption, decreased hepatic lipoprotein production

# Diagnosis

## Algorithm for the Diagnosis of Celiac disease



# Diagnosis

## Other Conditions with Similar Symptoms as Crohn's disease and Celiac disease

- Intestinal tuberculosis
- Behçet's disease
- Ulcerative colitis
- Nonsteroidal anti-inflammatory drug enteropathy
- Irritable bowel syndrome
- Crohn's disease (for celiac disease)
- Celiac disease (for Crohn's disease)

# US MLE TEST

A 22-year-old woman presents to her primary care physician complaining of a red, itchy rash on her elbows and shoulders for 2 months. She has no history of medical problems, and review of systems is positive only for occasional loose stools. She is appropriately prescribed dapsone, which relieves the rash within hours. What is the diagnosis? \_

1. Candida intertrigo,
2. Porphyria cutanea tarda,
3. Systemic lupus erythematosus,
4. Dermatitis herpetiformis,
5. Leprosy.

# US MLE TEST EXPLANATION

The correct answer is 4. This patient's presentation is consistent with dermatitis herpetiformis, a dermatologic manifestation of celiac disease. Dermatitis herpetiformis is a pruritic rash of extensor surfaces that occurs due to IgA deposition in the dermis. GI symptoms in patients with dermatitis herpetiformis and celiac disease are often absent, but the lesions respond to a gluten-free diet.

Incorrect Answers:

1: Candida intertrigo appears within the folds of the skin., 2: Porphyria cutanea tarda is not treated with dapsons. It does not feature abdominal pain such as is seen in the other porphyrias, 3: Systemic lupus erythematosus is not treated with dapsons, 5: Leprosy, caused by *Mycobacterium leprae* infection, is also treated with dapsons.

# Management

## Lifestyle modification in Crohn's disease 1

- Lifestyle changes reduce symptoms, including dietary adjustments, elemental diet, proper hydration, and smoking cessation
- Diets that include higher levels of fiber and fruit are associated with reduced risk, while diets rich in total fats, polyunsaturated fatty acids, meat, and omega-6 fatty acids may increase risk



# Management

## Lifestyle modification in Crohn's disease 2

- Eating small meals frequently instead of big meals
- A food diary may help with identifying foods that trigger symptoms
- Some people should follow a low dietary fiber diet
- Some find relief in eliminating casein and gluten from their diets
- Fatigue can be helped with regular exercise, a healthy diet, and enough sleep.

# Management

## Patient Education

Education of patients and their families is encouraged and is extremely important in the treatment process.

# Management

## Pharmacotherapy of Crohn's disease 1

- 5-Aminosalicylic acid derivative agents (e.g., mesalamine rectal, mesalamine, sulfasalazine, balsalazide)
- Corticosteroids (e.g., prednisone, methylprednisolone, budesonide, hydrocortisone, prednisolone)
- Immunosuppressive agents (e.g., mercaptopurine, methotrexate, tacrolimus)

# Management

## Pharmacotherapy of Crohn's disease 2

- Monoclonal antibodies (e.g., infliximab, adalimumab, certolizumab pegol, natalizumab, vedolizumab)
- Antibiotics (e.g., metronidazole, ciprofloxacin)
- Antidiarrheal agents (e.g., loperamide, diphenoxylate-atropine)
- Bile acid sequestrants (e.g., cholestyramine, colestipol)
- Anticholinergic agents (e.g., dicyclomine, hyoscyamine, propantheline).

# Management

## Surgery of Crohn's disease

- Crohn disease has no surgical cure
- Surgical management of the terminal ileum, ileocolon, and/or upper gastrointestinal tract may include resection of the affected bowel, ileocolostomy or proximal loop ileostomy, drainage of any septic foci with later definitive resection, strictureplasty, bypass endoscopic dilatation of symptomatic strictures.

# Management

## Celiac disease 1

- At present, the only effective treatment is a lifelong *gluten-free* diet
- No medication exists that will prevent damage or prevent the body from attacking the gut when gluten is present
- Strict adherence to the diet allows the intestines to heal, leading to resolution of all symptoms in most cases and, depending on how soon the diet is begun, can also eliminate the heightened risk of osteoporosis and intestinal cancer and in some cases sterility

# Management

## Celiac disease 2

- The diet can be cumbersome; failure to comply with the diet may cause relapse
- Up to 5% of people have refractory disease, which means they do not improve on a *gluten-free* diet, and if alternative causes have been eliminated, steroids or immunosuppressants (such as azathioprine) may be considered in this scenario

# Management

## Celiac disease 3

- In many countries, *gluten-free* products are available on prescription and may be reimbursed by health insurance plans
- Gluten-free products are usually more expensive and harder to find than common gluten-containing foods
- The term *gluten-free* is generally used to indicate a supposed harmless level of gluten rather than a complete absence



# Management

## Celiac disease 4

- The European Commission issued regulations in 2009 limiting the use of "*gluten-free*" labels for food products to those with less than 20 mg/kg of gluten, and "very low gluten" labels for those with less than 100 mg/kg
- In the United States, the FDA issued regulations in 2013 limiting the use of "*gluten-free*" labels for food products to those with less than 20 ppm (one part per million = one part per 1,000,000 parts, one part in  $10^6$ ) of gluten.

# US MLE TEST

A 35-year-old Caucasian female presents with anemia, malaise, bloating, and diarrhea. Past genetic testing revealed that this patient carries the HLA-DQ2 allele. The physician suspects that the patient's presentation is dietary in cause. Which of the following findings would definitively confirm this diagnosis?

1. CT scan showing inflammation of the small bowel wall,
2. Biopsy of the duodenum showing atrophy and blunting of villi,
3. Biopsy of the colon showing epithelial cell apoptosis
4. Liver biopsy showing apoptosis of hepatocytes,
5. Esophageal endoscopy showing lower esophageal metaplasia.

# US MLE TEST EXPLANATION

The correct answer is 2. The clinical presentation (anemia, malaise, bloating, and diarrhea) and the HLA-DQ2 genotype are consistent with celiac disease. Celiac disease is confirmed by a biopsy of the small intestine which shows severe atrophy and blunting of the villi along with chronic inflammatory infiltration of the lamina propria.

Incorrect Answers:

1: Although bowel wall inflammation on a CT scan may be found with celiac disease, it is not enough to confirm the diagnosis, 3: These findings would be more consistent with graft-versus-host disease, 4: Apoptosis of hepatocytes is consistent with cirrhosis, 5: Lower esophageal metaplasia is consistent with Barrett esophagus.

# Prognosis

Crohn's disease, Celiac disease 1

- Appropriate medical therapy helps patients with Crohn's disease to have a reasonable quality of life, with an overall good prognosis and an extremely low risk of a fatal outcome; most patients develop complications that require surgery, and postoperative clinical relapse occurs in a significant proportion

# Prognosis

## Crohn's disease, Celiac disease 2

- Most patients who have celiac disease begin to feel better soon after starting the *gluten-free* diet; patients who begin a strict, *gluten-free* diet immediately after diagnosis have the best chance of living a healthy and active life; full recovery can take a few months to several years.

# Prophylaxis

Crohn's disease, Celiac disease

- Crohn's disease can not be prevented
- Celiac disease can not be prevented; in the last years, several studies suggested a protective role of breast-feeding.

# Abbreviations

ANCA - antineutrophil cytoplasmic antibodies

ASCA - *Saccharomyces cerevisiae* antibodies

CT – computed tomography

ESR - Erythrocyte sedimentation rate

IBD - inflammatory bowel disease

MRI - magnetic resonance imaging

NK - natural killer cells

ppm - one part per million

# Diagnostic and treatment guidelines

[Gluten-Sensitive Enteropathy \(Celiac Disease\)](#)

[ESPEN guidelines on chronic intestinal failure in adults](#)

[Inflammatory Bowel Disease](#)

[Management of Crohn's Disease in Adults](#)

[Guidelines for the investigation of chronic diarrhea](#)

[Radiation-induced small bowel disease: latest developments and clinical guidance](#)

[Guidelines for the initial biopsy diagnosis of suspected chronic idiopathic inflammatory bowel disease](#)