

Clinical Anatomy of the Upper Limb

Kara Mudd, MSPAS, PA-C

Contents

- Bones and Joints
- Clinical Anatomy of Upper Limb Joints
- Clinical Anatomy of Upper Limb Muscles
- Clinical Anatomy of Nerve affect Upper Limb Muscles
- Special Diagnostic Tests

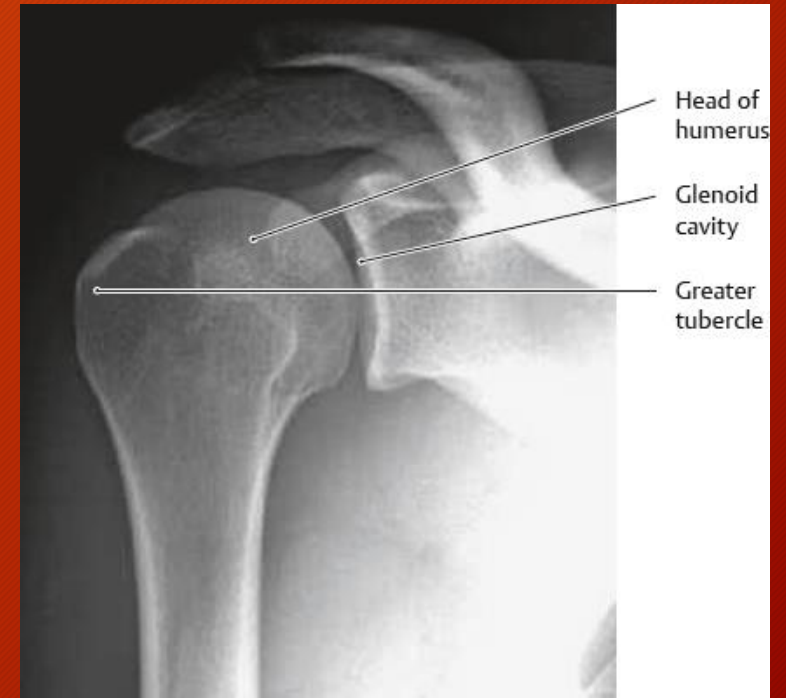
Bones and Joints of Upper Limb

Regions	Bones	Joints
Shoulder Girdle	Clavicle Scapula	Sternoclavicular Joint Acromioclavicular Joint
Bones of Arm	Humerus	Upper End: Glenohumeral Joint Lower End: See below
Bones of Forearm	Radius Ulna	Humeroradial Joint Humeroulnar Joint Proximal Radioulnar Joint Distal Radioulnar Joint
Bones of Wrist and Hand	8 Carpal Bones 5 Metacarpal 14 Phalanges	Intercarpal Joint Carpometacarpal Joint Metacarpophalangeal Joint Interphalangeal Joint

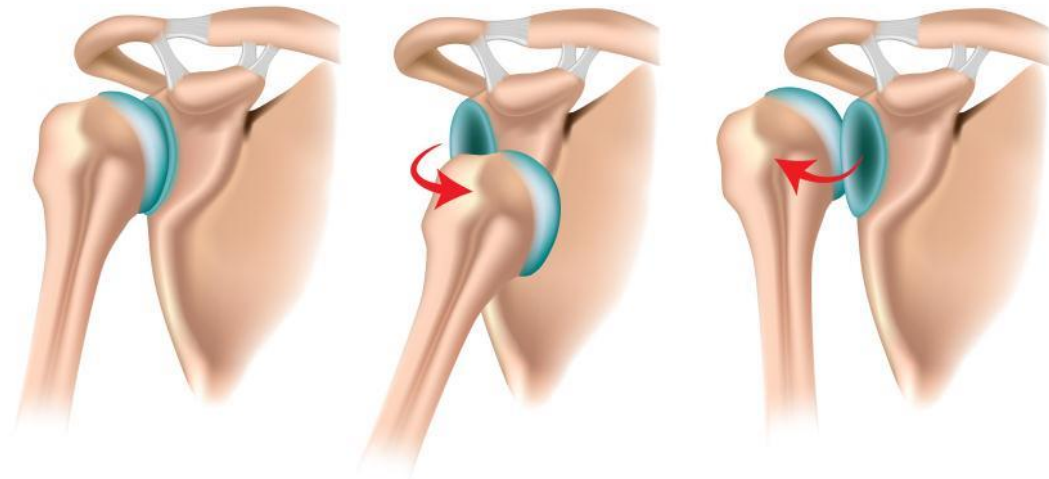
Upper Limb Joints

Glenohumeral Joint Dislocation

- Most commonly dislocated major joint in body.
 - Ball & Socket
 - Large head of humerus to shallow glenoid cavity
 - Stability depends almost entirely on the strength of surrounding muscles (Rotator Cuff).
- Commonly dislocated anteriorly and inferiorly.
 - Anteriorly shoulder joint protected by subscapularis.
 - Superiorly shoulder joint protected by supraspinatus.
 - Posteriorly shoulder joint protected by teres minor and infraspinatus.
 - Inferior aspect of shoulder joint completely unprotected.



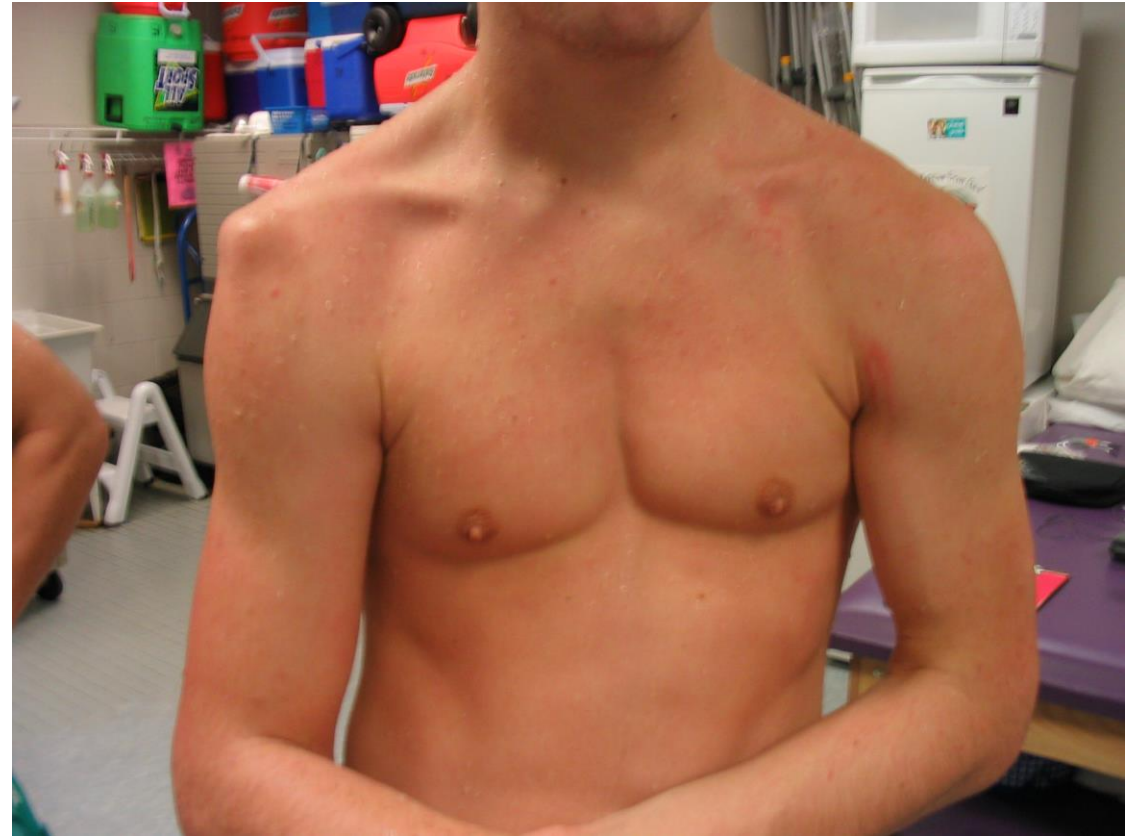Shoulder Dislocation



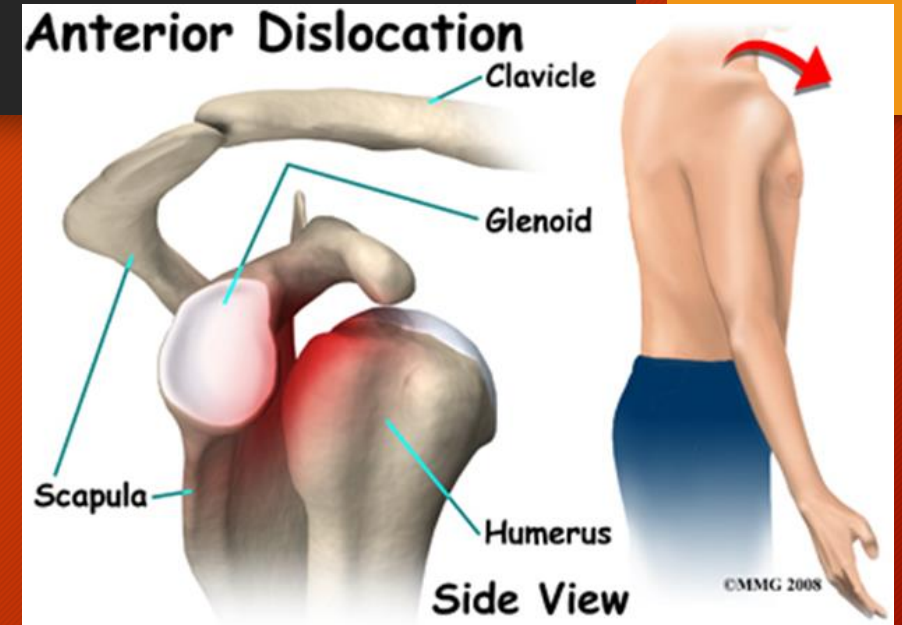
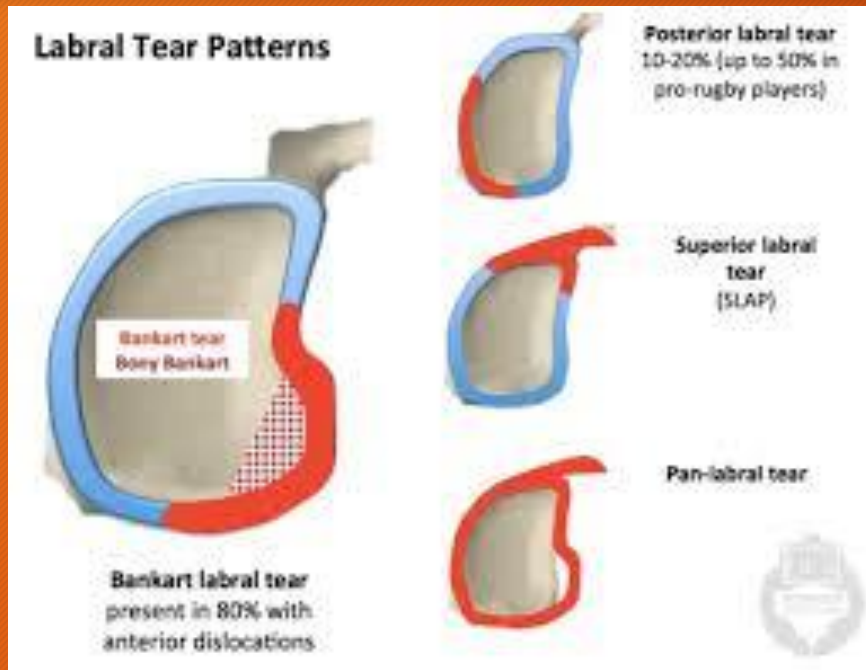
Normal
anatomy

Anterior
dislocation

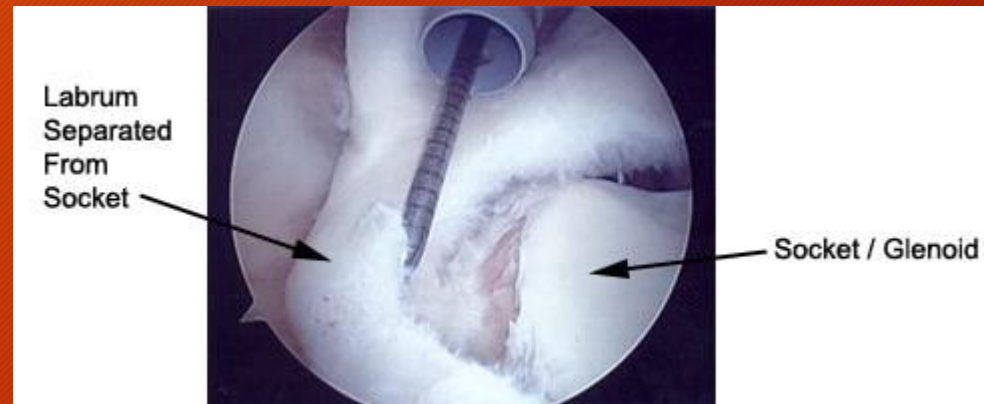
Posterior
dislocation



Glenohumeral Joint Dislocation

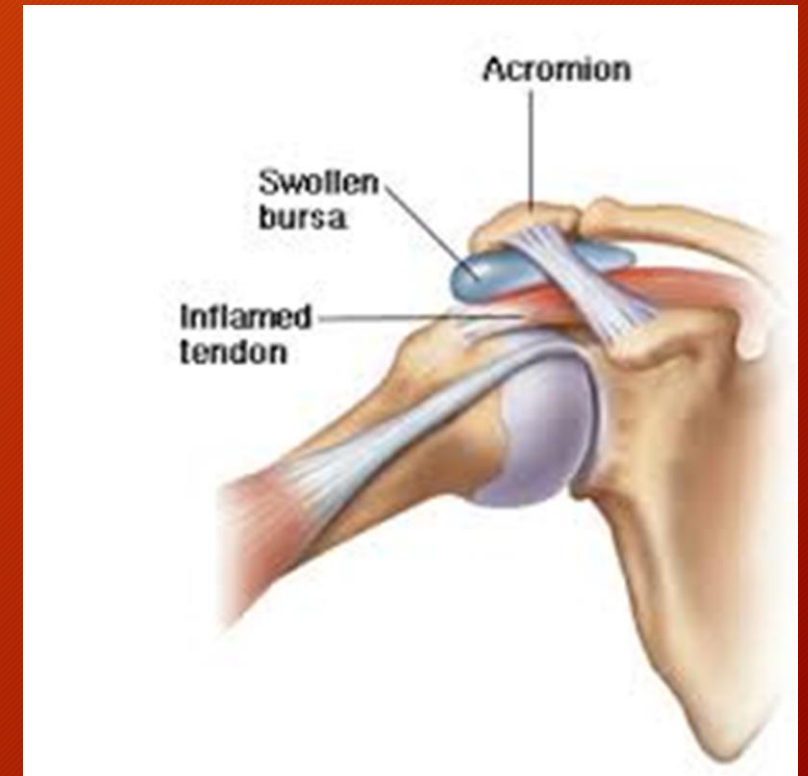

Labral tears are common with traumatic shoulder dislocations



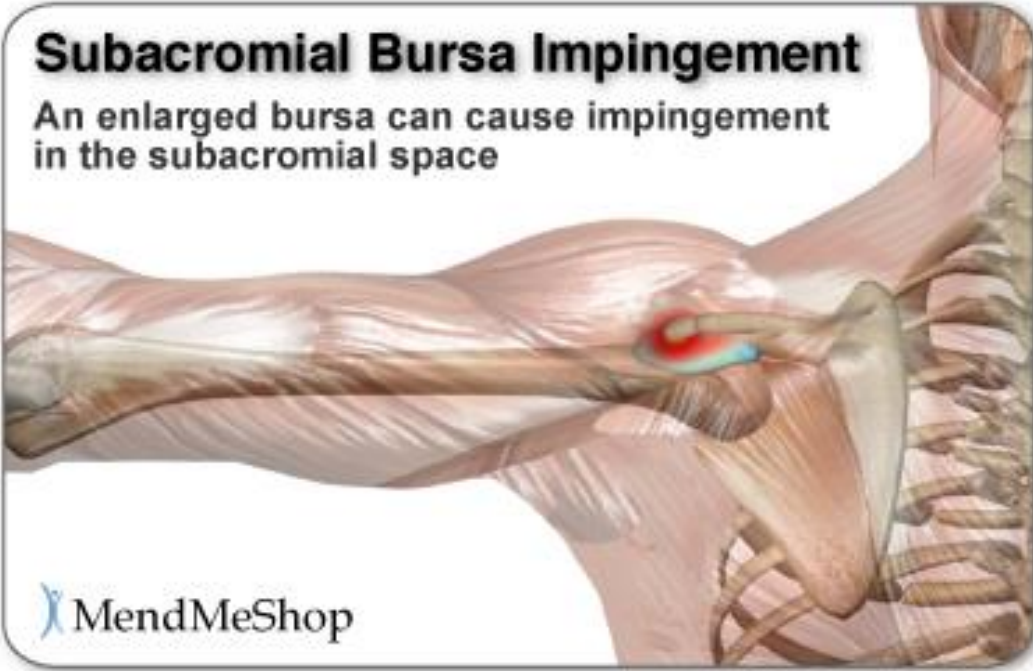Subacromial Bursitis

- Shoulder joint in abducted position = Pain
 - Subacromial bursa is located inferior to acromion, above supraspinatus tendon.
 - Pain occur when abduction because supraspinatus tendon comes in contact with inferior surface of acromion, inflammed bursa slips up underneath coraco-acromial arch and gets impinged between supraspinatus tendon and acromion.



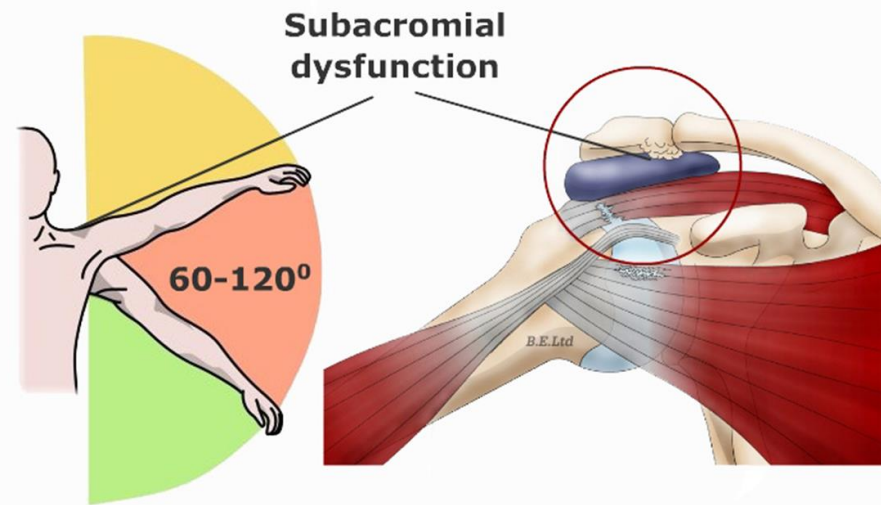
Subacromial Bursa Impingement

An enlarged bursa can cause impingement in the subacromial space



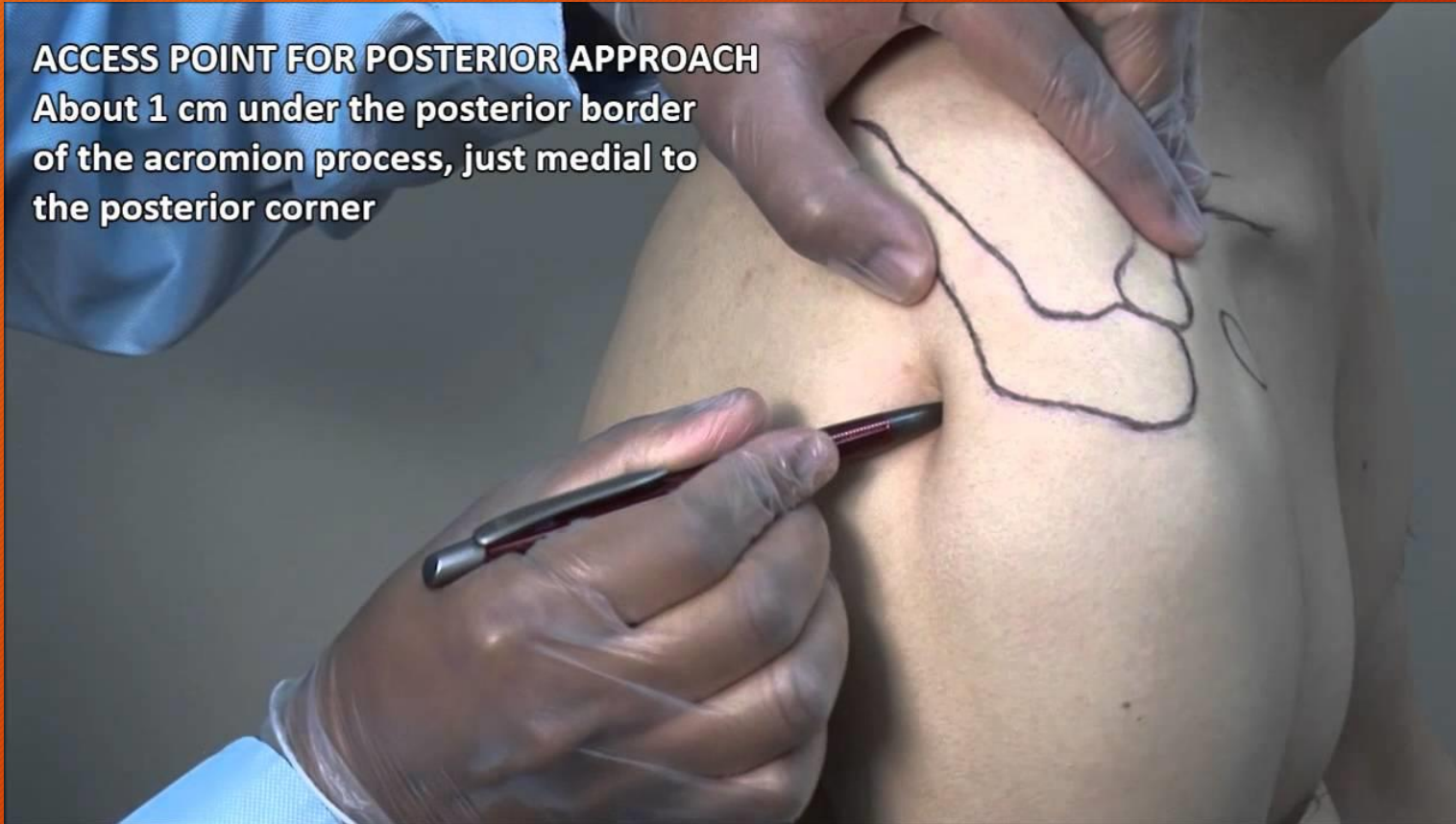MendMeShop

Painful arc syndrome



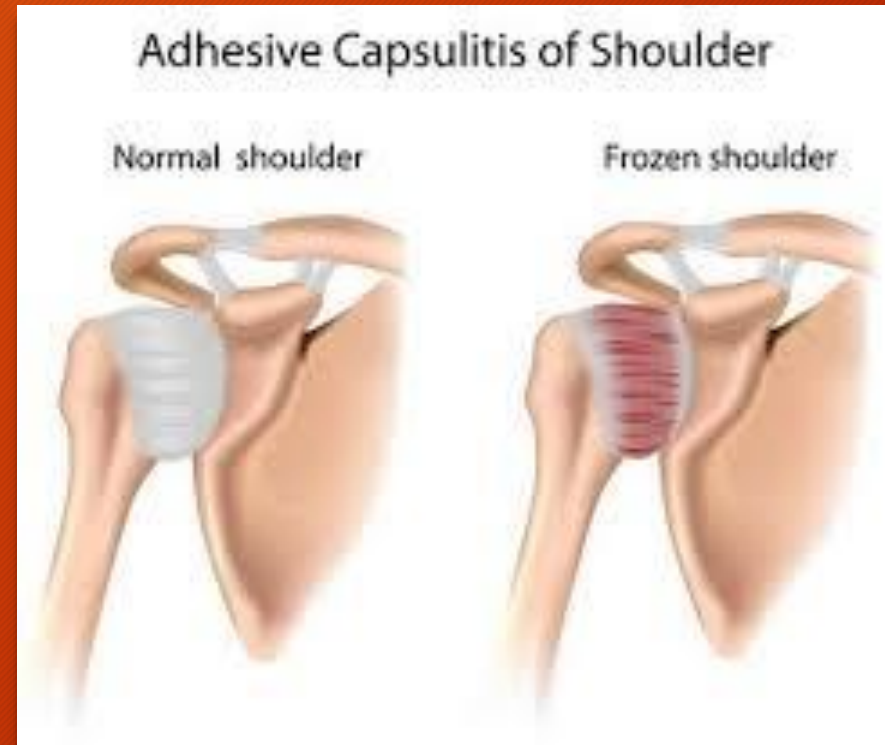Injection of the Subacromial Bursa

ACCESS POINT FOR POSTERIOR APPROACH
About 1 cm under the posterior border
of the acromion process, just medial to
the posterior corner



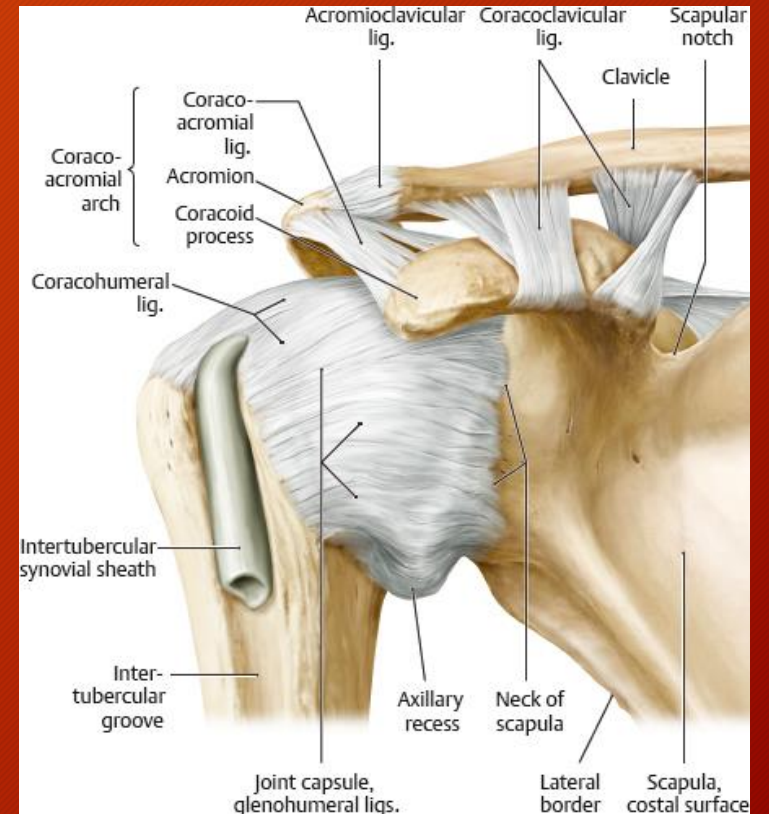
Frozen Shoulder (adhesive capsulitis)

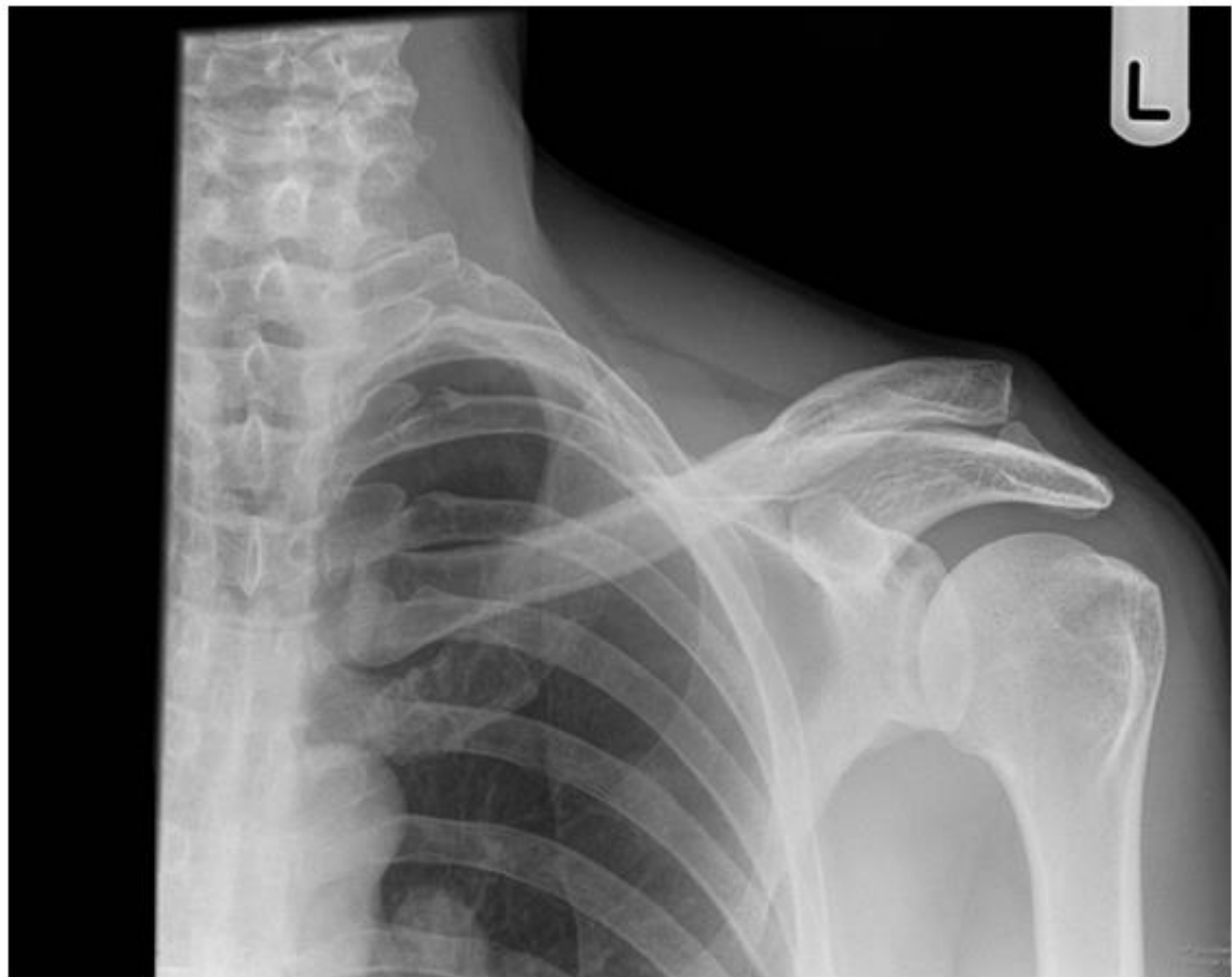- Pain and uniform limitation of all movements of shoulder joint, though there is **NO** evidence of radiological changes in the joint.
- Occurs due to shrinkage and chronic inflammation of capsule of glenohumeral joint
- Causes:
 - When not moving the shoulder joint for a period of time because of:
 - Pain
 - Injury
 - Chronic health condition



Shoulder Separation (Acromioclavicular Subluxation)

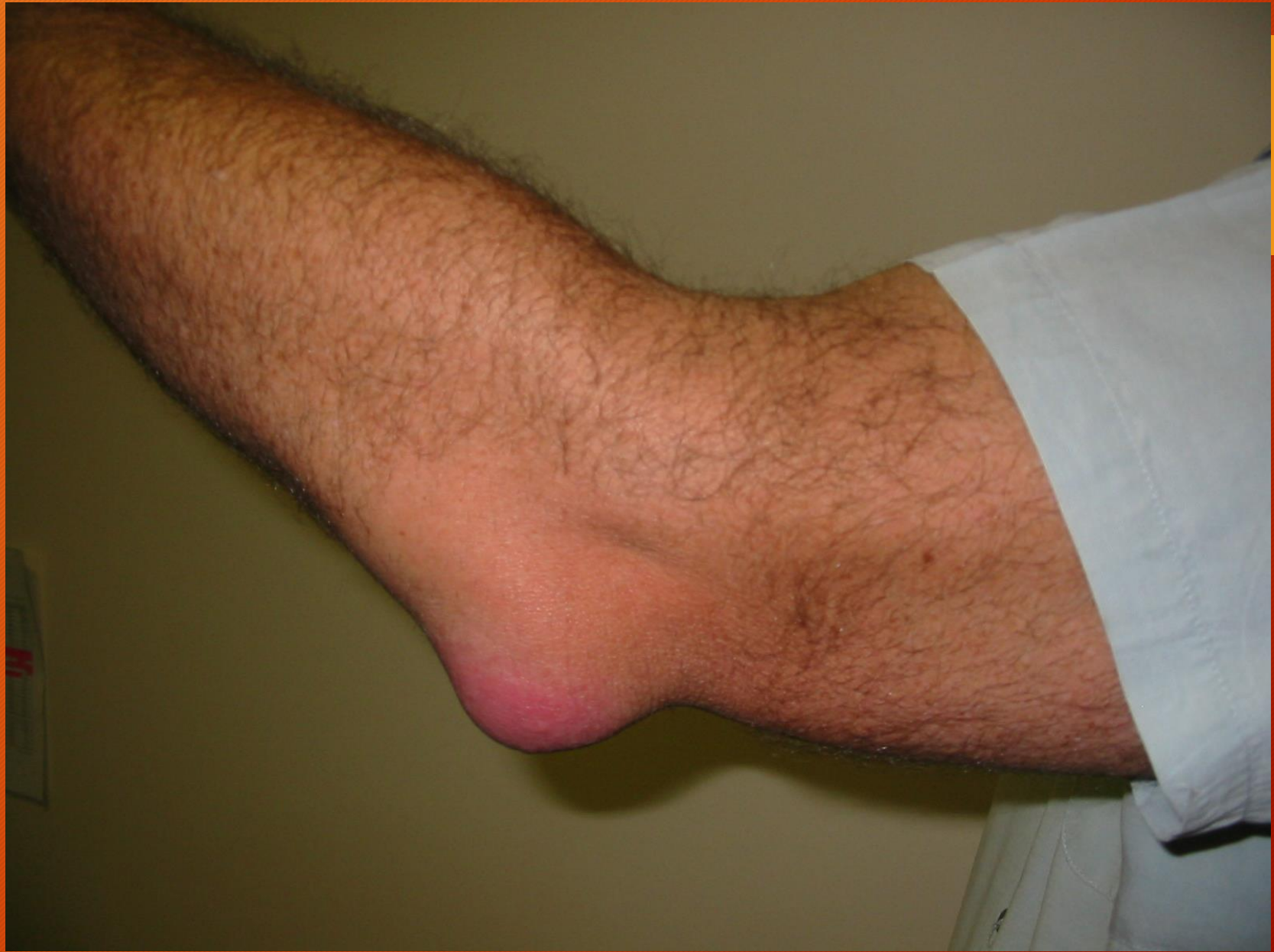- Tearing of coracoclavicular and coracoacromial ligaments caused by downward blow on tip of shoulder.
- Coracoclavicular and coracoacromial joint spaces become 50% wider than in normal contralateral shoulder.
- Presenting features:
 1. Injured arm hangs lower than normal (contralateral arm)
 2. Noticeable bulge at tip of shoulder as a result of upward displacement of clavicle.





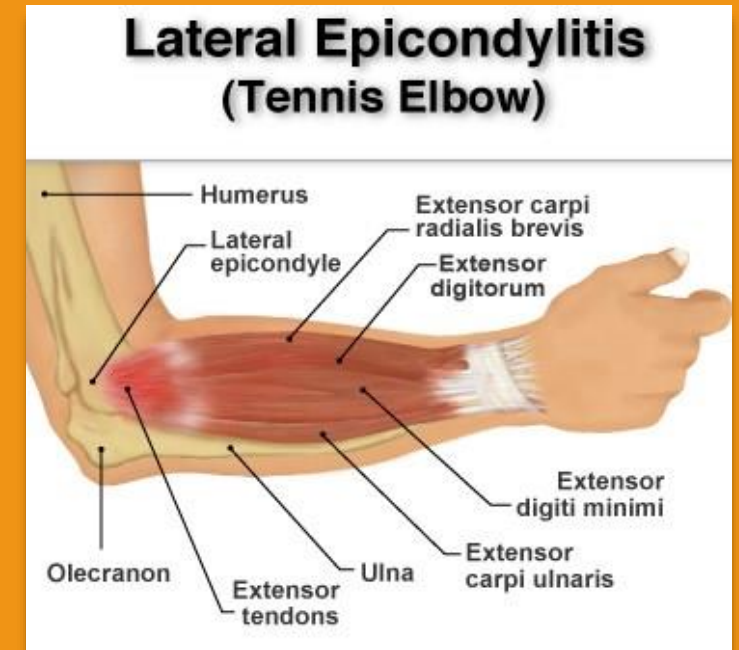
Olecranon Bursitis

- Inflammation of subcutaneous olecranon bursa (lying over the subcutaneous triangular area on dorsal surface of olecranon process of Ulna).
- Causes a round fluctuating painful swelling of 1” or so in circumference over olecranon.
- Occurs due to:
 1. Repeated friction as occurs in students who read for long hours with head supported by hand and elbow resting on table.
 2. Trauma during falls on elbow
 3. Infection from abrasions of skin covering olecranon process.



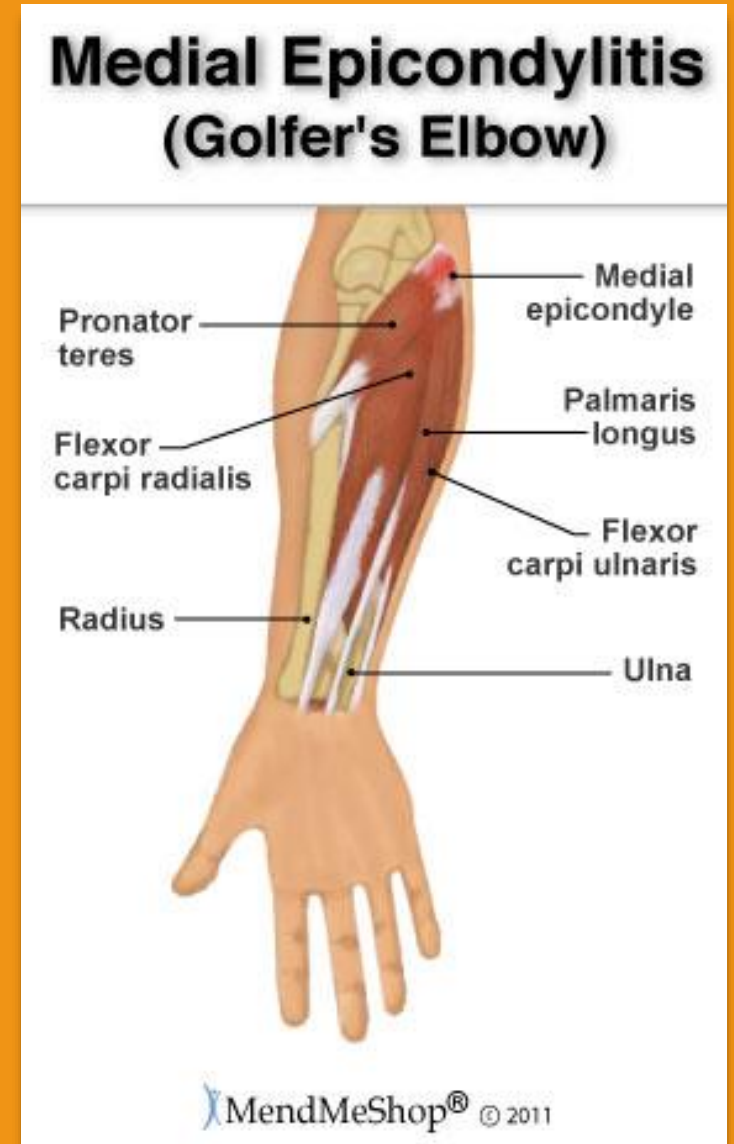Tennis Elbow (Lateral epicondylitis)

- Repeated or violent extension of the wrist with forearm pronated (i.e. movements required during backhand strokes in lawn tennis), leads to tenderness over lateral epicondyle of humerus.
- Possibly due to:
 - Sprain of radial collateral ligament.
 - Tearing of fibers of extensor carpi radialis brevis muscle.
 - Inflammation of the bursa underneath extensor carpi radialis brevis
 - Strain or tear of common extensor origin.



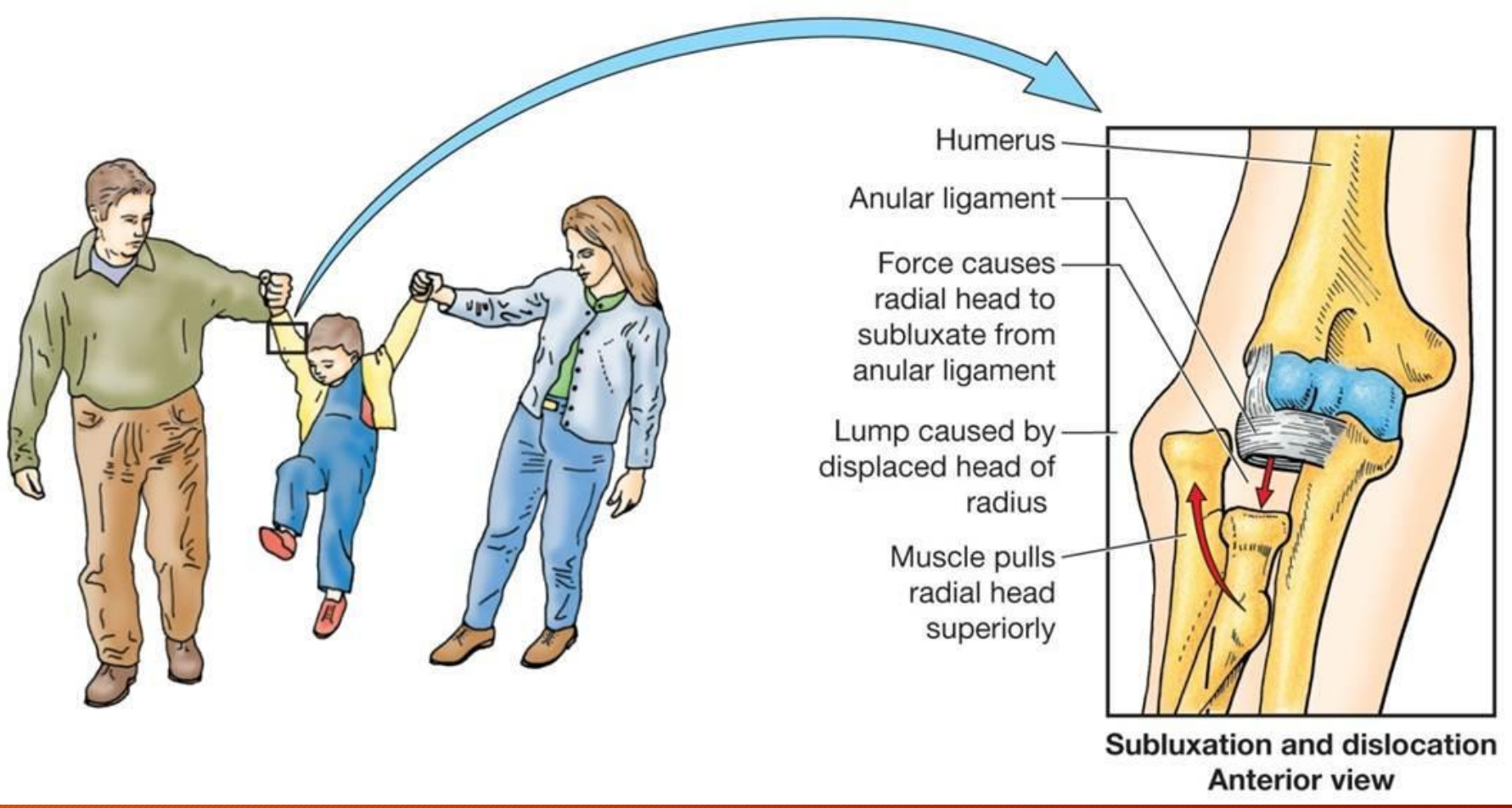
Golfer's Elbow (Medial Epicondylitis)

- Repetitive use of superficial flexors of forearm, strains their common flexor origin with subsequent inflammation of medial epicondyle (medial epicondylitis).
- Characterised by pain on medial side of elbow.



Radial Head Subluxation

- Also known as nursemaid's elbow.
- Vulnerable for preschool children (1-3 years old).
- Annular ligament is funnel-shaped in adults, but its sides are vertical in young children. (When child is suddenly lifted/pulled up when forearm is in pronated position, head or radius may slip out partially from annular ligament).
- Pain and limitation of supination.



Humerus

Anular ligament

Force causes radial head to subluxate from anular ligament

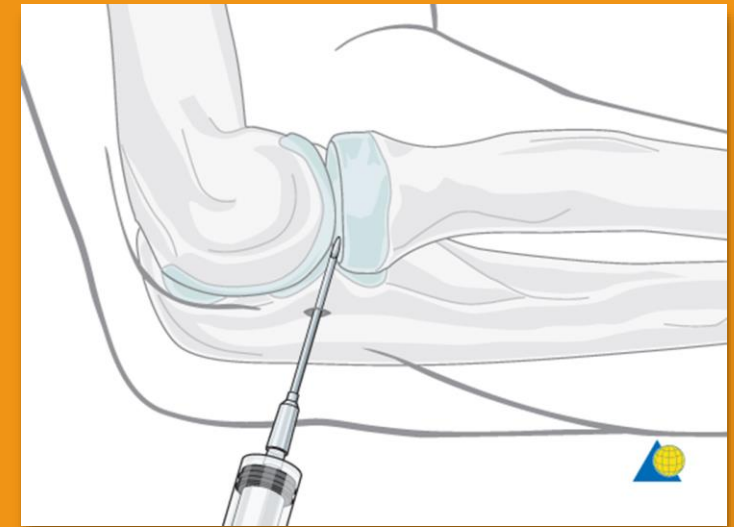
Lump caused by displaced head of radius

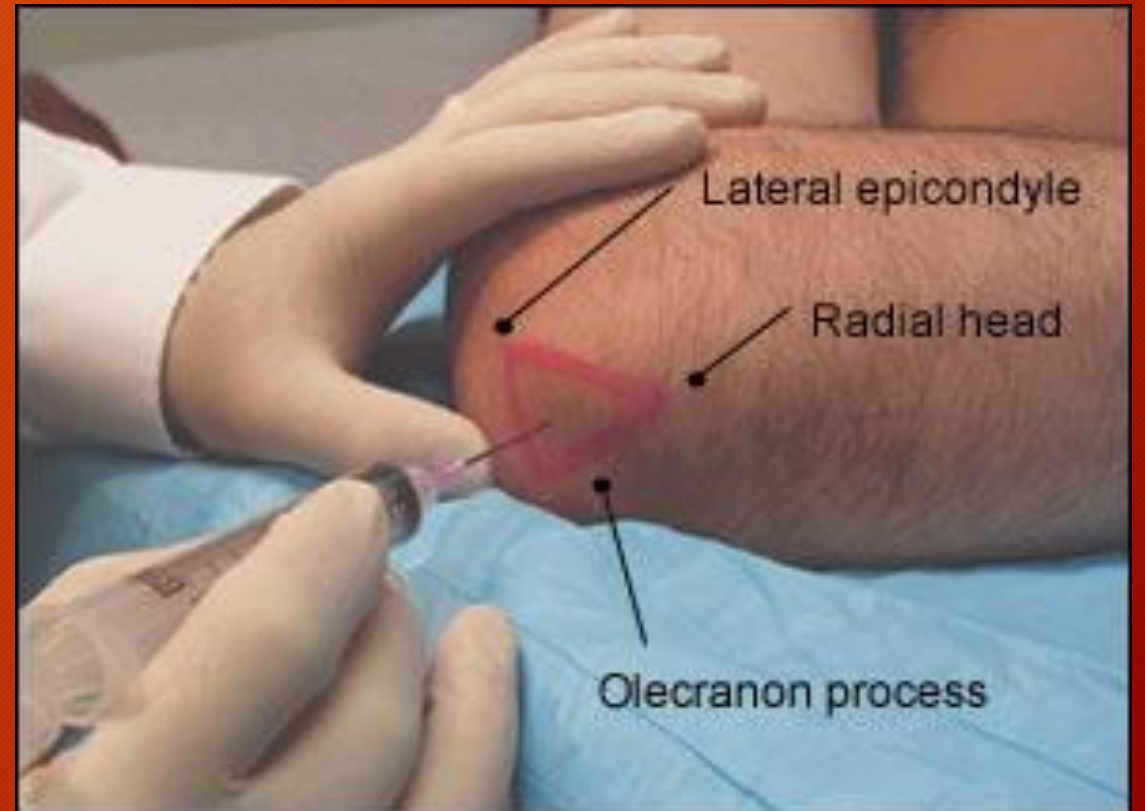
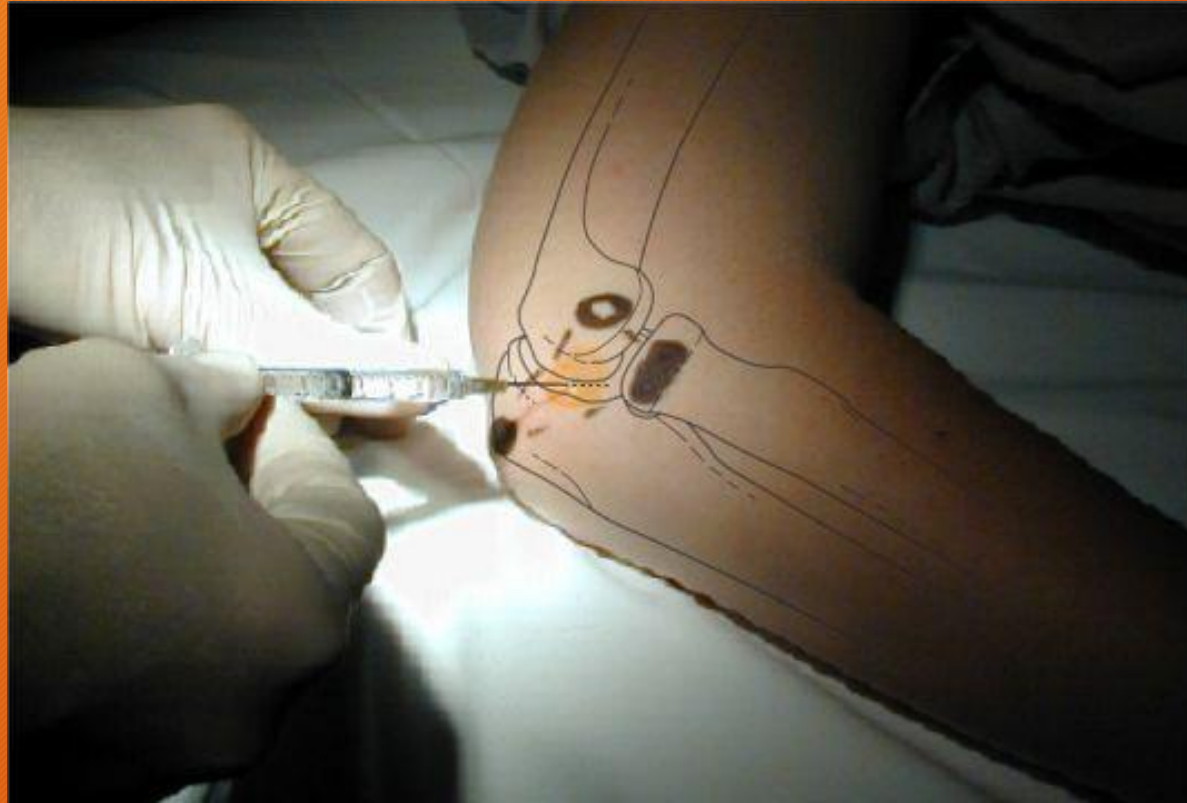Muscle pulls radial head superiorly

**Subluxation and dislocation
Anterior view**

Aspiration of Elbow Joint

- Locate the head of radius and capitulum of humerus. (flex elbow to 90 degrees, pronate and supinate forearm and feel with the thumb its rotation).
- Insert needle in the palpable depression between proximal part of radial head and capitulum in a direction directly forwards, the joint being flexed to right angle and forearm semi pronated.
- Safest and most direct approach. When elbow is distended with pus, the capsule bulges to either side of triceps and hence the pus can easily and efficiently be drained.



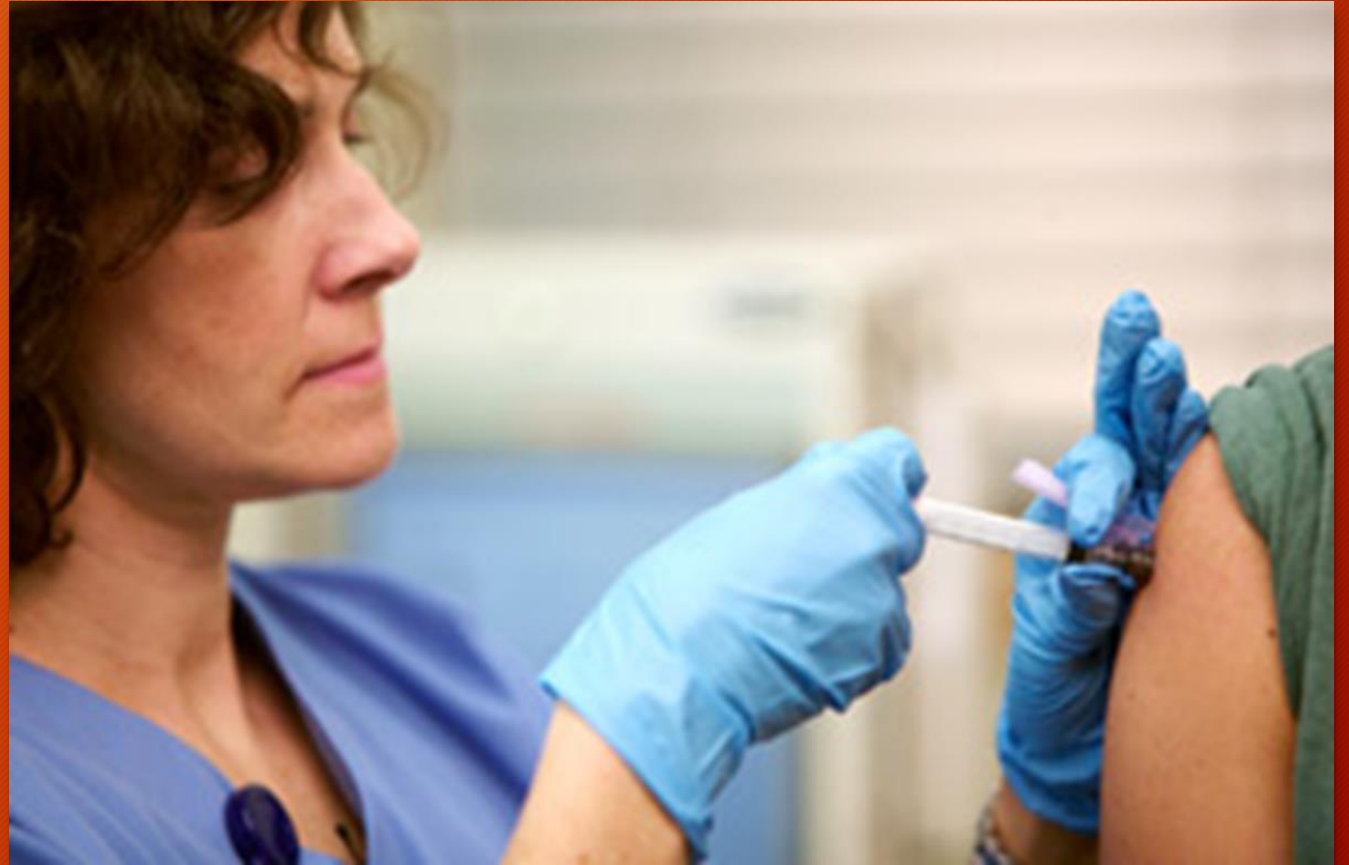

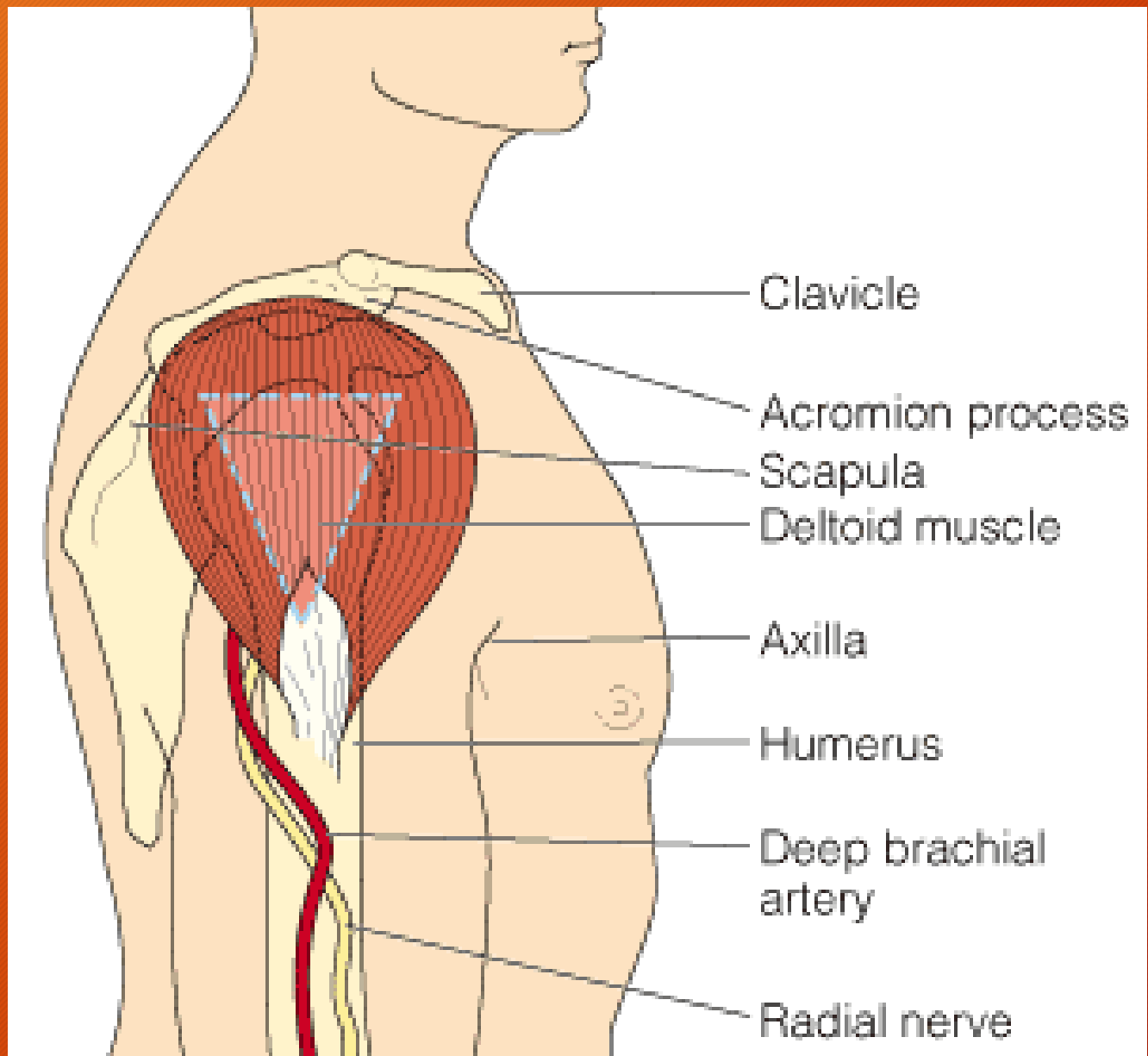
Upper limb Muscles

Preferred site for Intramuscular Injection

Deltoid Muscles

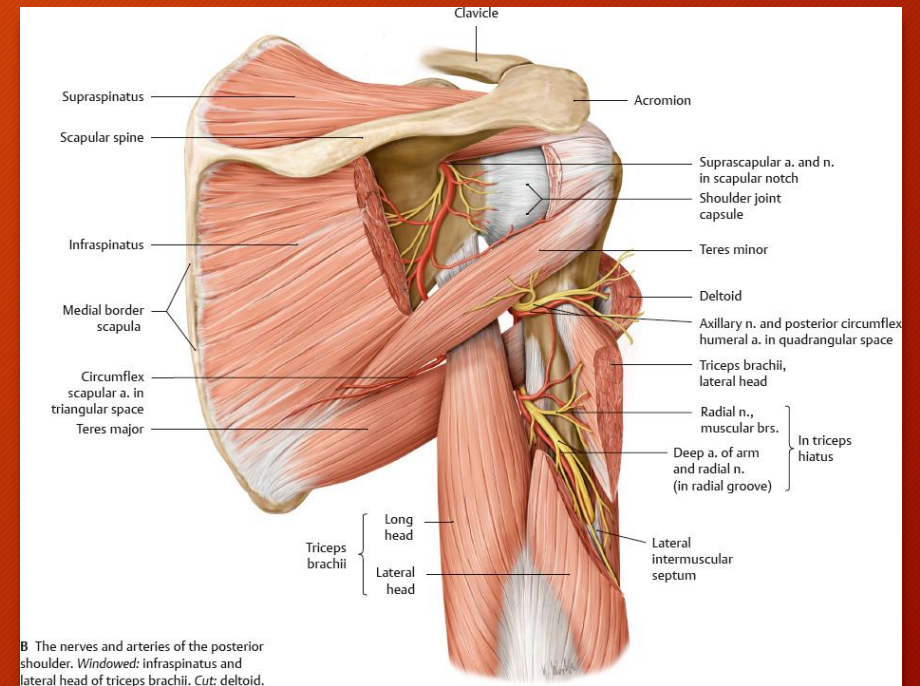
- Well-developed in most adults and easily accessible.
- Injection given in the lower half to avoid injury to axillary nerve.
- Exact site of injection: Needle should be inserted in center of triangle.
- Place 4 fingers across deltoid muscle with top finger kept along acromial process, injection site is 3 fingers breadth below acromial process.

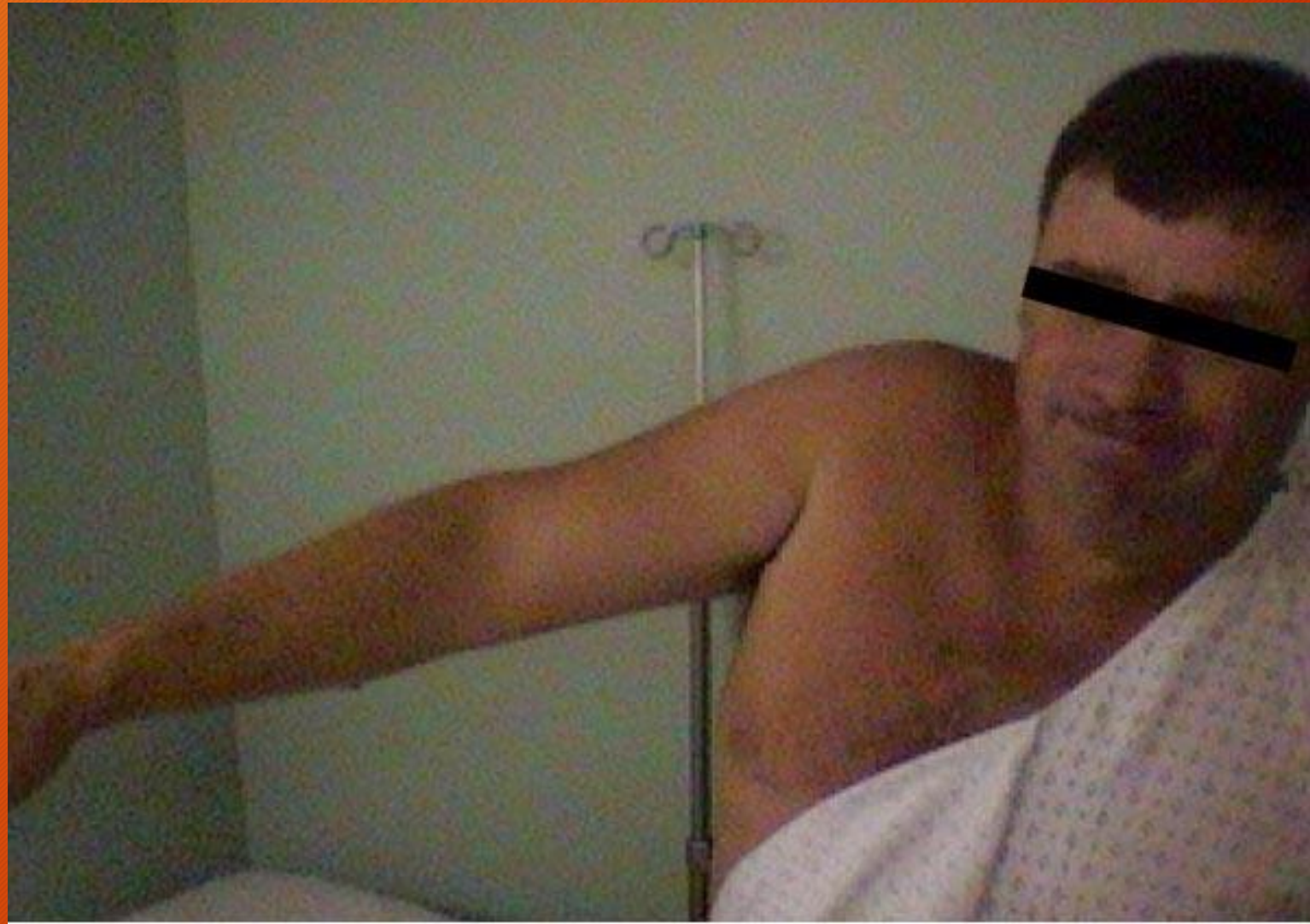



Ruptured Supraspinatus

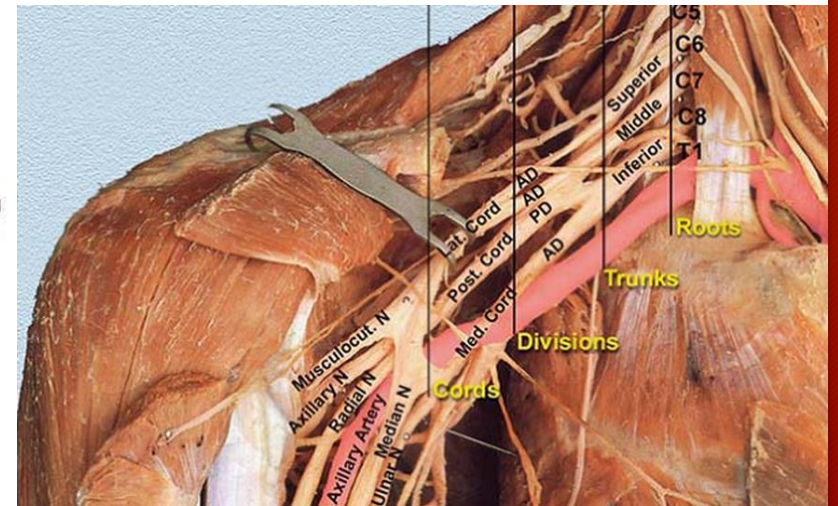
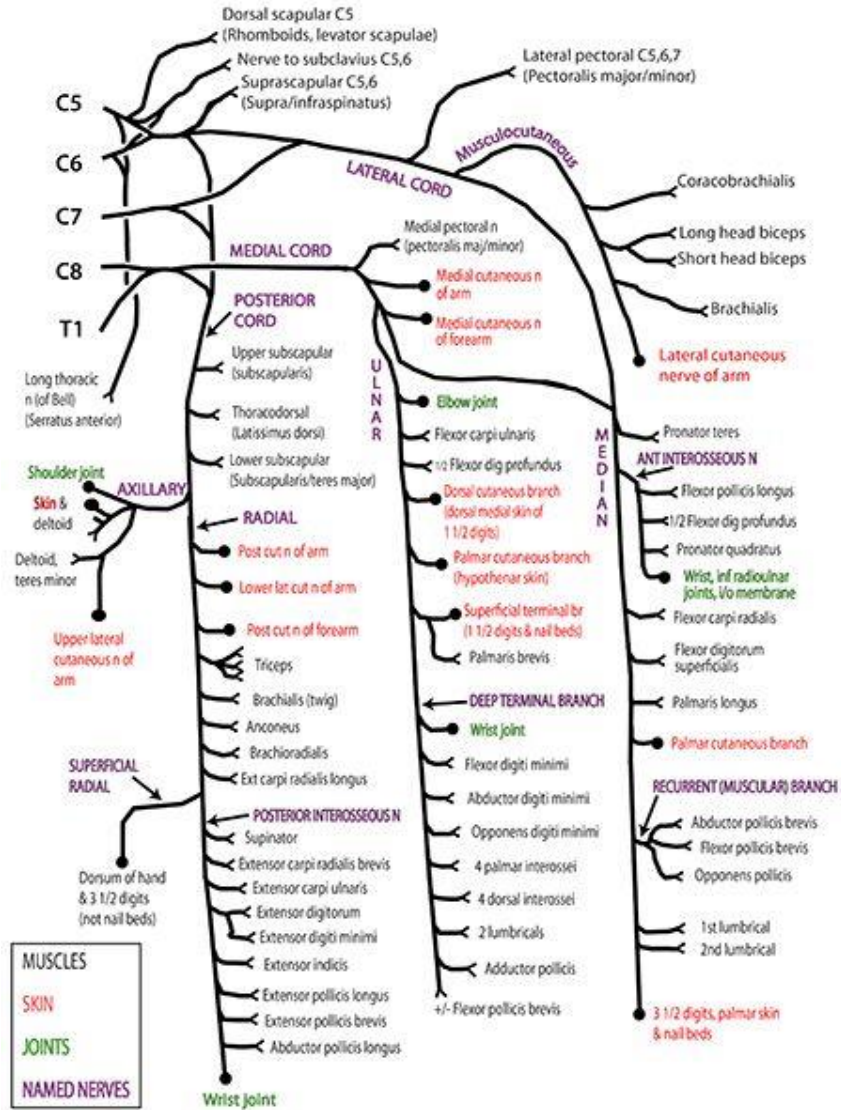
- Active initiation of abduction is not possible.
- Patient gradually develop a trick of tilting his body towards injured side so that the arm swings away from the body due to gravity leading to 15 degrees initial abduction. Later deltoid and scapular rotators come into play to do the required job.
- Sometimes may also lift arm on the side of injury with opposite hand to cause initial abduction





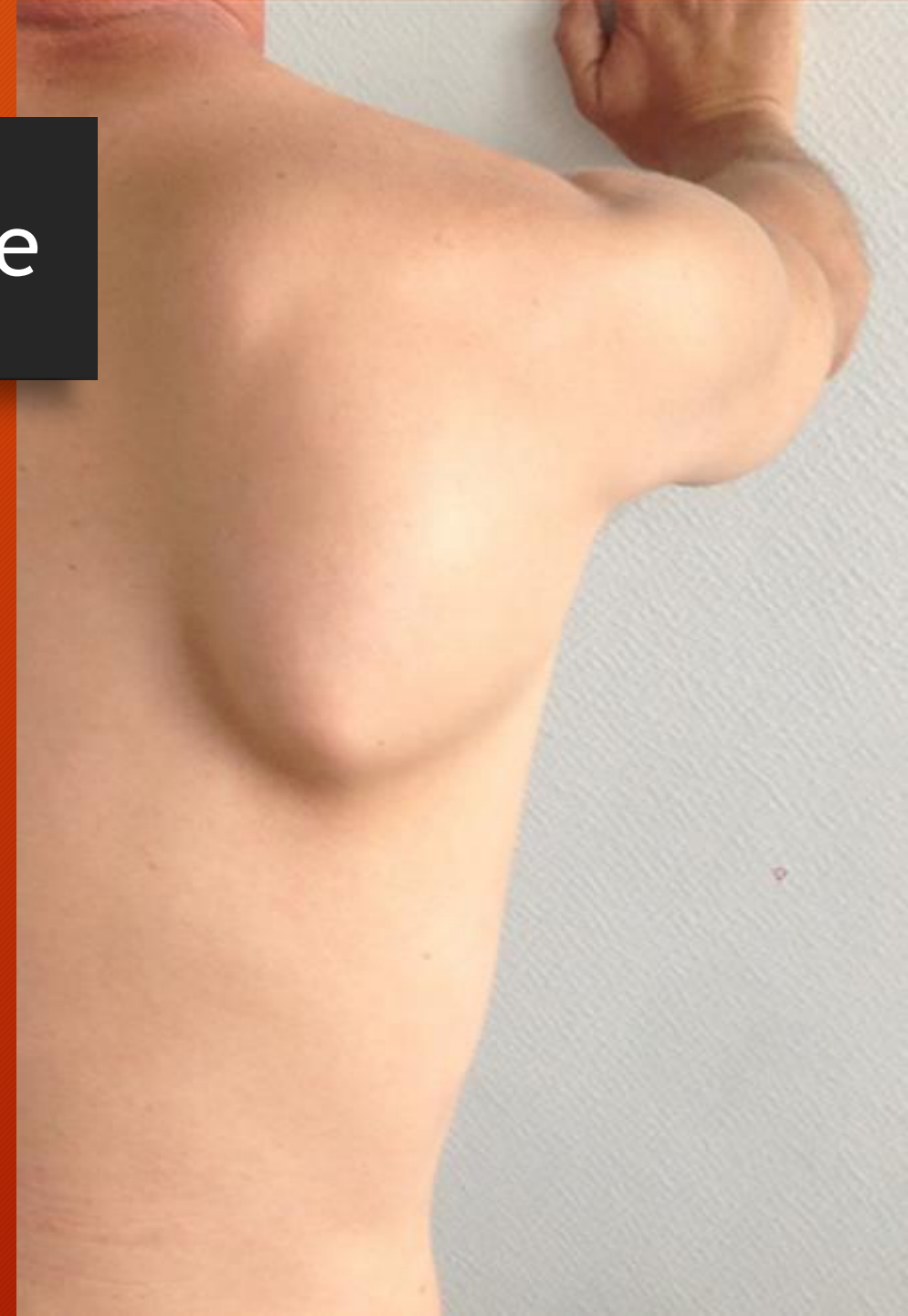Upper Limb Nerves

BRACHIAL PLEXUS - FULL DISTRIBUTION



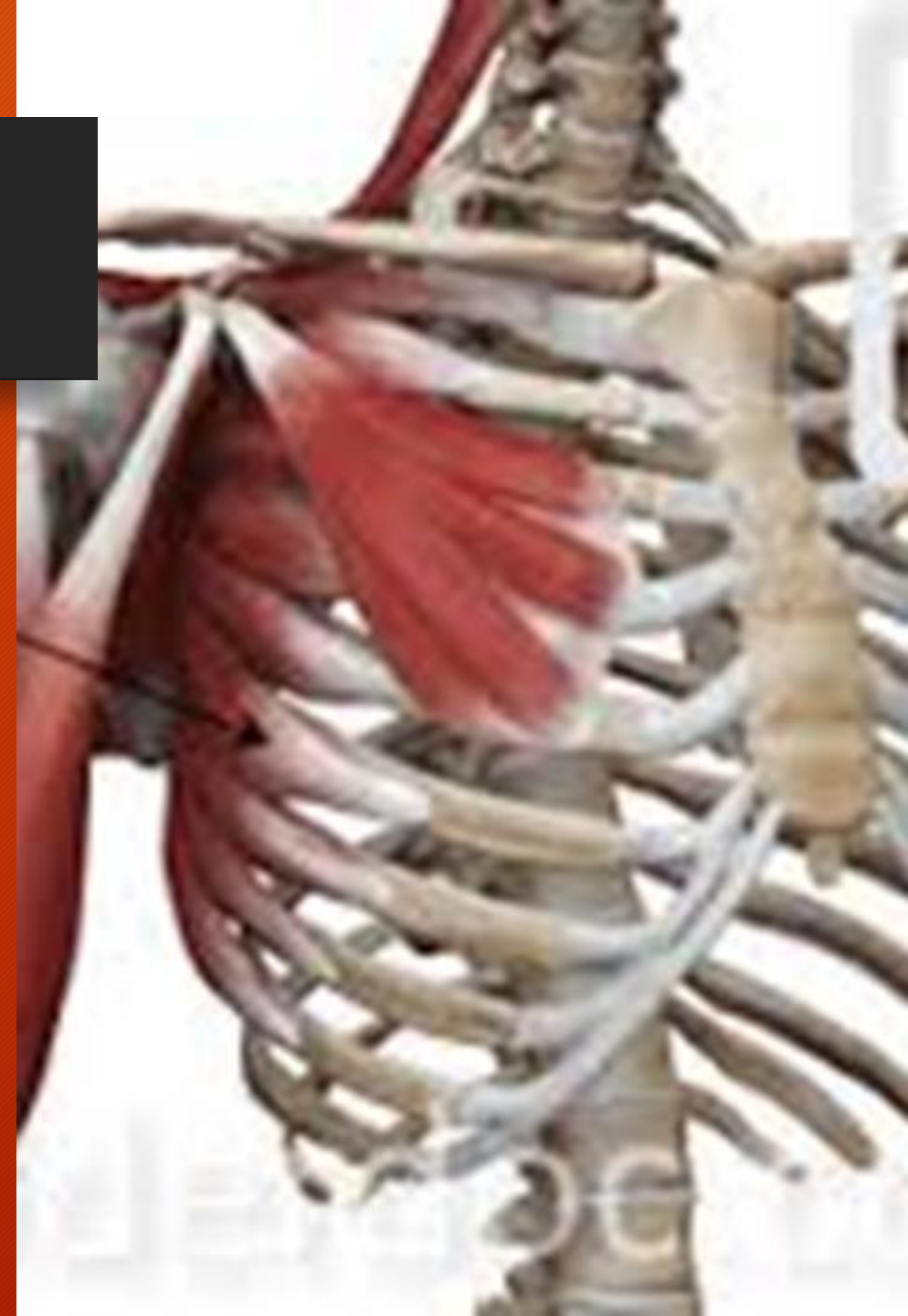Injury to the Long Thoracic Nerve

- Causes:
 - Surgical injury
 - axillary node dissection
 - trauma
- Results in paralysis of the serratus anterior and winged scapula/inability to abduct the arm

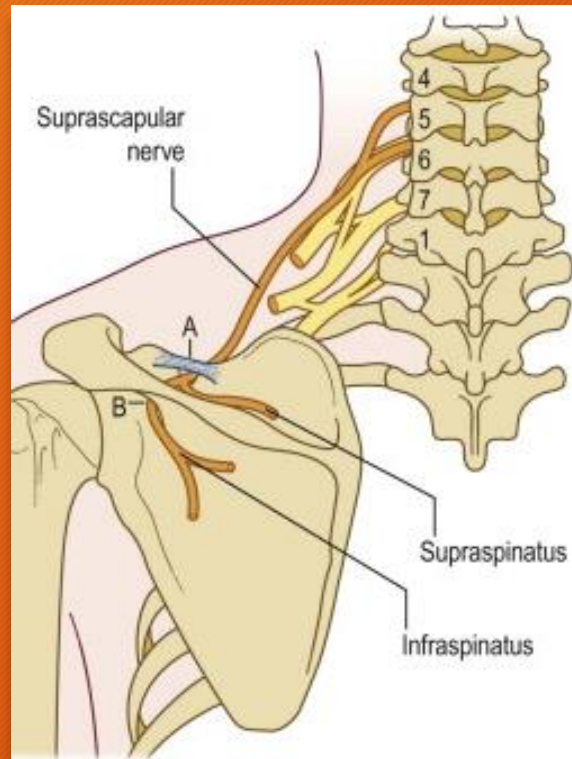


Paralysis of Serratus Anterior

- Functions of Serratus Anterior
 - Keeps medial border of scapula in contact with chest wall.
 - Important role in abduction of arm and elevation of arm above horizontal.
 - Pulls scapula forward as in throwing, pushing and punching.
- Effects of paralysis of serratus anterior
 - Medial border of scapula stands out from the chest wall, particularly when patient is asked to press against a wall in front of him (winged scapula).
 - Inability to raise arm above head.
 - Inability to carry arm forward in breast stroke swimming (Swimmer's Palsy).

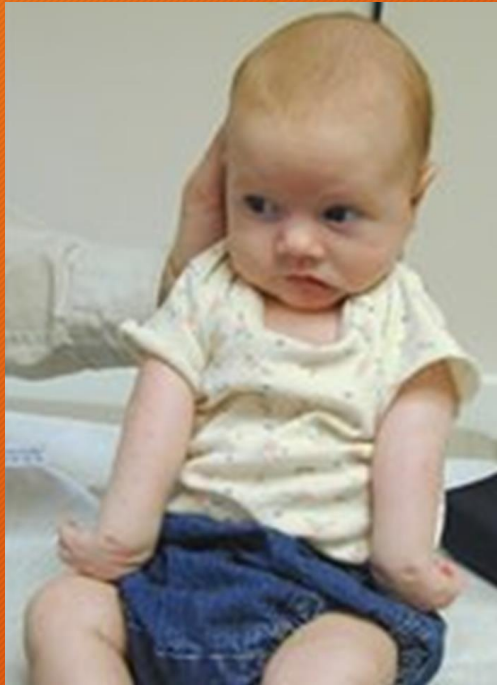

Suprascapular Nerve Entrapment



- Entrapment may occur as it passes through suprascapular notch or in spinoglenoid notch.
- Effects:
 - Typical dull posterior and lateral shoulder pain.
 - Tenderness, 2.5cm lateral to midpoint of spine of scapular
 - Weakness of shoulder abduction and external rotation due to involvement of supraspinatus and infraspinatus muscles.

Erb-Duchenne Paralysis (Erb's Palsy)



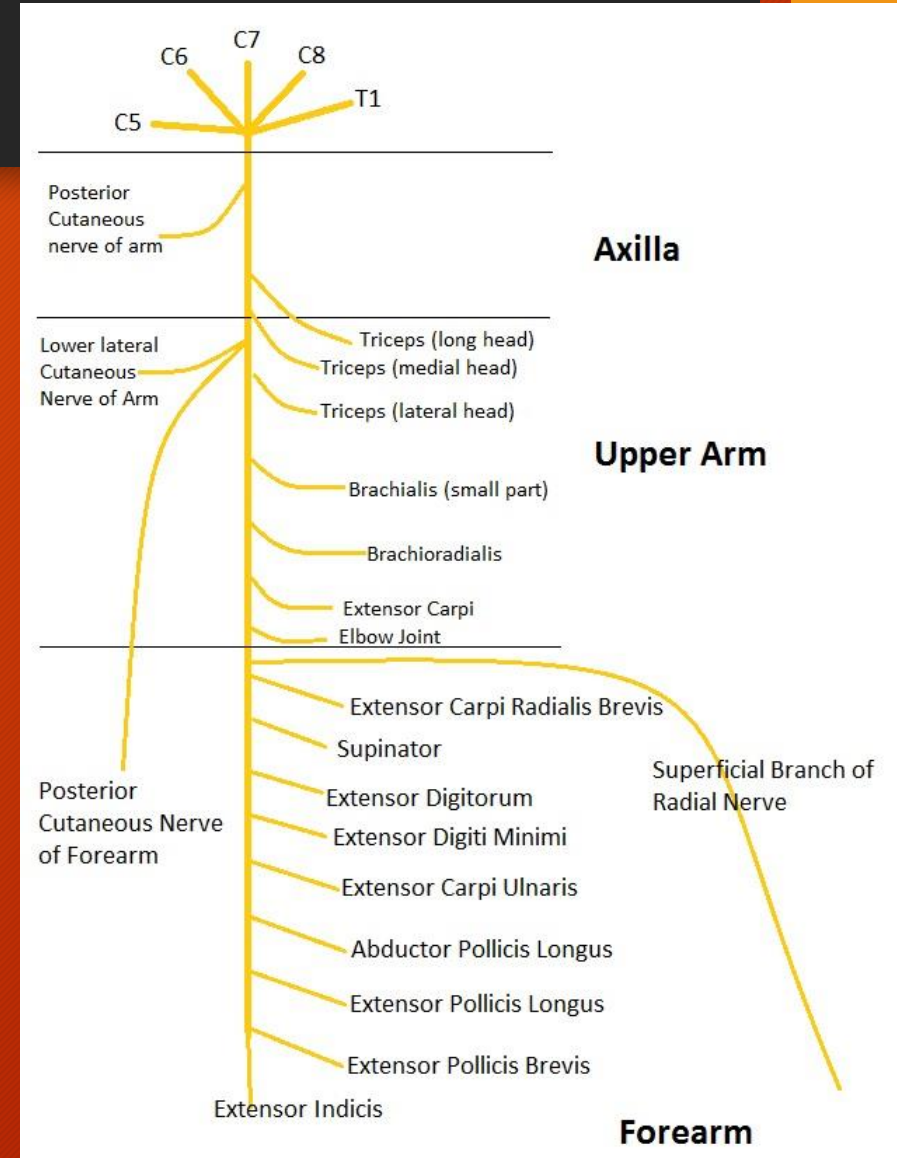
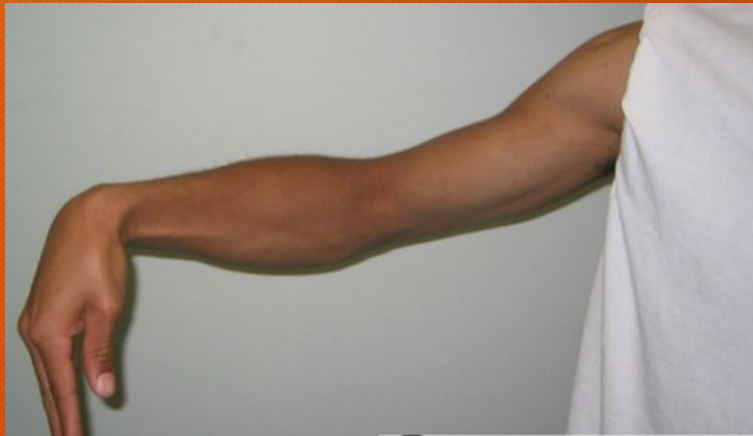- Brachial plexus injury at Erb's point (C5, C6).
- Maybe injured during childbirth, due to forcible downward traction of shoulder with lateral displacement of head to other side (Usually during forceps delivery).
- Upper limb assumes typical “waiter’s tip position”:
 - Shoulder adducted and medially rotated.
 - Elbow extended
 - Forearm pronated

Axillary Nerve damage

- Axillary nerve usually damaged by fractures of surgical neck of humerus or due to an inferior dislocation of shoulder joint.
- Effects:
 - Loss or weakness of abduction of shoulder (between 15 degrees to 90 degrees) due to paralysis of Deltoid.
 - Rounded contour/profile of shoulder is lost due to paralysis of deltoid
 - Sensory loss over lower half of the outer aspect of shoulder 'regimental badge area'.
- ❖ *Paralysis of teres minor is not easily demonstrated clinically.*

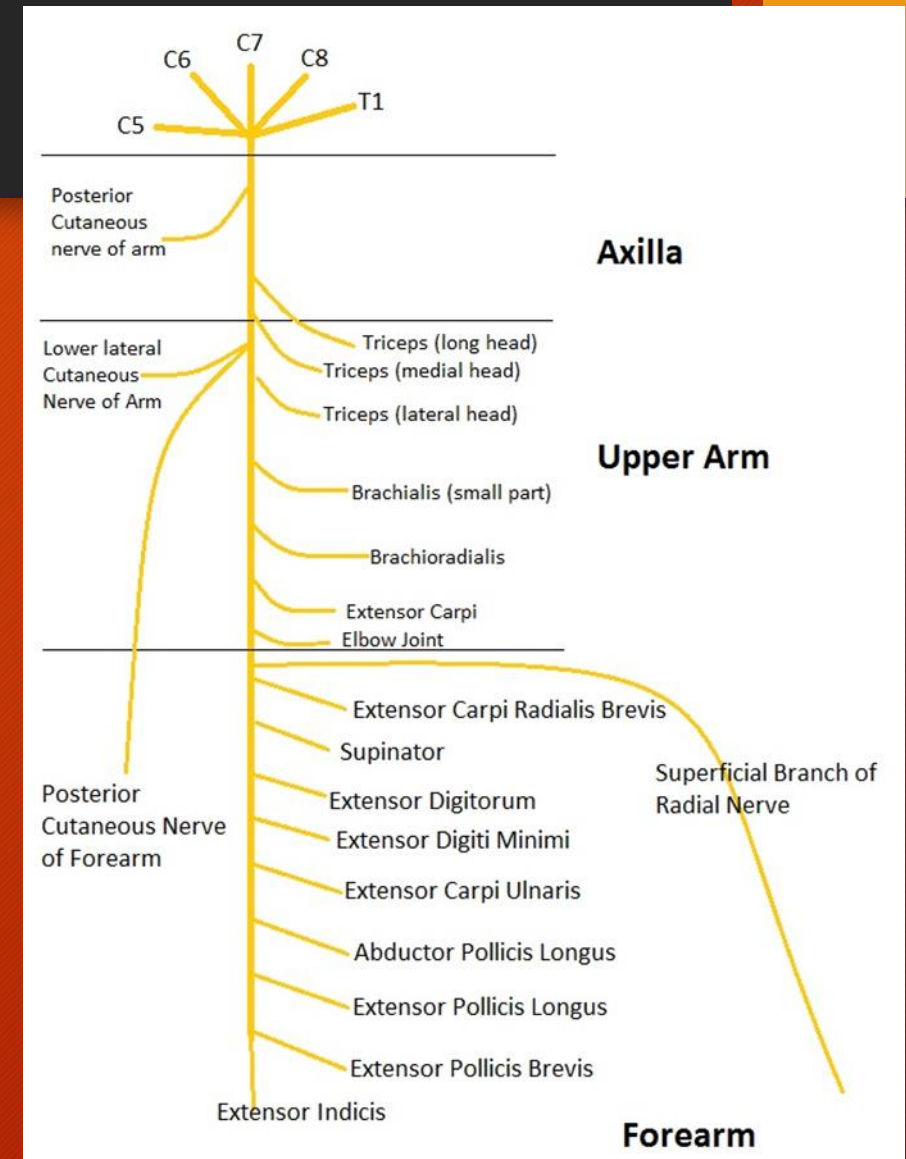
Effects of Radial Nerve Injury

- Severity and symptoms depend on site of lesion
- Most common clinical finding is wrist drop



Radial Nerve Injury (Axilla)

- Causes:
 - Prolonged use of crutches (Crutch Paralysis)
- Effects:
 - Loss of extension of elbow due to paralysis of triceps.
 - Loss of extension of wrist due to paralysis of extensor muscles of forearm (Wrist Drop).
 - Supination of forearm in elbow extension not possible (paralysis of supinator)
 - Loss of sensation over:
 - Posterior surface of lower part of arm and narrow strip over back of forearm
 - Over lateral side of dorsum of hand and lateral 3½ fingers
 - Loss of triceps and supinator reflexes.



Radial Nerve Injury (Radial Groove)

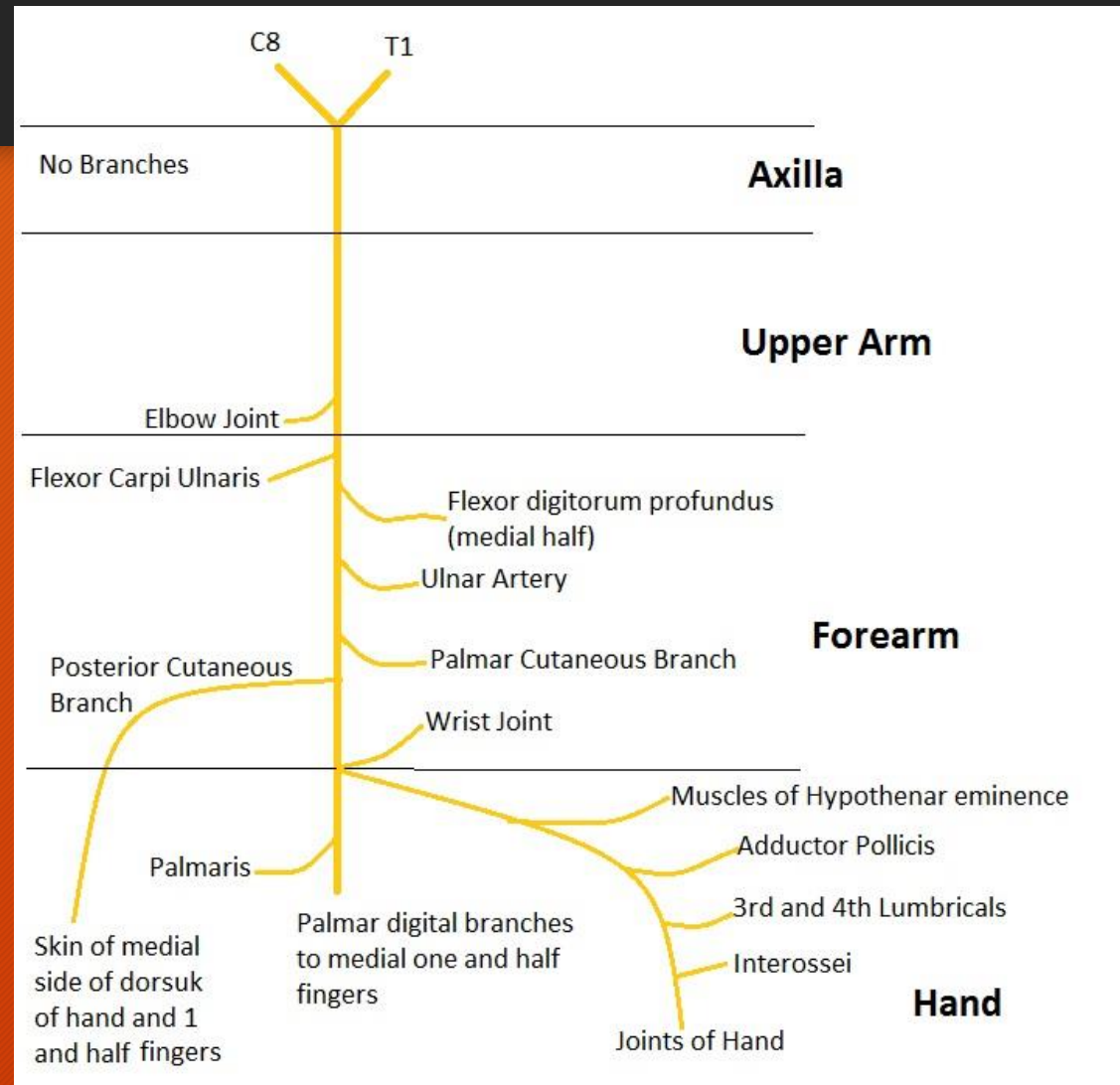
- Causes:
 - Fracture of shaft of humerus
 - Improper intramuscular injection
 - Prolonged pressure
- Effects:
 - Triceps brachii is spared (extension of elbow is possible)
 - Other effects are similar as those of a lesion of radial nerve in axilla

Ulnar Nerve

Usually injured at following sites:

- Elbow
- Cubital tunnel
- Wrist
- Hand

Effects depending on site of lesion



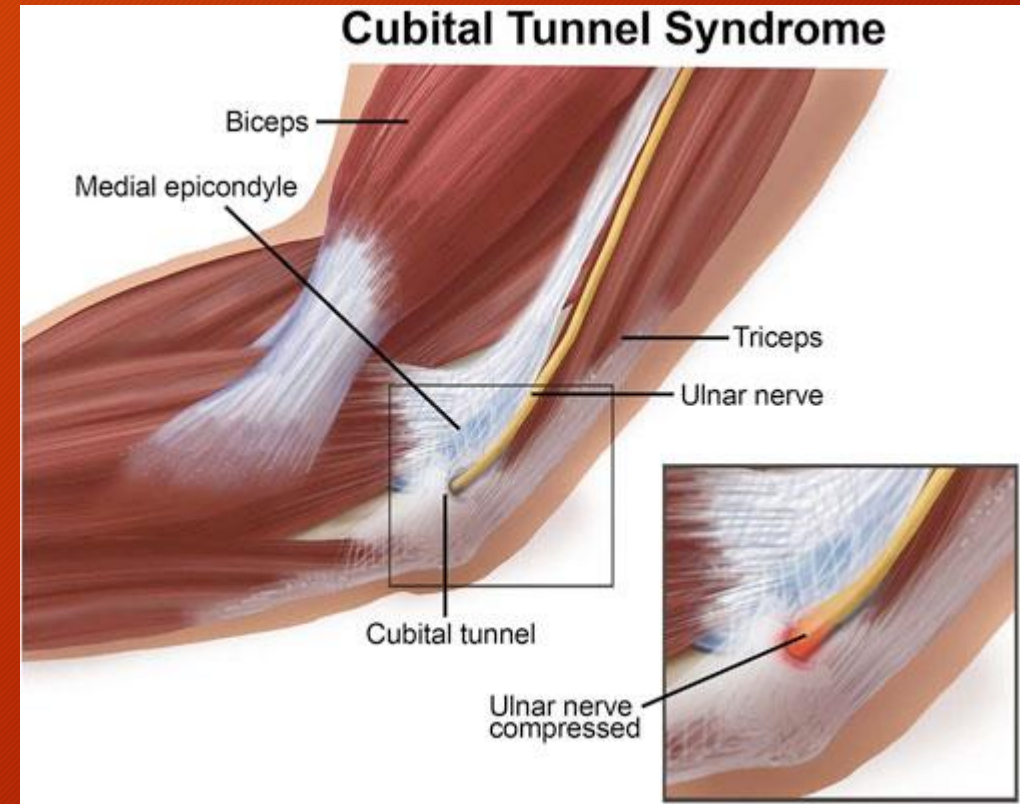
Ulnar Nerve Injury at Elbow



- Easily damaged (lies in ulnar groove behind medial epicondyle of humerus)
- Causes:
 - Fracture of medial epicondyle
- Effects:
 - Loss of flexion of terminal phalanges of ring and little finger due to paralysis of flexor digitorum profundus (medial half)
 - Weakness of flexion and adduction of wrist due to paralysis of flexor carpi ulnaris
 - Ulnar Claw Hand
 - Loss of adduction and abduction of fingers due to paralysis of Palmar (adductors) and dorsal (abductors) interossei
 - Loss of adduction of thumb due to paralysis of adductor pollicis.
 - Flattening of hypothenar eminence and depression of interosseous space due to atrophy of hypothenar and interosseous muscles

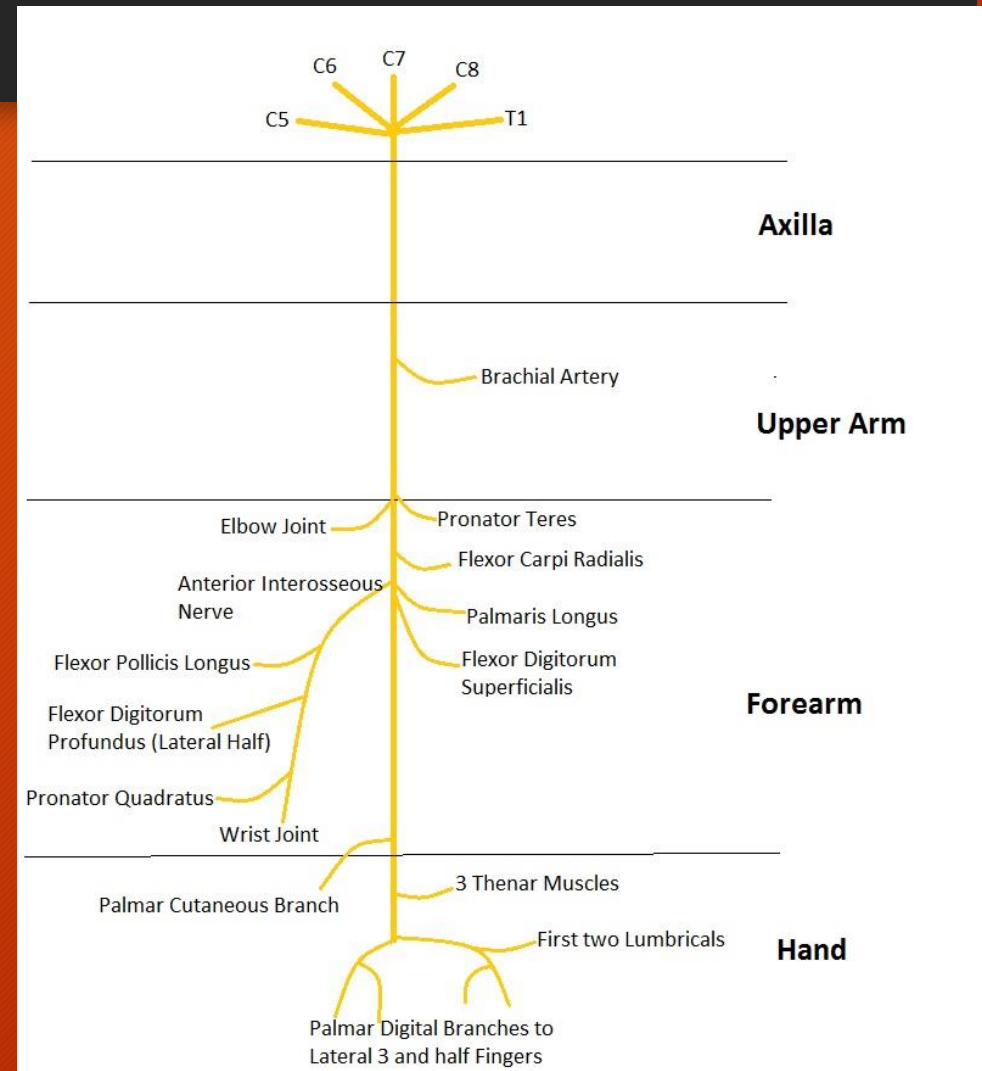
Ulnar Nerve Injury at Cubital Tunnel (Cubital Tunnel Syndrome)

- Cubital Tunnel - Formed by tendinous arch connecting 2 heads of flexor carpi ulnaris (arise from humerus and ulna)
- Causes:
 - Entrapment of ulnar nerve in this cubital tunnel (osseofibrous tunnel).
- Effects same as ulnar nerve lesion in elbow



Median Nerve

- Injury usually injured at following sites:
 - Axilla
 - Wrist
 - Carpal Tunnel
- Effects depending on site of lesion

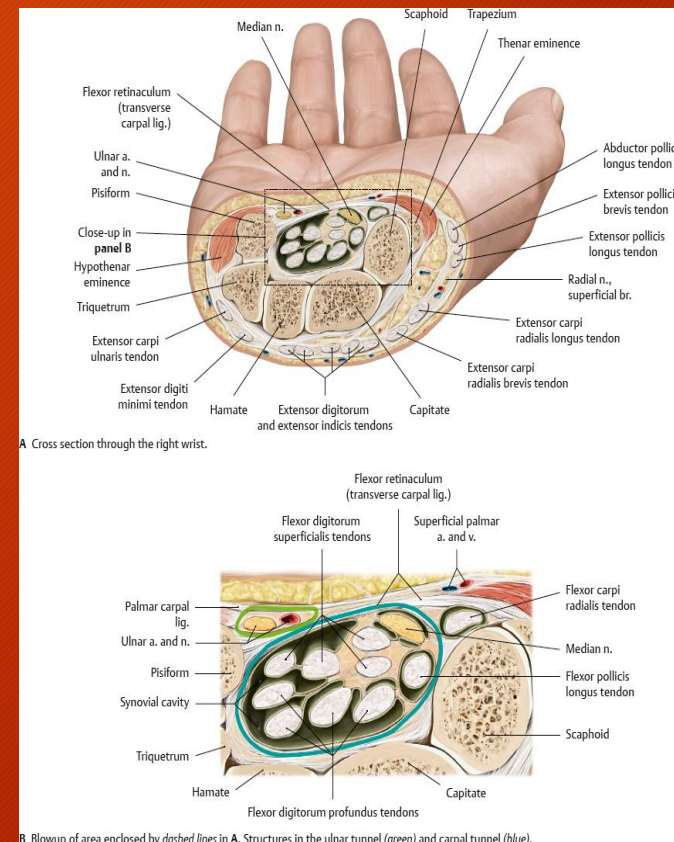


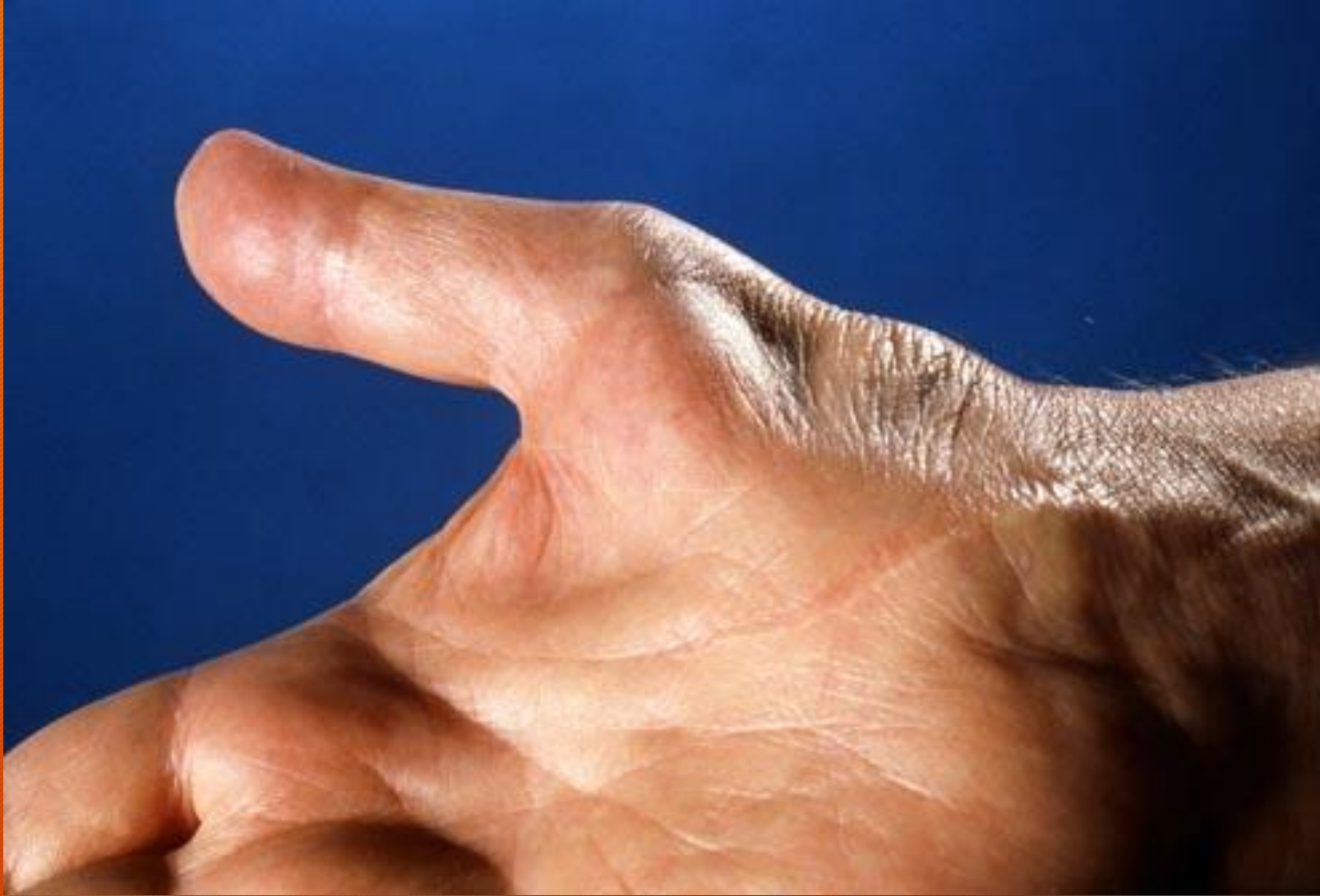Median Nerve Injury at Axilla

- **Motor Effects:**
 - Weakness of pronation of forearm due to paralysis of pronators.
 - Deviation of wrist to Ulnar side on wrist flexion due to unopposed action of flexor carpi ulnaris.
 - Weakness of flexion of distal phalanx of thumb and index finger.
 - Wasting of thenar muscles due to paralysis.
 - Loss of opposition of thumb due to paralysis of opponens pollicis.
 - Loss of flexion and weakness of abduction of thumb.
 - **Ape-hand deformity**
- **Sensory Effects:**
 - Loss of cutaneous sensations over palmar surface of lateral 3½ digits and radial two-thirds of palm

Medial Nerve Injury at Carpal Tunnel (Carpal Tunnel Syndrome)

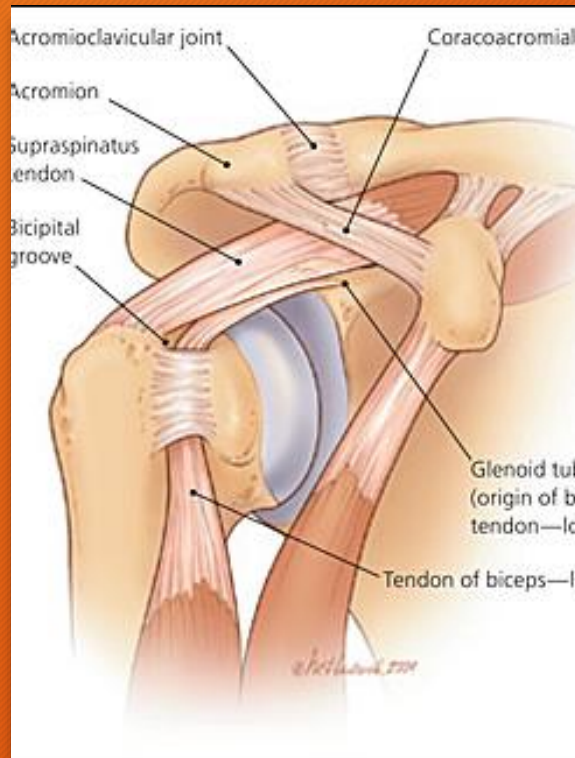
- Compression of medial nerve in carpal tunnel.
- More common in women than man.
- Causes
 - Tendosynovitis
 - Bony encroachment (osteoarthritis/injury)
 - Myxoedema, pregnancy, hypothyroidism etc conditions resulting in fluid accumulation.
 - Weight gain.
- Symptoms
 - Painful paraesthesia and numbness affecting radial 3½ digits of hand.
 - Wasting and weakness of thenar muscles.
 - Loss of sensation or hypoaesthesia to light touch and pin prick over palmar aspect of radial 3½ digits and corresponding part of hand except skin over thenar eminence





Special Tests

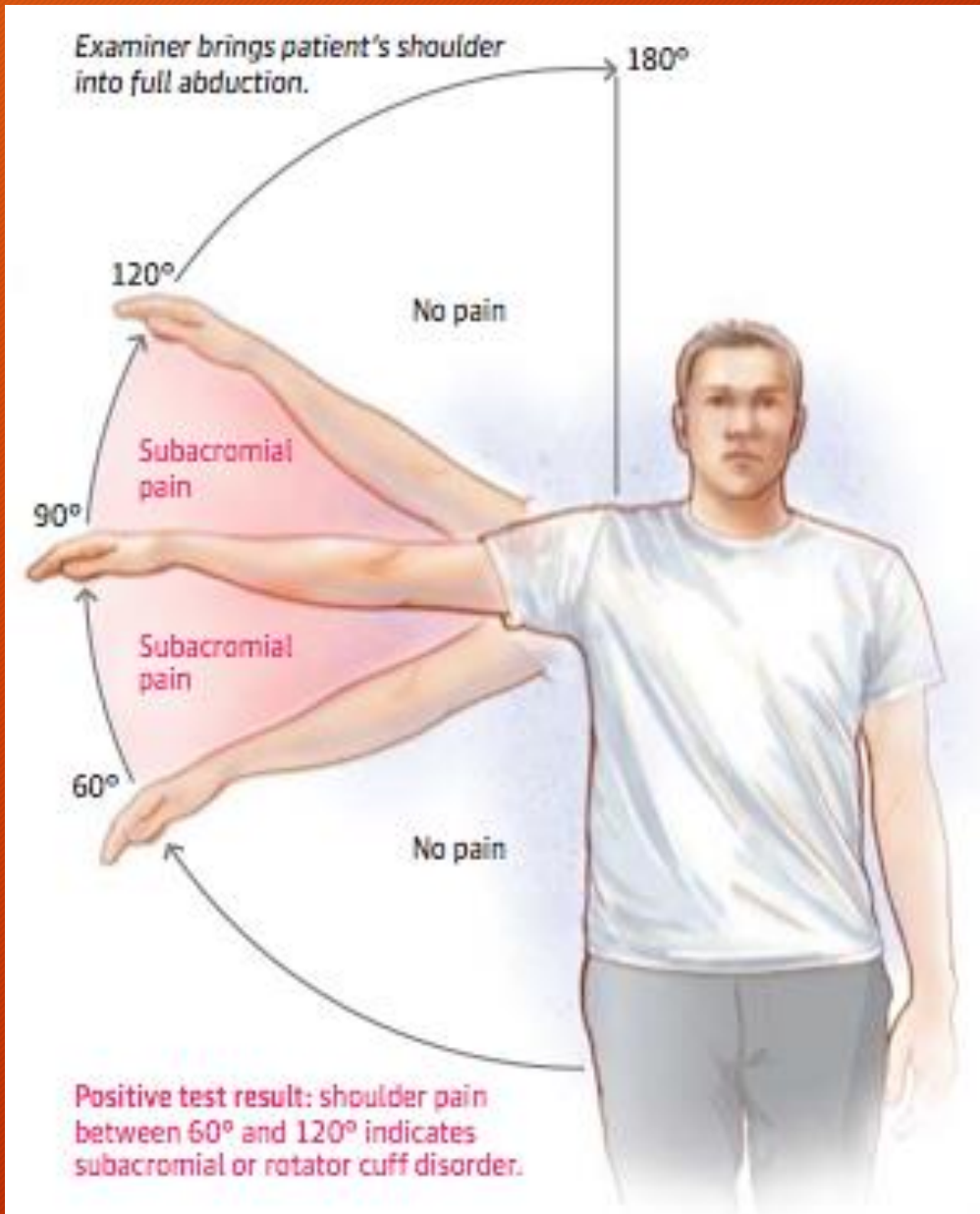
Yergason Test



- To determine if biceps tendon is stable in bicipital groove.
- Steps:
 - Instruct patient to fully flex elbow.
 - Clinician grasp the flexed elbow in one hand while holding his wrist with other hand.
 - External rotate patient's arm as he resists, at the same time pull downward his elbow.
- If biceps tendon is unstable in bicipital groove, it will pop out the groove and patient will experience pain; If stable, it remains secure and patient have no experience of discomfort.

Drop Arm Test

- To detect any tears in the rotator cuff.
- Steps:
 - Instruct patient to fully abduct his arm.
 - Ask patient to slowly lower it to his side.
- If there are tears in the rotator cuff (especially supraspinatus), the arm will drop to the side from a position of about 90° abduction.
- The patient will still not be able to lower his arm smoothly and slowly no matter how many times he tries.
- If he is able to hold his arm in abduction, a gentle tap on the forearm will cause the arm to fall to his side.



Apprehension Test

- To test for chronic shoulder dislocation or labral tear.
- Steps:
 - Clinician abduct and externally rotate patient's arm to a position where it might easily dislocate
- If patient's shoulder is ready to dislocate, the patient will have a noticeable look of apprehension and alarm on his face and will resist further motion.

Elbow Stability Test

- To assess stability of medial and lateral collateral ligaments of elbow.
- Steps:
 - Clinician cup posterior aspect of patient's elbow in one hand and hold patient's wrist with the other.
 - The hand on the elbow will act as fulcrum, other hand will force the forearm during the test.
 - Instruct patient to flex his elbow few degrees while forcing his forearm laterally, producing valgus stress on joint's medial side.
 - Then do it in reverse direction.
- Notice if any gapping collateral ligament with the clinician hand that act as fulcrum.

Questions?



References

- Singh, V. (2007) Clinical & Surgical Anatomy, 2nd edn. Elsevier; New Delhi.
- Snell, R.S. (2007) Clinical Anatomy: An Illustrated Review with Questions and Explanations, 3rd Edn. Lippincott Williams & Wilkins; Philadelphia.
- Slide share presentation by Gan Quan Fu, PT,
- Thieme
- <http://orthoinfo.aaos.org>