

CNS TRACTS AND PATHWAYS

David Kachlík

Processing of signals in the CNS – 4 levels

- spinal – elementary muscles reflexes
 - s: cells of dorsal columns of the grey substance
 - m: motoneurons of ventral columns of the grey substance
- stem – coordination of spinal muscle reflexe, more complex reflexes /caugh, suction, swolowing.../
 - s: cells of lateral part of reticular formation and sensitive nuclei of cranial nerves
 - m: cells of medial part of reticular formation and motoneuron nuclei of cranial nerves
- subcortical – complex movements, coordination of movements
 - s: thalamus
 - m: striatum and pallidum
- cortical – planning and supervision of voluntary motorics, creation of memory (higher neuronal activity)
 - s+m: cortical regions
 - they are supervised by association regions (conected to each other + pathways of cerebellum)

Basic division of brain tracts/pathways

- **Association** (regions in the same hemisphere)
- **Commissural** (corresponding places of both sides)
- **Projection** (different levels of the CNS)

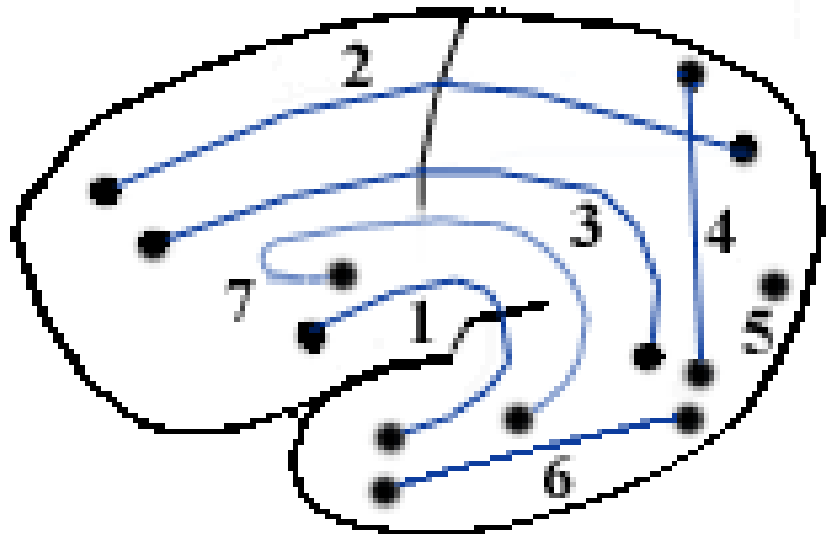
Association pathways (= Fibrae associationis telencephali)

Short (= fibrae associationis breves)

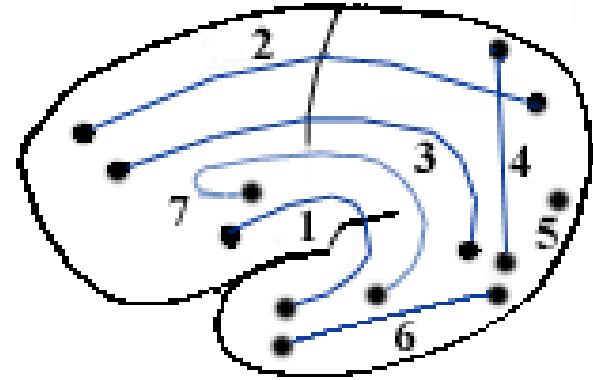
- fibrae arcuatae cerebri



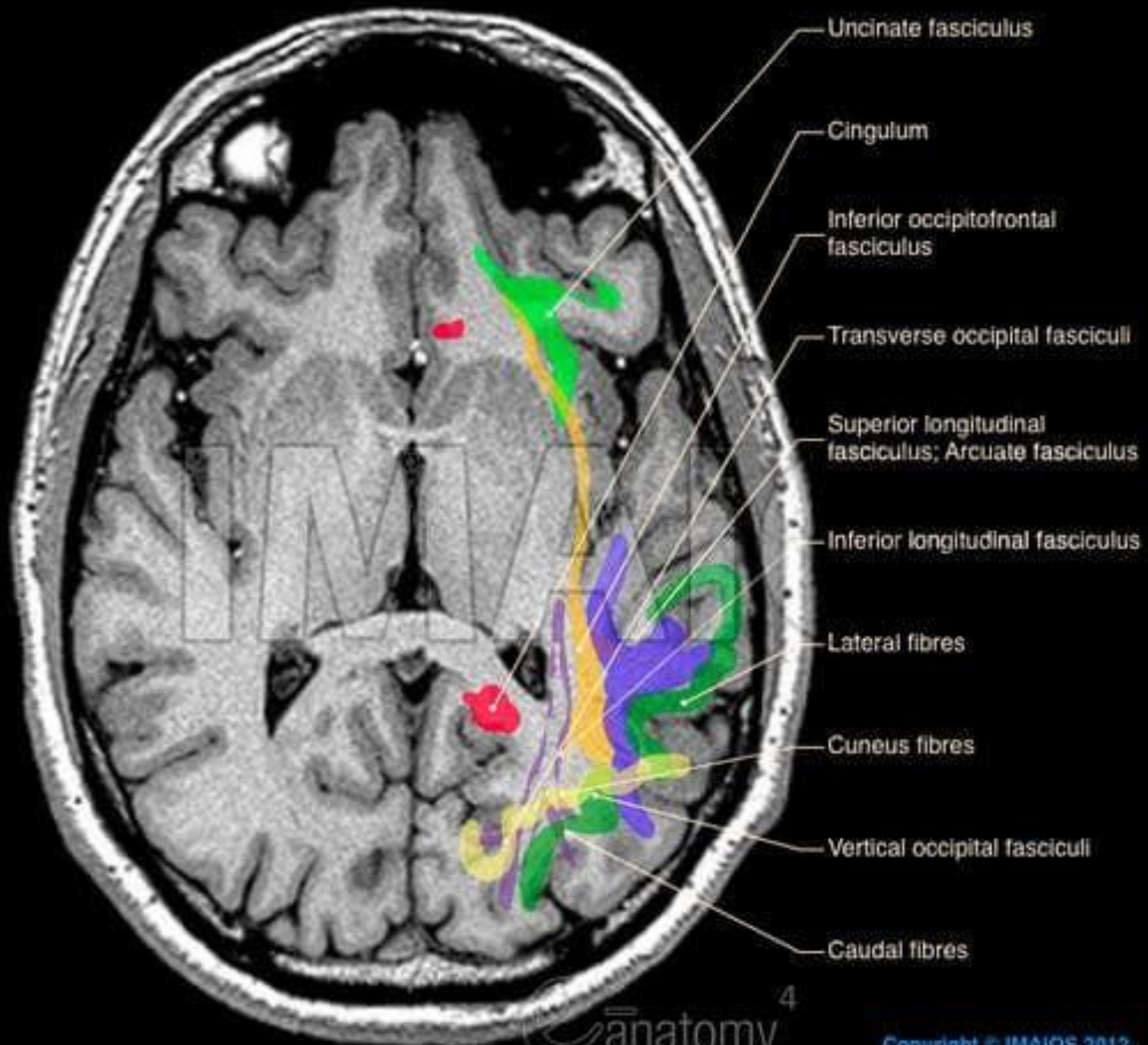
Long (= fibrae associationis longae)



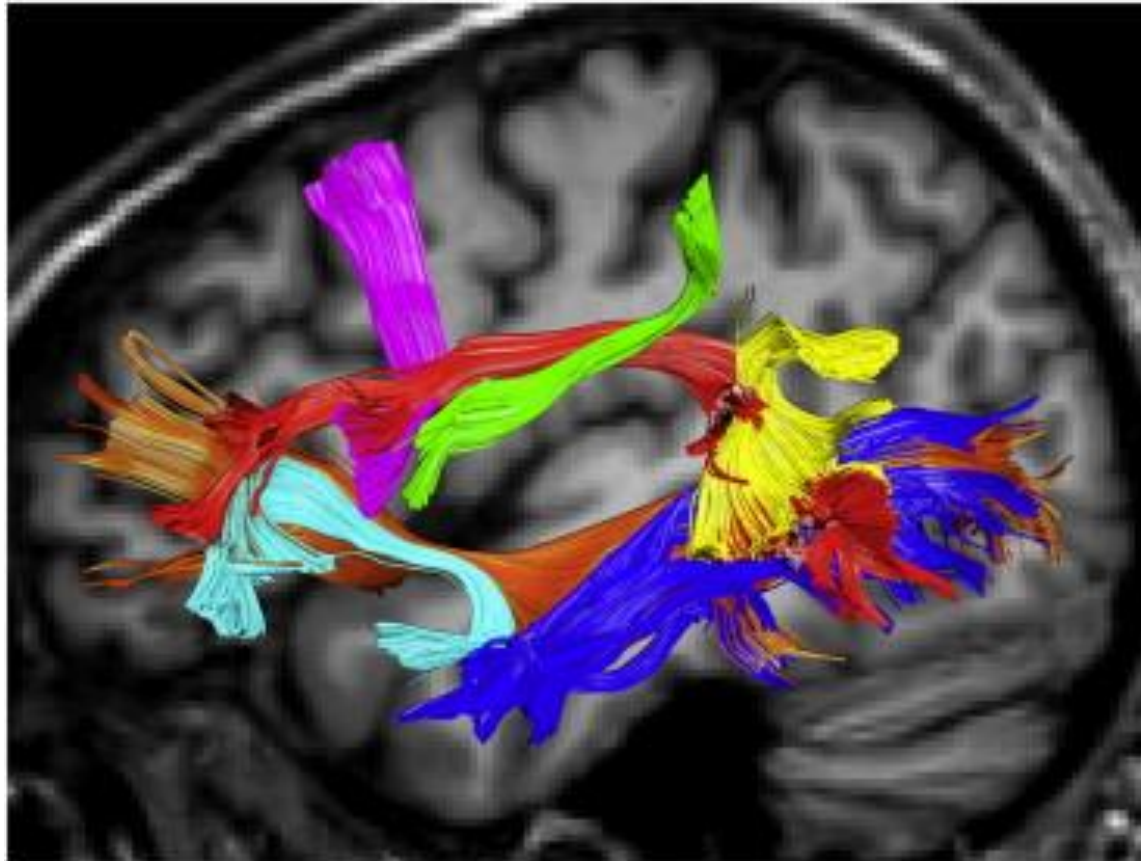
Long association pathways










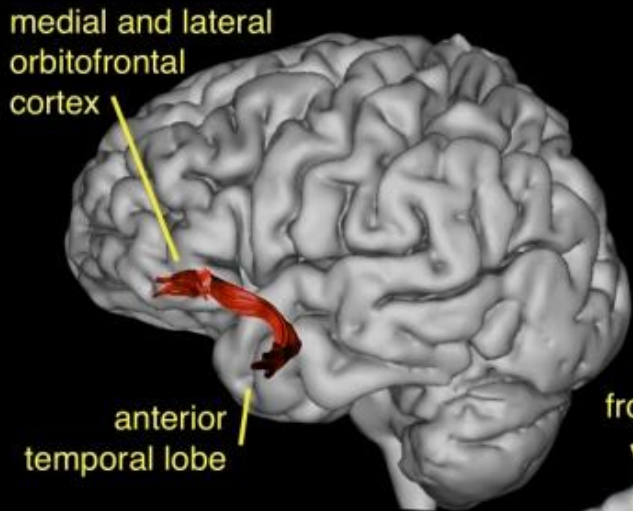
- fasciculus occipitofrontalis sup.
+ inf. (2,6)
- fasciculus longitudinalis sup.(3)
 - between frontal and occipital cortex
 - **fasciculus arcuatus** – between speech centers
- fasciculus longitudinalis inf. (6)
 - between frontal and occipital cortex (along tractus opticus)
- fasciculi occipitales verticales + horizontales (4,5)
- **fasciculus uncinatus** (1)
 - orbitofrontal cortex – temporal cortex
- **cingulum** (7)
 - in depth of gyrus cinguli between parts of limbic cortex



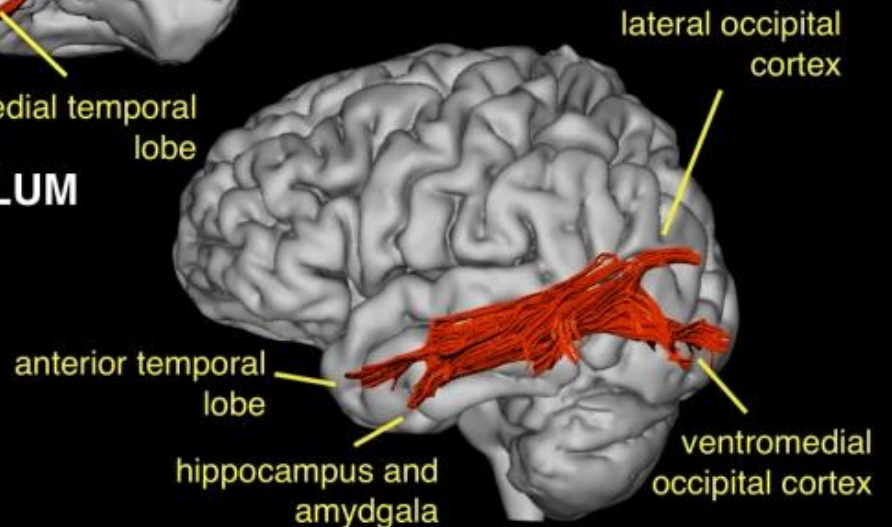
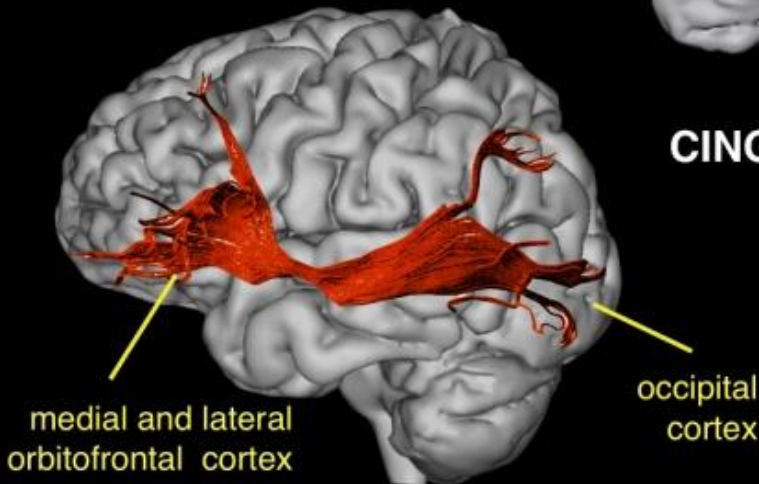
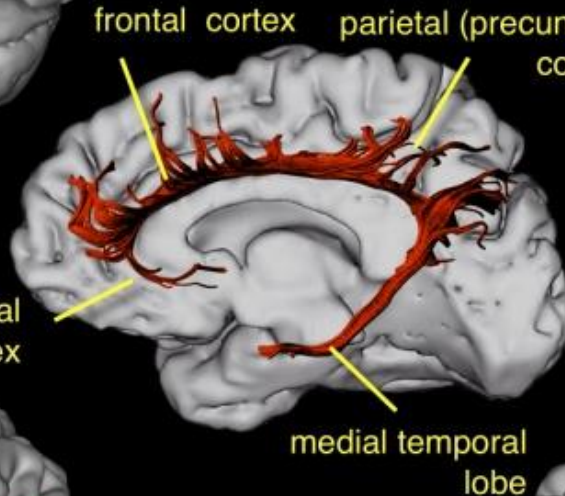
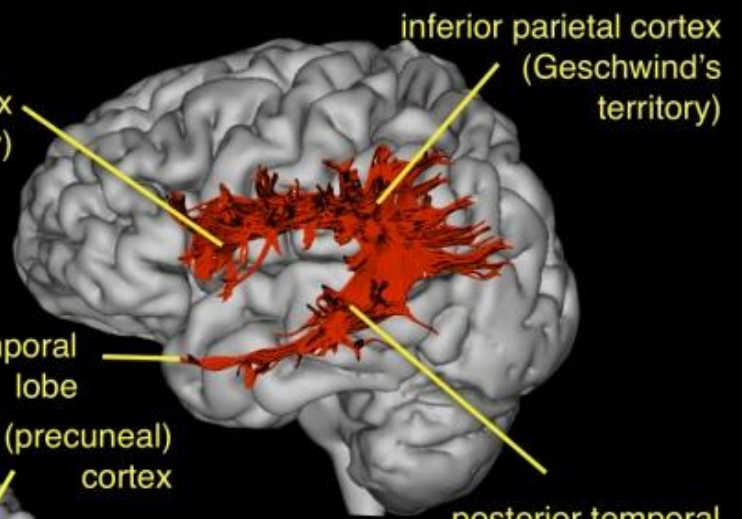
Long association pathways



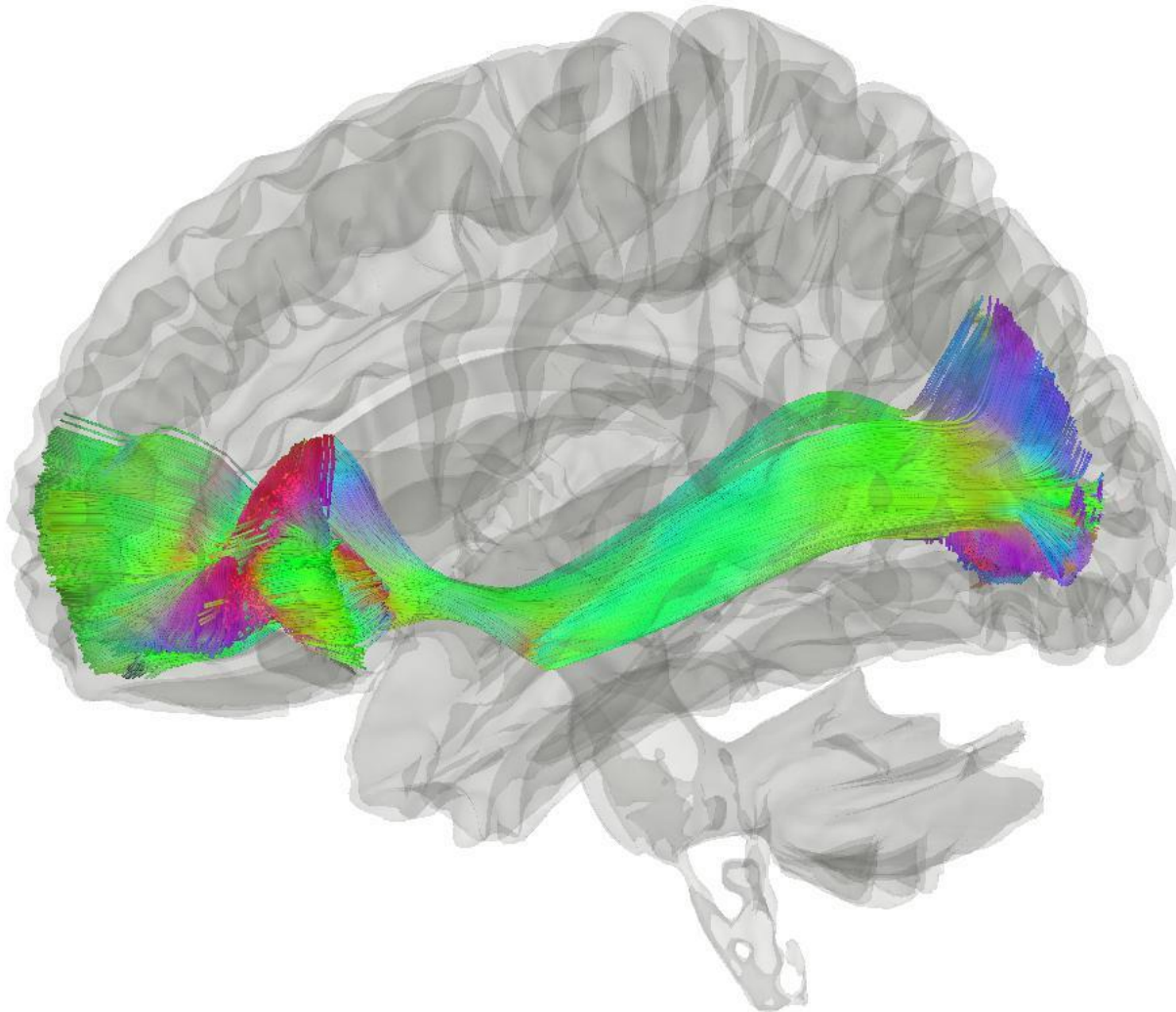
-  Arcuate fasciculus (long segment)
-  Arcuate fasciculus (anterior segment)
-  Arcuate fasciculus (posterior segment)
-  Frontal aslant tract
-  Uncinate
-  Inferior fronto-occipital fasciculus
-  Inferior longitudinal fasciculus



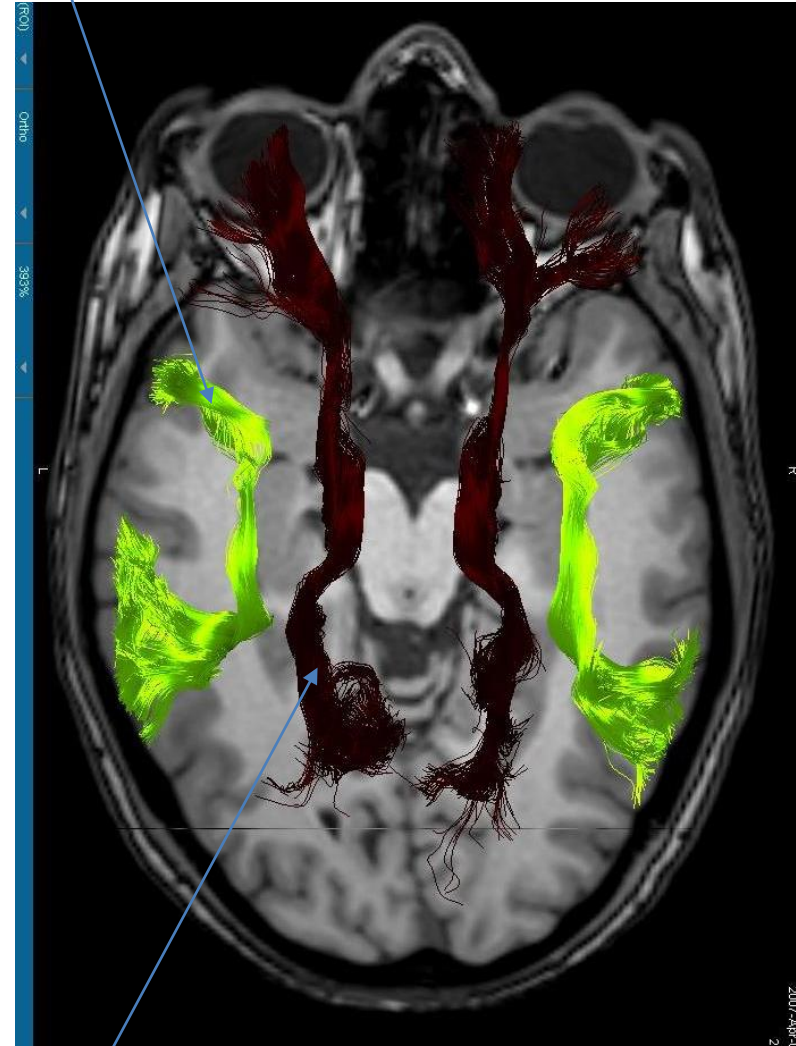
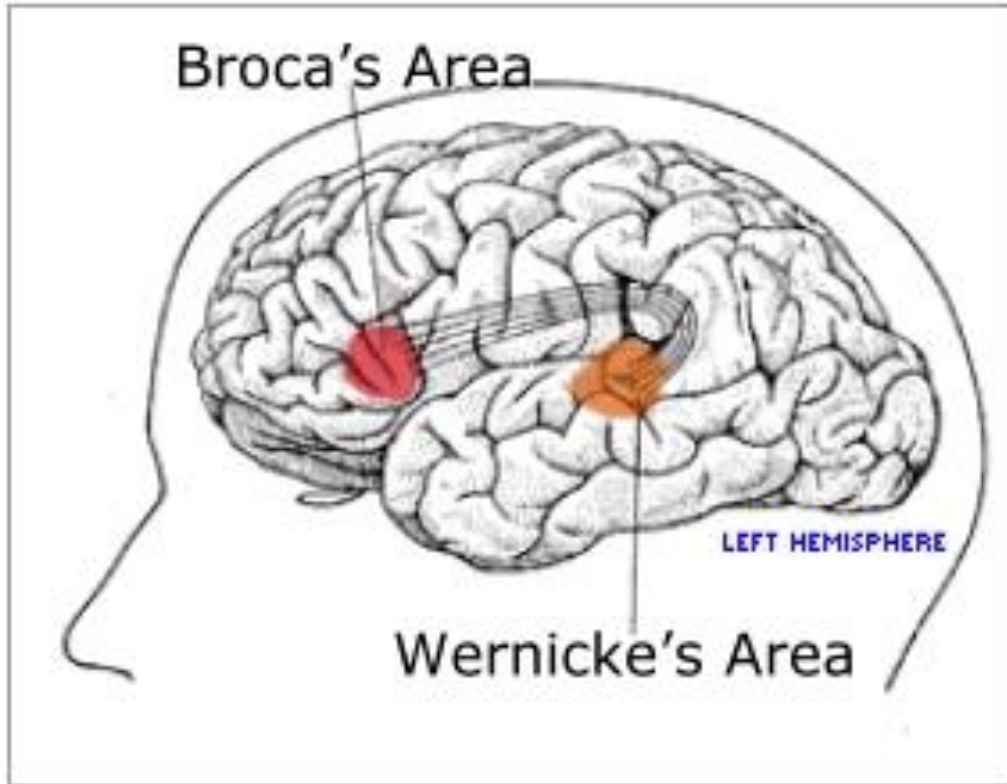
inferior frontal cortex (Broca's territory)



Fasciculus occipitofrontalis (sup. + inf.)



Fasciculus arcuatus



Fasciculus longitudinalis superior

Fasciculus longitudinalis inferior

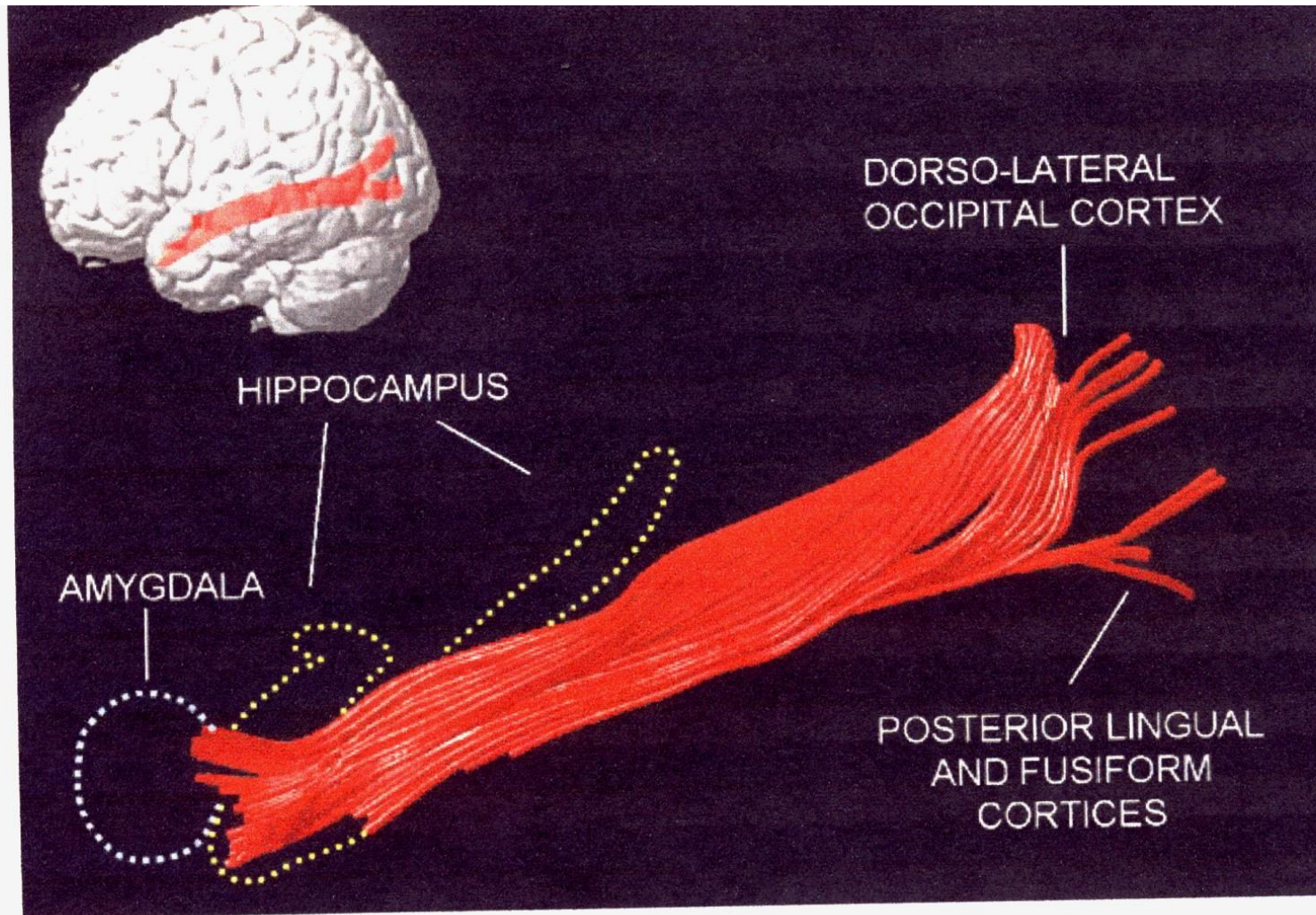


Fig. 7 Reconstruction of the ILF in the average DT-MRI data set. The long fibres originate from extrastriate areas of the occipital lobe and terminate in lateral temporal cortex and medial temporal cortex in the region of the amygdala and parahippocampal gyrus.

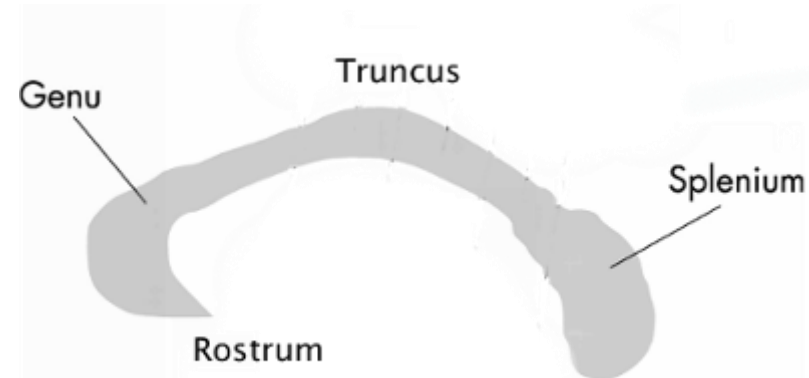
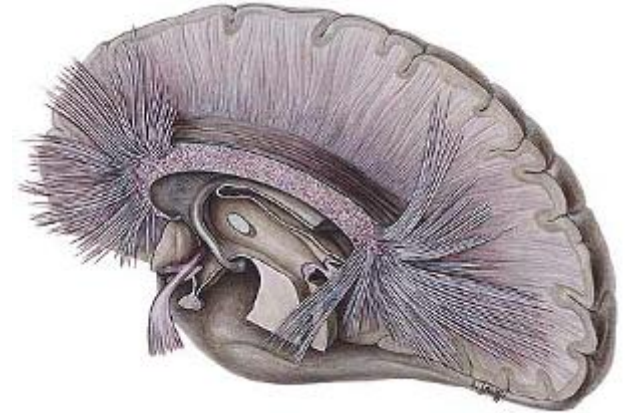
Commissural pathways (Fibrae commissurales telencephali)

Cortical

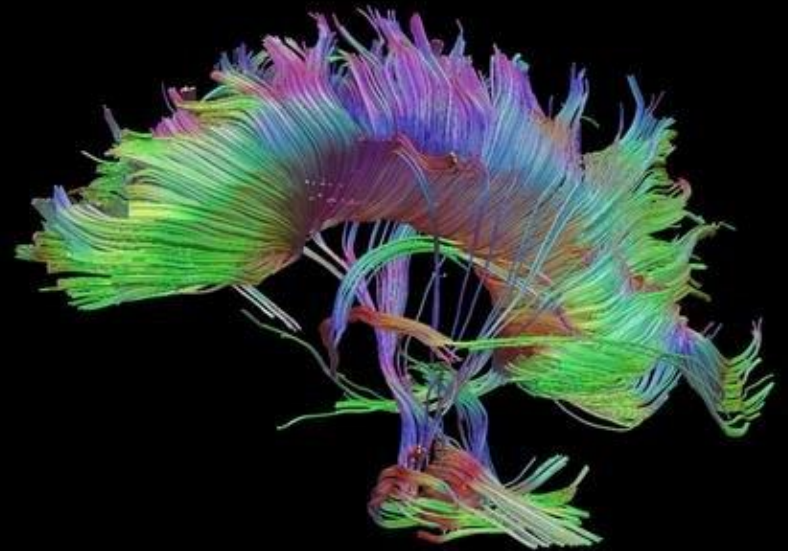
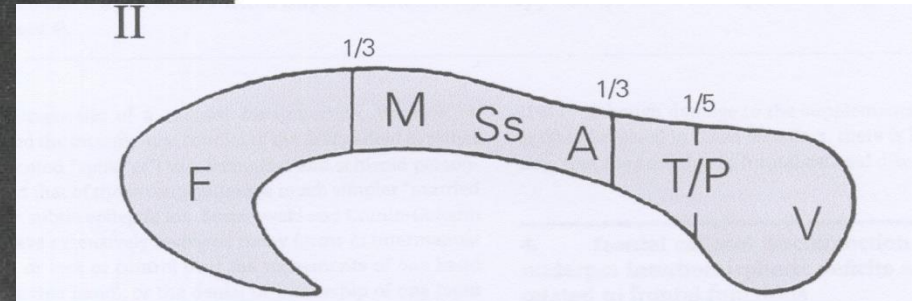
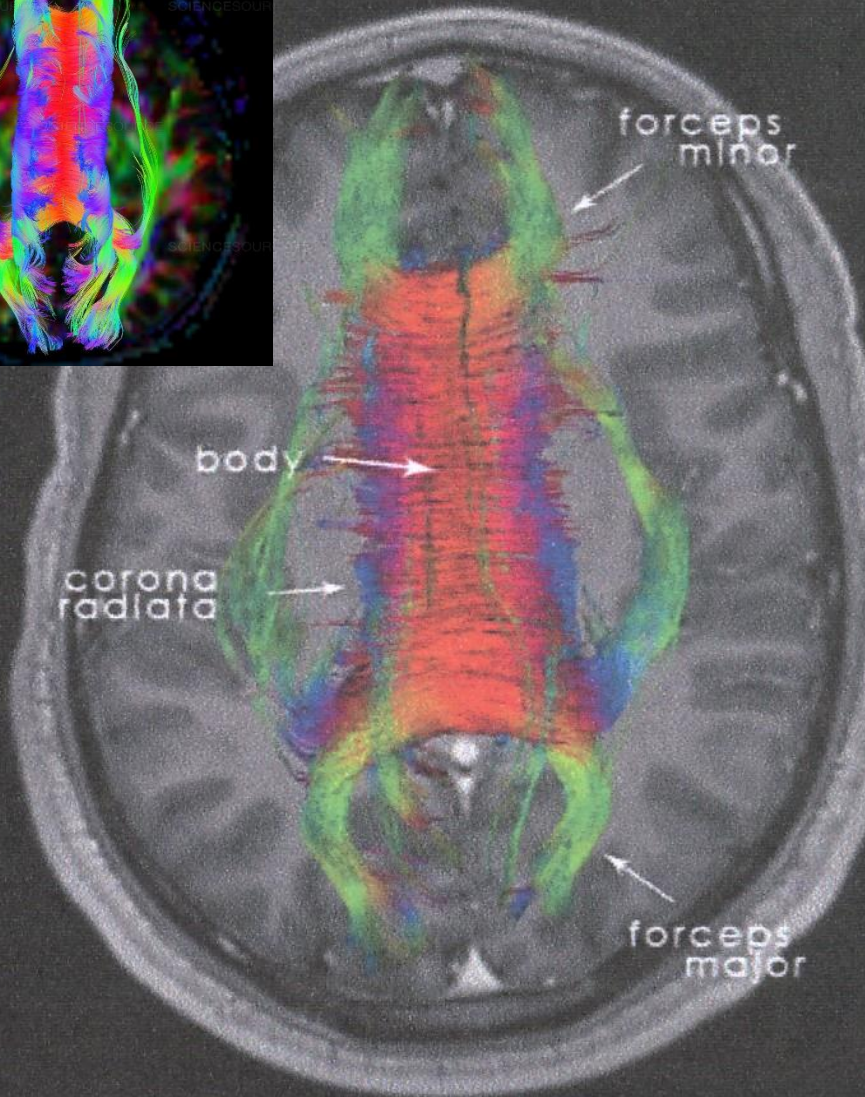
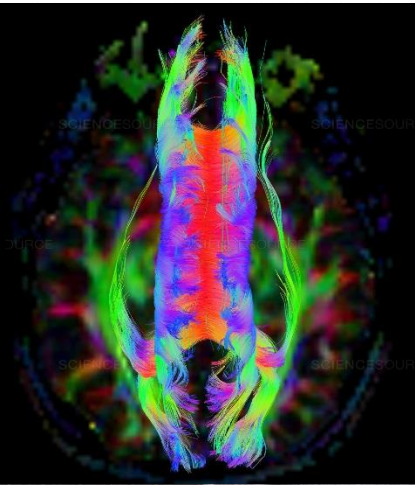corpus callosum

= fibrae corporis callosi

- connects all lobes, in temporal only auditory areas
- rostrum, genu, truncus, splenium
- forceps ant. + post.
- radiatio corporis callosi



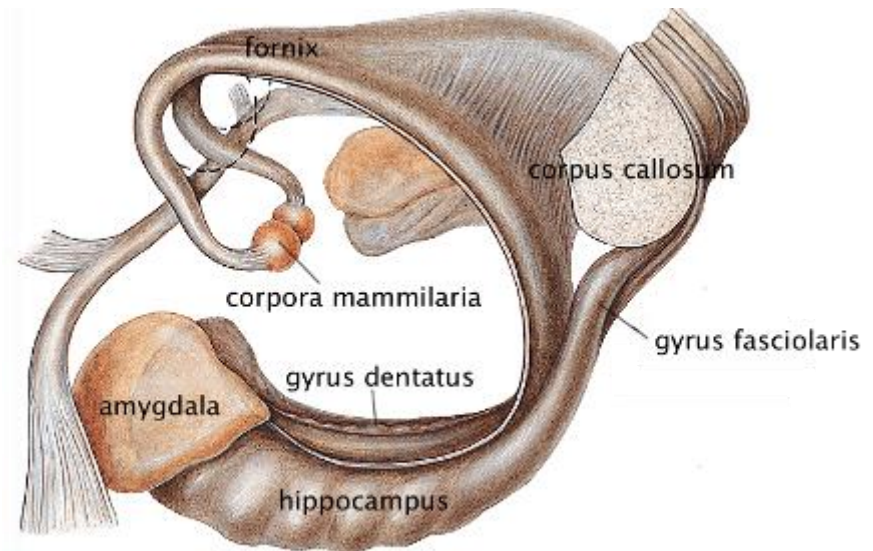
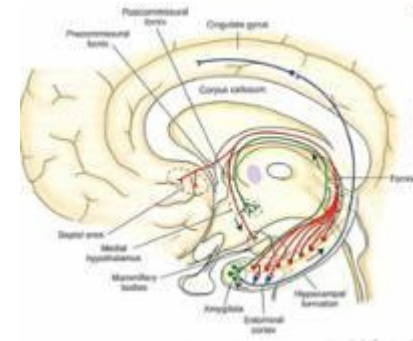
Corpus callosum – tractography



Commissural pathways (Fibrae commissurales telencephali) Cortical

commissura fornicis = lyra Davidis

- commissure of archicortex
 - columnae
 - fibrae precommissurales
 - fibrae postcommissurales
 - pars libera
 - pars tecta
 - corpus
 - commissura
 - crura



Commissural pathways (Fibrae commissurales telencephali)

Cortical

- commissura anterior

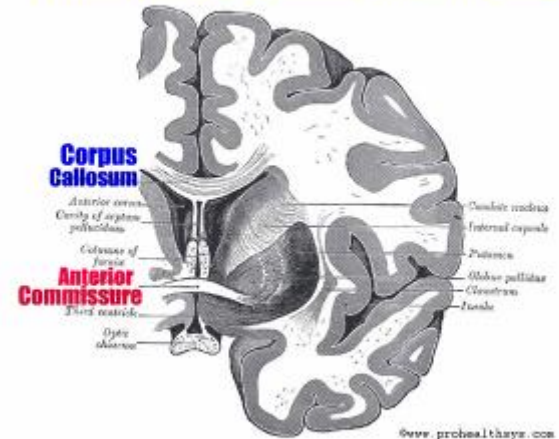
- pars anterior („olfactoria“)

- connects olfactory parts
- commissure of paleocortex

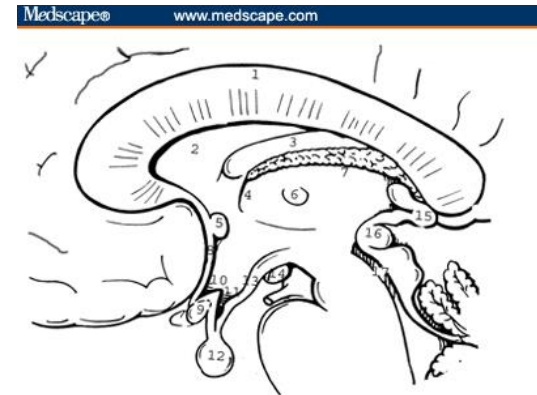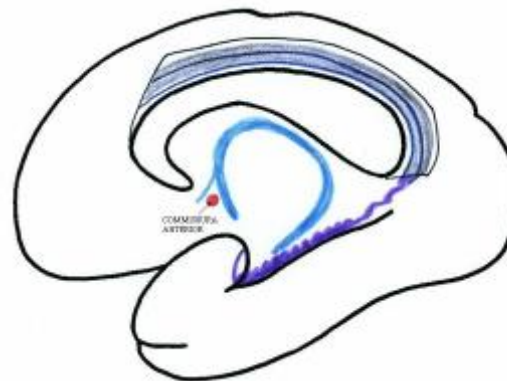
- pars posterior

- connects regions of temporal lobe except auditory and hippocampal parts

The corpus callosum is the largest commissural pathway in the brain consisting of over 200 million nerve fibers-axons



The anterior commissure is a small band of approximately 50,000 axons that connects the cerebral hemispheres



Commissural pathways (Fibrae commissurales telencephali)

Subcortical

Brainstem

- **commissura habenularum**

- connects nuclei habenulares of both sides

- **commissura posterior**

- commissural fibers

- nuclei posteriores thalalmi, colliculi sup., ncl. pretectales

- non-commissural fibers = decussation fibers

- takes fibers from ncl. interstitialis *Cajali* + ncl. commissurae posterioris *Darkschewitschi* into contralateral fasciculus longitudinalis medialis

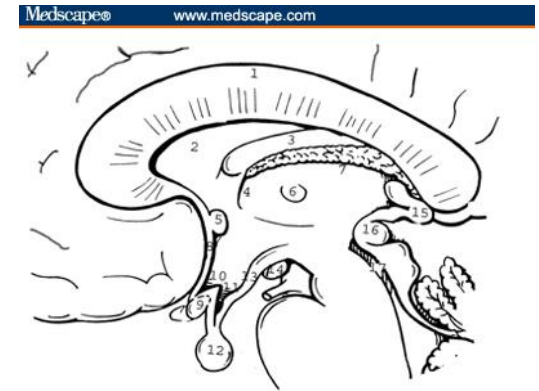
- commissura supraoptica ventralis et dorsalis

- commissura colliculi superioris et inferioris

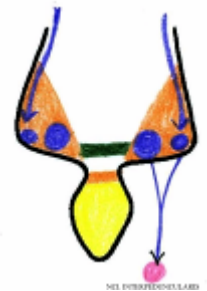Spinal cord

- commissura alba anterior et posterior

- tractus spinothalamicus, spinoreticularis, spinocerebellaris ant., corticospinalis ant.

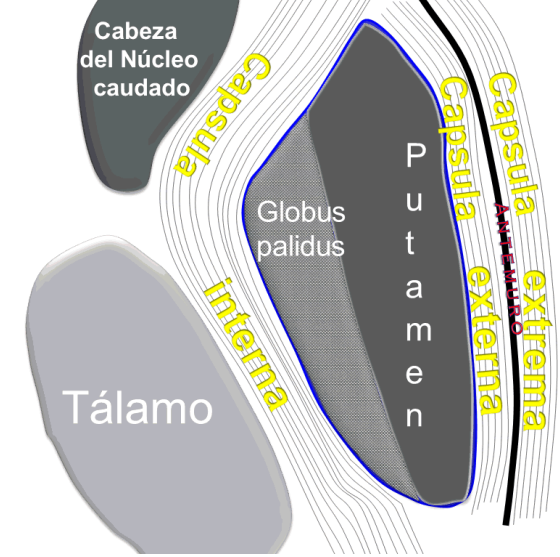


Source: Neurosurg Focus © 2005 American Association of Neurological Surgeons

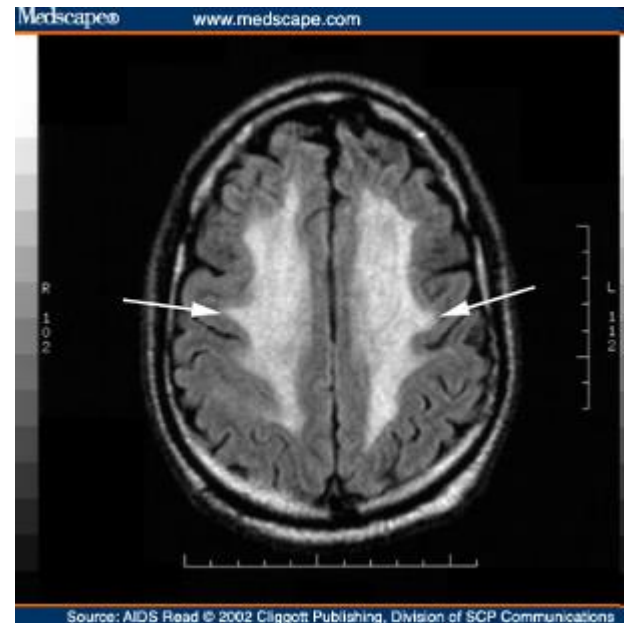
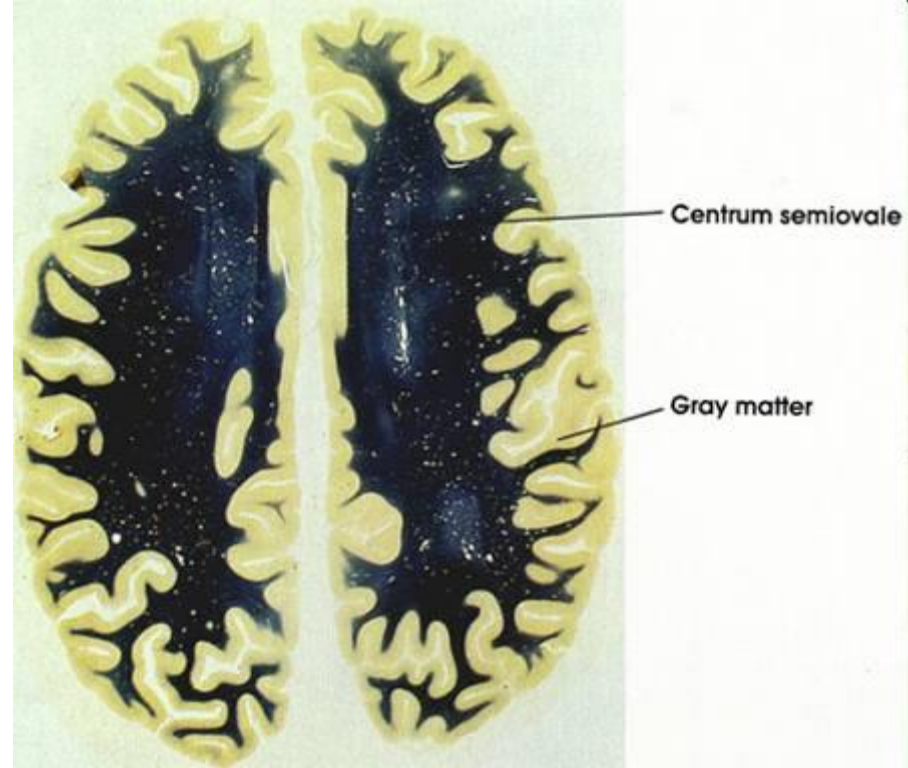
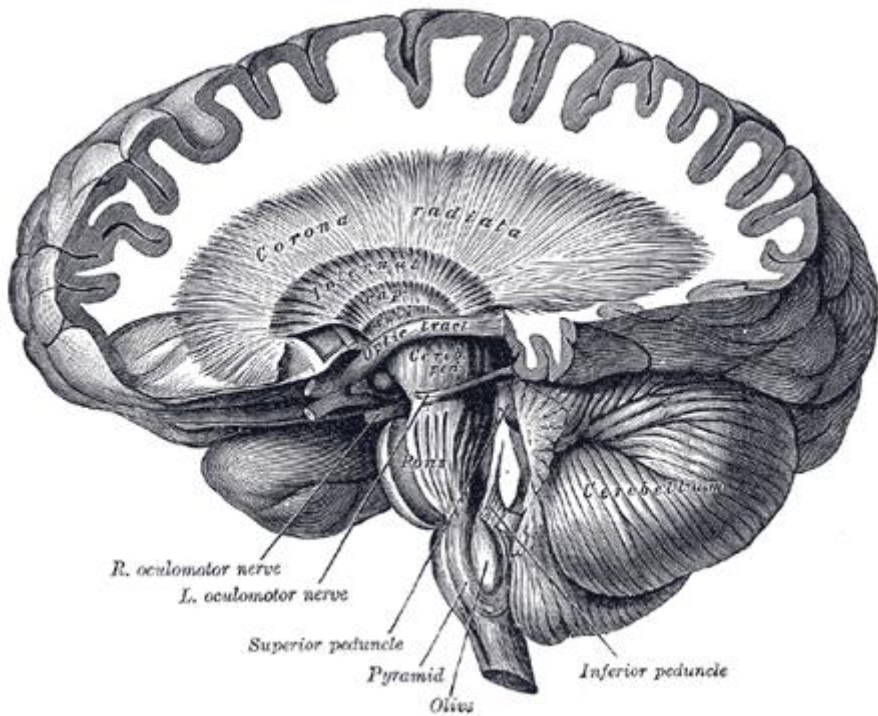


White matter

- centrum semiovale
- corona radiata
- **capsula interna**
 - between thalamus + nucleus caudatus (medially) and nucleus lentiformis (laterally)
 - crus anterior, genu, crus posterior
- **capsula externa**
 - between nucleus lentiformis (medially) and claustrum (laterally)
 - contains long association fibers processing speech
- **capsula extrema**
 - between claustrum (medially) a insular cortex (laterally)

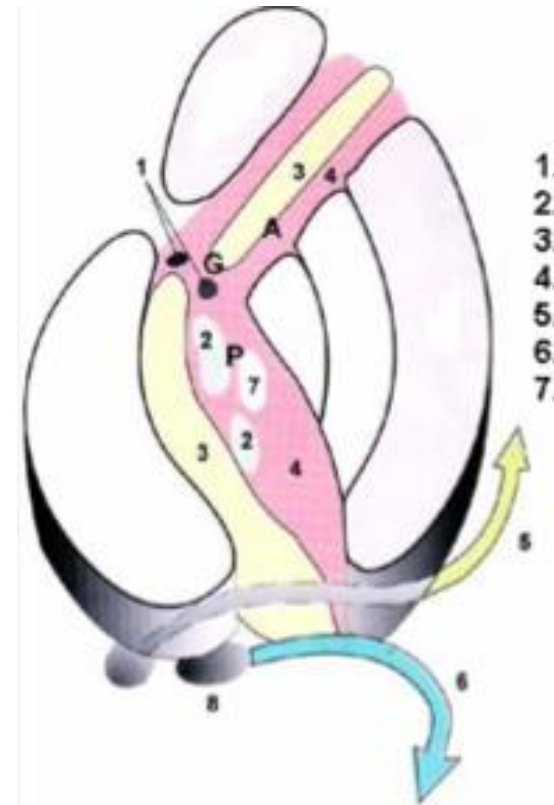


White matter

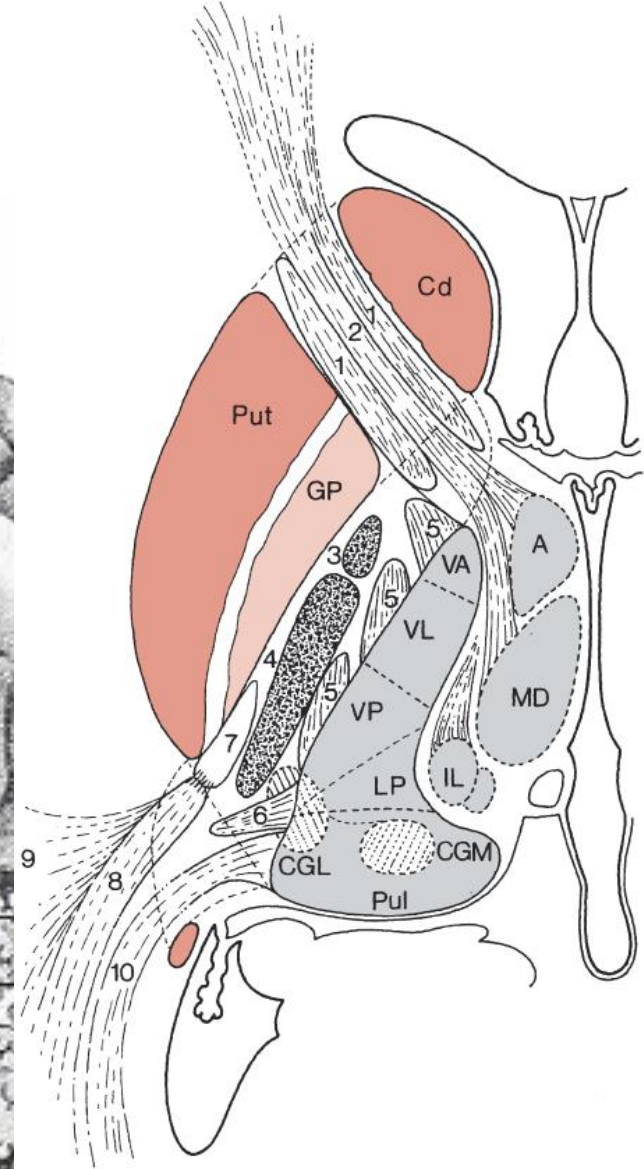
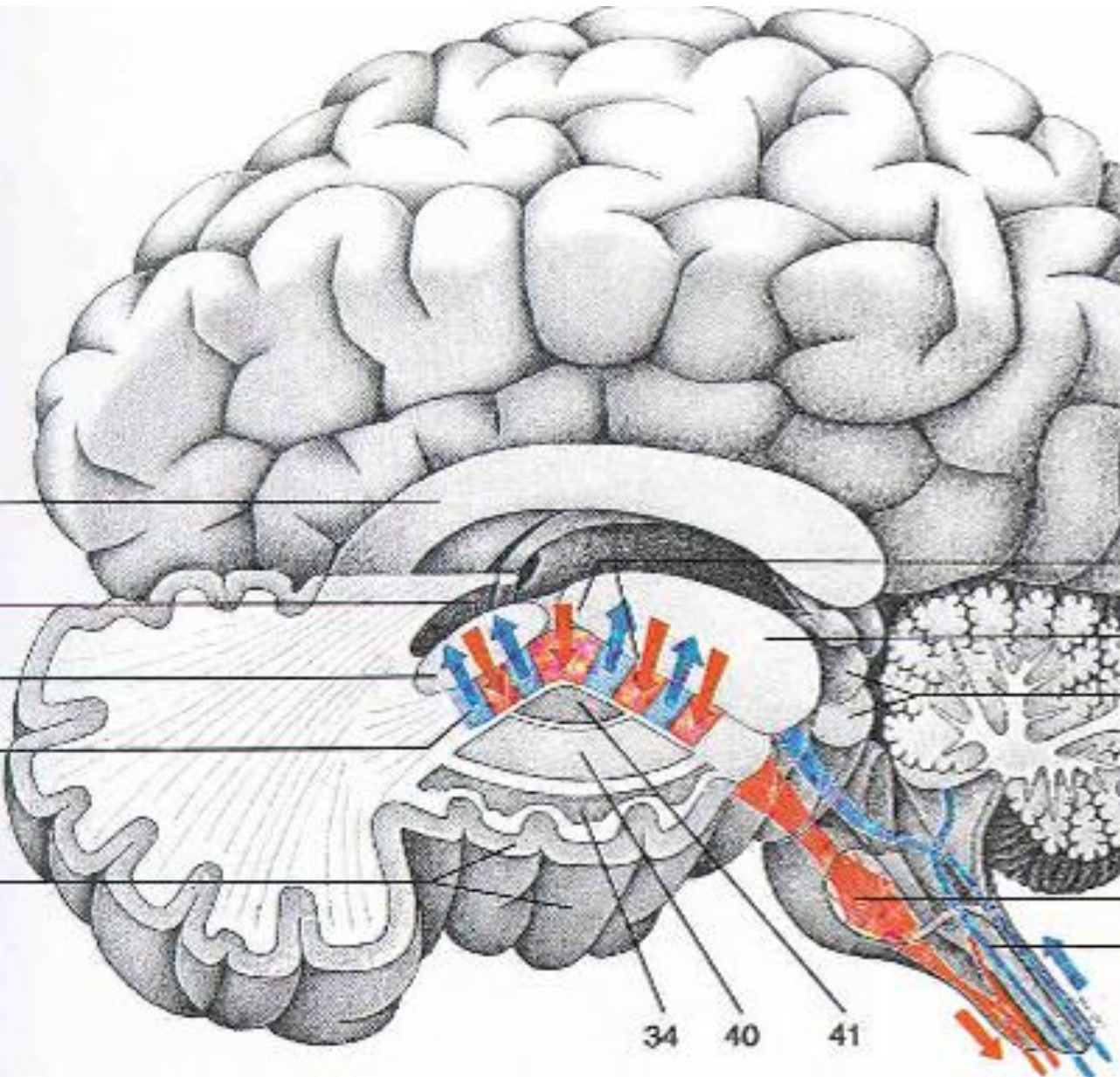


Capsula interna

- **crus anteriorus**
 - radiatio thalami ant. (tr. thalamocorticalis)
 - tr. frontopontinus
- **genu**
 - tr. corticonuclearis
- **crus posterius**
 - radiatio thalami centralis (tr. thalamocorticalis)
 - tr. corticospinalis in somatotopic arrangement
 - tr. corticoreticularis + tr. corticorubralis
 - tr. corticothalamicus
 - radiatio thalami post. (tr. thalamocorticalis)
 - tr. parieto- , temporo-, occipitopontinus
 - radiatio optica
 - radiatio acustica
 - *pars retrolenticularis et sublenticularis* (posterior part of crus posterius)
- *pontes grisei caudatolenticulares*



Capsula interna



Projection pathways I.

- ascending, afferent
 - sensory
 - direct
 - lemniscal system
 - » **spino-bulbo-thlamo-cortical** (lemniscus medialis)
 - anterolateral system (lemniscus spinalis)
 - » **spinothalamic tract**
 - » **spinoreticular tract**
 - » spinotectal tract
 - » sensory pathway of cranial nerves (lemniscus trigeminalis)
 - indirect (cerebellar) – 4
 - special sensory
 - » **visual pathway**
 - » **auditory pathway** (lemniscus lateralis)
 - » vestibular pathway
 - » **olfactory pathway**
 - » **gustatory pathway**

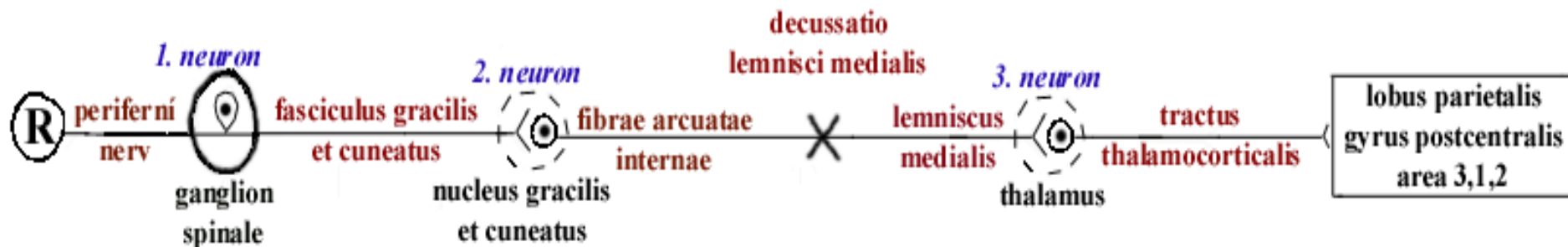Projection pathways II.

- descending, efferent
 - **pyramidal pathway** (tractus pyramidalis)
 - **fibrae corticospinales**
 - **fibrae corticonucleares**
 - **fibrae corticopontinae, corticoreticulares, -olivares**
 - **extrapyramidal pathways**
 - **tractus reticulospinalis**
 - **tractus vestibulospinalis**
 - tractus tectospinalis
 - tractus rubrospinalis
 - tractus raphespinalis
 - **brainstem pathways**
 - fasciculus longitudinalis medialis
 - fasciculus longitudinalis posterior

Projection → Ascending → Sensory → Direct:

TRACT OF DORSAL FASCICULI

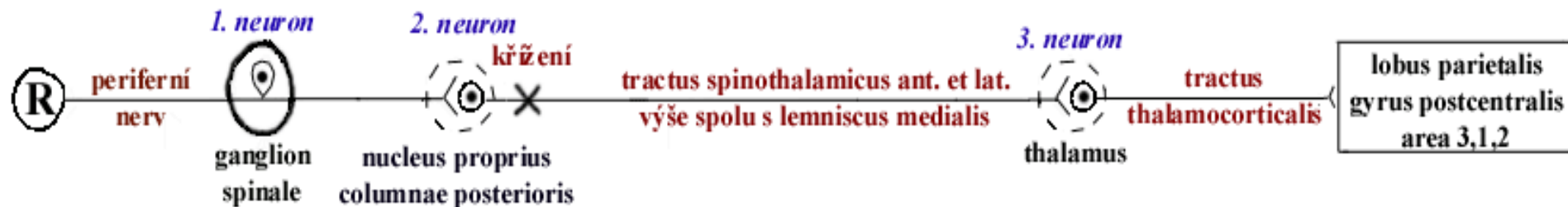
- called *lemniscal system*
- = *tractus spino-bulbo-thalamo-corticalis*
- 3-neuronal pathway, decussated in medulla oblongata
- fasciculus gracilis (T7–S5) et cuneatus (C1–T6)
- touch, vibrations, deep pressure, tension, proprioception from joints, tendons and muscles
- disorder: sensory ataxia (*sclerosis multiplex, tabes dorsalis*) – tabic dissociation of sensation



Projection → Ascending → Sensory → Direct →
Anterolateral system:

TRACTUS SPINOTHALAMICUS

- part of *anterolateral system* (neospinothalamic tract)
- 3-neuronal pathway, decussated in medulla spinalis
- fast pain, heat + cold (lat.) and gross sensitivity (ant.)
- lemniscus spinalis within brainstem
- from Rexed zone I,II, IV-VII
- *disorder: syringomyelia* – syringomyelic dissociation of sensation
- *stimulation / chordotomy in severe pain*



Projection → Ascending → Sensory → Direct →
Anterolateral system:

TRACTUS SPINORETICULARIS

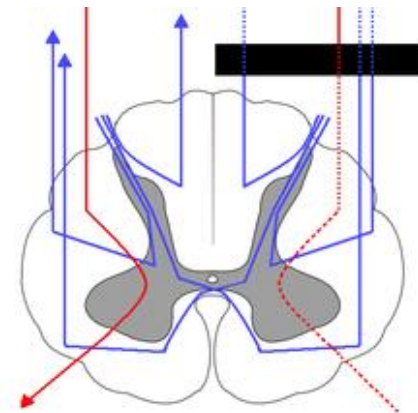
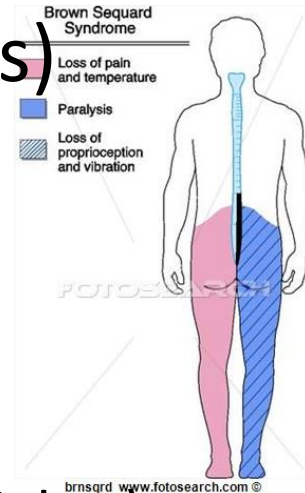
- part of *anterolateral system* (paleospinothalamic tract)
- 2(4)-neuronal pathway , usually non-decussated
- slow pain, activation ascending pathway of RF (ARAS)
- phylogenetically old pathway = arousal and affection
→ tractus reticulothalamicus (arousal – ARAS) → ncll.
intralaminares thalami → gyrus cinguli (emotion)

TRACTUS SPINOTECTALIS

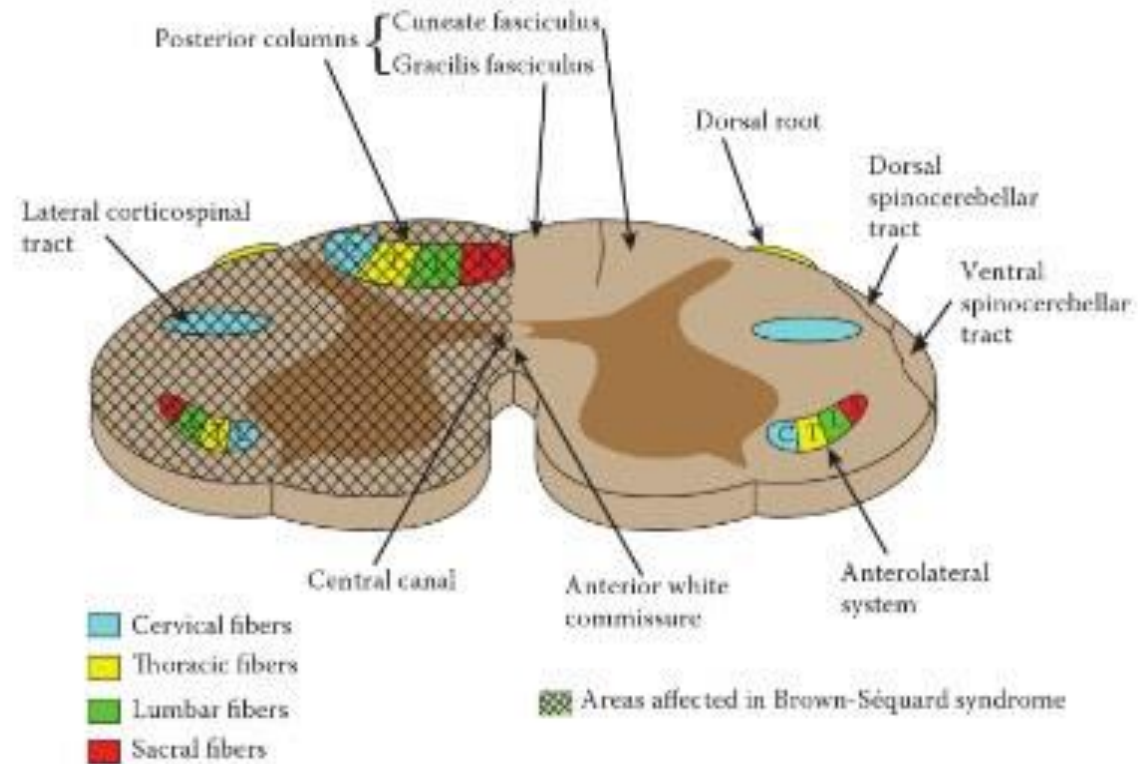
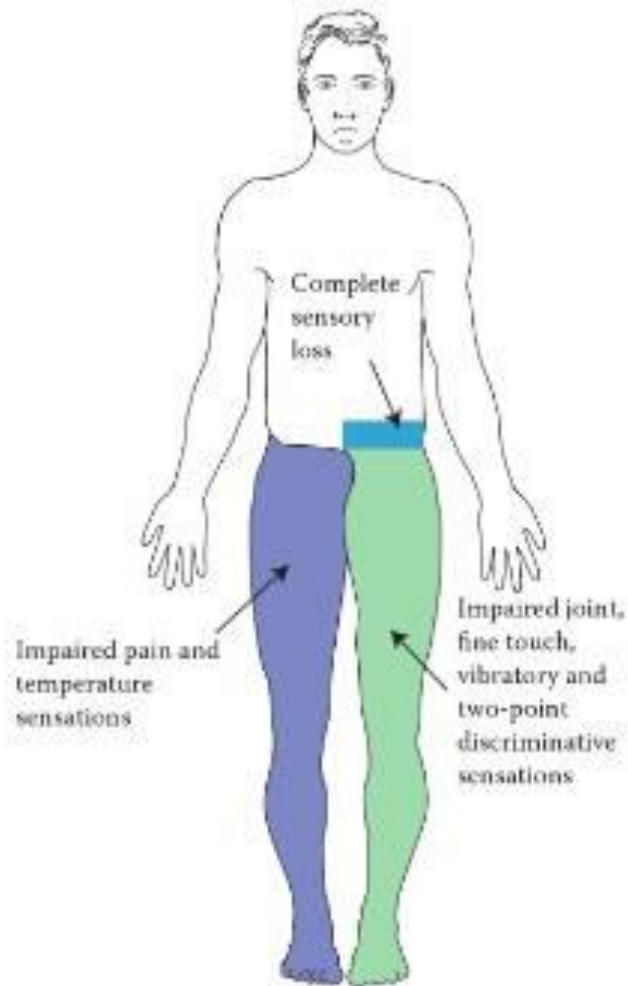
- phylogenetically old pathway, heavily reduced
- systems for motorics of muscles of eye, head and neck

BROWN-SEQUARD'S syndrome

- transversal spinal hemisyndrome
- after disappearance spinal shock (2-3 weeks)
 - ipsilateral hemiplegia
 - failure of *fibrae corticospinales*
 - contralateral analgesia = absent pain, heat and cold sensation
 - failure of anterolateral system (always 1 segment higher)
 - ipsilateral anaesthesia = absence of proprioception, touch, vibrations, tension and pressure
 - failure of dorsal fasciculi pathways
 - hyperaesthesia above the lesion
 - tactile irritability at the spot of the lesion



Brown-Sequard's syndrome



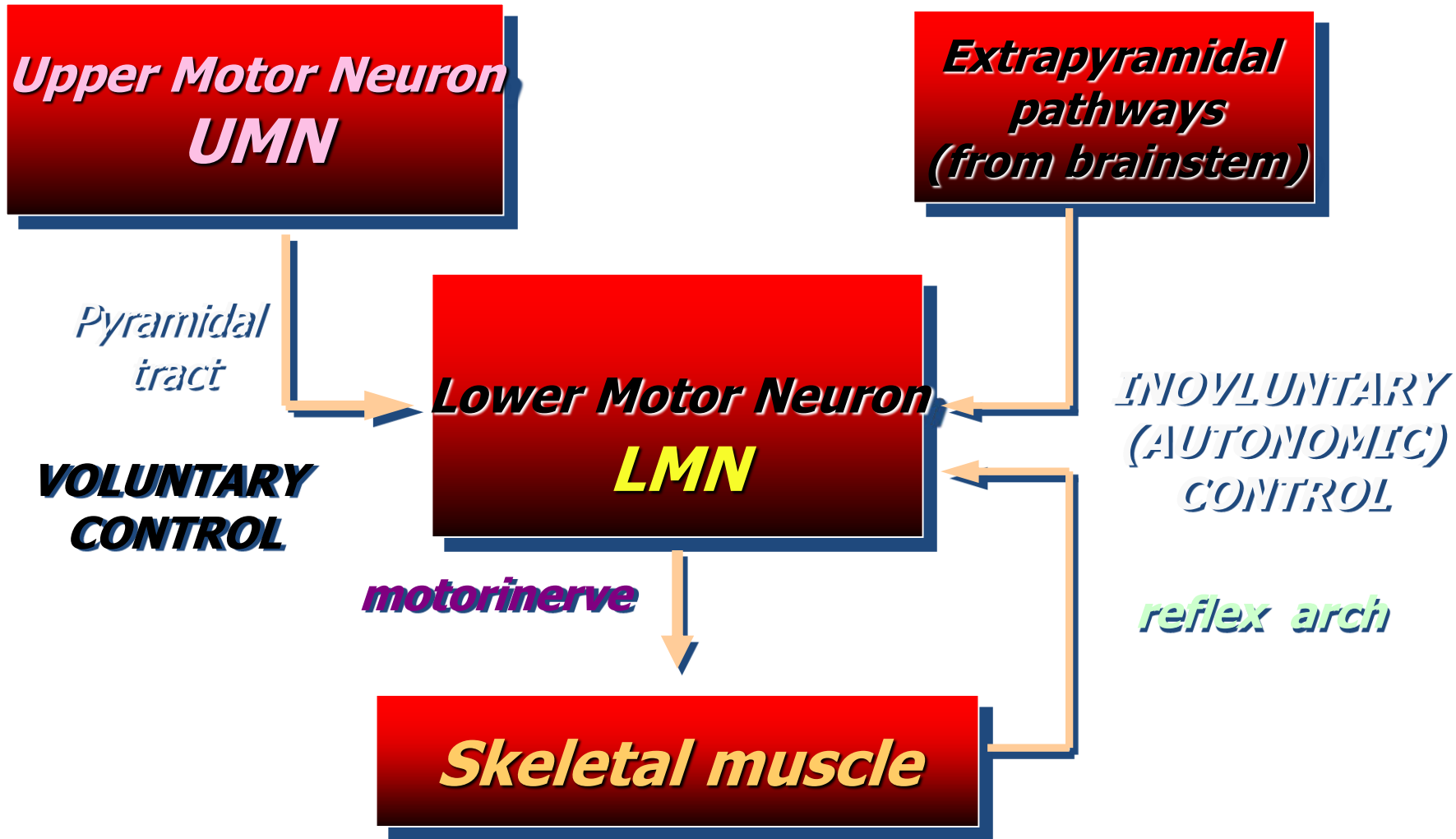
Projection → Ascending → Sensory → Direct →
Anterolateral system:

SENSORY PATHWAYS OF CRANIAL NERVES

- similar to both system for cranial nerves
- touch + proprioception (tr. trigeminothalamicus ant.) and pain from head (tr.t-th post.)
- n. V, IX, X
- lemniscus trigeminalis joins laterally lemniscus medialis



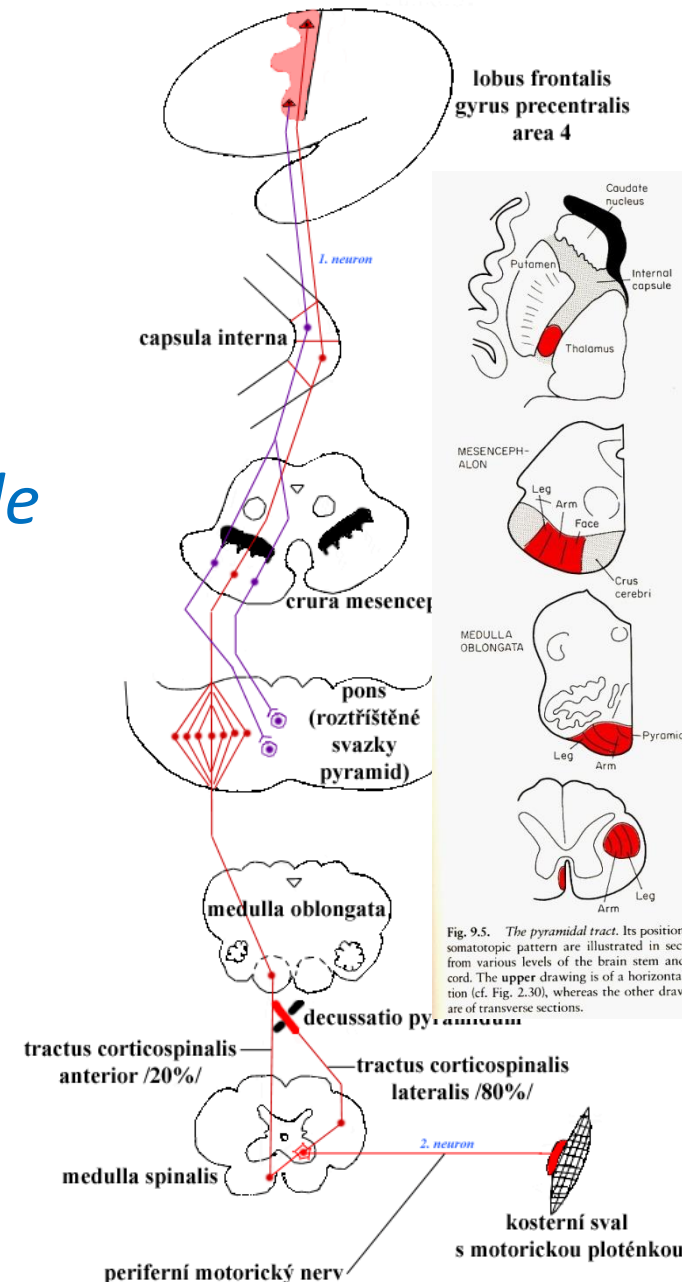
Somatomotoric system – overview

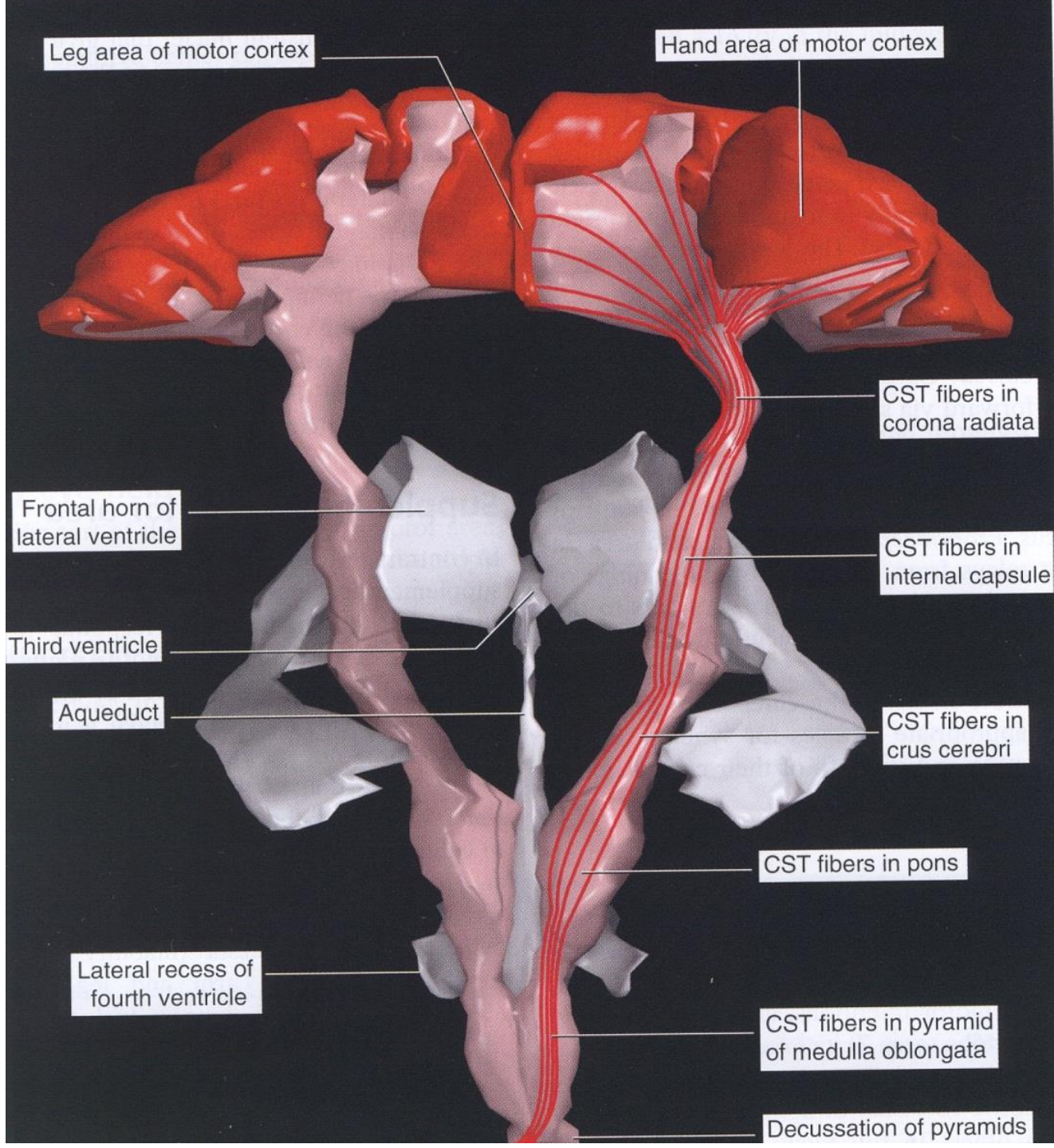


Projection → Descending →
 Tractus pyramidalis:
 FIBRAE CORTICOSPINALES

- clinical term „pyramidal pathway“
- 1-neuronal pathway
- 2-neuronal pathway: cortex → muscle
- 80% x → tr. corticospin. LAT.
- 10% → tr. cs. ANT. x → neck and UL
- 10% → joins tr. cs. LAT.
- Renshaw's cells
- „finger playing“
- failure: contralateral paralysis

TRACTUS PYRAMIDALIS
 - fibrae corticospinales (zkřížená dráha)
 - fibrae corticonucleares
 (nezkřížená dráha s výjimkou n. IV a části n. III)



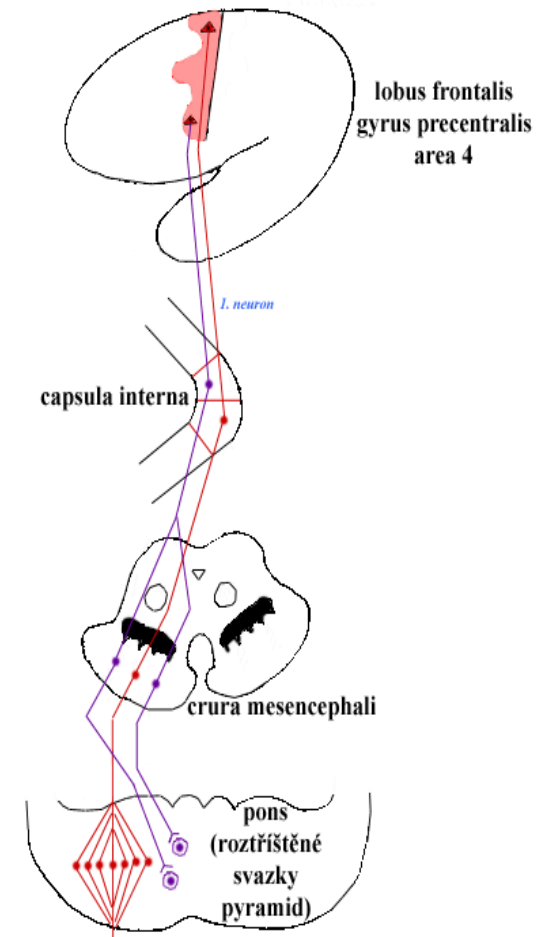


Projection → Descending → Tractus pyramidalis:

FIBRAE CORTICONUCLEARES

- 1-neuronal pathway to nuclei of cranial nerves
- 2-neuronal pathway: cortex → muscle
 - ncl. motorius n.V
 - ncl. n. VII
 - ncl. ambiguus (for n. IX,X,XI)
 - ncl. n. XII
 - for nuclei of n. III,IV,VI via interneurons + from other sources
- decussated and non-decussated
 - **only decussated** for inferior part ncl. n. VII and for whole ncl. n. XII
- *failure: hemiplegia alternans*

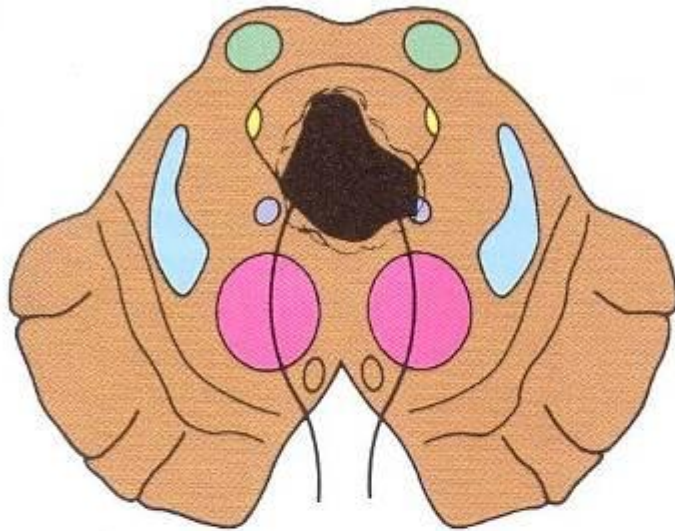
TRACTUS PYRAMIDALIS
- fibrae corticospinales (zkrřížená dráha)
- fibrae corticonucleares
(nezkřížená dráha s výjimkou n. IV a části n. III)



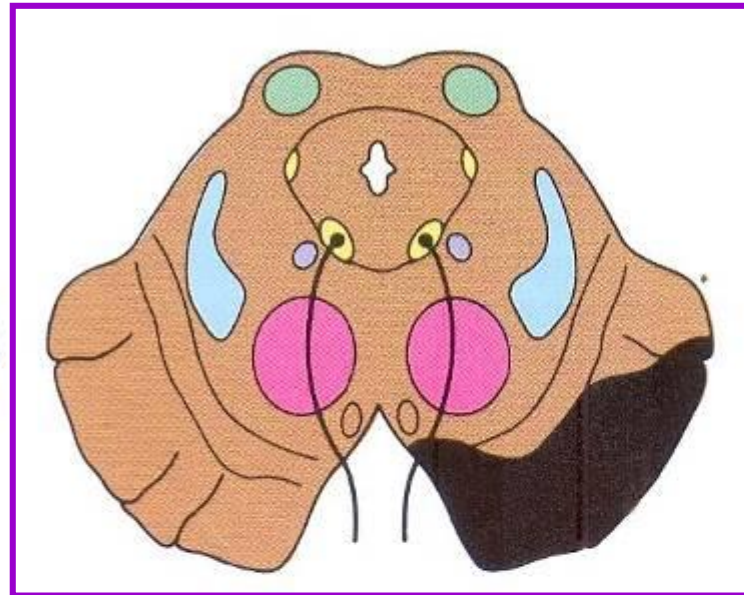
HEMIPLÉGIA ALTERNANS

- ipsilateral paralysis of muscle innervated by cranial nerves + contralateral paralysis of muscles of trunk and limbs
- fibers of cranial nerves pass corticospinal fibres → *double lesion*
 - hemiplegia alternans **superior**
(Weber) – n. III
 - Hemiplegia alternans **media**
(Millard-Gubler) – n. VII
 - Hemiplegia alternans **inferior**
(Jackson II) – n. XII

Sectio mesencephali

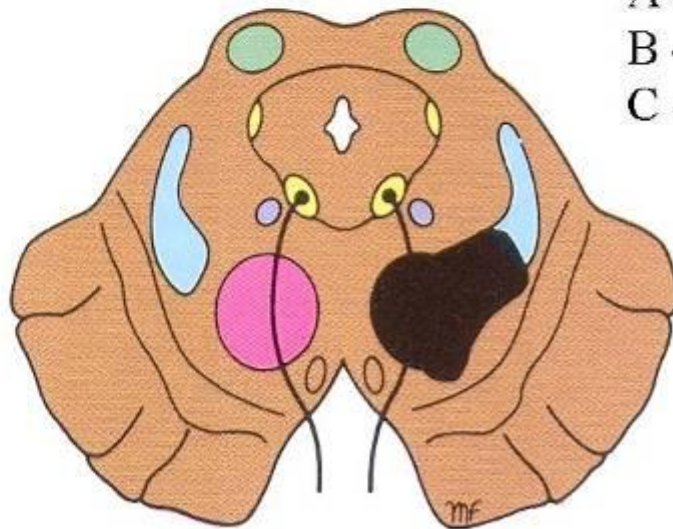


A



B

- A - tumor in aqueductu
- B - hemiplegia alternans superior (Weberi)
- C - syndroma Benedikti



C

Projection → Descending → Extrapyramidal pathways:

TRACTUS VESTIBULOSPINALIS

- **tr. vestibulospinalis lateralis**
 - from ncl. vestibularis lateralis *Deitersi*
 - non-decussated
 - excitation of extensors and epaxial (postural) muscles
- **tr. vestibulospinalis medialis**
 - from ncl. vestibularis medialis
 - both decussated and non-decussated
 - into fasciculus longitudinalis medialis → cervical spinal cord
 - reflex eye-head in one plane, stabilization of head and eyes during movement

Projection → Descending → Extrapyramidal pathways: :
TRACTUS RETICULOSPINALIS

lokomotion center – inferior RF of mesencephalon
→ gait

- pons → non-decussated → funiculus ant. → activation of extensors
- medulla oblongata → partially decussated → funiculus lat. → activation of flexors
- *controls gamma loops, muscle tone*
- *integrates influence of cortex, cerebellum, hypothalamus and limbic system*

Projection → Descending → Extrapyramidal pathways:

all continues from fibres originating in cortex and output BG
basic movements (gait, shaking hand)

- **tractus tectospinalis**

- motorics of head and neck
- decussatio tegmentalis posterior,
- terminates in cervical spinal cord

- **tractus rubrospinalis**

- magnocellular part of nucleus ruber
- (rudimentary in humans according to some opinions)
- excitation of flexors, inhibition of extensors of proximal muscles of UL
- decussatio tegmentalis anterior
- terminates in cervical spinal cord

Projection → Descending → Extrapyramidal pathways:

- **tractus raphespinalis**

- serotonin, decussated and non-decussated
- inhibition of pain at spinal cord level

- **tractus interstitiospinalis**

- within fasciculus longitudinalis medialis, non-decussated
- tone of posterior neck muscles based on visual and vestibular stimuli

- ***central autonomic pathway***

- sympathetic – baroreceptors
- parasympathetic – pontine micturion and defecation centers → Onuf's center S2-4

3 systems of motorics according to function

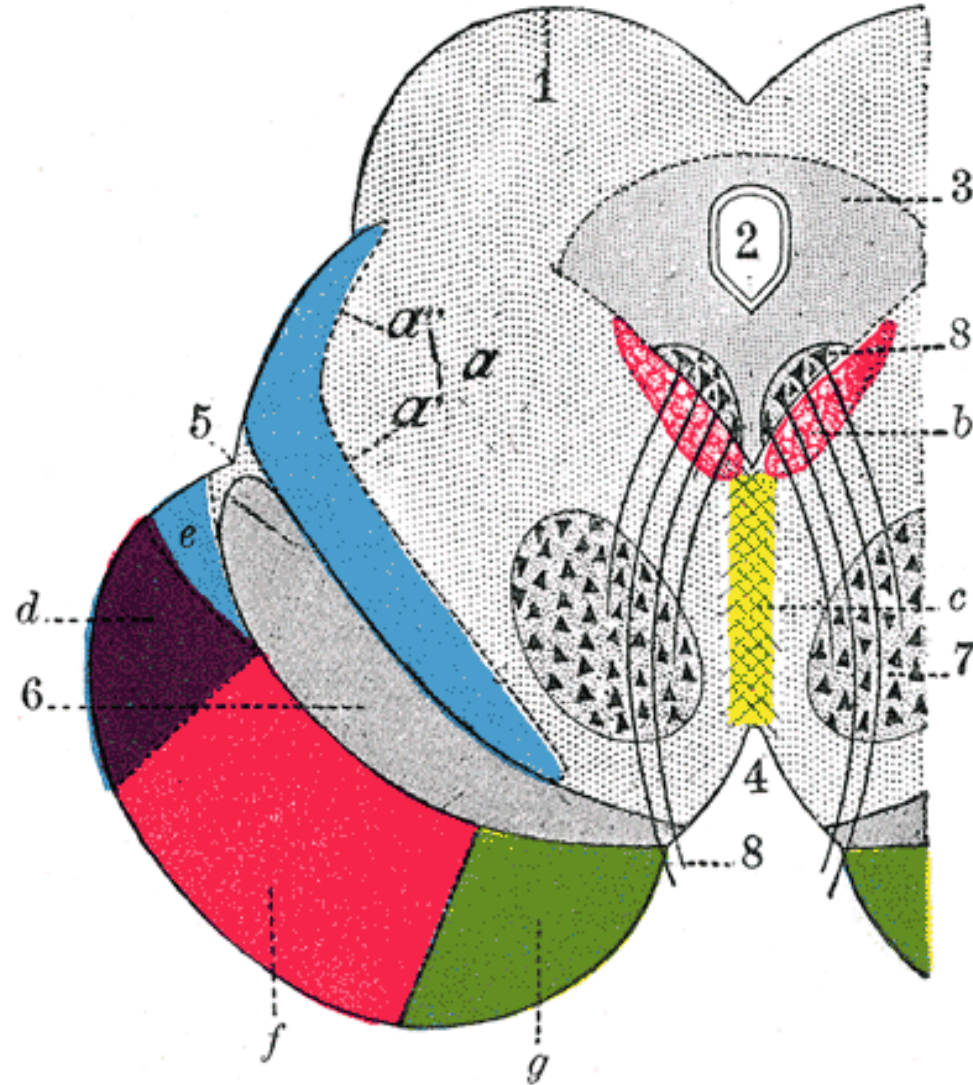
- medial – *gross motorics (trunk)*
 - tr. vestibulo-, tecto-, reticulospinalis (medial fibers)
- laterální – *fine motorics (limbs)*
 - tr. cortico-, rubrospinalis
- third – *involuntary emotional motorics (body speech, tremor, gamma loop)*
 - tr. raphe-, caeruleo-, spinalis, reticulospinalis (lateral fibers from medulla oblongata)

Projection → Descending and Ascending → Brainstem pathways:

- fasciculus longitudinalis medialis

- ncl. n.III, IV, VI, colliculus sup., ncl. interstitialis *Cajali* (*gaze center*), ncl. VII, nuclei vestibulares
- into cervical spinal cord
- decussated
- comprises: tr. tectospinalis, tr. vestibulospinalis medialis
- *function: coordinated eye, head and neck movements; optokinetic, vestibulo-ocular reflex, saccadic eye movements*

Projection → Descending and Ascending → Brainstem pathways:



Projection → Descending and Ascending → Brainstem pathways:

- fasciculus longitudinalis posterior *Schützi*
 - non-decussated tract from medial part of hypothalamus along midline
 - into parasympathetic nuclei of cranial nerves and sacral spinal cord, RF, sympathetic nuclei of thoracolumbar spinal cord
 - ascending: visceral information from RF into hypothalamus (+ gustatory and sensory information from ncll. tractus solitarii)
 - in mesencephalon passes through PAG
 - *function: bidirectional coordination of autonomic system*

Projection → Ascending → Sensory

OPTIC PATHWAY

4 - neuronal, partially decussated

1-order neuron: rod and cones of retina

2-order neuron: bipolar cells

3-order neurons: ganglionic cells → n. II → chiasma
opticum → corpus geniculatum laterale

4-order neuron: cells in corpus geniculatum laterale →
tractus geniculocorticalis (= radiatio optica
Gratioletti) → lobus occipitalis, area 17 (around
sulcus calcarinus)

- inferior (Flechsig-**Meyer**-Archimbault) loop – arches around cornu inferius ventriculi lateralis within temporal lobe – lower half of retina (upper 1/2 of visual field)
- superior (**Baum**) loop directly through parietal lobe – upper half of retina (lower 1/2 of visual field)

Projection → Ascending → Sensory

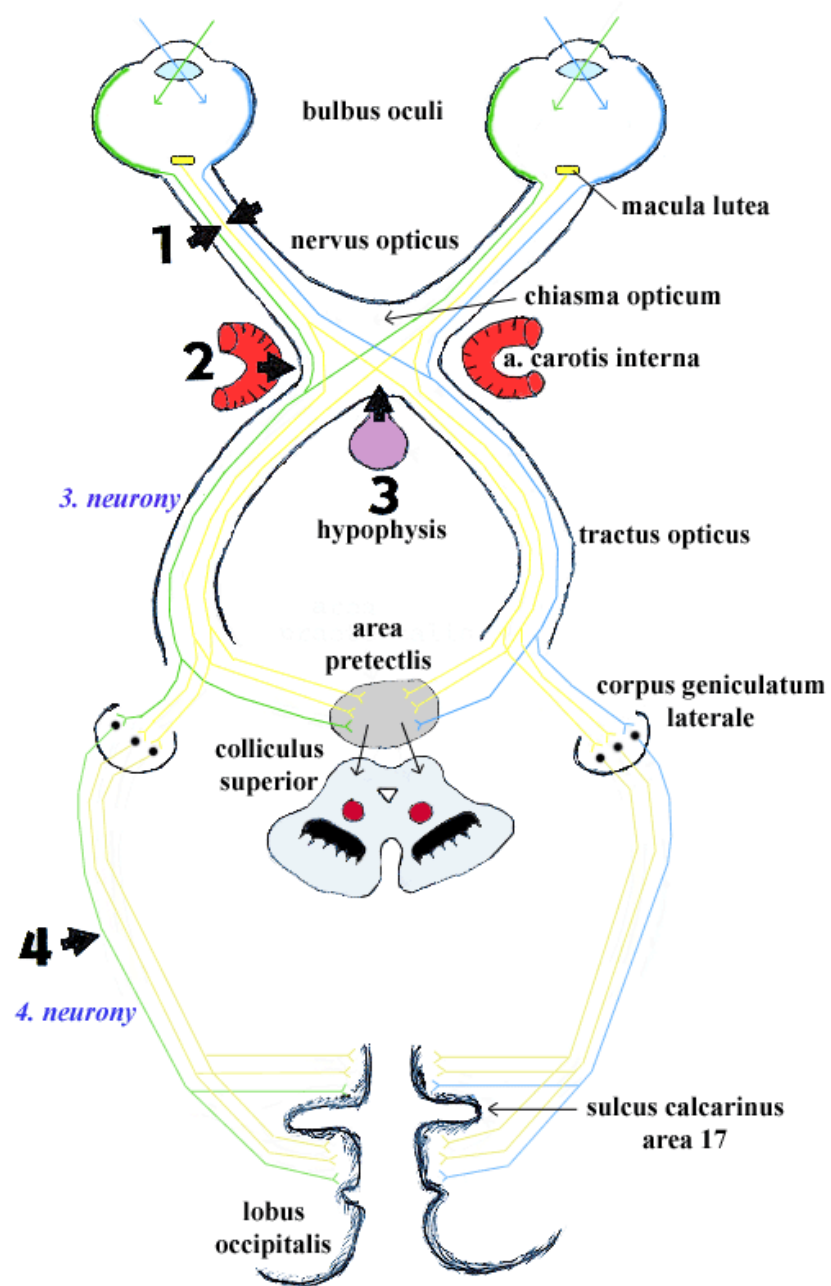
OPTIC PATHWAY – collaterals of 3-order neuron

- radix optica hypothalamica into **nucleus suprachiasmaticus** (nda paraventricularis) – visual stimuli to highest autonomic centers (food in visual field causes salivation)
- radix medialis (optica mesencephalica) into **area pretectalis** to ncl. pretectales (4.N) – pathway of pupillary reflex
 - for **miosis**: → 5.N: nucleus accessorius dorsalis n. III *Edinger-Westphal* → parasympathetic tract with n. III → 6.N: ganglion ciliare → nn. ciliares breves → m. ciliaris et m. sphincter pupillae (accomodation + miosis)

Projection → Ascending → Sensory

OPTIC PATHWAY – collaterals of 3-order neu

- for **mydriasis**: → 5.N: RF → tractus reticulospinalis → 6.N: centrum ciliospinale *Budge* (C8-T1) → r.com.albus → ggl. stellatum (no synapsing) → truncus sympathicus → 7.N: ganglion cervicale superius → n. et plexus caroticus internus → plexus ophthalmicus → ggl. ciliare (no synapsing) → nn. ciliares breves → m. dilatator pupillae (mydriasis)
- for **convergence**: 4.N: nucleus interstitialis *Cajali* → fasciculus longitudinalis medialis (both decussated and non-decussated) → 5.N nuclei of n. II, IV, VI bilaterally
- **tectal visual circuit** → tractus tectospinalis
 - coordination of eye, head and neck movements towards visual stimuli
 - coordination of these movements with movements of the whole body



- 1 - amaurosis (= slepota) levého oka
 2 - hemianopsia nasalis (porucha jen na levém oku)
 3 - hemianopsia heteronyma bitemporalis
 4 - hemianopsia homonyma dextra

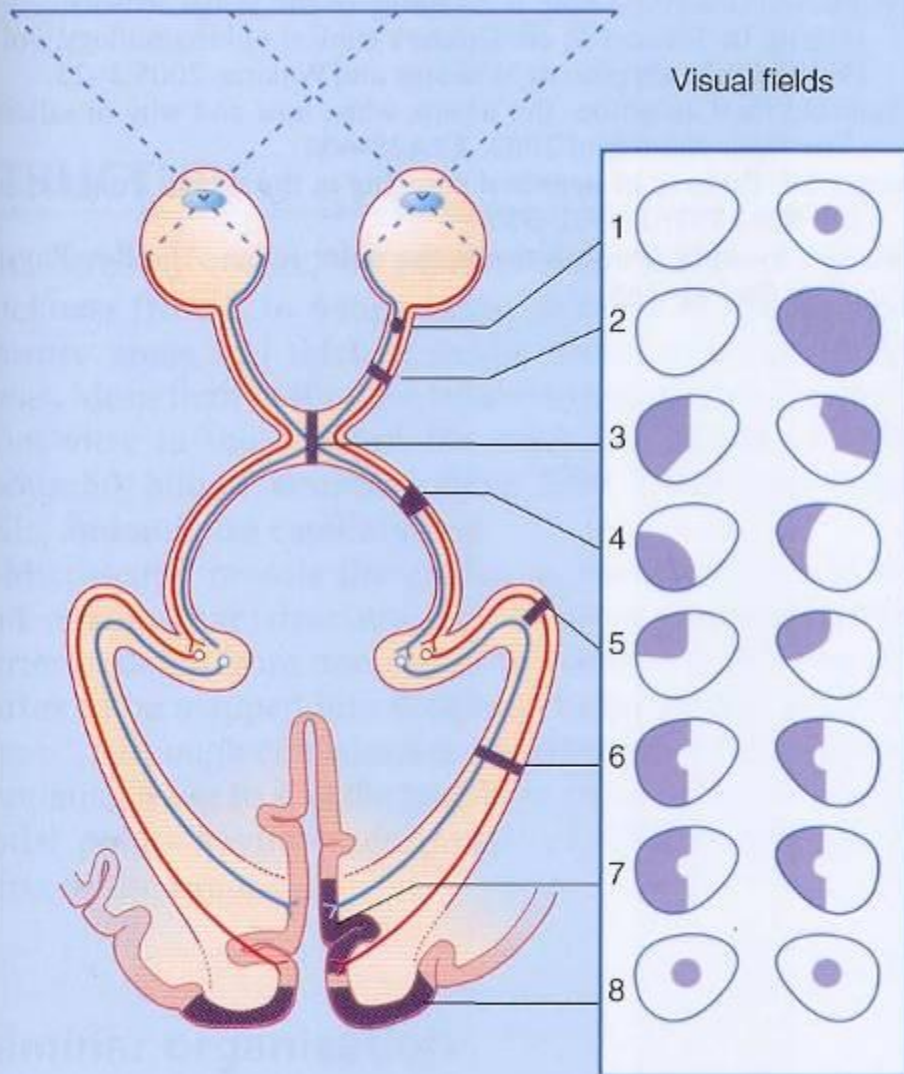
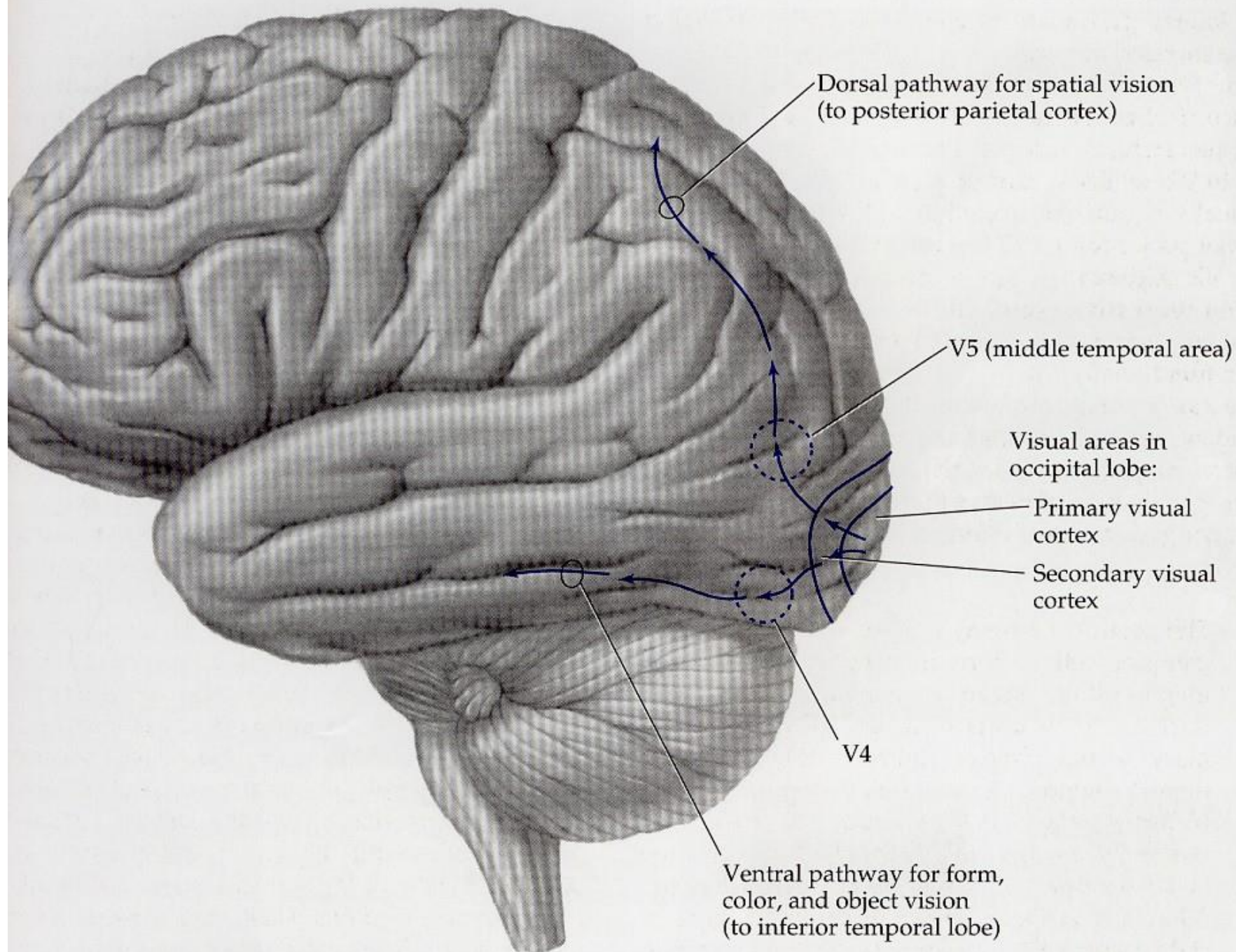


Table CP 28.1.1 Classification of dyphasia.

Number	Lesion	Field defect
1	Partial optic nerve	Ipsilateral*scotoma ^a
2	Complete optic nerve	Blindness in that eye
3	Optic chiasm	Bitemporal hemianopia
4	Optic tract	Homonymous ^b hemianopia
5	Meyer's loop	Homonymous upper quadrantanopia
6	Optic radiation	Homonymous hemianopia
7	Visual cortex	Homonymous hemianopia
8	Bilateral macular cortex	Bilateral central scotomas

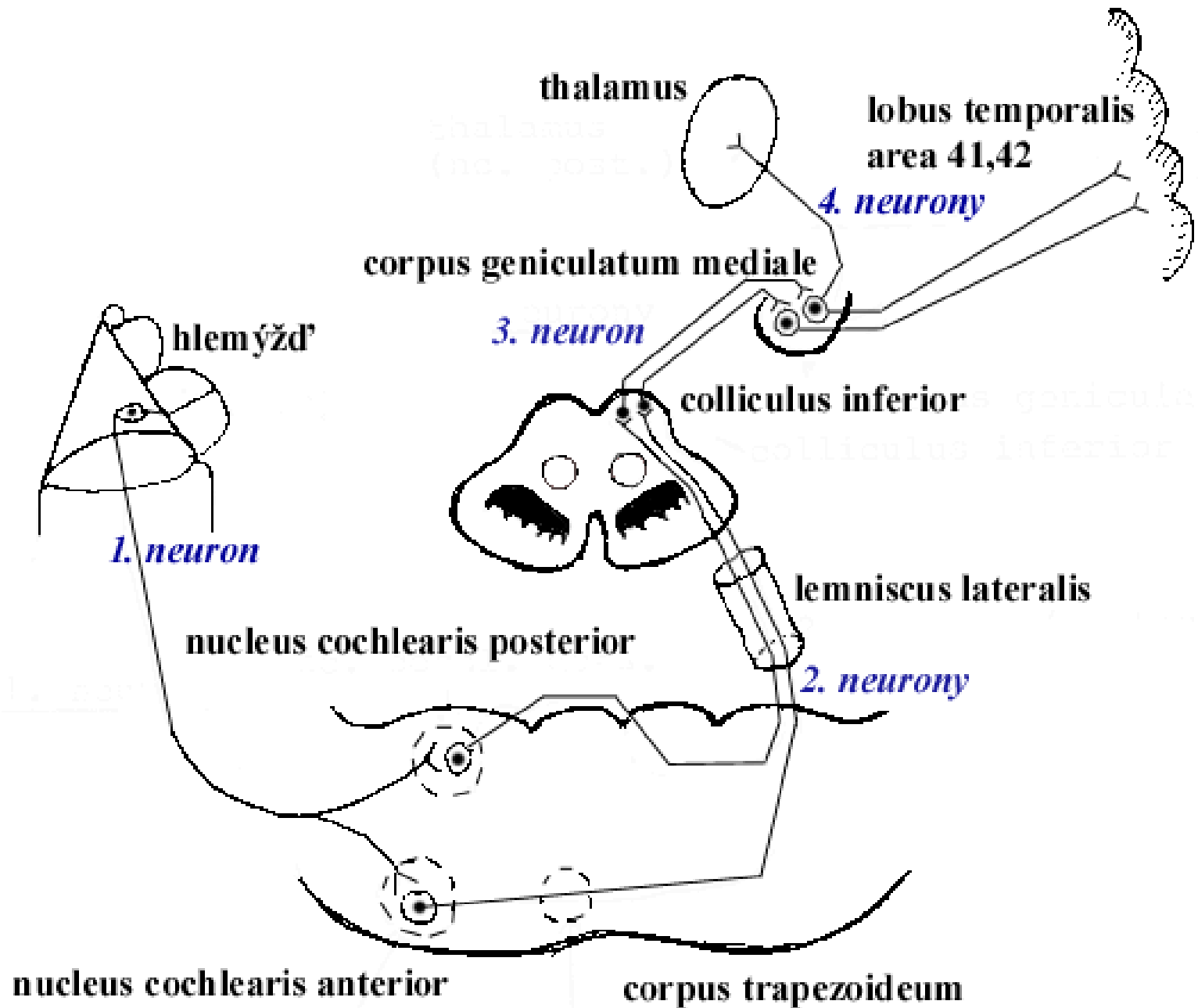


Projection → Ascending → Sensory

AUDITORY PATHWAY

4 - neuronal, decussated

1. neuron: bipolar cell of ganglion cochleare - n. cochlearis - n. VIII – splits to 2 parts to nuclei cochleares
2. neuron: cells in nucleus cochlearis posterior (pitch) et anterior (intensity) → lemniscus lateralis → colliculus inferior
 - nucleus olivaris superior (← kontralateral one is inhibited by corpus trapezoideum) → spatial orientation of sound
3. neuron: cells in colliculus inferior
4. neuron: cells in corpus geniculatum mediale → thalamus + lobus temporalis - gyrus temporalis transversus Heschli, area 41

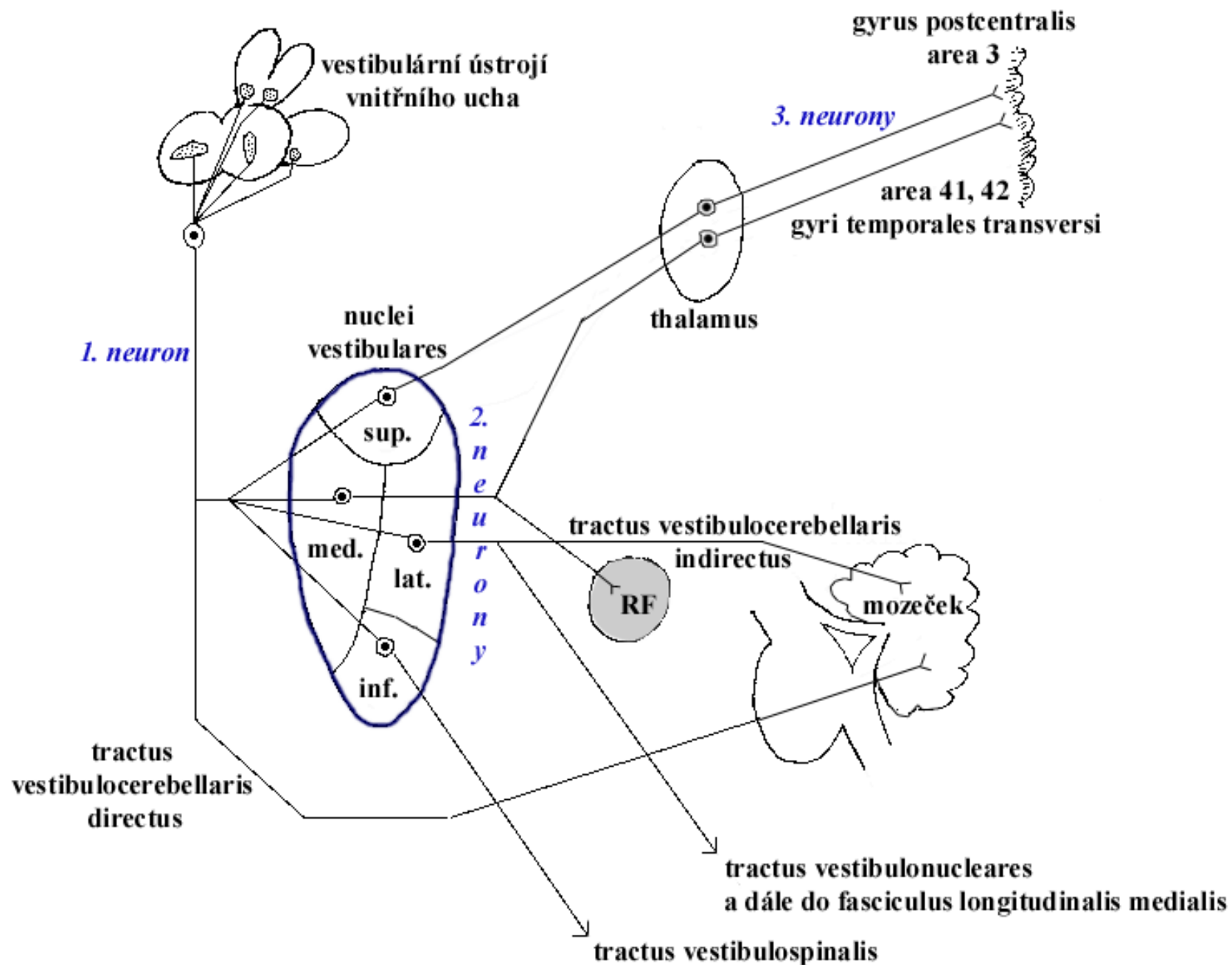


Projection → Ascending → Sensory

VESTIBULAR PATHWAY

3 - neuronal, decussated

- 1. neuron: bipolar cell of ganglion vestibulare → n. vestibularis → n. VIII (part of fibers goes as tractus vestibulocerebellaris directus without switch-over to cerebellum)**
- 2. neuron: cells of nuclei vestibulares pontis, their axons run to different structures (switched-over fibres as tractus vestibularis indirectus to cerebellum, to spinal cord, nuclei of cranial nerves, to fasciculus longitudinalis medialis, reticular formation and to thalamus)**
- 3. neuron: cells of nuclei ventrales thalami → cortex (lobus temporalis, area 41 = gyrus temporalis transversus /Heschl/, lobus parietalis - area 3, gyrus postcentralis)**

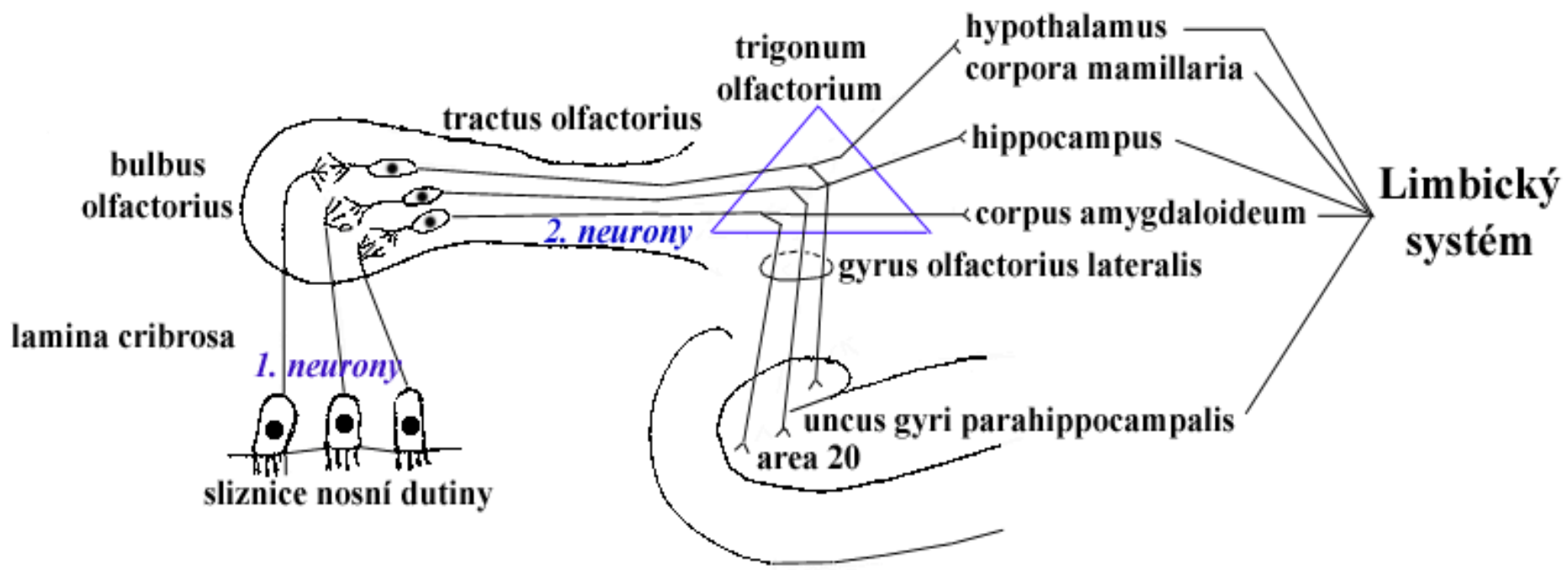


Projection → Ascending → Sensory

OLFACTORY PATHWAY

2 – neuronal, not decussated

1. neuron: neuroepithelial cells in pars olfactoria cavitatis nasi → fila olfactoria crossing through lamina cribrosa ossis etmoidalis into cranial cavity
2. neuron: mitral cells of bulbus olfactorius → tractus olfactorius → trigonum olfactorium → gyri olfactorii med. et lat. (= former stria) → **limbic system** (lobus temporalis - uncus gyri parahippocampalis, area entorhinalis /28/, corpus amygdaloideum, hypothalamus, corpora mamillaria)



Projection → Ascending → Sensory

GUSTATORY PATHWAY

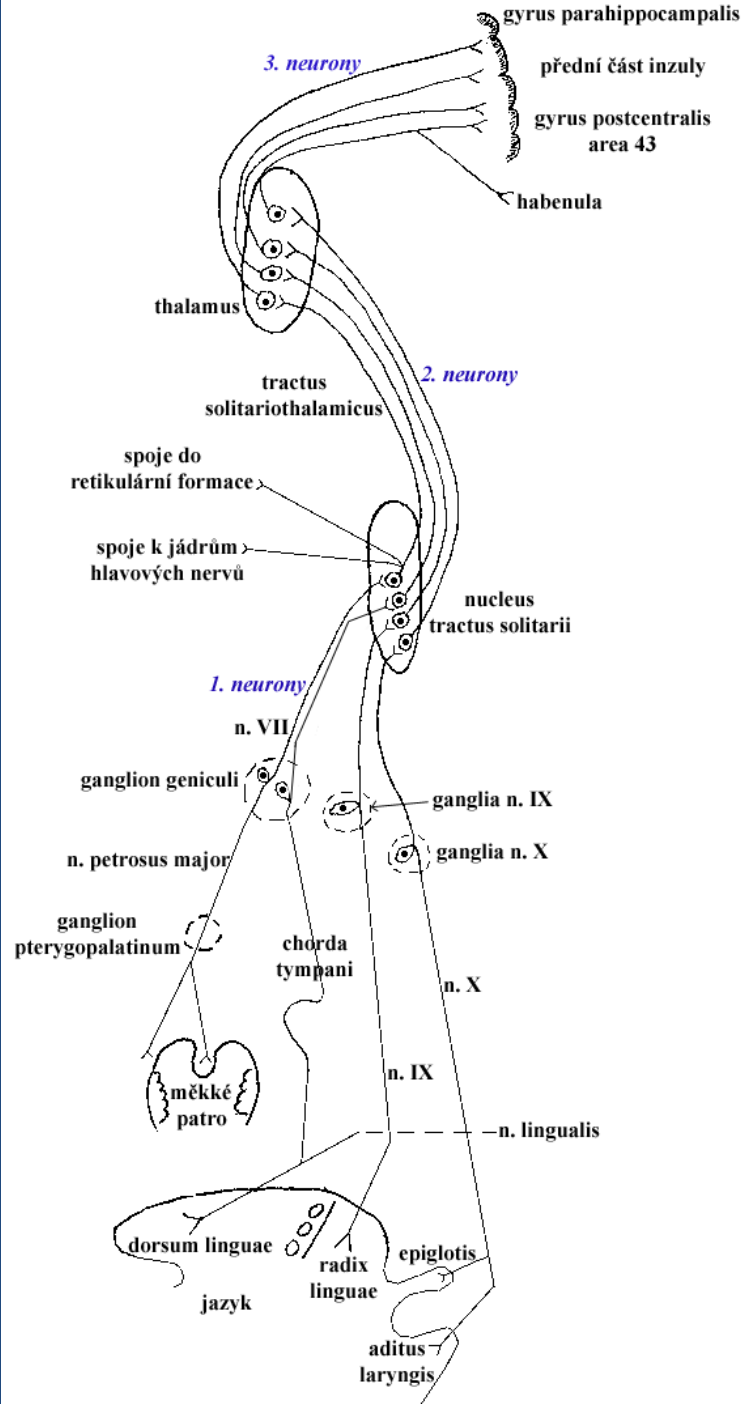
3 – neuronal, decussated and non-decussated

1. neuron:

- Soft palate → nn. palatini minores → ganglion pterygopalatinum (! without interpolation !) → n. petrosus major → ganglion geniculi → n. intermedius → nucleus tractus solitarii
- anterior 2/3 of tongue (= dorsum linguae) → n. lingualis → chorda tympani → n. intermedius → nucleus tractus solitarii
- dorsal 1/3 of tongue (= radix linguae) → n. IX → ganglion inf. et sup. n. IX → nucleus tractus solitarii
- epiglottis, aditus laryngis → n. X → ganglion inf. et sup. n. X. → nucleus tractus solitarii

2. neuron: nucleus tractus solitarii → thalamus (nucleus ventralis posteromedialis), to motoric nuclei of cranial nerves, to reticular formation

3. neuron: thalamus → cortex /lobus parietalis - area 43, gyrus postcentralis/ a rostral part of insula, to gyrus parahippocampalis and habenulae



Projection → Ascending → Cerebellar
proprioception

- **TRACTUS SPINOCEREBELLARIS POSTERIOR**

ncl. thoracicus post. *Stilling-Clarke* → medulla oblongata → pedunculus cer. inf. → vermis + paravermal cortex (*ipsilaterální*) – **proprioception from trunk and UE**

- **Tractus cuneocerebellaris**

dorsal fascicles tract → nucleus cuneatus accessorius *Clarke-Monakow* - **proprioception from thorax and LE**

Projection → Ascending → Cerebellar
information on spinal reflex arches

- TRACTUS SPINOCEREBELLARIS ANTERIOR

ncl. thoracicus post. *Stilling-Clarke* → decussation at spinal level →
mesencephalon → pedunculus cerebellaris superior →
decussation in cerebellar cortex → vermis + paravermal cortex
(*ipsilateral*) - **LE**

- TRACTUS SPINOCEREBELLARIS ROSTRALIS

ncl. thoracicus post. *Stilling-Clarke* → → pedunculus cerebellaris
inferior → vermis + paravermal cortex (*ipsilateral*) – **UE**

tractus spinoolivaris

- motoric learning
- *climbing the stairs, which are steep*

Projection → Descending → Cerebellar

- TRACTUS CORTICOPONTOCEREBELLARIS

Lobus f,p,o,t → capsula interna → ncl. pontis → fibrae pontis transversae → decussation → pedunculus cer. medius → cortex (*kontralat.*)

- TRACTUS CORTICO-OLIVOCEREBELLARIS

Lobus f,p,o,t → capsula interna → complexus olivaris inf. (*bilat.*) → decussation → pedunculus cer. inferior → cerebellar cortex

- TRACTUS CORTICORETICULOCEREBELLARIS

Lobus f,p,o,t (mainly sensorimotor cortex) → capsula interna → RF (*bilat.*) → decussation → pedunculus cer. medius + inf. → cerebellar cortex

Voluntary motorics, movements planning, setting of proper muscle tonus

Projection → Ascending → Cerebellar

- Tractus vestibulocerebellaris directus

vestibulum → corpus juxtarestiforme (v PCI) →
nodulus + uvula (*ipsilat.*)

- Tractus vestibulocerebellaris indirectus

vestibulum → ncl. vestibulares → corpus
juxtarestiforme (v PCI) → lobulus FN+ vermis
(*bilat.*)

- Tractus trigeminocerebellaris

Projection → Cerebellar → *Eferent*

Ncl. fastigii

→ PCI → RF (*bilat.*) → tr. reticulospinalis

→ ncl. vestibularis lat. *Deitersi* (*bilat.*) → tr. vestibulospinalis

Ncll. interpositi (globosus + emboliformis)

→ PCS → decussation → ncl. ruber → tractus rubrospinalis → decussation → mícha (*ipsilat.*)

Ncl. dentatus

→ PCS → decussation → ncl. VA+VL thalami → area 4 → tr. pyramidalis → decussation → mícha (*ipsilat.*)

PAIN TRACTS - *ascending*

- Anterolateral system
 - **tr. spinothalamicus ant. + lat.** (= *neospinothalamicus*) - *quick*
 - **tr. spinoreticulothalamicus** (= *paleospinothalamicus*) – *slow*
 - Tr. spinoparabrachialis (= *tr. spinomesencephalicus*) – *affective-emotional component*
- (Tractus spinobulbothalamicus = dorsal fascicles tract)
- (Tractus spinocervicalis)
- (Tractus spinotectalis)
- (Tractus spinothalamicus secundarius)

Somatic, quick pain

- weakly myelinated fibres A δ (7-14 m/s)
 - somatic (lateral) afferentation
- ➔ nociceptive-specific neurons in ncl. apicalis = Rexed's zone I,II (V)
- ➔ decussation at spinal level
- ➔ tractus spinothalamicus ant. + lat. (= „neospinothalamic tract“ (glutamate))
- ➔ ventrobasal complex of thalamus (ncl. VPL + VPM *face*)
- ➔ somatosensory cortex (area 3,1,2 = gyrus postcentralis)

Visceral, slow pain

- nemyelinated fibres C (0.5-3 m/s)
 - visceral (medial) afferentation
- multireceptive neurons in ncl. proprius columnae post. = Rexed's zones III-V (VIII,X)
- ➔ tractus spinoreticularis (= „paleospinothalamic tract“) ➔ RF
- ➔ ncl. intralaminares thalami (ncl. centri mediani, centralis lateralis, parafascicularis)
- ➔ prefrontal areas (area 6,9) + gyrus cinguli, insula – *awaiting of pain*

Affective-emotional component of pain

→ tractus spinoparabrachialis

→ ncll. parabrachiales

→ tractus longitudinalis posterior → hypothalamus

→ limbic system (*emotion and motivation centres*)

→ corpus amygdaloideum

PAIN TRACTS - *descending*

substantia grisea centralis mesencephali = PAG

enkefalins



ncl. raphes (ncl. raphe magnus, dorsalis) medullae
oblongatae

serotonine



dorsolateral spinal fascicles



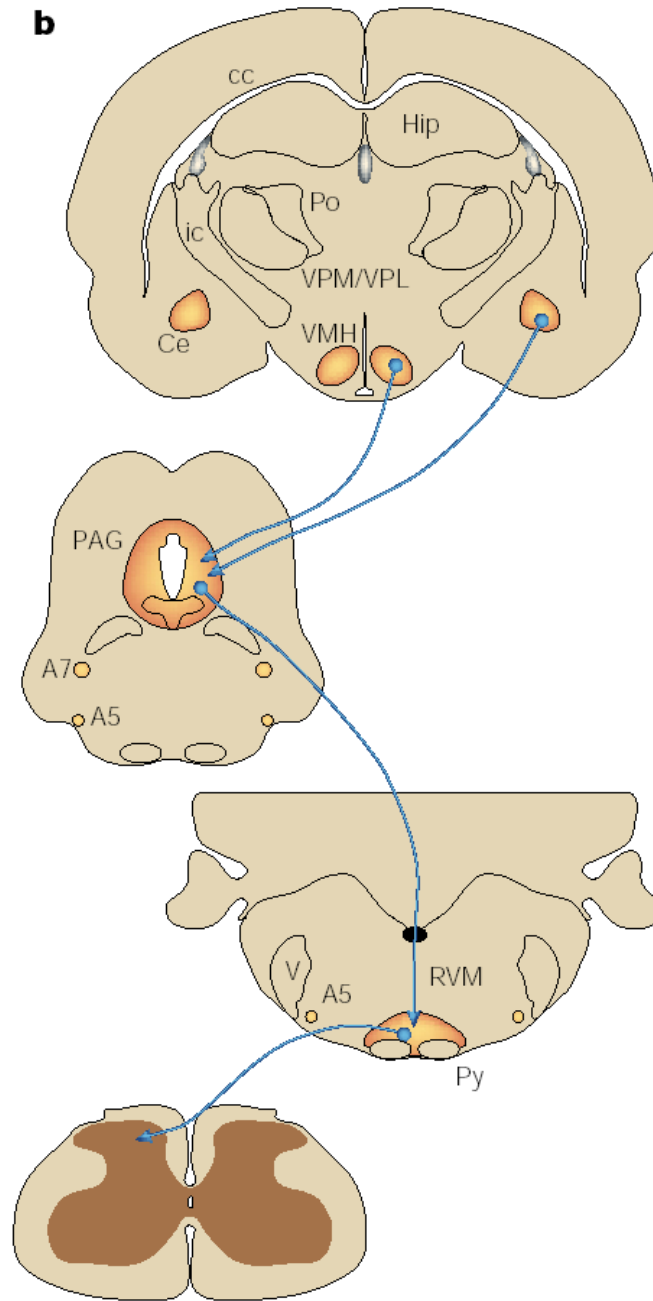
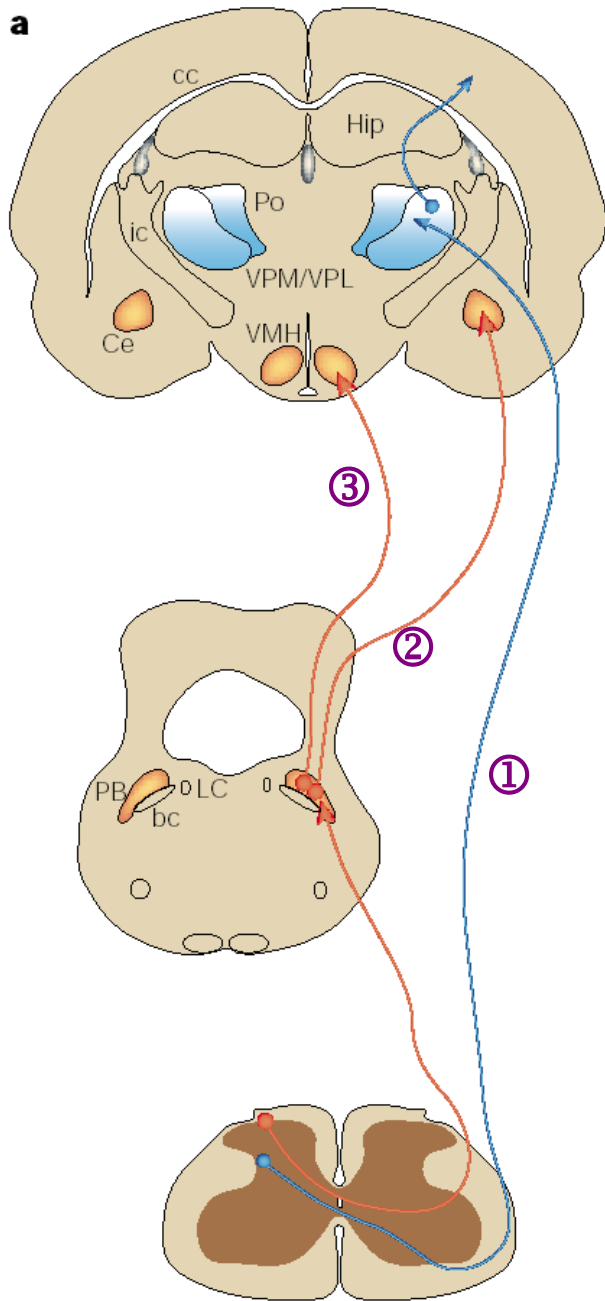
Rexed II – presynaptic inhibition

block of Ca²⁺ canals → block of substance P

subnucleus caudalis ncl. spinalis n. V

Ascending and descending pain tracts

- ① Spinothalamic
- ② Spino-parabrachio-amygdalar
- ③ Spino-parabrachio-hypothalamic

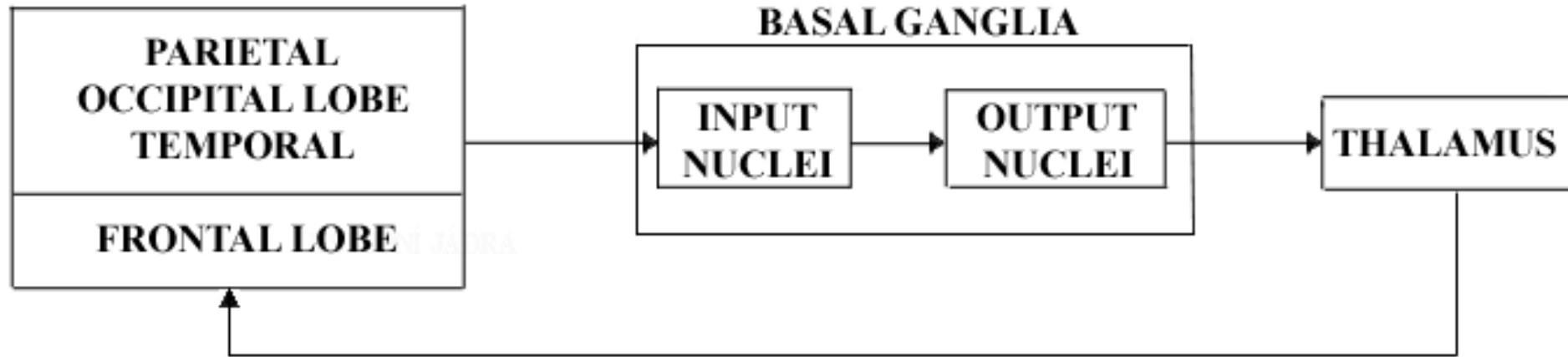


Circuits

Cerebellum – Main circuits

- cerebral cortex → pons / olive / RF (olive) – ncl. pontis / complexus olivaris inferior → *decussation* → ncl. dentatus → *decussation* → thalamus (ncl. VL) → cerebral cortex
- Papez's cerebellar control circuit
ncl. dentatus → ncl. ruber (pars parvocellularis) → olive → ncl dentatus
- cerebral cortex – cerebellum: **always contralateral**
- cerebellum – body/spinal cord: **always ipsilateral**

Basic functional telencephalic connections



Input nuclei

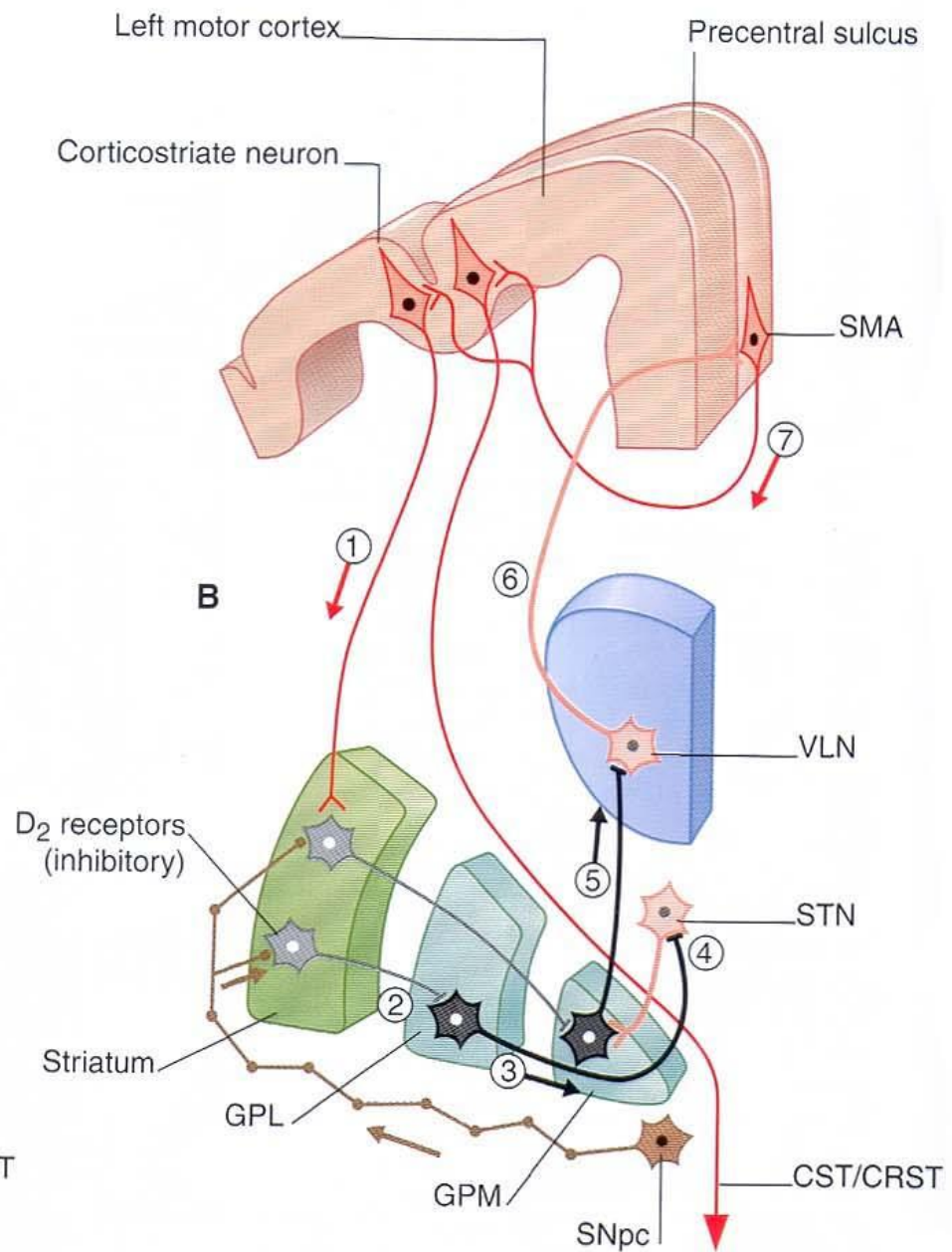
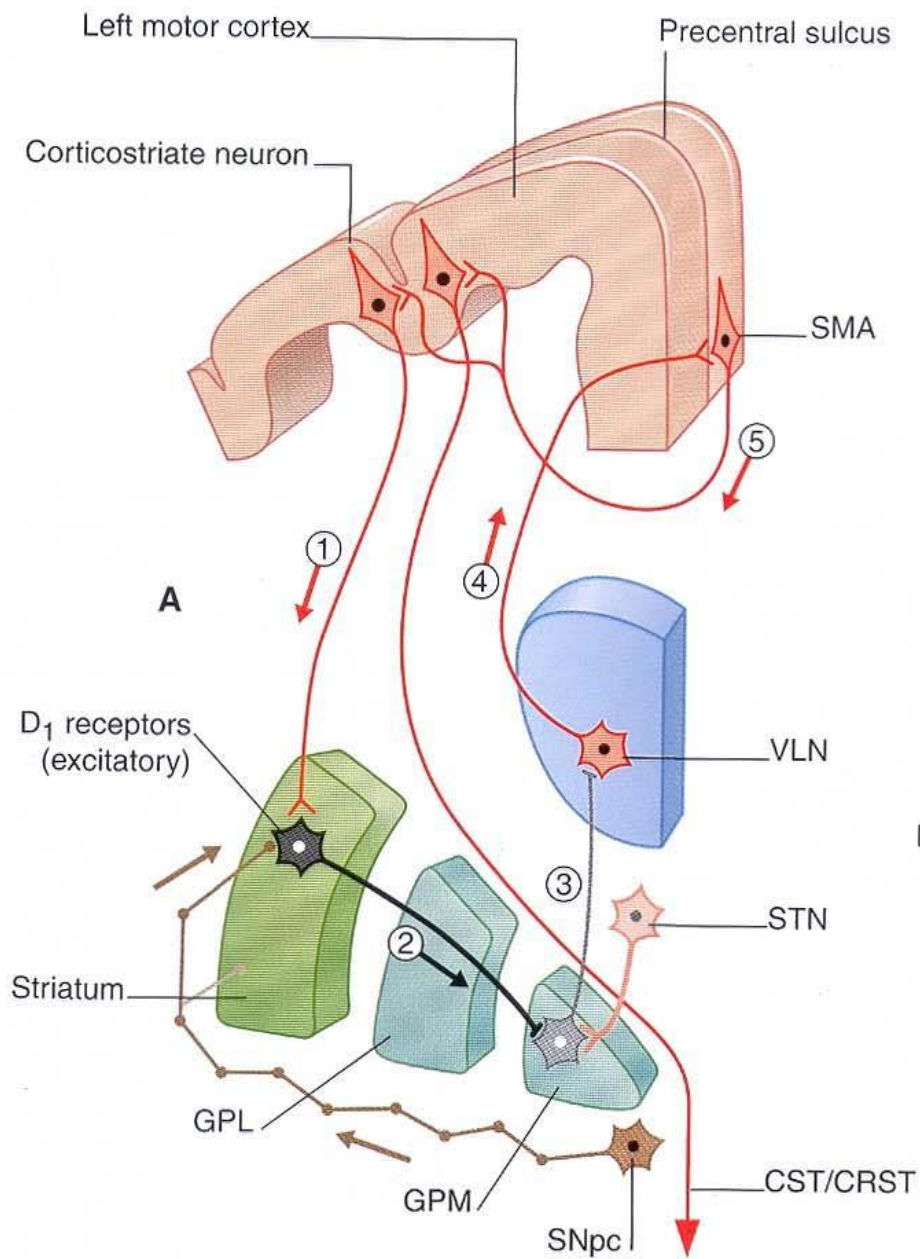
- nucleus caudatus
- putamen
- nucleus accumbens

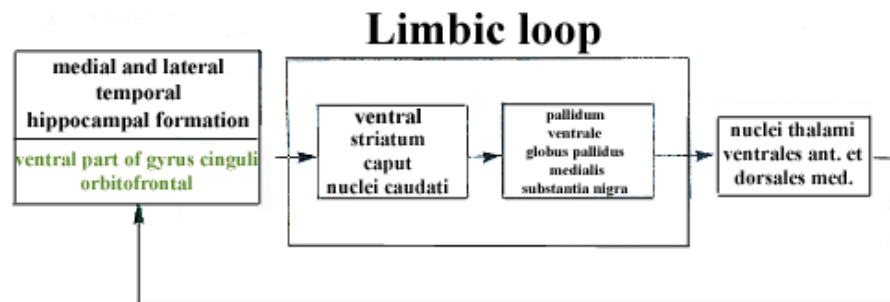
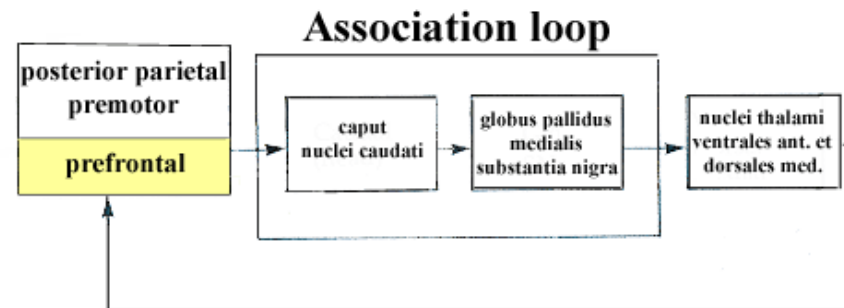
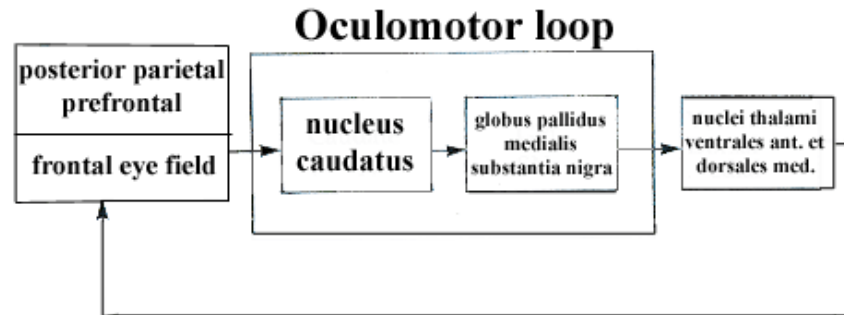
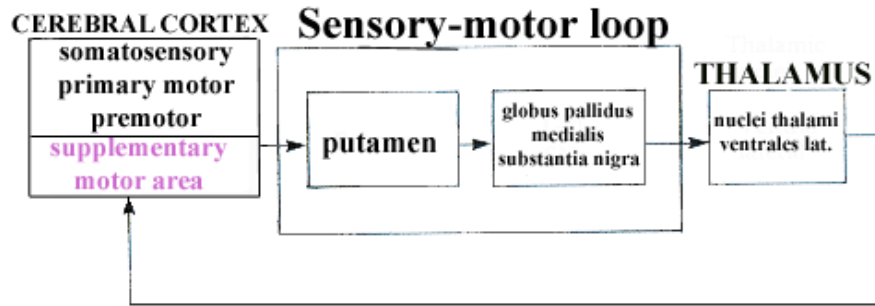
Output nuclei

- pars reticularis substantiae nigrae
- globus pallidus medialis
- pallidum ventrale

Intrinsic nuclei

- globus pallidus lateralis
- nucleus subthalamicus
- pars compacta substantiae nigrae
- area tegmentalis ventralis (ncl. subbrachialis)





Circuits of limbic system

Papez's limbic subcortical circuit (*John Papez 1937*)

- hippocampal formation → fornix → corpora mamillaria → fasciculus mamillothalamicus → ncll. anteriores thalami → area cingularis posterior → hippocampus + area entorhinalis
- *recent, short version skips hypothalamus*