

Practical Molecular Pathology I: Colon cancer

Wade S. Samowitz, M.D.
University of Utah and ARUP

Disclosure

- Dr. Samowitz has received royalties related to the Ventana BRAF V600E antibody.

Topics

- Brief background on Lynch syndrome
- Mistakes in Lynch syndrome work-up
- Therapy based upon mismatch repair deficiency
- EGFR pathway
- Mistakes in molecular testing of EGFR pathway
- The future

Lynch syndrome (HNPCC)

- Early onset colon cancer
- Right-sided
- Extra-colonic cancers: **endometrium**, ovary, renal pelvis, ureter, small intestine, stomach, hepatobiliary tract, pancreas
- Muir-Torre: Lynch + sebaceous neoplasms
- Turcot's: Lynch + brain tumor (GBM)
(Hamilton, NEJM, 1995)

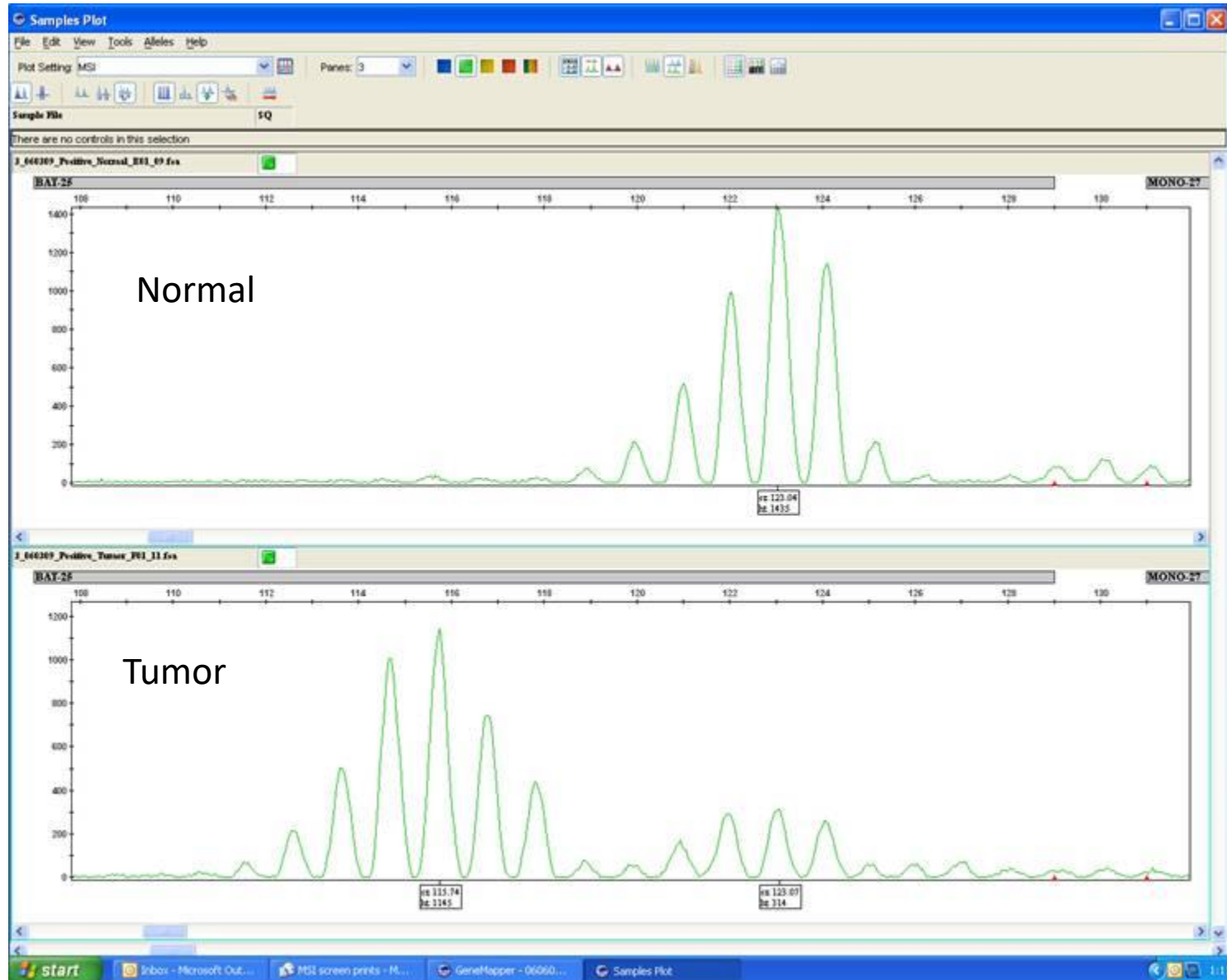Lynch syndrome

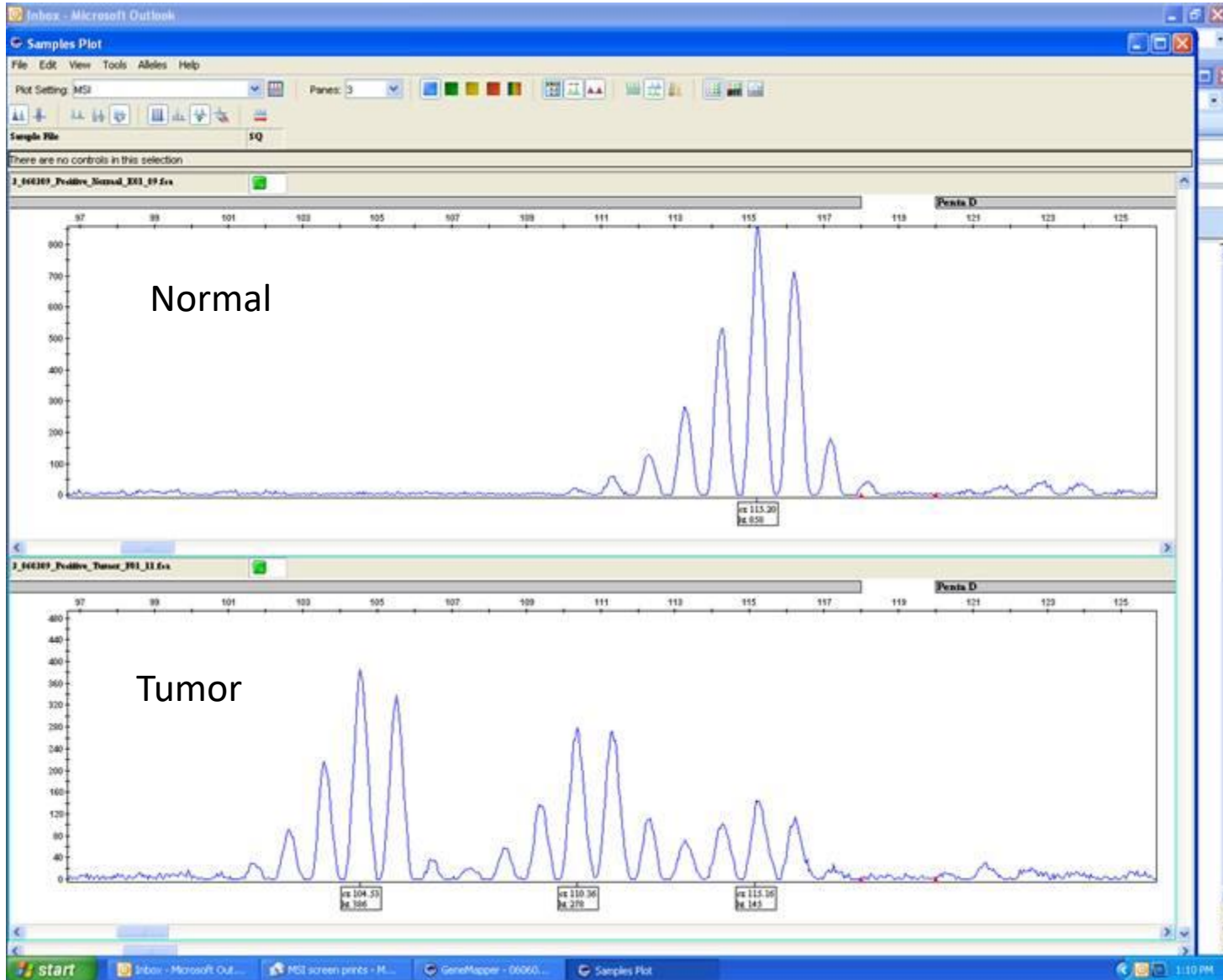- Germline mutations in mismatch repair genes: *MLH1*, *MSH2*, *MSH6* or *PMS2* (and *EPCAM*)
- Autosomal dominant
- Phenotype not so obvious (unlike FAP, for example)
- Family history not always obvious or available
- Fortunately, we can use the molecular features of the tumor (mismatch repair deficiency) to help in work-up

How do we work up Lynch syndrome?

- Determine if tumor is mismatch repair deficient
 - PCR for microsatellite instability
 - IHC for mismatch repair proteins
- Determine if mismatch repair deficient tumor is
 - sporadic: don't go on to germline testing
 - possibly inherited: go on to germline testing

PCR for Microsatellite Instability

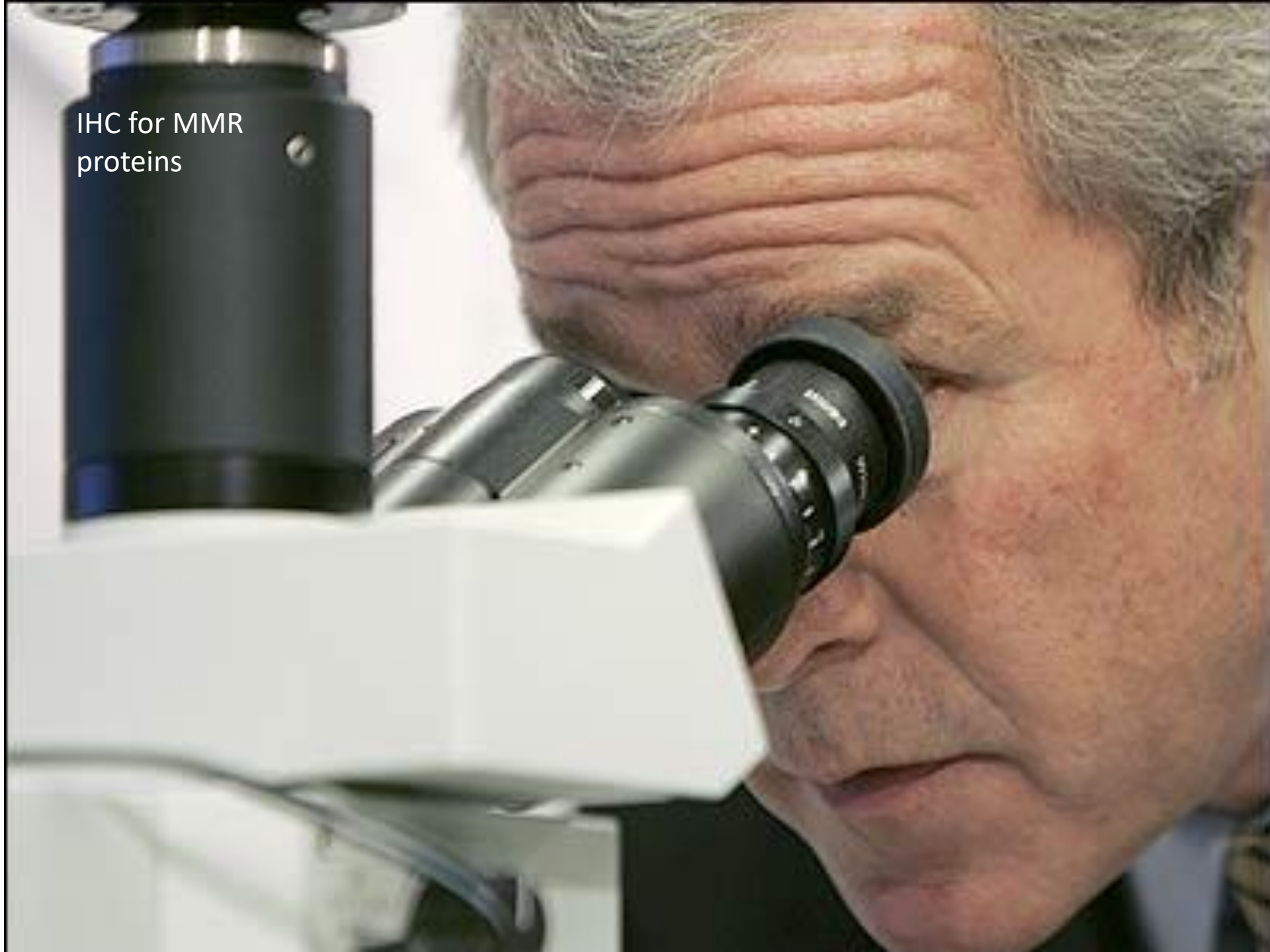




Mononucleotide repeat panel

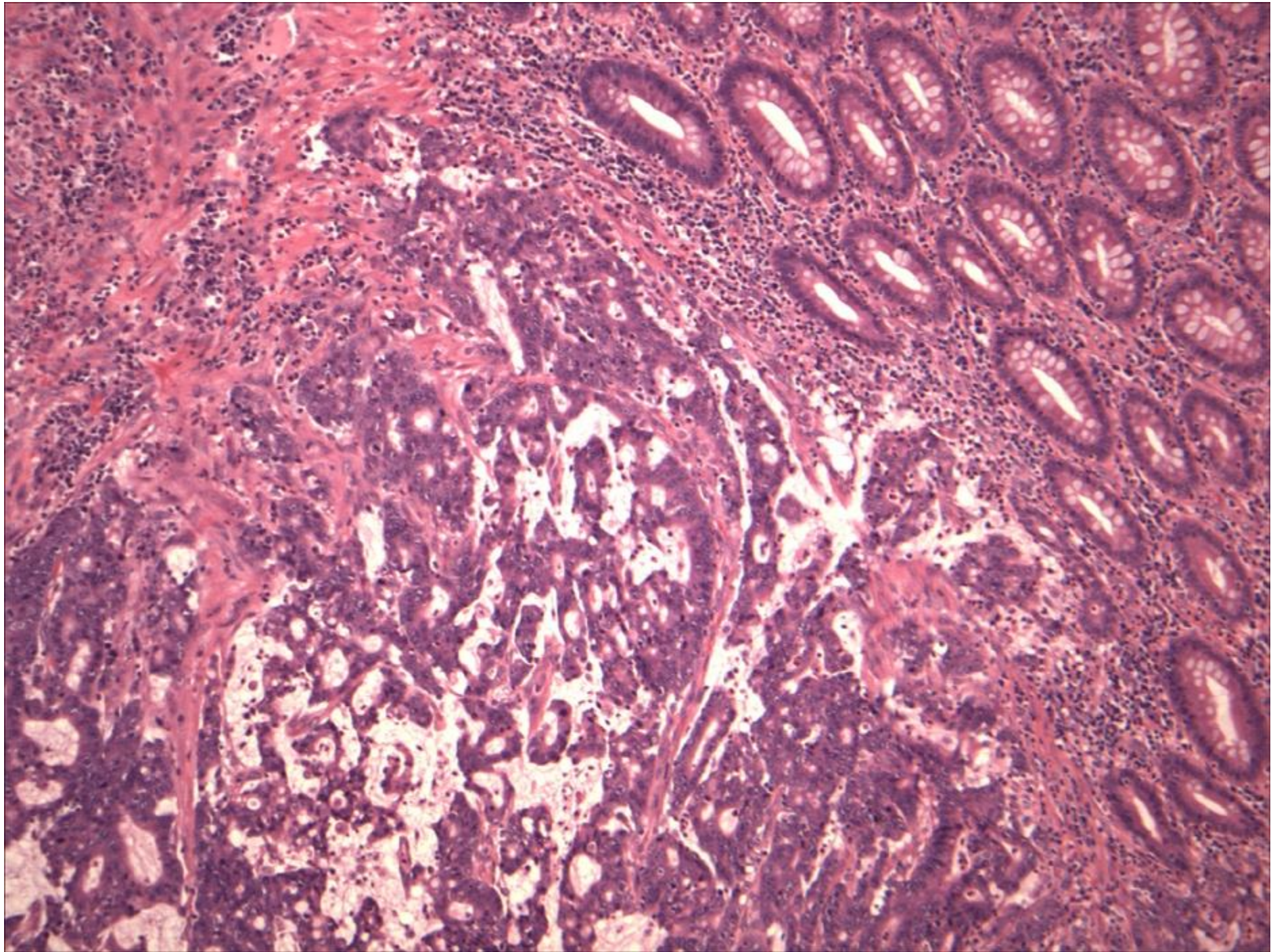
- Mononucleotide repeats are probably more sensitive and specific for MMR deficiency
- New panel(s) of 5 mononucleotide repeats
 - MSI high: two or more unstable, although typically all (or almost all) repeats are unstable
 - Since instability in even one mononucleotide repeat may indicate MMR deficiency, instability in one repeat is termed “indeterminate” rather than MSI low

IHC for MMR
proteins

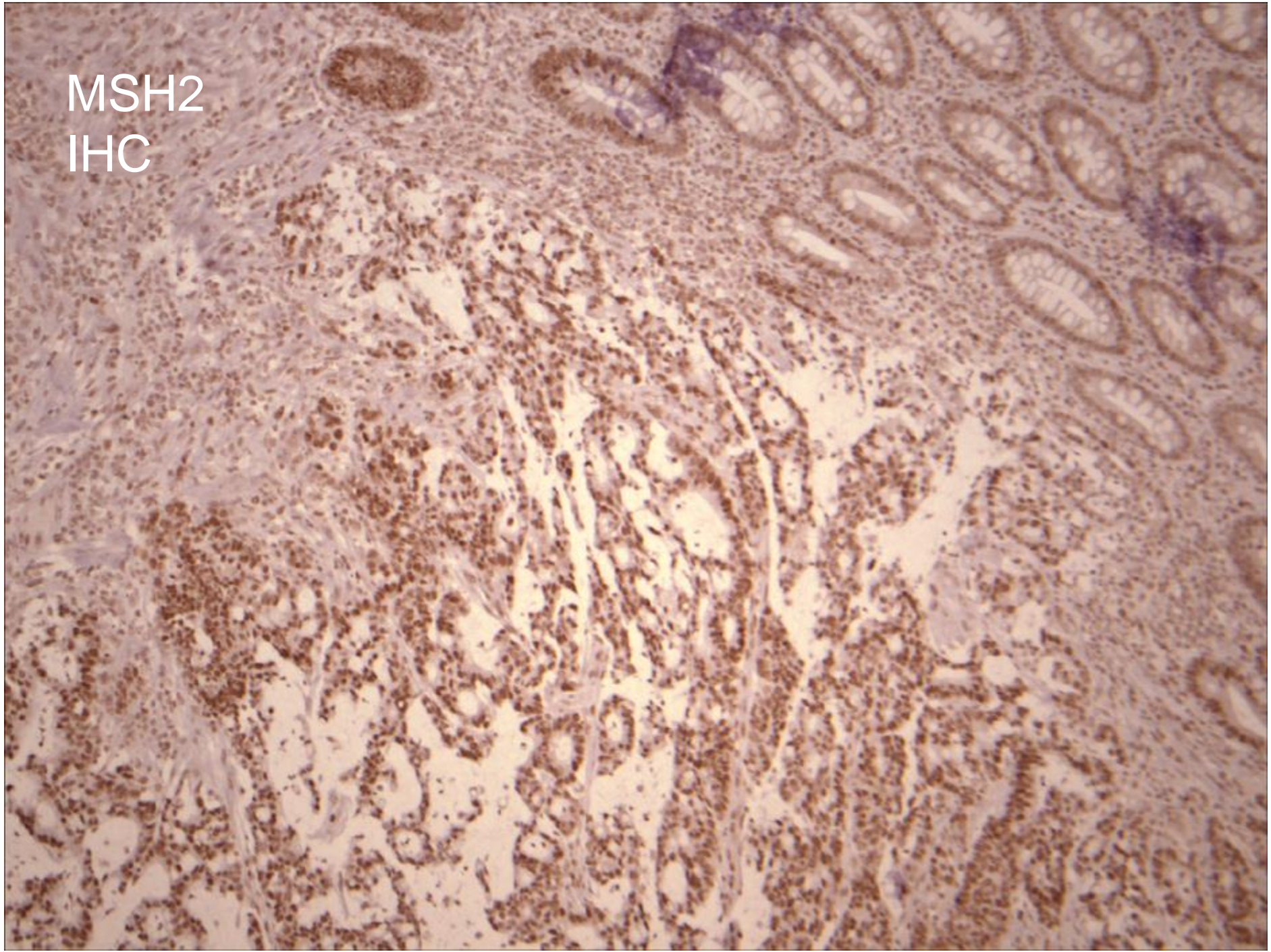




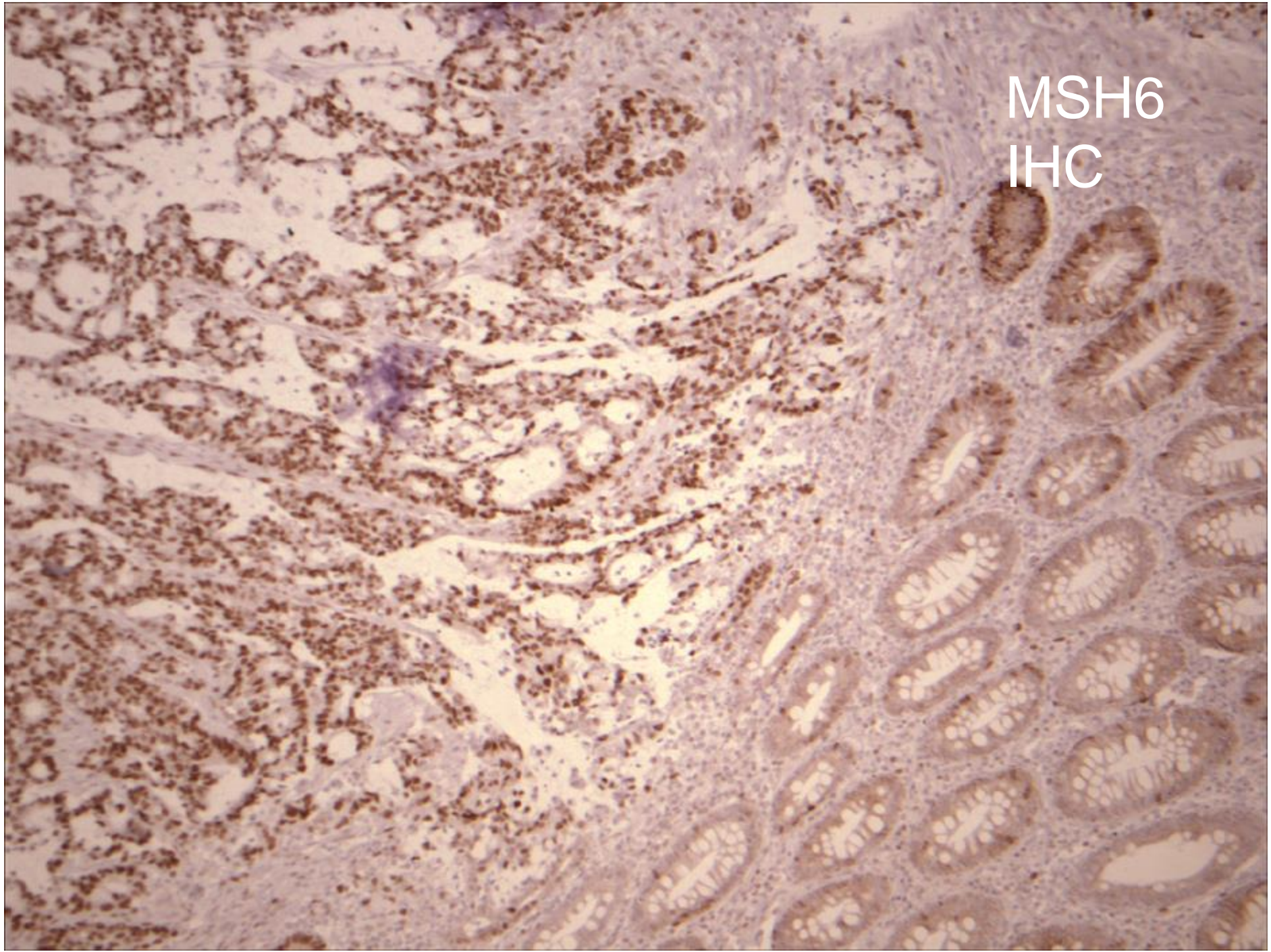




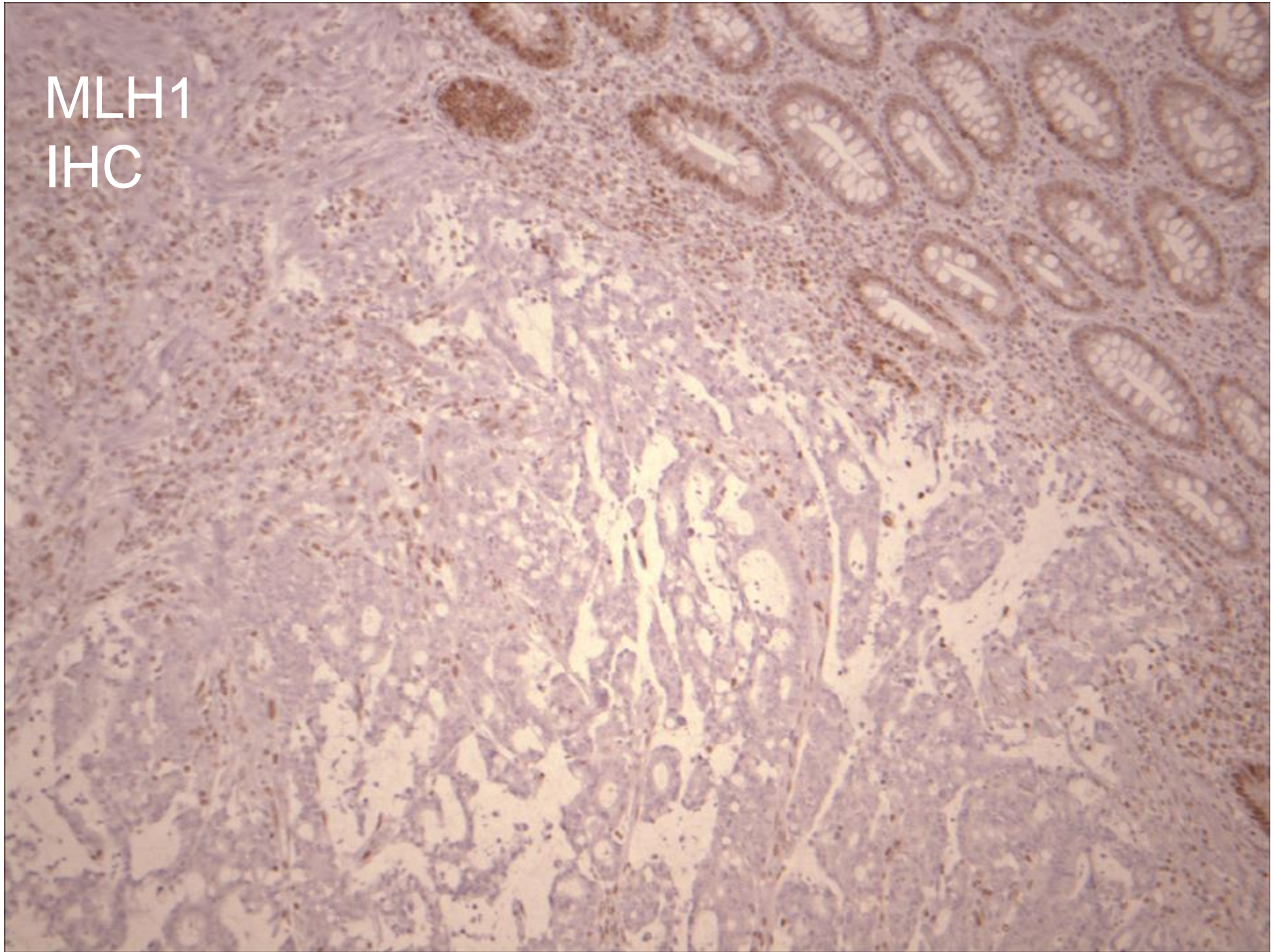
MSH2
IHC



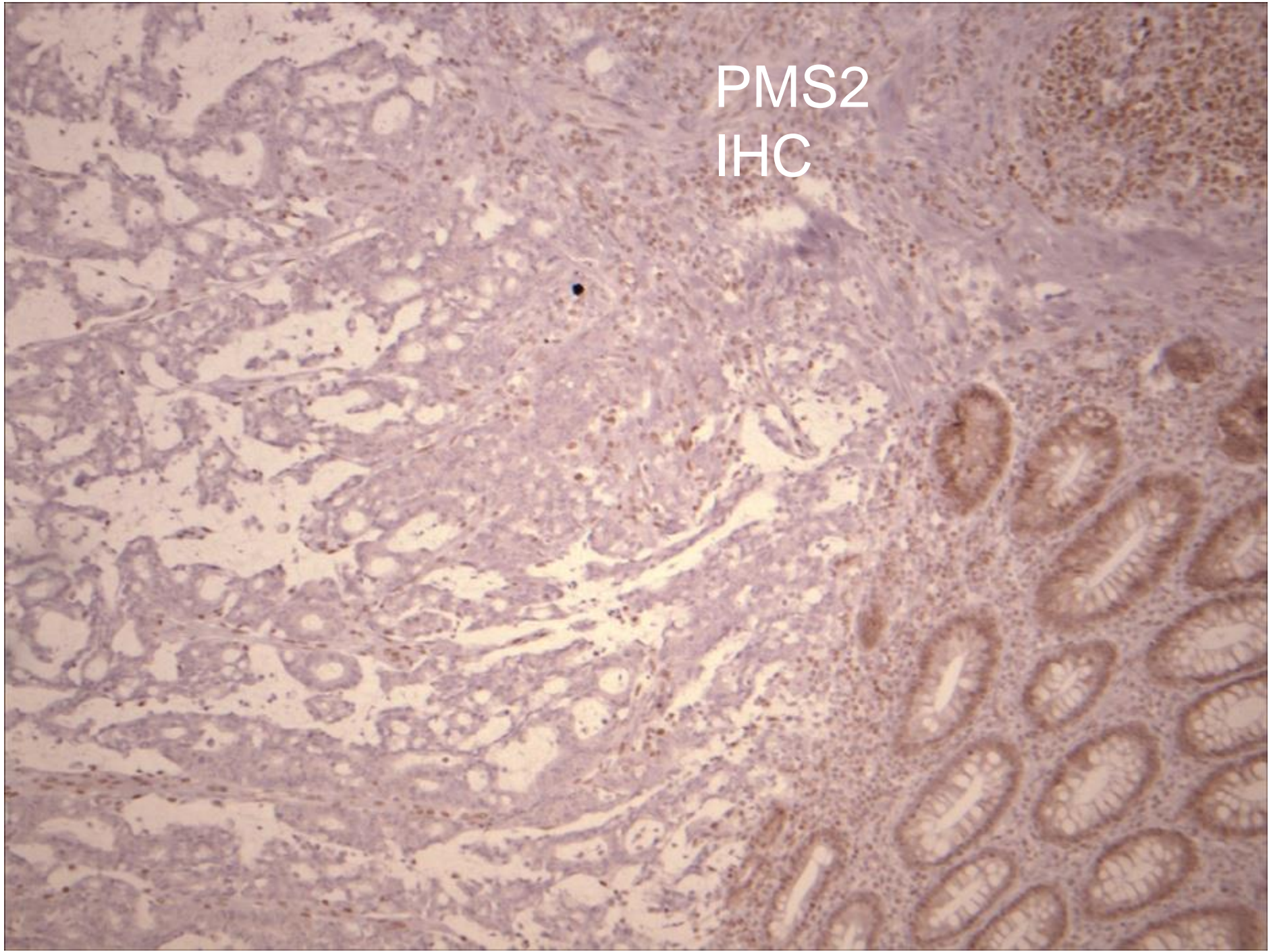
MSH6
IHC



MLH1
IHC



PMS2
IHC



How do we interpret IHC stains?

- Two complexes: MLH1/PMS2 and MSH2/MSH6
- Stability of PMS2 and MSH6 depends upon these complexes
- Therefore, loss of staining of MLH1 leads to loss of staining of PMS2
- Loss of staining of MSH2 leads to loss of staining of MSH6
- MLH1 and MSH2 are stable without complex; therefore, can have isolated MSH6 or PMS2 loss

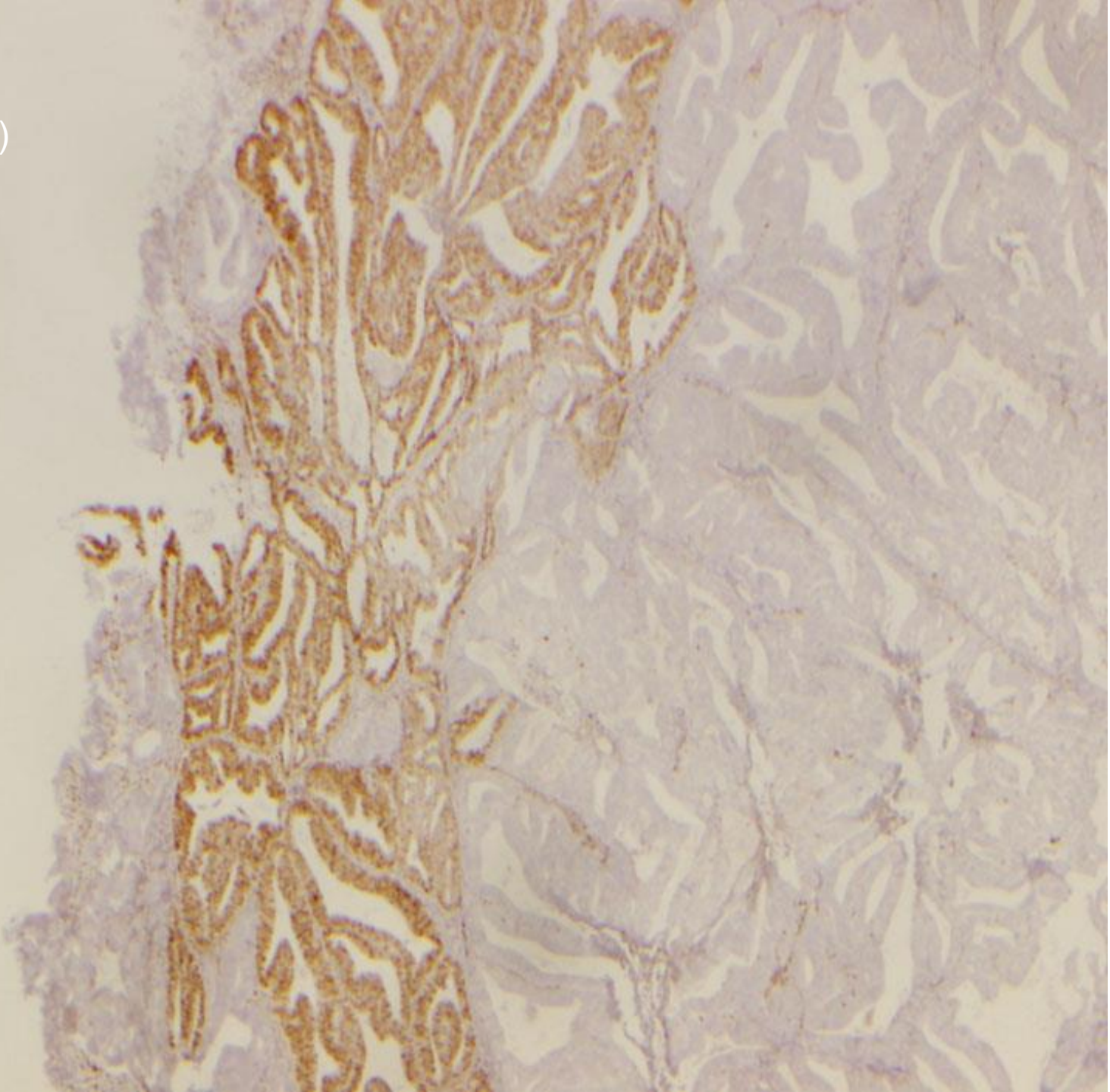
IHC interpretation

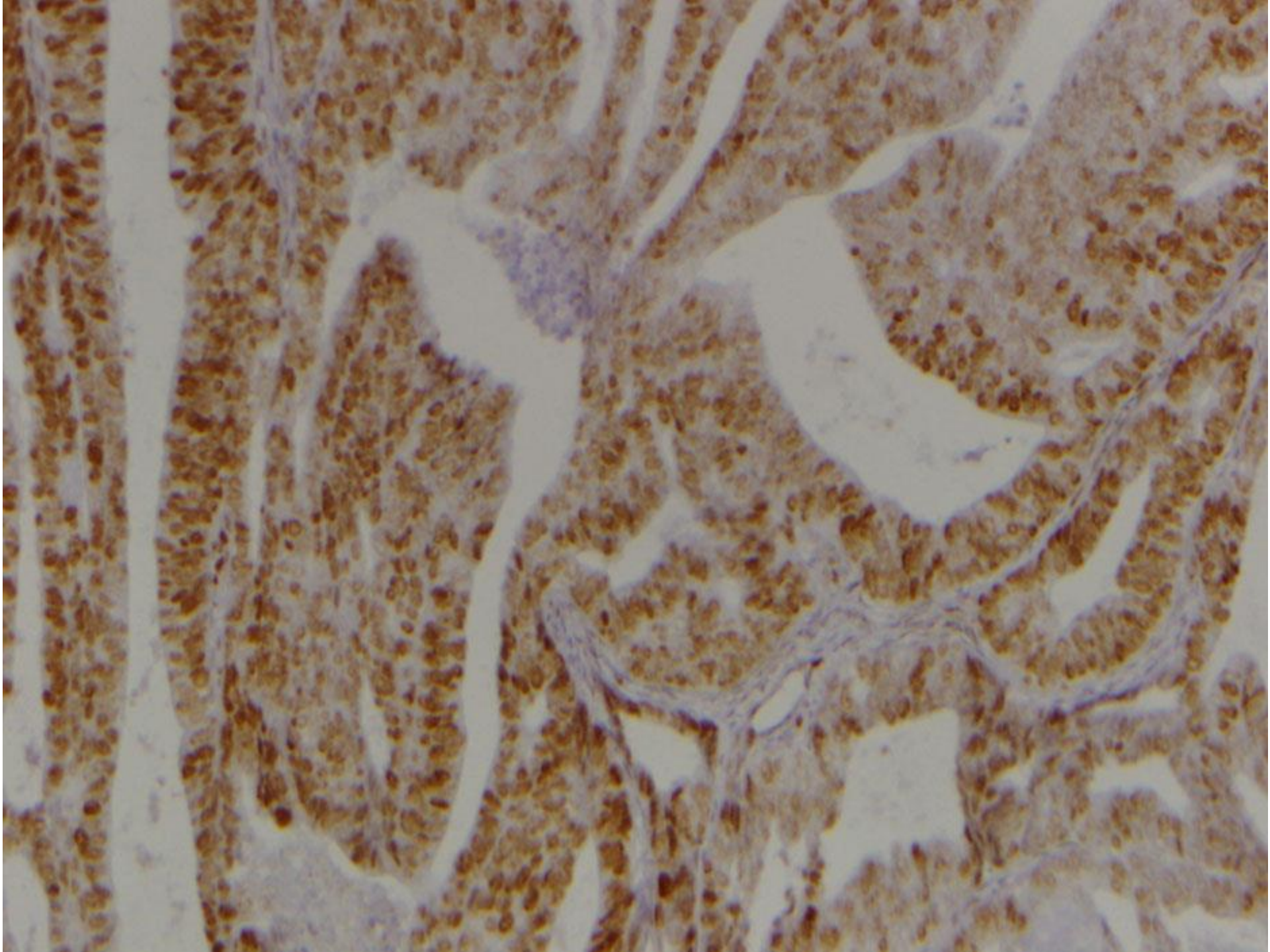
- Defect in MLH1: loss of MLH1/PMS2
- Defect in MSH2: loss of MSH2/MSH6
- Defect in MSH6: isolated loss of MSH6
- Defect in PMS2: isolated loss of PMS2
- There are exceptions
 - Isolated loss of PMS2 has been associated with MLH1 mutations
- Panel testing makes this less important

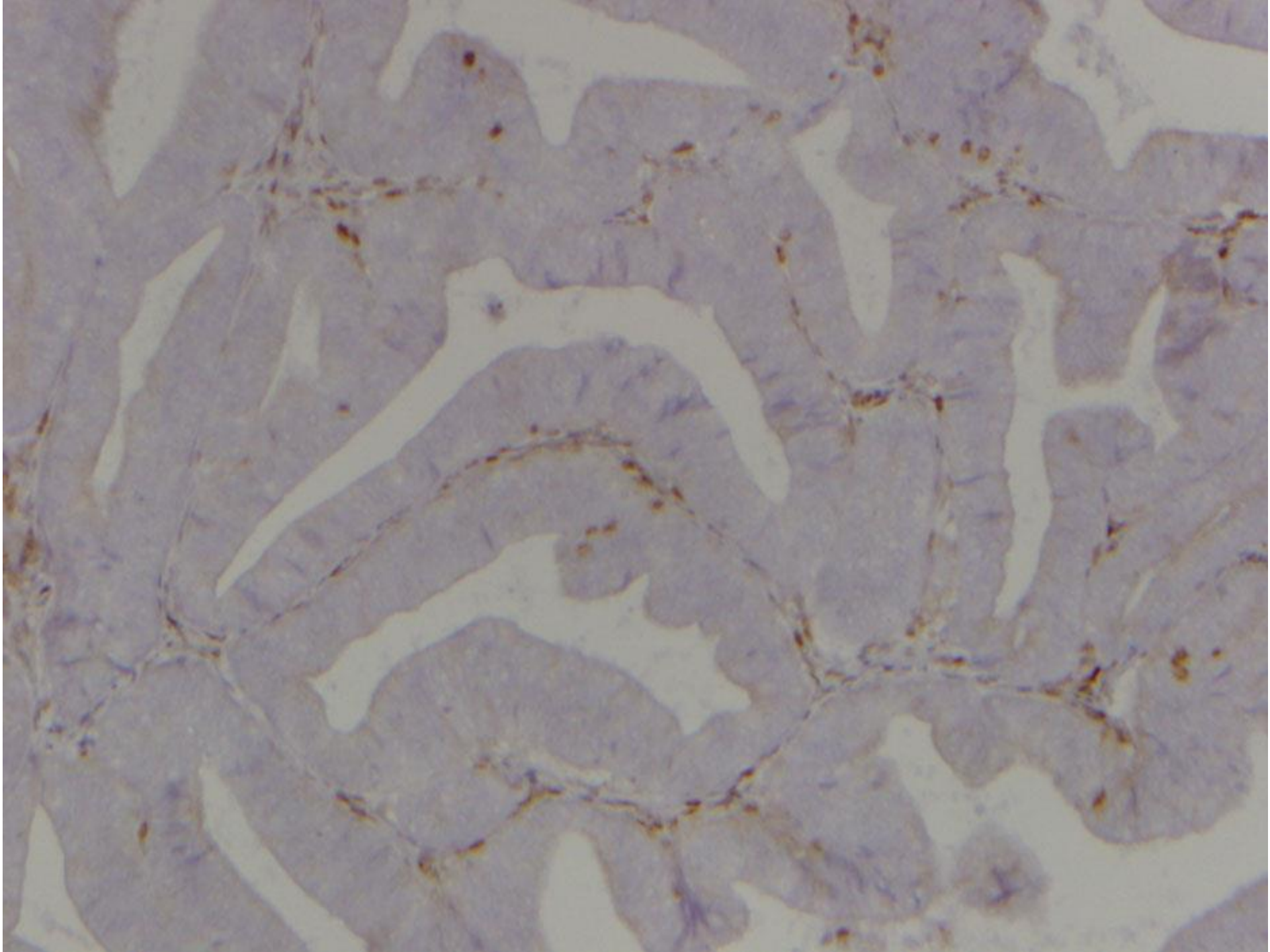
“Clonal” MSH6 loss

- Due to instability in a coding mononucleotide repeat in MSH6 (Shia, Modern Path 2013)
- Leads to focal (sometimes nearly complete/complete) MSH6 loss
- Primary cause of instability usually something else
 - MLH1 defect, either acquired methylation or germline
 - PMS2 defect

MSH6 IHC
(MLH1/PMS2 loss)







How do we work up Lynch syndrome?

- Determine if tumor is mismatch repair deficient
 - PCR for microsatellite instability
 - IHC for mismatch repair proteins
- Determine if mismatch repair deficient tumor is
 - Sporadic (more common): don't go on to germline testing
 - Possibly inherited: go on to germline testing

Clues mismatch repair deficient tumor is sporadic

- IHC profile of MLH1/PMS2 loss
 - Could still be Lynch with MLH1 mutation
- BRAF V600E mutation in colorectal cancer
- MLH1 promoter methylation in any mismatch repair deficient tumor

Mistake #1: IHC controls

- Haven't validated antibodies using known positive and negative controls
 - Need tumors with loss of MLH1/PMS2
 - Need tumors with loss of MSH2/MSH6
- Run these controls with every MMR IHC run
 - Need to see that antibodies stain tumors they should stain, and don't stain tumors they shouldn't
 - A tonsil doesn't show you this


U149 PMS2 OV



CONTROL
ARUP

12/28/14

U176 MSH6 OV



CONTROL
ARUP

12/28/14

17

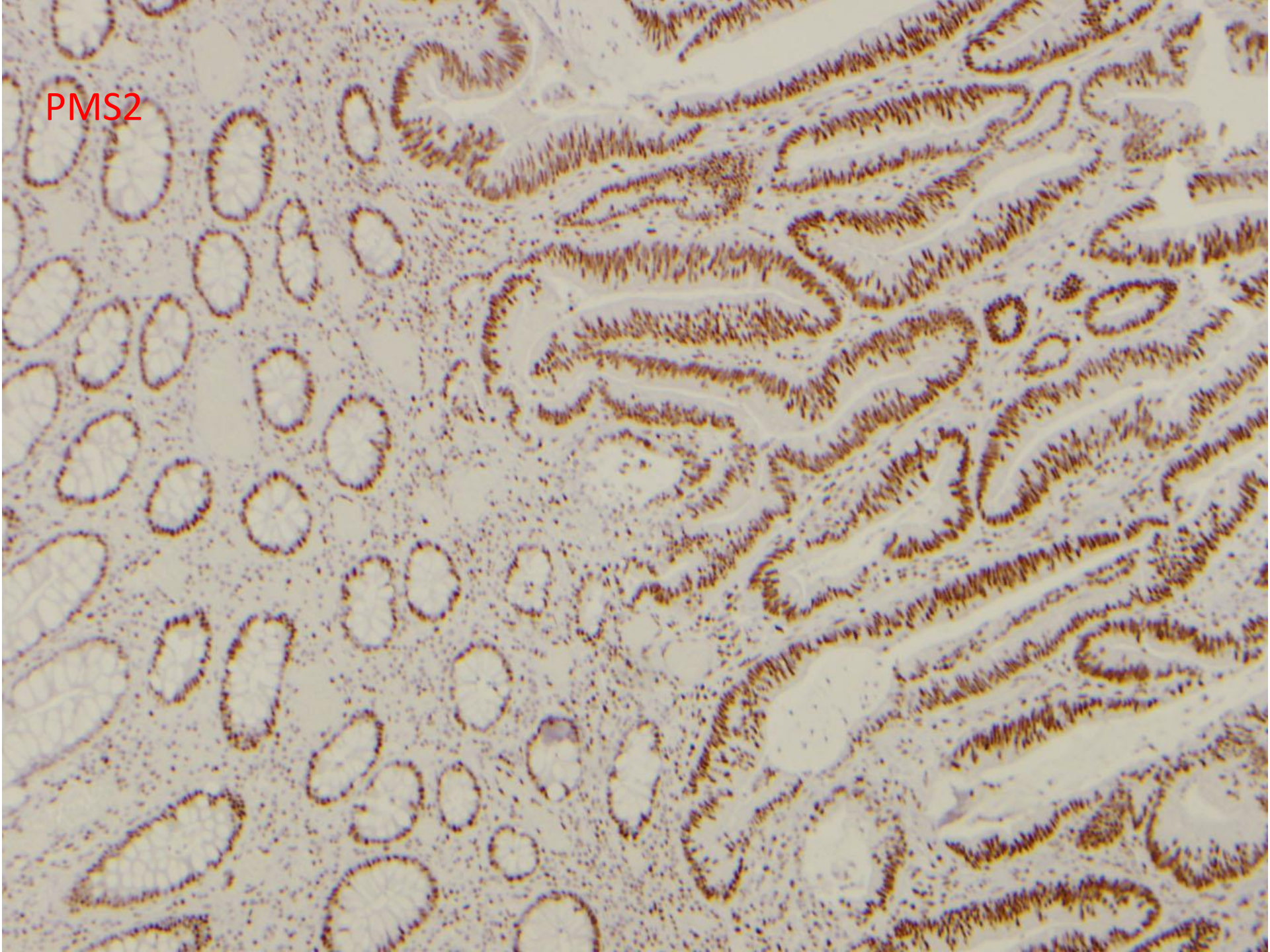
18

19

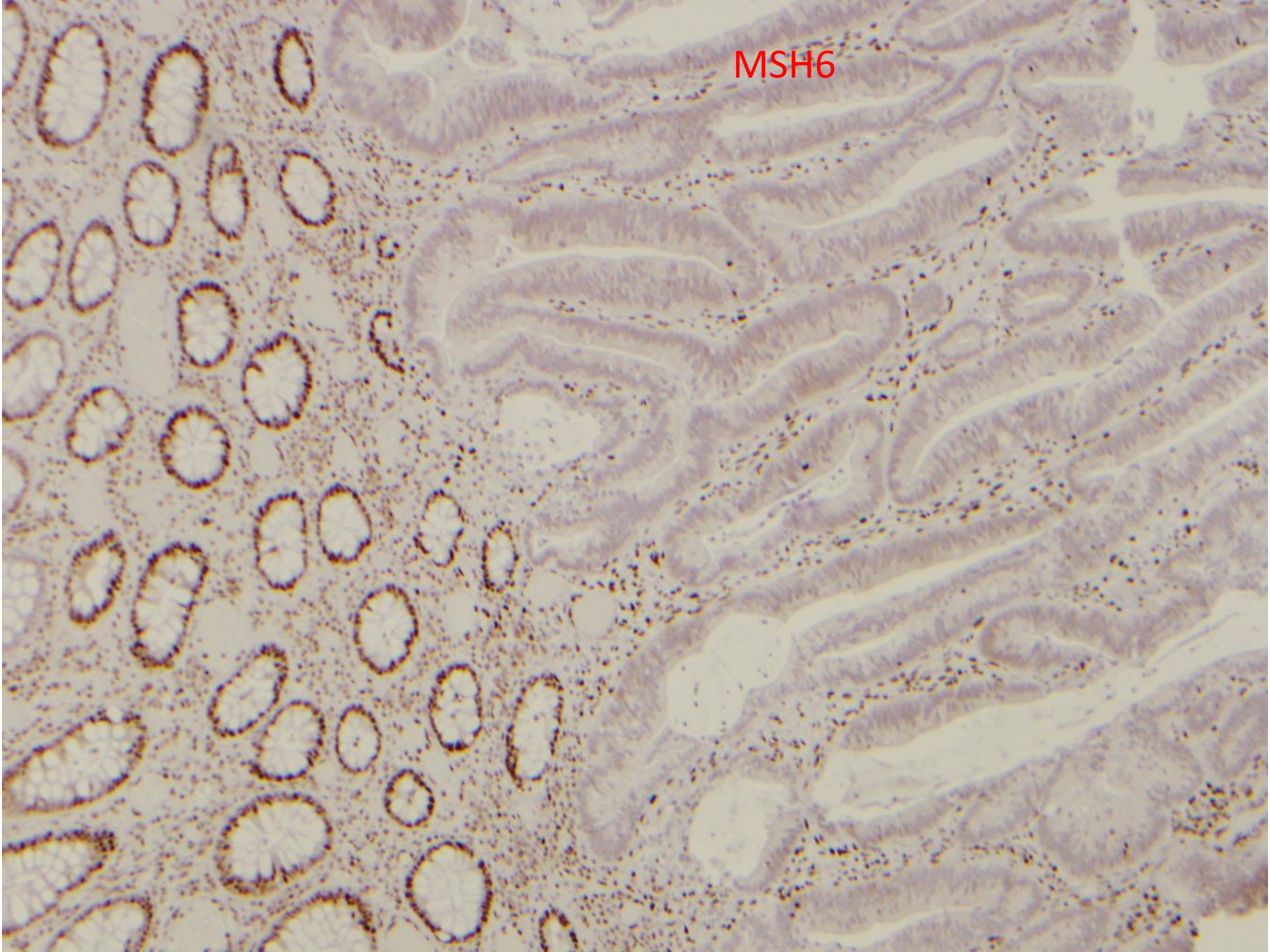
20

Leica
SYSTEMS

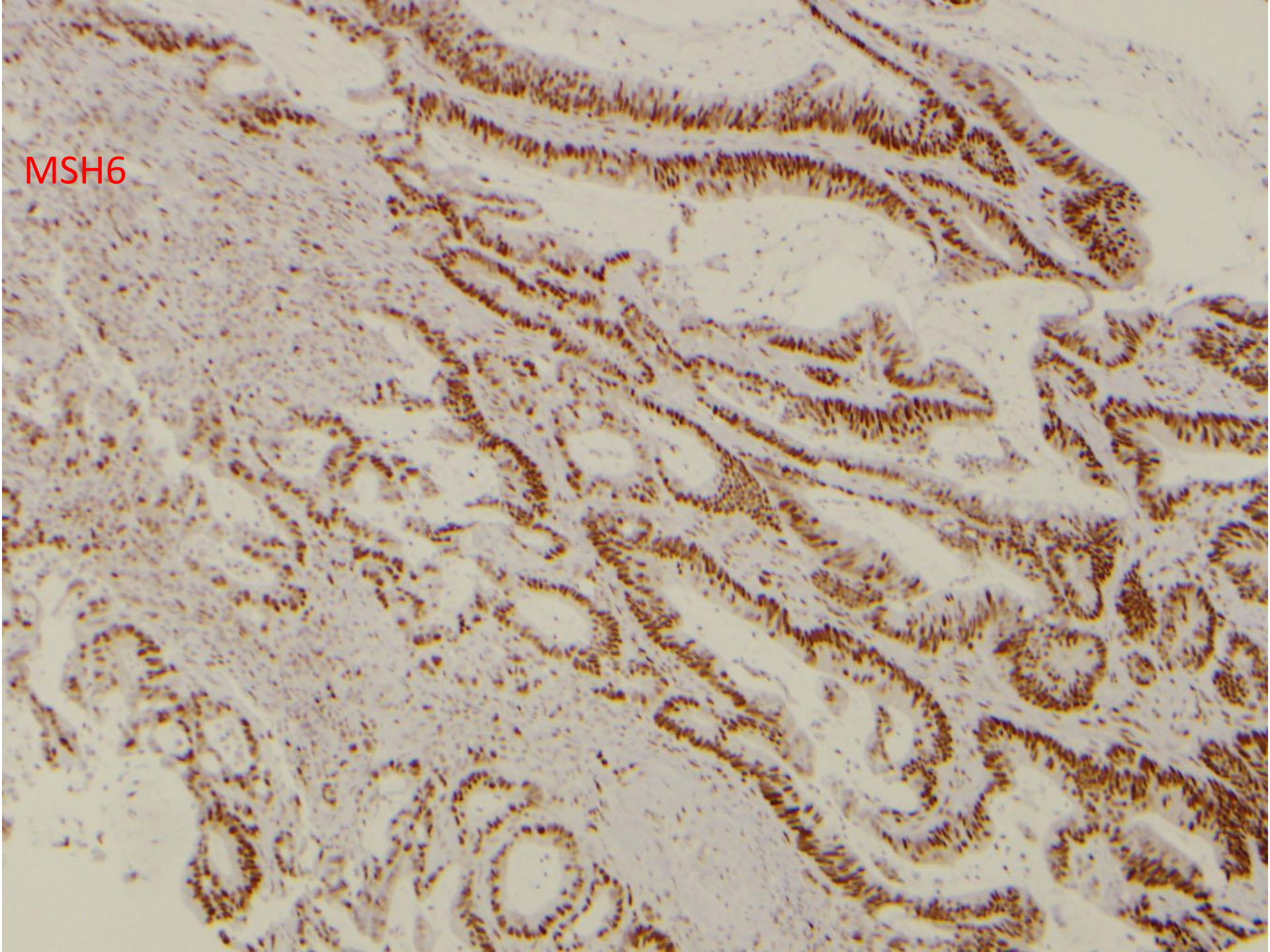
PMS2



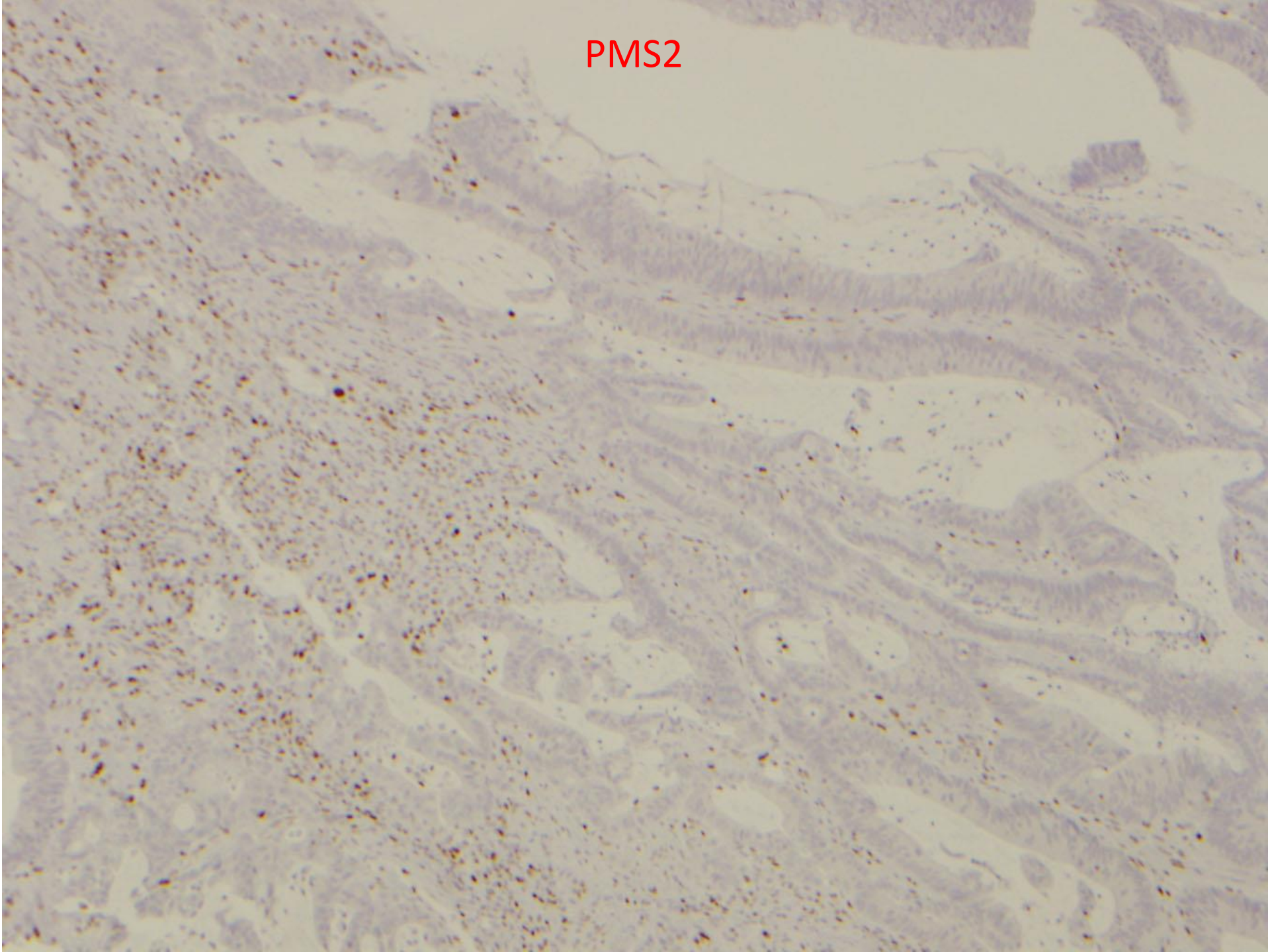
MSH6



MSH6



PMS2



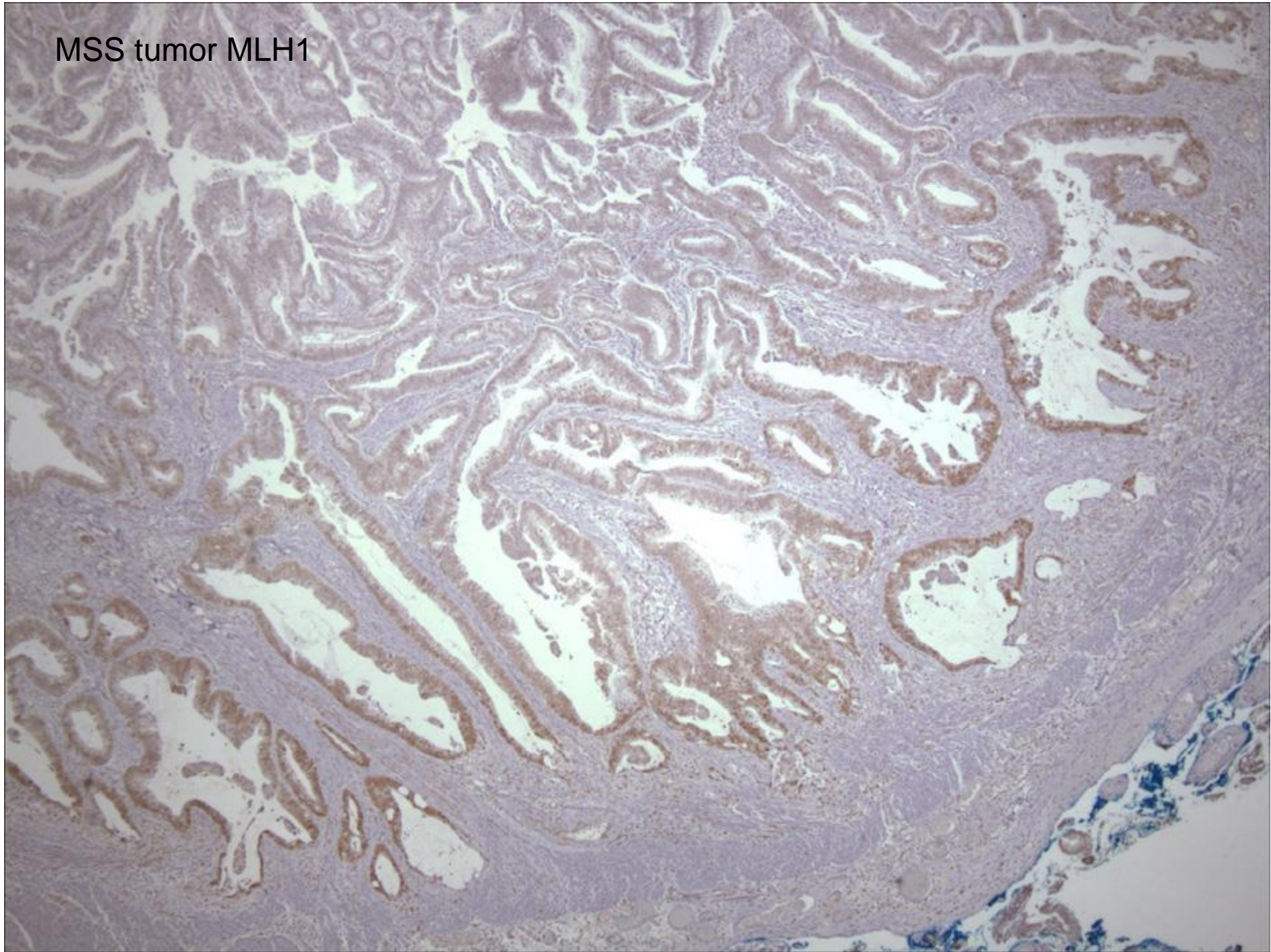
Mistake #2: reporting IHC results

- Don't describe IHC staining as “positive” or “negative”
- Say whatever you need to be clear; get feedback from clinicians (we say “normal” and “abnormal”)
- Don't report results that no one sees or acts upon
 - Interact with colleagues who deal with results
 - Make sure your reports are comprehensible to them and that they are reacting appropriately to these results (genetic counselors probably best)

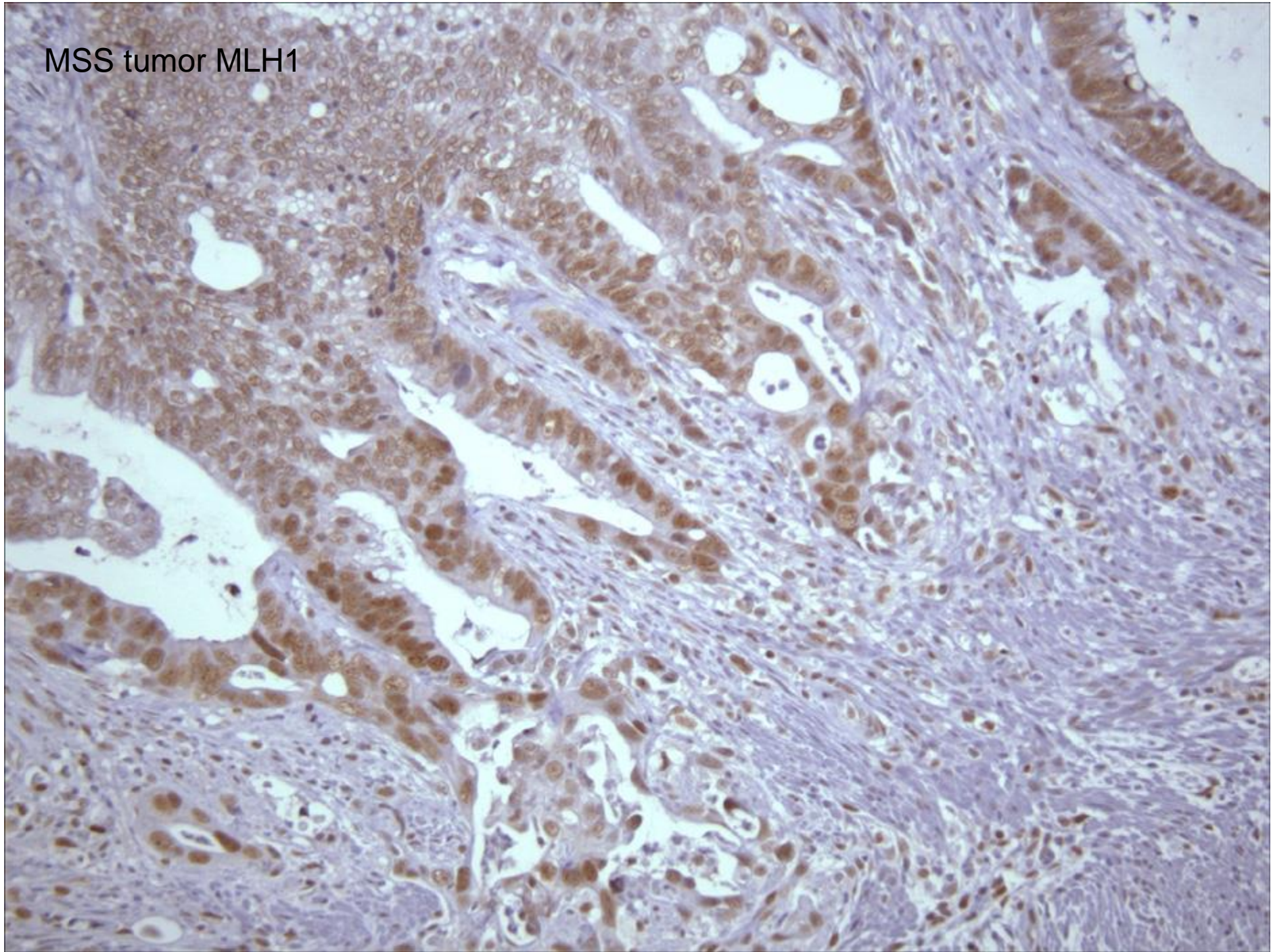
Mistake #3: IHC interpretation

- Loss of tumor staining without contiguous internal control staining is uninterpretable: don't call this abnormal
- Decreased staining intensity, unless quite marked, probably doesn't mean anything: this is a qualitative test
 - If quite marked, I write a note and usually suggest evaluating MSI by PCR to see if this supports an "abnormal" result by IHC

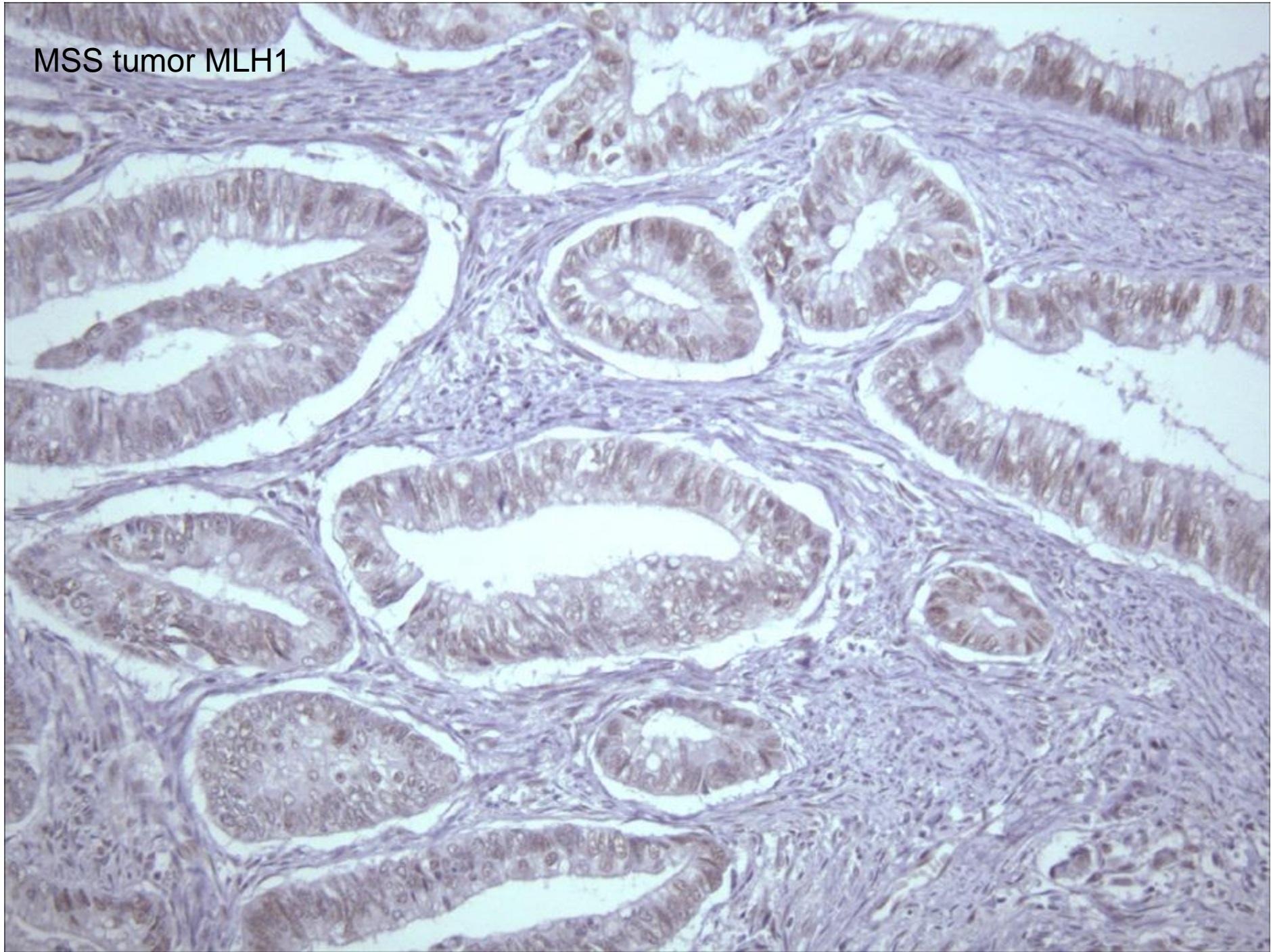
MSS tumor MLH1



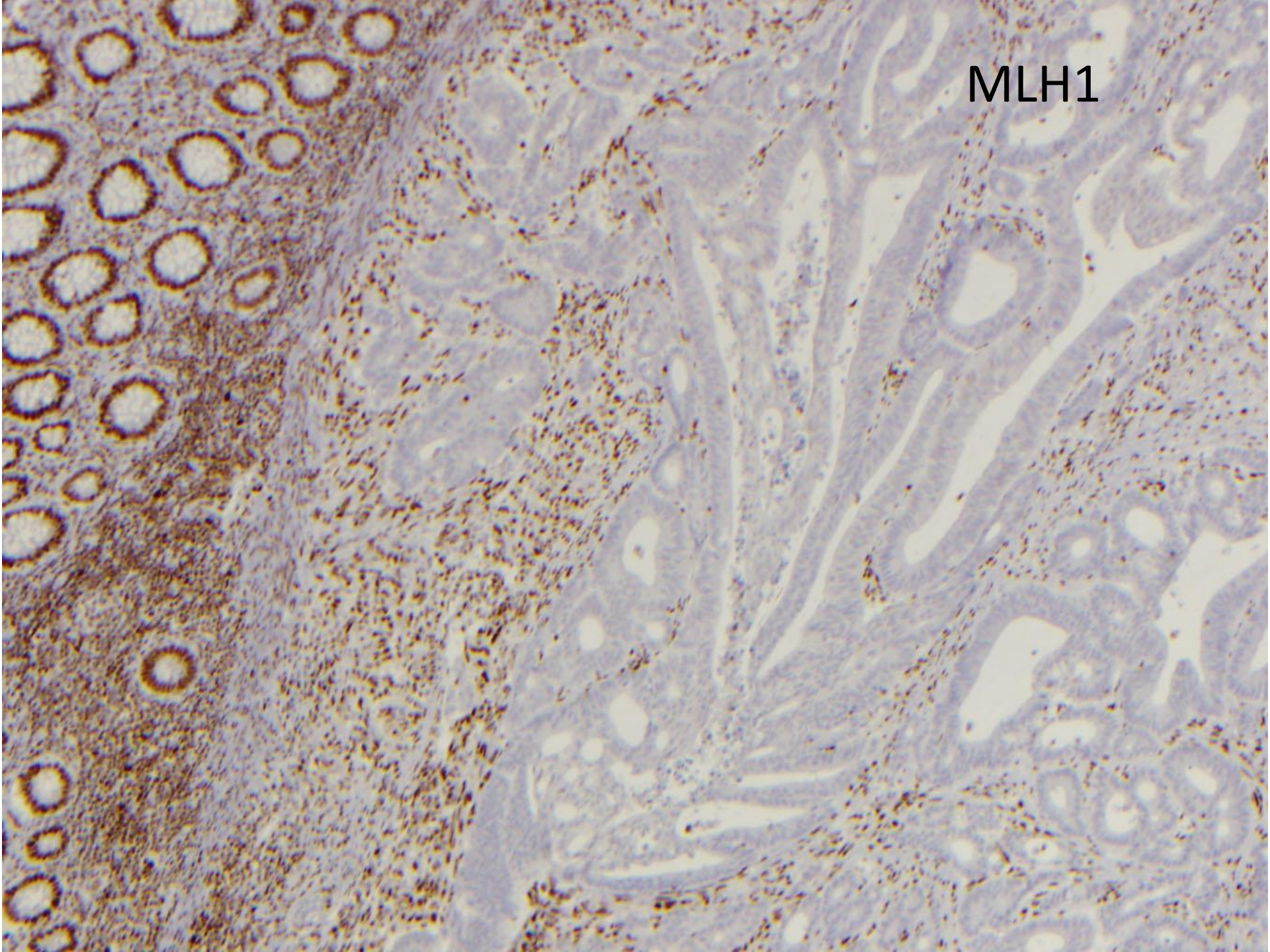
MSS tumor MLH1



MSS tumor MLH1



MLH1



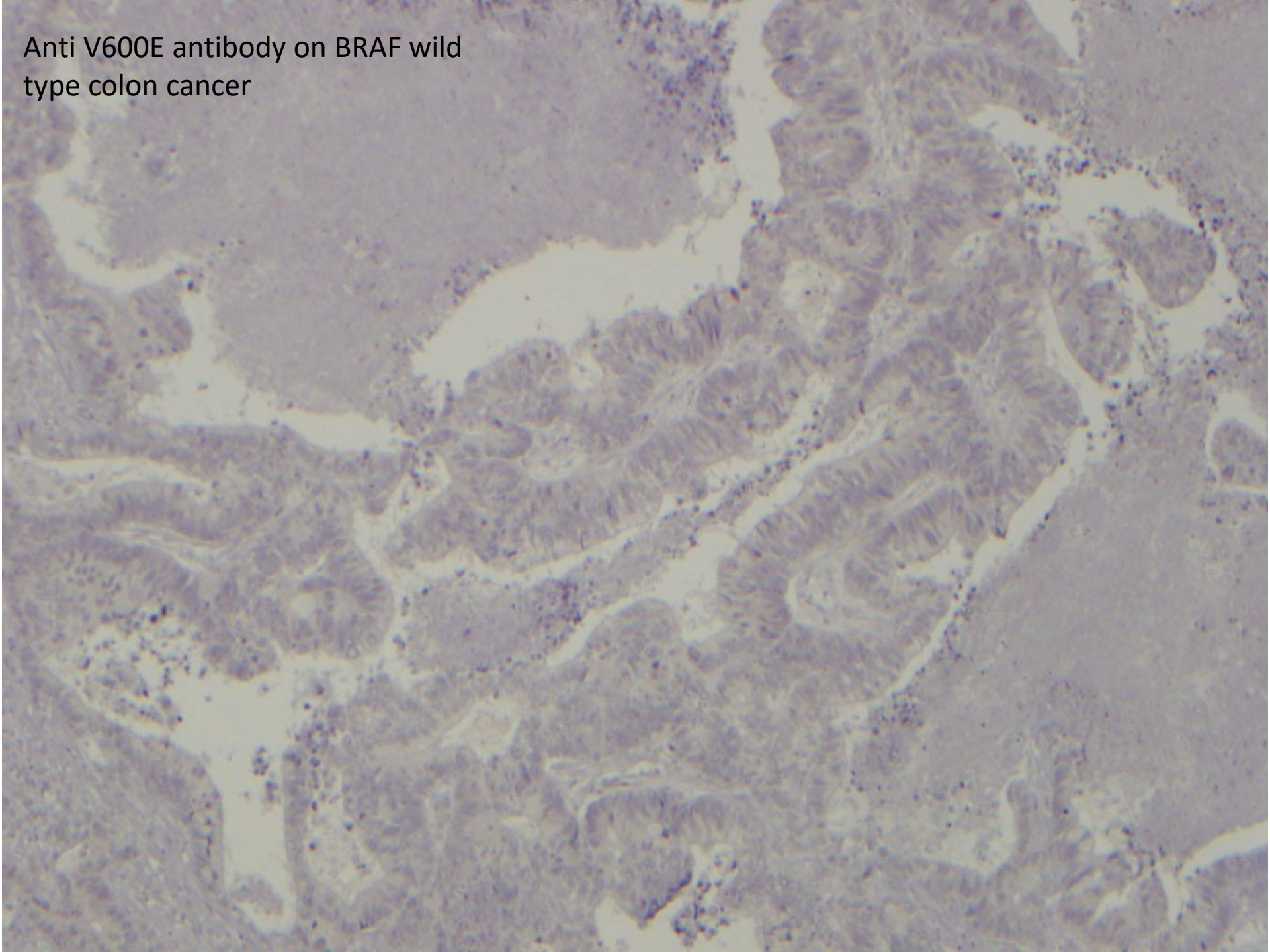
Mistake #4: Inappropriate BRAF testing

- Testing for BRAF mutation in non-colorectal (e.g. endometrial) cancers
- Uncommon for sporadic mmr deficient non-colorectal cancers to have BRAF mutations
- Need to test MLH1 methylation for non-colorectal cancers and for potentially sporadic colorectal cancers without BRAF mutations

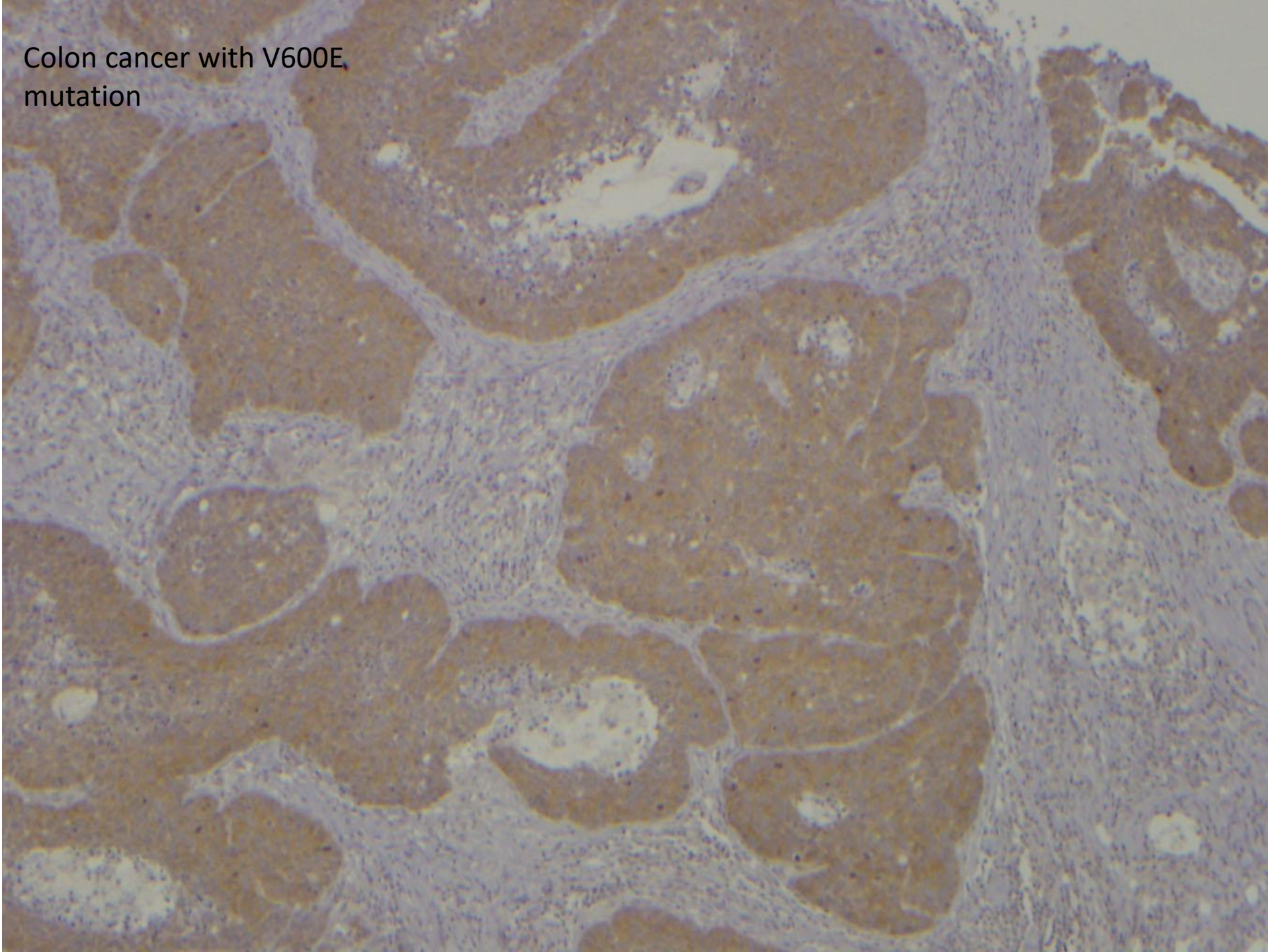
Mistake #5: all IHC Lynch work-up

- BRAF antibody: detects BRAF V600E mutation (Affolter, Samowitz et al GCC 2013)
- Has all issues of IHC tests, including staining variability and difficulties in interpretation.
- No internal controls for antibody staining
- Research vs. clinical test
 - Clinical test needs to be robust, easily interpretable

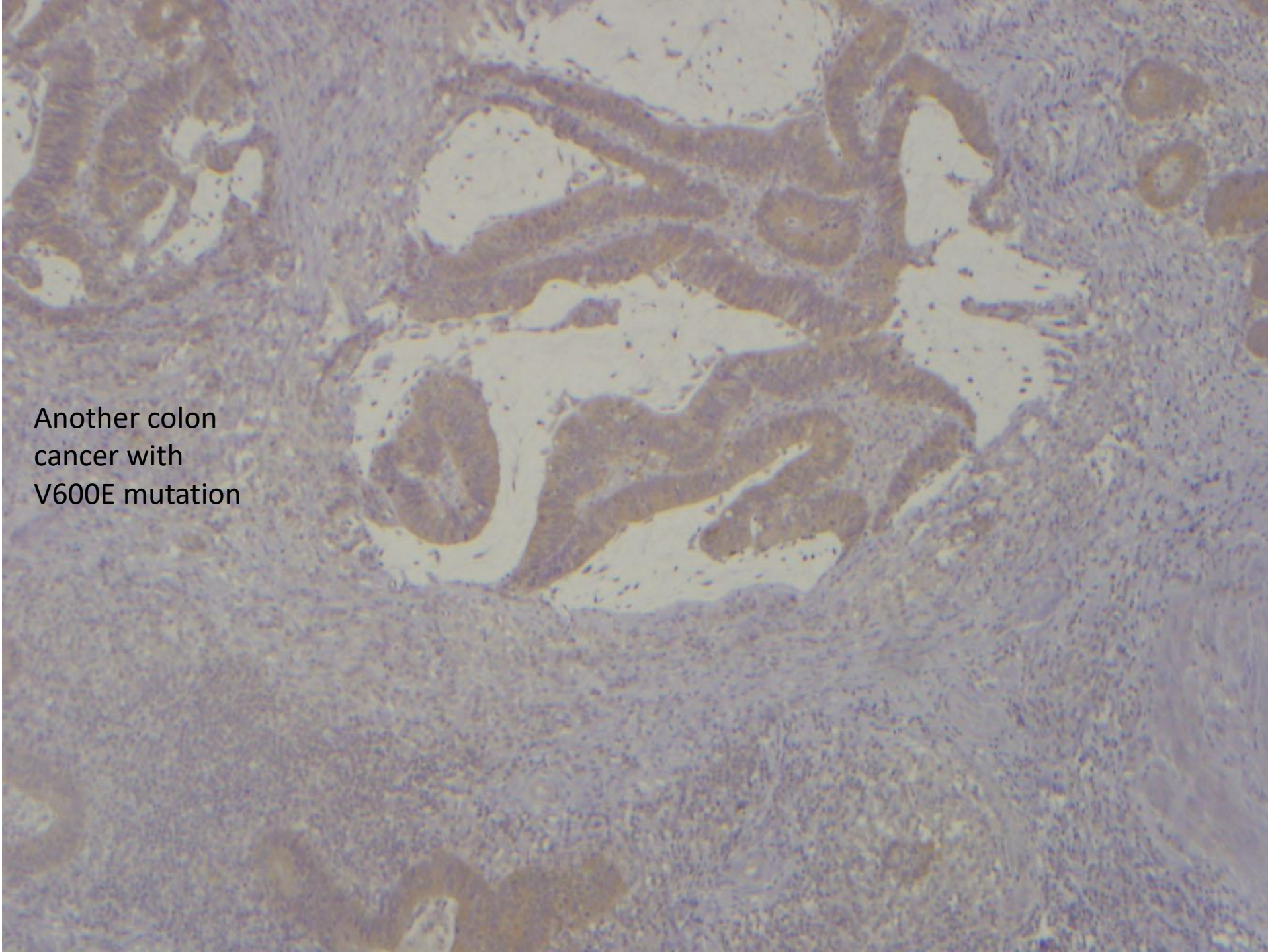
Anti V600E antibody on BRAF wild
type colon cancer

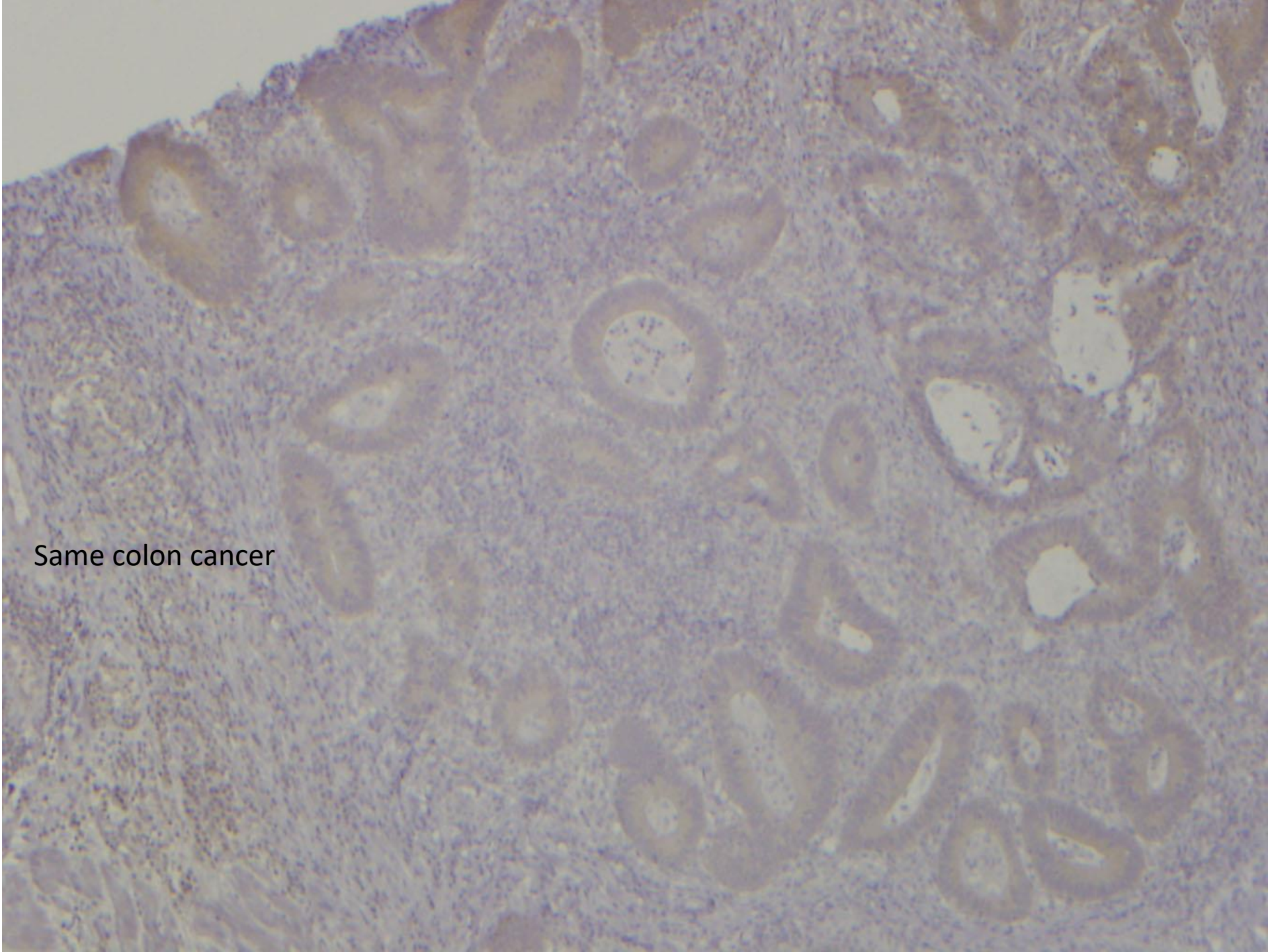


Colon cancer with V600E mutation



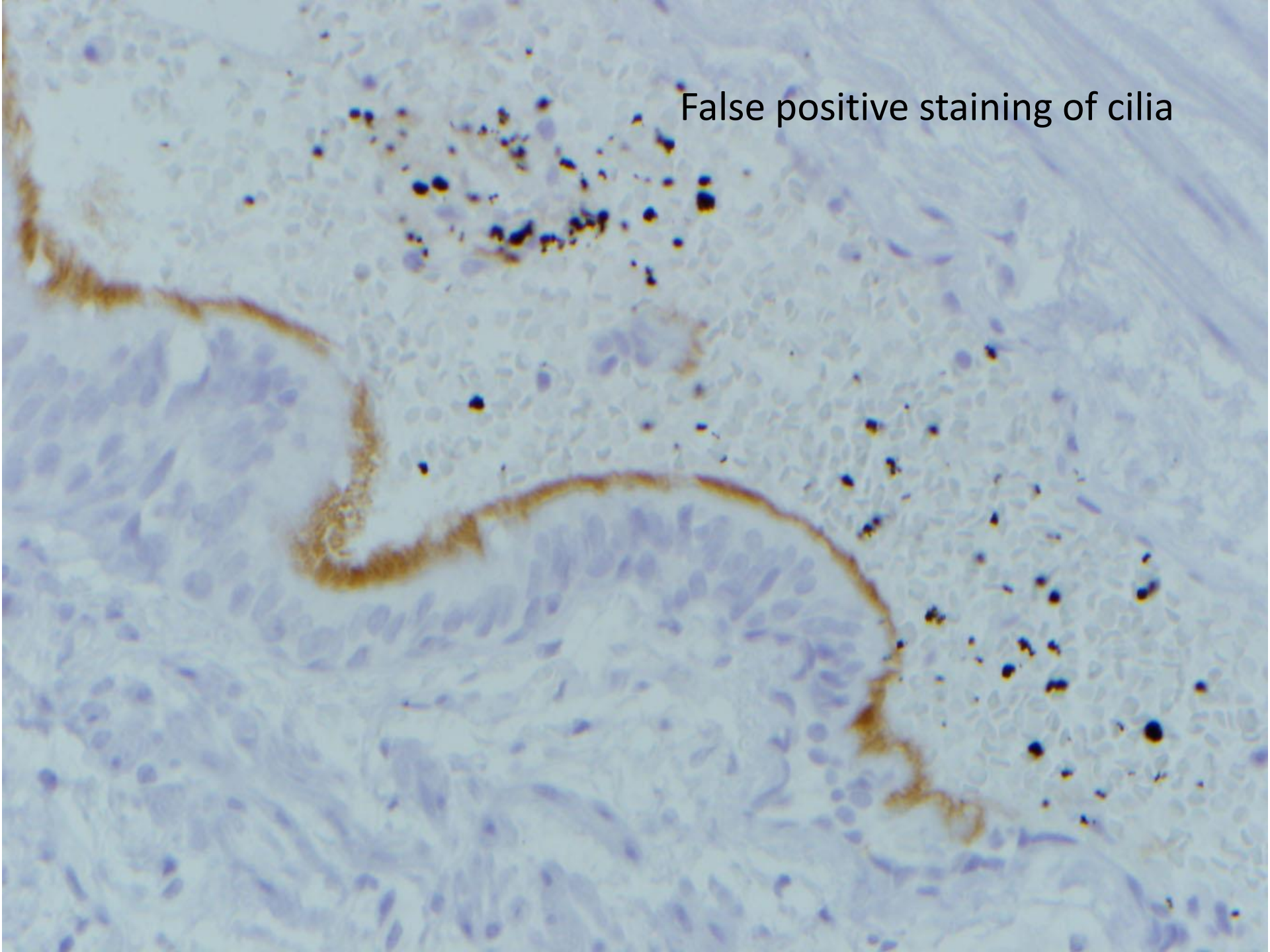
Another colon
cancer with
V600E mutation





Same colon cancer

False positive staining of cilia



Mistake #5: all IHC Lynch work-up

- BRAF antibody: has all issues of IHC tests, including staining variability, staining heterogeneity, and difficulties in interpretation.
- BRAF molecular test: robust, objective
- Still need to test MLH1 methylation for BRAF wild type colorectal cancers (50% of sporadic mmr deficient) and non-colorectal cancers

What about EPCAM?

- EPCAM is just five prime of MSH2
- Three prime EPCAM deletions lead to transcriptional read through, MSH2 methylation and Lynch syndrome
- EPCAM deletions associated with similar colon cancer risk as MSH2 mutations, but less of an endometrial cancer risk

Does EPCAM IHC help in Lynch work-up?

- Standard mmr IHC won't miss Lynch due to EPCAM deletions
 - IHC profile will be MSH2/MSH6 loss
- Standard germline genetic analysis for MSH2 will detect EPCAM deletions
 - Already includes probes for EPCAM deletions

Mistake #6: overstating likelihood of Lynch syndrome

- We used to think that any abnormal IHC profile other than typical sporadic mmr deficient (MLH1/PMS2 loss) was Lynch syndrome.
- We used to think that MLH1/PMS2 loss without BRAF mutation (in colorectal cancer) or MLH1 methylation (in all mmr deficient tumors) was Lynch syndrome.
- Accumulating evidence suggests that many of these are due to acquired mutations in MMR genes, such as two acquired mutations in MSH2-- ?Lynch-like (Haraldsdottir et al, Gastroenterology, 2014).
- IHC result should not include statements like “this probably represents Lynch syndrome.” May lead to unwarranted individual and family surveillance and/or intervention.

Mistake #7,8: testing of serrated lesions

- Evaluating serrated lesions for mismatch repair deficiency
 - Based on incorrect notion that this will separate clinically relevant SSP's from clinically irrelevant HP's
 - SSP's without dysplasia do not show microsatellite instability or loss of MLH1/PMS2 staining or MLH1 methylation
- Evaluating serrated lesions for BRAF mutations
 - Both SSP's and HP's commonly have BRAF mutations

SSP vs. HP

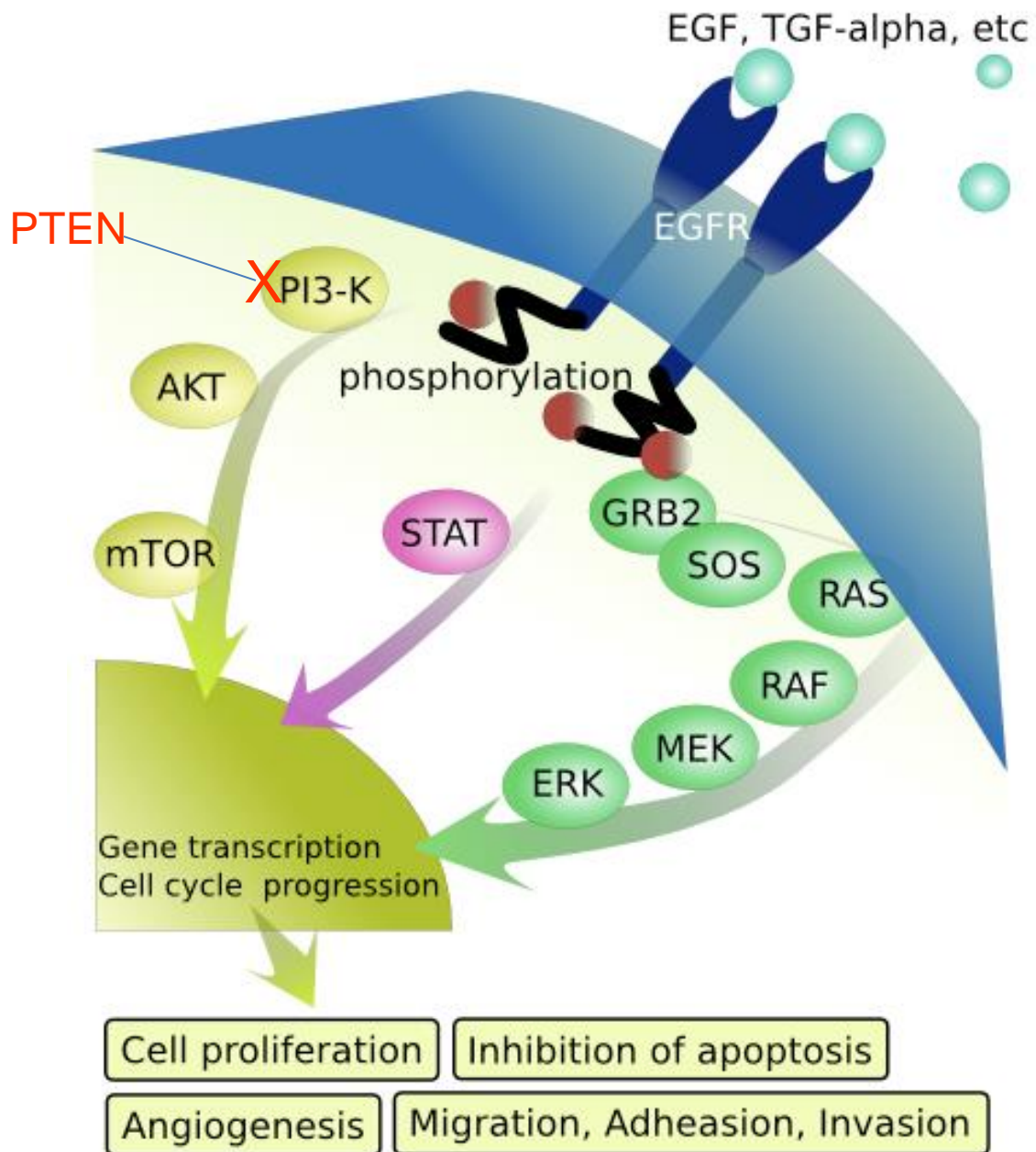
- No molecular test reliably separates these lesions
- Use polyp histology, site, size and number to guide clinical follow-up (Rex, Am J Gastroenterol, 2012)

Therapy based upon MMR deficiency

- Part of decision whether to treat Stage II
 - Good prognosis with MMR deficiency one reason not to treat
- May determine utility of immunotherapy
 - High mutation rate of MMR deficient tumors generate neoantigens which stimulates an anti-tumor immune response
 - Programmed Death 1 (PD-1) pathway inhibits this
 - Immunotherapy to block PD-1 is effective in MMR deficient tumors (colorectal and non-colorectal)
 - Immunotherapy may also work on hypermutator tumors due to POLE or POLD mutations

EGFR inhibitor therapy for colorectal cancer

- EGFR pathway is activated (but EGFR is not mutated) in colorectal cancer
- Cetuximab is an antibody that binds to EGFR, turns off EGFR pathway
- A mutation downstream of EGFR that activates the pathway makes this blocking irrelevant
- Bad to give a toxic and expensive drug if it won't work



Wikimedia


EGFR pathway inhibition

- Original studies: EGFR inhibition ineffective if mutation in codon 12 or 13 of KRAS
- Subsequently extended to codons 12, 13, 59, 61, 117 or 146 of KRAS and NRAS
- Codon 1047 PIK3CA mutations*, loss of PTEN*
- BRAF may be prognostic marker (bad) rather than predictive of therapy response


* Not recommended by recent guidelines (J Mol Diagn 2017 Mar;19(2):187-225)


What is your role in this?

- Selecting block to test
- Circling tumor
- Maybe performing the test, interpreting results



Early microscope



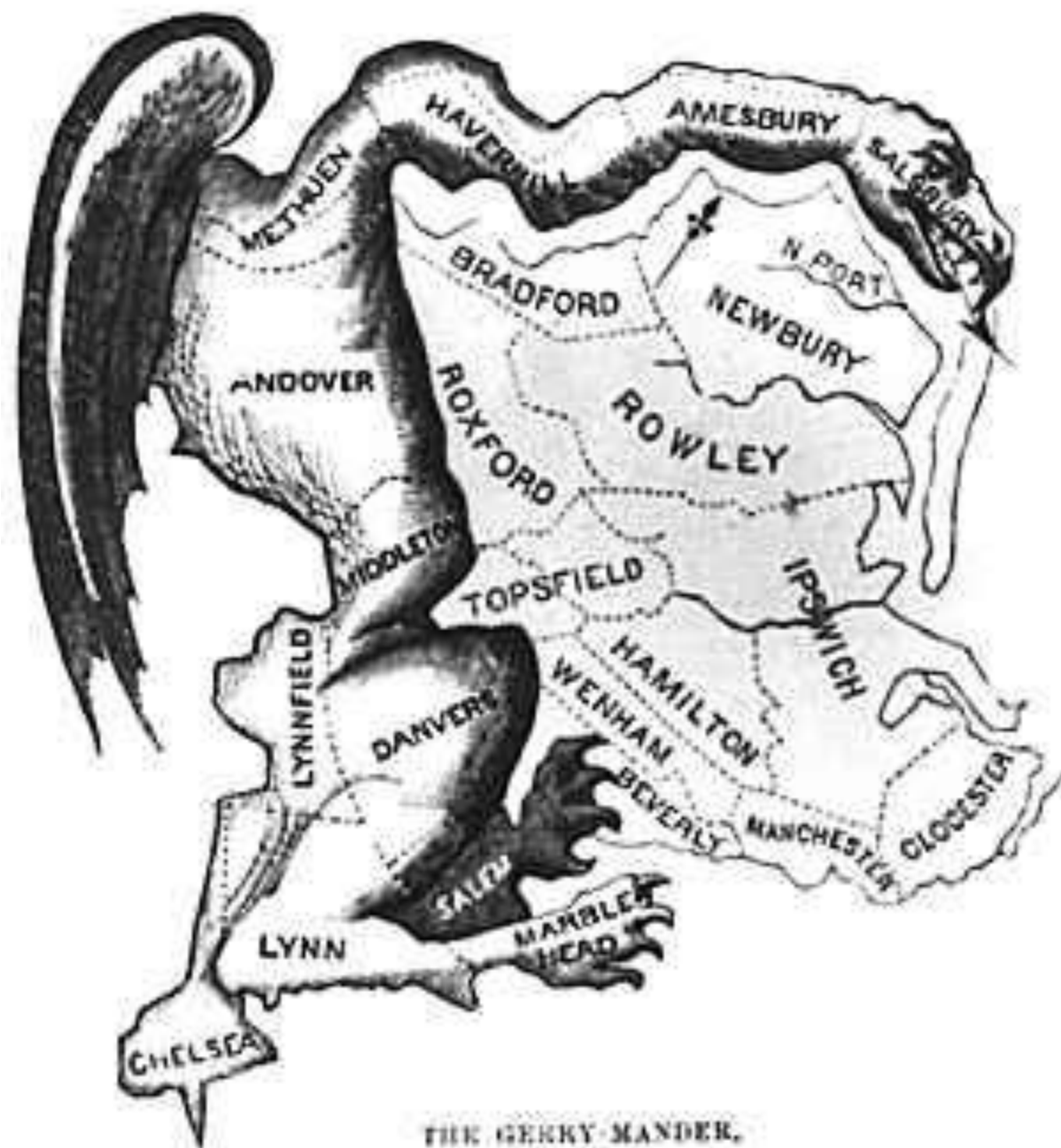

Mistake #9: choosing a bad block

- PCR isn't magic; garbage in, garbage out still applies
- With colon cancer, finding a block with sufficient tumor usually isn't a problem
- Rectal cancers resected after chemoradiation may be hypocellular; often better to choose pre-treatment biopsy
- Don't use decalcified specimens, specimens fixed in unusual fixatives

Mistake #10: poor circling of tumor

- Avoid (as much as possible) contaminating normal cells (such as lymphoid follicles)
 - Don't be ridiculous about this, most tests will work with about 20% tumor, usually easily achievable with colon cancer
- Don't need all the tumor
 - No need to “gerrymander” the circled area
 - Difficult to dissect, wastes everyone's time



THE GERRY-MANDER.





29

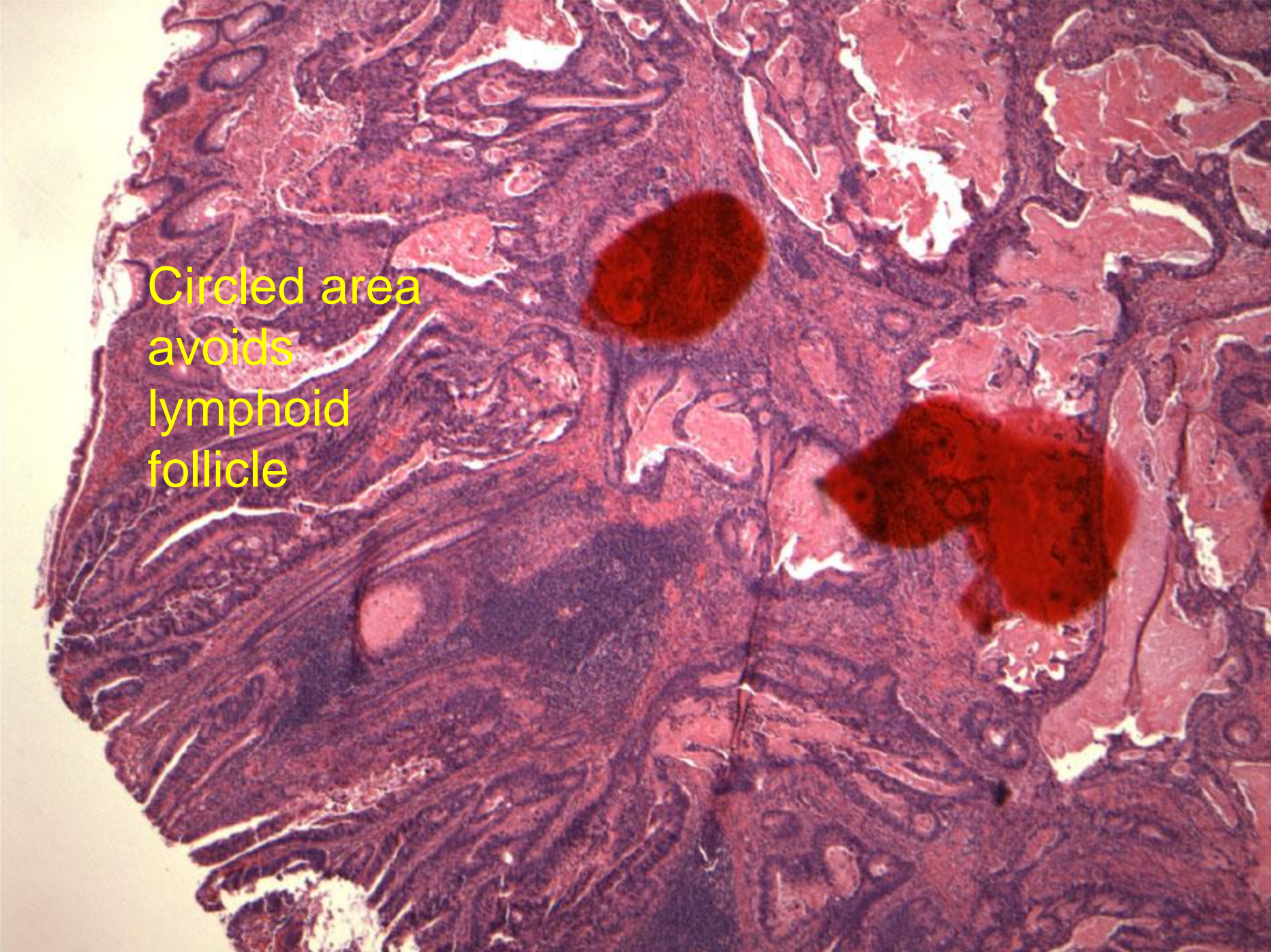


Slide of a colon cancer with a circled area of colon cancer which will be microdissected

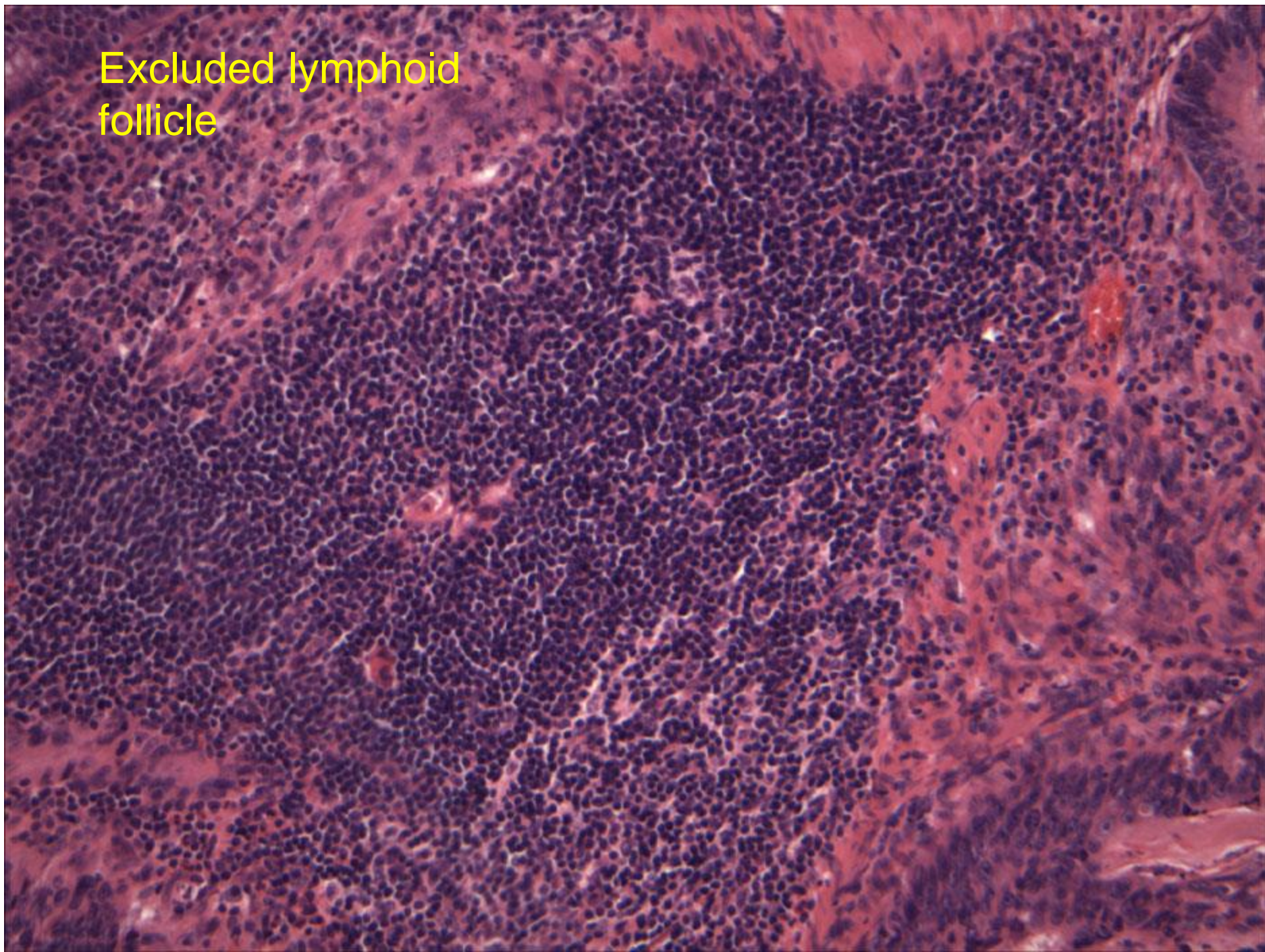
A low-magnification histological section of endometrial tissue stained with hematoxylin and eosin (H&E). The image shows a dense population of glands and stroma. A central area is circled in red, indicating a region of interest for higher magnification. The glands are lined by a simple columnar epithelium, and the stroma is composed of spindle-shaped cells. The overall appearance is consistent with a hyperplastic or neoplastic process.

Higher power
of circled area

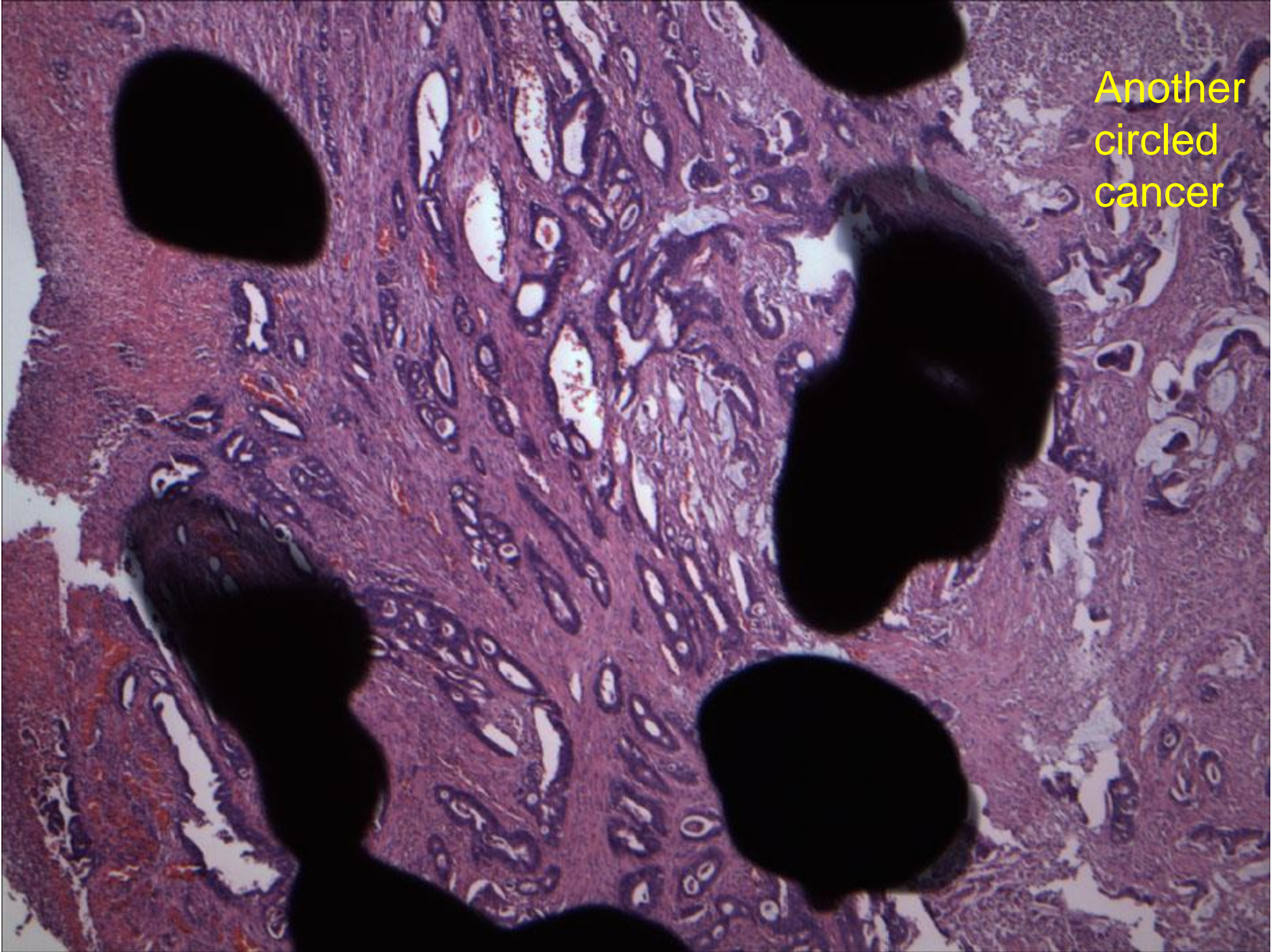
Circled area
avoids
lymphoid
follicle

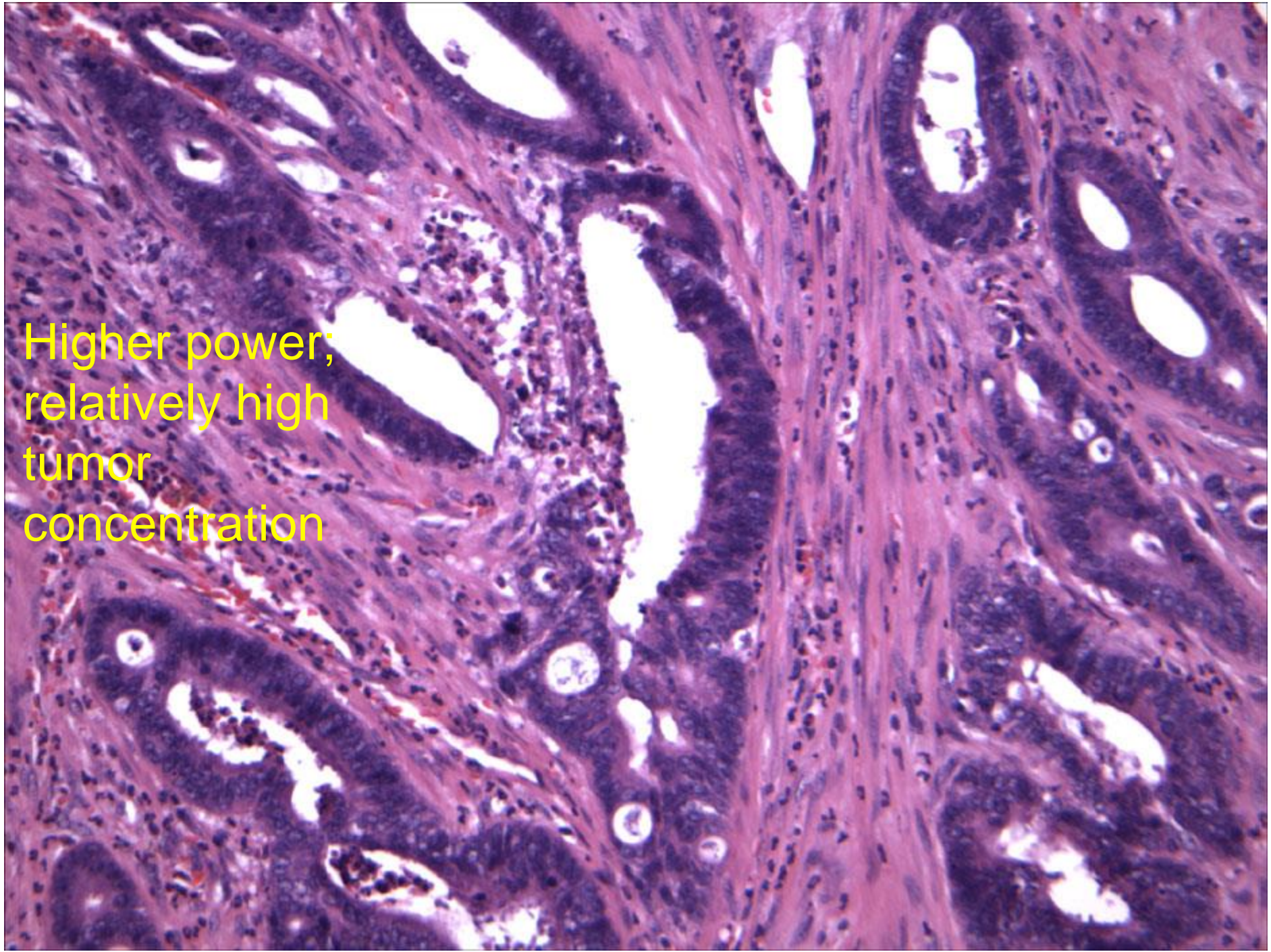


Excluded lymphoid
follicle



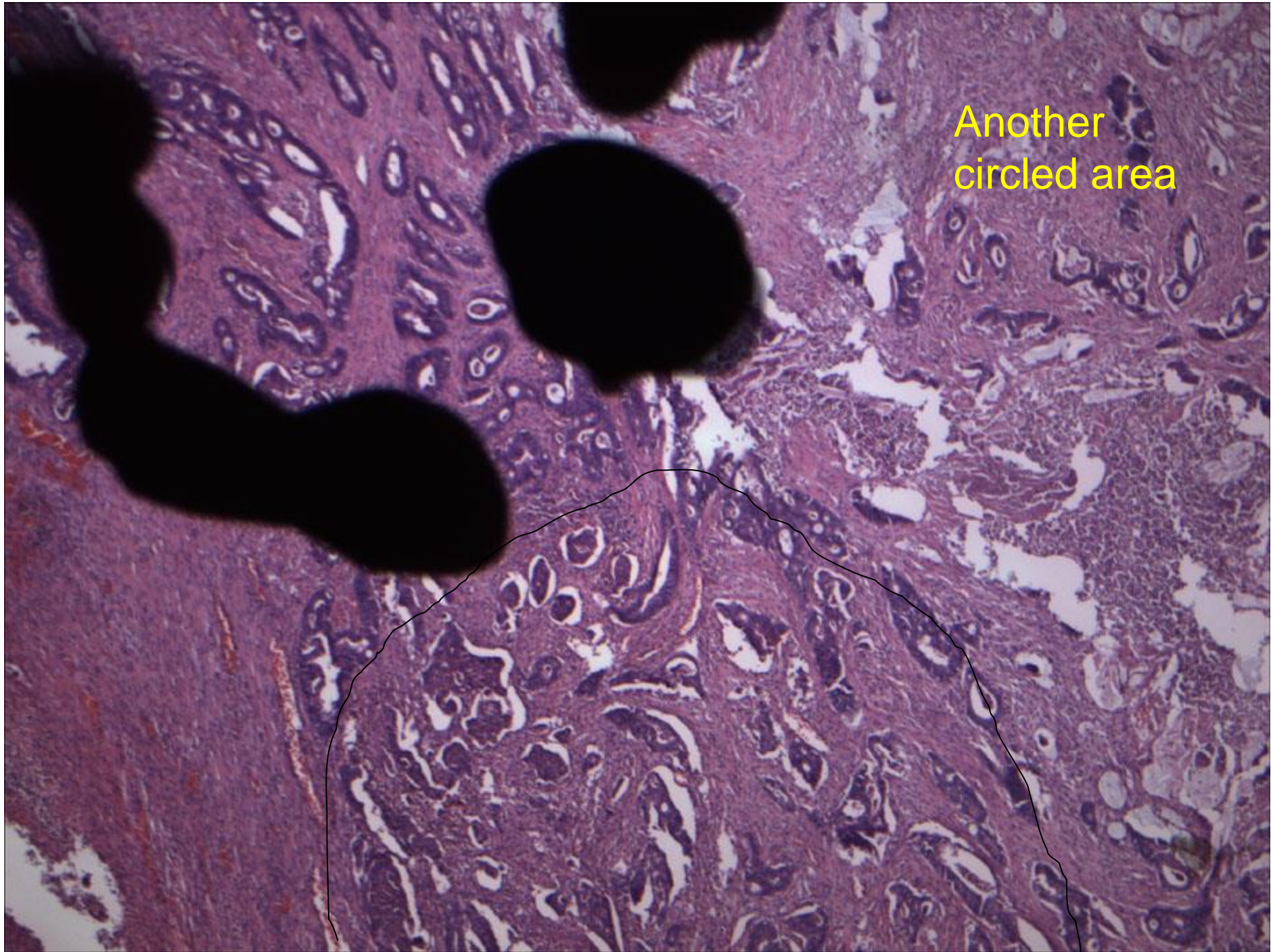
Another
circled
cancer

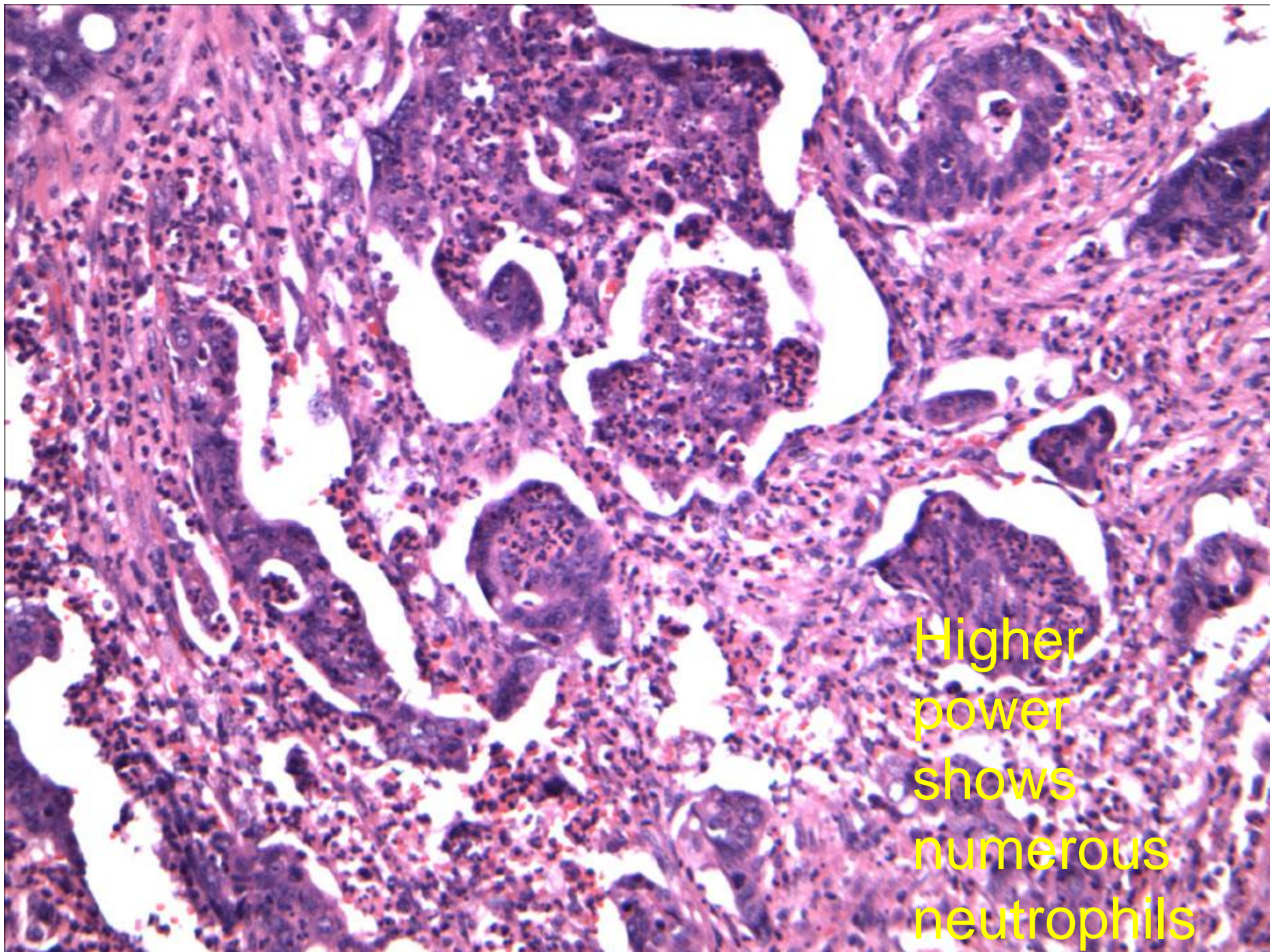




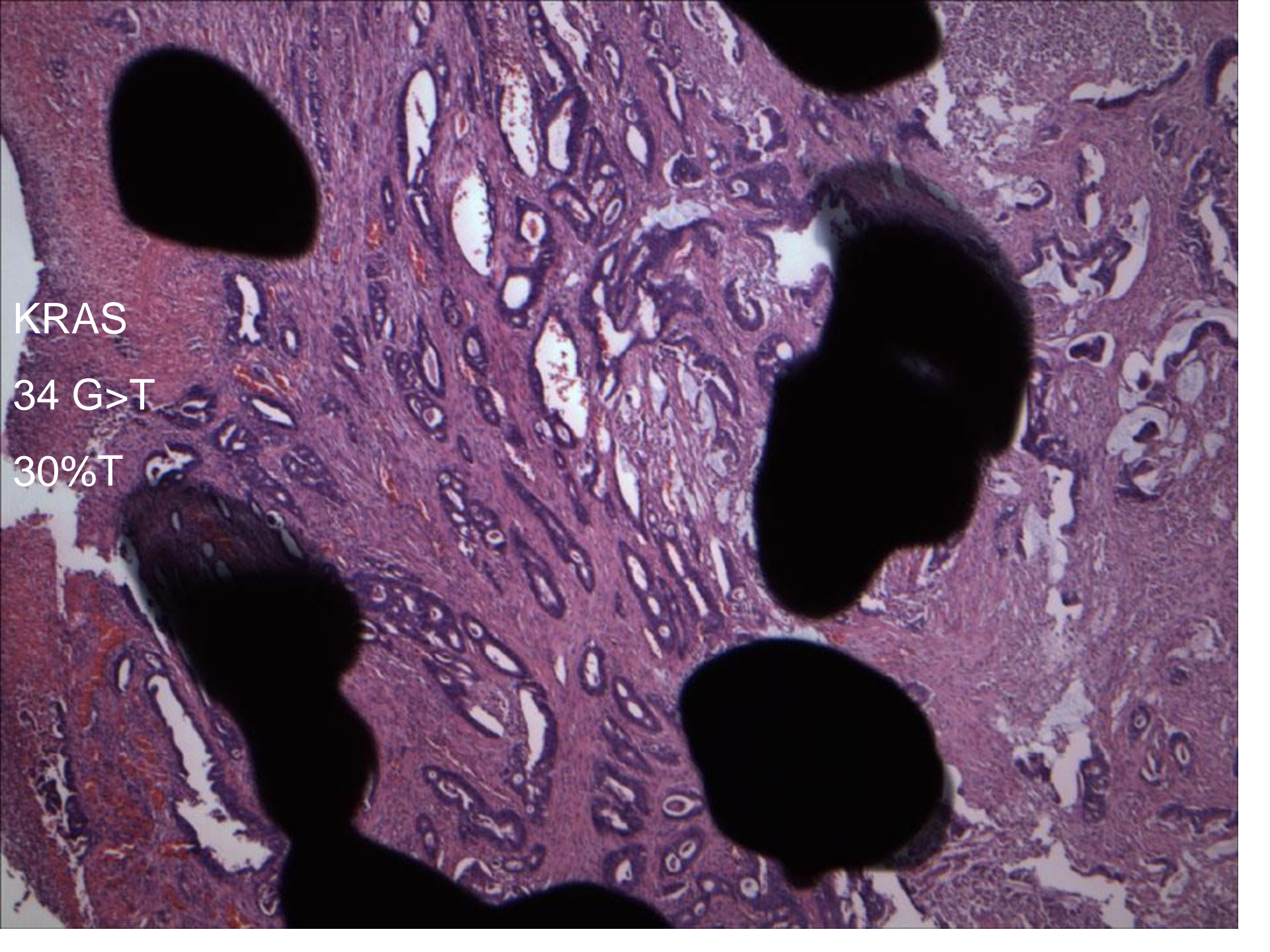
Higher power;
relatively high
tumor
concentration

Another
circled area

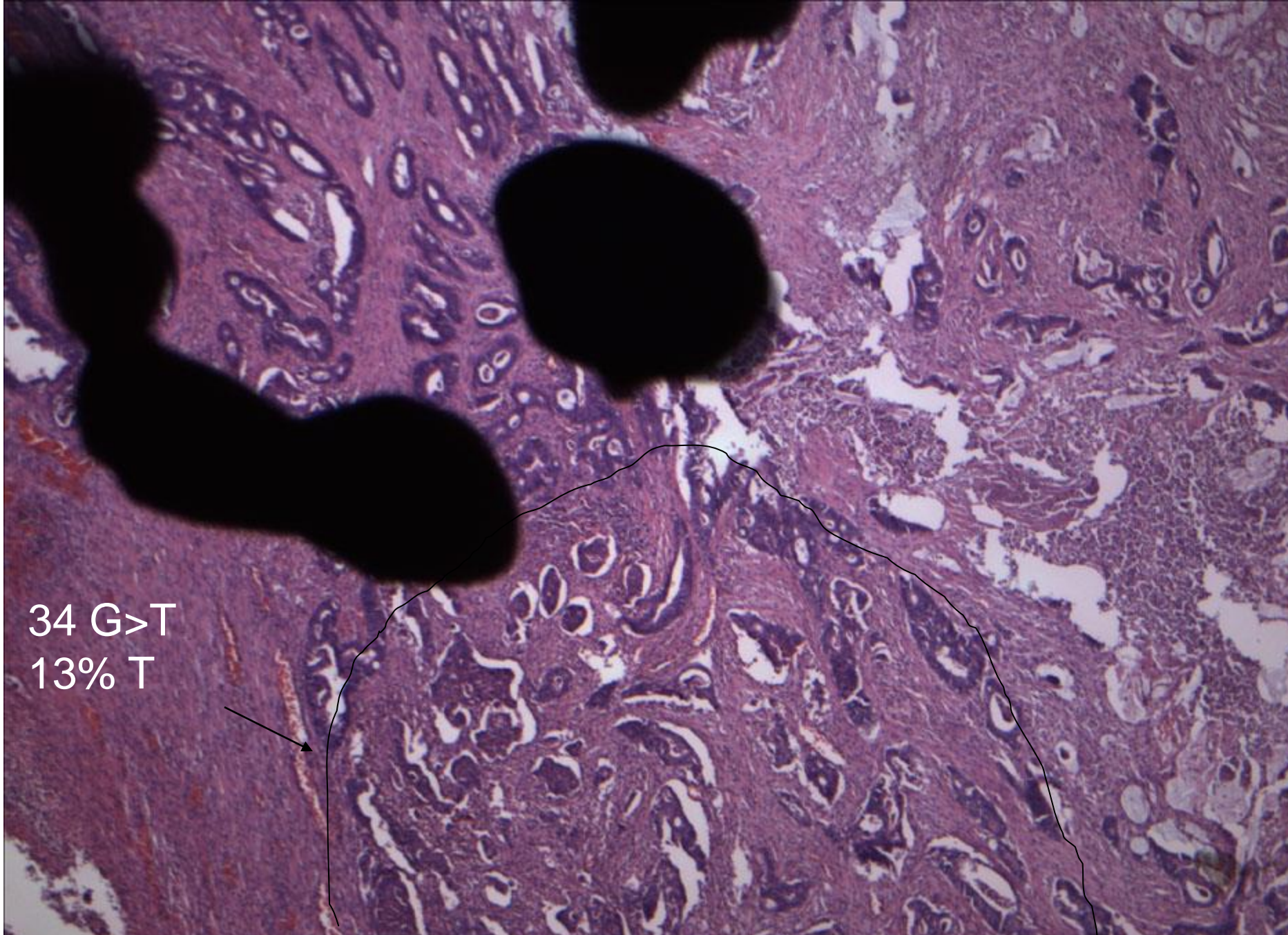




Higher
power
shows
numerous
neutrophils



KRAS
34 G>T
30%T



34 G>T
13% T



Mistake #11: Circle and forget it

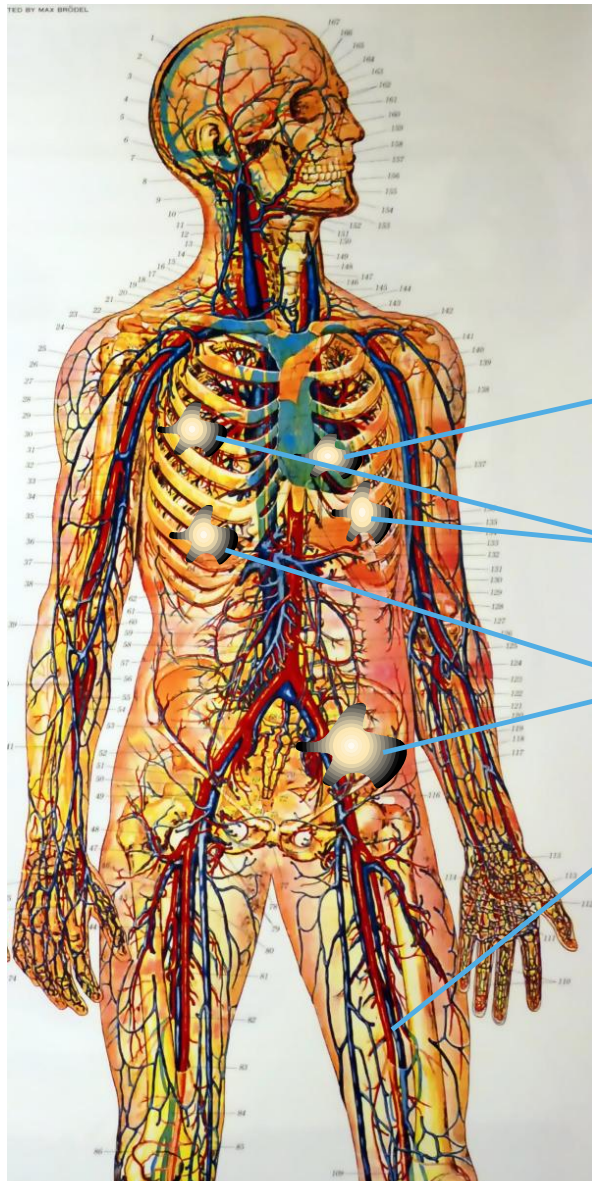
- Help troubleshoot a failed test
 - Decalcified, funny fixative?
 - Look at slide
 - Lots of tumor? Consider diluting sample to get rid of potential inhibitors
 - Hardly any tumor? Consider using more slides, or a different specimen

Mistake #12: assuming tumor homogeneity

- Different areas of a tumor, different metastases may have different mutations
- We ignore this by evaluating one part of a primary, or one of many metastases
- Evaluation of circulating tumor DNA may be a way to get a mutational evaluation of the entire tumor burden (for review see Heitzer, Clinical Chemistry, 2015)

ctDNA reduces sampling error and allows analysis of entire tumor burden: primary/mets/heterogeneous clones

Blood is the “window to the body”

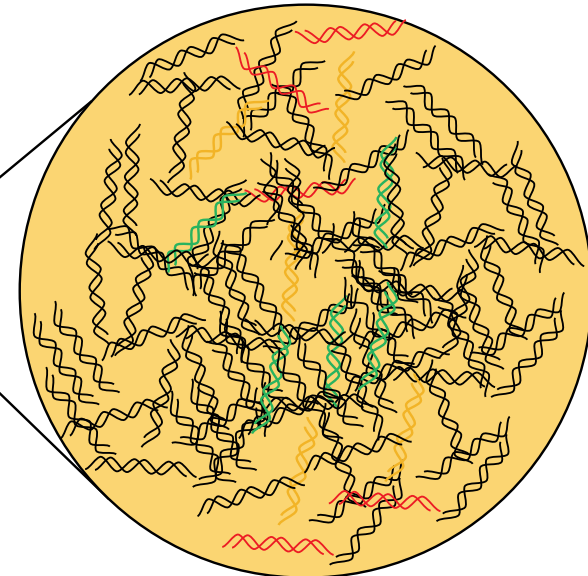
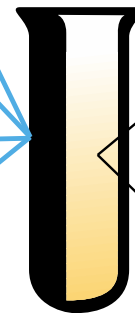

“Tumor5”


“Tumor3+4”


“Tumor1+2”


“Normal”

Molecular Biomarkers for the evaluation of colorectal cancer

- J Mol Diagn 2017, 19:187-225 (also published in AJCP, JCO, Arch Pathol Lab Med)
- Guidelines from ASCP, CAP, AMP, ASCO
- 21 guidelines
- Communicate with molecular lab and clinicians regarding how to best deal with these guidelines
- Clinical trials may have other requirements (such as, PTEN testing)

Selected guidelines

- “Metastatic or recurrent colorectal carcinoma tissues are the preferred specimens for treatment predictive biomarker testing and should be used if such specimens are available and adequate. In their absence, primary tumor tissue is an acceptable alternative and should be used.”
- For colon cancer, fairly high concordance between primary and metastases with respect to genetic changes.

Selected guidelines

- “Laboratories should establish policies to ensure efficient allocation and utilization of tissue molecular testing, particularly in small specimens.”
- For example, don’t cut through block and/or perform unnecessary IHC stains if diagnosis already established.
 - Consider up front unstained slides for molecular

Selected guidelines

- “Pathologists must evaluate candidate specimens for biomarker testing to ensure specimen adequacy, taking into account tissue quality, quantity, and malignant tumor cell fraction. Specimen adequacy findings should be documented in the report.”
- Communicate with molecular lab regarding requirements of various tests, such as amount of tumor, tumor percentage.

Future

- NGS on germline may make Lynch syndrome tissue work-up unnecessary
- NGS on tissue will probably replace most single gene assays
 - As number of targets increase (e.g. extended ras), NGS becomes more economical
- ? Up front NGS on germline and tumor for Lynch and EGFR pathway (no MLH1 methylation, though), can also see if hypermutator
 - Some conflict with Guidelines from ASCP, CAP, etc.
- Assays on circulating tumor DNA may replace biopsy of metastases (“liquid biopsy”)

