

**SEMESTER – IV**

**ZOO CC408 : Comparative Anatomy of vertebrates : Unit 3**

# **Comparative anatomy of aortic arches in vertebrates**

**Prof. (Dr) Shahla Yasmin**

**Department of Zoology**

**Patna Women's College**

**Patna University**

# Learning Objectives

The students will learn about:

- Origin and development of aortic arches
- Basic pattern of aortic arches
- Modifications in aortic arches in the vertebrates during evolution
- Comparative account of aortic arches among vertebrates

# Development of aortic arches

- Just when the heart is forming below the pharynx in the mid-ventral line, a blood vessel called ventral aorta also arises below the pharynx in the mid-ventral line.
- This ventral aorta grows backwards to join the conus of heart and also grows anteriorly and divides into two branches which course dorsally in the mandibular region and run backwards as paired dorsal aortae.

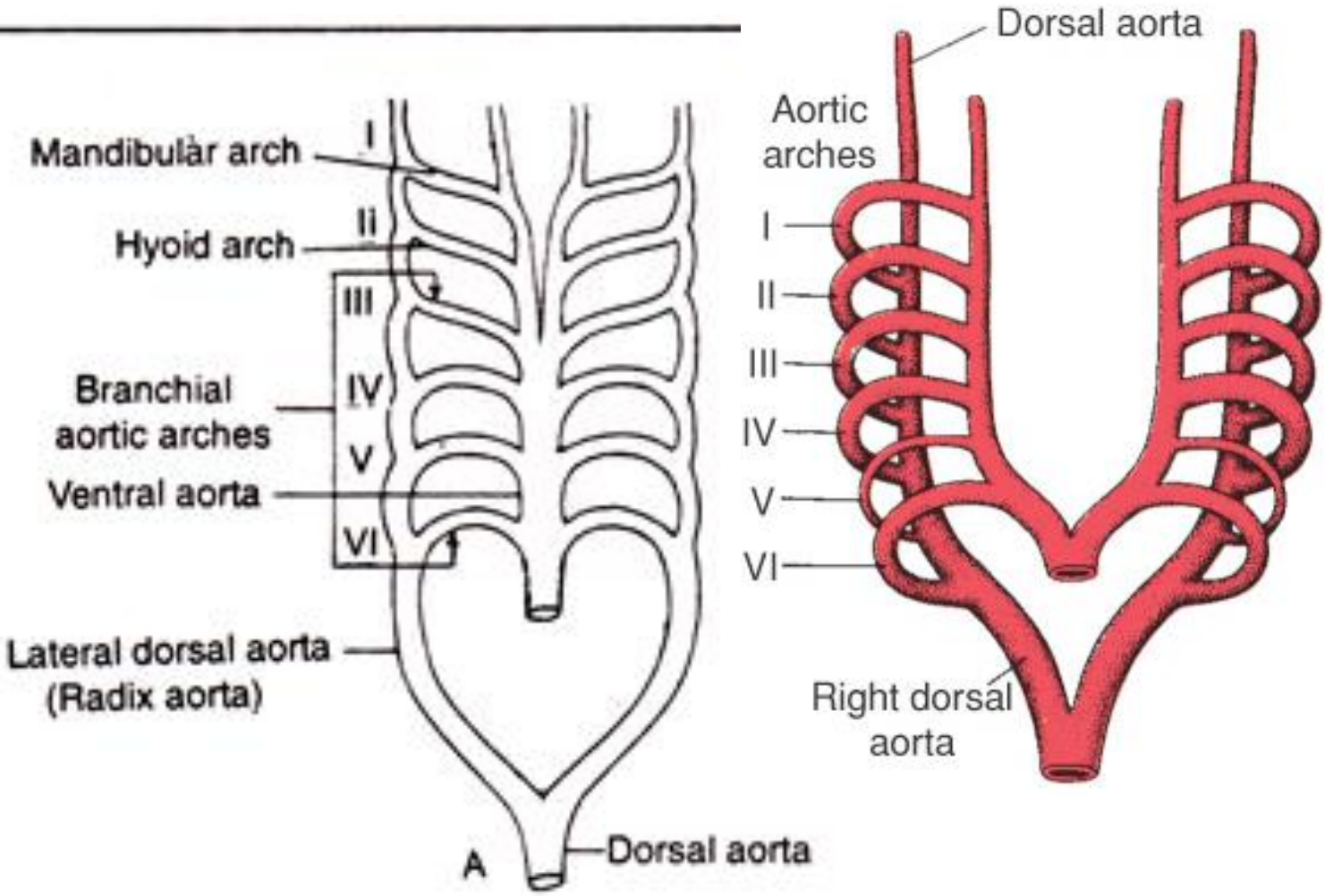
# Development of aortic arches

- The **paired dorsal aortae** from both sides **join** in the mid-dorsal line **to form** the **dorsal aorta proper**.
- Subsequently a number of **vessels** arise **connecting** the **ventral aorta** and the **paired dorsal aortae**, each coursing between adjacent pharyngeal pouches just anterior to the visceral cleft. These connections are **called aortic arches**.

# Embryonic aortic arches

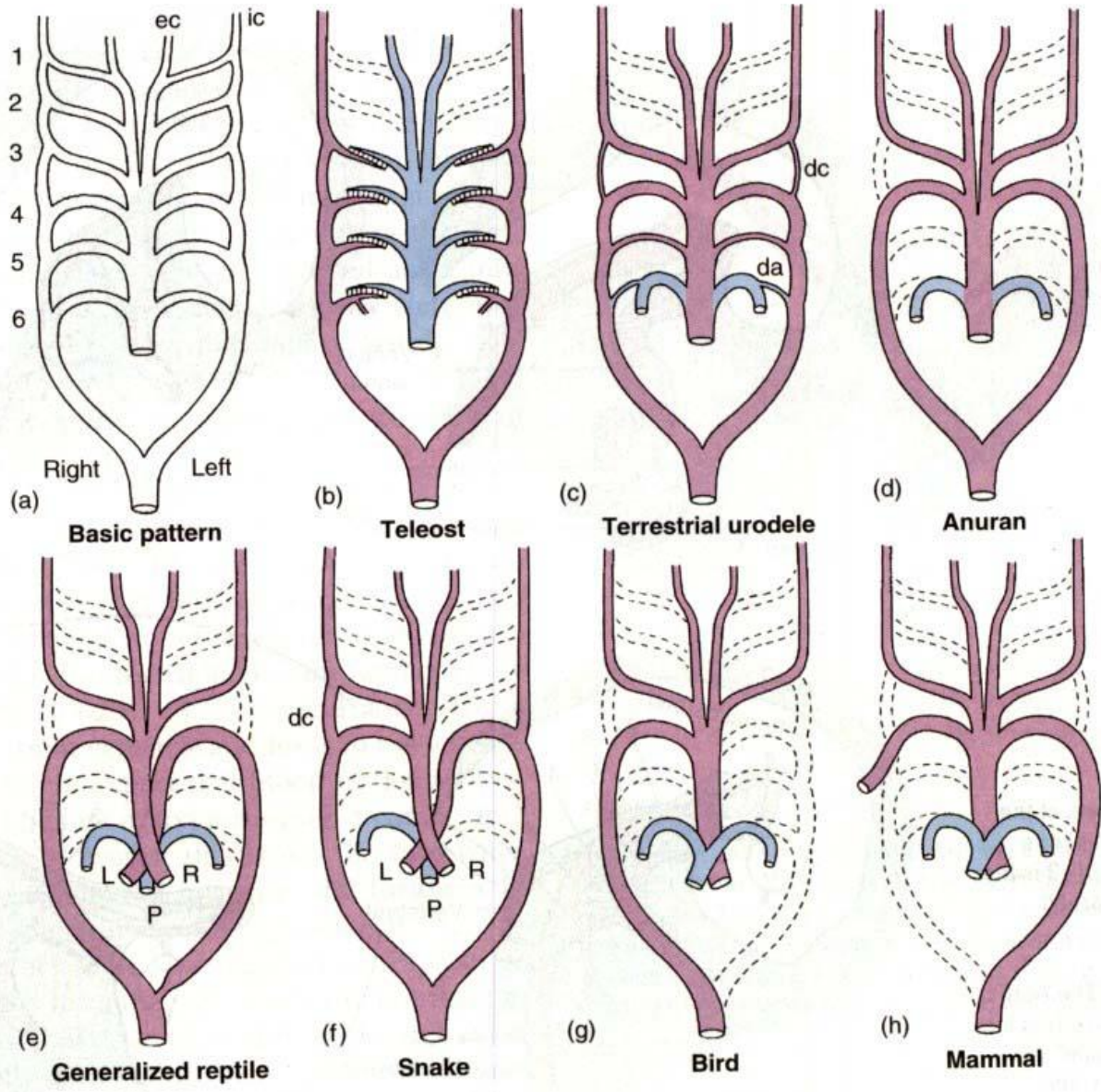
- During the embryonic stages, **Six pairs of aortic arches develop** in most gnathostomes and are named according to the name of the visceral clefts.
- These are designated by roman **numerals-I,II,III,IV,V and VI.**
- The first aortic arch is named **Mandibular arch.**
- The second aortic arch becomes **hyoid arch.**
- remainder called **third, fourth, fifth & sixth aortic arches**
- The heart pumps blood into the aortic arches via the ventral aorta. These aortic arches carry blood to the lateral dorsal aortae, from where it goes either to the head region or to the posterior region through dorsal aorta.

# Basic pattern of aortic arches



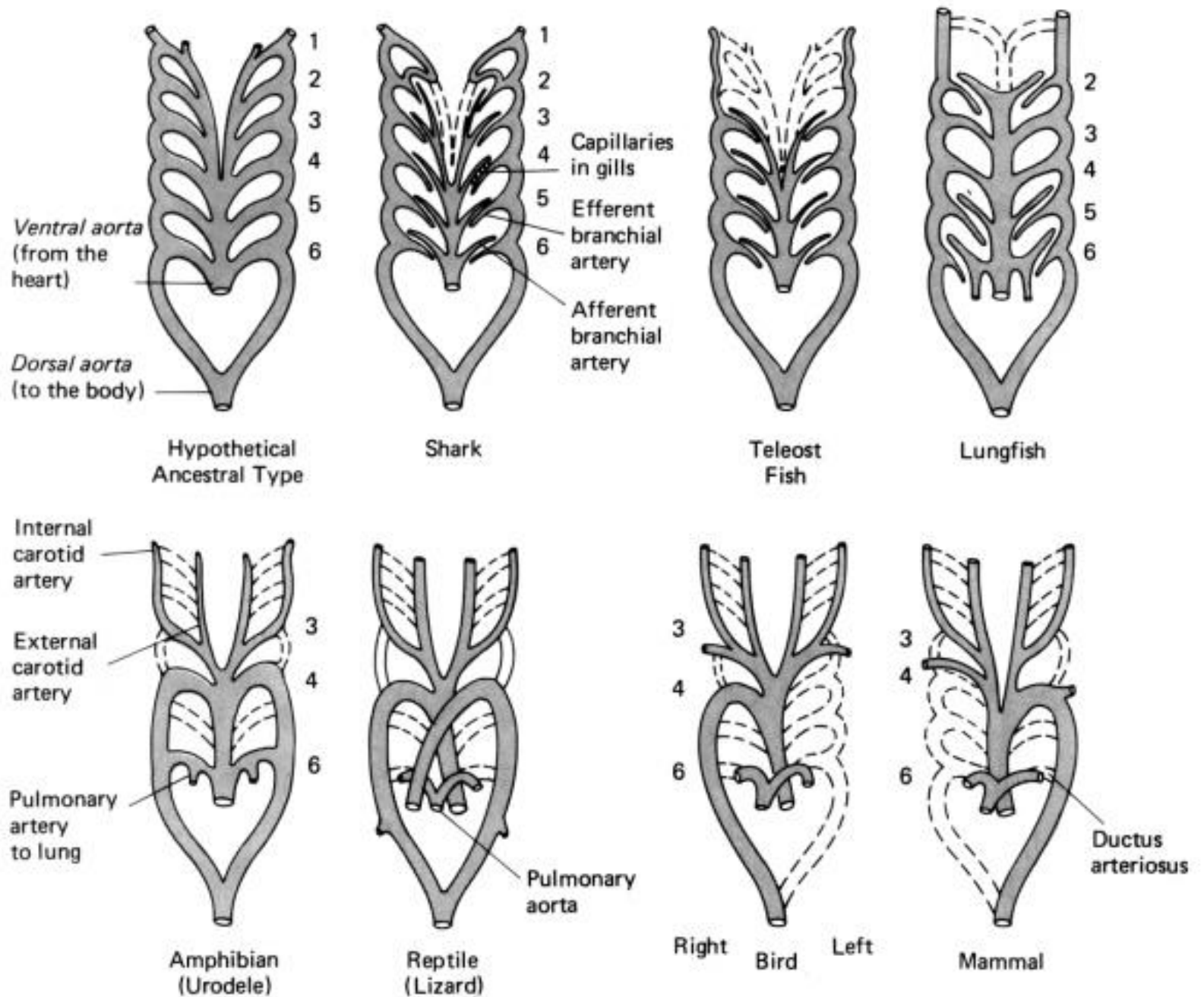
# Modification of aortic arches in different vertebrates

- The number of aortic arches is different in different adult vertebrates but they are built on the same fundamental plan in embryonic life.
- The differences in number of aortic arches are due to the complexity of heart circulation in the mode of living from aquatic (gill) to terrestrial (lung) respiration.
- There is a progressive reduction of aortic arches in the vertebrate series during evolution



Ventral perspective of aortic arches.

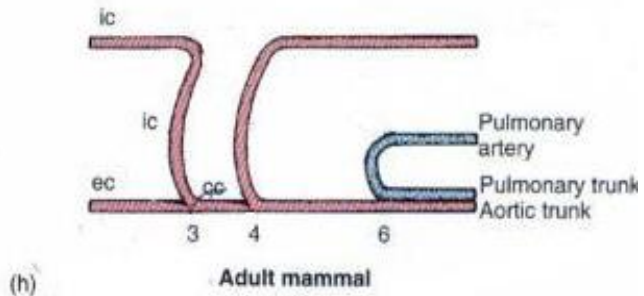
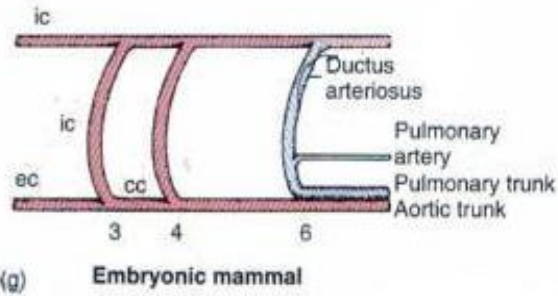
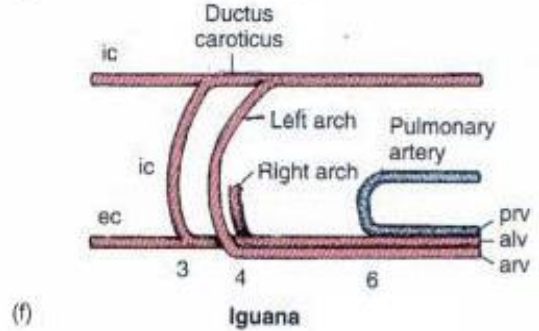
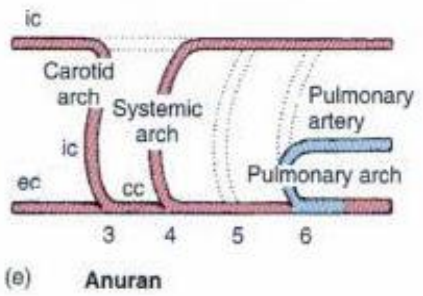
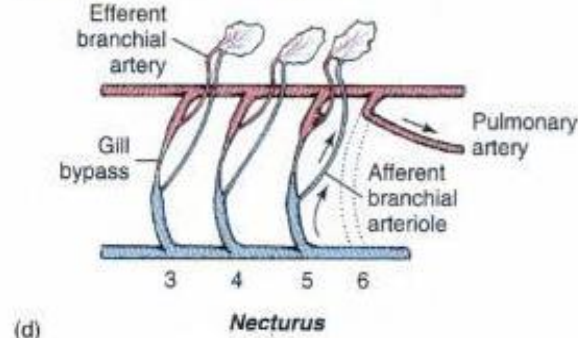
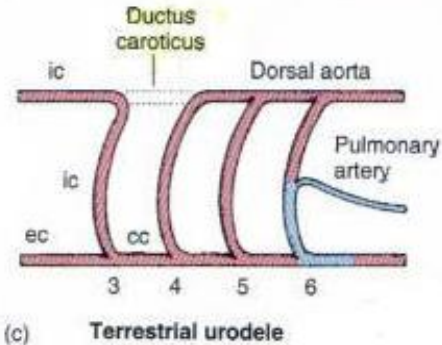
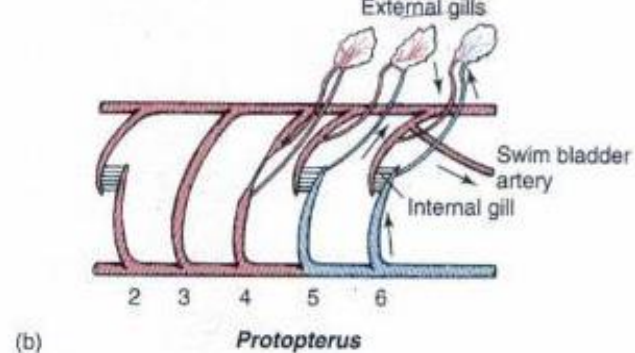
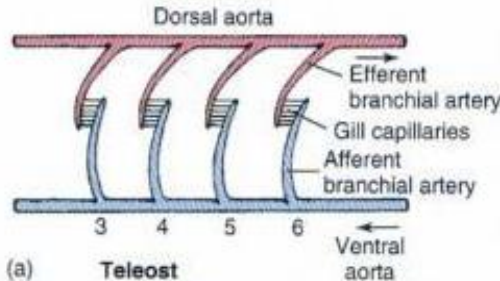




**Figure 5.8.** Diagrams of aortic arches in adult vertebrates (ventral views).

# Lateral view

## Left aortic arches.



# Aortic arches in fishes

- In fishes aortic arches break up into afferent and efferent branches because of the presence of internal gills.
- **In Elasmobranchs:**
- The primitive elasmobranchs, *Heptanchus* has only 7 pairs of aortic arches, where as Selachians have only 6 pairs of aortic arches.
- Scoliodon **has 5 pairs** of functional aortic arches; the first pair is reduced or disappears.
- **In Teleosts: four pairs of aortic arches remain**
- In most teleosts or bony fishes, the first and second aortic arches tend to disappear & thus only third, fourth, fifth & sixth pairs of aortic arches remain functional.

# In Lungfishes (Dipnoi)

- Third , fourth fifth & sixth aortic arches are functional.
- A set of pulmonary artery arises from the sixth aortic arches, near the dorsal aorta.
- In Dipnoi, III & IV aortic arches do not become interrupted by gill capillaries because gill lamellae are absent in this region, although IV arch bears an external gill. A Pulmonary arch sprouts from left and right VI aortic arch and supplies the swim bladder.

## Notes:

- **In Elasmobranchs**, each aortic arch has one afferent artery & two efferent arteries in each gill. **In teleosts**, each arch has one afferent & one efferent artery in each gill.
- In tetrapods, the arches do not break up into afferent and efferent branches.

# Aortic arches in amphibians

- Due to presence of lung as the main respiratory organ, the importance of gills is diminished.
- **In urodeles:**
- Four pairs of aortic arches (III to VI) are functional in general.
- V pair is present in reduced state, but absent in *Siren*, *Amphiuma*.
- III pair forms the carotid artery & the fourth pair forms the systemic arches.
- The radix or lateral aorta between third & fourth arches may persist as a vascular connection called **ductus caroticus**.
- VI pair forms the pulmonary arteries which supply blood to skin and lungs.
- VI arch retains connection with radix aorta, called **ductus arteriosus**

# Aortic arches in amphibians

- **In Anurans:**
- During embryonic life, III, IV, V and VI arches are present. III, IV and V supply the external gills during the 5-6 days these gills function. Thereafter, they supply internal gills until metamorphosis. Pulmonary arteries sprout from arch VI for supplying the developing lungs.
- At metamorphosis, with loss of gills, I, II & V aortic arches disappear altogether. A stapedia branch represents the remnant of II aortic arch
- Thus three pairs of aortic arches (III - carotid, IV-systemic & VI-pulmonary) are functional.
- **Carotid arch** takes oxygenated blood to head region.
- **Systemic arch** on each side continues to dorsal aorta to distribute blood elsewhere except head & lung.
- **Pulmonary arch** supplies venous blood exclusively to lungs for purification.
- The **ductus caroticus & ductus arteriosus** are usually absent.

# Aortic arches in reptiles

- Reptiles are fully terrestrial vertebrates in which gills disappear altogether and are replaced by lungs.
- Only three functional arches (**third, fourth & sixth**) are present. Ventral aorta splits into three trunks, two arising from the right side of the ventricle and one from the left ventricle
- **III aortic arches** along with the radix of Dorsal Aorta (lateral dorsal aorta) of that side becomes internal carotid arteries.

# Aortic arches in reptiles

- **IV aortic arch** on the right side establishes connections with the Right systemic arch arising from left ventricle, carrying oxygenated blood .
- **IV aortic arch** on the left side establishes connections with the left systemic arch arising from right ventricle.
- **VI arches** give rise to pulmonary arteries which join the Pulmonary trunk arising from the right ventricle carrying deoxygenated blood to the lungs for purification.



# Exceptions in reptiles

- Generally ductus caroticus & ductus arteriosus are absent but in certain snakes & lizards (**Uromastix**) the ductus caroticus is present and in some turtles & **Sphenodon**, the ductus arteriosus is present in Alligator and some turtles.
- In some snakes, the left III aortic arch disappears, but ductus caroticus persists throughout life and blood reaches the left internal carotid artery and brain through this route

# Birds & mammals

- In both Birds & mammals the ventricle is completely divided. Heart is four chambered.
- Six aortic arches develop in embryo, but only 3 arches (**third, fourth & sixth**) persist in the adult. Ventral aorta splits into two, **systemic and pulmonary aortae**
- **In birds the IV aortic arch on the right side** joins the systemic aorta arising from left ventricle and then joins the radix of dorsal aorta to become the dorsal aorta proper. IV arch on left side may give rise to subclavian.
- **In mammals, the IV aortic arch on the left side** joins the systemic aorta arising from left ventricle and then joins the radix of dorsal aorta to become the dorsal aorta proper. IV arch on right side becomes subclavian.
- **Third arch with radix** of that side becomes internal carotid arteries.

# In birds

- In embryos, **ductus arteriosus** is present on both sides, left one persists for short time, **right one acts as shunt** between pulmonary and systemic aortae, becomes occluded at birth when lungs begin to function. A **ligamentum arteriosum** finally remains.
- Sixth arch gives rise to pulmonary arteries which join single pulmonary trunk taking deoxygenated blood from right ventricle to the lung.

# In mammals

- In embryos, **ductus arteriosus** is present on both sides, right one persists for short time, left one acts as shunt between pulmonary and systemic aortae, becomes occluded at birth when lungs begin to function. A **ligamentum arteriosum** finally remains
- Remains of **V arch** is seen in some embryos
- In some mammals dorsal part of **II arch** persists as stapedial artery with which the external carotid artery connects
- Remains of **I arch** may contribute to mandibular artery

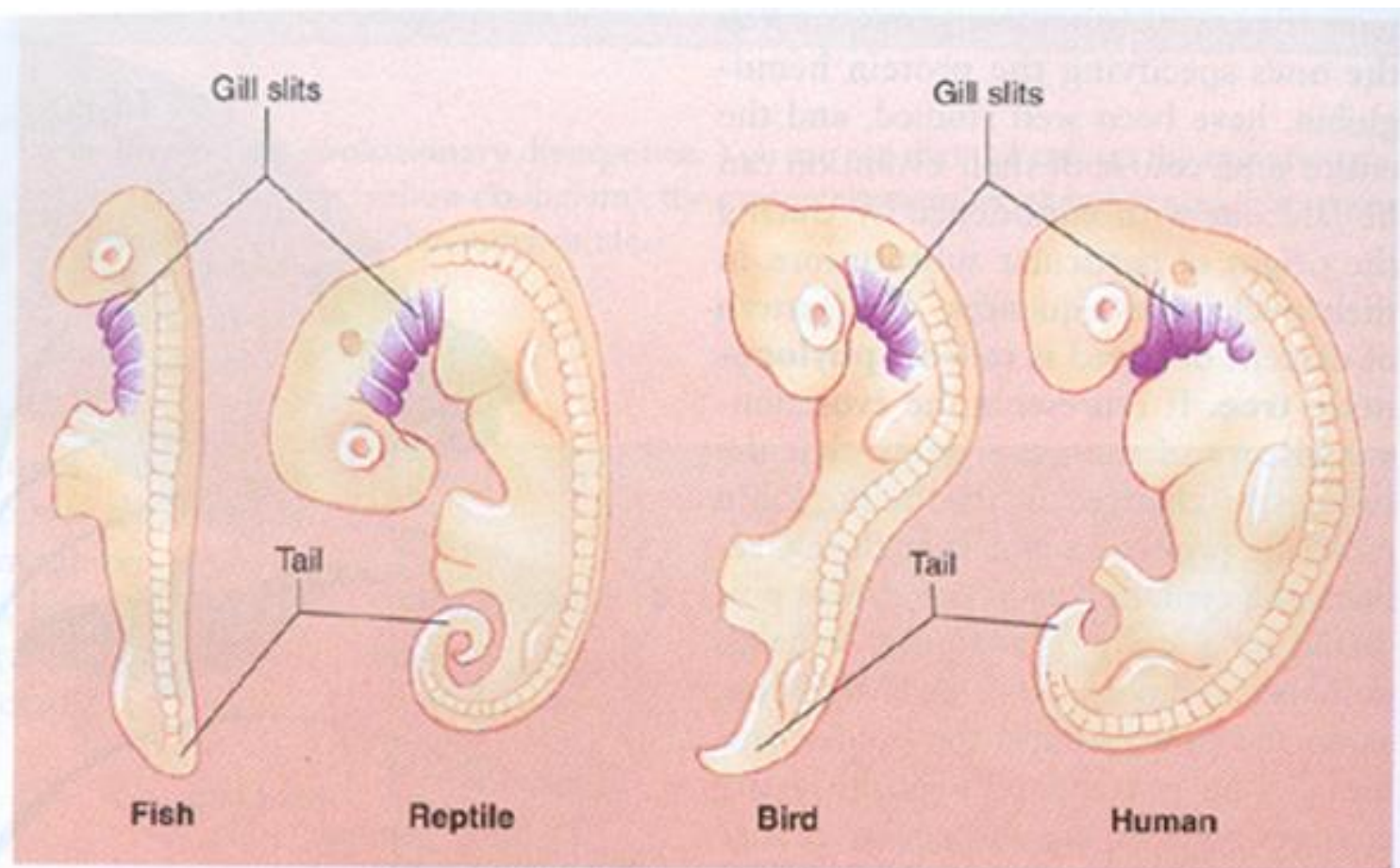
# In mammals

- Sixth arch gives rise to pulmonary arteries which join single pulmonary trunk taking deoxygenated blood from right ventricle to the lung.

## **Conclusion:**

- Discussing the aortic arches in these vertebrate groups, it is clear that they have originated from a common ancestral stock and their embryonic condition of aortic arches supports the

**recapitulation theory of Haeckel**



**FIGURE 20.18**

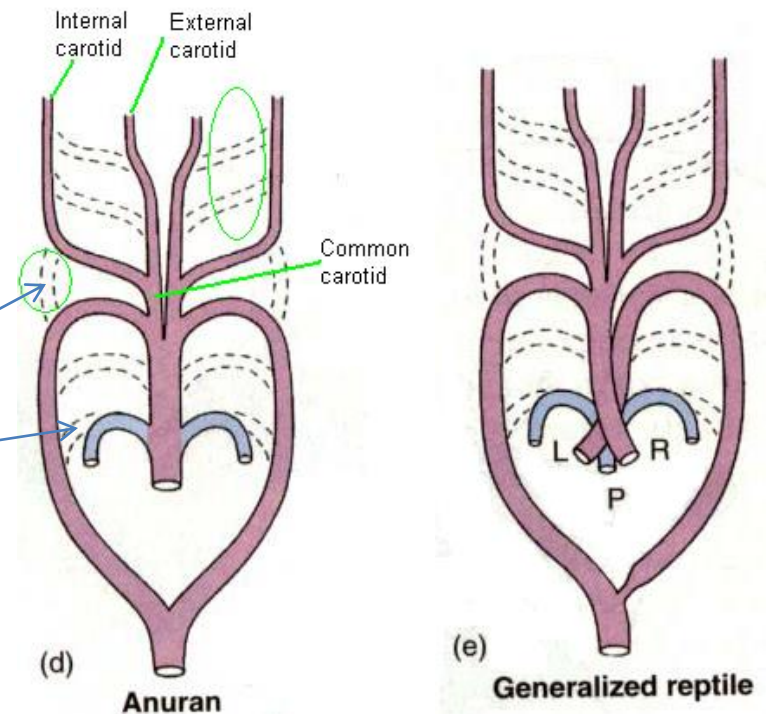
**Our embryos show our evolutionary history.** The embryos of various groups of vertebrate animals show the features they all share early in development, such as gill slits (*in purple*) and a tail.

# Aortic Arches (Summary)

- Elasmobranch
  - I arch is lost
- Teleost
  - I and II arches lost
- Lungfish
  - I and II arches lost
  - Pulmonary artery arises from VI arch
- Tetrapods
  - Pulmonary artery arises from VI arch
  - V arch lost

# Tetrapod Aortic Arches

- I and II arches lost
- Dorsal segment dropped between III and IV arches, i.e.
  - Ductus caroticus lost
  - **Connection of sixth arch with lateral dorsal aortae lost**
  - Ductus arteriosus lost

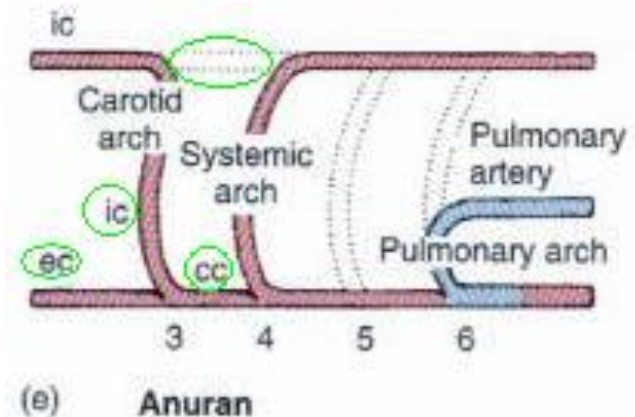


Adult aortic arches



# Tetrapod Aortic Arches (cont.)

- III arch extends to internal carotids
  - Carotid arch
- Ventral aorta extension
  - External carotid
- Common carotid at base between III and IV
- V arch lost
- Dorsal segment of VI arch lost



Aortic arches, internal carotid (ic), external carotid (ec) and common carotid (cc).

# Aortic Arches

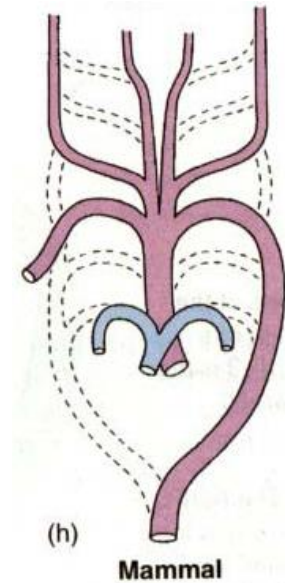
- Urodele
  - V arch present,
  - Ductus caroticus present
  - Ductus arteriosus- dorsal segment of VI arch present
- Reptiles
  - I and II arches lost
  - Ductus caroticus lost
  - V arch lost
  - Ductus arteriosus lost

# Bird Aortic Arches

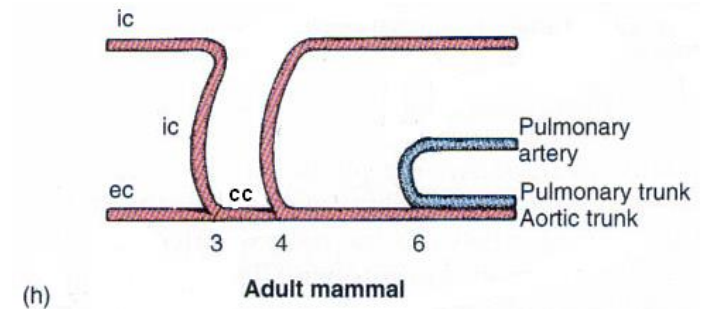
- III, IV, V, & VI retained embryonically
- In Adults- I and II arches dropped
- III becomes carotid arch
- IV becomes systemic arch
- V arch lost
- Right portion of IV aortic arch is retained and left is lost (opposite to mammals)
- So, Birds have right systemic arch

# Mammalian Aortic Arches

- III, IV, V, & VI retained embryonically
- In Adults- I and II arches dropped
- III becomes carotid arch
- IV becomes systemic arch
- V arch lost
- Dorsal segment of VI arch lost
  - Retained embryonically- ductus arteriosus (becomes ligamentum arteriosum)



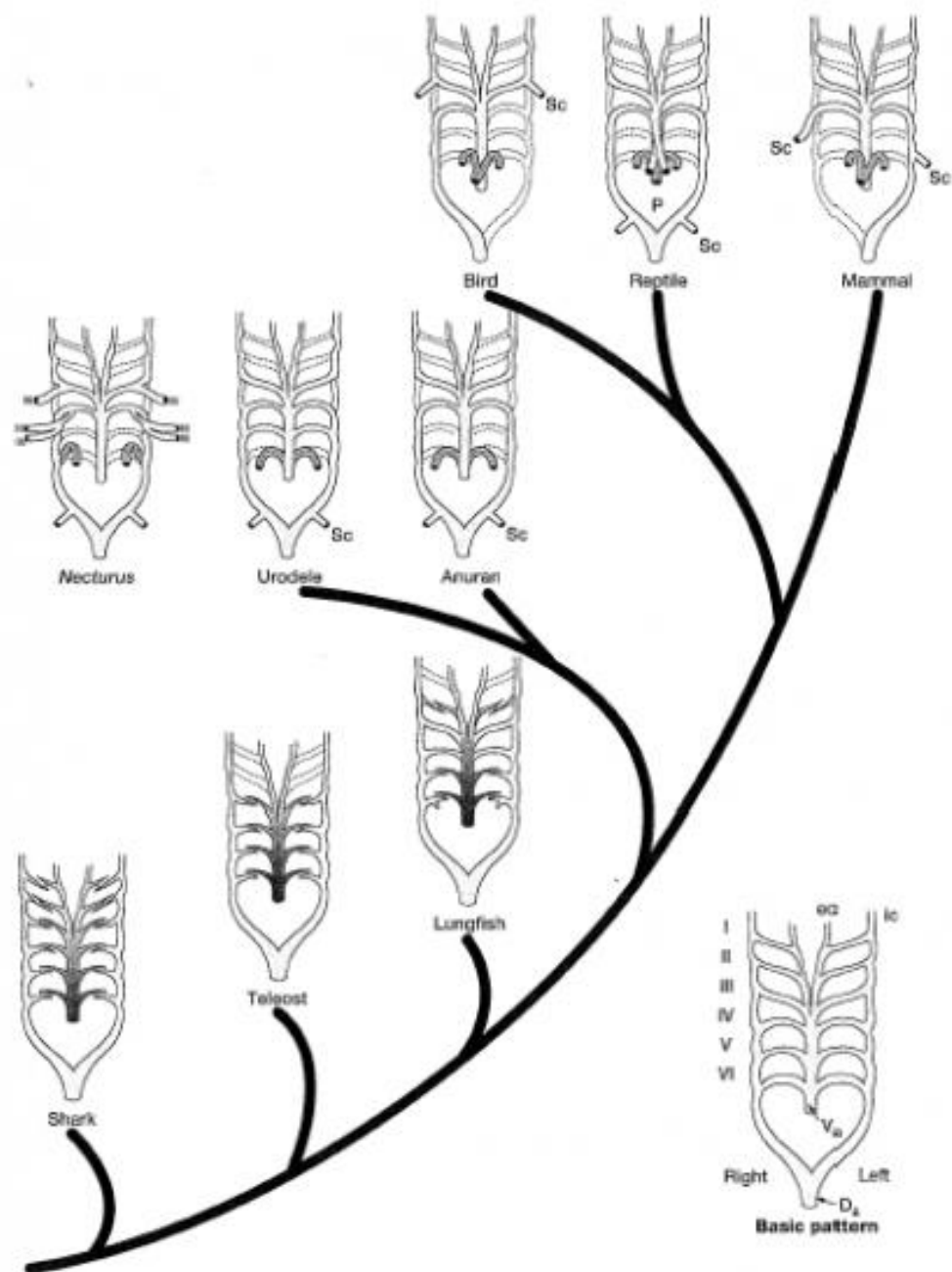
Adult aortic arches.



Left aortic arches.

# Circulation At Birth

- Placenta shuts down
- Umbilical vein collapses
- Interatrial aperture closes (fossa ovalis)
- Ductus arteriosus closes (ligamentum arteriosum remains )
- Deoxygenated blood now enters right ventricle, pulmonary arteries, and continues to lungs



**FIGURE 12.19** Evolution of aortic arches. Viewed from the ventral surface, the basic six-arch pattern includes a ventral aorta, paired aortic arches, and paired dorsal aortae. Selective loss or modification of this underlying pattern produces the derived aortic pattern of adult vertebrates. Vertical lines on the aortic arches represent gills. Dashed vessels are lost from the basic pattern in the adult. Abbreviations: dorsal aorta ( $D_a$ ), external carotid (ec), internal carotid (ic), paired dorsal aorta (Pa), subclavian (Sc), ventral aorta ( $V_a$ ).

# References

- Kardong, K.V. (2005) *Vertebrates' Comparative Anatomy, Function and Evolution*. IV Edition. McGraw-Hill Higher Education
- Kent, G.C. and Carr R.K. (2000). *Comparative Anatomy of Vertebrates*. IX Edition. The McGraw-Hill Companies