

Available online at www.sciencedirect.com

journal homepage: www.elsevier.com/locate/sdj

Case report

Complete denture copy technique—A practical application



Steven Soo^{a,*}, Ansgar C. Cheng^{a,b,c}

^aSpecialist Dental Group, Mount Elizabeth Hospital, Republic of Singapore

^bNational University of Singapore, Republic of Singapore

^cUniversity of Hong Kong, Hong Kong

ARTICLE INFO

Article history:

Received 24 September 2013

Received in revised form

2 December 2013

Accepted 3 December 2013

Keywords:

Copy denture

Replica technique

Complete dentures

ABSTRACT

The copy denture technique is a misnomer for the clinical and laboratory procedures involved in making complete dentures that replicate most of the features of the original prosthesis. The aim is to replicate the good features of an otherwise successful prosthesis that now requires replacement and to alter the poor features and so it is strictly speaking not a copy. There are many purported advantages to this technique which include reduced treatment time, increased patient acceptance especially for the elderly who may not adapt so well to a new prosthesis, maintenance of tooth position and vertical dimension. A typical case is presented illustrating the clinical stages involved with a discussion of the merits of this technique.

© 2013 Published by Elsevier B.V.

Introduction

The copy denture technique is not a single technique, but a variety of techniques designed to replicate complete dentures [1–3]. A range of techniques both clinical and laboratory exist which vary in their ability to “copy” a prosthesis. If one thinks of a denture as having three surfaces—occlusal, polished and fit surface—then it becomes easier to decide which of these one should copy or alter as the clinical situation requires.

Of course prior to constructing a new prosthesis, the clinician should have a good indication for using this treatment modality based on an accurate diagnosis of the problem and reason for replacement. An exact copy of a denture may be indicated if the patient is entirely satisfied with the prosthesis and there are no errors of a technical variety that impact clinically.

For example, if the denture material has simply degraded or has fractured and cannot be repaired satisfactorily then a

direct copy may be indicated. A patient may request a spare set of dentures.

However, it is more common to see dentures in which one or more surfaces can be improved by relining or replacing worn teeth. The polished surface is probably the least often cited requiring alteration and the one the patient will notice the most if changed. An exception to this might be if speech is not satisfactory changes are need to the palatal contour to aid pronunciation of certain sounds. Therefore, by definition, if the dentures are modified in any way it is not a “copy” and hence the term “replica” might be more suitable.

Case study

Mr N was a 49 year old male who presented with a fractured upper complete denture. His present dentures were made 3

*Correspondence to: Specialist Dental Group, Mount Elizabeth Medical Centre, 3 Mount Elizabeth, #08-08, Singapore 228510, Republic of Singapore. Tel.: +65 6734 9393; fax: +65 6733 6032.

E-mail address: drsoo@specialistdentalgrou.com (S. Soo).

years ago following the loss of all his teeth i.e. an immediate denture. He was otherwise very happy with the appearance, comfort and function and wanted a replacement set without too many changes that others might notice.

Clinical findings

The upper and lower arches were U-shaped with well-formed minimally resorbed ridges showing signs of scalloping where the natural teeth were present. The ridges were firm and the mucosa healthy (Figs. 1-3).

Current dentures

The upper and lower dentures were stable, retentive and well-supported. With both dentures in situ the appearance, centre line and occlusal vertical dimension (OVD) were acceptable (Fig. 4). The occlusal plane and incisal level were satisfactory. There was a partial fracture in the midline of the upper denture palatally (Fig. 8).

Examination of the static occlusion showed bilateral simultaneous contacts in maximum intercuspation (MI) which was coincident with retruded contact position (RCP). Examination of the dynamic occlusion showed that in protrusion there were only posterior contacts with no

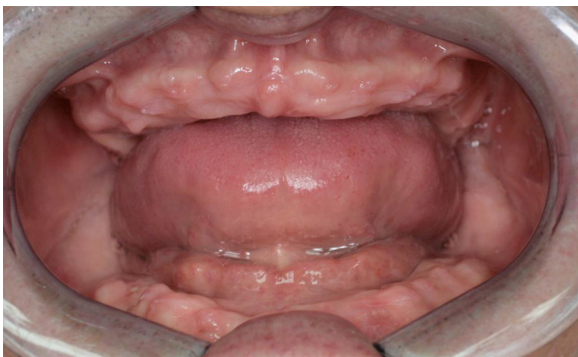

Fig. 1 – Edentulous ridges at approximate final vertical opening.

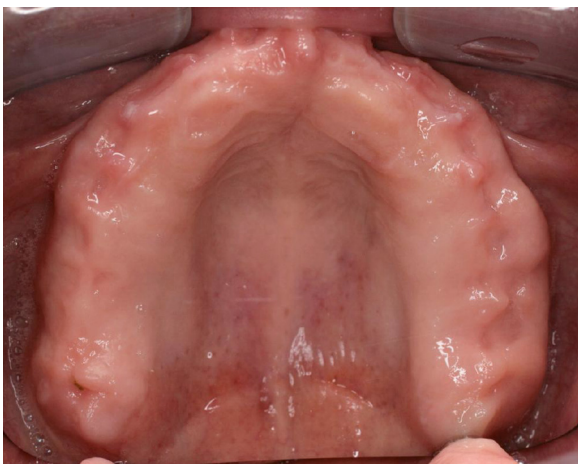


Fig. 2 – Upper arch showing uneven resorption.

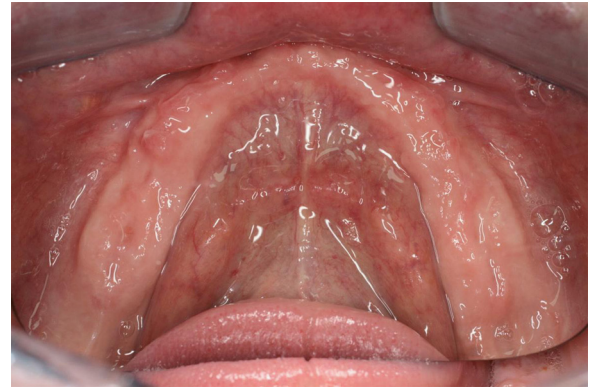


Fig. 3 – Lower arch.

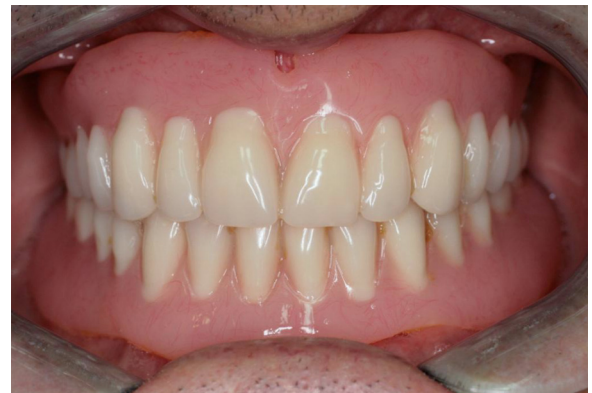

Fig. 4 – Current dentures in ICP.

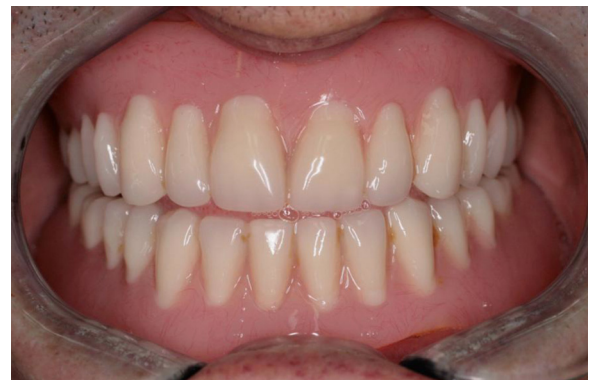

Fig. 5 – Current dentures in protrusion.

anterior contact (Fig. 5). Lateral excursions were canine guided and there were no non-working side (NWS) contacts (Figs. 6 and 7).

Diagnosis

The following diagnoses were made:

1. Fractured upper denture and stained lower denture (Figs. 8 and 9).
2. Poor occlusal scheme not ideal for removable complete prostheses.

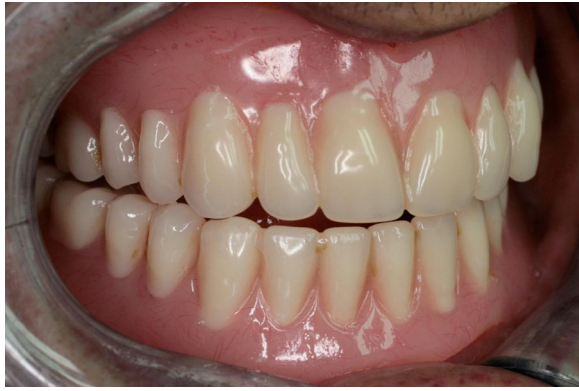

Fig. 6 – Current dentures in right lateral excursion.

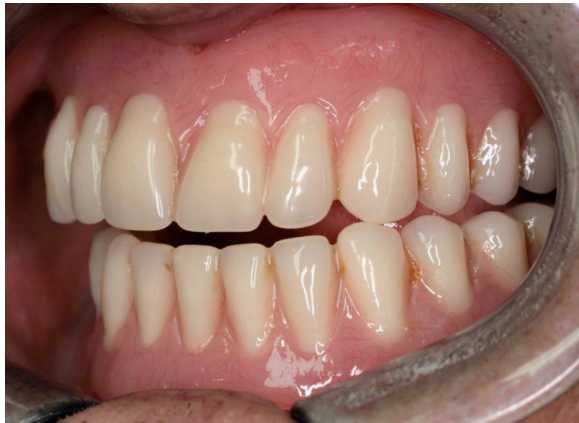

Fig. 7 – Current dentures in left lateral excursion.

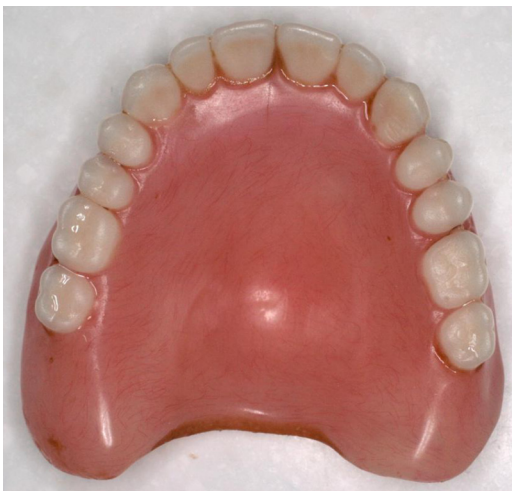

Fig. 8 – Current upper denture showing fracture palatal to upper centrals.

The treatment objective was to replicate the bucco-lingual tooth position and maintain the OVD. After 3 years post-extraction a degree of bone resorption was expected and hence a new fitting surface was indicated. The occlusal scheme was unsatisfactory and a balanced occlusion and articulation was to be developed necessitating a change in

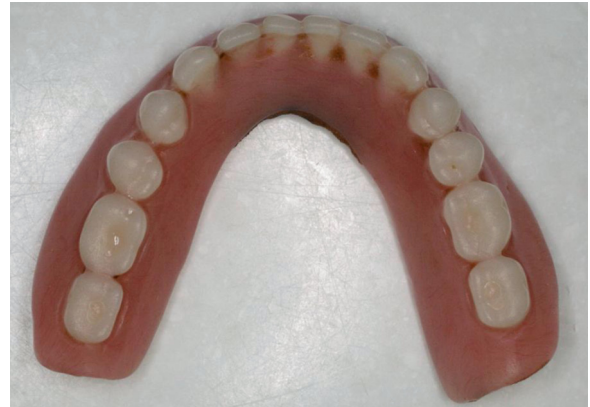

Fig. 9 – Current lower denture showing staining from smoking.

the occlusal surface. The appearance could be improved with minor changes in the tooth arrangement and a better mould using higher quality teeth. Interestingly the patient had no complaints pertaining to the fit or occlusal surface, but from a clinical and technical perspective improvements could be made.

Treatment plan

The treatment plan is outlined below:

1. Repair existing upper denture to be kept as a spare.
2. Construct new upper and lower dentures using copy technique to replicate tooth position and polished surfaces, but allow for minor improvements to mould, shade and arrangement.
3. Take wash impressions to improve accuracy of fit surface.
4. Ensure balanced occlusion and articulation at the same OVD.

Treatment

1. Make clear acrylic copies of existing dentures in laboratory silicone (Figs. 10–12).
Heavy bodied silicone is rigid enough to be used without additional support. However, if extra rigidity is required then two large stock trays for each denture can be used to contain and support the impression material.
2. Take wash impression, after reduction of any undercuts, with ZnOE using open mouth technique (Figs. 13 and 14). The acrylic copies are effectively used as close-fitting special trays. They must have the undercuts removed prior to the wash so that once poured in die-stone, the denture can be removed without damage to the model. A fluid wash impression material is used to ensure a thin impression which will not significantly increase the OVD and also capture the denture bearing area accurately. Pressure relief holes in the palatal vault will aid escape

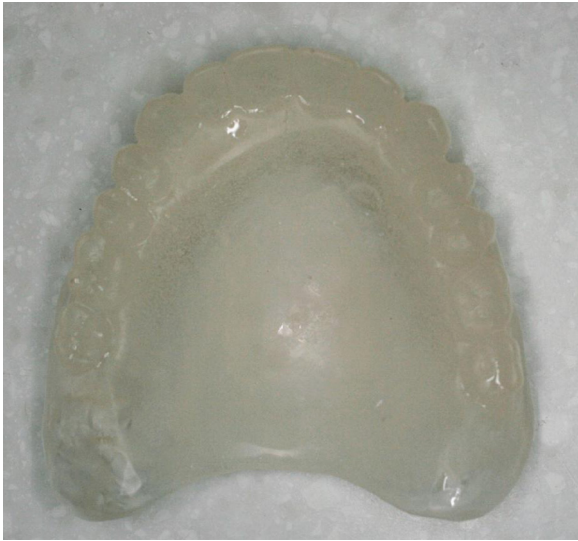

Fig. 10 - Acrylic copy of upper denture.

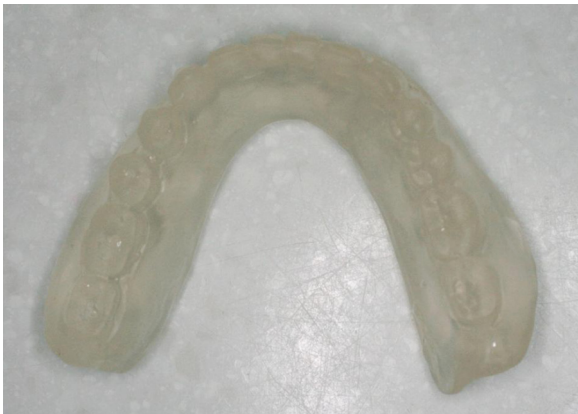

Fig. 11 - Acrylic copy of lower denture.

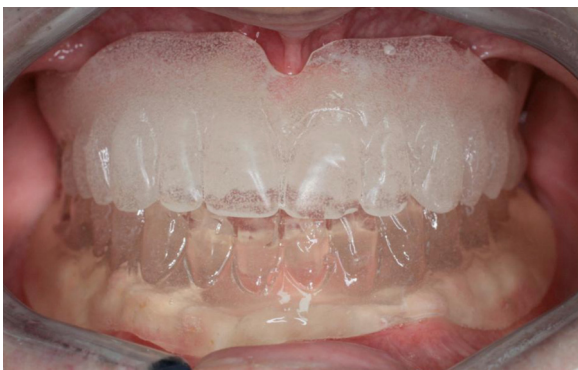

Fig. 12 - Acrylic copies in situ.

of material, reduce pressure build up and ensure a thin impression.

An open mouth technique is clinically easier to perform than a closed mouth technique the advantage of which it is thought will minimise changes in the OVD. In practice it is very difficult for the patient to occlude with precisely the correct force to avoid changes in the vertical dimension. Border moulding is also easier with the open mouth technique. If the OVD is recorded and checked at each

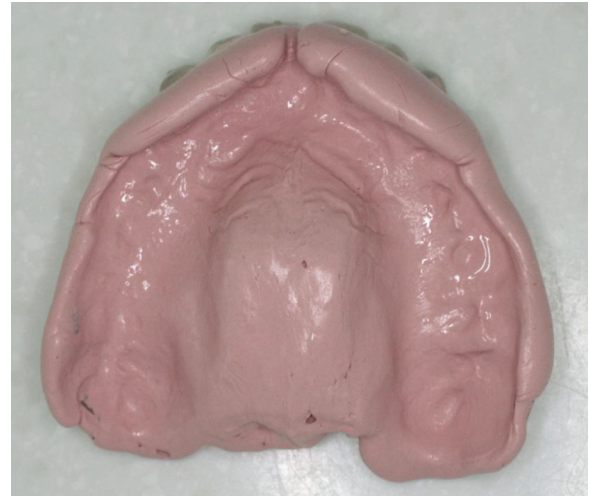

Fig. 13 - ZnOE wash in upper copy.

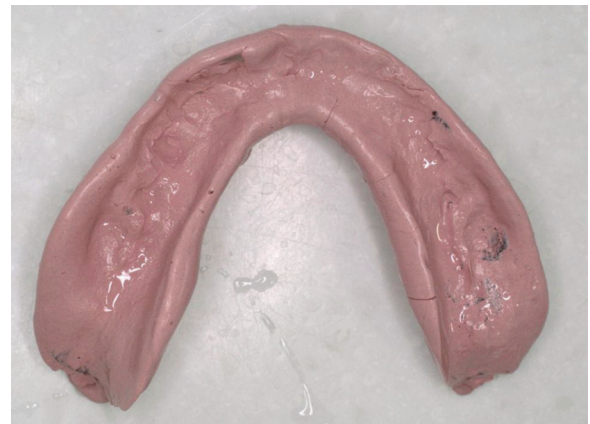

Fig. 14 - ZnOE wash in lower denture.

stage then as the occlusal surface is being changed, it is easy to keep control of this dimension.

3. Take jaw registration at same visit as step 2. Maintain the same OVD. Silicone jaw registration material to be used (Fig. 15).

The acrylic copies serve a double purpose i.e. that of a registration block as well as special tray. If the OVD has increased then it will have to be reduced with an acrylic bur and balanced occlusal contact developed. The choice of jaw registration material is up to the clinician.

4. Facebow record and mounting on Kavo semi-adjustable articulator.

The need to take a facebow record will necessitate that the jaw registration material will allow separation of the dentures. Silicone will allow this to be done cleanly and easily.

5. Tooth-try in wax to verify tooth position and OVD (Figs. 16 and 17).

Tooth mould and shade information can be taken from the existing dentures. However, the patient may wish to take this opportunity to change the aesthetics. The bucco-lingual tooth position was replicated by removing and replacing one tooth at a time. If bucco-lingual tooth position is critical then a buccal putty index can aid

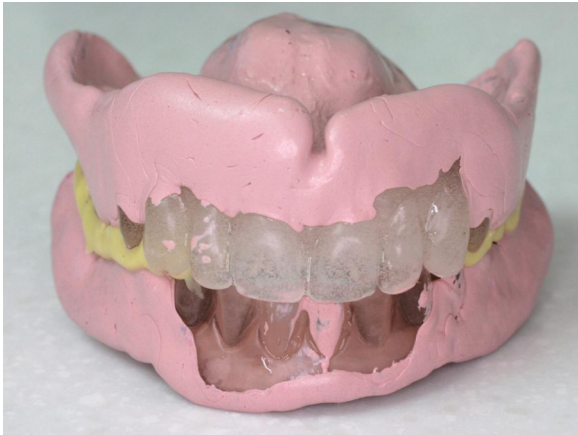

Fig. 15 - Jaw registration with silicone material.

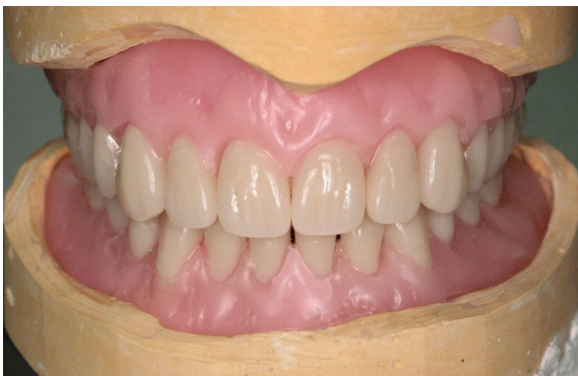

Fig. 16 - Tooth try-in on articulator.

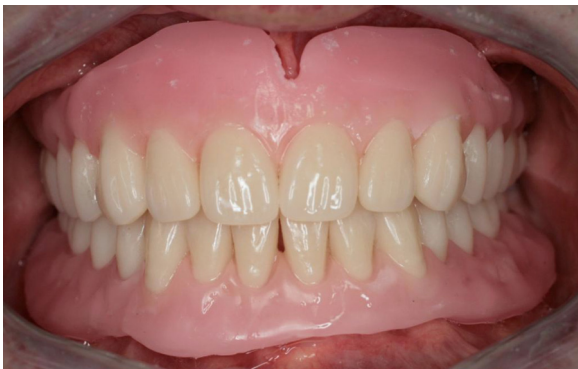

Fig. 17 - Tooth try-in in situ.

accurate tooth placement. In this case the contours of the polished surfaces were not critical and were replicated by hand carving the wax.

6. Finish in pink veined high impact acrylic and delivery of dentures (Figs. 18-24).

Discussion

The technique presented above was appropriate and successful in this case. Its use depended upon a correct assessment of the problem that needed addressing. If not applied correctly then it would be all too easy to perpetuate a

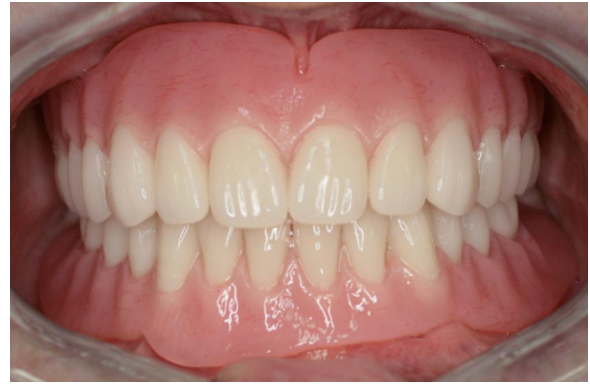

Fig. 18 - Finished dentures in situ.

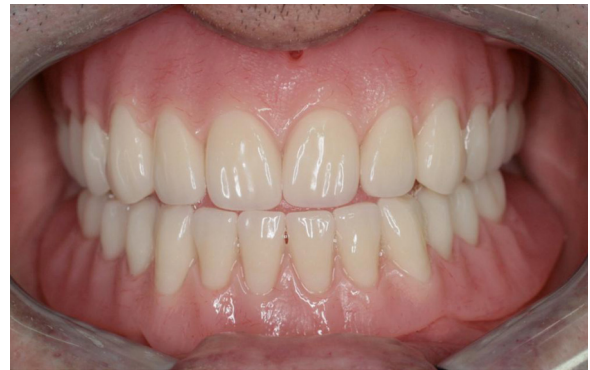

Fig. 19 - New dentures in protrusion.

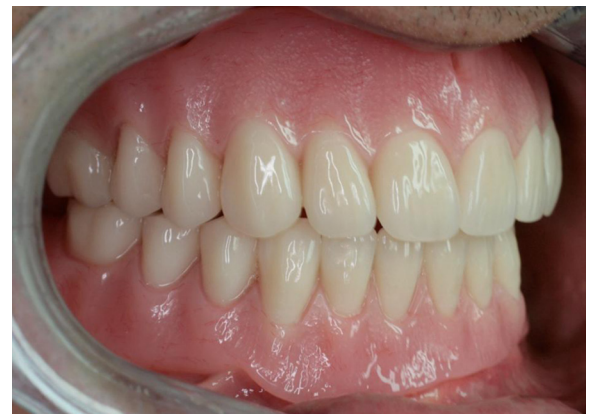

Fig. 20 - New dentures in right lateral excursion.

deteriorating denture situation. The technique has often been used incorrectly when the clinician is unable to correctly diagnose the denture fault with which the patient presents. In these types of cases, copies can be made of the dentures for trial modifications, such as extending borders, adding post-dams, balancing occlusion and increasing or reducing OVD. The patient's original dentures have not been altered in any way and so nothing is lost. Once the patient is happy with the modifications, then this is copied to make a definitive denture.

There are several ways to make copies of dentures. Metal denture flasks are probably the best option. Alginate is mixed and loaded into one half and the denture is pressed into it so that the alginate is level with the flange. Once set a second

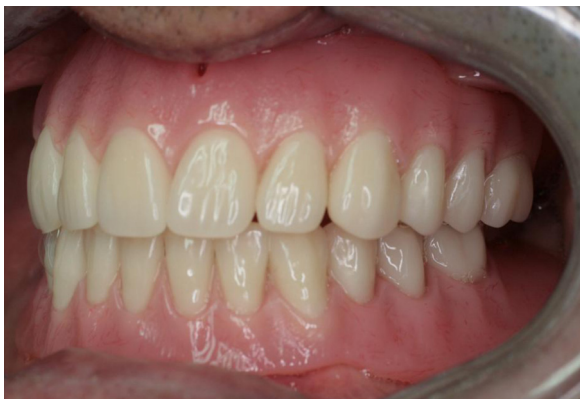

Fig. 21 – Balancing contacts on the left in right lateral excursion.

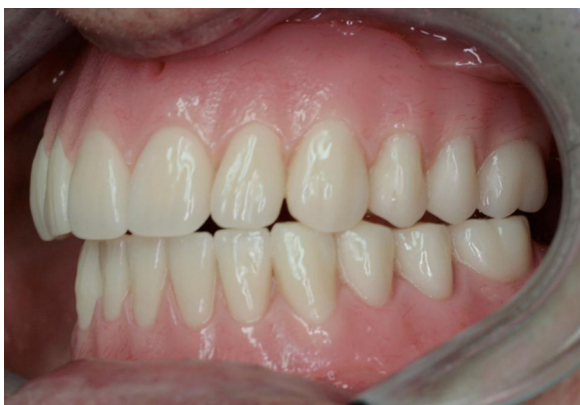

Fig. 22 – New dentures in left lateral excursion.

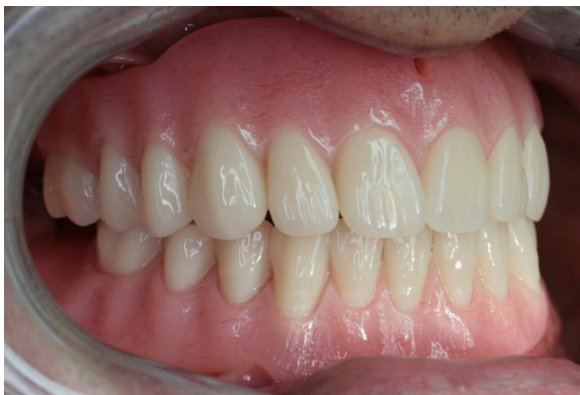

Fig. 23 – Balancing contacts on the right in left lateral excursion.

mix of alginate is mixed and loaded into the other half of the flask and the two halves closed. In order to avoid trapping air into the mould, alginate is preloaded into deep depressions or undercuts using a finger. Once set the flask is opened and the denture retrieved. Holes are cut into the heels of the mould for pouring cold cure acrylic resin.

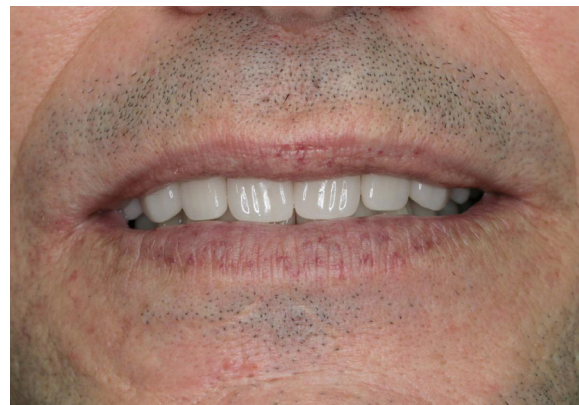

Fig. 24 – A satisfied patient.

If the patient is able to leave the dentures at the laboratory for a period then reversible laboratory hydrocolloid can be used. In the clinic, a heavy-bodied silicone putty is simplest with or without support using metal stock trays.

Replicating immediate dentures preserves valuable information on tooth position and vertical dimension without having to resort to biometric guidelines applied to the “blank canvas” of edentulous ridges. There is some saving in clinical time at the wash and jaw registration phase which are done at the same time rather than as two separate stages. There can also be time saved at the try-in stage if tooth position is not significantly altered.

The term replicating technique is more accurate than copy technique as there are few situations where an exact copy is what is required. Applied appropriately, it is a useful addition to the prosthodontists treatment choices.

Conclusion

A denture replication technique was used to make a new set of complete dentures. Tooth position and vertical dimension were copied and alterations to the fit surface, to account for resorption and the occlusal surface, to provide balanced occlusion and articulation, were made.

Correct application of this technique can reduce both clinical and laboratory time, but depends on an accurate diagnosis of the problem and an understanding of the advantages and limitations of this method.

REFERENCES

- [1] R.M. Basker, J.C. Davenport, H.R. Tomlin, *Prosthetic Treatment of the Edentulous Patient*, First edition, The Macmillan Press Ltd., London and Basingstoke, 1981.
- [2] J.A. Hobkirk, *A Colour Atlas of Complete Dentures*, Wolfe Medical Publications Ltd., 1985.
- [3] J.A. Hobkirk, *Complete Dentures*, IOP Publishing Ltd., Bristol, 1986.