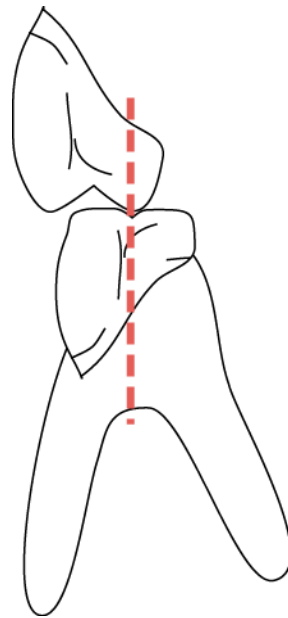

Complete Denture Manual

Robert W. Loney, DMD, MS
2012



 DALHOUSIE
UNIVERSITY
Inspiring Minds
Faculty of Dentistry



Complete Denture Manual

Robert W. Loney, DMD, MS
2012



Table of Contents

CD Diagnosis and Treatment Plan..... 1

 Medical history 1

 Dental History 1

Instructions to Patients..... 4

 Limitations of Dentures 4

 Adaptation to Dentures 4

 Oral Hygiene..... 5

 a. Dentures: 5

 b. Mucosa: 6

 Continuing Care 6

Preliminary Edentulous Impressions..... 7

 Irreversible Hydrocolloid Storage 7

 Tray Selection 7

 Irreversible Hydrocolloid Syringe Technique 7

 Patient preparation 8

 Making the Impression 9

 Possible Problems with Syringe Technique: 10

 Diagnostic Casts 10

 Pouring a Model 10

 Trimming 10

Tissue Conditioning 11

 Tissue Conditioning Techniques: 11

 1. Oral hygiene 11

 2. Tissue Rest 11

 3. Occlusal Correction 12

 4. Temporary Soft Liners 12

 Tissue Conditioning Treatment Protocols 13

Placement of Temporary Resilient Liners (Tissue Conditioners) 14

Custom Trays 17

 Purpose of a custom tray 17

 Procedure: 17

Border Molding 19

 Procedure for border molding with modeling compound 19

 Maxilla 20

 Mandible 21

Exercise: Maxillary Custom Tray for Border Molding for a Dentate Patient.....Error!

Bookmark not defined.

Final Impressions for Complete Dentures.....	23
Potential Impression Materials	23
Polyvinyl Siloxanes (Addition Reaction Silicone).....	23
Custom Trays:.....	23
Final Impressions	23
Post-palatal Seal.....	24
Boxing and Pouring Final Impression	25
Recording Maxillo-mandibular Relationships.....	27
Record Bases (Baseplates) and Occlusion Rims	27
A. Arbitrary Adjustment of Occlusion Rims	28
B. Establishing the Occlusal Vertical Dimension.....	28
Technique.....	29
C. Hinge Axis Location	31
Centric Position.....	32
Where is CR?	32
Reasons for using CR in edentulous patients.....	33
Reasons's for NOT using CO in edentulous patients	34
When to use CR	34
How to obtain CR	34
Procedure for recording the centric position and mounting the mandibular cast:	35
Protrusive Records	37
Selecting and Setting Denture Teeth.....	39
Reference Marks on the Occlusion Rims, Record Bases and Master Casts.....	39
A. Maxilla	39
B. Mandible.....	41
Selecting Anterior Teeth.....	42
Size.....	42
Shape.....	42
Shade.....	42
Material	43
Selecting Posterior Teeth Form	43
Anatomic (40 °, 30°, 20°(semi-anatomic), 10°).....	43
Non-anatomic (0°)	44
Posterior Tooth Size :	44
Prescribing Denture Teeth	45
Trubyte Portrait Recommended Combinations for Lingualized Occlusion:	45

Setting Anterior Teeth	46
Intraoral Checks:	49
Philosophies of Denture Occlusion:	50
1. Lingualized Occlusal Scheme	50
2. Monoplane Occlusal Scheme.....	51
Setting Posterior Teeth:	52
Achieving a Balanced Lingualized Occlusion.....	54
The Wax Try-in.....	60
A. Initial Wax Try-in	60
1. Occlusal Vertical Dimension and Interocclusal Distance.....	60
2. Centric Position Contacts.....	61
3. Tooth Position	62
4. Excursive contacts	63
5. Esthetics	63
6. Phonetics	63
7. Denture base contours.....	64
8. Patient Input	64
B. Final Wax Tryin	65
C. Completion of the Laboratory Prescription.....	65
Delivering and Adjusting Complete Dentures	66
Clinical Remount for Occlusal Adjustment.....	68
Cast Fabrication	69
Remounting the dentures	69
Differential Diagnosis of Post Insertion Problems.....	71
Principles	71
1. Denture base.....	71
2. Occlusion	71
3. Retention Problems.....	71
4. Occlusal Vertical Dimension (OVD).....	72
5. Allergies and Infections	72
6. Tooth Position.....	72
Most Common Areas Requiring Adjustments.....	72
Single Complete Dentures	73
Diagnosing Denture Pain & Looseness: Principles and Practice	76
References.....	90
Complete Denture Checklist	91

CD Diagnosis and Treatment Plan

Medical history

- Make efficient use of time - don't need history of relatives 4x removed
- Follow-up significant positive responses
- Note systemic conditions that impact on therapy (e.g. angina, hepatitis, Sjogren's syndrome)
- Obtain physician consultations where appropriate
- If some debilitating disease - discuss with instructor – to ensure acceptability

Dental History

- How many dentures, how long patient has worn dentures
- Satisfaction with dentures
- Things patient likes - what they want changed
- Be brief

Clinical Exam – routine clinical exam

Intraoral Exam - Examine one arch at a time – look, then write

1. General tissue health

- Attached mucosa / non attached
- Colour
- Character
- Displaceability

2. Specific Anatomical considerations

- Examine systematically, e.g. posterior 1st quadrant to post. 2nd quadrant, then palate
- Note the significance that a finding has to the therapy you are providing
- Visual and tactile exam.

MAXILLARY

The form of the maxillary arch affects retention – advise the patient if retention will be compromised

A. Posterior border of denture:

1. Hamular notches - posterior denture border – palpate position, visually deceiving

- Over extension - extreme pain
- Under extension - non-retentive
- Must be captured

2. Vibrating line - identified when the patient says "ah"

- At junction of the movable and non-movable portions of the soft palate
- Don't want denture on movable soft palate - it may be displaced
- Fovea - rough guide to the position of the vibrating line
- Throat form can affect breadth of vibrating line

3. Pterygomandibular raphe

- Behind hamular notches - significant rarely
- Have patient open wide as possible
- Can displace denture – requires relief in extreme cases

B. Tuberosity

- Displaceability
- If undercut - use elastomeric impression material – palpate for undercuts

C. Ridge form

- Advise patient if poor, since it will affect retention and stability

D. Labial/Buccal vestibule - 2-4 mm thick

- Buccal vestibule - zygomatic process - can be prominent
- When flat ridge - use care in accurately registering the vestibule to maximize retention

E. Frena - check prominence:

- Buccal frenum - usually broader
- Thin labial frenum

F. Bony areas, tori - mid palatal suture

- Don't want binding or fulcruming on the midline
- Fulcruming will cause discomfort, loss of retention & possible denture fracture

MANDIBULAR

Form of the mandibular arch is even more critical than in the maxilla, since there is less surface area for retention, and the moveable structures of the tongue and floor of the mouth can cause denture displacement if the denture is overextended- inform patients of any potential retentive problems.

A. Retromolar pad

- Terminal border of the denture base
- Compressible soft tissue – affects comfort and denture peripheral seal
- Must be captured in impression

B. Buccal shelf

- Check width - alginate will almost always overextend - painful
- Custom tray, border molded - not felt extraorally
- External oblique ridge sometimes prominent - do not cover - painful

C. Labial/Buccal vestibule

- Easy to overextend
- Check with minimal manipulation of lips
- Masseter - affects distobuccal border
 - if more prominent - concave border of denture

D. Frena

- Labial and buccal frena - narrow and wide respectively
- Lingual frenum - must allow for movement - or displaces easily

E. Retromylohyoid fossa

- Need to capture - especially when there is a severely resorbed ridge
- Mylohyoid muscle - raises floor of mouth during activity – in some cases there may be large differences between level at rest and level when active
- Affects length of flange.
- Mylohyoid ridge - palpate - if prominent, it will probably require relief

F. Tori

- Rarely need surgery unless large
- May require relief once dentures are delivered - advise patient

G. Genial tubercles

- Bony insertion for the genioglossus muscle
- May be projecting above the residual ridge if there has been severe resorption

Instructions to Patients

Limitations of Dentures

- Dentures are less efficient than natural teeth
- Some people can eat all foods easily, but these are the exception
- Generally the better the ridge form, the less problems are encountered. Patients with minimal ridges should be advised that their dentures will likely move (especially the mandibular) and their efficiency will therefore be reduced
- Patients with minimal ridges will likely encounter more sore spots than others
- It is wise to point out these limitations to patients prior to the delivery appointment so that it is viewed as an explanation, rather than an excuse

Adaptation to Dentures

- Because new dentures have usually been changed in some respects to the old dentures (otherwise there would be no need for new dentures), it will take time to adapt to them
- Studies show that it may take 6 to 8 weeks for patients to become optimally adapted to new prostheses (explain to patients)
- Adaptability is reduced in complete denture wearers because proprioceptors of the periodontal ligament have been lost and large areas of mucosal proprioceptors are covered in acrylic
- Adaptability is affected by:
 1. Length of time wearing dentures
 2. Amount of residual ridge remaining
 3. Degree of changes made in new dentures
 4. Individual variation (e.g. patients with more acute oral sensory perception have more difficulty adapting)

Adaptation to Chewing may be affected if:

1. CO has been changed to coincide to CR
2. Tooth positions (esp. incisors) have changed
3. Vertical dimension has changed

These patients may experience initial decreased efficiency, cheek or lip biting.

Adaptation may be improved by initially eating soft foods, increasing to hard foods, cutting food into smaller pieces, and placing food towards the corners of the mouth. Adaptation may be accompanied by an initial, transitory increase in saliva. Patients should be advised of the need to persevere while their neuromusculature adapts to the new prostheses.

Speaking may be affected by changes in:

1. Tooth position (esp. anteriors)
2. Tongue space (particularly if patients have been without dentures for some time)
3. Palatal contours

Initial speaking problems are usually transitory, since the tongue is very adaptable – tooth positions must be close at delivery, however).

Appearance may be changed in some individuals. These changes are usually due to:

1. Increasing length of incisors (worn)
2. Changes in vertical dimension
3. Improved lip support (not help with wrinkles)

In most instances these changes in appearance will be beneficial and not of concern to the patient. However, it may be of concern if appearance is radically changed. Patients may require reassurance during the period of adjustment to their new appearance.

Oral Hygiene

- Affects plaque retention, inflammation, fit and infections
- Provide proper instructions and demonstration
- Disclosing solution can be used to demonstrate plaque adherence for patients

a. Dentures:

- Brushing has been shown to be most effective method to remove plaque:
- Use non-abrasive cleanser (commercial pastes, dish detergents, not regular toothpaste)
- Patients are usually not vigorous enough around the denture tooth/base junctions
- Use soft brush with long bristles (less wear)
- Inner and outer surfaces must be cleaned
- Brush over a filled basin or face cloth (protection against damage if dropped)
- Brush after every meal, before bed

Chemical cleaners:

- Efferdent, Polident etc. must be used overnight to be effective (15-30 minutes is not sufficient)
- Brushing is more effective (60-80% vs 20-30% plaque removal compared to soaking alone)
- Combine brushing with soaking for more efficiency

Ultrasonic cleaners:

- True ultrasonic cleaners work well
- “Sonic” cleaners are not effective without chemical cleaner (brushing is more effective)

b. Mucosa:

- Remove dentures at night
- Brush mucosa with a soft tooth brush and warm tap water, massage all of the tissue - this will improve health for the next denture
- Stimulates tissue
- Alternatively use face cloth (less convenient, more pleasant feel, less plaque removed)

Continuing Care

- Most patients and many dentists don't schedule yearly denture recall appointments
- Easier to correct small problems, wear, fractures, resorption, reinforce hygiene, etc.
- Can do something small - improved patient rapport
- Denture life expectancy is 5-7 years, but if tissues change, remakes may be required sooner
- It is better for dentures to wear out rather than the denture bearing tissues

Preliminary Edentulous Impressions

In order to make accurate edentulous impressions for the purpose of making dentures, a custom tray is required to more accurately adapt to the patient's mouth. In the reference to complete dentures, it is particularly important to accurately capture the vestibular tissue anatomy, in order to create an effective seal for retention. Stock trays can result in distortion and shortening of the final denture flange. Custom trays are most easily made on accurate diagnostic casts made from preliminary impressions using an irreversible hydrocolloid (alginate) syringe technique. The use of the syringe technique ensures that alginate captures critical anatomy that is sometimes missed using a simple tray technique.

The use of border molding in conjunction with the custom tray helps prevent distortion of the movable vestibular tissues. Displacement of these tissues could lead to dislodgment of the dentures during functional movements of muscles and frenal attachments, which could cause unseating of the denture.

Irreversible Hydrocolloid Storage

1. Pre-weighed pouches make dispensing easier, and minimizes contamination
2. Store bulk material in airtight containers, store in cool dry containers
3. Alginate deteriorates if stored above 54°C, or with repeated openings
4. Deterioration results in thin mixtures, reduced strength, permanent deformation

Tray Selection

1. Select a tray with 5 mm of clearance with soft tissues – alginate requires bulk for accuracy, strength and stability.
2. Maxillary trays should extend from the labial vestibule to slightly beyond the vibrating line. Mandibular trays should cover the retromolar pads.
3. Sto-K trays or equivalent edentulous trays give the best results, but stock dentate trays can be used (distortion, overextensions are more common with dentate trays).
4. Trays can be modified with compound to extend the tray if desired.

Irreversible Hydrocolloid Syringe Technique

Using a syringe to make preliminary impressions helps to register critical anatomy, which can be otherwise missed. In particular, these areas are captured more easily with a syringe technique:

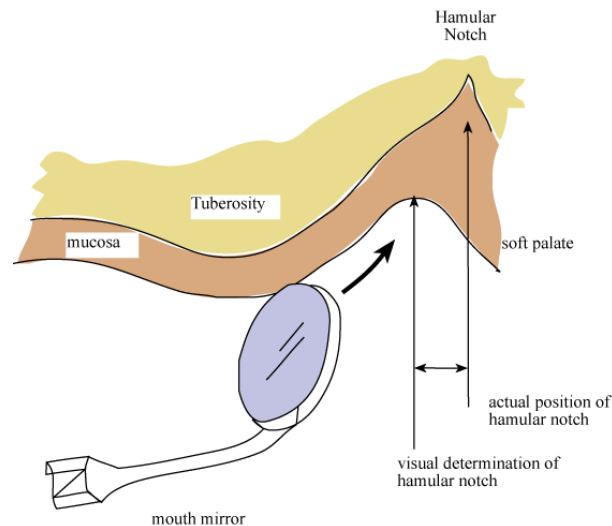
- Retromylohyoid area
- Hamular notches
- Retrozygomal area

Patient preparation

1. Practice placing and removing the tray so dentist and patient are better prepared
2. Dry the mucosa with gauze – don't let patient close until the impression is made. Otherwise, dry the tissues again.
3. Mark the vibrating line prior to making preliminary and final impressions. *The fovea should not be used for arbitrarily determining the posterior border.* The technique for determining the correct posterior border is outlined below:

a. Locate and mark the hamular notch with indelible stick

1. The posterior border of a complete denture and some partial dentures must pass through this notch, between the bony tuberosity and hamulus. Denture border must terminate on "soft displaceable tissue", to provide comfort and retention. In some patients the notch is posterior to where the depression in the soft tissue appears.
2. Use the head of a mirror, to palpate the notch and mark it with an indelible



marker.

b. Locate the posterior border of hard palate

Ensure the denture terminates posterior to this landmark by palpating the end of the hard palate.

c. Locate and mark the vibrating line

The denture should terminate here in the midline at the junction of movable and immovable portions of the soft palate. If the denture terminates posterior to this, movements of the soft palate may cause it to dislodge. If the denture terminates anterior to this, on the hard palate, no seal or a poor seal may be created, and the denture may be unretentive and/or uncomfortable.

d. Make the impression after the vibrating line & hamular notches are marked

The marks will transfer to the impressions and the cast when it is poured. The clinician and technician will not have to guess the proper position. Do not allow the patient to get saliva on the indelible mark or it will smear, or not transfer to the alginate impression.

Making the Impression

1. Select a 12 cc. disposable syringe, cut off the tip to provide at least a 5 mm orifice (Syringes can be sterilized and reused several times)
2. Vaseline the syringe plunger - this is particularly important if syringes have been sterilized
3. Use an uncontaminated bowl and spatula, use *regular* set alginate
4. Fluff (shake) the powder, measure, tap and flatten the scoop with powder
5. Use three scoops for syringe impressions
6. Have an assistant mix the material for at least 45 seconds, until there is a smooth creamy homologous consistency that glistens. The material should not appear granular or lumpy.
7. The assistant loads the syringe nearly full, from the back and inserts plunger.
8. The clinician syringes a broad rope into the vestibule, beginning at the posterior, moving quickly toward the anterior, and filling the vestibule until the labial frenum is reached.(do not cross the midline - this traps air bubbles). The cheek should be retracted with a mirror, instead of a finger, to provide more room for visibility. In the **maxilla**, begin opposite the region of the tuberosity and inject until alginate is seen in the hamular notch area, before moving forward. In the **mandible**, start with the buccal vestibule adjacent the retromolar pad, and move forward until the labial frenum is reached. Repeat on the opposite side. For the lingual vestibule, roll the tip of syringe under the tongue, inject into retromylohyoid space until alginate is seen coming upward between the tongue and the residual ridge, then move anteriorly, filling vestibule until the lingual frenum is reached. Repeat on the opposite side. Do not scrape the mucosa – this is a bloodless procedure!
9. If there is a steep palate, some material can be syringed into the palate, but it should be smoothed with a finger, or voids may occur around the syringed material
10. If the patient is partially edentulous, syringe a small amount of hydrocolloid on the occlusal surfaces (or use some of the vestibular material) and push it forcefully into the occlusal surfaces.
11. The assistant loads the tray while the clinician is syringing
12. Place the posterior portion of the tray first, then seat the anterior of the tray

13. Less gagging will occur, if the patient is lying down (tongue position avoids gagging)
14. The clinician molds the vestibular areas by pulling on the cheeks and lips to activate the muscles and frena
15. Support the tray during setting – do not leave the patient, or allow the patient to support the impression – if the tray moves during gelation, distortion will occur
16. Remove with a sudden jerk (to avoid permanent deformation)
17. Evaluate impression and, if it is acceptable, pour within 12 minutes
18. Rinse the impression thoroughly with water, gently shake to remove excess water. Spray with disinfectant to coat all surfaces, and seal in a bag for ten minutes

Possible Problems with Syringe Technique:

1. Saliva contamination – vestibular material will appear separate from the tray material
2. Insufficient material – lack of integrity between the syringed and tray material
3. Omitting lubrication of the plunger may make it difficult to express the alginate
4. Trapping tongue under the tray will result in underextension of the lingual vestibule
5. Severe gaggers – the syringe technique involves a slight increase in intraoral manipulations which may be counter productive for these patients

Diagnostic Casts

Pouring a Model

1. Weigh powder, measure water
2. Vacuum mix (less time, stronger cast)
3. Use a two pour technique
4. Modulate speed of pouring by tilting back and forth or pressing the tray more firmly onto the vibrator
5. Make sure the model is moist during trimming soak in slurry water, or soak with base of cast in water
6. Casts should be a minimum of 12 mm (.5 inch) in thinnest part
7. Separate the alginate impression from the stone cast after 45 minutes

Trimming

1. Trim the base on the model trimmer parallel to the residual ridges
2. Leave the mucous membrane reflection intact for making a custom tray. Remove extensive areas of the cheek or lip reflection which create undercuts and which will make it difficult to make or remove the custom tray
3. All anatomical surfaces should be included with minimum voids

Tissue Conditioning

Definition: Non-surgical methods of improving the patients' denture foundation tissues, including the use of tissue rest, occlusal correction, temporary soft liners and/or improvement of hygiene. Tissue conditioning is usually considered prior to performing a permanent relin and or making final impressions for complete or partial dentures.

Poor tissue health can be the result of:

1. Pathological conditions

- The result of systemic disease - nutrition, hormone imbalance, autoimmune diseases (Lupus)

2. Local factors

- Inaccurate denture bases
- Occlusal disharmony
- Tissue abuse – ill-fitting dentures, poor oral hygiene, no tissue rest.

The dentist has the responsibility for proper diagnosis.

Tissue rehabilitation is limited to reversible tissue changes such as:

- Red inflamed, edematous tissues
- Ulcerations
- Candidiasis
- Epulis fissuratum (limited – may require surgery if extensive)
- Papillary hyperplasia (limited – may require surgery if extensive)

Tissue Conditioning Techniques:

1. Oral hygiene

- Plaque causes inflammation and edema
- Demonstrate how to brush all denture surfaces
- Have patient massage tissues with a soft tooth brush twice a day - morning/night; begin with 30 seconds and increase to 2 minutes.

2. Tissue Rest

Lytle (JPD, 7:27, 1957; JPD 9:539, 1959)

- Abused tissues were treated by removing dentures for periods of 48 - 72 hours
- Tissue inflammation disappeared, then recurred if faulty dentures were replaced

Kydd, Daly, Wheeler, (JPD 32:323,1974)

- When tissue was loaded, recovery was affected by age:
 - a. 10-30 years old: 90% had immediate recovery when load released.
 - b. 72-86 years old: 61% had recovery after 10 minutes; some took 4-1/2 hr.

- Clinical reports suggest regular finger massage/tooth brushing of mucosa with a warmed, soft brush may be useful to improve tissue health

3. Occlusal Correction

Lytle showed improper occlusion can cause to poor tissue health

****This is one of the most overlooked causes of tissue irritations****

Methods for correction:

1. Add to occlusal surfaces of acrylic teeth with acrylic resin, - improves vertical dimension, balances occlusion
2. Soft mouth guard over teeth – reversible procedure, inexpensive
3. Clinical remount and occlusal adjustment

4. Temporary Soft Liners

(Reference: Dent. Clin. N.A. 28(2): 239, 1984)

(Lynal, Viscogel, Coe-Comfort, Tru-Soft, Soft-Tone)

- Can improve comfort, retention, occlusal vertical dimension (minor changes), and extension of denture bases (minimal).
- Use manufacturers recommendation for mixing, usually 1:1.5-2.0 powder/liquid.
- Typical composition:
 - Powder - polyethyl methacrylate
 - Liquid - aromatic ester-ethanol
- These materials are soft and resilient and flow under pressure.
- Material becomes rigid after a week - plasticizer leeches out
- Change the soft liner as necessary (usually lasts no longer than 4-6 weeks)

The length of time required for tissue conditioning depends on the severity of irritation. A combination of treatment may be necessary.

Tissue Conditioning Treatment Protocols

All patients requiring tissue conditioning:

1. Clean denture for patient (ultrasonic and cleanser)
2. Educate the patient concerning the condition and home care
 - brushing denture
 - oral hygiene - brush, massage tissues
 - tissue rest - 8 hrs./day
 - tissue rest - 24 hours prior to final impressions

**Patients should understand that inconvenience (1-3 days) now
will affect their new denture over the years of use***

Patients with moderate to severe inflammation:

1. Check extensions of the denture
 - if over extended - trim as required
 - if under extended - limited increase in base with soft liner
2. Correct occlusal disharmonies, if present:
 - clinical remount
 - soft acrylic mouthguard
 - addition of acrylic to teeth
3. Soft denture liner to:
 - provide resilience, and comfort
 - provide minor alterations of the occlusal vertical dimension
 - improve the fit and stability of the denture
 - make minor extensions to the denture base

When treatment is not successful:

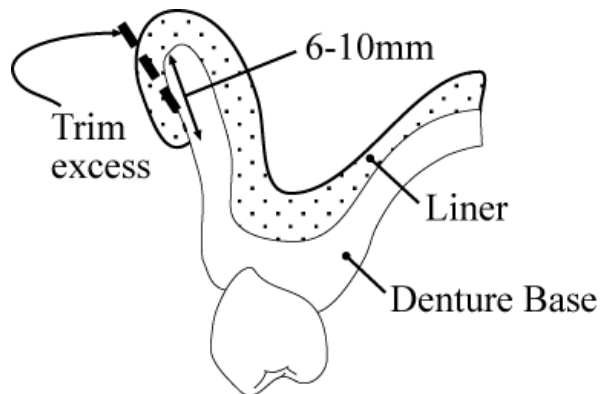
1. Refer for diagnosis/treatment of systemic disorder
2. Surgical treatment/ biopsy may be necessary

Placement of Temporary Resilient Liners (Tissue Conditioners)

Tissue conditioners provide one of the easiest means of improving the health of the denture foundation tissues. These materials are also one of the most abused in the dental office. It is often presumed that the mere presence of a temporary resilient liner will resolve any mucosal problem. This section outlines a technique that can be used to reduce soft liner adjustment time, while improving patient comfort and liner longevity. The technique described has been used with tissue conditioners such as Lynal (Dentsply International Inc., Milford, DE), Visco-gel (Dentsply Ltd, Detrey Division, Surrey, England), and Tru-Soft (Harry J. Bosworth Co., Skokey, IL), but it can be adapted to most other materials that are available in similar powder/liquid formulations.

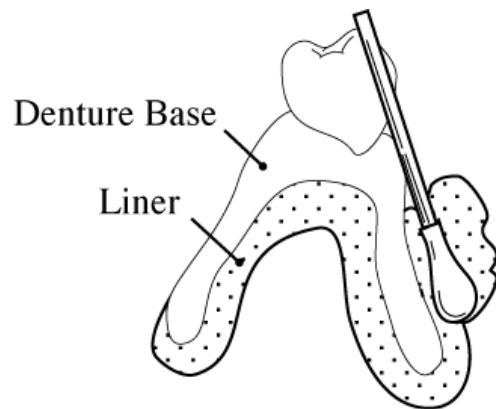
Technique:

1. Clean the denture prior to application of the soft liner. Use scalers, pumice on a wet ragwheel, and an ultrasonic cleaner to eliminate gross debris and calculus. Disinfect the denture by immersion in sodium hypochloride for at least 10 minutes prior to placement of the liner. This will help to minimize the presence of microbes, which might subsequently colonize the liner, thereby shortening liner lifespan. When relining opposing dentures, reline the least stable denture first so that the more stable denture can be used as reference for positioning the relined denture, using the occlusal contacts.
2. Determine if the denture base needs to be reduced prior to the placement of the liner. Flanges that are excessively long or areas that are causing severe inflammation or frank ulceration should be reduced. The entire denture bearing area should also be prepared to provide room for the liner. Most materials require a minimal thickness of approximately 2 mm in order to provide sufficient resiliency to minimize tissue trauma. If the existing occlusal vertical dimension is acceptable, and the thickness of the denture base will allow, provide uniform relief of internal surface of the denture using pilot grooves, acrylic burs and arbor bands. If there is insufficient occlusal vertical dimension (excessive interocclusal rest space or freeway space), there may be room to place the liner without reduction of the denture base. If the denture base is not reduced, the incisal display will probably be increased once the liner has been placed. The esthetic consequences of such a change should be evaluated and discussed with the patient.
3. Remove the glossy surface around the denture periphery where the conditioner will terminate on the denture (at least 6 mm past the edge of the flange). This helps ensure that the conditioner will adhere to the denture to minimize separation, leakage and microbial colonization.



4. Mix the tissue conditioner according to the manufacturer's instructions. Mix with a stropping action against the mixing container. Do not use a vigorous stirring action which can lead to the incorporation of bubbles that are difficult to eliminate from the viscous mixture. In general, liners can be mixed slightly stiffer than recommended by adding additional powder to the liquid component. This can be done to decrease the flow from underneath a denture during setting, when an increase in the occlusal vertical dimension is desired. Do not mix the liner thinner than suggested by the manufacturer, as this can have deleterious effects on the physical properties and longevity of the liner.
5. Apply a smooth even layer to the denture, usually starting at the posterior and teasing the material forward without incorporating air bubbles. Bring the tissue conditioner over peripheries about 6 mm, so that saliva cannot get between the denture and the conditioner in the area of the periphery. This will minimize the possibility of separation of the conditioner from the denture. Excess can be removed later.
6. Place the denture intraorally, having an assistant help retract the commissures of the mouth to avoid accidental removal of the liner during insertion. Insertion is easier if the patient relaxes the cheeks and lips rather than opening maximally. Avoid touching the material during initial placement.
7. Stabilize the denture and have the patient close lightly, until initial contact is felt or seen. If occlusal contacts are uneven, have the patient open, and tilt, tip or bodily move the denture into a position where stable even contacts can be obtained. Border mold the peripheries, when the material begins to gain viscosity (about 3 minutes for most tissue conditioners).

8. Use a cotton swab to remove any areas of gross excess prior to initial set. This will reduce the amount of trimming needed, and make for a neater, more comfortable external surface. Excess material most commonly requires removal in the area of the lingual vestibule and distobuccal flange of the mandibular denture, and the retrozygomal area and palate of the maxillary denture.



9. Remove after initial set (commonly 8-10 minutes) and trim with a hot scalpel blade. Heating the blade will allow the scalpel to cut through the liner without sticking, and leave a cleaner, smoother surface, which will enhance patient comfort. Do as little modification as possible at this time, as the material will be sticky and adjustment will often result in a rough or ragged surface that is uncomfortable and difficult to clean.
10. Clean the opposing denture and provide care instructions. Explain the temporary nature of the material to the patient. Have the patient rinse the denture with water, after eating, for the first 24-48 hours, and brush the liner with a soft tooth brush and a small amount of

liquid dish detergent subsequently. Most commercial denture cleaners should be avoided as they contain sodium hypochloride which will reduce the lifespan and resiliency of the liner. The denture should be placed in a container with high humidity over night, but not immersed in liquid.

11. Have the patient return to the office twenty four to forty eight hours after placement, so that the conditioner can be trimmed with acrylic lab burs and polished with pumice on a damp rag wheel. Both the external surface and the peripheral roll should be polished, with care, to a fairly high shine. Polishing the liner will make it smoother, more comfortable and less prone to microbial colonization. In some instances polishing may improve liner longevity or hasten tissue resolution, since the liner will be easier to clean.
12. Change the soft liner as necessary. If there are no signs of tissue resolution, systemic conditions should be considered and appropriate investigations undertaken.

Criteria for Tissue Conditioning Liner

- No significant voids
- Liner is well polished
- Adequate thickness ($\approx 2\text{mm}$)
- Liner has been well mixed and applied
- The peripheries are smooth, with no sharp areas, not ragged
- Excess material cleaned off external denture surface, teeth

Custom Trays

Custom trays are individualized impression trays made from a diagnostic cast that are used for making final impressions. They are most commonly made of a rigid acrylic resin (e.g. SR-Ivolin, Hygon, Formatray, Triad). Trays are made short of the periphery of the diagnostic casts, since they are usually overextended, due to the viscosity of the irreversible hydrocolloid used to make the preliminary impression.

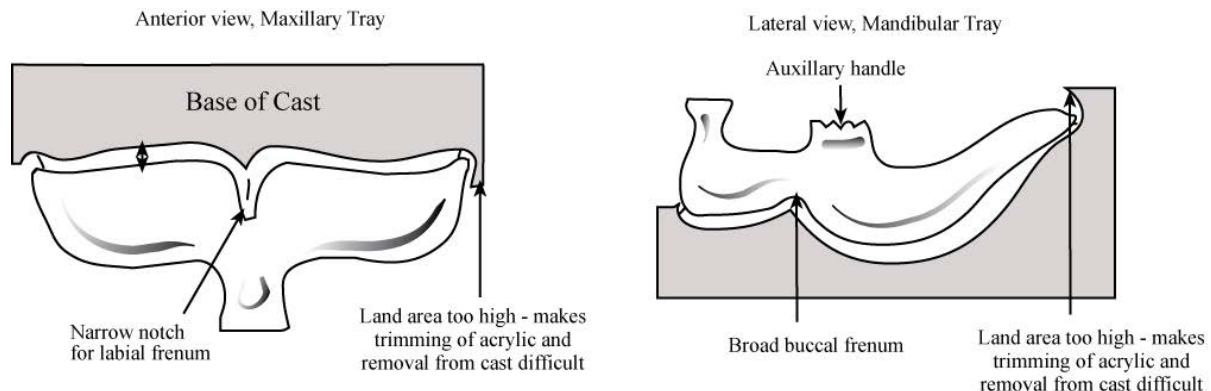
Purpose of a custom tray

1. Minimize impression material distortion (uniform thickness, rigid tray)
2. Prevent tissue distortion (less viscous material, more accurately adapted tray)
3. Reduce costs - less impression material (expensive) is used
4. Allow for accuracy by molding the border, resulting in improved retention

Procedure:

1. Use a pencil to outline the depth of the vestibule (where the vertical portion of the ridge begins to turn toward the horizontal portion of the vestibule) and across the vibrating line.
2. Draw a second line 3-4 mm short of the first around the vestibule, (at the posterior border).
3. Provide adequate room for frenal attachments (narrow labial, and wide buccal).
4. Block out all undercuts with baseplate wax to prevent the tray from locking onto the cast
5. Lightly lubricate the cast (petroleum jelly, Alcotex or material specific release agent).
6. Adapt one thickness of base plate wax to the cast. Trim the wax 3 mm short of the second line in the vestibule and in a “butterfly” configuration at the vibrating line from hamular notch to hamular notch (do not place relief wax over the blockout wax). Wax provides room for the impression material, but more importantly minimizes the production of hydraulic pressures that could distort the mucosa. Where blockout is placed, these pressures cannot build up because the acrylic is already away from the tissue.
7. Place a piece of unpolymerized light-curing acrylic resin (e.g. Triad, Tru-Tray) on the cast. Wear gloves to minimize exposure to material to prevent sensitivity reactions.
8. Adapt the resin to the cast (palatal area first), trim excess using a scalpel blade. Push down through the resin, rather than pulling the blade along the periphery (This will minimize sticking and tearing of the resin, and result in a better periphery).

9. Mold a small vertical handle, attach it to the anterior of maxillary tray and blend well to the tray material, ensuring it has slight undercuts to aid in removal from the mouth.
10. Construct two auxiliary handles for stabilization and orientation of the tongue. Place the handles in the area of the 2nd premolars or 1st molars.
11. Adapt the palatal and posterior portions of the tray to ensure proper adaptation.
12. Place the cast with uncured resin under water in a clear container with a lid. The entire tray must be covered in water to prevent the formation of an air-inhibited layer on the tray. The water keeps the wax spacer from melting during curing and permits curing without the use of an air barrier coating. Ensure the container is kept water tight with a lid and that no water spills in the curing unit (to prevent an electrical accident). Polymerize in a light-curing unit as per the manufacturer's recommendations.
13. Use the arbor-band and acrylic burs to trim trays make all edges round and smooth.
14. Mandibular trays should be made with two auxiliary handles for stabilization and orientation of the tongue. Ensure the handles do not impinge on the tongue space, or the tongue may retract and alter the resting position of the floor of the mouth.



Criteria for Acceptable Acrylic Impression Trays:

- Tray not significantly underextended
- Stable, does not rock on cast or in mouth
- Tray not significantly overextended
- Uniform thickness (2-3mm; wax /cast not showing through tray)
- Tray flange adapted as closely to residual ridge as possible
- Wax relief over mobile tissue, undercuts, incisive papilla, other critical anatomy
- Labial and buccal notches properly placed
- Borders rounded, not sharp
- Small handles, properly positioned

Border Molding

Border molding is the shaping of the border areas of an impression tray by functional or manual manipulation of the tissues to duplicate the contour and size of the vestibule. Border molding can be performed with thermoplastic modeling compounds, waxes or impression materials. The custom tray wax spacer remains in place during border molding procedures.

Procedure for border molding with modeling compound

1. Try the custom tray in the mouth - it should be comfortable and provide 2-3 mm of space to the height of the vestibule - trim with an acrylic bur if indicated
2. Dry the periphery of tray (otherwise compound will not stick to the tray)
3. Heat the modeling compound over a Bunsen burner until it starts to droop
4. Do not overheat – if the compound catches fire or boils, it will not mold as easily, and may have to be removed to complete the border molding procedure
5. Apply compound over the periphery of the tray, in a thickness just slightly narrower than the compound stick
6. Flame with a hand torch until all seams or sharp contours have disappeared
7. Do not burn or blister, do not melt wax spacer inside tray
8. While heating, it may help to hold the tray upside down so that the softened compound droops toward, rather than away from, the depth of the vestibule
9. Temper the compound in a water bath (135-140°F) for several seconds to prevent burning the patient. The hot water bath is set at a temperature that will keep the compound soft for an extended period, so it will not harden in the hot water bath
10. Try to keep the wax spacer out of the hot water bath as much as possible or it will melt, and make it difficult to replace the tray intraorally in the same position between intraoral insertions. This will result in uneven border molding.
11. The patient should be seated with head against the headrest, with mouth open and relaxed prior to removal from the hot water bath. When the patient ‘opens wide”, the commissures constrict, limiting access to the oral cavity and making it more difficult to place the tray
12. Place the tray intraorally by rotating it into place and mold the material by pulling on the cheeks and lips and having the patient make functional movements
13. Chill in cold water

14. Trim excess compound that has overlapped the wax spacer or external material that is thicker than 4-5 mm before moving to another area of the tray. Clean debris from the tray
15. If the border is sharp after trimming or has seams, re-flame with a torch, temper and readapt intraorally
16. Repeat until the periphery is completed
17. Some textbooks suggest reducing the border molding material by 1-2 mm prior to making a final impression. This is not necessary if any of the modern, low-viscosity impression materials are used and sufficient relief from hydraulic pressure is provided during the impression procedure (spacer and holes in tray). Only a thin layer of impression material (0.5-1 mm) is desired over the surface of the border molding in the final impression. However, once the wax spacer is removed, if the operator uses too much pressure during stabilization of the tray, compound borders may overextend the impression. If this happens reduce the compound showing through the impression material, remove the set material and remake the impression.

Maxilla

1. Seat the tray firmly in the mid-palatal area during border molding procedures
2. Border mold the posterior buccal areas by pulling the cheek down and forward with slight circular movement. Have the patient move the mandible side to side and open wide. This will mold the retrozygomal area to allow movement of the coronoid process and relief for the pterygomandibular raphe, to prevent impingement
3. Border mold the anterior labial frenum by pulling the lip outward and straight downward in an exaggerated fashion (do not pull the frenum to one side)
4. The labial frenum should be narrow and distinct, while the buccal frena are usually broader and somewhat “V-shaped”

Post palatal area:

1. Add compound from hamular notch to hamular notch across the top of the tray (not at the edge) of the posterior border of the tray
2. Check that the posterior extension of the denture terminates at the vibrating line and hamular notches by using an indelible stick. Insert the tray and check visually that the compound terminates at the indelible line

Mandible

Border molding in the mandible is generally more challenging due to the changing position of the floor of the mouth - the position of the lingual periphery can differ greatly between positions at rest and activity

Posterior buccal areas:

1. Pull the cheek upward while holding tray in place. Have patient suck their cheeks inward while holding tray in place.
2. The retromolar pad should be covered (at least partially) to provide a seal and comfort.
3. Border molding should not normally extend beyond the external oblique ridge. Palpate the cheek at the angle of the mandible to feel for a smooth transition between the mandible and the border molding. Palpation of a prominent ledge of compound indicates overextension of the compound lateral to the retromolar pads and posterior ridge
4. The distal buccal extension of denture often needs to converge medially to allow movement of the masseter muscle. This portion can be molded by having the patient try to close with some pressure against your support of the mandibular tray. This activates the masseter, which will displace the compound on the distobuccal area of the flange, if the tray itself is not over extended.
5. The labial frenum is narrow and distinct; the buccal frena are broad and “V-shaped”. To mold the labial frenum, pull the lip straight up, but not in as exaggerated manner as is used for the maxilla.

Posterior lingual areas

1. Have the patient touch their tongue to the corners of the mouth, to the palate and stick their tongue out of their mouth
2. An “S” shaped lingual flange commonly results in the posterior lingual area
3. Compound should extend into the retromylohyoid space. The distolingual border can present a squarish rolled border, extending straight down from the retromolar pads, or it may curve anteriorly to varying degrees, depending on the lateral throat form. The distolingual border almost never angles posteriorly from the retromolar pads.

4. The lower border should be at or slightly below the mylohyoid ridge but not deeply into the undercut below the ridge, particularly if it is sharp. (This minimizes, abrasion and discomfort around the mylohyoid ridge)
5. The denture should not lift with normal tongue movements

Anterior lingual

1. Have patient lift tongue to palate, to corners of mouth and stick tongue out while holding tray in place – denture should not lift by normal tongue movements
2. Do not cover sublingual gland orifices

Criteria for Border Molding-Maxillary

- Tray stays in place at rest and during slight manipulation of tissues
- Tray exhibits firm suction when an attempt is made to remove it
- Labial and buccal flanges extend into height of vestibule
- No tray is showing through border molding
- Flange thickness generally no greater than 4-5 mm (unless severely resorbed)
- Patient feels no areas of discomfort
- Posterior palatal seal is properly covered
- Frenal areas properly contoured
- Flanges smooth, continuous; rolled and not sharp
- Flanges relatively symmetrical on contralateral sides

Criteria for Border Molding – Mandibular

- Tray stays in place at rest and during slight manipulation of tissues
- Tray is relatively stable when a vertical force is applied (within constraints of anatomy)
- No tray is showing through border molding
- Flange thickness generally no greater than 4-5 mm
- Patient feels no areas of discomfort
- Labial and buccal flanges extend into depth of vestibule
- Frenular areas properly contoured
- Flanges smooth, continuous; rolled and not sharp
- Flanges relatively symmetrical on contralateral sides
- Covers retro-molar pads
- Does not extend past buccal shelf
- Lingual flanges at or slightly below mylohyoid ridges
- Posterior extensions of lingual flanges extends into retromylohyoid spaces
- Palpation over masseter reveals no over-extension

Final Impressions for Complete Dentures

Potential Impression Materials

Irreversible hydrocolloid - hydrophilic, but viscous; stock tray distorts vestibular tissues

Zinc oxide and eugenol - fast set, rigid (undercuts difficult), poor taste

Polysulfides - poor taste, poor dimensional stability, poor elastic recovery

Silicones - addition reaction – acceptable taste, dimensionally stable, elastic recovery

Polyethers - poor taste, dimensionally stable, elastic recovery, expensive

Polyvinyl Siloxanes (Addition Reaction Silicone)

- Inherently hydrophobic but newer materials more hydrophilic (similar to the polysulfides and polyethers)
- Flow - many are thixotropic, requiring pressure to flow
- Good dimensional stability
- Excellent elastic recovery
- Excellent dimensional accuracy

Custom Trays:

- After completion of border molding, remove wax spacer carefully, so as not to dislodge the border molding
- The remaining space provides relief from the buildup of hydraulic pressure and provides room for an adequate, uniform thickness for impression material to improve impression accuracy
- Bevel any sharp internal surfaces of the border molding or tray to provide a smooth transition that will not distort the tissue
- Place holes in tray to allow release of hydraulic pressure
- Paint inside of tray and border molding with adhesive - allow to dry 7-15 minutes

Final Impressions

- Leave dentures out for 24 hours prior - tissue recovery
- Use low viscosity polyvinyl siloxane material (must use rubber base adhesive in tray)
- Place enough impression material to replace the wax spacer
- Try not to incorporate bubbles when loading the custom tray
- Cover all border molding with impression material
- Dry tissues with 2x2 gauze folded in cotton pliers

- Insert by placing one side of the tray against one of the commissures of the mouth and rotating the tray into the mouth while pulling outward on the commissure of the contralateral side
- Seat tray front to back - use gauze over holes in tray
- Ensure the tray is centered and properly oriented
- Manipulate cheeks, lips and move mandible to sides for maxillary impression; hold tray in position and have patient suck cheeks together, lift and move tongue forward and toward the corners of the mouth
- Most polyvinyl siloxane materials set within approximately 6 minutes
- Material should not be more than 1 mm thick over border molding (otherwise it was not fully seated)

Post-palatal Seal

- Mark the area of the post-palatal seal intraorally with indelible stick – glandular area and vibrating line
- Place impression in mouth, line transfers to the impression
- Disinfect, refresh the line with a new indelible stick
- Prescribe a mechanical post-palatal seal
- Pour impression in Microstone

Criteria for Final Impression - Maxillary

- Post-palatal seal area recorded (vibrating line & displaceable tissue outline)
- Peripheries covered by a thin layer of impression material (.5-1 mm)
- Tray properly vented and compound relieved
- No significant voids
- Impression is stable and retentive when moderate pressure is applied to the canine region No significant areas of "burn through"
- Accurately records available supporting structures

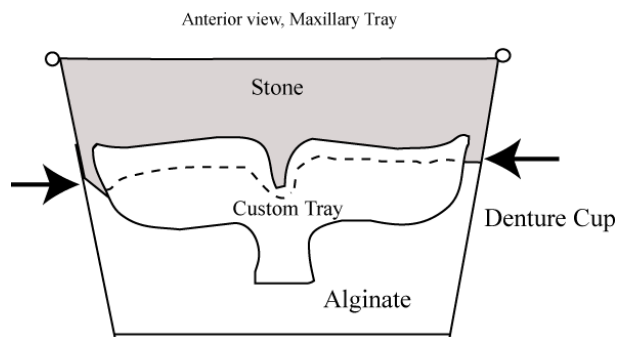
Criteria for Final Impression - Mandibular

- Peripheries covered by a thin layer of impression material (.5-1 mm)
- Tray compound properly relieved
- No significant voids
- Impression is stable with tongue at rest when moderate unseating pressure is applied
- No significant areas of "burn through" (distortion of the contours of the surrounding tissue)
- Mandibular retention evident - when tongue at rest and moderate vertical force applied
- Accurately records available supporting structures

Boxing and Pouring Final Impression

Boxing of a final impression should be:

1. Quick and easy with consistent results
2. Provide support and preserves flange contours
3. Compatible with cast material and impression material
4. Inexpensive
5. Avoid excessive trimming



The right side at the arrow is prepared correctly, with a 6 mm land area which is horizontal, with approximately 2-3mm of the periphery expose. The left side at the arrow is prepared incorrectly so that stone will lock around the rigid tray. Don't cut the alginate back too deeply below the peripheral role, or the impression will be difficult to remove.

At the posterior border of the impression, make sure the denture is cut back to the vibrating line (recheck before cutting). **The edge of the posterior border should show about 1 mm above the alginate** in this area to ensure that the posterior border can be detected on the master cast. If the impression is perfectly continuous with the alginate, it will not be possible to discern the posterior border of the denture.

Criteria for Master Casts

- No significant bubbles or flaws in stone
- Includes all anatomical surfaces of final impressions
- Posterior border of maxillary cast clearly demarcated
- Includes 3-4 mm. land area
- Base approximately parallel to ridge and approximately 1/2 inches thick (minimum)
- Evidence of a dense stone surface
- Clean and well trimmed (no dried slurry on casts)

Mechanical properties of rubber impression materials

Material	Consistency	Permanent deformation (%)	Strain in compression	Flow	Shore A hardness	Tear strength (g/cm ²)
Polysulfides	Low	3-4	14-17	0.5-2	20	2500-7000
	Medium	3-5	11-15	0.5-1	30	3000-7000
	High	3-6	9-12	0.5-1	35	-
Silicones	Very high	1-2	4-9	0.05-0.1	15-30	2300-2600
		2-5	2-5	0.02-0.05	50-65	-
		0.05-0.4	3-6	0.01-0.03	35	1500-3000
Addition (polyvinyl siloxanes)	Low	0.05-0.3	2-5	0.01-0.03	50	2200-3500
	High	0.1-0.3	2-3	0.01-0.03	60	2500-4300
	Very high	0.2-0.5	1-2	0.01-0.1	50-75	-
Polyethers	Low	1.5	3	0.03	35-40	1800
	Medium	1-2	2-3	0.02	35-60	2800-4800
	Medium plus thinner	2	6	0.04	30-50	2500
	High	2	3	0.02	40-50	3000

In general the light consistency materials of each type are more flexible than the heavy consistency rubber impressions. The polyethers containing thinner are more flexible than the regular material. Also, the silicones are stiffer than the polysulfides of comparable consistency, and the addition silicones are slightly stiffer than the condensation silicones.

Comparison of elastomeric impression materials

Representative brands	Condensation silicone			Polyether	Poly(vinylsiloxane)
	Polysulfide	Condensation silicone	Polyether		
Working time	Coe-Flex	Accore	Impregum F	Express	
Curing time	Neo-Plex	Cutter Sil	Permadyne	Mirror 3	
Tear resistance	Perm lastic	Xantopren	Polygel	Reprosil	
Stiffness	Medium-v. long	Medium-long	Short-medium	Short-medium	
Elastic recovery	Long	Low	Medium	Short-long	
Dimensional accuracy	High	High-low	High	Low	
Dimensional stability	Poor	Good	Fair	Medium-high	
Flow after setting	Fair	Fair	Good	Excellent	
Esthetics (odor, taste, color)	High	Poor	Good	Excellent	
Ease of cast pouring	Poor	Excellent	Low	Low	
Time to cast pouring	Good	Fair	Fair	Excellent	
Shell life	Immediately	Immediately	Excellent	Poor	
Cast per impression	Fair	Poor	Excellent	1 Week	
	Medium	Low	Very high	Fair	
				High	

Recently introduced polyethers are more flexible than the original materials and are rated medium. Newer polyvinyl siloxanes identified as hydrophilic range in model pouring ease from equivalent to polyethers or polysulfides.

Recording Maxillo-mandibular Relationships

In order to fabricate complete dentures outside of the patient's mouth, certain relationships need to be transferred to an articulator, which will be used to set the teeth and arrange the denture occlusion. These relationships include:

Occlusal vertical dimension - amount of separation between the mandible and maxilla when the denture teeth will be in contact

Hinge Axis Location - locating the relationship of the maxilla to the transverse horizontal axis and an anterior reference point

Centric position - the horizontal relationship (anterior/posterior and medio-lateral) of the maxilla and mandible, where maximum intercuspation of the denture teeth will be created

Protrusive relationship - used to program the articulator to simulate the relationship of the maxilla and mandible in excursive movements so that the denture teeth can be set in a harmonious relationship

Record Bases (Baseplates) and Occlusion Rims

The maxillary and mandibular casts can be accurately related on an articulator using record bases and wax occlusion rims. The record bases simulate the finished denture base and the wax occlusion rims simulate the position of the teeth for the purposes of making these records. To make the recording of jaw relationships easier, the occlusion rims are made slightly bulkier than the denture teeth to provide additional stability during record making. After the maxillary and mandibular casts are related on the articulator, the bulk of the wax rim is replaced by denture teeth, so that the contours of the denture and position, size and other aspects of the dentures can be evaluated prior to processing.

The maxillary record base should be retentive. A non-retentive record base usually results from failure to adapt the resin (particularly from the posterior border and palate) during polymerization. Alternatively, looseness may be caused by over- or under-extension, or by the use of too much blockout. In cases of minimal looseness, a denture adhesive may be used to keep the record base in place. *If pronounced looseness exists, time will be saved by remaking the record base prior to jaw relation records.*

Make the rims slightly higher than required (23 mm average height from the flange of the record base to the rim), so you can reduce the height as necessary.

A. Arbitrary Adjustment of Occlusion Rims

Prior to determining the occlusal vertical dimension of occlusion, the occlusion rims should be adjusted separately to using average dimension and guidelines. This arbitrary adjustment provides a 'starting point' for adjustments and should be fairly rapid. *It should normally not take longer than 15 minutes per arch.*

1. Maxillary Occlusion Rim Adjustment

- The maxillary wax rim should be slightly facial to the ridge to compensate esthetically for facial resorption of the bone
- Anterior height should be 1-2 mm below the lip when the patient slightly smiles
- The rim should touch the wet line of the lower lip, when the "F" or "V" sounds are spoken (have the patient count from 50 to 60)
- The nasolabial angle should be approximately 90°, and the lips should be unstrained, with the vermilion border showing
- The anterior-posterior orientation of the occlusal plane should be parallel to the ala-tragus line (Fox plane)
- The mediolateral orientation of the occlusal plane should be parallel to the pupils

2. Mandibular Occlusion Rim Adjustment:

- The mandibular wax rim should be centered over the middle of the ridge to maximize stability, which is usually compromised in the mandible
- The posterior height of the wax rim should intersect with a point 1/2 - 2/3 up the retromolar pad
- The anterior height of the wax rim should be even with the corners of the mouth when the lip is relaxed
- The maxillary wax rim should have 1-2 mm horizontal overjet anteriorly and posteriorly when the patient is in a centric position
- The patient should demonstrate unstrained lips, with the vermilion border showing

B. Establishing the Occlusal Vertical Dimension

Physiologic Rest Position (PRP) - at rest, when the lips are barely touching, the occlusion rims should not touch

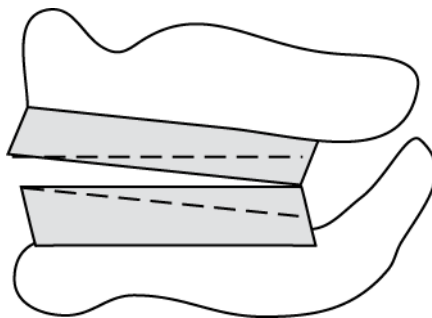
Interocclusal Distance (ID) is the space between opposing occlusal surfaces or wax rims while a person is in the physiologic rest position - **usually 2-4 mm.**

Occlusal Vertical Dimension (OVD) is the distance between the maxilla and mandible when the teeth or wax rims are in contact in centric position

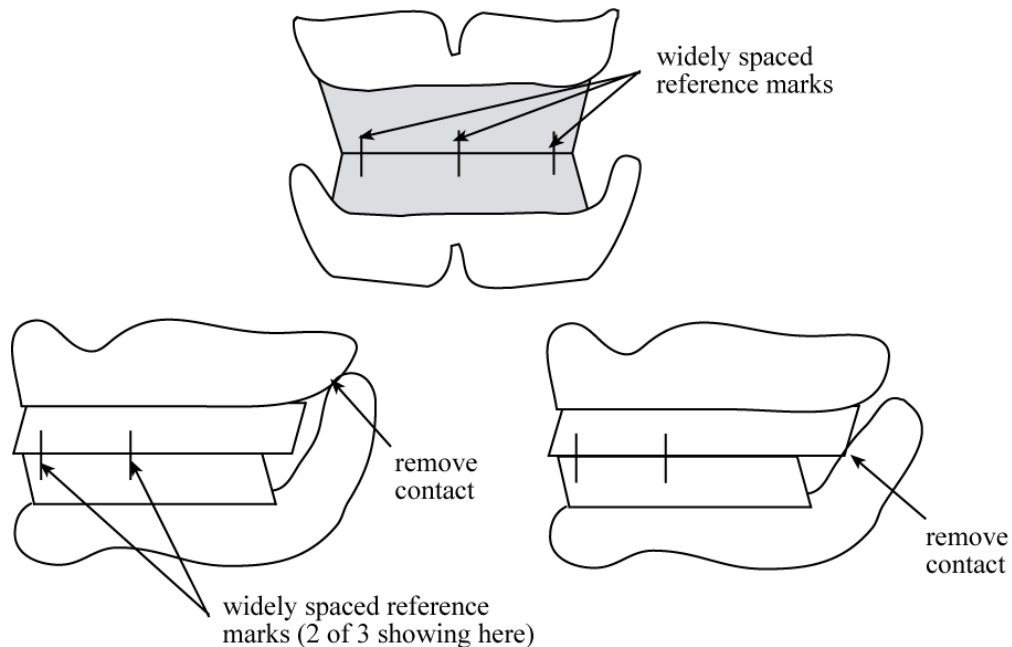
$$\text{PRP} = \text{ID} + \text{OVD}$$

Technique

1. Use an indelible stick to make one dot on the philtrum, just below the columella of the nose and another on the chin.
2. Measure the distance between the dots at physiologic rest position and also at the occlusal vertical dimension. The patient should be sitting upright without head support - jaw position is affected by posture.
3. The patient should open and close until lips barely touch - **physiologic rest position**. Place a finger below the patient's chin, then have patient close until wax rims touch - you should feel movement of the mandible through the freeway space as a double check on the measurements you made.
4. If insufficient interocclusal distance is present- remove wax from one or both of the rims
5. Use closest speaking space to confirm the occlusal vertical dimension- when speaking sibilant sounds ("s", "z", "sh", "ch"), the rims should be at least 1 mm apart
6. Use large wax formers, #7 and Cottrel wax spatulas and wax, and red-handled knife (scalpel) with Bunsen burner and torch to adjust rims.
7. Rims should make flat contact evenly along the entire length of the occlusal surface. **This is extremely critical.** If the rims touch in one area first, the patient can be forced into an eccentric or strained position.
8. If the patient does not contact evenly over the entire occlusal surface, scribe lines parallel to the opposing occlusal surface on the facial sides of the maxillary and mandibular rims. These guides should be used to parallel the rims during reduction.



9. Ensure the record bases are not in contact by scribing lines between the maxillary and mandibular dentures on three widely separated areas. Remove the record bases, superimpose the lines and check the posterior regions for areas of record base contact - eliminate contacts between the record bases, or between the record base and the occlusion rims (these will cause tilting movements of the record bases). There will be only one position where all three lines will line up.



10. Continue to adjust the rims until the interocclusal distance is 2-4 mm and there is even contact between the rims in the centric position.

A patient with **excessive occlusal vertical dimension** may have symptoms:

- Sore muscles
- Sore spots on the tissue bearing surfaces
- Rapid bone resorption
- clicking of dentures during speech

A patient with **inadequate occlusal vertical dimension** may have symptoms:

- Face looks collapsed - chin too close to the nose or protruding
- Fatigue when chewing
- Sore muscles or joints

C. Hinge Axis Location

A face-bow or ear-bow is a device used to record the relationship of the maxilla to the transverse horizontal hinge axis of the mandible, which is then transferred to the articulator. Location of the transverse horizontal hinge axis is important to prevent occlusal errors, particularly when cusped teeth are used in dentures.

Making a Facebow/Earbow Transfer:

1. Mark the facial midline on maxillary wax rim
2. Heat the edentulous bite fork, center and insert it into the facial surface of the maxillary occlusion rim on the fork, about 1-2 mm from the occlusal surface. Make sure all prongs insert into the wax, and attach firmly. If you overheat the fork, it will melt the wax and make attachment difficult
3. Place the bitefork with the attached record base in the patient's mouth, have the patient close against the opposing rim to stabilize the bite fork
4. Slide the facebow/earbow onto bite fork handle with the earbow pointing vertically at the beginning
5. Rotate the facebow until the earpieces are centered over the external auditory meatae, then center the assembly
6. Establish the third point of reference - Whip Mix uses Nasion; Hanau should contact cheek at infraorbital foramen
7. Tighten the assembly on the bite fork, ensuring the record base is fully seated
8. Loosen the earpieces and remove carefully
9. Attach to articulator in a centered position
10. Zero the incisal pin and incisal guidance table, lock the condylar elements in the hinge position and then attach a mounting ring to upper member of the articulator

Indirect Mount : (Whip Mix) attach the indirect mounting platform, remove the transfer rod/bitefork assembly intact from the facebow and attach to the mounting platform

OR

Direct Mount: if using an H2 Hanau articulator/**earbow** combination - set horizontal condylar elements to 70° and Bennett adjustment to 0° - ear piece slides on pin which is on the movable element. If using a **facebow**, this does not apply. Lower the bite fork handle to the lower mark on incisal pin or match the third point of reference attachments.

11. Adjust a cast support under the bite fork
12. Mix **fast set** or **mounting plaster** to a creamy consistency - apply to ring and wet cast surface
13. Close the articulator. Once set, remove the ring and cast and add mounting stone to make the mounting smooth and neat.

Centric Position

A centric position is an acceptable reference position for complete denture treatment that is:

1. Conducive to health - not pathogenic
2. Relatively repeatable - so the patient can find stable occlusal contacts easily
3. A hinge position - allows change in the vertical dimension easily and so the patient can find stable occlusal contacts easily
4. A relatively symmetrical position - avoids muscle strain which might occur in excursive positions

Many prosthodontic and occlusion textbooks use the term “**Centric Relation**” (CR) to define the position that the mandible should take in relation to the maxilla for the purpose of arranging the occlusal contacts on a denture (or extensive crown and bridge case). It is usually defined by the position of the condyles, rather than the teeth. Centric relation can be thought of as a **treatment position**, which is not necessarily ideal or normal in the natural dentition.

“**Centric Occlusion**” (CO) is usually defined as the maxillomandibular position determined by the position of the teeth (when present), and is sometimes considered coincident with maximum intercuspation, habitual closure or other tooth-related position. The problem with both of these terms (CR and CO) is that they have been defined differently by various investigators, and differently over different time periods.

Where is CR?

The most recent definition of centric relation in the Glossary of Prosthodontic Terms is:

*“The maxillomandibular relationship in which the condyles articulate with the thinnest avascular portion of their respective disks with the complex in the **anterior-superior** position against the slopes of the articular eminences. The position is independent of tooth contact. This position is clinically discernible when the mandible is directed superiorly and anteriorly. It is restricted to a purely rotary movement about the transverse horizontal axis.”*

Other definitions of centric relation have included:

- a. Rearmost, Uppermost, Midmost (RUM)
- b. Most posterior

Posterior positioning of the condyles is no longer considered desirable for several reasons (*Celenza*):

1. In joints there is usually thickening (buttressing) of the bone over the area of the articular surfaces –the thickest part of the bone of the articular eminence is in the anterior portion of the glenoid fossae, not the posterior area
2. The articular disk is in a superior-anterior position
3. The neurovascular supply of the retrodiscal pad is posterior to the articular disk - if the condyles articulated in a most posterior position, these tissues would probably be impinged upon
4. Cartilage usually covers articular surfaces - fibrocartilage covers the anterior portion of the glenoid fossae, not the posterior, and articular cartilage covers the superior and anterior surfaces of the head of the condyles, not the posterior surfaces
5. Posterior most positions usually require operator force to obtain, and it is possible that this pressure may force the condyles down posterior slope of fossa, or cause flexing of the mandible

For the purpose of fabricating dentures, we will accept the superior-anterior definition for Centric Relation, which we will use as our Centric Position

Remember, however, that **clinically** the dentist cannot determine the actual position of the condyles at the time jaw relations records are made, and so that the actual condylar position cannot be assured, even if we agree on a definition of centric relation

Reasons for using CR in edentulous patients

- a. Allows function to all positions
- b. Conducive to health (non-pathologic)
 - *Brill et al* - pain and loss of occlusal sense when not in CR
 - *Reynolds* - 24% of normal population has CR=CO
- c. Convenient - relatively centered condyles (*Celenza*)
- d. More reproducible (*Grasser*) - easier to set a stable maximum intercuspation

- e. If the OVD is changed, condylar inclination will not have to be readjusted if an arcon articulator is used (*Celenza*)
- f. CR is not far from CO at same occlusal vertical dimension (*Wilson and Nairn*)

Reasons's for NOT using CO in edentulous patients

- a. CO may be a dysfunctional position (must palpate muscles, TMJ to ensure no dysfunction) (*Brill et al*)
- b. The actual position is more difficult to determine - studies have shown it is not as reproducible. **Patients cannot tell where centric occlusion or a habitual position is** with bulky wax rims in position. Basically there is no habitual position with new wax rims (*Crum & Loiselle; Brill et al.*)
- c. Since CO is not reproducible, the influence of other variables on the centric record cannot be assessed (*Yurkstas and Kapur*) e.g.:
 - Wax consistency
 - Biting force
 - Symmetry of guidance
- d. CO may lead to dysfunction - no studies to absolutely prove this hypothesis

When to use CR

- a. When **entire** occlusion being restored (i.e. no remaining posterior centric stops)
- b. When complete, fixed, or removable partial dentures involve the entire occlusion
- c. if a **nonpathologic** natural occlusion exists (posterior centric stops present), and there is no valid reason to change it, then restorations should be made in maximum intercuspation

How to obtain CR

The Dawson method (bimanual manipulation) produces reasonably good results:

1. The patient should be placed in a slightly supine, position
2. Place notches in the occlusion rim to aid in stabilizing the record bases with index fingers on the rim, and thumbs under symphysis
3. Jiggle the lower jaw – the mandible should freely arc
4. Allow the patient to close the last portion
5. **DO NOT PUSH THE MANDIBLE or dislodge the record base**
6. **The registration media must be dead soft** , when the patient close into it

What type of registration media to use

1. Never use wax if you can use something else! Waxes produce the least accurate interocclusal records. Numerous studies with dentate patients have even shown that the most accurate mountings are achieved when NO MATERIAL is used with DENTATE casts where the patient has stable contacts (i.e. no rocking when placed together - you need to remove all positive bubbles to check for this). Alternatively, for dentitions that do not have stable contacts, elastomeric materials produce more accurate interocclusal records than wax. For best records for complete or removable partial dentures:
 - a. Use no material for tooth borne RPD's with stable occlusal contacts.
 - b. Use elastomeric bite registration material (e.g. Memoreg) with record bases and wax rims for CD's & most RPD's. Record the entire occlusal surface for stability. Use small 'V' shaped notches on the occlusal rim surface.

Procedure for recording the centric position and mounting the mandibular cast:

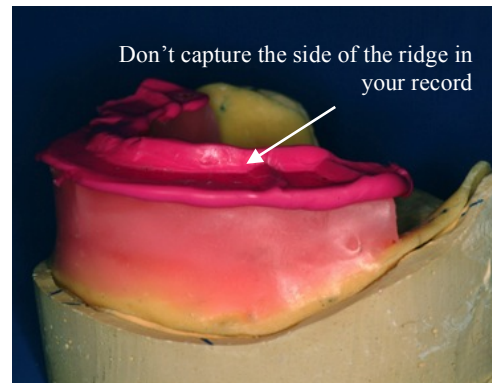1. Place 3 widely separated marks between the maxillary and mandibular wax rims as you did previously and check that the record base heels do not touch
2. Place two sharp 'V'-shaped notches in the wax in the premolar and molar areas of the maxillary and mandibular rims (1-2mm deep). Make sure there are no undercuts in the rims or the 'V'-shaped notches
3. Place the record bases and occlusion rims intraorally and rehearse making the centric position record without recording media.
4. Place a thin layer of elastomeric registration material over the entire arch of the mandibular rim.
5. Stabilize the mandibular record base using index fingers on the flange (or in a recess in the occlusion rim) and the thumbs under the symphysis.
6. Ask the patient to open, relax, and slowly close
7. You should be able to gently arc the mandible in a hinge like motion - without translation of the mandible, without much splinting
8. The patient slowly closes, and the operator uses tactile input to ensure the mandible does not move suddenly forwards or to the side
9. The patient should close until the occlusion rims are almost touching (1 mm apart). Ask the patient to stop as soon as this position has been reached, or as soon as they feel they



are just barely touching the rims together. If you see contact between rims ask the patient to stop closing, so they do not contact the rims and possibly translate from hinge position.

10. Never instruct the patient to bite firmly - this can cause translation/ inaccuracy.
11. Stabilize the patient's mandible while the material sets (never make a record without keeping your hands in place - if you feel movement during setting, redo the record).
12. Hold this position for approximately 1 minute (or other required set time of your media) and have the patient open and remove both rims together. Separate carefully.

13. Reseat and ensure the record is repeatable. Make sure the record does not capture the sides of the occlusion rims. If it does, it will be difficult to confirm whether the record was taken at the hinge position, because the portion of the registration capturing the sides of the rim will guide the patient into the same closure whenever they close – it will look repeatable only because the patient cannot close in any other position.



14. Remove the records and rims and seat your casts into the record bases extraorally. Ensure the record bases fit together with no space between the rims and the records. If you do see spaces, look for interfering contacts between casts and or rims that may be preventing full seating into the records. Do NOT mount the casts unless you can get full seating into the registration. As a last resort, make a new record to ensure the first record is not inaccurate.
15. Increase the height of the incisal pin 1 mm., and invert the articulator.
16. Place wax rims together, and lute them together with sticky wax - 4 spots between the wax rims or use tongue blade sticks and sticky wax to immobilize your casts during mounting. **If you mount your casts without immobilizing them, you can introduce a mean occlusal discrepancy of close to 1.6mm** (vs. 0.25 mm with sticks & sticky wax) (Gunderson & Siegel, J Prosthodont 2002).
17. Mix mounting plaster to creamy consistency - place on cast and ring - close articulator - smooth the mounting plaster. Return the incisal pin to its original height after the record has been removed. The occlusal rims should be touching evenly, over the entire occlusal surface with no contact of the maxillary and mandibular casts or record bases. **Only the occlusions rims should be contacting.**

Protrusive Records

When a balanced occlusion is selected, a protrusive record should be made, in order to set the condylar guidance.

1. The patient should be allowed to protrude a minimum of 5-6 mm (for ease of determination) but less than 12 mm (maximum travel of the condylar element on the most articulator).
2. Elastomeric registration material is placed over the entire mandibular rim and the patient closes in an anterior position.
3. The registration media must interdigitate with the opposing "V-shaped" notches placed previously.
4. The record is taken at a height greater than the established vertical dimension.
5. The record bases and registration are removed, placed on the articulator.
6. The condylar elements are released from the hinge position, the instrument protruded, and the records approximated. The condylar elements are rotated until there is maximum interdigitation of the registration and opposing occlusal rims.
7. ONLY the wax rims and registration should contact. If the casts and/or record bases contact, eliminate the contacts and reseat into the record.
8. The lateral component of condylar guidance (Bennett Angle) can be set arbitrarily at 15° or the lateral component can be determined using the formula: $L = (H/8) + 12$
9. When a monoplane occlusion is selected, the protrusive record may be omitted. However, it may be advantageous to alter the occlusal plane angle in patients with steep condylar guidance, in order to improve denture stability. This cannot be assessed if the condylar guidance has not been set on the articulator. If a protrusive record is not obtained, the condylar guidance should be set at 0°.

References

1. Brill N, Schubeler S and Tryde G. Influence of occlusal patterns on movements of the mandible. *J. Prosthet. Dent.* 12:255, 1962.
2. Celenza F. The theory and clinical management of centric positions: II. Centric relation and centric relation occlusion. *Int. J. Periodont. and Rest. Dent.*, 4:63, 1984.
3. Crum RJ, Loisel RJ. Oral perception and proprioception: a review of the literature and its significance to prosthodontics. *J. Prosthet. Dent.* 28:215, 1972.
4. Grasser GN. An evaluation of terminal hinge position and neuromuscular position in edentulous patients. Part 1. Maxillomandibular recordings. *J. Prosthet. Dent.* 36:491, 1976.
5. Reynolds JM. Occlusal wear facets. *J. Prosthet. Dent.* 24:367, 1970.
6. Wilson J, Nairn RI. Occlusal contacts in mandibular retrusion. *Int J Prosthodont.* 2:143, 1989.
7. Yurkstas A and Kapur K. Factors influencing centric relation records in edentulous mouths. *J. Prosthet. Dent.* 14:1054, 1964.

Selecting and Setting Denture Teeth

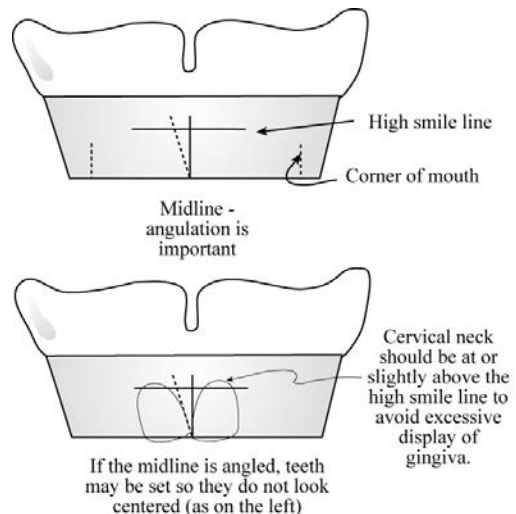
Reference Marks on the Occlusion Rims, Record Bases and Master Casts

When a dental laboratory technician will be setting the denture teeth, it is critical that the occlusal vertical dimension, the lip support, the angulation and overjet of the wax occlusion rims be determined correctly, for the technician will not have the benefit of patient contact to help them set the teeth in proper position. After accurately adjusting these aspects of the occlusal rims, the dentist should place some additional reference marks on the occlusion rims to aid in tooth selection and placement.

A. Maxilla

In the maxilla, reference marks should include:

Midline of the maxillary rim - Use a #7 wax spatula to score a line demarcating the position of the midline of philtrum of the lip. This is one of the most critical references to record. Ensure the mark is a line, not just a dot, which parallels the patients overall facial midline. Otherwise the incisors can be set at an angle, making the set up look off center. The mandibular midline can be marked at the same time.



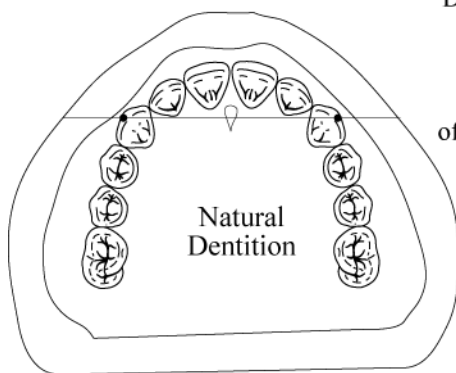
Corners of the mouth - Use a #7 wax spatula to mark the corners of the patient's mouth, when closed, at rest. This approximates where the distal of the canine teeth should terminate. Use the flexible Trubyte Auto-Rule to measure around the circumference of the rim between contralateral marks - tooth size of the six anterior teeth can be read off the ruler in mm or by the Dentsply letter code (A,B,C,etc.)

High Lip line -Use a #7 wax spatula to mark the highest point the upper lip reaches when the patient smiles. The maxillary anterior teeth should be selected so the

cervical necks lie at or above this line. If shorter teeth are selected, the esthetic result will be compromised.

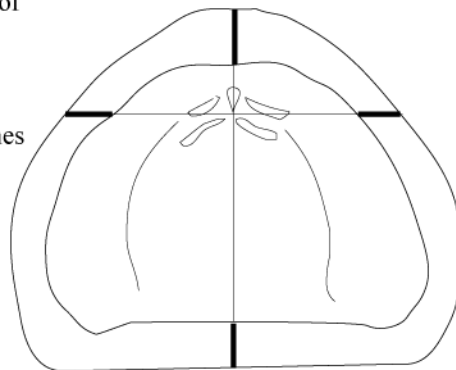
Palatal Midline - With a pencil (NOT an indelible stick) and a straight edge, draw a line through the middle of the incisive papilla and the mid-palatal raphe, extending it onto the land area of the cast. Check your occlusal rim for symmetry about this important midline. If it is not symmetrical, adjust the rim prior to sending it to the lab for placement of teeth.

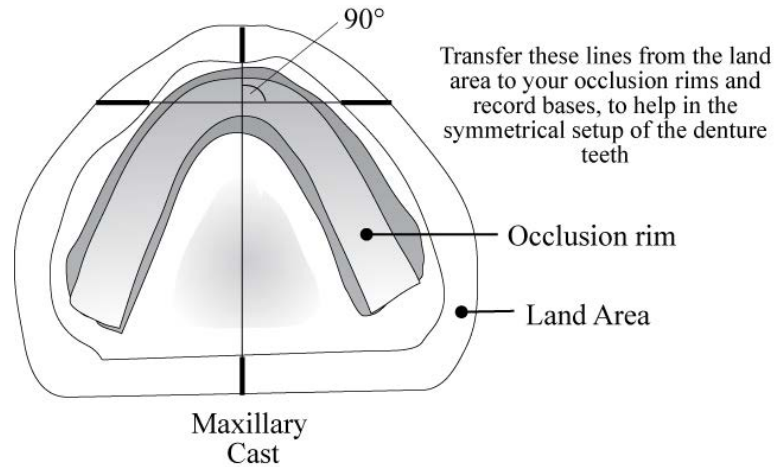
Distal aspect of the incisive papilla - In the edentulous maxilla, a line drawn perpendicular to the palatal midline, passing through the distal aspect of the incisive papilla should normally intersect with the cusp tips of the canines. Draw this line with pencil and a straight edge, on the cast, extending out to the land area. It will provide verification that your tooth size selection was correct. Additionally, it will provide another line to verify the symmetry of the wax rim and denture tooth setup. On average, the facial surface of the **central incisors should be approximately 8-10 mm anterior** to this line.



Draw a line at the back of the incisive papilla, perpendicular to the midline- this defines where the cusp tips of the replacement canines should be. Note the papilla changes position after extractions, due to ridge resorption and tissue changes

Line through the incisive papilla and the midline raphe define the midline for the denture teeth setup, and should be scribed on the cast and record base





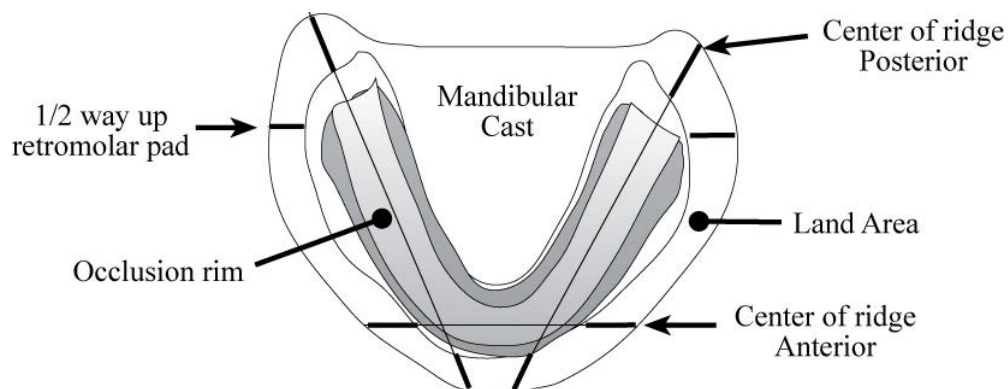
B. Mandible

In the mandible, reference marks should include:

Half way up the retromolar pad - the posterior aspect of the occlusal plane should intersect the midpoint of the pear shaped pad, to ensure the occlusal plane is not set too low (can cause tongue biting) or too high (can cause strain as tongue struggles to place the food bolus back on occlusal table)

Center of the posterior mandibular ridge - Draw this line with a pencil and a straight edge, on the cast, extending out to the land area. The lingual cusp of the maxillary posterior teeth should be centered over this line to ensure denture stability, by reducing fulcruming forces during function

Center of the anterior mandibular ridge - Draw this line with a pencil and a straight edge, on the cast, extending out to the land area. If the anterior teeth are set too far anterior to this line, heavy fulcruming forces can cause tilting and dislodging of the mandibular denture, particularly when the mandibular ridge is severely resorbed.



Selecting Anterior Teeth

Selection of anterior teeth requires a combination of science and artistic ability based on observation. Measurement, formulas etc. are only a starting point – use your eyes and common sense.

Size

- Use existing teeth as a guide:
 - Too big or small? If so, use other means of establishing size
 - Does patient like them? Do you?
 - If acceptably close, use Boley gauge to measure width and length of central incisors and check with the paper **Trubyte mould guide chart** (measurements for central are given; pictures are life size).
- **High Lip Line** gives indication of inciso-gingival length (minimal gingival display)
- Mark **the position of the commissures** of mouth with patient relaxed, mouth closed (position of distal of canines - use the Auto-Rule to pick a corresponding mould e.g. C, D, E, F etc.)
- **Bizygomatic width measured** by facebow divided by 16 = width of the central incisor; divided by 3.3 = width of 6 anteriors
- Pre-extraction casts or photographs can be useful, if available

Shape

- Tooth shape does not correspond to facial shape, but the Trubyte system can be a good starting point for experimenting; there are proven no male/female characteristics
- Use existing teeth as a guide — do they look too good to you?
- USE COMMON SENSE AND OBSERVATION

Shade

- Tooth shade darkens with age, but the suggestion that there is any correlation with skin and hair colour is suspect
- We will use the Dentsply Trubyte shade guide for Portrait IPN acrylic teeth
- Don't show a patient all shades in the shade guide outside of the mouth – patients will almost always pick the whitest shade
- Instead show patient 2 or 3 shades under lip and ask their opinion (colour perception is affected by background) – disinfect the tabs afterward

- Use the Portrait Shade number and not the Vita shade code when prescribing denture teeth from the Portrait shade guide. (Portrait numbers begin with a "P" and are listed as the bottom-most shade code on the shade tabs)
- Anterior and posterior tooth shades are the same (e.g. anterior shade P3.5 corresponds with posterior shade P3.5)
- Shade selection for porcelain restorations should be made with the Vita shade guides
- If you need to match a porcelain restoration to denture teeth, select the Vita shade for porcelain and pick the corresponding Portrait shade (P1-P34) for the Vita shade (the Vita shades are listed on the top of the Portrait shade tabs)
- The patient should choose the shade guided by the dentist – if they want the whitest teeth possible, offer your opinion, don't persuade
- Use the squint test for value (brightness) - squinting reduces the influence of hue - if the teeth look too bright while squinting, suggest something less bright

Material

- Porcelain teeth are becoming less prevalent
- Acrylic much easier to set and adjust; they will last life of denture (5-7 years)

Porcelain	Acrylic
- wear less	- new materials wear well
- more translucent	- better teeth have layers to improve transluc.
- brittle - fracture easily if dropped	- resilient - acts as shock absorber
- don't bond to base (stain, fall out)	- chemically bonds to base
- difficult to adjust/set	- quieter; gum sticks

Selecting Posterior Teeth Form (shape of the posterior teeth)

Anatomic (40 °, 30°, 20°(semi-anatomic), 10°)

- More esthetically pleasing (especially in the premolar region) – use for patients with esthetic concerns, if there are no contraindications (severe ridge resorption, jaw malrelations, uncoordinated jaw movement)
- Use when a balanced occlusion is desired – they are easier to balance. Select a tooth cusp angle similar to the condylar inclination
- Use when coordinated jaw movements are present

- Use when setting teeth for a single denture opposing a natural dentition (easier to interdigitate)

Non-anatomic (0°)

- Use when there are jaw size discrepancies (use in cross-bite situations, Angles Class III)
- Use when a reduction in horizontal forces is desired (severe ridge resorption)
- Use when a patient has uncoordinated jaw movements are present
- Poorer esthetics, due to lack of cuspal inclines
- Set with no incisal guidance (no overbite) when used in a monoplane occlusal scheme
- Selection of tooth form also depends on:
 - Condylar and incisal guidance inclinations - easier to balance using a cusp angle similar to the condylar inclination
 - Curve of Spee - determined by the dentist
 - Angulation of occlusal plane - determined by the dentist

No tooth form has been proven most efficient – most patients can't discern a difference.

Posterior Tooth Size :

- The Trubyte mould chart has a list of corresponding size to match the anterior teeth already selected
- Select by determining distance of distal of canine to position of beginning of ascending ramus (29, 30 mm. etc), also look at mould guide chart
- The posterior teeth should at least approximately match the cervico-incisal height of anteriors (no large discrepancies)
- Selection may be affected by the interocclusal distance available for setting teeth (amount of space for 'S', 'M', or 'L' teeth) - if limited space, choose a shorter mould
- buccolingual size of teeth can affect the tongue space – choose smaller teeth if tongue space is limited

Prescribing Denture Teeth

Keep your Trubyte denture tooth mould guide chart at school so you can select teeth easily. The teeth in mould guide are printed life size. For most cases we will prescribe **acrylic** denture teeth, of the **Portrait** type. **IPN** is a proprietary type of acrylic that has improved wear resistance. The chart below shows how to complete the prescription for denture tooth selection.

	Shade	Mould	Tooth Form
Max. Ant.	P22	22E	
Mand. Ant.	P22	H	
Max. Post.	P22	30L	33°
Mand. Post.	P22	630	0°

Step 1
Select a shade using the shade guide

Step 2
Select a maxillary anterior mould and the corresponding mandibular mould from the chart in the mould guide

Step 3
Decide on an occlusal scheme and select posterior molds based on the table

Trubyte Portrait Recommended Combinations for Lingualized Occlusion:

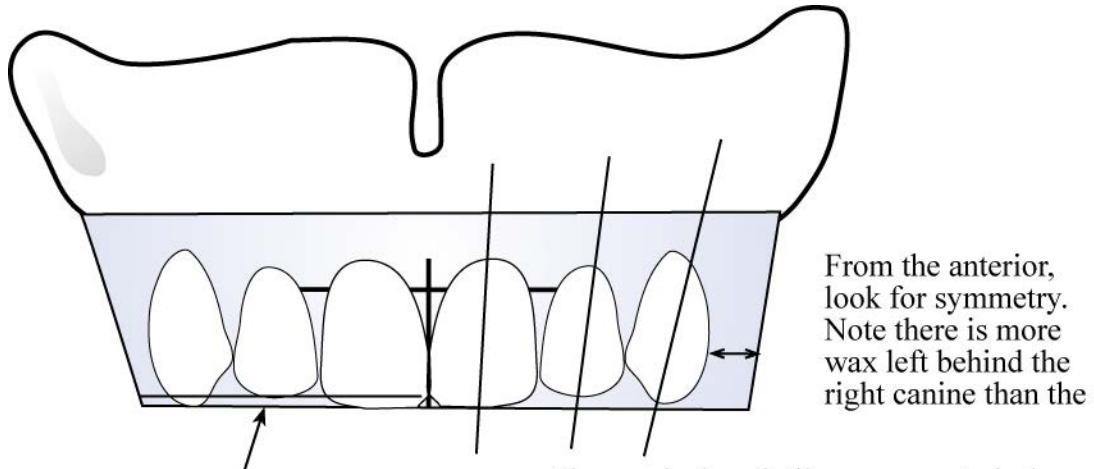
Recommended Set-up Combinations		Maxillary 33°		
		30L	32L	34L
Mandibular	22°	530		
			532	
	0°	630		
			632	
			634	

Other tooth series and other companies also offer a range of denture teeth that also differ in cost and quality - the dentist should select the proper tooth quality, not the laboratory.

Setting Anterior Teeth

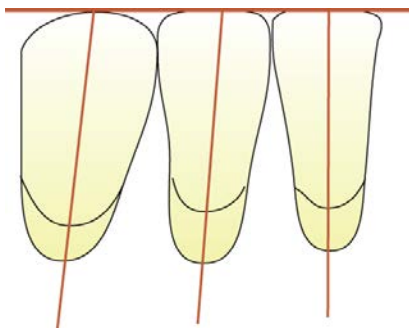
Additional Reading:

1. Watt DM, MacGregor AR. **Designing Complete Dentures**. 2nd ed. 1986. Bristol, Wright. Ch. 2 Biometric guides to the design of complete dentures, pp 3-31.
2. Landa, LS. Anterior tooth selection and guidelines for complete denture esthetics. In Winkler S, ed. **Essentials of Complete Denture Prosthodontics**. 2nd ed. 1988. Littleton, Mass., PSG Publishing Co. pp 202-16.



The incisal edge of the central incisor and canine should be placed at the occlusal plane, while the lateral should be placed approximately .5mm above the level of the occlusal

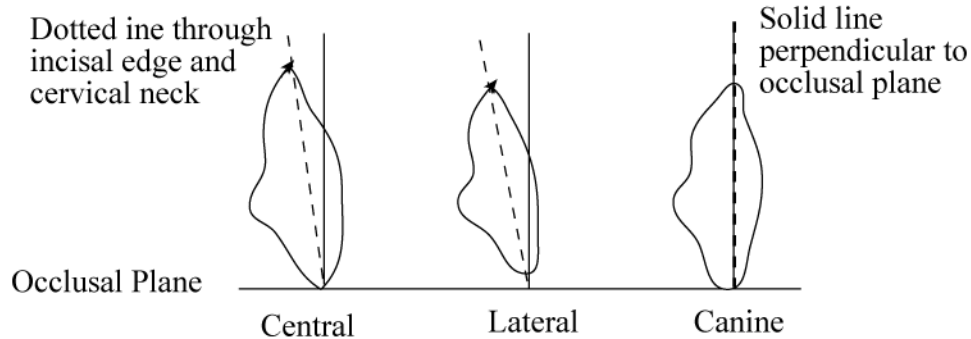
The cervical neck tilts more posteriorly as one moves from the central incisor to the canine. The greatest height of the free gingival margin is slightly distal to the mesiodistal center of the tooth.



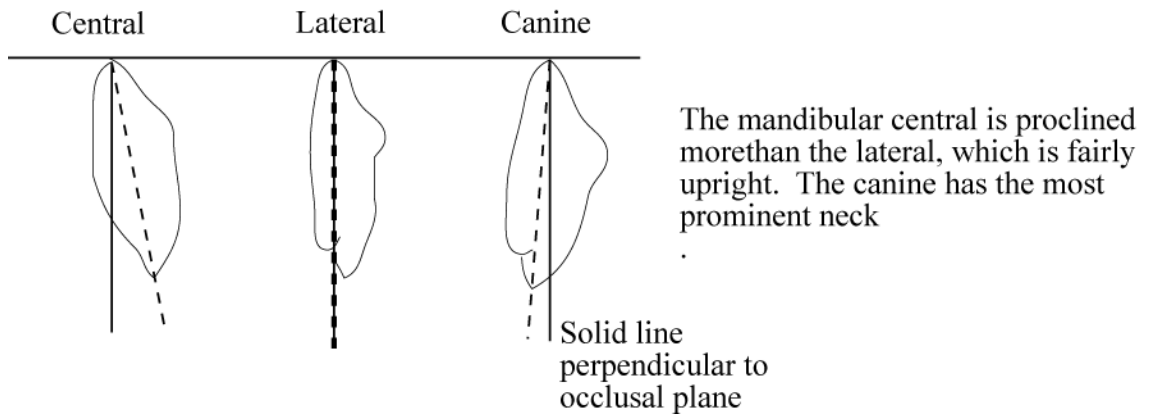
Mandibular anterior teeth incline similar to the maxillary teeth, but the incisal edges are placed at a similar level to each other.

The mandibular anterior teeth are set even with the occlusal plane (no overbite) for monoplane and lingualized occlusal schemes.

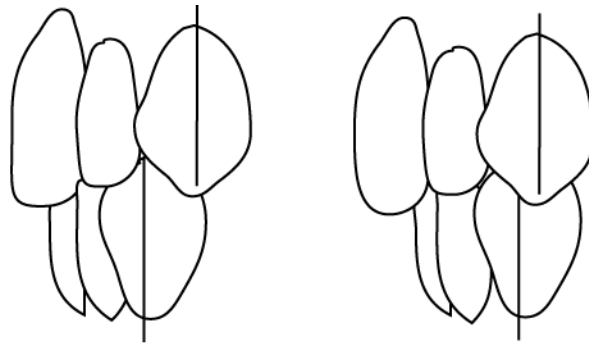
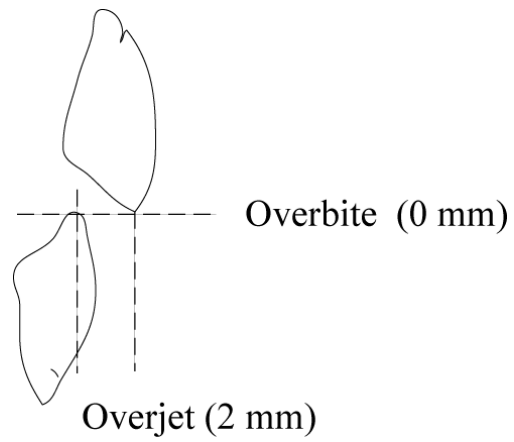
Canines should be tilted more posteriorly than other anterior teeth, and should have a more prominent cervical neck



The facial surface of the central incisor is approximately perpendicular the occlusal plane, while the neck of the lateral incisor is slightly depressed. The neck of the canine is more prominent



- check symmetry against land area and land area reference lines
- 1-2 mm horizontal overlap (overjet), .5 mm vertical overlap (overbite) – anterior teeth don't contact in centric position
- for monoplane occlusions, NO OVERBITE is set - this means you need to determine the type of posterior occlusion to be set before the anterior teeth are set



From the lateral aspect, there should be one half tooth offset (left) between the maxillary and mandibular teeth to ensure the posterior teeth can have a normal cusp to fossa relationship.

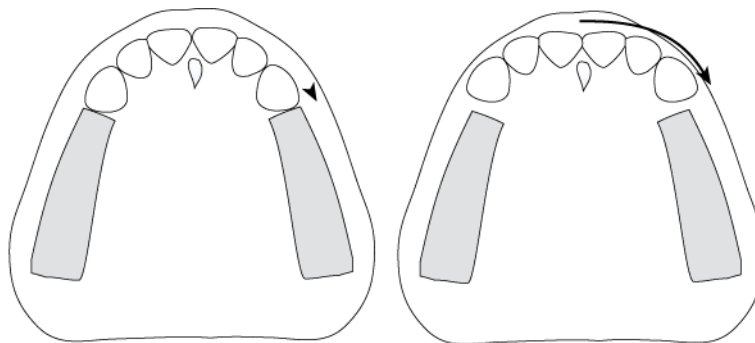
Intraoral Checks:

- Maxillary central incisors should lightly touch inside of vermilion border of lower lip for 'F', 'V' sounds; 'S' sounds — incisal edges should approximate each other
- Incisal edges of maxillary incisors should follow line of lower lip when smiling ('smile line')
- Crown removing forceps can be used to bodily move and angle teeth that need repositioning
- Do not hesitate to grind the record base and/or tooth to modify position if teeth do not appear properly positioned – don't let the record base dictate the position
- The nasolabial angle should be approximately 90°; if there is insufficient support, the lip will thin, lengthen and the vermilion border will be reduced or lost
- The junction of glossy oral mucosa should just be barely visible when the lips are slightly separated. If it is not visible, then the lip is probably insufficiently supported; lips should meet at the junction of the oral and transitional epithelium
- Excessive blockout of the record base in the anterior will tend to push the lip out at the height of the vestibule, shortening and distorting the lip and nasolabial angle – the teeth will look short when denture is finished and the flange is properly contoured
- Lipping:
 - too much horizontal overlap
 - palatal contour too constricted
 - anterior teeth too far labially
 - broaden & thicken contour for tongue contact
 - arch form too broad

Remember that anterior teeth are not set just where precursors were - Stability is important

AVOID THE DENTURE SMILE: TEETH TOO SMALL, NOT SHOWING, TOO STRAIGHT ACROSS; "CHICLETS"

In setting the maxillary teeth, make sure the central and lateral incisors are placed so they begin to turn along the curvature of the arch. Note the parallelism with the



A common mistake is to set the anterior teeth too straight across the front, so that the canine is not placed sufficiently posteriorly or palatally to be in harmony with the posterior teeth (right). Note the difference in visible land area in the incisal and canine areas.

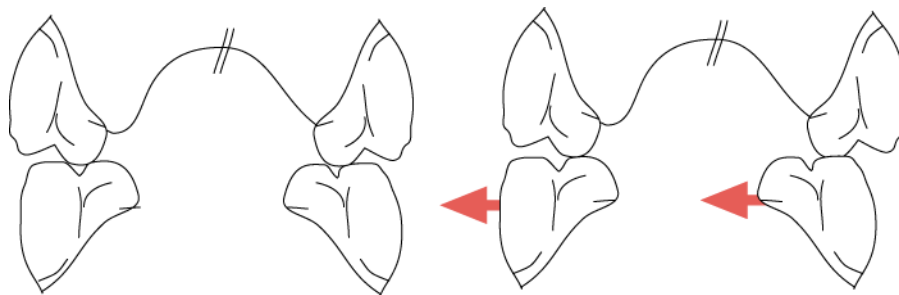
Philosophies of Denture Occlusion:

There are many philosophies of arranging the denture occlusion, but no definitive scientific studies have proven one type of occlusion to be clearly superior to another. Clinicians have developed some principals, based on experience, to make it easier to determine which type of occlusal scheme to use. We will learn two occlusal schemes (there are others):

1. Lingualized Occlusal Scheme

Lingualized occlusion is a type of bilaterally balanced occlusal schemes. The philosophy of a balanced occlusal scheme is to improve denture stability by maintaining contacts on both sides of the denture in excursions during function. Patients feel more confident and have less discomfort when dentures are more stable. There is indirect evidence that balanced occlusion may reduce ridge resorption and allow for increased functional forces in excursions. Lingualized occlusion differs from traditional fully balanced schemes by having only the lingual cusp of the maxillary tooth contacting the mandibular teeth to maintain this contact.

- a) Centric position contacts are set maxillary lingual cusp to fossae of the mandibular posterior teeth. No anterior contacts should be present in the centric position.
- b) Anatomic teeth are used in the maxilla opposing a flat-cusped, or shallow cusped mandibular tooth.
- c) Overbite is incorporated into the anterior setup to improve esthetics, and eccentric contacts.
- d) In eccentric movements there are contacts on both the working and balancing sides of the denture, whether excursions are protrusive or lateral in nature. Anterior teeth make grazing contact in excursions.

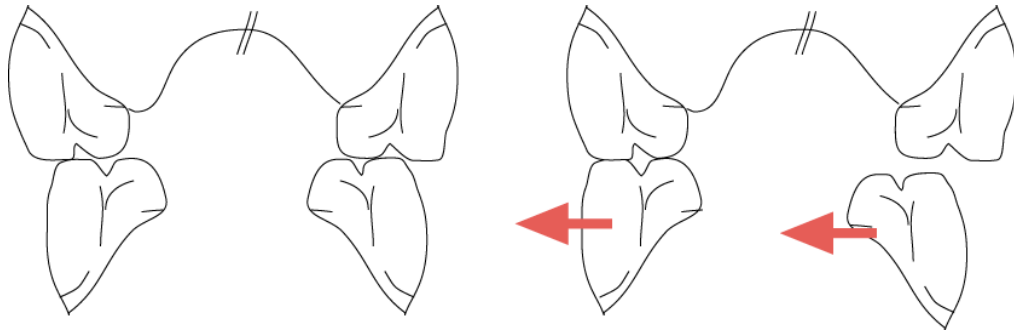


- e) The condylar guidance, incisal guidance, angle of the occlusal plane, cusp angle of the denture teeth, and compensating curves placed during the posterior tooth setup all affect the ability to achieve these contacts.

- f) **Advantages:** More natural appearance (anatomic teeth) of the maxillary teeth with forces centered over the mandibular teeth
- g) **Disadvantages:** Technically more challenging than monoplane scheme, no definitive studies to prove improved stability;
- h) **Contraindications:** Extreme cases of the following: difficulty in obtaining repeatable centric record (incoordination, jaw malrelations, severe ridge resorption (lateral forces displace the denture) may more easily be handled with a monoplane scheme.

2. Monoplane Occlusal Scheme

- a) Cuspless teeth are set on a flat plane with 1.5- 2 mm overjet – there is no cusp to fossa relationship. No anterior contacts are present in the centric position

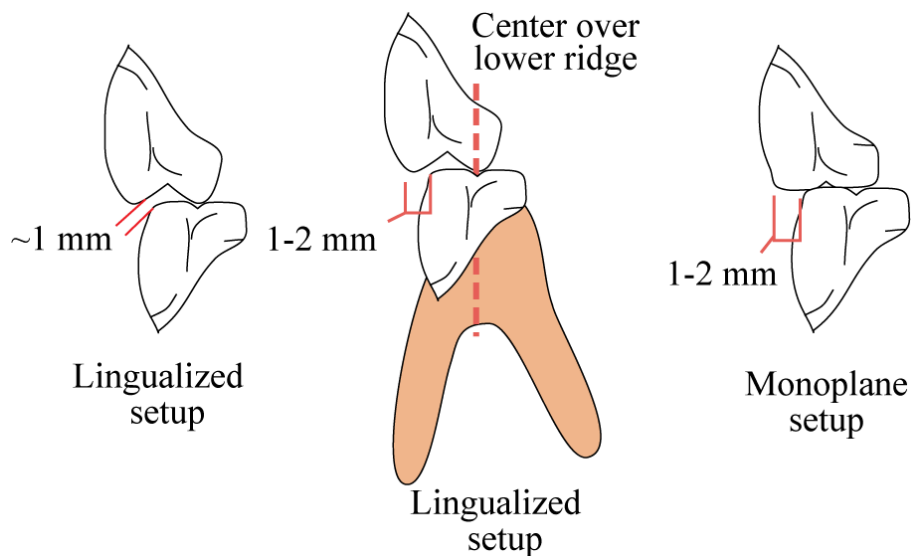


- b) No overbite is incorporated into the anterior setup. An overjet of 2 mm is used to create an illusion of overbite.
- c) **In eccentric movements there usually no contacts on the balancing sides** of the denture, depending on the condylar inclination and other aspects of the denture setup. Anterior teeth make contact in excursions. Modifications have been made to the monoplane scheme, so that balancing ramps, compensating curves can be added in an attempt to improve stability.
- d) The philosophy is based on the idea that by eliminating cusps, lateral forces on the dentures will be reduced, thereby improving denture stability. This scheme was proposed as a means to simplify the arrangement of denture teeth.
- e) **Advantages:** Technically easier to achieve, especially if there is difficulty in obtaining repeatable centric records (muscle incoordination), or if there is a skeletal malocclusion, or severe residual ridge resorption.

- f) **Disadvantages:** Poorer appearance (non-anatomic teeth); can be unstable if the condylar guidance is steep (posterior teeth separate, leaving only the anteriors in contact)
- g) **Contraindications:** The patient has high expectations for improved appearance, very steep condylar guidance may make a monoplane scheme less stable, unless modifying ramps or compensating curves are used.

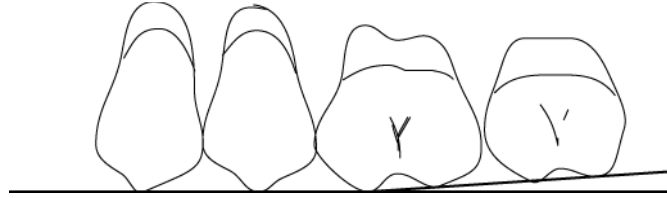
Setting Posterior Teeth:

- Posterior teeth are set for function, while the anterior teeth are set mainly for esthetics and phonetics (although placement can affect incising ability and fulcruming potential of the denture)
- Stability is increased when centric contacts are on flat surfaces, rather than on inclines
- The most important cusp in the posterior setup is the maxillary lingual cusp which is set over the middle of the mandibular ridge (mandibular central fossae will be placed here)

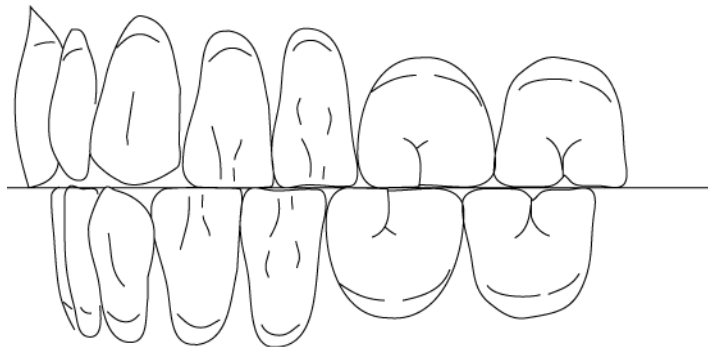


- Ensure 1-2 mm of overjet in order to prevent cheek or lip biting
- Mandibular buccal cusps are lateral to the residual ridge and have more tipping potential for the lower denture
- For a lingualized setup, there should be 1mm separation of the maxillary and mandibular BUCCAL cusps

Lingualized Maxillary Tooth Setup: Maxillary teeth are set with the distal cusp of the first molar and the cusps of the second molar raised slightly above the occlusal plane. This provides a curve of Spee to aid in maintaining posterior contacts.

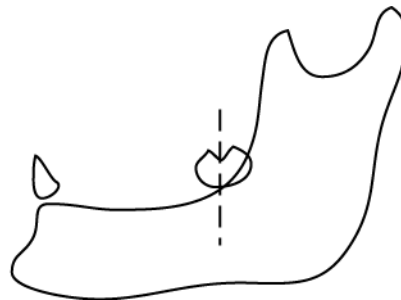


Monoplane Denture Tooth Setup: All denture teeth are set flush with the occlusal plane, in maximum contact with the opposing teeth. No overbite is present.




- Posterior teeth should not be placed over a sharply ascending ridge. If there is not enough room, set three, rather than four posterior teeth if necessary. When doing so, eliminate the 2nd premolars, since the first premolar usually has a longer neck (important for esthetics) and it has a lingual contour that smooths the transition from the anterior teeth to the posterior teeth (in some moulds). Don't eliminate molars as they provide a greater number of centric and excursive contacts.

Do not place the posterior teeth over the ascending portion of the ramus (posterior to dotted line). Functional forces will cause the denture to tilt or shift, causing looseness and/or discomfort. Instead, eliminate the 2nd premolars from the setup, if necessary.



- Usually set the maxillary posterior teeth first as their placement has more impact on esthetics, especially the first premolar.

- Set the maxillary teeth, then the mandibular antagonist
- The posterior teeth should be set to follow the occlusal plane of the record base - the teeth should not be set on a plane higher than that intersecting a point 1/2-2/3 up the retromolar pads
- In some cases where there is a ridge size discrepancy or skeletal malocclusion, the tooth positions may have to be modified into cross bite positions. Often it is easier to set cusplless teeth in a monoplane scheme, because it is not necessary for cusps and fossae to interdigitate
- Don't let the record base dictate the buccolingual inclination of teeth:

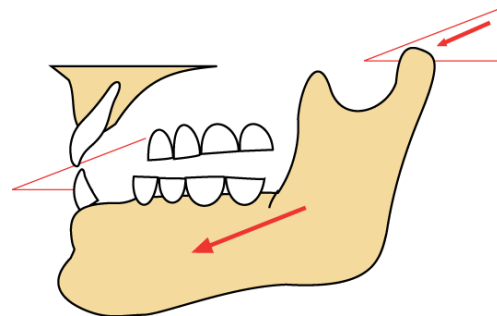


If the cervical neck of the tooth hits the record base(left), the correct axial alignment may not be possible, causing tipping of the tooth (right), which will reduce the overjet, making balancing difficult and adversely affecting appearance.

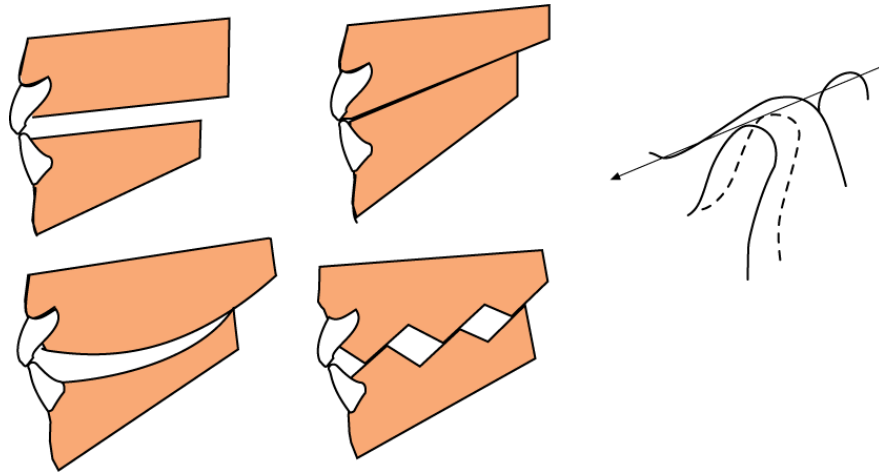
Achieving a Balanced Lingualized Occlusion

- Normally, when the mandible moves in lateral or protrusive directions, the condyles move down the slope of the glenoid fossae, causing the whole mandible to move downwards and the posterior teeth to separate. This is separation, called

Christensen's phenomenon, makes any balanced occlusion (such as lingualized occlusion) more difficult. **When condylar inclination is steep, using a shallow cusped tooth (e.g. Anatoline), rather than a non-cusped mandibular tooth for will make balancing easier to achieve.**

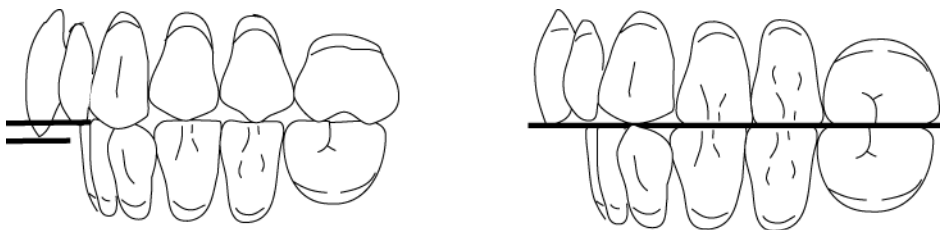


- the separation of posterior teeth, is affected by several factors (Hanau's quint):
 - a) Condylar angulation (recorded by the protrusive record)
 - b) Incisal guidance (set by the dentist when making dentures)
 - c) Cusp angle and fossae depth (selected by the dentist)
 - d) Occlusal plane (determined by the dentist in forming the wax rims)
 - e) Curve of Spee and Curve of Wilson (depends on inclination that teeth are set)

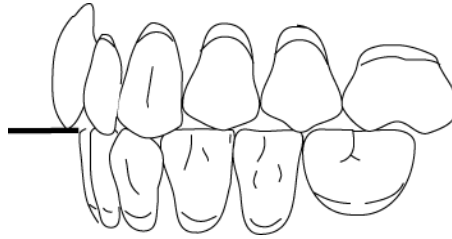


As the condyle moves down the fossa, posterior teeth separate (upper left). Contacts can be maintained by tilting the occlusal plane to more closely approximate the angles of the condylar and incisal guidances (upper right), introducing more of a curve to the occlusal plane (lower left), or adding teeth with higher cusp angles (lower right).

- Because setting of anterior teeth affects the incisal angle, which can also cause separation of the posterior teeth, the clinician should stipulate how anterior teeth are set. In general, for a monoplane occlusion, no overbite is set. For lingualized occlusion, an overbite may be set to improve appearance if the posterior teeth can balance in excursions 2-3mm from centric. If the incisors prevent the posterior teeth from balancing by discluding them (usually this occurs when very little horizontal overlap or overjet is present), then the incisal angle can be set to zero (i.e. no overbite).



When 1.5-2.0mm of overjet can be set, a lingualized occlusion (left) can have overbite set. Monoplane occlusion (right) should normally have no overbite set.



When very little overjet can be set (usually due to ridge position and jaw relation problems), a lingualized occlusion (left) should be set to have less, or in some cases, no overbite. This will prevent incisor contact causing immediate separation of the posterior teeth in excursive movements.

Occlusal adjustment

Occlusal adjustment is almost always required to optimum occlusion.

Developing & Adjusting **CENTRIC** Contacts for Lingualized Occlusion

Goals: Even distribution on all posterior teeth

- No anterior contacts
- No posterior buccal cusp contacts :1mm of space between buccal cusps
 - 1-2mm of buccal overjet
- Even weight darkness (mention target/bulls eye)
- No contact on marginal ridge 1st PM
- Max Lingual cusp tip to FLAT mandibular contact area (fossa, marg ridge)

Rules for whether to move teeth in wax or adjust with a bur:

Adjust with bur if:

- All contacts all showing in close to proper position
- All contacts present but not even in weight
- Contact(s) not in proper position, but minor reshaping will move them
- Contacts not all showing, but appear close to contacting
- Contact(s) is/are on an incline, and can be adjusted to move to flat area

Move teeth in wax if:

- Lack of contact **or** position of contact will take a lot of time to correct
- Lots of adjustment is required to correct
- Tooth is rotated/tilted so contacts/relationships/appearance is/are poor

Principles for Adjusting Centric Contacts

- Incisal pin should be just barely out of contact with the incisal table
- Don't lose occlusal vertical dimension (note pin setting)
- Mark with articulating paper on both sides of the arch simultaneously
- Don't tap too hard – could cause teeth to move, lose occlusal vertical dimension
- Use fresh articulating paper
- Heaviest contacts will have a 'target' or bulls-eye appearance (dark ring with empty center); heavy contacts are darker and wider. Adjust these to establish similar size and darkness as other contacts
- Use medium Brasseler H79 bur tip easy for adjusting, sides flat for recontouring
- Remove marks with dry gauze – no water, no toothbrush
- **Adjust centric stops before adjusting excursions:**
 - Deepen/reshape mandibular contact area first
 - Reshape maxillary cusps if on inclines, or need greater amount of adjustment
 - Ensure no buccal cusp contacts, adequate overjet
 - When done, note a solid sound (sharp rap, woodpecker knocking on a tree)
 - Contacts should not feel bouncy or sound dull on the articulator

Developing & Adjusting **ECCENTRIC Contacts for Lingualized Occlusion**

Rule: Develop acceptable centric stops before adjusting excursive contacts. Ensure you don't remove centric stop contacts during adjustments in excursions

Goals:

- Even distribution of contacts on all teeth in excursions for balancing type
- Anterior contacts in excursions should not disclude posterior teeth
- NO MAXILLARY POSTERIOR BUCCAL cusp contacts in excursions
- At least one working and one balancing contact on each mandibular posterior
- Balancing contacts should never be heavier than working contacts
- Excursive contacts should appear as lines not dots on mandibular teeth
- Adjusted occlusion should feel very smooth in excursions on the articulator, and intraorally. No jumps or bumps should exist.

Rules for **moving teeth in wax *versus* **adjusting with a bur** are the same as for centric contacts**

Principles for Adjusting Excursive Contacts

- Incisal pin should be just barely out of contact with the incisal table
- Mark with articulating paper on both sides of the arch simultaneously
- Mark excursive contacts in one colour, then mark centric stops with a different colour prior to adjusting, so centric stops can be identified, and not eliminated.
- Use fresh articulating paper
- Use medium Brasseler H79 bur tip easy for adjusting, sides flat for recontouring
- Remove marks with dry gauze – no water, no toothbrush
- There should be NO CONTACT ON MAXILLARY BUCCAL cusps in any excursions
- If there are inadequate excursive contacts (uneven weight, missing) then lighten existing excursive contacts by making cuspal inclines more shallow, removing heavy contacts, reshaping cusps
- **IIIF** – balancing contacts will be on Inner Inclines of Functional Cusps
- Reshape mandibular teeth first. Only adjust the maxillary lingual cusp if there are heavy contacts on inclines, or if a greater amount of adjustment is needed
- Eliminate any posterior contacts between teeth and denture bases

Adjusting Contacts with a Monoplane Occlusion:

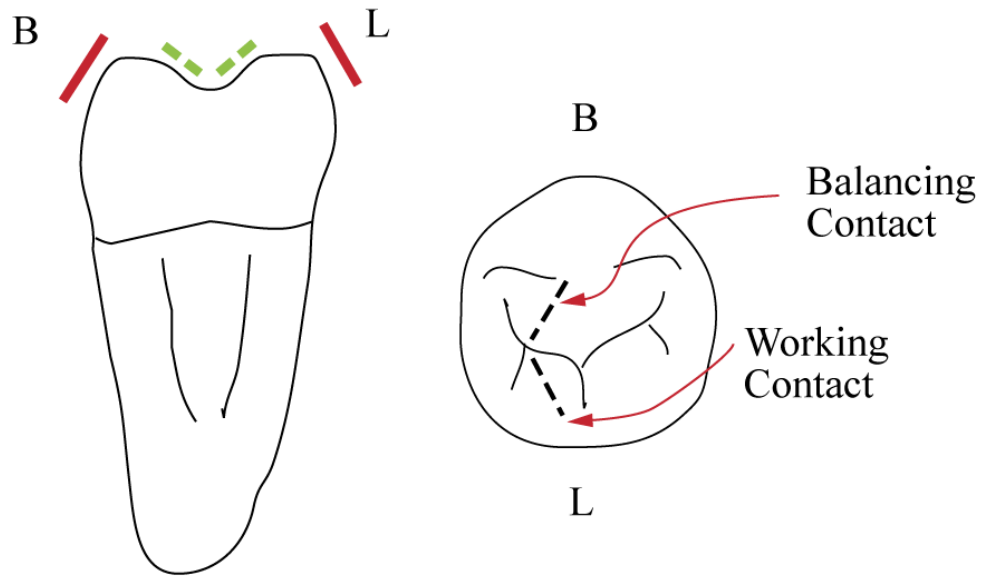
For adjusting centric stops or excursions in a monoplane occlusion, use a large, flat sided bur and reduce the occlusal surface of premature contacts with side of the bur level with the occlusal plane until the surrounding and contralateral contacts are even in weight and distribution.

Balanced Occlusion in a Nutshell:

IIF

=

Balancing Contacts



--- Inner Inclines (inside of cusp)

— Outer Inclines (outside of cusp)

(Inner Inclines of Functional cusps)

Balancing contacts should be lines, not points
Balancing contacts should never be heavier than working contacts

The Wax Try-in

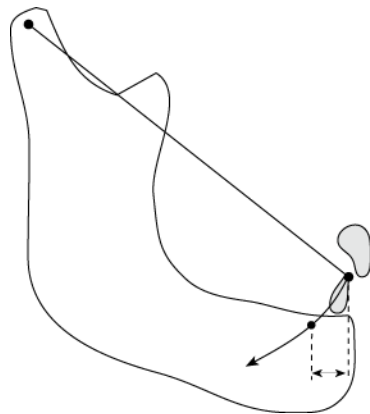
The purpose of the wax try-in appointment is to verify all aspects of the denture tooth setup – the appearance, phonetics, occlusal relationships and patient comfort. Normally two try-in appointments are required, an initial wax try-in and a final wax try-in. Never overlook problems you find in the wax try-in stages. If you or the patient find problems, the problems may be more difficult or impossible to change after processing. Failure to make changes at this stage might require removal, resetting and reprocessing of the teeth on the finished denture – procedures that are more costly and time consuming.

A. Initial Wax Try-in

The main purpose of the initial try-in is to verify the appearance of the anterior teeth and the accuracy of the centric record. Changes will almost always need to be made at this appointment. At the initial try-in appointment, the dentist should make any changes which would be difficult for the technician to make without the presence of the patient (e.g. many esthetic problems with the anterior teeth). Other changes can be prescribed for the technician to make.

1. Occlusal Vertical Dimension and Interocclusal Distance

The occlusal vertical dimension should be verified using the same techniques that were used previously. At this point it is critical that 2-4 mm of interocclusal distance can be measured and felt, and that the posterior denture teeth do not contact during assessment of the closest speaking space. If the vertical dimension is incorrect, it should be changed before altering other aspects of the denture setup, since it can affect the relationship of the maxillary and mandibular teeth and the facial esthetics.



As the mandible opens (ie. by increasing the occlusal vertical dimension) the incisal edge moves downward and backward. By increasing the vertical dimension, more overjet is obtained and there is a tendency toward moving to a skeletal Class II situation.

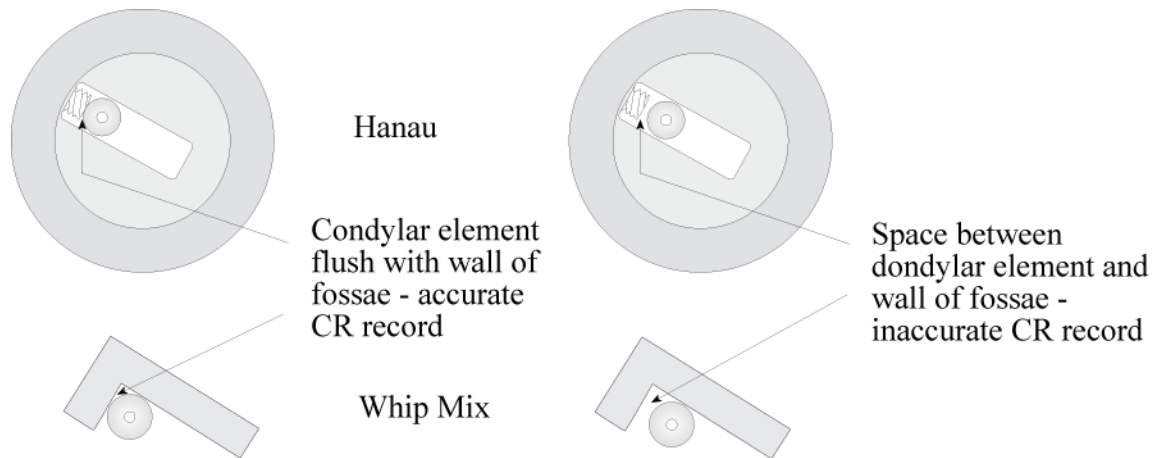
If the vertical dimension is too great, assess whether one or both arches will require reduction in height. Changes can be done in the laboratory, since a change will necessitate the resetting of all the teeth in at least one of the arches. Remember, that the height of both the anterior and posterior teeth must be changed. If only the posterior teeth are changed, there will be an undesired effect on overbite relationships, esthetics, and balancing contacts. Assess how these changes will affect the overall appearance of the patient, before sending the dentures to the laboratory.

2. Centric Position Contacts

Mark the centric contacts with articulating paper while stabilizing the mandibular denture and placing patient into centric relation (you will need an assistant to hold the articulating paper). Place a thin line of polyvinyl siloxane bite registration material over the occlusal table and make a new centric relation record. Using a small amount of registration material will improve the accuracy of the record by providing less resistance during patient closure. The opposing cusps should not penetrate the registration, but you may be able to see the articulator markings through the thin areas of the material. This is a preliminary means of confirming the record was acceptable.

To confirm the accuracy of the articulator mounting, loosen the centric locking mechanism of the articulator, so the condylar elements are free to translate. Seat both record bases and interdigitate the teeth into the centric record. **If the mounting is accurate, the condylar elements should be firmly seated in the hinge position** (no space between the condylar ball and the wall of the fossae) **and the teeth should perfectly interdigitate with the recording medium** (no space around the cusps). If either of these criteria are not met, the record should be remade. If a second record shows the mounting to be inaccurate, the mandibular cast should be removed from the mounting ring, half of the mounting plaster ground from inferior aspect and the cast should be remounted, using the new record.

Lateral view of condylar element of Hanau and WhipMix articulators with accurate and inaccurate CR records:



3. Tooth Position

a. Canine Relationship The most critical tooth position relationship for the initial try-in appointment is the half tooth offset between the maxillary and mandibular canine teeth. If this relationship is not present for a setup of anatomic teeth, a space between the anterior and posterior teeth will be required in order to produce correct interdigitation of the posterior teeth. Technicians will encounter problems setting the correct canine relationship when there are jaw size discrepancies, malocclusions, or improper contouring of occlusal rims at the jaw relation record appointment. *Prior to sending the setup back to the laboratory for final setup, the dentist should determine how to eliminate a canine relationship discrepancy.* It could involve one or more of the following:

1. Reducing or increasing overjet
2. Reducing or increasing facial arch circumference of one or both occlusion rims
3. Altering vertical dimension
4. Bodily moving teeth more facially or more lingually within esthetic limits
5. Changing axial inclination (tilting teeth) of one or more teeth

b. Verify overjet relationships - to help prevent cheek or lip biting. If there is inadequate overjet, the teeth may require bodily movement or tilting to 1-2 mm.

c. Verify patient comfort with the tongue space (denture teeth not set too far lingually) by asking the patient to comment on the comfort of the dentures or their ability to speak with the dentures

4. Excursive contacts

If the canine relationship is not acceptable, and will be changed, excursive contacts will change as well. Nonetheless, the presence of working and balancing contacts should be evaluated both visually and with articulating paper intraorally, and then compared to the contacts on the articulator, to verify the accuracy of the articulator settings. If the contacts appear noticeably different (check the amount of space between posterior teeth in excursions) or the markings are different between the intraoral and articulator situations, the protrusive record should be remade, and the condylar inclination reset.

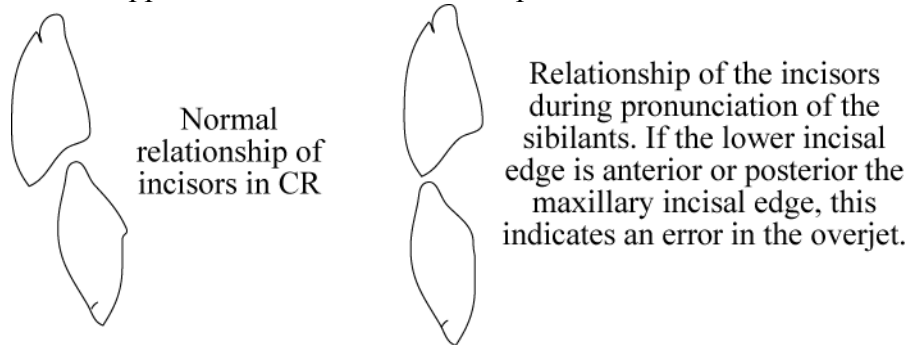
5. Esthetics

Check the amount of the incisal display, the harmony of the maxillary teeth with the smile line, the accuracy of the midline, and the cant of the occlusal plane. Check for proper soft tissue profile, contours, lip support, display of the vermilion border, and correct nasolabial angle. Ask the patient for their opinion of the appearance, prior to voicing your opinion so that you avoid biasing the patient. It can be helpful to have a family member or friend attend the wax try-in to provide a third opinion on appearance. If you or the patient have reservations about the appearance, the problem should be clearly resolved prior to final processing. Never attempt to persuade a patient out of a concern they may have – the problem will be yours later if the patient still does not like the appearance. It is helpful to the technician if the dentist can make changes, but major changes can be delegated to the lab, if necessary.

6. Phonetics

Phonetics can be assessed more readily at the try-in stage since denture teeth have replaced the relatively bulky occlusion rims. Patients will normally find speaking more comfortable at this appointment. Watch for lisping. It can be caused by non-uniform overjet of the anterior teeth, diastemas between teeth or faulty palatal contours. Sometimes a crowded tongue space can adversely affect phonetics. If the initial wax try-in has a diastema between anterior and posterior teeth due to canine malrelationship, this can allow for the escape of air, and produce altered phonetics. In most instances phonetics can not be corrected until the final wax tryin, when the diastemas should be eliminated. If patients have not worn dentures for an extended period, or if the new denture will have dramatic changes in contour, tooth position and/or vertical dimension, the patient should be allowed to read a passage from a magazine out loud for 5 minutes to allow them time to assess phonetics and comfort.

Sibilant sounds ('S', 'Z', 'T', 'CH', 'SH', 'sixty-six', 'Mississippi') - upper and lower incisors should approach end to end relationship

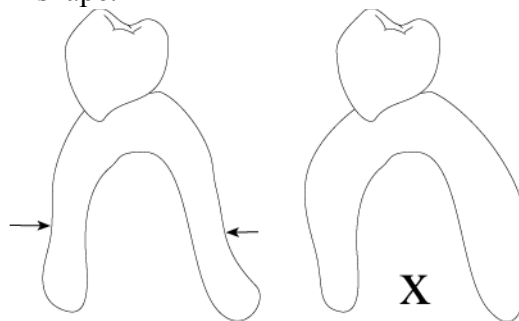


Fricative sounds (F, V, 'Fifty-Five', ask patient to count from 50 to 60) - upper incisal edges should just touch the posterior one third of the lower lip

7. Denture base contours

Denture base contours can affect phonetics, comfort and retention. In general, the denture bases should not be convex in shape.

External contours should be slightly concave (arrows), rather than convex, to aid retention and comfort



Remove excess wax to provide room for tongue if you note the patient struggling with phonetics, or noting that they do not have enough tongue space. Ensure that the denture base is not unduly thick or thin. Excess bulk will impair comfort, and a base that is too thin will be structurally weakened.

8. Patient Input

At any point in the try-in appointment, ask for patient input, using open ended questions ("How do you like the appearance?" rather than "Don't the new dentures look great?"). If the patient sounds unconvincing in their approval of the setup, attempt to get more information by asking further questions. Do not let the patient dissuade you that the wax try-in stage should be rushed in the interest of saving time.

B. Final Wax Try-in

The second try-in appointment is used to confirm that the prescribed changes have had the desired effect. While it is possible that no changes may be required at this appointment, the clinician should not shy away from making further alterations if any aspect of the setup is not acceptable. **If any changes have been made to the vertical dimension, centric position, tooth position, or excursive contacts, then these aspects of the setup should be rechecked.** Otherwise, the final try-in appointment should be used to concentrate on the aspects of esthetics, phonetics and patient comfort. By this appointment diastemas will have been closed, and phonetics should be similar to that in the final denture, making assessment easier.

C. Completion of the Laboratory Prescription

Complete the laboratory prescription, requesting processing, finishing and polishing of the denture. You should also request the lab remount the dentures and adjust the occlusion to compensate for processing changes. Ask the lab to fabricate a remount record and casts, which will be used at the delivery appointment. Add any special instructions for touchup of the wax-up or other unique requirements. Send your remount jig to the laboratory with the dentures.

Delivering and Adjusting Complete Dentures

1. Prior to the patient appointment :

- Use gauze or cotton roll to inspect the entire tissue surface for spicules or sharp edges (gauze will snag on the spicules)
- Smooth any sharp areas
- Inspect the posterior border - it should be 2-3 mm thick, gradually tapering to the soft palate (right), not thick or ending in a sharp ledge (left)



- if necessary use a large acrylic bur to blend any sharp changes in the flange periphery with the art portion of the denture

2. Insert the maxillary denture first:

- ask patient if it is comfortable, identify areas of discomfort for potential adjustment
- if there is any resistance to seating, proceed immediately to next step

3. Check the adaptation of the denture base using pressure indicating paste (PIP)

- remove a small amount of paste and place it on a mixing pad, reseal the jar to avoid cross contamination
- dry the denture, place a thin coat of pressure indicating paste on the tissue surface with a stiff bristled brush
- leave streaks in the paste, but use enough material so that the denture appears more the colour of the indicating material rather than the denture (i.e. more white than pink)

4. Seat the denture firmly over the first molars (not the palate), remove carefully and inspect the paste:
 - a. Burnthrough - no paste left, indicates excessive pressure that should be relieved
 - b. Streaks remaining - no tissue contact; other areas need to be relieved to produce contact
 - c. Paste remaining with no streaks - proper amount of contact
 - relieve pressure spots using acrylic burs
 - take care with undercuts - they will cause burnthrough as the denture is seated past the height of contour of the soft tissue. These areas may not require adjustment.

5. Repeat the procedure until the denture seats fully with relatively uniform contact - minimal streaks, no gross burnthrough.

6. Check for peripheral overextensions.
 - bring the indicating material at least 5 mm over peripheries on to the external surface of the dentures
 - seat denture and carefully manipulate tissues as per border molding
 - facial flanges should fill vestibule but NOT be dislodged by movements or manipulation
 - if the denture dislodges, use PIP on peripheries to ascertain area, and reduce
 - use special attention to frenal areas - they can be common sources of irritation

7. Remove the paste with gauze. Use alcohol if there is some stubborn paste requiring removal.

8. Adjust for posterior overextension using an indelible marker to mark the vibrating line.

9. Replace denture and check for retention (push outward and upward from lingual of canines)

10. If the patient notices areas of excess bulk or discomfort on the external surface of the denture, coat these areas with PIP and perform functional movements to identify areas requiring reduction.

11. Set the maxillary denture aside and repeat for the mandibular denture. Have an assistant (classmate) in your office remount the maxillary denture using the remount index and jig, if the laboratory has not done so. Polish any areas of adjustment with pumice on a wet ragwheel and tin oxide on a dry ragwheel. Use sterile ragwheels and new pumice for each patient.

12. Check the occlusion. Insert both dentures, place a cotton roll between the posterior teeth on both sides and have the patient bite forcefully for one minute. This will simulate compression of the tissue after the patient has worn the denture for a period of time. Then place the patient in centric relation and visually check the occlusion. Stabilize the mandibular denture, using index fingers on the facial surface of mandibular denture and thumbs under mandible.

14. If there appears to be an open bite or very unstable posterior contacts, the heels of the dentures or the occlusal contacts may require adjustment. Use articulating film to mark the interferences and adjust the dentures to provide stable bilateral contacts.

Clinical Remount for Occlusal Adjustment

- A clinical remount involves remounting the processed dentures on an articulator for the purposes of adjusting the occlusion extraorally
- Overall, the clinical remount can save time - there will be fewer subsequent adjustment appointments, and the operator doesn't have to continually remove and replace the dentures intraorally during the adjustment procedure
- Clinical remounting allows identification of interferences that may not be seen intraorally, since occlusal interferences can cause pain or instability of the dentures. when this occurs, patients reflexly avoid the interferences, so that the problem may be difficult to identify
- While not all dentures will require an occlusal remount, we will routinely remount dentures over the course of the next several years, so that you become proficient in this procedure. All dentures with cusped tooth forms and any dentures with 0° tooth form and a demonstrated centric record occlusal discrepancy should be remounted, and the denture occlusion be adjusted for centric and excursive contacts on the articulator.

Cast Fabrication

Usually when a denture is processed, it can only be removed from the master cast by destroying the cast. Therefore, if you want to remount the dentures on an articulator for the purpose of adjusting occlusion, new remount casts will be needed. Normally you should ask the laboratory to make a remount cast and a remount index on **your** remount jig. The remount index is used in lieu of a facebow transfer for reorienting the maxillary cast to the hinge axis. If you have not requested a remount cast from the lab, one can be made as outlined below:

1. Place petroleum jelly on the tissue surface of denture
2. Blockout ALL undercuts in maxillary and mandibular dentures with plasticine, wet paper towel or Kleenex)
3. Set the denture into the index fabricated on your remount jig(or into a new facebow record, if an index has not been fabricated) attached to the articulator.
4. Vibrate fast set plaster into the denture, and attach to the maxillary mounting ring. Plaster should capture the peripheral roll of the denture flange but it should not overlap onto the external surface of the denture, or it will be difficult to remove from the cast. When plaster is set, separate the denture from the remount cast.
Alternatively casts can be made separately from the articulator and subsequently attached with mounting plaster.

Remounting the dentures

1. Clean the dentures, and seat intraorally. Place elastomeric registration material (e.g. Memoreg) over the entire mandibular arch. Stabilize the mandibular denture with index fingers.
2. Have the patient close into the material while it is still dead soft, closing just until they feel contact.
3. Remove dentures and registration. Interdigitate the dentures and stabilize with sticky wax.
4. Place maxillary denture on mounted maxillary cast, invert articulator and mount mandibular model.
5. IMPORTANT - Verify centric position after mounting by making a second record. Seat the second record, release the condylar elements and interdigitate dentures in the

record. If the condylar elements remain flush with the anterior metal stops, then continue - otherwise remake the centric position record. A second check is to mark centric contacts both intraorally and on the articulator with different colour articulating paper to ensure that the marks coincide. Do NOT adjust the occlusion until the centric record is verified.

6. Verify the protrusive record using an elastomeric registration material over the occlusal surfaces of all posterior teeth, and have the patient occlude 4-6 mm in protrusion. Set the condylar inclination. It should be similar, but not necessarily identical to that taken previously.
7. Adjust the occlusion on the articulator, using articulating film of separate colour for centric and excursive contacts. Ensure:
 - there are no anterior contacts in CO
 - there are even simultaneous, bilateral contacts of centric stops
 - that movement of teeth over antagonists feels smooth, not bumpy
 - ensure balancing contacts (lines on inner inclines of functional cusps)
 - there are balancing contacts should never be heavier than working contacts
 - light grazing contacts of the anterior teeth in protrusion and lateral excursions
8. Intraorally verify the contacts are similar and the occlusion feels comfortable to the patient
9. Check vertical dimension:
 - 2-4 mm of interocclusal distance at physiologic rest position
 - phonetics:
 - ‘F’ sounds- max. incisors touch lower lip
 - ‘S’ sounds, incisors close together maxillary and mandibular posterior teeth do not hit
10. Check the esthetics, provide care instructions

Differential Diagnosis of Post Insertion Problems

- Minimal problems if remount
- Most problems will be occlusal if denture base has been adjusted properly

Principles

Never adjust unless you can see exactly where to adjust on denture – Use indicator medium (PIP, indelible marker, articulating paper, etc.)

Patients frequently wrong in **exactly locating** source of problem

Spend time to look and think

Ask patient to describe in detail:

Where?- dentist needs to locate (PIP, tip of instrument, indelible stick)

When? (chewing only?)

How long?

Anything makes it better or worse?

Have patient demonstrate problem if you have difficulty diagnosing the cause.

Limited number of problems:

1. **Denture base**
2. **Occlusion** - interferences - esp protrusive
3. **Retention**
4. **Vertical Dimension**
5. **Allergies and Infections**
6. **Tooth Position**

1. Denture base

- impingements, spicule, sharp edges.
- Dx - PIP (never adjust unless marks)
- **sore all time**; if changes throughout day, think occlusion
- may still be occlusal, if inflammation causes swelling

2. Occlusion

ONE OF THE MOST COMMON POST-INSERTION PROBLEMS

- May require time to adjust to CR
- difficult to determine, intraorally - reflex
- interferences – especially in protrusive
- **fingers on canines** –should feel smooth
- **sore when bite**
- **fit changes** or **comfort deteriorates** through day
- **remount again** - be prepared this morning

3. Retention Problems

Short flanges

- PIP - still streaky
- fingers on canines outwards (post palatal seal).
- look for space

- may be retentive for a while if a lip seal established, until movement disturbs the lip seal

Long flanges

- burn through (PIP)
- intrudes tissue when placed
- may not dislodge if good seal, may loosen after much function or hyperfunction

Post-palatal seal

- if the denture is short of the vibrating line, the denture may bind on hard palate, (check with PIP)
- if there is inadequate tissue contact, food may get underneath the denture, bubbles may extrude as the denture is placed (check intraorally with PIP)
- if over-extended to the movable portion of the soft palate, the denture may drop during speaking, eating

4. Occlusal Vertical Dimension (OVD)

- continual and generalized pain and fatigue or muscle soreness (excessive OVD)
- no power (insufficient OVD)

5. Allergies and Infections

- rare allergies - general inflammation
- hygiene - generalized inflammation

6. Tooth Position

- instability (teeth not over ridge)
- difficulty chewing (occlusal table not long enough -esp. rational teeth)
- check and lip biting (insufficient overjet)
- esthetic, phonetic problems
- may have to grind off teeth and reset

Most Common Areas Requiring Adjustments

Maxillary

- Hamular notches – ulceration can occur if over-extended
- Labial frenum – requires adequate relief (often feels too bulky to the patient)
- Mid-line fulcrum on the bony raphe
- Zygomatic impingement

Mandibular

- Lingual frenum – impingement can cause displacement of the denture or ulceration
- Retromylohyoid overextensions - sore throat; denture moves when swallowing
- Buccal shelf overextension

Phonetic problems - wait and allow time for adaption

- add soft wax to palate and check
- if anterior poorly positioned, then remove and replace


Single Complete Dentures

Single dentures are more often fabricated in the maxillary arch, as these teeth are usually lost before their mandibular antagonists. Mandibular single dentures should rarely be considered, unless a means of stress reduction can be used - a processed resilient denture liner, overdenture or implant retained denture. Otherwise rapid and severe residual ridge resorption can result from the forces on the mandibular ridge. Single dentures tend to be difficult to fabricate for the following reasons:

1. More force from the opposing natural dentition tends to displace the denture, or cause fracture due to flexure
2. Greater forces from the natural dentition (especially anterior teeth) tend to result in severe residual ridge resorption, making denture retention & stability more difficult yet. (Combination Syndrome)
3. Tooth malpositions (extrusion, tipping, rotations) cause the denture to be less stable (difficult to balance occlusion)

Treatment differs from normal complete denture therapy in the following ways:

1. Occlusal adjustment of natural teeth may be required to level the plane of occlusion by:
 - a. reducing any severe curve of Spee
 - b. leveling steps in the occlusal plane caused by supraeruptions
 - c. alter the contour of rotated teeth to permit bilateral contacts on flat surfaces



Reduce cusps in shaded area, to level plane of occlusion

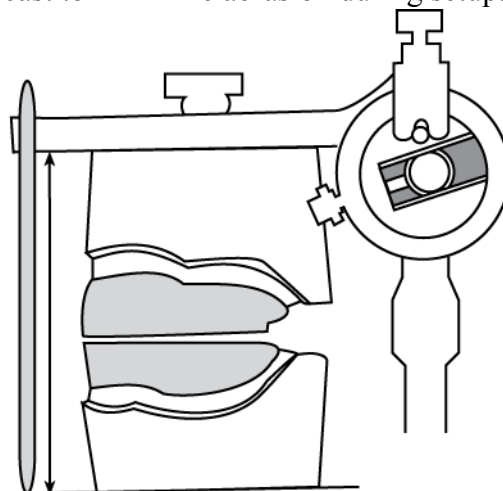
A diagnostic cast should be obtained to assess the occlusal plane. Mock adjustment can be performed on the diagnostic cast and a reduction template fabricated to aid intraoral adjustment

3. Avoid a complete single denture against an opposing 6- 8 teeth in the anterior of an arch - it can lead to resorption, or loosening or fracture of the denture

CONSIDER FABRICATING AN OPPOSING PARTIAL DENTURE IF THERE IS EXTENSIVE LOSS OF POSTERIOR TEETH IN THE OPPOSING DENTITION

4. If a partial denture is to be fabricated opposing a complete denture, the dentures should be made at the same time. RPD preparations are made, an impression taken, and the framework fabricated. While the framework is being fabricated, the final complete denture impression is made, and the record base constructed. The framework is adjusted, denture base is added to the framework and jaw relations recorded between a complete denture occlusion rim and an opposing occlusion rim on the framework. Setting the complete denture and RPD denture teeth at the same time allows maximum control of tooth positions to optimize the occlusion. Any crowns or bridges should be waxed up against the CD tooth setup for the same reason.
5. Setting of the anterior teeth is more difficult. Setting them for esthetics may result in a placement which produces excessive overbite in relation to the natural teeth. This will compromise stability of the denture. Anterior teeth are often set in a compromised position, taking esthetics and function into consideration. Maxillary teeth may have to be set higher to avoid excess overbite, which compromises display of the incisal edges.
6. Posterior denture teeth require more grinding to obtain stable centric contacts. Tip: After obtaining the proper vertical dimension, increase the incisal pin height 1mm on articulator (i.e. increase OVD 1mm) set all posterior teeth, let wax harden, return pin to original position and grind occlusion until pin touches table. Use a type IV stone (e.g. Silky Rock) on the opposing dentate cast to minimize abrasion during setup.

Increase the pin height by 1mm (arrows), so the teeth will actually be set too high in occlusion. Then reduce the pin height 1mm (to its original position), and grind the denture teeth until there are even contacts and the incisal pin rests on the



7. A cast metal complete denture base can be considered if fracture of denture has occurred repeatedly. Fractures usually are caused by the heavy forces from the natural dentition in combination with occlusal contacts on inclines (causes flexing of the denture) or impingement on a bony midline (again causing wedging forces on opposite sides of the denture).
8. Denture teeth will wear more rapidly against natural teeth. Patients must have more frequent recalls to adjust the denture occlusion to prevent changes in stress distribution.
9. Never use porcelain denture teeth against natural teeth - they can cause severe attrition of the natural teeth. It is preferable for the denture teeth to wear, rather than the natural teeth.

Diagnosing Denture Pain & Looseness: Principles and Practice

General Principles for Diagnosing Denture Problems

Clinicians can save time and minimize repeat visits for patients with complete or removable partial denture problems by employing five strategies for eliminating etiological factors: 1) establishing a differential diagnosis, 2) identifying variations from normal 3) having denture patients demonstrate their problems, 4) always using an indicating medium when making adjustments to prostheses, and 5) having the patient rate how much better they feel after adjustments.

Establishing a Differential Diagnosis

To effectively eliminate denture problems, one must correctly identify the etiology of the problem. Take a good history and perform a thorough clinical exam. Establish a list of potential causes (a differential diagnosis), rank them as to which ones occur most commonly, and begin by eliminating the causes that could most likely be causing the problem. If the cause of a problem is removed, the pain, ulceration or other related signs and symptoms should normally resolve in 10-14 days¹. Biopsy is mandatory in any lesion that fails to heal within 14 days of onset², particularly when a denture has been ruled out as the source of the ulcer. Work down the list of differential diagnoses until the problem is eliminated².

Looking for Normal

Many denture problems can be identified by inspecting dentures critically for variations from normal (Fig. 1-5). Unusual extensions, contours, tooth position, thickness and finish can all be sources of denture problems. Intraoral inspection for anatomical or tissue abnormalities or variants may also give clues to the cause of some denture problems (Fig. 6-8). If an abnormality is found, attempt to ascertain if it is related to patient signs and symptoms by correcting the denture. If the source of the problem is eliminated, there should be resolution of signs and symptoms within 10-14 days.

Have a Patient Demonstrate the Problem

Many times asking the patient to demonstrate how the problem occurs will help a clinician identify the source of the problem. If the problem occurs only when the patient chews, cut a small piece of a cotton roll, dampen it and let the patient demonstrate the location where the bolus causes the symptom (Fig 9). If a problem occurs during speaking, singing, drinking, or opening wide have the patient replicate the circumstances. Have the patient describe what they feel is happening and watch carefully to determine the cause of the problem. Attempt to eliminate the cause and recall the patient in 10-14 days to ensure the problem has resolved.

Never adjust without using diagnostic media

Clinicians normally check occlusion of restorations using an indicator such as articulating paper or shim stock. Similarly, denture adjustments are more accurate and effective, when made using an indicating medium. Pressure or fit checking medium, indelible markers and articulating paper can all be used to aid in the location and the determination of the degree of adjustment that is required.

How Much Better?

If a patient is asked if a denture adjustment has made a problem 'better', the most likely response will be 'yes'. But if the adjustment has only made things feel 20% better, the patient may be dismissed only to be seen again at a subsequent appointment. A less biased question to ask is 'how does that feel?' Then, if the patient states that the problem feels 'better', they should be asked to rate how much better it feels in terms of a percentage. An ulceration may not feel '100%' better at the end of an appointment but it should feel closer to 90% than 20%.

Diagnosing Denture Problems

Causes of Denture Pain

- Occlusion
- Denture base (fit & contour)
- Vertical dimension
- Infection
- Systemic disease/condition
- Allergy (rare)

Causes of Denture Looseness

- Occlusion
- Denture base (fit & contour)
- Tooth Position Problems
- Poor Anatomy

It is probable, but not proven, that occlusion and denture base fit cause more repeat visits for denture-related pain and looseness than the other causes listed above. Infection, systemic diseases and allergies should never be overlooked, especially when ulcers or pain are persistent despite interventions.

Many clinicians deal with denture-related pain by grinding the denture base in the area of the reported pain. This type of blanket solution is akin to a physician prescribing a broad spectrum antibiotic to all patients reporting with a sore throat and runny nose. It assumes, incorrectly, that the denture base is the source of all denture pain.

Diagnosing the problem requires a thorough history from the patient, including specific information such as:

- When did it start?
- How long does it last?
- What makes it better?
- What makes it worse?

Combined with the information of the clinical exam, this information will help establish a differential diagnosis, ranking most likely causes at the top of the list. The clinical examination should use the strategies of identifying variations from normal, having denture patients demonstrate their problems, and always using an indicating medium (Fig. 10-21).

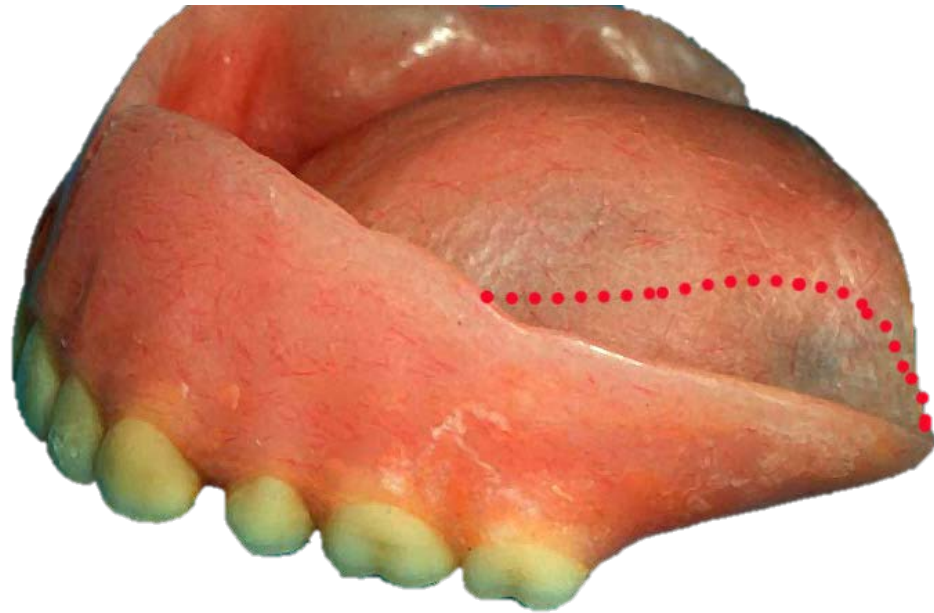


Figure 1. The posterior buccal flange of this denture is shorter than normal. It should be extended to the dotted line. Compound or light-cured acrylic resin could be added to the periphery to attempt to extend the border. When this was done, the patient's denture became markedly more retentive.

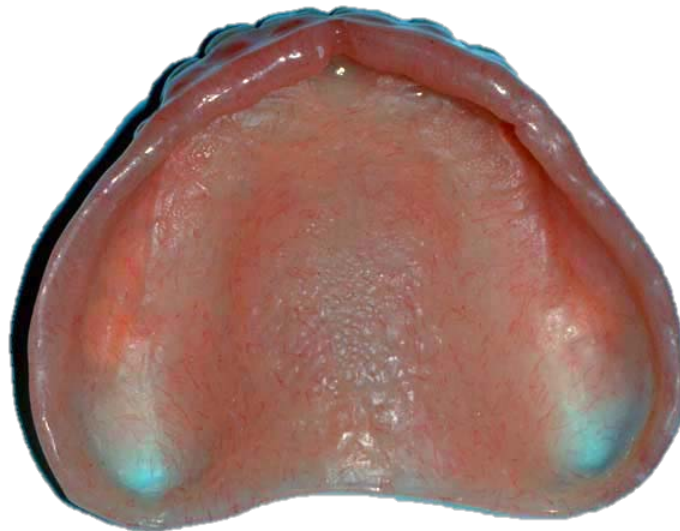

Figure 2. The transparent areas of resin over the tuberosities provide a clue that the opposing denture is contacting the denture, thereby wearing the base. Such denture base contact can cause loosening of the denture.

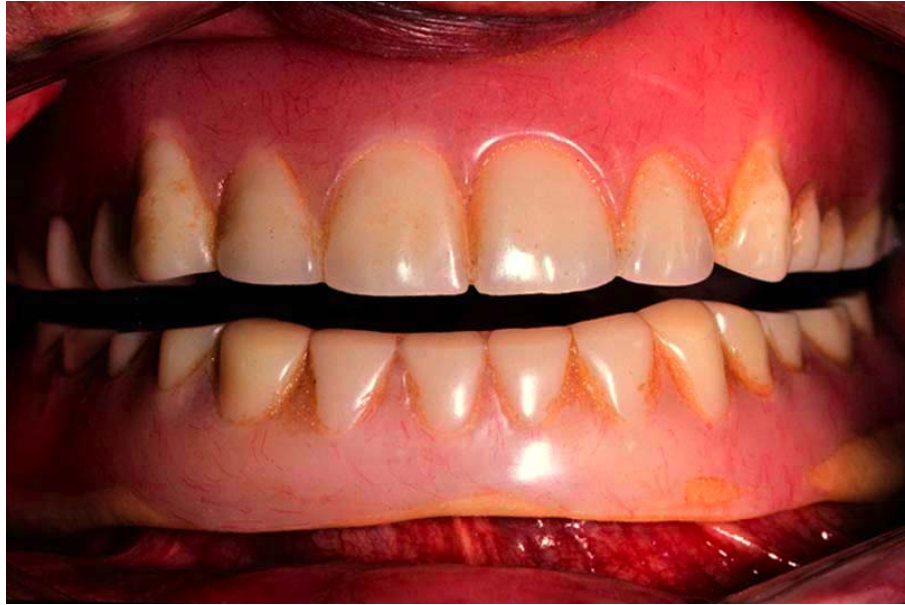

Figure 3. The severe and uneven wear on these dentures are responsible for esthetic problems, discomfort and difficulty chewing.

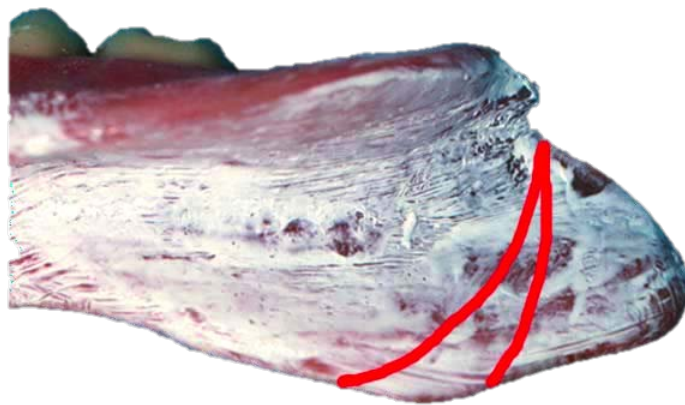


Figure 4. The distolingual flange of this mandibular denture looks different than a typical flange. It goes too far posteriorly from the position of the retromolar pad. Normally the flange contour will either proceed straight down or arc gently downward and forward from the pear-shaped pad. This overextension caused pain on swallowing for the patient.

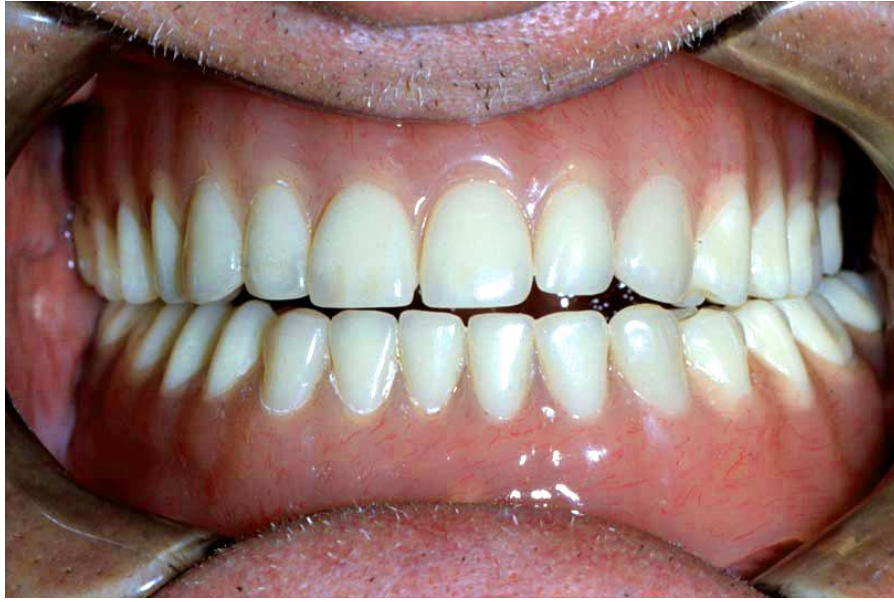

Figure 5. The chief complaint for this patient was multiple denture sore spots. The denture midlines are off and the denture teeth in the second and third quadrants are meeting cusp to cusp, suggesting that occlusion could be the cause of the patient's problems. This explains why previous adjustments to the denture bases had not provided the patient with any relief.

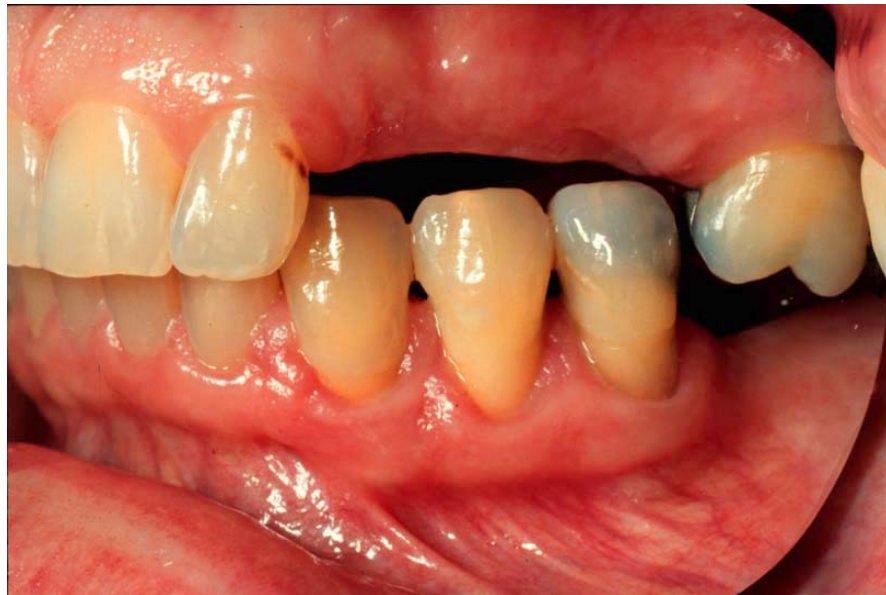

Figure 6. This patient had three unsuccessful maxillary partial dentures made within one year. She only wanted a new 'upper plate and nothing else'. All three dentures failed due to fracture of denture teeth and severe mobility of the prostheses. The care providers failed to identify lack of interarch space for the prosthesis because, in taking direction from the patient, they were only looking at the maxillary arch. Ensure the clinical exam is thorough and identifies all potential problems and variations from normal.

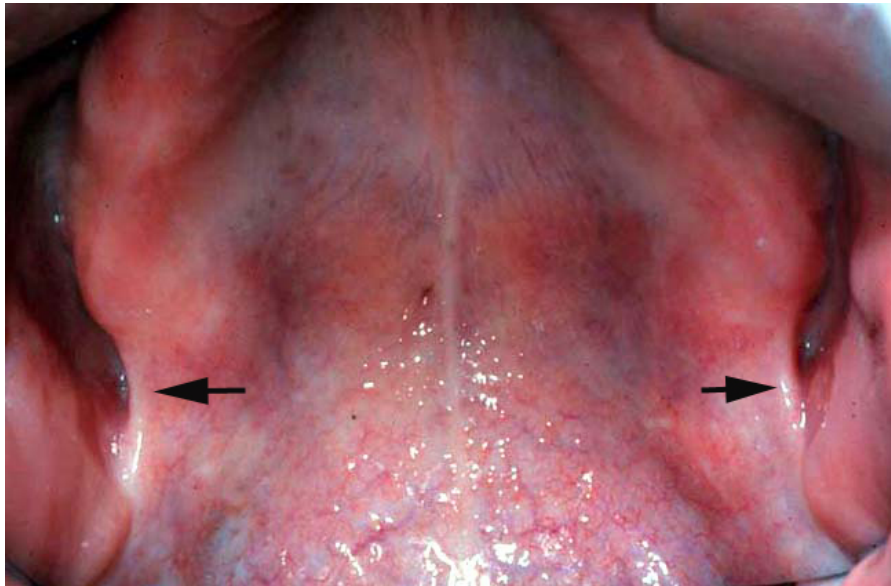


Figure 7. This patient has very tight pterygomandibular raphes (arrows). During opening, as the raphes tighten, they pull on the posterior border of the denture, causing it to loosen (the patient's chief complaint). Relief must be provided for these structures during the making of impressions. Anatomical variations must be identified in order to minimize denture problems.

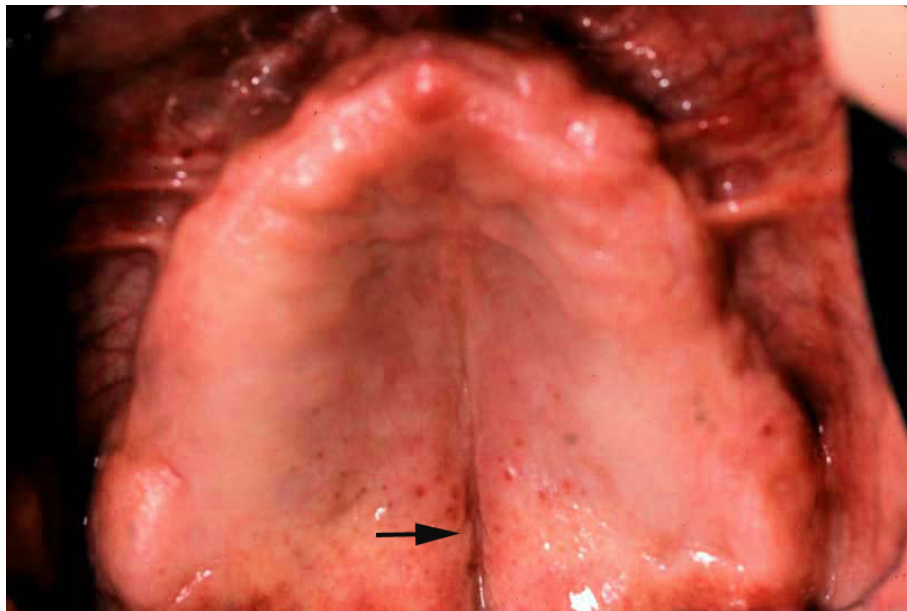


Figure 8. The deep midline soft tissue fissure at the posterior of the palate caused a break in the seal of the denture, causing looseness and dropping of the denture. Special attention needs to be paid to ensure the posterior palatal seal of the denture maintains tissue contact to provide adequate retention.

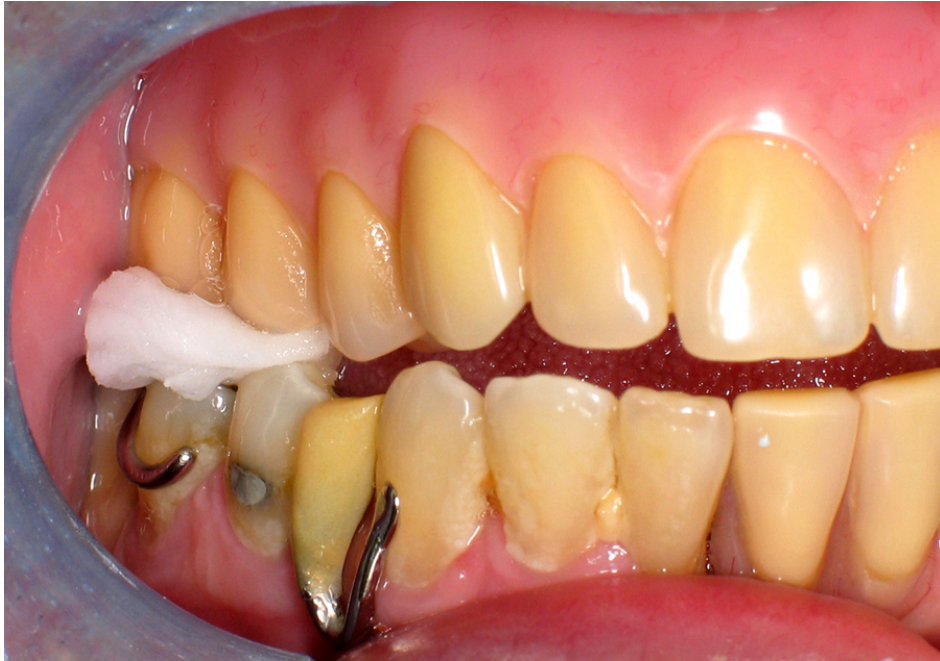

Figure 9. This patient is using a small piece of a cotton roll to demonstrate where his maxillary denture loosens when he is chewing. Having patients demonstrate their problems while the dentist watches can often expedite the diagnosis of denture problems.

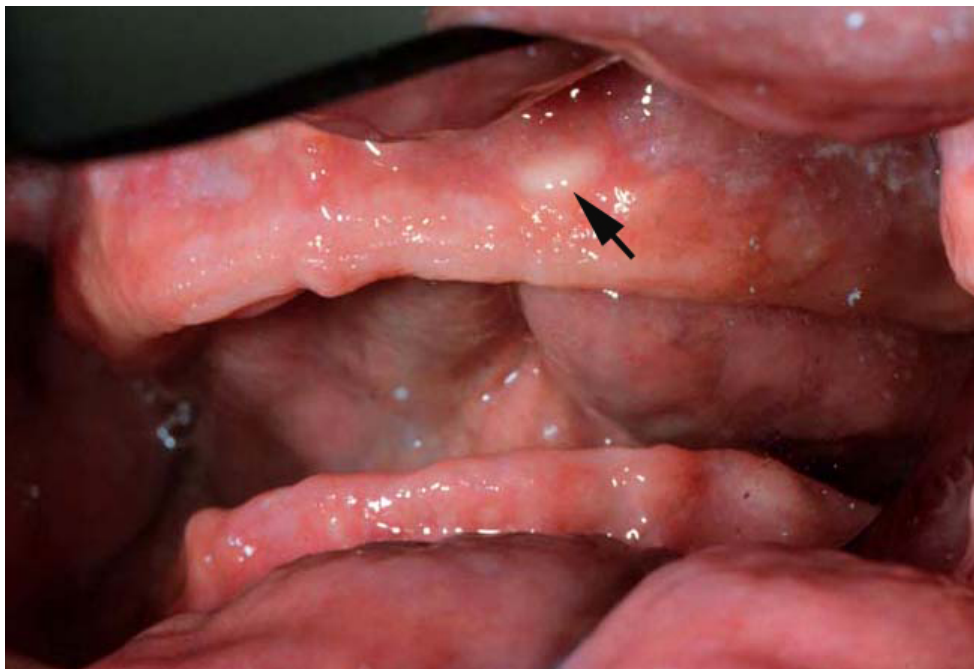

Figure 10. Ulcers, sore spots or areas of hyperkeratosis on the sides of the ridges, which are not identified using pressure indication medium are typically caused by tipping of the denture. Tipping is frequently associated with occlusal problems.

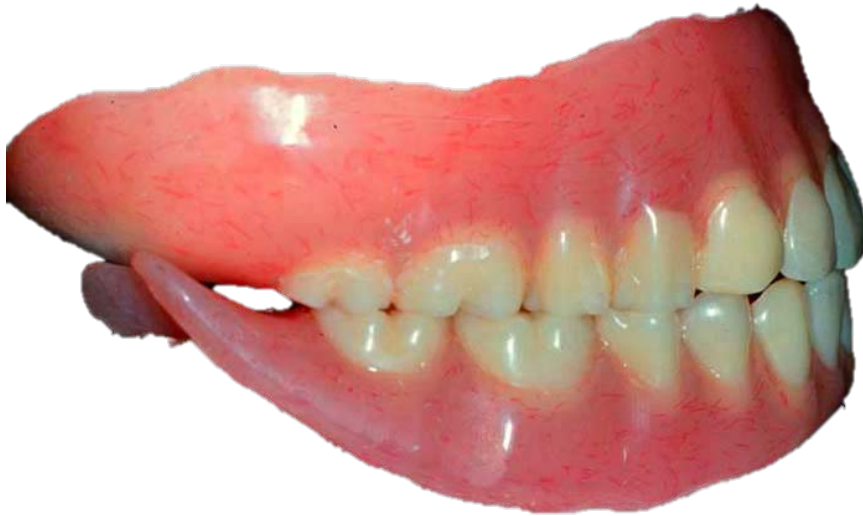

Figure 11. Posterior interferences between the denture bases can cause tipping of the dentures, resulting in pain similar to that caused by occlusal problems.

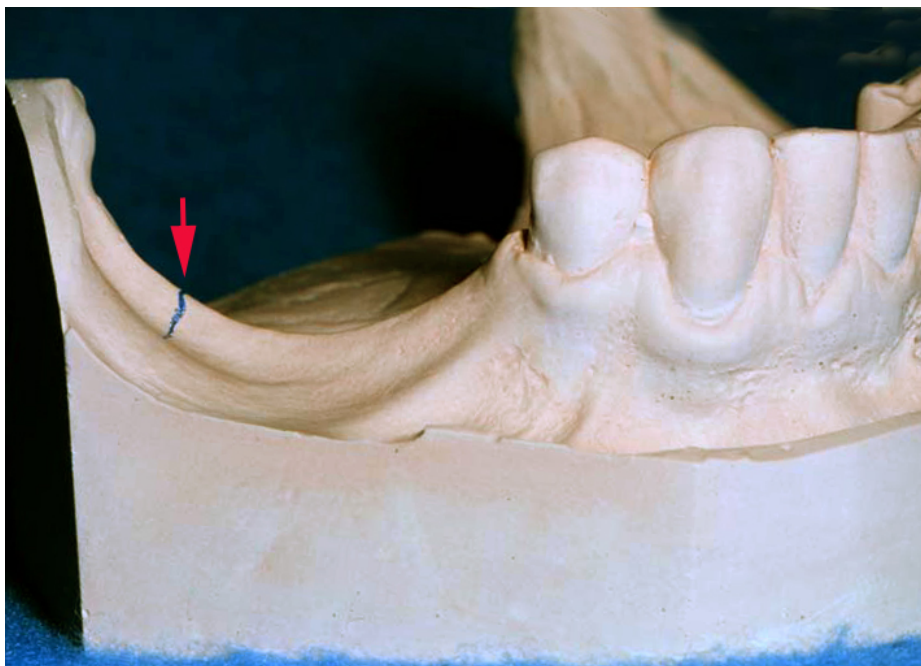


Figure 12. Posterior teeth set over the ascending portion of the ramus can cause a denture to slide or shift during function, causing occlusion-related pain⁵. Don't set denture teeth posterior to the arrow.

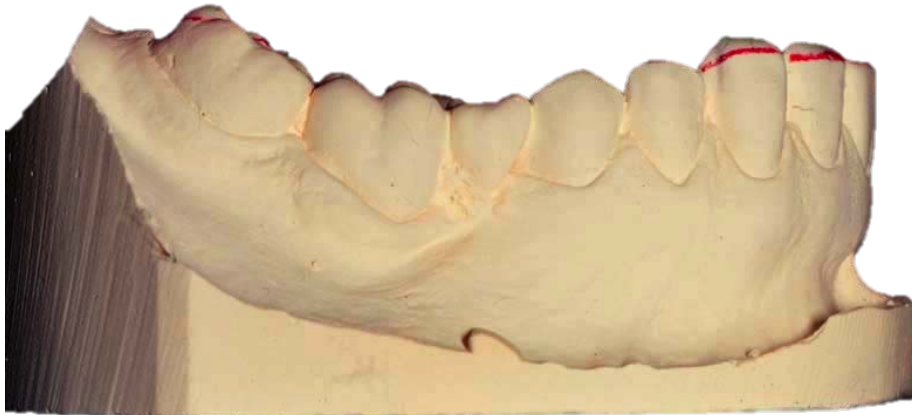

Figure 13. When single dentures oppose a natural dentition, the occlusal plane should not have a severe Curve of Spee. Such a curve will place tilting forces on the denture in excursive movements, frequently causing both looseness and discomfort.

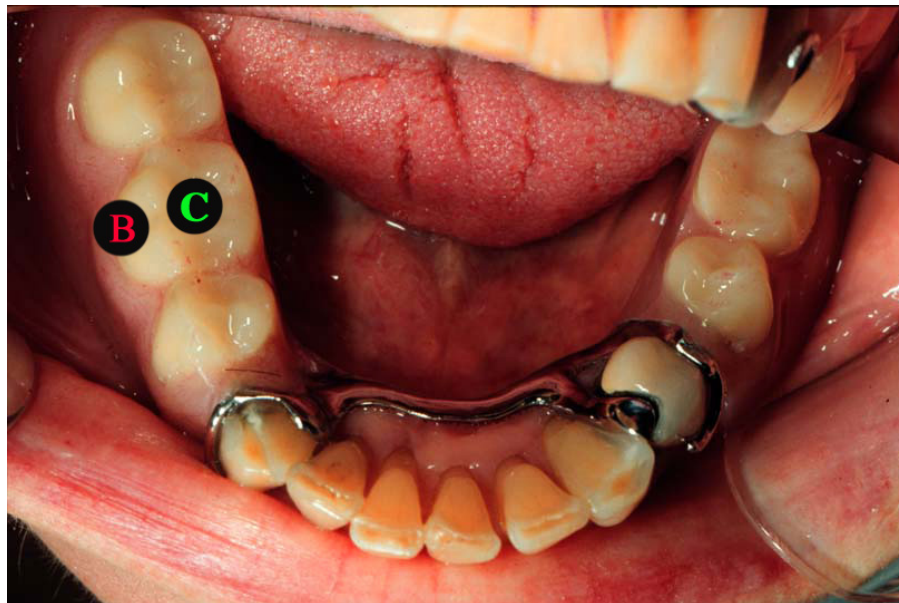


Figure 14. Normally it is better to place and load posterior denture teeth centrally (C) over the ridge. More tipping problems result when occlusal forces are placed buccal to the ridge (B)^{5,6}. This can cause both looseness and pain.

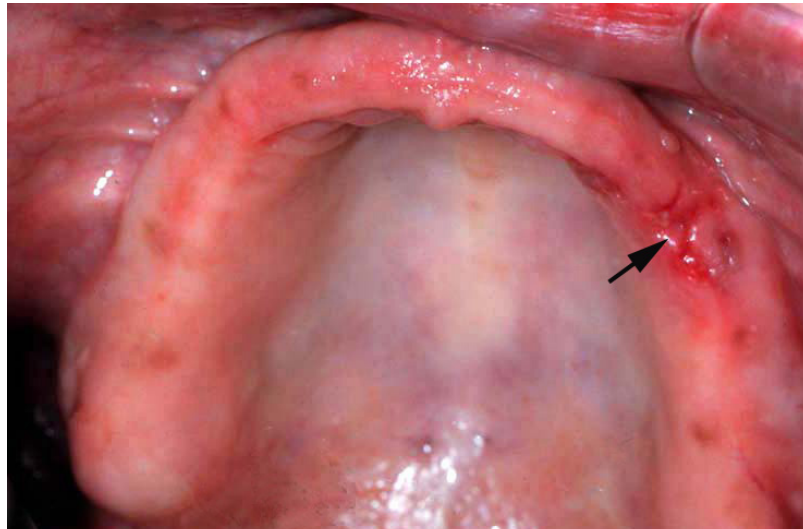


Figure 15. Areas of inflammation or ulceration that are caused by the denture base are often discrete, and cannot be distinguished from similar areas related to occlusal problems. Diagnosis needs to be established using the history, clinical exam and indicating medium. Often the definitive diagnosis will be determined by exclusion of other possible etiologies.

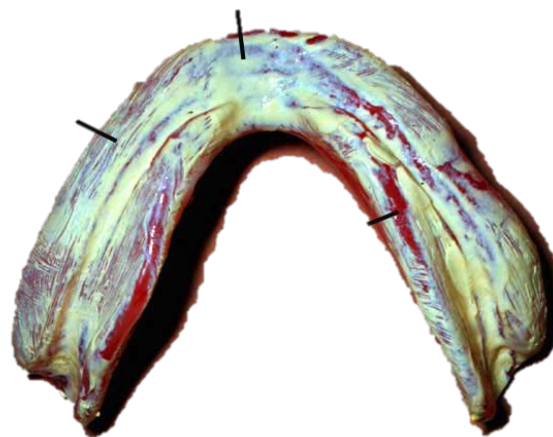


Figure 16. Pressure indicating medium is necessary to identify denture base impingements. Place medium with a stiff bristle brush, coating with enough paste so that the base is mostly the colour of the medium. Leave streaks in the paste. Place the denture intraorally, avoiding contact with cheeks and lips. Press firmly into place over the first molars. Do not tip, tilt or wiggle. Remove and inspect. Areas with paste and no brush strokes represent areas of moderate tissue contact (C). Areas without paste (burnthrough) represent areas of tissue impingement (I). Areas with streaks remaining in the paste have not contacted the tissue (N)

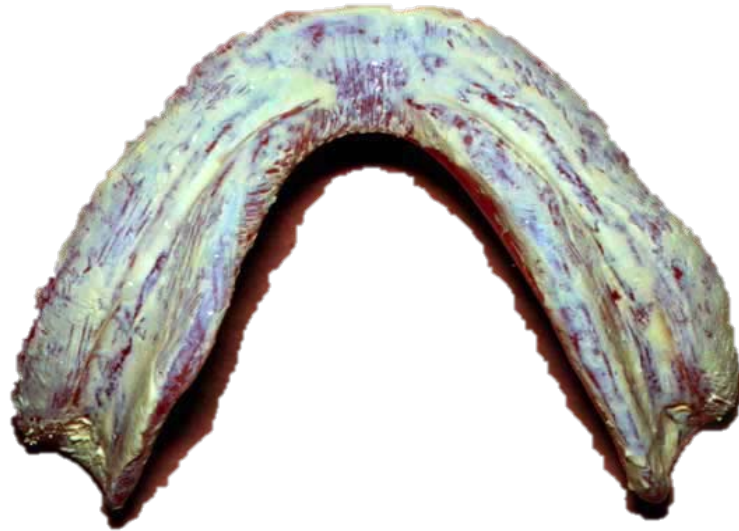


Figure 17. A well-adjusted denture base. Areas of tissue inflammation that do not correlate to areas of burnthrough are most likely caused by tilting of the denture. Investigate occlusal causes for these problems.

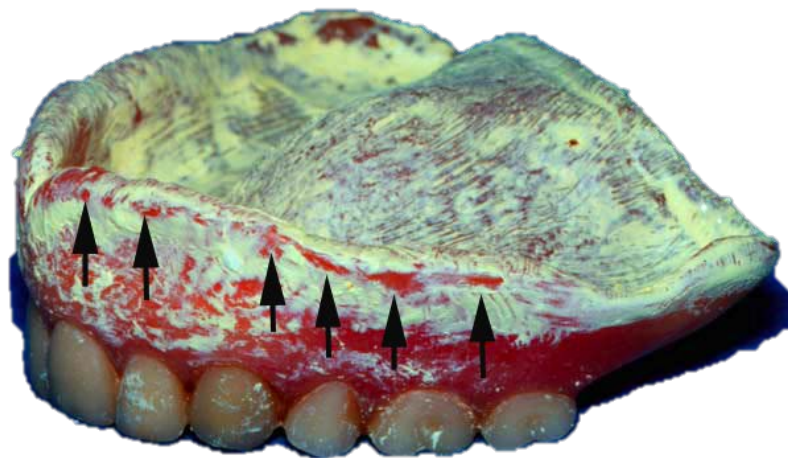


Figure 18. Lines of burnthrough on flanges often indicate areas that are overextended or too thick. They may require repeated paste applications and adjustments.

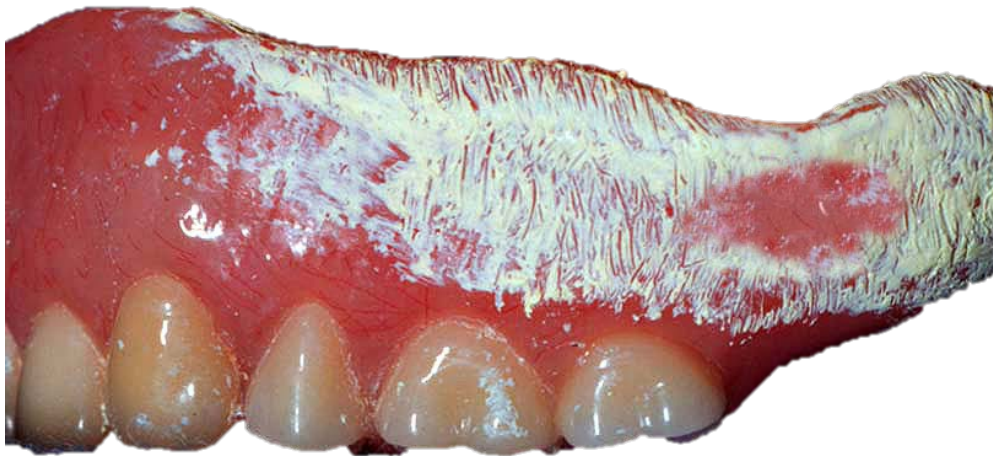

Figure 19. Pressure indicating medium can be used on non-bearing surfaces of the denture to identify other undesirable contours. This photo demonstrates an impingement of the coronoid process on the posterior denture flange in lateral excursions. This interference caused both pain and loosening of the denture.

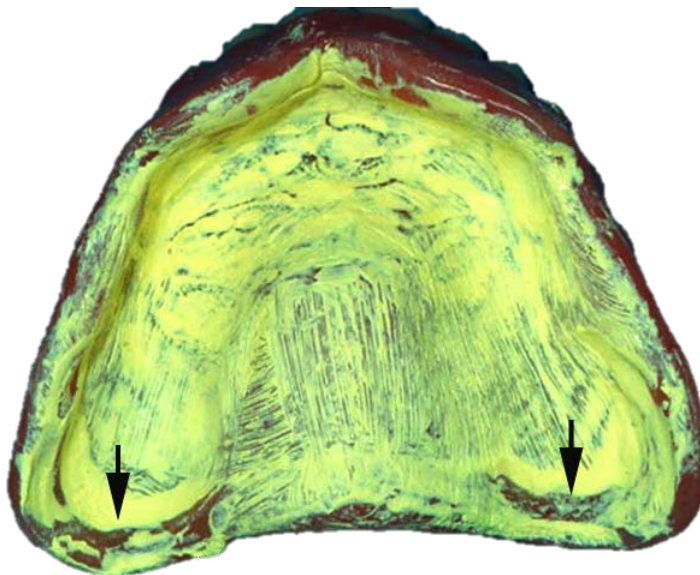


Figure 20. A sharp, thin or overextended periphery in the hamular notch area can cause very painful ulcers for a denture wearer. Use of indicating medium for adjustment of these areas is critical, as removal of acrylic in the wrong area can result in a breach of the posterior palatal seal, resulting in loosening of the denture with little relief of the discomfort.

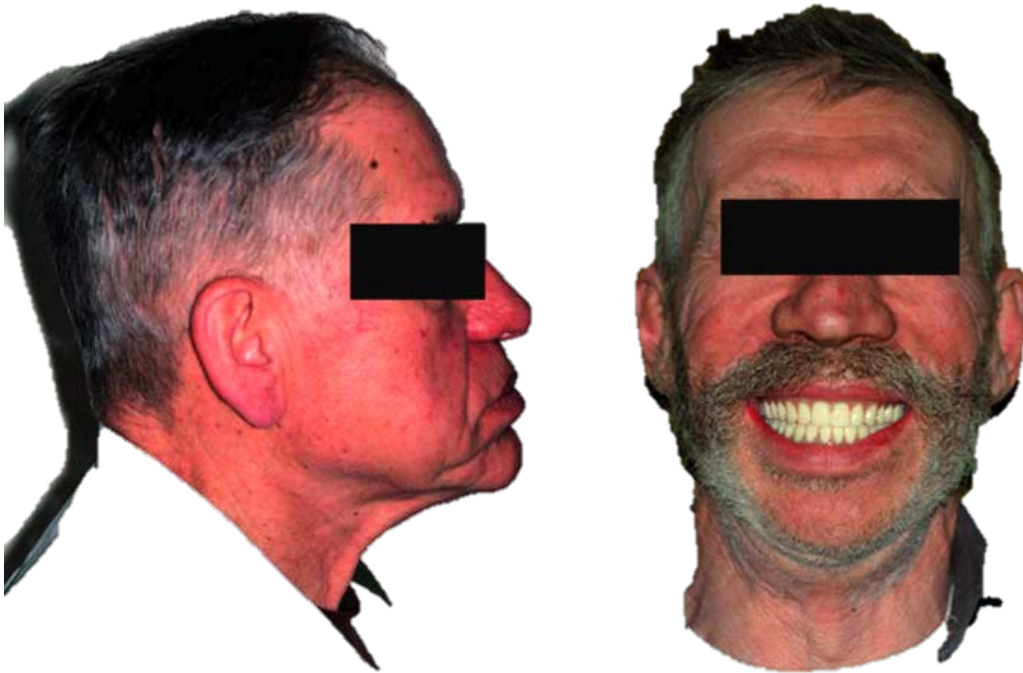

Figure 21. Examples of insufficient (left) and excessive occlusal dimension (right). See text for diagnostic criteria. While adjustments are sometimes helpful, normally a remake of the denture is required to completely resolve these serious denture problems.

References

1. Peterson LJ. Contemporary oral and maxillofacial surgery (4th ed.). St. Louis, Mo.: Mosby, 2003: 776 p.
2. Sonis ST, Fazio RC, Fang L. Principles and Practice of Oral Medicine (2nd Edition). Elsevier, 1995: 587p.
3. Winkler S. Essentials of complete denture prosthodontics (2nd ed.). Littleton, Mass.: PSG Pub. Co., 1988: 464 p.
4. Watt DM, MacGregor AR. Designing complete dentures (2nd ed.). Bristol: John Wright, 1986: 214 p.
5. Zarb GA, Bolender CL. Prosthodontic treatment for edentulous patients: complete dentures and implant-supported prostheses (12th ed.). St. Louis: Mosby, 2003: 560 p.
6. Browning JD, Jameson WE, Stewart CD, McGarrah HE, Eick JD. Effect of positional loading of three removable partial denture clasp assemblies on movement of abutment teeth. J Prosthet Dent 1986;55:347-351.

Complete Denture Checklist

1. Diagnosis and Treatment Plan

- Significant clinical findings and history recorded in data base
- Pertinent radiographs taken
- Required diagnostic procedures identified (consults, diagnostic casts, etc.)
- Student understands significance of data collected
- Treatment plan appropriate for prosthodontic and health problems identified
- Treatment plan recorded in correct sequence
- Infection Control/Other/Other _____

2. Preliminary Alginate Impressions

- Peripheries well defined (minimum of voids; showing muscle and frenal attachments)
- Accurate recording of the retromolar pads, retromylohyoid area, post palatal seal area and proper height of floor of mouth
- Material properly mixed as indicated by impressions
- Minimum of voids
- Trays properly selected and centered over the ridges
- Minimal areas where trays have contacted tissues
- Accurately records the available supporting tissues
- Infection Control/Judgment/Other _____

3. Acrylic Impression Trays

- Tray not significantly underextended
- Stable, does not rock on cast or in mouth
- Tray not significantly overextended
- Uniform thickness (2-3mm; wax /cast not showing through tray)
- Tray flange adapted as closely to residual ridge as possible
- Wax relief over mobile tissue, undercuts, incisive papilla, other critical anatomy
- Labial and buccal notches properly placed
- Borders rounded, not sharp
- Small handles, properly positioned
- Infection Control/Other/Other _____

4. Border Molding-Maxillary

- Tray stays in place at rest and during slight manipulation of tissues
- Tray exhibits firm suction when an attempt is made to remove it
- Labial and buccal flanges extend into height of vestibule
- No tray is showing through border molding
- Flange thickness generally no greater than 4-5 mm (unless severely resorbed)
- Patient feels no areas of discomfort
- Posterior palatal seal is properly covered
- Frenal areas properly contoured
- Flanges smooth, continuous; rolled and not sharp

- Flanges relatively symmetrical on contralateral sides
- Infection Control/Other/Other _____

5. Border Molding – Mandibular

- Tray stays in place at rest and during slight manipulation of tissues
- Tray is relatively stable when a vertical force is applied (within constraints of anatomy)
- No tray is showing through border molding
- Flange thickness generally no greater than 4-5 mm
- Patient feels no areas of discomfort
- Labial and buccal flanges extend into depth of vestibule
- Frenular areas properly contoured
- Flanges smooth, continuous; rolled and not sharp
- Flanges relatively symmetrical on contralateral sides
- Covers retro-molar pads
- Does not extend past buccal shelf
- Lingual flanges at or slightly below mylohyoid ridges
- Posterior extensions of lingual flanges extends into retromylohyoid spaces
- Palpation over masseter reveals no over-extension
- Infection Control/Other/Other _____

6. Final Impression - Maxillary

- Post-palatal seal area recorded (vibrating line & displaceable tissue outline)
- Peripheries covered by a thin layer of impression material (.5-1 mm)
- Tray properly vented and compound relieved
- No significant voids
- Impression is stable and retentive when moderate pressure is applied to the canine region
No significant areas of "burn through"
- Accurately records available supporting structures
- Infection Control/Other/Other _____

7. Final Impression - Mandibular

- Peripheries covered by a thin layer of impression material (.5-1 mm)
- Tray compound properly relieved
- No significant voids
- Impression is stable with tongue at rest when moderate unseating pressure is applied
- No significant areas of "burn through" (distortion of the contours of the surrounding tissue)
- Mandibular retention evident - when tongue at rest and moderate vertical force applied
- Accurately records available supporting structures
- Infection Control/Other/Other _____

8. Master Casts

- No significant bubbles or flaws in stone
- Includes all anatomical surfaces of final impressions
- Posterior border of maxillary cast clearly demarcated
- Includes 3-4 mm. land area
- Base approximately parallel to ridge and approximately 1/2 inches thick (minimum)
- Evidence of a dense stone surface
- Clean and well trimmed (no dried slurry on casts)

9. Record Bases and Occlusal Rims

- Well adapted to cast with no rocking
- Uniform thickness - about 2 mm.
- Wax rim at level 1/2-2/3 up the retromolar pad; level with corner of mouth anteriorly; parallel to ala-tragus lines and line between pupils of eyes
- Undercuts blocked out so baseplate does not scrape master cast upon removal
- Peripheries smooth and rounded
- Wax rim centered over ridge (mandibular), slightly facial to ridge (maxillary)
- Labial inclination on anterior portion of wax rim
- Width approximately 7 mm anteriorly and 10 mm posteriorly
- Flat occlusal surface, even contact between rims
- Wax smooth, neat and sealed to base
- Record base well adapted to cast tissue surface
- Infection Control/Other/Other _____

10. Facebow Record (Check prior to removal from patient & prior to mounting)

- Casts properly notched
- Bitefork correctly oriented on occlusal rim and tightened
- Facebow condylar arms properly oriented
- Maxillary cast mounted in same relationship to articulator as maxilla to arbitrary hinge axis
- Proper anterior reference point used
- Incisal pin correctly oriented
- Cast well united to mounting ring with a smooth neat finish
- Infection Control/Other/Other _____

11. Vertical Dimension

- Palpable closure from physiologic rest to OVD (usually 2-4 mm)
- Interocclusal distance measures 2-4 mm using extraoral marks
- Lips or cheeks do not appear or feel strained
- Phonetics tests ("50`s-60`s" or "Mississippi") - 1mm between rims
- Patient seated upright or standing during vertical dimension evaluation
- Infection Control/Other/Other _____

12. Centric Relation

- Repeatable recording (within constraints of patient)
- Occlusal rim properly reduced for recording medium (2nd PM to 2nd molar)
- Mandibular cast notched and grooves lubricated
- Proper quantity and utilization of medium
- Indices interdigitate accurately
- Horizontal component is correct
- Vertical component is correct
- Cast well united to mounting ring with smooth neat finish
- Casts and/or record bases not touching
- Infection Control/Other/Other _____

13. Protrusive Record

- Mandibular cast and articulator guides indicate the proper amount of protrusion
- (usually 4-6mm)
- Proper quantity and utilization of medium
- Indices interdigitate accurately
- Condylar inclination properly adjusted and locked
- Lateral condylar guidance (Bennett Angle) set at 15° (or calculated angle)
- Protrusion relatively centered
- Registration at a jaw opening greater than the vertical dimension of occlusion
- Casts and/or record bases not touching
- Infection Control/Other/Other _____

14. Wax Try-In

- Centric record verified with recording medium on widely separated teeth
- Vertical dimension verified (guidelines):
 - a. 2-3 mm between lip closure and teeth touching
 - b. Phonetics tests ("50`s-60`s" or "Mississippi") - space between rims
 - c. Lips appear and feel unstrained
- Tooth form, arrangement and shade verified
- Phonetics verified ("S", "F" and "M" sounds)
- Balanced occlusion, anterior teeth only grazing in protrusion
- Infection Control/Other/Other _____

15. Insertion/Delivery - Denture base

- Retentive, does not displace with moderate vertical pressure
- Proper flange extension (not dislodged by moderate tissue manipulation; palpation reveals no overextensions)
- Indicating medium reveals no areas of significant soft tissue impingement
- Not underextended
- No spicules and well polished
- Proper flange thickness (generally not > 4-5 mm, rolled not sharp)
- Proper relief of frenula
- Bases terminate at proper anatomical landmarks (post-palatal seal area, hamular notches retromolar pads, mylohyoid ridge, retromylohyoid spaces)
- Patient comfortable
- Not rocking on overdenture abutments
- Infection Control/Other/Other _____

16. Insertion/Delivery-Occlusion and Vertical Dimension

- Posterior teeth contact bilaterally and simultaneously when closed, without denture shift as jaw is guided to centric position
- Degree of balance evident in centric and eccentric positions
- Acceptable interocclusal space
- Anterior teeth are not in contact in centric occlusion, only grazing contact in protrusion
- Acceptable æsthetics
- Acceptable phonetics
- Instructions re: use and home care
- Infection Control/Other/Other _____

17. Clinical Remount

- Accurate centric record using medium on widely separated teeth
- Mounted accurately and neatly on an articulator
- Occlusion balanced in centric relation
- Occlusion balanced in eccentric relation
- Occlusal interferences eliminated
- Infection Control/Judgment/Other _____

18. Adjustment

- Demonstrates knowledge of problem prior to adjustment
- Adjustment not overextended
- Patient comfortable, no evidence of tissue irritation
- Infection Control/Other/Other _____