

the Ophthalmologist™

In My View

The secret is the secretions

17

In Practice

A minimally invasive approach to corneal neurotization

40 - 43

Profession


Treating patients as more than their disease

46 - 49

Sitting Down With

The fighting fit Michele Acton

50 - 51



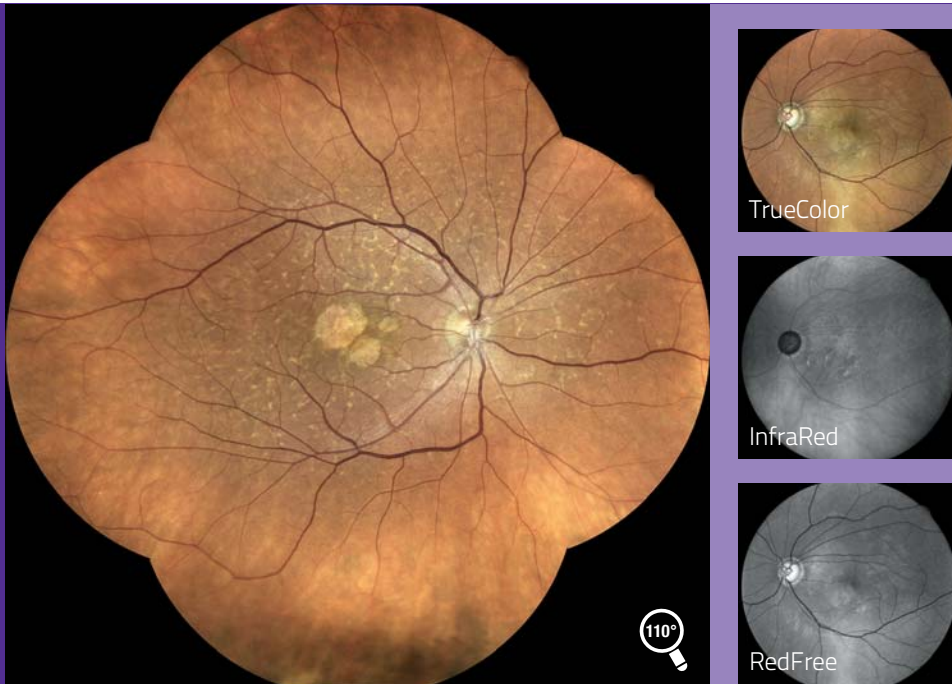
Confessions of a Live Surgeon

The intriguing world of live surgery, as told by those who know it best

18 - 26



The device for everyday eyecare practice

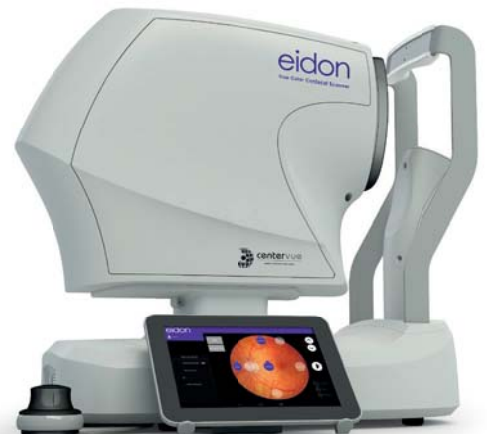

Ultra-high resolution • Non Mydriatic 2,5mm • Mosaic • Self Driven

Many eyecare diagnosis can benefit from a detailed and accurate fundus photograph, but currently available devices are often complicated and may be inaccurate in cases of small pupil and cataract.

Eidon, the only TrueColor confocal scanner on the market, is able to provide ultra-high resolution, real color pictures of the retina, even through media opacities (eg. cataract), improving diseases' progression monitoring and management.

Its usage is intuitive, fast and fully automatic, allowing to divert more time and qualified resources to diagnosis (even remotely) from the instrument's operation, while the option of switching to manual mode allows for full exam customization at any time.

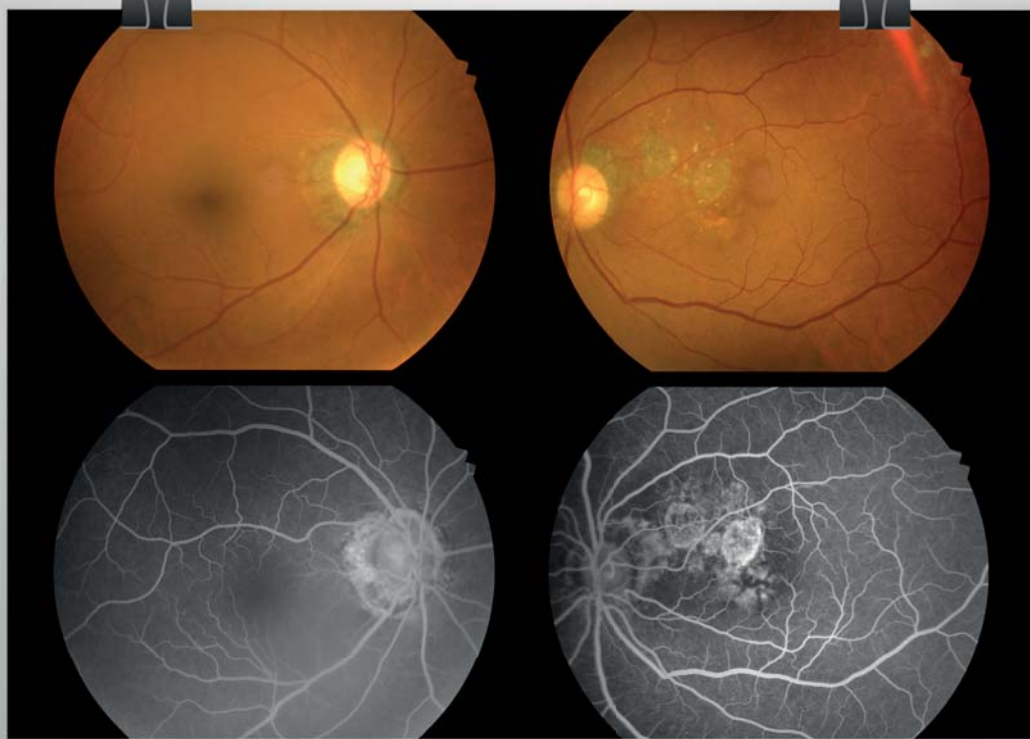


True Color Confocal Scanner

Eidon - the indispensable device for eyecare practitioners.



Image of the Month



An Eye on Gout

Fundus photographs (top) and a fluorescein angiogram (bottom) obtained from a 62-year old male patient with poorly controlled gout, demonstrating highly refractile, crystal-like lesions. As the first evidence of refractive macular lesions in a patient with gout, the case report authors suggest that patients with gout and visual complications should receive careful examination of both the posterior and anterior segment (Y Jiang et al., BMC Ophthalmol, 18, 11 (2018). PMID: 29351793).

Credit: Y Jiang, JE Brenner and WJ Foster.

Do you have an image you'd like to see featured in *The Ophthalmologist*?
Contact edit@theophthalmologist.com



03 **Image of The Month**

09 **Editorial**
Generally Regarded as Safe
by Mark Hillen

On The Cover



The Warhol-esque cover this month features four live surgery veterans, and illustrations of what they've gone through to present – from international travel to an unfortunate encounter with cobra bile...

Upfront

- 10 Ditch the Diet... Drinks
- 11 Don't Leave the Door Open
- 12 Musical Theater
- 13 Early Learning
- 14 More Coherent Surgery
- 15 Dimmer and Dumber

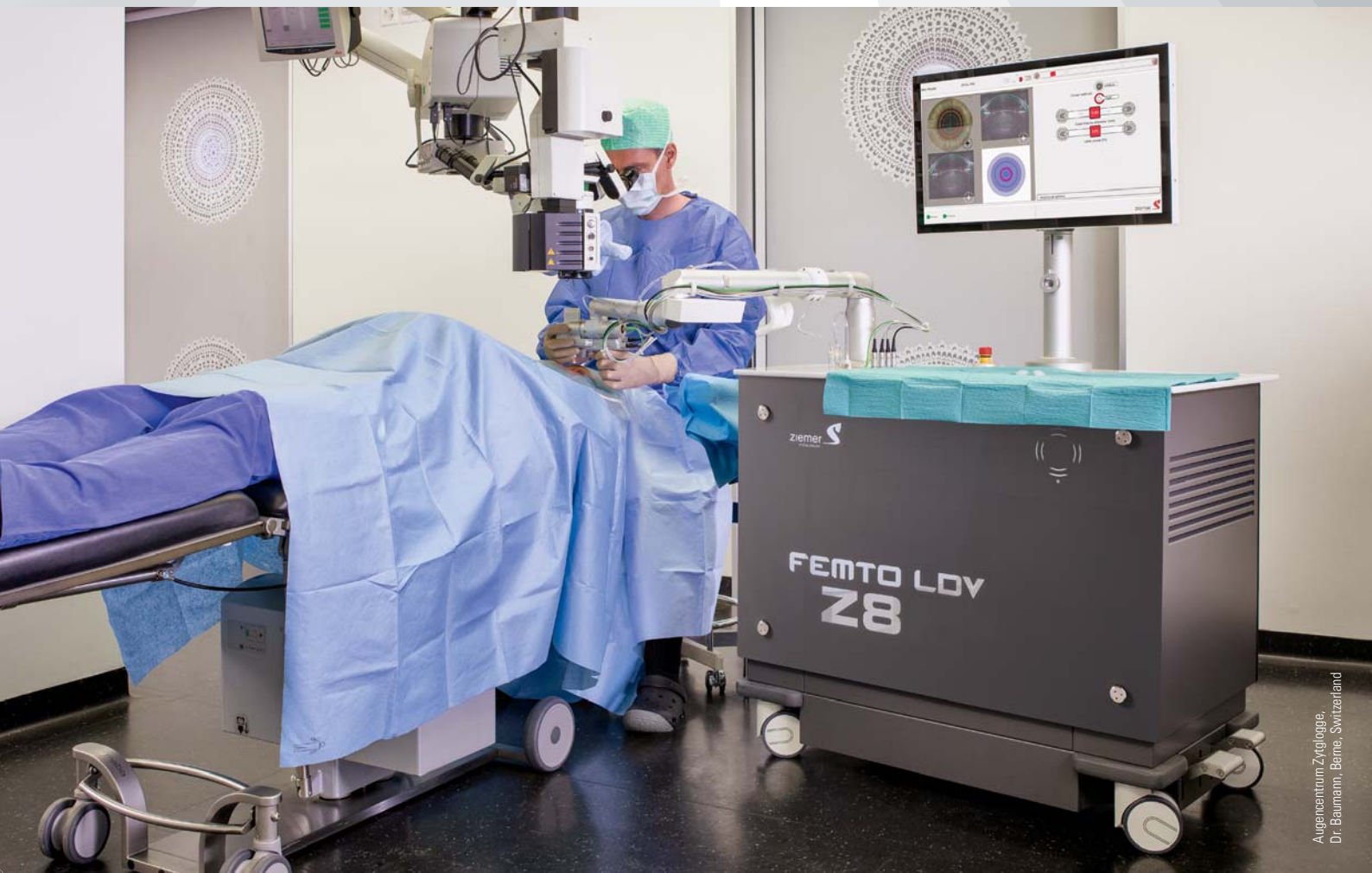
In My View

- 16 **John Sandford-Smith** on why training non-doctors to perform cataract surgery is an obvious approach to tackle cataract blindness.
- 17 **Nicolas Sohl** knows that stem cells hold great promise for regenerating the retina... but is it the cells that we really need?

It's Time to make a Move

It has never been so simple to adapt new technology into your daily workflow. The truly mobile FEMTO LDV Z8 finally enables you to use next generation femtosecond laser technology for your cataract and refractive surgeries.

www.femtoldv.com



Augenzentrum Zytglogge,
Dr. Baumann, Berne, Switzerland

FEMTO LDV
Z8 Cornea
Cataract

ziemer 
OPHTHALMOLOGY

The FEMTO LDV Z8 is CE marked and FDA cleared for the use in the United States. For other countries, availability may be restricted due to regulatory requirements; please contact Ziemer for details.

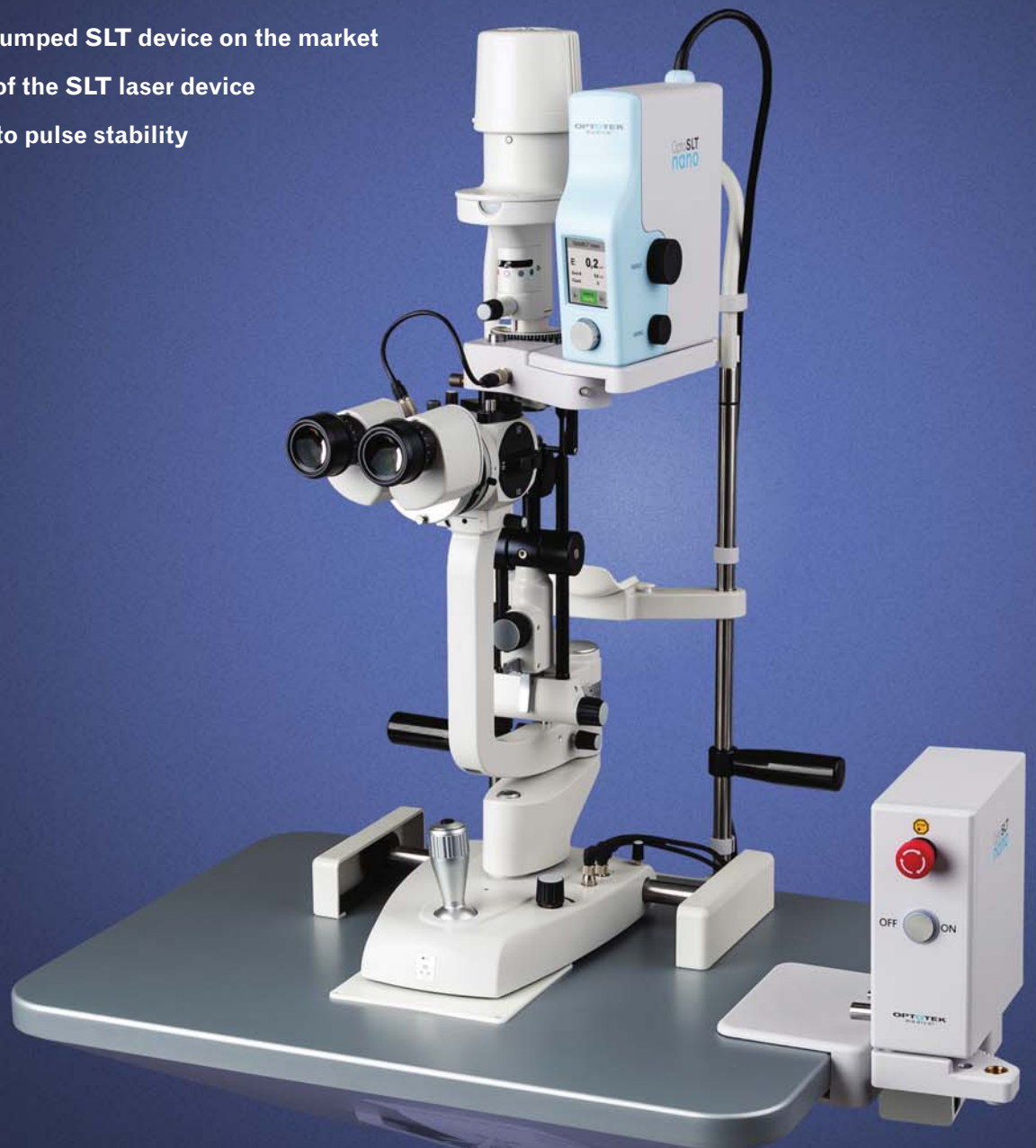
Preserve vision with

OptoSLT nano

The first diode pumped SLT device on the market

True portability of the SLT laser device

Very high pulse to pulse stability



OPTOTEK
medical

optotek-medical.com



40

Feature

18 **Confessions of a Live Surgeon**
Live surgery is the beating heart of surgical education and training in ophthalmology. But what is it actually like to be a live surgeon? Uday Devgan, Paul Singh, Steve Charles and James Lewis share their experiences and knowledge – and tell their most memorable stories.

In Practice

40 **Minimally Invasive Corneal Neurotization**
Neurotrophic keratopathy is a devastating condition which has few options for management, but Ilya Leyngold wants to change that...



50

Profession

46 **Addressing Needs Beyond Disease**
John D. Shepherd on the importance of low vision rehabilitation – and the responsibility of ophthalmologists to recognize those patients who are struggling to cope with vision loss and in need of help.

Sitting Down With

50 **Michele Acton, CEO of Fight for Sight, UK.**

Editor - Mark Hillen
mark.hillen@texerepublishing.com

Managing Editor - Ruth Steer
ruth.steer@texerepublishing.com

Content Director - Rich Whitworth
rich.whitworth@texerepublishing.com

Publishing Director - Neil Hanley
neil.hanley@texerepublishing.com

VP Sales North America - Molly Phillips
molly.phillips@texerepublishing.com

Sales Manager - Abigail Mackrill
abigail.mackrill@texerepublishing.com

Head of Design - Marc Bird
marc.bird@texerepublishing.com

Designer - Hannah Ennis
hannah.ennis@texerepublishing.com

Digital Team Lead - David Roberts
david.roberts@texerepublishing.com

Digital Producer Web/Email - Peter Bartley
peter.bartley@texerepublishing.com

Digital Producer Web/App - Abygail Bradley
abygail.bradley@texerepublishing.com

Audience Insight Manager - Tracey Nicholls
tracey.nicholls@texerepublishing.com

Traffic & Audience Database Coordinator - Hayley Atiz
hayley.atiz@texerepublishing.com

Traffic & Audience Associate - Lindsey Vickers
lindsey.vickers@texerepublishing.com

Traffic Manager - Jody Fryett
jody.fryett@texerepublishing.com

Social Media / Analytics Associate - Ben Holah
ben.holah@texerepublishing.com

Events Manager - Alice Daniels-Wright
alice.danielswright@texerepublishing.com

Marketing Manager - Katy Pearson
katy.pearson@texerepublishing.com

Financial Controller - Phil Dale
phil.dale@texerepublishing.com

Accounts Assistant - Kerri Benson
kerri.benson@texerepublishing.com

Vice President (North America) - Fedra Pavlou
fedra.pavlou@texerepublishing.com

Chief Executive Officer - Andy Davies
andy.davies@texerepublishing.com

Chief Operating Officer - Tracey Peers
tracey.peers@texerepublishing.com

Change of address
hayley.atiz@texerepublishing.com
Hayley Atiz, The Ophthalmologist,
Texere Publishing Ltd, Haig House, Haig Road,
Knutsford, Cheshire, WA16 8DX, UK

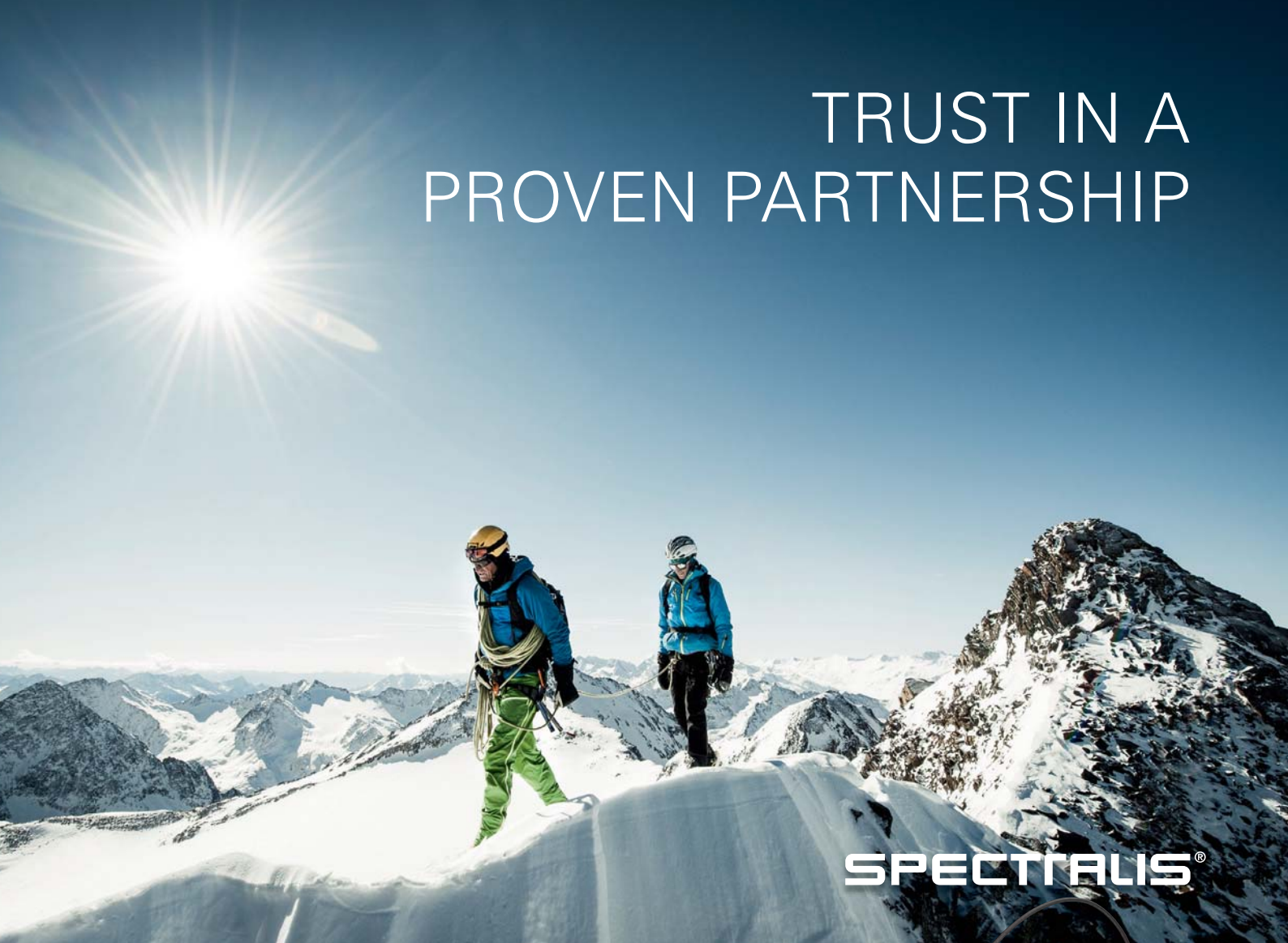General enquiries
www.texerepublishing.com
info@texerepublishing.com
+44 (0) 1565 745 200
sales@texerepublishing.com

Distribution
The Ophthalmologist (ISSN 2051-4093)
and The Ophthalmologist North America
(ISSN 2398-9270), is published monthly by
Texere Publishing Ltd and is distributed in the
US by UKP Worldwide, 3390 Rand Road,
South Plainfield, NJ 07080.
Periodicals postage paid at South Plainfield, NJ
and additional mailing offices.
POSTMASTER: Send US address changes to
The Ophthalmologist C/O 3390 Rand Road,
South Plainfield NJ 07080.
Single copy sales \$15/€20
(plus postage, cost available on request
tracey.nicholls@texerepublishing.com)
Annual subscription for non-qualified
recipients \$140/€110

Reprints & Permissions – tracey.nicholls@texerepublishing.com
The opinions presented within this publication are those of the authors
and do not reflect the opinions of The Ophthalmologist or its publishers,
Texere Publishing. Authors are required to disclose any relevant financial
arrangements, which are presented at the end of each article, where relevant.
© 2017 Texere Publishing Limited. All rights reserved.
Reproduction in whole or in parts is prohibited.



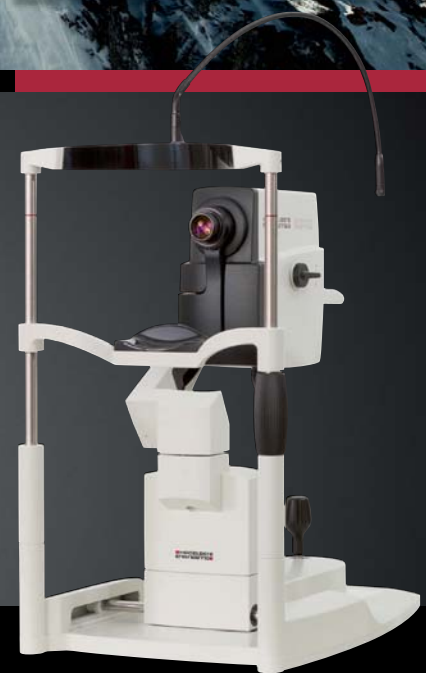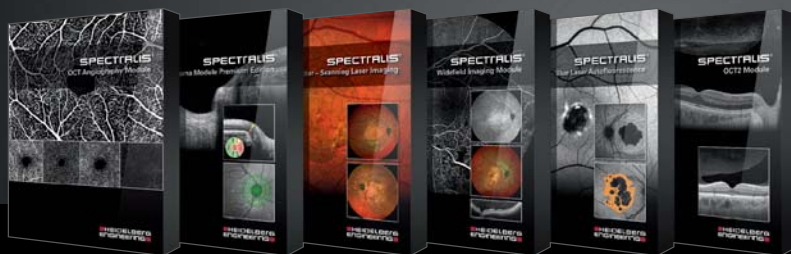TRUST IN A PROVEN PARTNERSHIP



SPECTRALIS®

Be confident with SPECTRALIS®, a future-proof platform

Our upgradeable imaging platform allows you to refine clinical decision making and gives you the flexibility to grow your business. Together we can improve patient care.



200209-001 INT_AE18 © Heidelberg Engineering GmbH

www.be-confident-with-spectralis.com

**HEIDELBERG
ENGINEERING**



I'm a child of the 1980s and, when I think about it, people were thinner back then. So it's quite odd that it was also the decade in which 'diet' carbonated drinks came to market and Lycra-clad aerobics instructors started to yell at us to move our bodies on breakfast TV. Did we need to be even thinner and healthier? In any case, why are we not all gods and goddesses in human form today?!

Something else happened in 1981. After extensive study, the FDA approved aspartame and acesulfame potassium as 'generally regarded as safe' food additives. In short, food and drink manufacturers can use the ingredients, and the public should be fine to consume them.

Here's the thing. On average, we developed-nation dwellers consume fewer calories than 30–40 years ago. But we're bigger and more likely to be diabetic than in the past. And now, we read that aspartame consumption is associated with increased HbA1c, hunger – and that the rates of proliferative diabetic retinopathy (PDR) soar as diet soda consumption increases (1) – see page 10.

There are a number of potential explanations. Perhaps those who are overweight or diabetic/prediabetic choose to avoid 'full-fat' Coke and go for the Diet or Zero alternatives. Another explanation is that artificial sweeteners alter gut bacterial flora, which then affects energy metabolism (experiments have shown that you can turn a fat mouse thin – and vice versa – by changing their gut bacteria). Or perhaps after 20–30 years of near-daily consumption, ingredients 'generally regarded as safe' might not be particularly safe after all – in this case, to the retina.

But I see hope. When you're a child of the 1980s, you've also seen a number of dietary fads come and go: fat is bad, fat is good; carbs are good, carbs are bad; monounsaturated fats are the Devil's work, polyunsaturated fats are so much healthier. We are still figuring out that it's far more complicated than that. And when there's solar-system's-worth of data out there, there's insight to be had. When the ferocious pace of artificial medical intelligence helps us mine the golden nuggets of what's actually good (and bad) for you, I suspect many 'old wives' tales' of fish being good for your brain, and so on, will objectively be proven right. Hopefully, we will then be able identify compounds that are generally regarded as 'safe,' sparing us from more of what it looks like we have here: a full pipeline of PDR cases waiting to happen.

Reference

1. EK Fenwick et al., "Diet soft drink is associated with increased odds of proliferative diabetic retinopathy", *Clin Exp Ophthalmol*. [Epub ahead of print] (2018). PMID: 29360260.

Mark Hillen
Editor

Upfront

Reporting on the innovations in medicine and surgery, the research policies and personalities that shape the practice of ophthalmology.

We welcome suggestions on anything that's impactful on ophthalmology; please email edit@theophthalmologist.com



Ditch the Diet... Drinks

Research finds a link between consumption of low-calorie beverages and proliferative diabetic retinopathy

From ginger beer to cola, many people enjoy a refreshing soft drink. Obesity and tooth decay are well-known as potential risks of consuming sugary beverages, but what about their artificially-sweetened, lower-calorie cousins? Evidence is building around the theory that such drinks may not circumvent all potential health issues. And now, a team from the Singapore Eye Research Institute and Centre for Eye Research Australia has found that consumption of diet drinks may be linked with diabetic retinopathy (DR) (1). In a cohort of 609 patients with diabetes, high levels of diet soft drink consumption (over four cans per week) was independently associated with an increased likelihood of having proliferative DR (odds ratio, 2.51; 95% CI, 1.05–5.98) when compared with no consumption. Ecosse Lamoureux, senior author of the study, tells us more.

The results seem somewhat surprising... The association of diet soft drink consumption with DR was certainly unexpected, and prospective studies are needed to confirm this cross-sectional phenomenon. We were also surprised by the differential impact that diet and regular soft drinks had on DR risk. However, as few individuals with diabetes in our sample consumed regular soft drinks, the lack of an association could be due to inadequate statistical power; this caveat was noted in our manuscript and caution is needed when interpreting our results.

What impact could your findings have? Our findings indicate that daily



consumption of low-calorie soft drinks may be associated with DR in people with diabetes. And although more research is needed, doctors could advise patients with diabetes to reduce or eliminate the consumption of diet soft drinks. Such advice could be important for individuals with existing DR to prevent disease progression to vision-threatening stages. More importantly, our results may inform future dietary management plans for individuals with no or existing DR.

Next steps?

Given the cross-sectional nature of our study, we are unable to determine causality. Therefore, we are planning to undertake a longitudinal study, using prospectively collected dietary data to determine whether diet soft drinks are indeed unhealthy substitutes for regular soft drinks in patients with diabetes, so as best to inform the clinical management guidelines for DR.

Reference

1. EK Fenwick et al., "Diet soft drink is associated with increased odds of proliferative diabetic retinopathy", *Clin Exp Ophthalmol*, [Epub ahead of print], (2018). PMID: 29360260.

Don't Leave the Door Open

Is a small spike in endophthalmitis events with Eylea nothing more than a refrigeration issue – or something more?

Endophthalmitis is a nightmare for ophthalmologists; sometimes you can treat it, sometimes you lose the eye. But when you go into the eye to perform surgery – or even inject a drug – there's always a risk that infection can occur. But even then, with precautions, the risk of endophthalmitis is miniscule. After all, the most commonly performed surgery (of all of medicine, not just ophthalmology) is cataract surgery, and people receive intravitreal injections as a matter of routine.

However, it appears that no one can fully relax. On February 21, Bloomberg published an article with a troubling first sentence: "Doctors say they're seeing an unexplained increase in a rare, frightening side effect in patients getting Regeneron Pharmaceuticals Inc's top-selling product, the blockbuster eye drug Eylea" (1). So what's the story?

According to the article, the American Society of Retina Surgeons (ASRS) issued a letter to doctors in October last year asking them to be extra vigilant for endophthalmitis after administering intravitreal injections of aflibercept (Eylea), as a slight upswing in endophthalmitis rates had been noted. The society then issued another letter this January stating that the FDA had deemed a recall unnecessary and that aflibercept's producer and distributor of the drug in the US, Regeneron, had found no manufacturing problems; the ASRS urged its members to keep the medicine refrigerated. A third letter was issued

on February 15, stating that the society had received increased reports of the adverse event over the past six months, with clusters reported from practices in Ontario, Massachusetts, New Jersey, New York, Nevada, Iowa and Pennsylvania – reinforcing Regeneron's claim that this is not due to manufacturing problems.

Despite this, endophthalmitis with Eylea is still a vanishingly rare event. Is this a case of conflating relative with absolute risk? According to the Bloomberg report, "The FDA received 71 reports last year, almost triple 2014 when the next-highest number were made. The company said it sold about 2.2 million vials of the drug last year, up from about 1 million in 2014." The report added, "Last year, the side effect was reported in about 1 in 10,000 people who got Eylea." So, in short: triple the absolute number of a (thankfully) incredibly rare event, when the total number of injections has more than doubled.

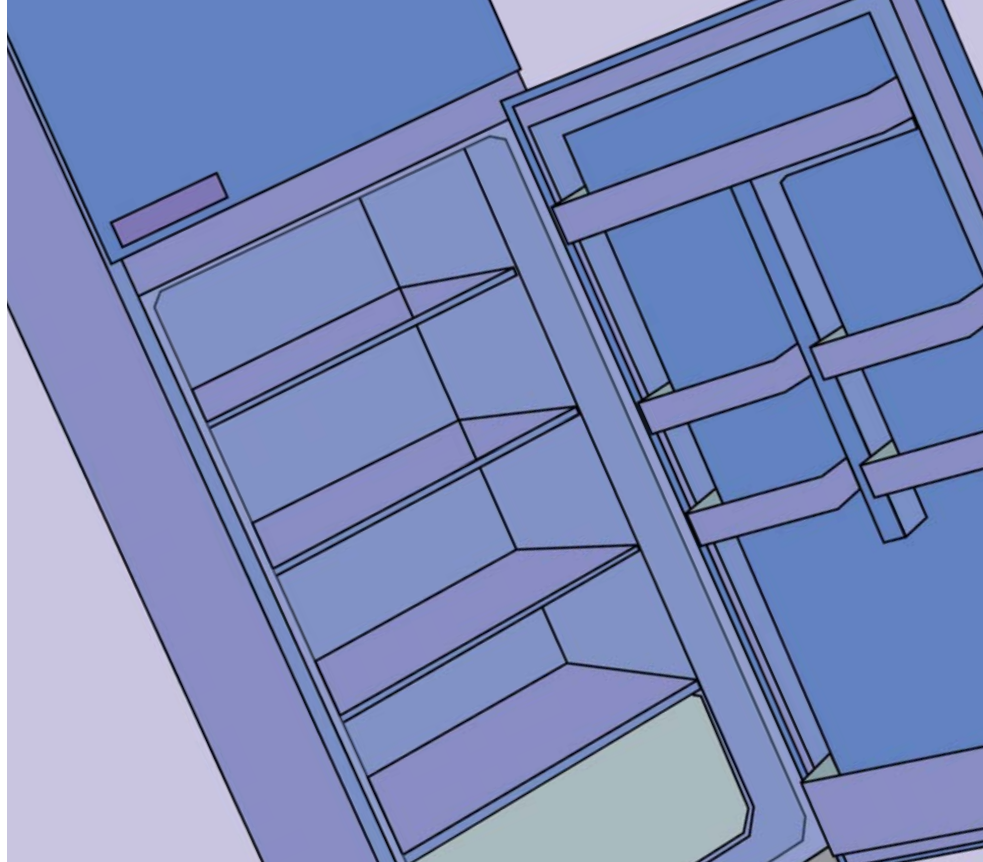
Still, every case of endophthalmitis is potentially blinding – what has been done to assess and address this? Regeneron is allowing doctors with an affected patient to swap out any unused vials for vials from another batch, and the ASRS noted that, though the side effect is still rare, the

benefits of the drug outweigh the risks. And they agreed with Regeneron's plan to replace vials of the drug upon request.

What might be causing the problem? The ASRS statement in the January letter, urging its members to keep the drug refrigerated, might be a clue. Bloomberg quoted Neil Bressler, Professor of Ophthalmology at the Johns Hopkins Wilmer Eye Institute, as saying: "It's possible that the medicine, which must be constantly refrigerated from the time it leaves the factory until it is injected, has been mishandled somewhere along the line." He went on to add: "It should be looked into and corrected if it's real, even though it would be rare, but I don't think there is cause for alarm at this time. The number of events is tiny, and you have to weigh that against the benefits of the treatment, which are enormous." Whether this is the explanation or not, it's important to keep things cool – and don't leave the fridge door open.

Reference

1. M Cortez, "Regeneron's Eylea Has Mysterious Rise in Side Effect Reports", *Bloomberg.com* Available at: bit.ly/eylea2018. Last accessed February 25, 2018.



Musical Theater

How a fine melody might make you a better surgeon

Music can be a great motivator; it's why runners listen to it as they pound the pavement and why the Rocky III training montage features the iconic "Eye of the Tiger." And according to new research, it might also improve the surgical skills of ophthalmologists.

There is a connection between music and cognitive abilities – the so-called 'Mozart effect', but how music might affect surgical skills is not well understood. "My colleague and I had always had a passion for music and played it in our operating rooms," says Ralph Kyrillos, lead author on the associated paper (1). "We'd noticed that preference to operate with music, and

opinions on the effect of music on surgical skill varied widely between surgeons.

When our hospital acquired an EyeSi simulator we saw an opportunity to actually measure the impact of music on microsurgery."

According to Kyrillos, the EyeSi offered a great platform to record precise parameters that could not be measured in the real clinical setting.

In their prospective study, 14 ophthalmologists and 12 residents stratified by surgical skill were randomized to perform surgical tasks with or without music (Mozart's Sonata for Two Pianos in D major K.448, in case you're wondering).

"Many of the participants routinely listened to music while operating, but they all had different preferences, such as rock, classical, instrumental – or even letting the patient choose – as well as whether they kept listening to music when performing a complex or delicate part of the procedure," says Kyrillos. "This made the study really fun, as everyone had a different opinion on the subject and were intrigued what the results would show!"

For the anti-tremor task, the group found no statistically significant differences in recorded parameters between the group exposed to music and the group who were not. For the capsulorhexis task, the 'total score' and 'roundness of capsulorhexis' parameters showed statistically significant improvements in the group exposed to music ($p=0.0249$ and $p=0.0367$, respectively). Subgroup analysis showed no significant differences between surgical experience or between male and female surgeons. A post-hoc analysis identified greater improvements with music in the capsulorhexis parameters 'total score' ($p=0.0015$) and 'roundness' ($p=0.0021$) for participants who hadn't used the simulator before the study.

Concluding that exposure to music does not negatively impact surgical skills, Kyrillos says they were surprised that listening to music seemed to improve certain scores. "Based on literature describing the 'Mozart effect,' we thought music might positively affect skills, but we expected any effect to be minimal and not in the most

experienced surgeons who already excelled at surgery." Kyrillos says that the group actually constructed their study to determine if music had a negative impact on surgical skill: "We thought it would be more useful to find out if we needed to stop listening to music while operating."

The group studied simulated intraocular surgery, but do their results translate to the real world? "Validation in the real operating world would be hard but not impossible," says Kyrillos. "Possible ways include comparing complication rates, or filming surgeries and analyzing the videos to measure parameters similar to those recorded by the EyeSi."

For now, if you listen while you work, you can continue safe in the knowledge that it might actually have some benefit!

Reference

1. R Kyrillos and M Caissie. "Effect of music on surgical skill during simulated intraocular surgery", *Can J Ophthalmol*, 52, 538–542 (2017). PMID: 29217019.



Early Learning

The link between depleted omega-6 fatty acid levels and retinopathy of prematurity

When babies are born pre-term, the final stages of retinal development can be disrupted by the intensive oxygen therapy administered to compensate for underdeveloped lungs, leading to retinopathy of prematurity (ROP) in some cases – and potentially blindness. It's why many researchers are on a quest to determine how best to support the ongoing retinal development and avoid disease.

Knowing that long-chain polyunsaturated fatty acids (LC-PUFAs) drive brain and retinal development in the third trimester, a Swedish team from the Sahlgrenska Academy, University of Gothenburg, decided to investigate the association between circulating LC-PUFAs and ROP in extremely pre-term infants. In their study (a secondary

analysis of the randomized Donna-Mega trial comparing fish and olive oil-based supplements on ROP and other morbidities, 1), the group analyzed serum lipid levels in cord and venous blood samples obtained from 78 infants born before 28 weeks gestational age (2).

And there was a clear finding: low levels of arachidonic acid were strongly associated with ROP. In the first month of life, levels of arachidonic acid (an omega-6 fatty acid) were significantly lower in infants who then had a later diagnosis of ROP compared with those who had no ROP ($p < 0.05$); at 32 weeks post-menstrual age, the fatty acid was significantly lower in infants who developed later severe ROP ($p < 0.001$). Through logistic modeling, the team also identified that low arachidonic acid levels, as well as low gestational age at birth, had greater than 90 percent sensitivity for identifying ROP development.

The group hypothesize that arachidonic acid supplementation could protect against ROP development, and plan to investigate

the potential in an upcoming study. The team also suggest that low levels of the fatty acid could serve as a biomarker for risk. Commenting on their findings, Chatarina Löfqvist, lead author of the study, said (3): “We believe and hope that providing children with arachidonic acid will raise the levels and reduce the amount of ROP to minimize the risk of children becoming blind.”

References

1. *ClinicalTrials.gov*. “A fatty acids study in preventing retinopathy of prematurity: NCT02760472”. Available at: <http://bit.ly/DonnaMega>. Accessed February 15, 2018.
2. CA Löfqvist et al., “Association of retinopathy of prematurity with low levels of arachidonic acid”, *JAMA Ophthalmol*, [Epub ahead of print], (2018). PMID: 29423508.
3. Margareta Gustafsson Kubista. “New discovery offers hope of protecting premature babies from blindness”. Available at: <http://bit.ly/ROPDiscovery>. Accessed: February 15, 2018.

More Coherent Surgery

Three-year results from the DISCOVER study

Over the last decade, intraoperative OCT has emerged as a valuable tool; not only can it provide real-time information on surgical outcomes, it can influence decision-making during the surgery. “Previous research has demonstrated the potential feasibility of intraoperative OCT when used externally to the microscope,” says Justis Ehlers of Cole Eye Institute of the Cleveland Clinic, Ohio, USA. Ehlers is Principal Investigator on the DISCOVER study, which was launched to evaluate the role of microscope-integrated OCT in ophthalmic surgery.

Building OCT directly into the microscope could bring several potential advantages over a separate system, such

as increased efficiency and the ability to visualize tissue-instrument interactions. In this ongoing study, three prototype microscope-integrated OCT systems are being used by Cole Eye Institute surgeons to the feasibility and potential utility – the three-year outcomes of which have just been published (1). Of 837 eyes enrolled to date (244 anterior and 593 posterior segment cases), images were acquired successfully in 820 eyes (98.0 percent; 95% CI, 96.8–98.8 percent). In 106 anterior cases (43.4 percent; 95% CI, 37.1–49.9 percent) and 173 posterior cases (29.2 percent; 95% CI, 25.5–33.0 percent) surgeons reported that the technology influenced decisions during the surgical procedure. “We were surprised by the high frequency that OCT added value and impacted surgical decision-making – something that has also been confirmed in other studies,” says Ehlers.

According to the team, the three-year results demonstrate the feasibility and usefulness of microscope-integrated

OCT. “I use intraoperative OCT for most of my surgeries, including macular cases, complex retinal detachments, and proliferative diabetic retinopathy,” says Ehlers. “I hope this study will help guide and inform surgeons about the potential impact of using the technology.” A multi-center randomized trial is apparently in the pipeline to provide critical information on comparative outcomes with intraoperative OCT. And Ehlers says that extensive work is continuing on enhancing the technology for image quality and tracking, as well as OCT-compatible instrumentation and software analysis platforms. Who knows what the surgeons of the future will be able to see as they operate.

Reference

1. JP Ehlers et al., “The DISCOVER study 3-year results: feasibility and usefulness of microscope-integrated OCT during ophthalmic surgery”, [Epub ahead of print], (2018). PMID: 29409662.



Dimmer and Dumber

Too much time in the dark could impact brain function

As diurnal beings, light exposure is important. As well as dictating circadian rhythm, it also impacts other processes, such as wakefulness or mood. But does it also affect brain function during tasks? Research from a team of neuroscientists suggests that insufficient exposure to bright light could impact brain structure and function. The group from Michigan State University, East Lansing, USA, studied how bright and dim light affects hippocampal function in Nile grass rats (which are diurnal, like humans) (1). Following four weeks of exposure to dim light, the rats showed cognitive and behavioral changes, including impairments in spatial memory. Furthermore, hippocampal expression of brain-derived neurotrophic factor was reduced, and there was a 30 percent

decrease in dendritic connections in the hippocampus (Figure 1). Impairments in functioning and changes in hippocampal structure were reversed after four weeks exposure to bright light.

The authors concluded that light intensity affects cognitive performance and hippocampal structural plasticity. Could these findings have implications for people with ocular diseases, such as glaucoma and retinal degeneration? An ever better question was posed by Lily Yan, the paper's corresponding author (2): "For people with eye disease, can we bypass the eye and directly manipulate this group of neurons in the brain to provide them with the same benefits of bright light exposure?" Watch this space!

References

1. JE Soler et al., "Light modulates hippocampal function and spatial learning in a diurnal rodent species: a study using male Nile grass rat (*Arvicanthis niloticus*)", *Hippocampus*, [Epub ahead of print], (2017). PMID: 29251803.
2. Andy Henion. "Does dim light make us dumber?" *MSU News*. Available at: <http://bit.ly/MSU-dim>. Accessed: February 14, 2018.

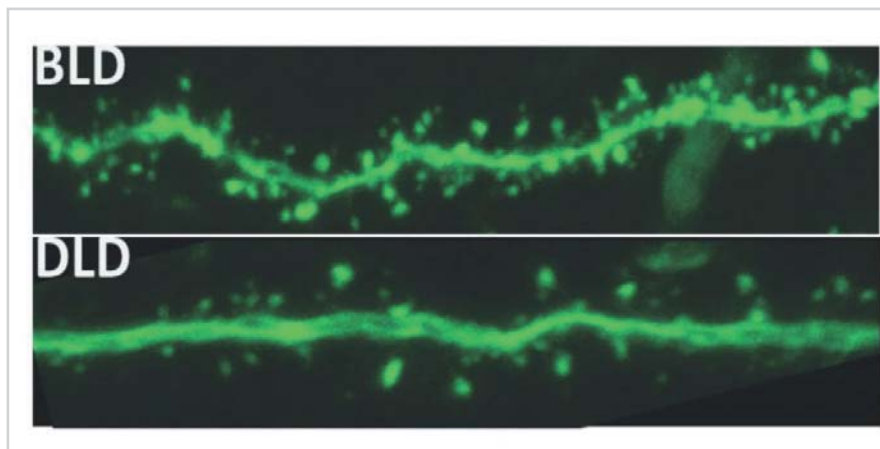


Figure 1. Nile rats exposed to dim lights (DLD) for four weeks showed a 30 percent decrease in hippocampal dendritic spine connections compared with rats exposed to bright light (BLD). Hippocampal apical dendrites were visualized by HSV-GFP expression following its injection into the dorsal hippocampus. Credit: Michigan State University.

FEMTIS®

NEXT FRONTIER IN IOL DESIGN:

Turn your Automated Capsulotomies
into Great Vision!

Oculentis® Am Borsigturm 58 | 13507 Berlin
Phone. 030 43 09 55 0 | Fax. 030 43 09 55 11
Web. www.oculentis.com/femtis

In My View

In this opinion section, experts from across the world share a single strongly-held view or key idea.

Submissions are welcome. Articles should be short, focused, personal and passionate, and may deal with any aspect of ophthalmology. They can be up to 600 words in length and written in the first person.

Contact the team at edit@theophthalmologist.com

Swallowing Professional Pride

Training non-doctors to perform cataract surgery is an obvious approach to tackle cataract blindness



By John Sandford-Smith, emeritus Consultant Ophthalmologist at Leicester Royal Infirmary, UK.

Untreated cataract remains the most common cause of blindness in all low-income countries, as well as many middle-income countries. Why, when it is easily, cheaply and quickly treated with good results?

In the developing world, where there may be barely one ophthalmologist for 1 million people, the bulk of surgeries become cataract surgeries. But this is not enough to eradicate cataract blindness, and our likely failure to eradicate treatable blindness by 2020 shows that the situation is under-resourced. In my view, the obvious solution is to train non-doctors (such as nurses). Many people have suggested this approach, and some countries, mostly in Africa, have accepted it. There are many advantages of training non-doctor cataract surgeons:

- Both the undergraduate academic training and postgraduate practical training are much shorter and less costly.
- Such a person is more likely to stay in the rural areas where they are needed rather than migrating to the big cities.
- Having had less training and less qualifications, they are likely to be content with a lower salary scale and

less likely to emigrate.

- Because the training is more focused and intensive, their surgical results should be as good if not better than the “fully” trained ophthalmic surgeon.

In modern slang, it would be considered a “no-brainer” in those countries where there is still a huge backlog of cataract blindness. But the idea remains a controversial one, and I don’t understand why. I have been involved in training “nurse cataract surgeons” in Africa, and could see little difference in their skills compared with those of the local ophthalmologists or with my own. Unfortunately, in some instances, although the government accepted this training, the local ophthalmologists were often very unsupportive, and in one case plainly obstructive. One would like to think that the reason for this opposition was to maintain professional standards. However, numerous audits have shown that the surgical results of a properly trained nurse cataract surgeon are just as good as those of an ophthalmologist.

I believe the opposition comes from more subtle causes. It could relate to professional rivalries; some ophthalmologists may feel like they have to preserve their privileged position (and income) after many years of training and education. Ophthalmologists may also be fearful that nurse cataract surgeons may take away some of their business. But in these underserved countries, there is potentially more than enough work for everyone. Unfortunately, ophthalmologists in developing countries often face challenging situations: government salaries are low and government hospitals often dispiriting places in which to work, and the only social security is the extended family. This usually means entering the very competitive – and sometimes ‘cutthroat’ – private practice market in the big cities to maximize one’s income.

For the most part, the boundaries between duties and responsibilities of doctors and nurses are blurred in both rich and poor countries. For instance, in the USA, nurses

can be trained to administer anesthetics, but most routine births are delivered by obstetricians. By contrast in the UK, anesthetics are always given by doctors, and nearly all babies are delivered by midwives. In my own postgraduate teaching hospital in Leicester (UK), most carpal tunnel surgery

is now performed by a specifically trained nurse rather than an orthopedic surgeon. His audited results have always been excellent, and he has probably performed more carpal tunnel surgery than anyone else in Britain.

It is high time for us to swallow our professional pride and accept that where

there is a desperate shortage of fully trained specialists, that anyone who has been properly trained and accredited is the right person to do the work. An ophthalmologist does not just perform cataract extractions, and there is still a great deal of other needy work for the fully qualified surgeon to undertake.

The Secret is the Secretions

Stem cells hold great promise, but is it the cells we really need?



By Nicolas Sohl, CEO and co-founder of Cell Care Therapeutics, Los Angeles, California.

Ophthalmology is full of advances, but sometimes the field is very conservative. Look at the extended-release drug delivery systems that have made it to market: Vitrasert, Ozurdex, Retisert, Iluvien. New drug delivery technology, but really old drugs (ganciclovir, dexamethasone, and fluocinolone acetonide). I think it's clear that the use of steroids for the treatment of retinal disease will diminish – their drawbacks and side-effects are well-known, and there's (hopefully) better therapeutic approaches on the horizon.

Many companies are focusing on cell therapies to treat retinal diseases. They look like an attractive option; they've been heralded as being able to “regenerate” or “rebuild” the retina. There are a number of companies that are currently developing and even trialing intravitreal stem cells clinically for retinopathies, in particular for retinitis pigmentosa, Stargardt disease and AMD.

If they can deliver on their promise, that's wonderful. But there are aspects of this approach that still need to be resolved.



Adult bone marrow or adipose tissue-derived mesenchymal stem cells (MSCs) and CD34+/hematopoietic stem cells (HSCs) – look like they have beneficial paracrine effects on ischemic and/ or degenerating retina. Placing them into the vitreous, or on a scaffold, subretinally to replace damaged tissue are all potential ways of treating currently untreatable diseases. But what is really happening to MSCs or differentiated retinal progenitor cells (RPCs) once they've been implanted? What happens to their phenotype and their therapeutic capacity over time? Some incredible work has been put in to ensuring that implanted cells behave well but, over time, growing evidence suggests that they can become problematic when they abnormally turn towards an epithelial-like phenotype.

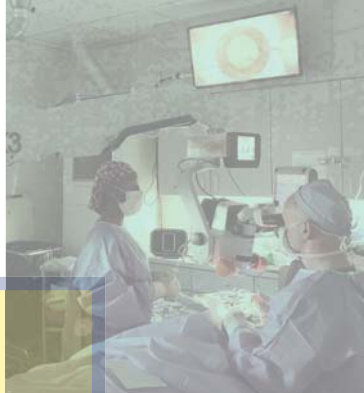Nevertheless, there are a number of companies developing treatments that use MSCs. Other stumbling blocks ahead? If they're allogenic, and the goal is transplantation, they will need to express MHC – and the immune system will seek and destroy them. So if they're being used for their immunoregulatory properties, they won't persist for too long. Essentially, the transformative effect is only that of the initial dose, so it truly is an initial benefit, not a prolonged one. How frequently and how often, then, would you need to continue administering stem cells for?

What if the main benefit of MSCs is the secretion of a potent mix of anti-inflammatory mediators and pro-regenerating growth

factors and extracellular vesicles? And if you can harvest those and administer them, why do you need the stem cells?

We are doing exactly that. We can – on an industrial scale – grow engineered MSCs, harvest their secretions, and process them into a cell-free biologic (at high concentrations – essential for intraocular drug formulations – and stable at room temperatures) that can be administered by traditional intravitreal injection. We've implemented robust manufacturing controls and use a panel of analytics to ensure comprehensive product identity and batch-to-batch consistency. We're still at a pre-clinical stage, but animal studies have shown that for chronic inflammatory diseases in the retina, such as wet AMD and DME, you can get very robust protection from inflammation, oxidative stress and fibrosis, thereby protecting vision – which, at a minimum, should provide a treatment option for patients refractory to anti-VEGF therapy. We're still working on dosing frequency. Clearly, treating a chronic disease with a single injection won't have a permanent effect, but we believe our offering will be comparable with the latest biologics administered intravitreally to the eye. Furthermore, unlike cell therapy, this approach allows you to tightly control the dose administered – something that “conservative” ophthalmologists will both appreciate and be comfortable with. Perhaps the future of retinal stem cell therapy isn't a single application of stem cells, but rather one that looks much like it does today: intravitreal injections, but with far better outcomes.

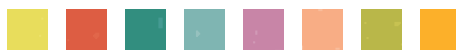



CONFESSIONS OF A LIVE SURGEON

Four leading veterans of the operating theater share their experiences – in gripping detail


By Ruth Steer



Visuals play a huge part in our learning – and it’s no wonder, we’re visual creatures. When it comes to pages of text or a colorful infographic, it’s clear which most people would prefer. Similarly, we learn many skills through observing others. The ophthalmic surgeon is no stranger to this form of education; whether a novice or a practiced professional, observing others is a

valuable learning tool. It’s why live surgery is so essential.

But what is the live surgery experience actually like – and what goes into delivering it? Four veterans reflect on their encounters, share notable memories, and offer insight into secrets behind the “show.” Whether you’re an observer – or a performer – join us on a journey of language barriers, surprise surgery events, and even cobra bile.



NO REGRETS

Live surgery is tougher than it looks – but it is a very worthwhile experience

By Uday Devgan



Live surgery is a lot more challenging than people think. My first live surgery was back in 2003, and I was nervous – the pressure was on! So I prepared in my own private operating room in Los Angeles, giving a running commentary – either out loud or in my mind – as I was operating. I recorded all my cases, and went back afterwards to go over them and check that I wasn't making too many 'ums' or 'ahs' or stutters. Basically, I practiced. And it made a difference.

I've performed live surgeries in over a dozen countries, primarily at the large ophthalmology meetings (such as AAO, ASCRS, ESCRS, and the Asia-Pacific meetings) as part of industry showcases. What many people don't realize is that the goal of live surgery is to make it look effortless – it should look smooth and choreographed, like watching a ballet dancer. But this can actually be very difficult, as the operating room setup can be very different to the traditional operating room that people are accustomed to seeing. There can be half a dozen extra people, there'll be multiple cameras and the floor can be covered with cables. You may also have to hold your instruments slightly differently so that the camera angles aren't obscured. Another big challenge is that you might have two different earpieces whilst operating; in one ear, the director is giving you instructions, and, in the other, the moderator is talking

to you and the audience. Additionally, though people mainly want to see you do well, they wouldn't mind seeing a fumble or two. But if complications arise during live surgery, you just need to stay calm and manage them as you would in your normal operating room.

LIVE LEARNING

I think there is a beautiful learning to live surgery. When sitting in a live surgery audience, I learn a lot. Even now at large meetings, I always seek out the live surgery events as I want to see them! You're seeing everything in real time – rather than edited clips – so you pick up a lot of subtleties. As surgeons, we're used to seeing through the microscope, but in live surgery, cameras can show how your hand is positioned, as well as what your feet might be doing. It's why there are meetings entirely focused on this area. One such event, organized in Italy by Lucio Buratto, is a two-day meeting of entirely live 3D surgeries; it is a fantastic meeting and a great way to learn.

I haven't been involved in live surgeries in the last few years; as my career advanced to running my own practice, I have found I have less time to do it. Plus, I also want to give others a chance at experiencing it! For surgeons at an earlier stage of their careers – and with more available time – it's a great way to make a name for themselves. I think live surgery is a fantastic experience and an amazing thing to do; I loved it. And I would definitely encourage skillful surgeons to get involved.

Would I go back to doing live surgeries in the future? A definite yes – if the timing and circumstances were right. For now, I am just so glad I got to experience it.

Uday Devgan is a cataract and refractive surgeon at Devgan Eye, Beverly Hills, California, USA.

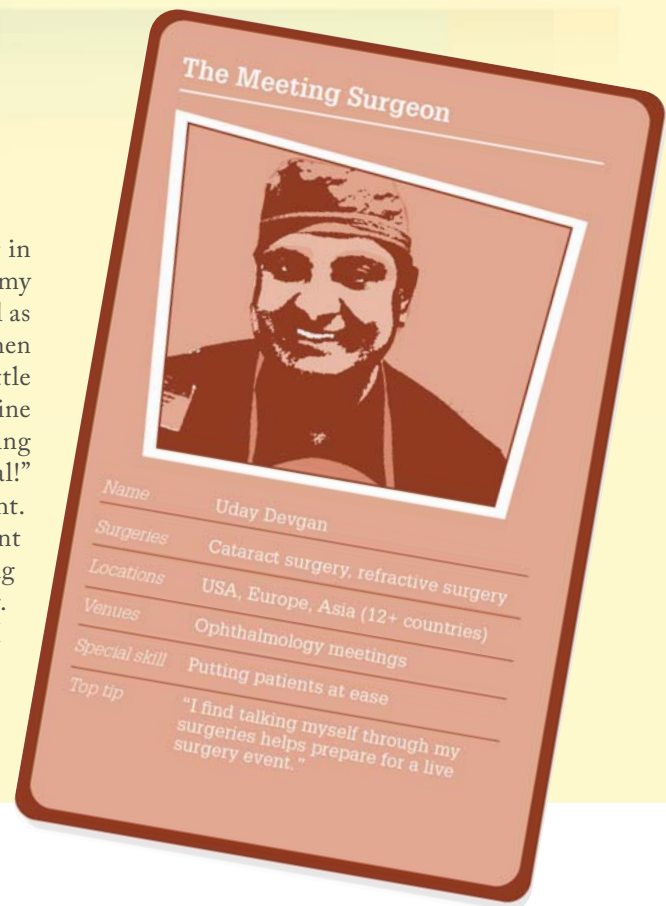Practical considerations

- Generally, patients have already had their first eye completed so they know what to expect and are more comfortable with the process on their second eye.
- If performing more than one live surgery in a day, make sure that you're operating on all the same eyes (right or left). It can be quite time consuming to switch all the cameras and angles between different patients!
- Try to choose people with lighter-colored eyes if you can. I myself have brown eyes but, in my opinion, a blue eye just works better on the screen!
- Stay calm under pressure – you have to ensure the outcome for the patient. Remember that you wouldn't be operating in front of hundreds or thousands of colleagues if you weren't at the top of your game, and that companies wouldn't select you to represent their products if you weren't the 'best of the best'.
- Don't be afraid to moderate the moderator. If you're performing the capsulorhexis and the moderator asks about IOL insertion, you can acknowledge the question but refer back to what you are actually doing. "That's a good question – let's address this later." It is much easier to talk about what you are actually doing.
- Likewise, if moderating a live surgery event, stay on the same page as the surgeon – it is difficult for them to be doing one thing and talking about something entirely different.
- Practicing before the event can be really helpful. Also, try to be entertaining – don't drone through the procedure in a monotonous voice. It has to have some cadence to it; it has to be fun.
- Most importantly, remember to enjoy yourself. Live surgery is not an easy task, but it is fun, and a great and enriching learning experience.

Confession

Sometimes surgical terms don't hold the same meaning in other languages. In the US, I use 'topical' anesthesia for my cataract cases, which means I use anesthetic drops as well as patient sedation. At my first Italian live surgery event, when I requested topical anesthesia for my patient – a sweet little grandmother – they presented me with a bottle of tetracaine and said, "Go ahead!" When I queried if they were going to administer sedation they replied, "No! You said topical!"

"Oh my god. How am I going to do this?" I thought. Asking someone to help me translate, I told the patient she looked exactly like my grandmother and I was going to perform the same beautiful surgery that I did for her. That was like her sedation – it calmed her right down! I also learned one important phrase that helped hugely with the procedure: "Signorina, per favore guarda la luce." And I don't speak Italian!



KEEP CALM AND CARRY ON PERFORMING



Live surgery is great, but sometimes it's complicated... I share my top tips

By I. Paul Singh

Most know me as an ophthalmic surgeon. But outside the clinic I play keyboard in a band, and the experience has really influenced my surgical skills. Not only has it helped me strengthen the ability of my non-dominant hand, it has helped me when it comes to performing live surgeries.

Pretty much every surgeon, whether doing live events or presenting on the podium, gets a little nervous. Me too – I'm not immune to a bit of stage fright! Performing live on stage with my band and talking to the audience has definitely helped me learn that your approach is what matters.

Leading up to the event is the most nerve-wracking part. It will likely be on your mind the night before and in the morning when you wake up. Then you get to the operating room to find all the cameras and the production team; it can feel a little overwhelming. But if you're feeling stressed, you just need to revert back to basics. You're talking to your colleagues, and they are learning from you. Some of your surroundings might be unfamiliar – the microphone on your scrub and the camera in your face – but once you sit at

the microscope or laser and get started, it isn't any different to the thousands of cases you've performed before in your own office. It is just you and the patient, and you automatically revert back to your muscle memory. I find it is helpful to make your surroundings as familiar as you can, whether it is how you sit or the chair you use.

EXPECT THE UNEXPECTED

You may have a version in your head of how you expected the surgery to go. But if it doesn't go that way, don't panic. If a complication does occur, just take a pause to re-evaluate. Those 10 seconds might feel like an hour in your mind, but they can help you stay calm and go back to the 'basics' of the procedure that you are trying to teach the audience. This brings to me a key piece of advice – be prepared to expect the unexpected. Surgery is surgery. No matter how much you plan, unexpected things can happen (See 'A series of unexpected events'). If things don't go the way you planned, turn it into a teaching tool – tell the audience: "This is part of real surgery." It's important because the learning process for everybody is not just a perfect case! And that's actually the beauty of live surgery – it's unedited. A bit of a challenge is good because every surgeon encounters challenges – and it makes it more real for the audience. Just keep talking through what you are doing to overcome the challenge and it all adds to the learning experience for the audience. It also helps to remember that much of the time you're teaching colleagues who haven't had as much experience with the topic as you. So even if something doesn't go the way you hoped, they're not necessarily going to know the

A series of unexpected events

- One time, I was moderating a live femtosecond laser-assisted cataract surgery case – and the suction clip fell off. The surgeon and I looked at each other. There was nothing to do but start stalling. “Let’s talk about some of the different nuances of the laser,” I told the surgeon. And it turned out well because while he was re-docking the suction clip, we got to talk about the features of the laser. It wasn’t a big deal!

You just have to take these things in your stride. Also, it shows how important it is for the moderator to think fast on their feet to minimize any impact to the event.

- On two separate occasions, I’ve been in South America to provide some teaching on laser floater removal. But arriving at the venue, I discovered my host had arranged live surgeries for me to perform as well. One included a patient who had a history of vitreous trauma – not the

easiest case – and the host’s son who had a floater! Honestly, I was extremely nervous being confronted with these surprise live surgeries. But I just went with the flow and took my mind to being back in my own office. As soon as I sat down at the laser, muscle memory kicked in. The case where the patient had prior vitreous hemorrhage was tough but it went well; afterwards, the case host revealed he’d set that one up to test how good I really was...

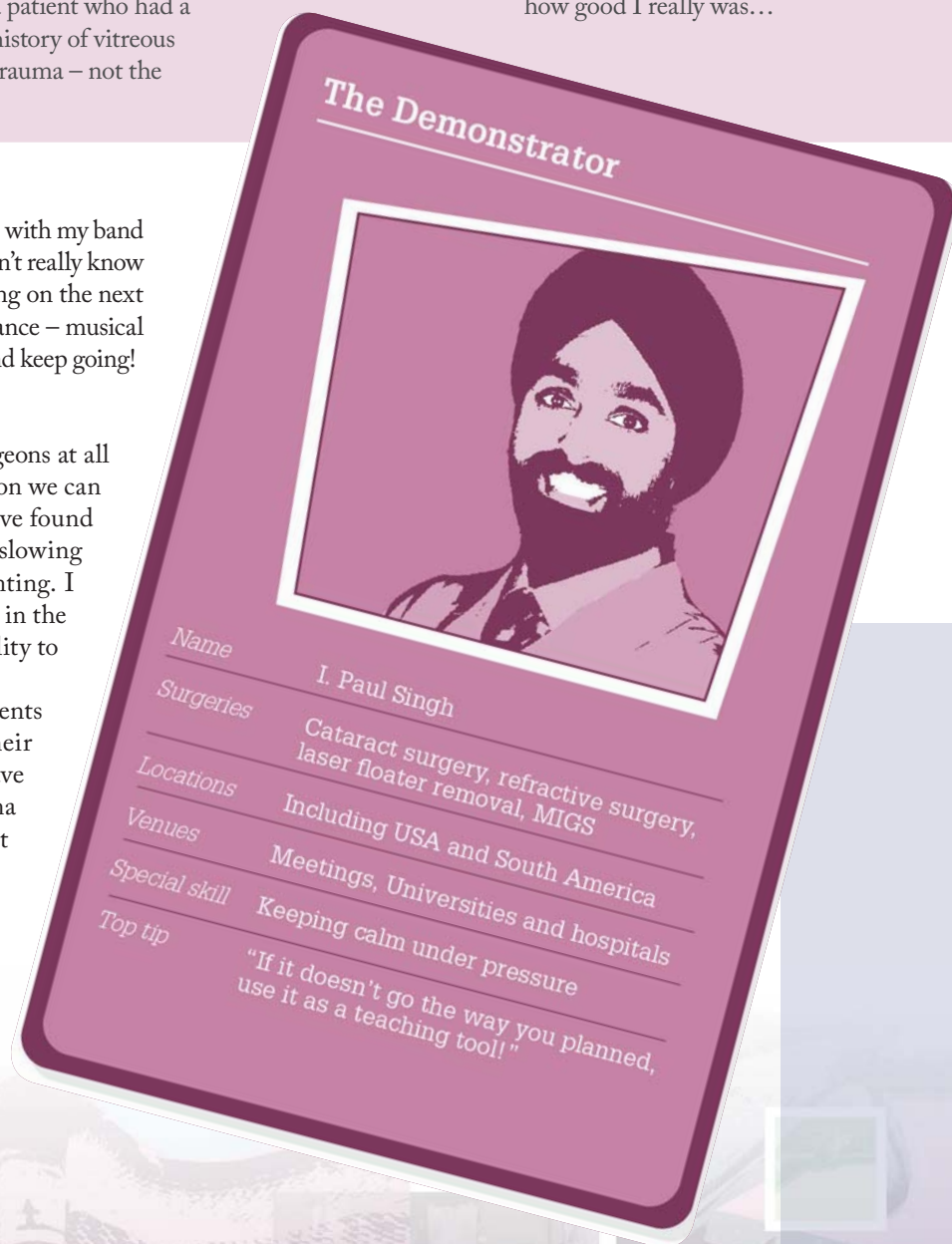difference! I’ve made many mistakes when on stage with my band and thought “Oh no – I suck!” But the audience don’t really know what the song was supposed to be, or were focusing on the next part of the song. How you approach the performance – musical or surgical – is the important part. Keep smiling and keep going!

A SOCIAL COMMENTARY

Live surgeries are a key learning element for surgeons at all levels of experience. The more surgical interaction we can have, the more we can learn from each other. I’ve found the news that some companies are considering slowing or shutting down live surgery events disappointing. I do hope that they will continue to support them in the future because it is so important to have the ability to share ideas and experiences in this way.

With this in mind, I am hoping smaller events will incorporate live surgery as part of their program. A group of glaucoma surgeons have helped to create a meeting called, “The Glaucoma Forum.” As part of this, we are hoping to host an interactive live surgery event on the decisions and different factors influencing the choice of MIGS procedures in patients. We’re excited about the idea – and it will likely serve as a great teaching tool. Watch this space!

I. Paul Singh is President of The Eye Centers of Racine & Kenosha, Wisconsin, USA. Singh reports that he is a consultant for Ellex.



“TEACH A MAN TO FISH...”

International ophthalmology is about so much more than just performing live surgeries



By Steve Charles

I don't like the term “medical mission.” I actually recoil when people use it. Over the past 42 years, I have performed live vitreoretinal surgeries in 25 different countries in a variety of venues, but I'm not a missionary – I'm just sharing my surgical experience with my colleagues across the world.

International ophthalmology is never just about doing volume surgery. True international ophthalmology is about a multiplier effect – think of the old adage “teach a man to fish.” If you just perform a load of surgeries, you're not really helping to improve the status quo, because you're not leaving much behind. But if you truly partner with your ophthalmology colleagues abroad, you can have a sustainable impact; you can ensure that they can deliver volume care based on your teaching – as well as passing that teaching on to others.

REAL SUSTAINABILITY

Promoting surgical efficiency is a key early teaching. On my first trip to Beijing, I found they were performing two or three cases a day and had 20 or 30 employees in the operating room. In my operating room in Tennessee, I do 12 cases a day and have two employees! They had a two-year waiting list and people were

going blind; teaching them how to be fast and how best to use their equipment and human resources was vital.

Building relationships and maintaining contact is key – as is sharing resources. If you have any books or papers that you can take over and give them, please do; it will support what you have demonstrated in the operating room. Furthermore, if you can share the resources on screen to describe what you are doing beyond the operating room, it has a huge multiplier effect. Even in 1987, when I was operating on the Orbis DC-8 Flying Eye hospital in Moscow, a black and white TV in the cabin screened what was happening in the operating room. When in Beijing on the Orbis DC-10 in 1994, there were way more doctors than could fit into the aircraft, so a large screen was installed in the hangar to allow more people to watch the surgery. And because the doctors were ‘on site’, they could alternate physically coming on board the plane and asking questions – a much higher level of engagement than just live-streaming the surgery on the web.

Sustainability isn't just about partnership and education, it's also about ensuring feasibility; there is no point using fancy equipment in a live surgery, if that particular location will not have access to it when you are gone. You also need to make sure they have sufficient finances to source the consumables needed for the surgeries. ‘Vetting’ hospitals to assess infrastructure, as well as the best and most ethical people to teach and pass on knowledge, means that your efforts are likely to be more sustainable. Collaborating with the right people is also important. When attending international meetings, it is always worth seeing who shows up and gives the most insightful and interesting talks; these are typically the leaders in the field back in their country, and are often the best people to collaborate with to ensure sustainability.

The do's and don'ts of international ophthalmology

DO

- Take a sustainable approach – train the trainers and teach the teachers. Partner with your new colleagues and share skills. Build relationships and maintain email contact. Even facilitate visits to your operating room. All this ensures an ongoing sustainable approach beyond performing surgeries.
- Be culturally sensitive.

- Make sure you are delivering the highest care possible.
- Use their team and their equipment. If you bring technology that they cannot afford, it isn't sustainable.
- Emphasize medical ethics and post-operative care. Also teach when to operate and when not to operate.
- Teach and instill the importance of efficiency – 70 percent of surgery costs are labor.
- Watch your ego! International ophthalmology is not a ‘photo-op’ for practice building at home.

DON'T

- Show off. There is no need to show an extreme triple procedure. Perform and show a mainstream procedure; something that will be encountered frequently, but can be a little bit difficult. There is no point demonstrating a really uncommon case that might never be encountered again.
- Use the term ‘third-world country’. If you really must assign a title use the term ‘developing country.’
- Drink too much or party too hard...
- Forget why you are there!


Confession

I remember operating in Beijing, when the temperature hit the highest ever recorded. Unfortunately, the operating room only had one spare electric outlet, so either the air conditioning unit or the laser we needed for the procedure could be plugged in. They cut the back out of my scrubs; and when I wasn't using the laser they blew cold air onto my bare back so the sweat wouldn't drip off my head and onto the patient!

I have a lot of experiences where my engineering background came in handy. I remember operating in Havana with Orbis, and the power generator and the air conditioning failed. Because the engineers had left the plane, I went and checked what was wrong with auxiliary power unit. I fixed it and got it re-started, restored electrical power and finished the case. Similarly, another time in Singapore, the microscope failed. I found some tools and a ladder, took apart the power supply, and fixed it so that the case could be finished. Being knowledgeable about how equipment works and how to fix it on the fly has definitely been important to my live surgery experiences. Wherever I go, I always try to instill an understanding of how the equipment works.

I have also had some interesting live surgery experiences outside of the operating room. Once again in Beijing, I was invited to a large reception where I was seated across from the Minister of Health. He handed me the aperitif: cobra bile. It was the vilest smelling substance I had ever encountered – but all eyes were on me. So I knocked it back and slammed it down. One of the Englishmen at the same table asked me how it was, and all I could say was that it was much finer quality than the cobra bile we drink back home! So every now and then strange food objects might appear. It does pay to be culturally sensitive, but I do have rules...

The International Teacher



Name Steve Charles

Surgeries Vitreoretinal surgery

Locations Worldwide (25 countries)

Venues International meetings, Orbis Flying Eye Hospital (DC-8 and DC-10), local hospitals, private surgery clinics, universities

Special skill Engineering and sustainable teaching

Top tip "Remember why you are doing the live surgery, and use it as an opportunity to teach others – and to learn from them."

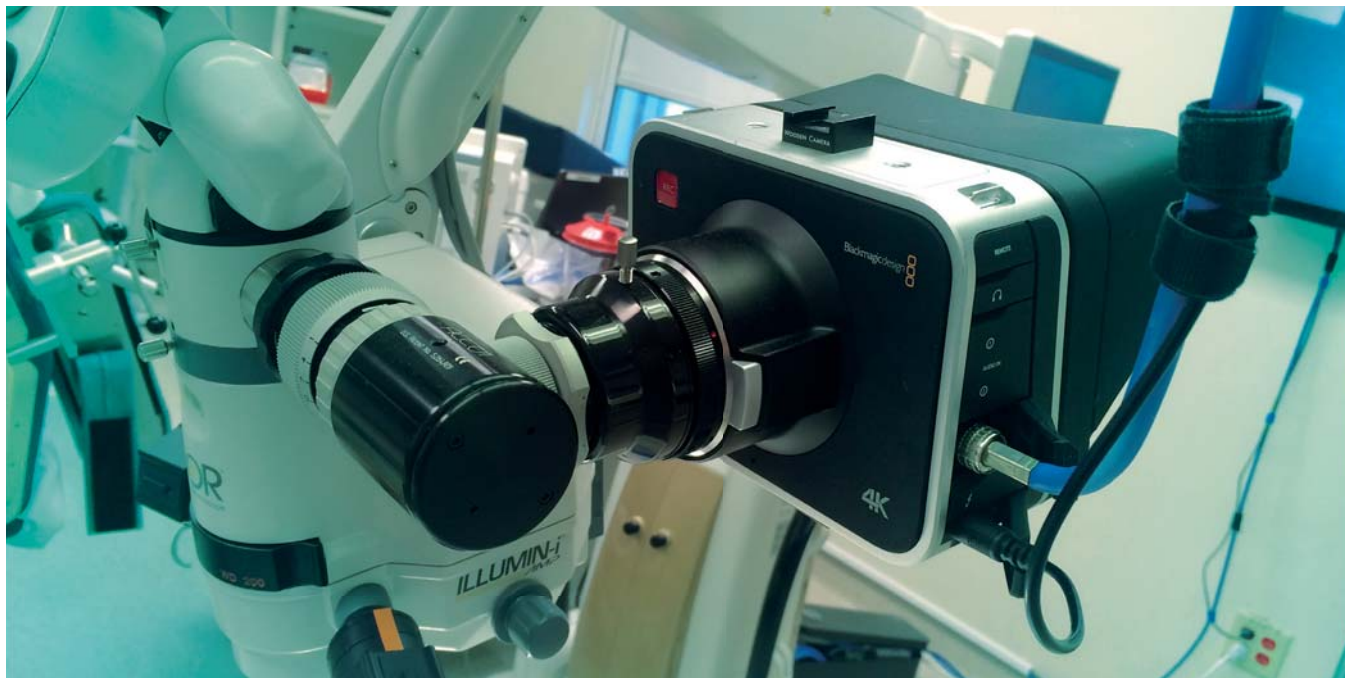INTERNATIONAL GUIDELINES

In my opinion, there are too many surgeons who can't wait to travel to a country with eyecare challenges, perform a handful of cases, spend four weeks climbing a mountain or sightseeing, before returning back home and declaring that they are a philanthropist. I think it is simply wrong to go to another country and spend one day pretending to help people so you can put it on your Facebook page or declare a victory in your local church. When I am performing international surgeries, I try to send the right messages (see 'The do's and don'ts of international ophthalmology'). I don't need to go on a VIP trip to the Taj Mahal or the pyramids; I don't want a fancy private dinner with the chairman of the department or the President; I don't want to be given an award or have my picture taken for the wall. I am just a regular surgeon, and I want

to spend time with all the doctors that I am there to work with. I'm not saying that all sightseeing is bad – if your international colleagues are proud of their culture and initiate the process it is a wonderful way to build collaborative relationships! I just think that spending the majority of your time vacationing and resting can send the wrong message. I also discourage gifts – I would much rather see money being put into equipment and education.

International ophthalmology is about so much more than going and performing live surgeries, it's really about delivering sustainability. And it is not about you. Train the trainer and leave behind a legacy of better care.

Steve Charles is a vitreoretinal surgeon and founder and owner of Charles Retina Institute, Memphis, Tennessee, USA.



STREAMING REALITY

Live streaming is an exciting extension to the clinical practice of ophthalmology

By James Lewis



As a cataract and refractive specialist, a typical week involves seeing patients and performing surgeries, just like many other ophthalmologists. What isn't so typical is that every week I live stream approximately 50 of my cases via YouTube and my website, LASIKTV.com.

What inspired me to do this? Live streaming my surgeries demystifies ophthalmic surgery for the public, as well as demonstrating LASIK and anterior segment surgery for prospective patients. The live surgery also enhances communication with fellow surgeons, provides students and clinicians with an appreciation of techniques painfully absent in highly edited videos, and allows me to compare my techniques with other practitioners.

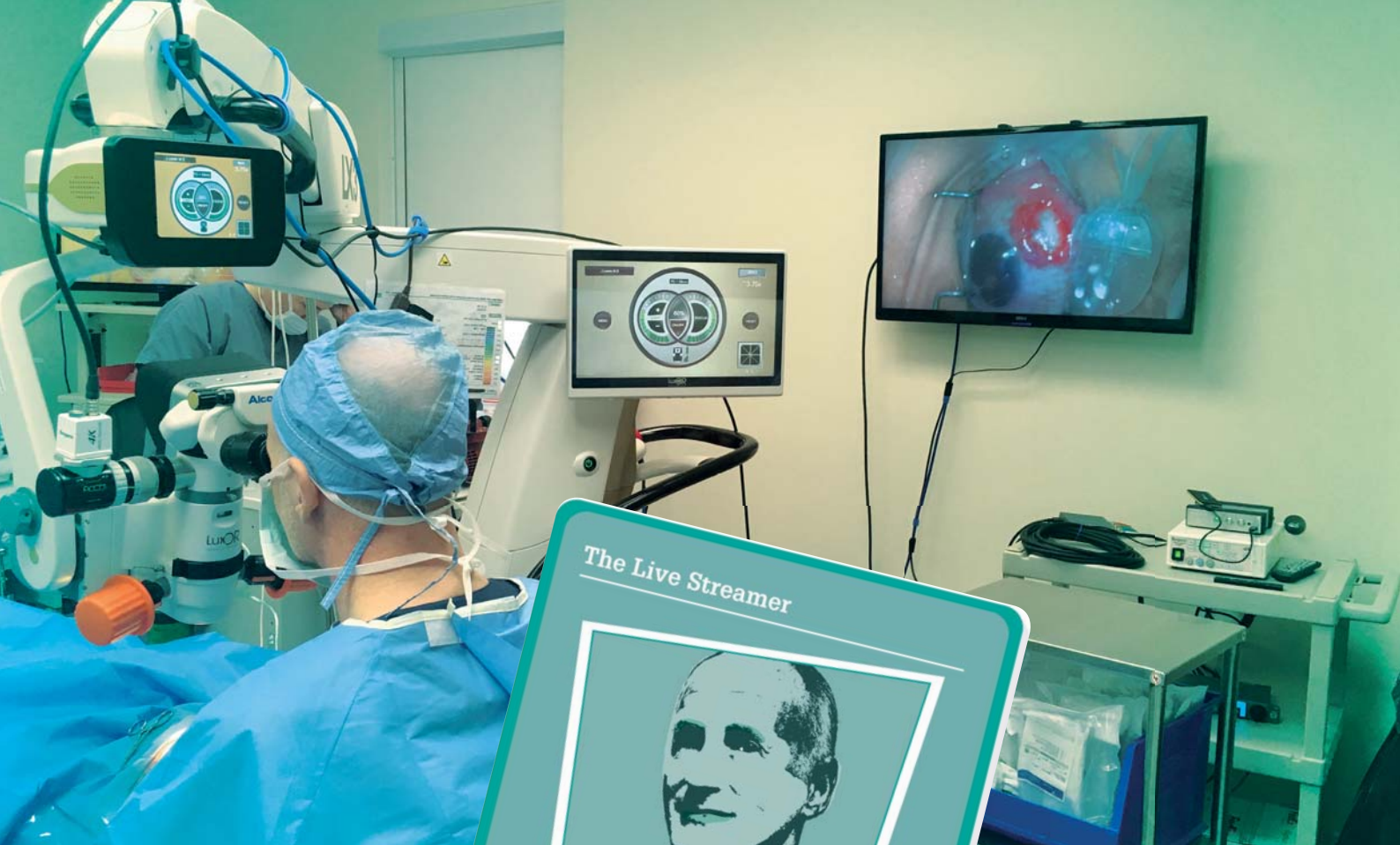
GOING LIVE

I first began recording my cases in the 1990's and handed VHS tapes to my patients. I then migrated to DVDs and

finally to YouTube streams. I actually found the first cases psychologically atraumatic because I was accustomed to being observed by residents, fellows, referral sources – and the occasional insistent family member. It is actually reassuring to know that your best efforts are memorialized and the management of difficult clinical scenarios is well documented. I also retain 4K copies of interesting cases for lectures or other presentations.

Incorporating streaming into surgery has been incredibly useful. At the end of the case, I can collect the YouTube URL and paste it into the patient's chart as well as forward it to their email address. The live surgeries also enhance the patient-physician relationship through generating a level of understanding and appreciation – questions are answered and patients are often reassured that I am willing to provide unrestricted access to my surgery. Some are interested in the mechanics and find viewing the procedures calming; some appreciate the realism. Referral sources also enjoy watching select cases, which helps with patients choosing my practice. Students have found that streaming extends their educational experiences, and I have used live streaming to teach hundreds of surgeons transzonular instillation of antibiotics/steroids.

I have also used my streaming to help device manufacturers assess new instruments, as they can gather vital information from live remote observation. Furthermore, while the pundits contemplate the merit-based incentive payment system (MIPS)



The Live Streamer



Name	James Lewis
Surgeries	Cataract, CAT/MIGS, Valves and Shunts, DSEK, Lens Exchange, Visian ICL, LASIK and PRK
Locations	USA
Venues	James Lewis MD, Pennsylvania; YouTube: LASIKTV.com
Special skill	Routine performer, enhancing physician-patient relationships
Top tip	"Live streaming can help demystify ophthalmic surgery, as well as enhance patient-physician relationships. It also helps me in my practice too!"

and other clinical assessment tools, I find that video preservation of clinical and surgical encounters to be far superior to all the arduous documentation. Furthermore, live streaming can convince a skeptical insurance company that a cataract surgery should be reimbursed as ‘complex’.

Despite expanding hard drive capacities and improved compression techniques, nothing compares to the permanent, limitless, zero cost, secure storage provided by YouTube. Fellow ophthalmologists who are interested in live streaming should first optimize their microscope, their video adapters, cameras, recording systems and monitors. Next, they should explore software, webcams, and format converters/switchers so the production remains trivial yet polished. With the growing popularity of webcasting and streaming, the market is replete with highly professional and affordable devices.

A staff member, preferably someone motivated, should act as the Director. I defer all streaming decisions to the Director so that I can focus on entirely on the procedure. Before your first live streaming, master the camera software, resolve

network considerations, finalize camera positions and establish a protocol for the video sequence. Sound, color, brightness, contrast, centration, patient privacy – and staff demeanor – must be established before you go live. Also remember that the quality and content of the live stream is of course secondary to the well-being of your patient; you should ‘de-stream’ if the clinical situation warrants or convert the stream to private.

My next endeavor is to video-document my clinic securely online. For now, catch me every Friday and every other

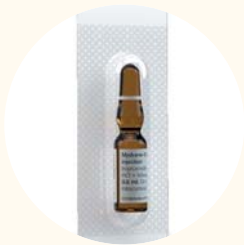Monday on my YouTube channel, and every Wednesday on my LASIK channel!

James Lewis is a cataract and refractive specialist in Elkins Park, Pennsylvania, USA.

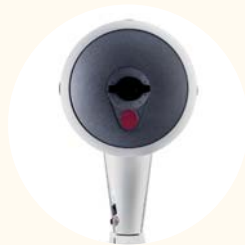Lewis’ live streamed surgery can be watched on YouTube via the following link: www.youtube.com/user/jslewisMDPC. Live LASIK surgeries can be viewed through: lasiktv.com

Technology to Empower: Cataract

Cataract surgery is one of the most ubiquitous procedures in ophthalmology – in fact, it's the most commonly performed elective surgical procedure in the world today. With a strong history of innovation and development, today's cataract surgery offers better outcomes than ever – and this trend is set only to continue. Here, leading ophthalmic companies showcase their latest cataract surgery technology, and explain what these advances mean for you and your patients.



28–29
The future of
Mydriasis



30–31
Two
in One



32–33
Simplicity Itself:
the IC-8® Small
Aperture IOL



34–35
Three Words:
Simplicity, Quality,
Performance



36–37
The Next
Generation

THE FUTURE OF MYDRIASIS

Mydrane® intracameral injection: a new standard in cataract surgery¹



The lengthiest part of a cataract procedure often isn't the surgery itself – it is the time needed for patients to achieve mydriasis. Dilating eyedrops may be the traditional standard of care, but there are drawbacks associated with delayed mydriasis: longer pre-operative preparation and systemic side effects. Now, there is a faster, more convenient and safer way: Mydrane®.

Mydrane® is a standardized, ready-to-use preparation for intracameral mydriasis that contains a unique combination of two mydriatics (tropicamide 0.02 percent and phenylephrine 0.31 percent) and the anesthetic lidocaine (1 percent). Intracameral injection of 0.2 ml of Mydrane® after the first incision induces rapid and stable mydriasis; 95 percent dilation is achieved within 30 seconds after administration (see Figure 1)(1, 2). Furthermore, the effects are long-lasting: mydriasis is maintained during the whole procedure, unlike eyedrops, where re-mydriasis might be required (3).

In a Phase III trial involving over 555 patients (4), Mydrane® was proven to be a safe and effective alternative to eyedrops for initiating and maintaining large and stable mydriasis and analgesia during cataract surgery. It has also been associated with significantly less patient discomfort during the procedure, and surgeons reported that cataract procedures were easier in cases where Mydrane® was used, as compared with dilating eyedrop use – particularly with lens insertion. Most importantly, less time is needed to complete the surgery with Mydrane®. Thanks to the simplified procedure in which the unique combination is injected directly into the intracameral chamber in the operating room, the time that patients need to wait during the pre-operative stage in the outpatient

department is significantly reduced. Not only is the routine use of intracameral mydriatics more comfortable for the patient, it could also modify the organization of surgical sessions, allowing surgeons to take advantage of more flexibility and rapidity for the turnover of patients.

Mydrane® is available in Europe as a box of 20 sterile 0.6 mL ampules and 20 sterile filter needles, and is indicated for cataract surgery to obtain mydriasis and intraocular anesthesia during the surgical procedure (2). Mydrane® is the first marketed product for this indication in Europe, offering a ready-to-use standardized solution with regulatory protection as an alternative to the DIY process already used in some countries.

References

1. Internal report on phase II clinical study on small pupils. Efficacy and safety assessment of intracameral T2380 (Fixed combination of lidocaine, phenylephrine and tropicamide) to obtain mydriasis in patients with small pupils for cataract surgery by phacoemulsification. Pilot, multicentre, open Study. Data summary in Clinical Overview (LT2380-PII-09/12). Data on file Marketing Authorization dossier.
2. Mydrane Summary of Product Characteristics (September 29, 2017). Laboratoires Théa, Clermont-Ferrand, France. Available at: bit.ly/mydranesmpc
3. F Chiambaretta et al., "Pupil dilation dynamics with an intracameral fixed combination of mydriatics and anesthetic during cataract surgery", *J Cataract Refract Surg*, In press.
4. M Labetoulle et al., "Evaluation of the efficacy and safety of a standardized intracameral combination of mydriatics and anaesthetics for cataract surgery", *Br J Ophthalmol*, 7, 976–985 (2016). PMID: 26531052.

1. Indicated for cataract surgery to obtain mydriasis and intraocular anesthesia during the procedure in adults only. Mydrane is indicated for patients who have demonstrated a satisfactory pupil dilation with topical mydriatic therapy during pre-operative visit.

Mydrane® in Action

Mydrane® offers the fastest way to obtain an efficient and stable dilation compared with mydriatic eye drops (3). Within 30 seconds of administration, 95 percent of pupil dilation is obtained – and subsequent viscoelastic injection often has an add-on effect. Figure 1 shows three separate cases in which mydriasis has been obtained within 30 seconds after Mydrane® administration, with one case achieving dilation in only 10 seconds. Figure 2 shows the speed of pupil dilation, with 95 percent of pupil dilation obtained with Mydrane® within 30 seconds.

Mydrane® induces a long-lasting pupil dilation that remains stable throughout the surgery, allowing IOL implantation under good conditions (Figure 3).

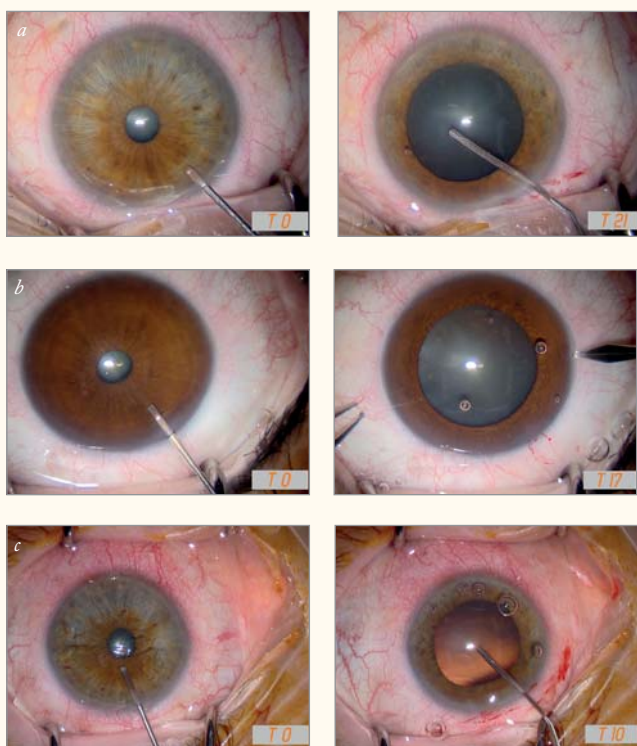


Figure 1. Pupil sizes before Mydrane® injection (T0), and 21 seconds (a), 17 seconds (b) and 10 seconds (c) after administration

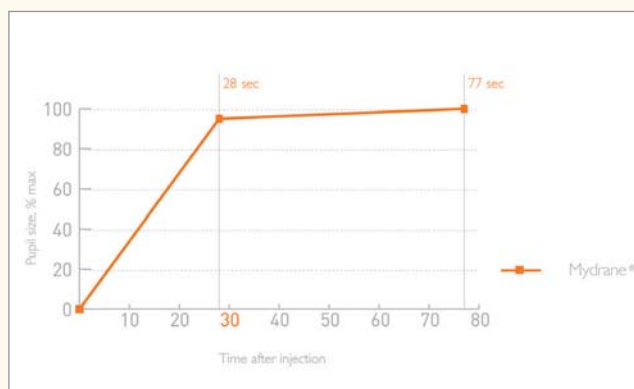
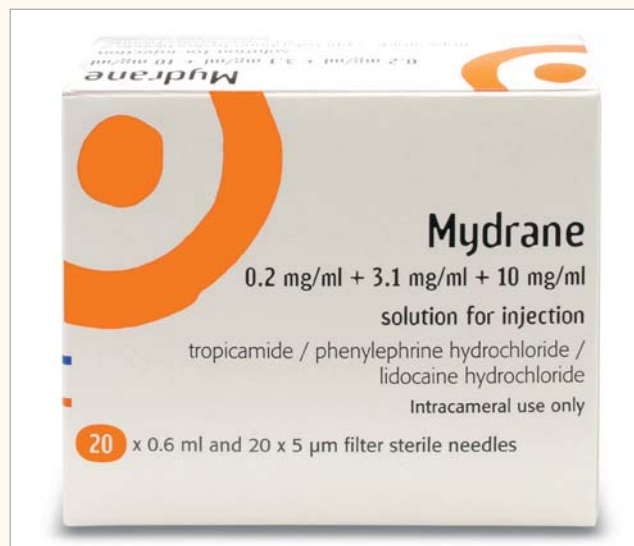

Figure 2. Pupil size after Mydrane® injection

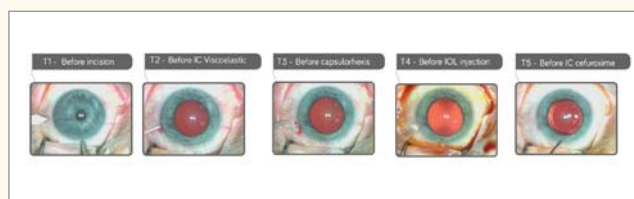

Figure 3. Pupil size throughout the cataract procedure. IC, intracameral.

TWO IN ONE

Anterior segment tomography and IOL calculation all-in-one device: the OCULUS Pentacam® AXL

All surgeons want the best for their patients, and when it comes to refractive outcomes, anterior segment analysis plays a key role. The Pentacam® and Pentacam® HR provide a gold-standard in anterior segment tomography. Now meet the newest member of the family – the Pentacam® AXL.

Based on the trusted Pentacam® HR system, which offers high-resolution Scheimpflug imaging, the Pentacam® AXL offers the additional feature of axial length measurement – a crucial part of accurate IOL calculation and customized IOL selection. Through partial coherence interferometry biometry, the Pentacam® AXL collects several successive axial length measurements; patient eye movement is detected by the pupil camera and corrected for, and a 3D model of the anterior segment based on ray tracing allows for the correction of individual optical distortions. Using fourth generation IOL formulas, the system can automatically calculate IOL power. Because the total corneal refractive power (TCRP) map shows the influence of the posterior corneal surface with regard to total corneal astigmatism axis, magnitude and regularity, the IOL calculation software can account for posterior corneal astigmatism. The software also accounts for prior refractive surgery and pre-existing conditions, ensuring a reliable IOL power calculation for any IOL type in both virgin and post-refractive eyes.

The upshot? The Pentacam® AXL enables full screening before corneal refractive and cataract procedures. Laser vision correction procedures can be planned effectively; patients can be screened for existing diseases such as Fuchs endothelial dystrophy or angle-closure glaucoma; prior refractive surgeries can be detected; and crystal lens densitometry can be used to plan femtosecond laser-assisted cataract surgery (FLACS). Now, accurate IOL calculation can also be achieved – as well as customized IOL selection regarding multifocal, toric and aspheric IOLs, all from one device.





Pentacam® AXL in Action

A case study by Ina Conrad-Hengerer, MD,
University of Heidelberg, Germany.

A 63-year-old woman presented with subjective loss of visual acuity and increased glare. Corrected distance visual acuity (CDVA) was reduced in both eyes; 20/63 (-0.5 D -1.0 D × 98°) in the right eye and 20/40 (-1.0 D -0.75 D × 75°) in the left eye. Examination of the anterior segments revealed senile cataract without corneal pathology. Before medical mydriasis or further examinations, Scheimpflug imaging and anterior segment analysis by Pentacam® AXL was performed. The postoperative target refraction was emmetropia for distance, and funduscopy showed no macular changes.

The TCRP map showed increased corneal astigmatism of the axial topography from 0.9–1.6 D (right eye) and from 1.4–1.8 D for the left eye, respectively (Figures 1 and 2). Usually, toric IOL implantations are considered based on spectacle correction and anterior corneal keratometry values – but that approach would not have identified this result. Total spherical corneal aberrations (6 mm zone) were 0.353 μm (right eye) and 0.305 μm (left eye), revealing that an asphericity-correcting IOL could be a good option. Total corneal irregular astigmatism (4 mm zone) was 0.154 μm (right eye) and 0.145 μm (left eye); as 0.3 μm is the recommended limit to avoid photic phenomena, multifocal IOLs could be offered to this patient.

The IOL calculations are presented in Figure 3. Femtosecond laser-assisted cataract surgery followed by implantation of monofocal aspheric toric IOLs was performed (right eye, +18.0 D 1.5 D/6°; left eye, +18.0 D 2.25 D/6°). One day after surgery, UDVA was 20/20 in both eyes, increasing to a UCVA of 20/16 one month after surgery. Objective refraction measured by Nidek AR310A was +0.25 D 0.25 D/110° (right eye) and plano -0.25/60° (left eye).

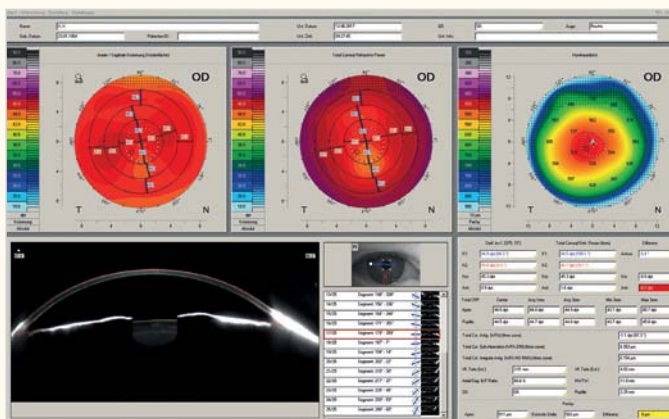


Figure 1. TCRP map for the right eye.

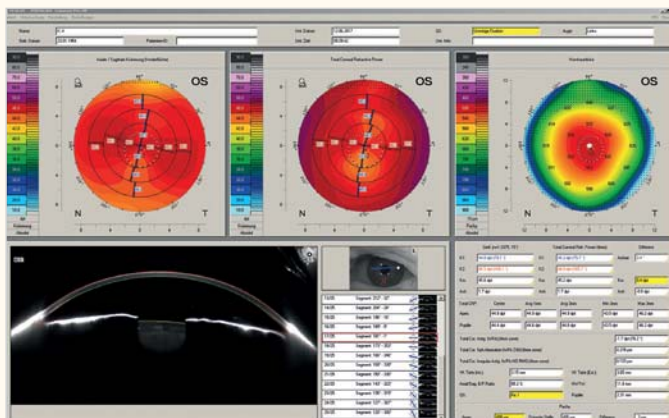


Figure 2. TCRP map for the left eye.

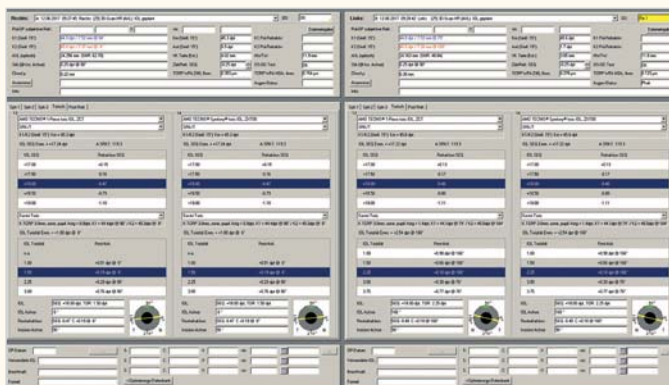

Figure 3. IOL calculations.

SIMPLICITY ITSELF: THE IC-8[®] SMALL APERTURE IOL

This premium solution works for a wide range of patients – and is as easy to implant as a monofocal IOL.

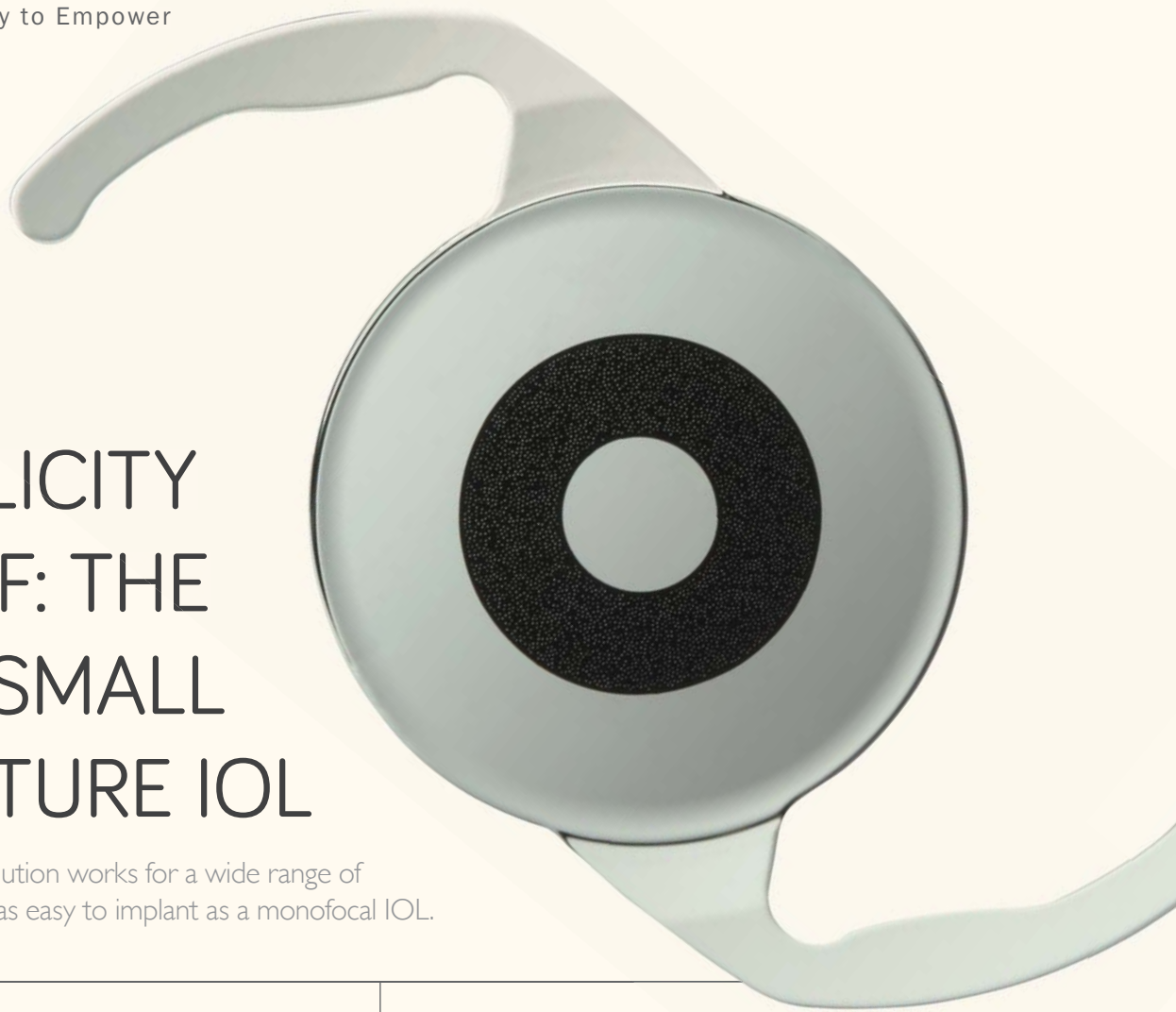Premium IOLs, implanted correctly, can give the right patient a great visual outcome. But there are also risks attached. If a target refraction is missed, or a toric IOL is misaligned or rotates after implantation, you'll be dealing with an unhappy patient – and everything else that follows. It's no wonder that in many cases, the surgeon opts to exercise caution and choose to offer a monofocal IOL instead.

But what if there were an IOL that could negate those risks? Acufocus' IC-8 IOL is a high-quality, single-piece, hydrophobic acrylic aspheric monofocal IOL with an opaque small aperture mask (or pinhole) embedded in the IOL optic. When implanted monocularly (and with a monofocal IOL in the fellow eye), the IOL's small aperture design eliminates peripheral defocused light, allowing only central focused light to reach the retina. This novel application of the long-established pinhole principle of vision correction results in high-quality range of vision from far through near without blurry zones.

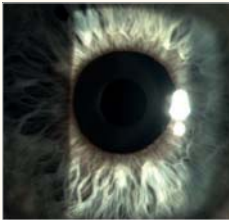Importantly, this approach also provides surgeons with

a soft refractive landing zone: they can be off by as much as 1.00 D from their intended refractive target and their patients will maintain good range of vision (1). The lens' small aperture optics also provide relief from up to 1.50 D of corneal astigmatism (both pre-existing or surgically induced) without needing to align the lens to a specific axis or fearing lens rotation – the lens could rotate 180° and maintain its effectiveness! What this means is surgeons now have a lens that can simplify the astigmatism correction process for 83 percent of all cataract patients (2), as no marking or alignment is needed. Similarly, if astigmatism is induced, the small aperture optics mitigate its effect.

These unique qualities make the IC-8 lens the simple, ideal solution for routine cataract patients as well as patients with regular and irregular corneal astigmatism. The IC-8 IOL can therefore be used to treat patients with keratoconus, corneal scars, and even post-refractive surgery and post-radial keratotomy eyes. The IC-8 IOL delivers on the promise of a premium solution for a broad spectrum of normal and therapeutic patients with the ease of use of a monofocal IOL.



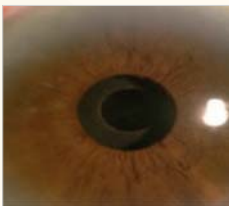IC-8® IOL in Action



Normal Eye
Photo by Mr Sathish Srinivasan

Normal Eyes

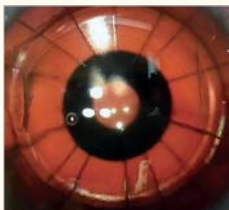
“Compared with diffractive IOL technologies, patients find it much easier to adapt to vision with the IC-8 IOL. It performs like a monofocal with respect to visual symptoms and a multifocal with respect to improving visual acuity.” – Sathish Srinivasan, MD



Corneal Astigmatism
Photo by Dr Robert Edward Ang

Corneal Astigmatism

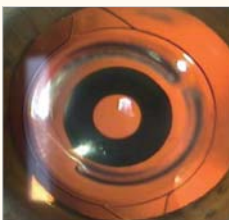
“Although the IC-8 lens is not a toric lens it can effectively compensate for up to 1.50 D of corneal astigmatism without the need for lens alignment or concern for post-op lens rotation. In my experience is, it more tolerant to the effects of cylinder than a monofocal or trifocal IOL.” – Robert Edward Ang, MD



Post-refractive procedure
Photo by Dr David Kent

Post-Refractive Eyes

“For my post-LASIK patients who have previously enjoyed spectacle freedom for their daily activities, the IC-8 IOL maintains high quality distance vision without loss of intermediate and near vision. It is highly forgiving of a missed target refraction – which I find to be extremely beneficial in post-refractive surgery patients as lens power selection can be especially challenging.” – Tess Huynh, MBBS, FRANZCO



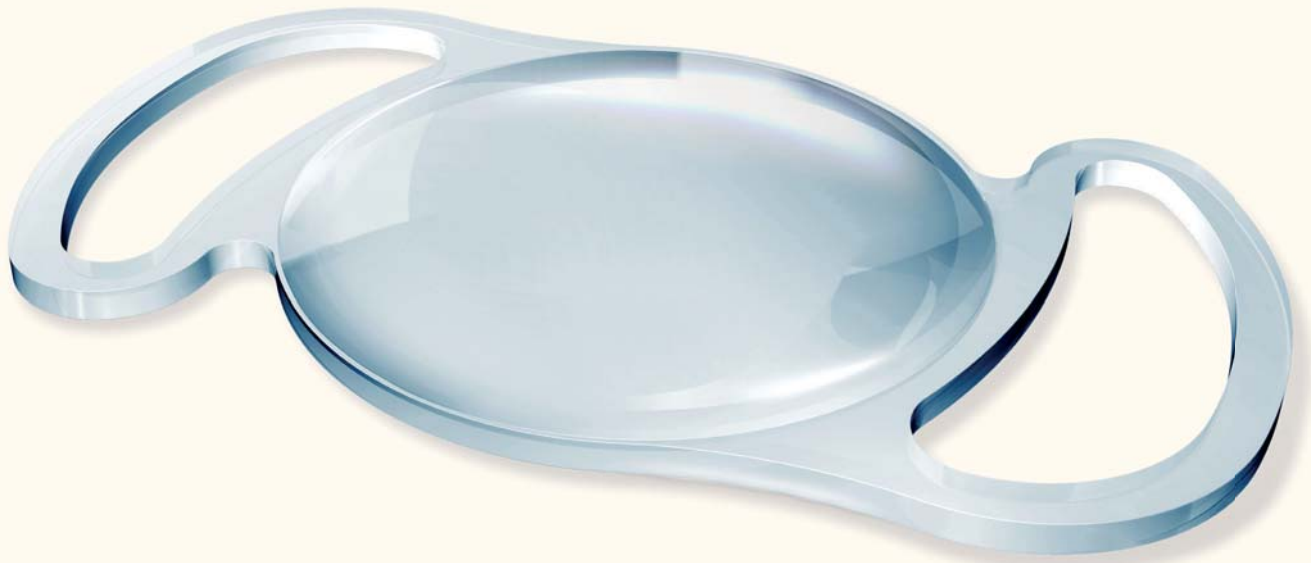Keratoconus
Photo by Dr Omid Kermani

Irregular Corneas

“The IC-8 IOL is my preferred choice for patients with irregular corneas such as keratoconus or PMD, higher order aberrations in the cornea, lack of stereopsis or abnormal endothelium (<2,200 cells/μm).” – Amir Parasta, MD

References

1. HB Dick et al., “Prospective multicenter trial of a small-aperture intraocular lens in cataract surgery”, *J Cataract Refract Surg*. 43, 956–968 (2017). PMID: 28823444.
2. W Hill, *Keratometry database results of 6,000 cataract patients*. Available at: <https://doctor-hill.com/physicians/docs/Astigmatism.pdf>



THREE WORDS: SIMPLICITY, QUALITY, PERFORMANCE

SAV-IOL's Lucidis IOL combines the fantastic far vision and few photopic phenomena of a monofocal lens, with the added bonus of a high-quality extended depth-of-focus.

In some respects, monofocal IOLs are hard to beat. Other than the obvious – a single focal plane – the drawbacks are few, and compared with the current crop of diffractive multifocal IOLs, they provide unparalleled distance vision with a very low rate of visual disturbances. Neuroadaptation is rapid, and patients are almost immediately comfortable with their postoperative vision.

The Swiss IOL company, SAV-IOL, set out to make a lens with all of the advantages of a monofocal IOL, but with the benefit of continuous vision. To that end, they adapted their

“Instant Focus” extended depth-of-focus (EDOF) technology to a classic monofocal design to make Lucidis – a hydrophilic single-piece foldable IOL. The optic comprises a 6 mm-diameter refractive part providing distance and a 1 mm-diameter aspheric element in the center of the optic to extend the depth of focus from near towards distant vision (Figure 1a,b). The aspheric element uses a pseudo non-diffracting beam (PNDB); the benefit of this approach being the maintenance of a constant resolution and light intensity on the retina (Figure 1c).

Since its launch at the ESCRS in October 2017 in Lisbon, Lucidis is gaining worldwide interest among the ophthalmic surgeons' community.

Here's what the surgeons who use it think:

Dr Johan Blanckaert, Belgium

"We can see that a growing number of patients are willing to have multifocal IOLs – but many are reluctant to choose this type of lens because of the optical side effects (halos and glares) that traditional diffractive multifocal lenses are known for. These patients need an IOL that's capable of multifocality, with the least possible visual disturbances. Lucidis with its 'Instant Focus' EDOF technology perfectly fills this gap."

"I was expecting a moderate reading capability and I warned my patients that they might need a low diopter reading glass for small print. However, to our surprise, the reading capability was very good, even for small print."

Dr Marco Alberti, Italy

"Compared to monofocal lenses, premium IOLs come with an added cost. For patients, the cost is financial, for surgeons, the cost is added time. Lucidis can be an appropriate solution for surgeons put off by the extra time needed to explain those technologies. You can present the Lucidis lens as a standard monofocal IOL with the possibility to have a better visual acuity for the near and intermediate vision."

"As squared shape platforms in a round bag are more prone to decentration in cases of anterior capsule retraction, I feel more confident with the strength of the platform of Lucidis, because of the profile of its closed-loop haptics."

"The Lucidis lens has a very stable design – its stability in the capsular bag is great, and I get perfect centration. I was skeptical in the beginning regarding the smaller 10.8 mm diameter model,

but the haptic design is strong, and the 10.8 mm version is a very good compromise. Furthermore, the 12.4 mm version perfectly fills up the largest capsular bags!"

Dr Frédéric Sutto, Belgium

"Lucidis is positioned between monofocal and multifocal IOLs, and I think there's a growing population of patients requiring cataract surgery who will benefit from such a lens. To me, one of the main benefits of Lucidis is the regularity of results: typically 9/10, P2."

Prof Dr Hanefi Çakır, Turkey

"I realized that implantation and manipulation of Lucidis are extremely easy – right from the very first time I used it. When patients came for post-op examination, I always saw smiling faces, as they were able to see very well for both near and far, without any halo or glare."

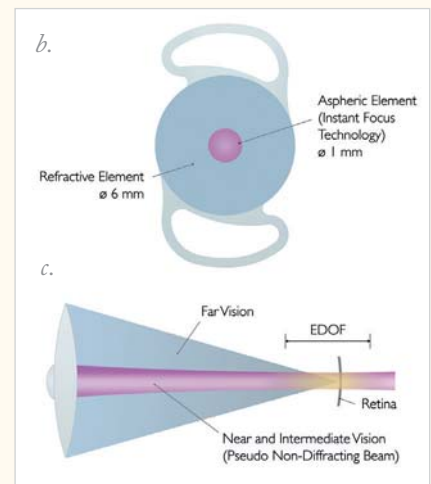
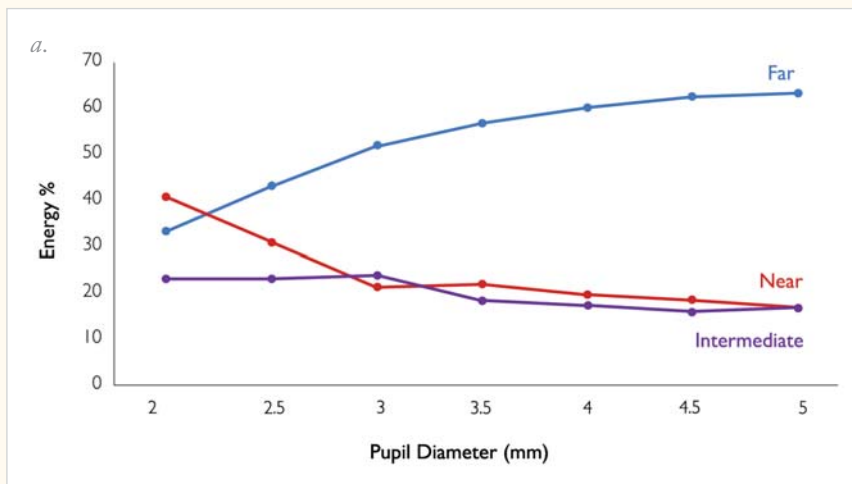


Figure 1. a. The light distribution of the Lucidis IOL – available in two sizes (10.8 mm and 12.4 mm) with a power range of +5.0 D to 30.0 D, in steps of 0.5 D; b. The refractive and aspheric optical elements with the innovative closed-loop haptic design to give an optimal centration; c. The pseudo non-diffracting beam approach providing a constant resolution and light intensity on the retina.

THE NEXT GENERATION

Clareon® AutonoMe™: A new monofocal IOL platform and delivery system.



Recently, Alcon achieved 100 million implantations of their AcrySof® platform, one of the world's most frequently implanted IOLs (1). But there is always room for improvement, and as cataract surgery constantly advances and evolves, two key areas of innovative focus are the IOL design and biomaterial, and preloaded delivery devices.

What improvements would cataract surgeons like to see in IOLs? High biocompatibility, greater optical clarity, as well as a simplified and easy to use IOL injector that delivers reproducible results. Alcon – a company with a proven track record of developing and manufacturing best-in-class IOLs – has a new offering based on this feedback: Clareon® AutonoMe™, the next generation of preloaded IOLs.

Clareon® (Box 1) is an advanced monofocal IOL with all the same features of the trusted AcrySof® platform. However, a new hydrophobic acrylic biomaterial and an enhanced manufacturing process have enabled further innovation, such as the precision edge design, which reduces edge glare (2, 3). Clareon® allows surgeons to provide unsurpassed clarity for their patients with no haze, subsurface nanoglistenings or glistenings, all with a low incidence of posterior capsule opacification (4–8). Accompanying Clareon® is AutonoMe™ (Box 2) – the next evolution of IOL delivery from Alcon. AutonoMe™ is the first and only automated, disposable, pre-loaded IOL delivery system in the market, and uses an innovative CO₂-powered delivery mechanism that allows surgeons easy – and predictable – control over IOL delivery and speed. Not only that, it is simple to use.

Box 1. Key Features of Clareon® AutonoMe™

Key BioOptics features

- Precision edge design to minimize potential for edge glare and positive dysphotopsias (2,3)
- Fully usable 6 mm biconvex aspheric optic (9)
- UV and blue light filtering (4)

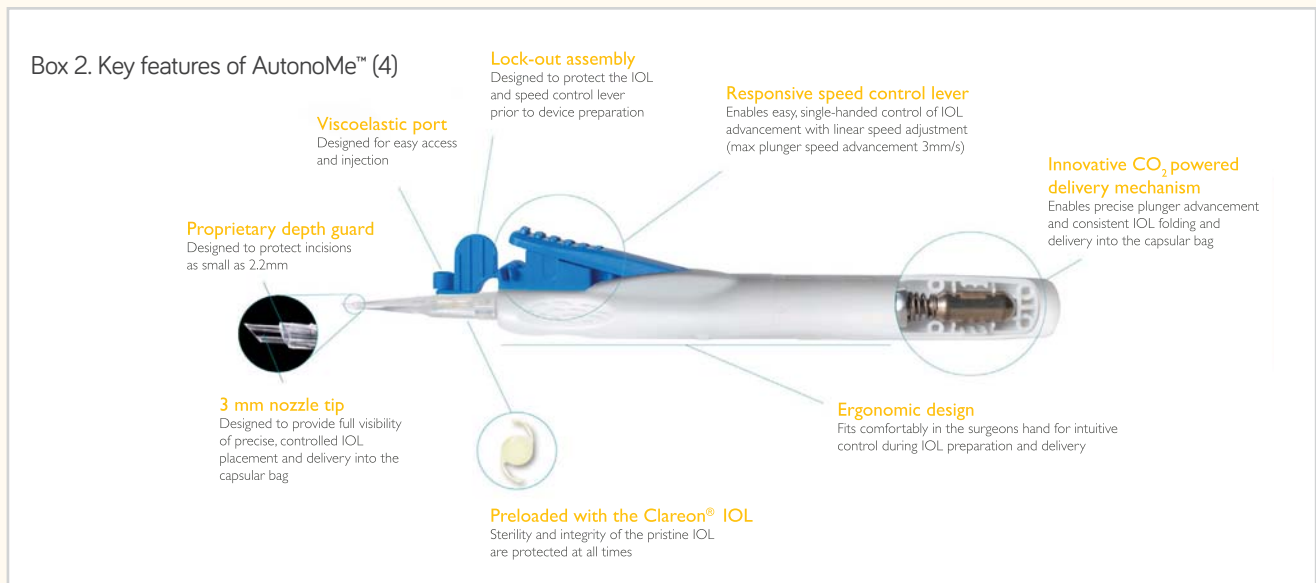
Key BioMechanics features

- STABLEFORCE® Haptics remain planar during unfolding
- Rapid and controlled unfolding (10)
- Precision edge design that guards against PCO and minimizes Nd:YAG procedures, in addition to reducing edge glare (3,4)

New BioMaterial features

- Advanced manufacturing process
- Among the lowest level of surface haze, subsurface nanoglistenings (SSNGs), and glistenings of competitive monofocal IOLs (5–8)*
- Automated, disposable, preloaded IOL delivery system
- Innovative CO₂-powered lens advancement with a responsive speed control lever (4)
- Linear control of IOL delivery speed up to 3.0 mm/s (4)
- Easy, intuitive and control

**Based on aggregate results from in vitro evaluations of haze, SSNGs and glistenings compared to TECNIS OptiBlue ZCB00V (Johnson & Johnson), TECNIS ZCB00 (Johnson & Johnson), Eternity Natural Uni W-60 (Santen), Vivinex XY-1 (HOYA) and enVista MX60 (Bausch & Lomb).*



Rudy Nuijts, Professor of Ophthalmology and Director of the Cornea Clinic, Maastricht University Medical Center, Maastricht, The Netherlands

“We have been implanting Clareon® lenses in patients since July 2017, and we’ve found that the Clareon® IOL handles less ‘stiffly’ during the cartridge manipulation and loading than the AcrySof® lens, and that there is a quicker unfolding of the optic and haptics in the eye. We also found less ‘stickiness’ of the haptics on the optic, as you can sometimes see with the AcrySof®. We identified a four second unfolding difference between the Clareon® and AcrySof® lenses (30 ± 13.5 s vs, 34 ± 15.7 s, respectively).”

Stephen Lane, Clinical Professor of Ophthalmology at the University of Minnesota and Medical Director of Associated Eye Care in Stillwater, Minnesota, USA; and Chief Medical Officer of Alcon

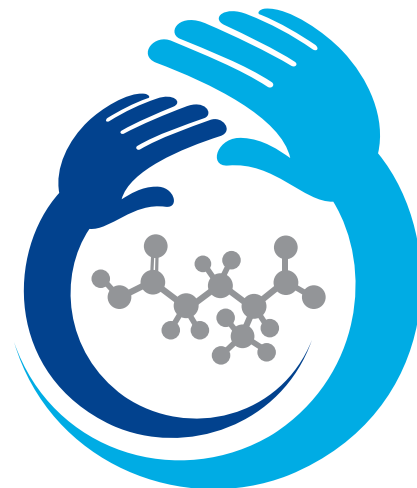“AutonoMe™ allows single-handed delivery, and utilizes a very innovative, automated delivery system with a CO₂-powered cartridge and responsive speed control lever that allows the surgeon to stop or start – and vary the speed of – the delivery. All surgeons like control throughout all phases of the surgery, and AutonoMe™ enables precise delivery into the capsular bag, whilst protecting incisions as small as 2.2 mm

and providing full IOL visibility during the delivery. I believe it will change the way which we deliver IOLs into the eye.”

References

1. Alcon. “Alcon flagship AcrySof® intraocular lens reaches 100 million implants and counting”. Available at: <http://bit.ly/2hqAnYT>. Accessed October 31, 2017.
2. Improved Milled Edge Quality of Clareon® IOLs. Alcon internal technical report: TDOC-0053598, effective March 13, 2017.
3. Schematic Model Eye and In Vitro Evaluation of Positive Dysphotopsia or Glare Types Photoc Phenomena. Alcon internal technical report: TDOC-0053578, effective August 8, 2017.
4. Clareon® AutonoMe™ Directions for Use.
5. Microvacuole Evaluation of Clareon® and Other Marketed IOLs. Alcon internal report: TDOC-0053516, effective February 28, 2017.
6. Clareon® and Marketed IOL Slit Lamp Surface Haze. Alcon internal technical report: TDOC-0053487, effective February 28, 2017.
7. Clareon® and Marketed IOL Nidek Surface Scatter and Bulk Haze. Alcon internal technical report: TDOC-0053488, effective February 28, 2017.
8. Elimination of Clareon® IOL Surface Haze Summary. Alcon internal technical report TDOC-0053072, effective 05-Jan-2017.
9. Imaging of the Usable Optic Diameter of Clareon® SY60WF, TECNIS ZCB00, and enVista MX60 IOLs. Alcon internal technical report: TDOC-0053803, effective July 12, 2017.
10. L Werner and N Mamalis. Evaluation of IOL positioning stability and ocular biocompatibility of a new IOL material in the rabbit cataract surgery model (University of Utah) – Interim Report.

CELEBRATING THREE YEARS OF HUMANITY IN SCIENCE



HUMANITY IN
SCIENCE AWARD

the Analytical Scientist

*The Humanity
in Science Award
recognizes and rewards
scientific breakthroughs
that aim to have a real
impact on humankind's
health and wellbeing.*



2015

Peter Seeberger & Andreas Seidel-Morgenstern, Directors at two collaborating Max Planck institutes in Germany, developed an innovative process to manufacture the most effective drugs to treat malaria from plant waste material, air and light.



2016

Waseem Asghar, Assistant Professor at Florida Atlantic University, developed flexible sensors for the rapid and cost-effective diagnosis of HIV – and other infectious diseases – in point-of-care settings.



2017

Richard Jahnke, Global Pharma Health Fund (GPHF), developed and continuously improved GPHF Minilab – a “lab in a suitcase,” enabling resource poor countries to rapidly identify substandard and falsified medicines.

Nominations will open soon for the 2018/2019 Humanity in Science Award

www.humanityinscience.com



In Practice

*Surgical Procedures
Diagnosis
New Drugs*



40–43

Minimally Invasive Corneal
Neurotization

Ilya Leyngold on his less-invasive corneal neurotization procedure for treating neurotrophic keratopathy, and how he wants to change perceptions on the surgery so that more patients can be treated before vision is lost.

Minimally Invasive Corneal Neurotization

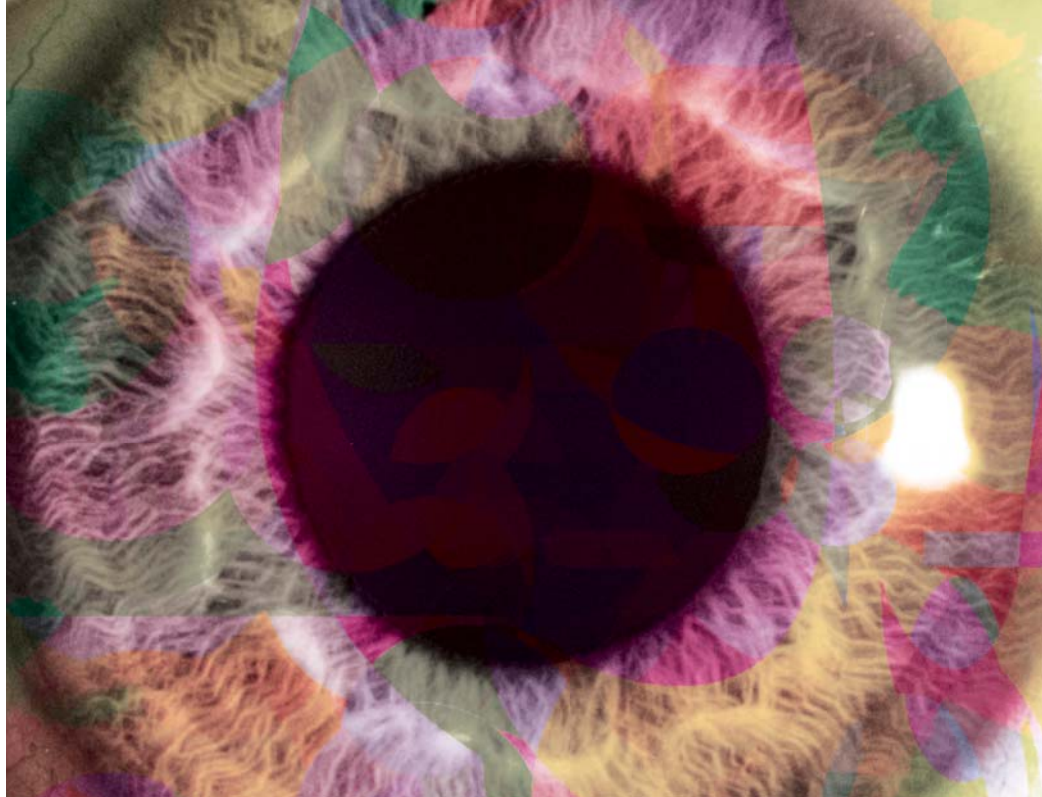
A new paradigm in managing neurotrophic keratopathy

By Ilya Leyngold

Neurotrophic keratopathy can be a devastating disease (See Box 1. Neurotrophic keratopathy pathology). Lost corneal sensation may lead to corneal scarring, ulceration and thinning, which can lead to corneal perforation and vision loss. It's a debilitating condition for patients, and doctors have limited treatment options. Multiple 'temporizing' treatments try to decrease the chance of infection, ulceration and scarring, such as ocular lubricants, topical antibiotics, autologous serum drops, contact lenses, amniotic membrane grafts, and tarsorrhaphy. But none restore corneal sensation or the ability of the eye to respond

At a Glance

- *Neurotrophic keratopathy – the loss of corneal sensation – has a poor prognosis with limited available treatment options*
- *Current techniques for corneal neurotization can restore corneal sensation, but may be associated with significant morbidity*
- *I describe two minimally invasive techniques for corneal neurotization: using a cadaveric nerve graft and an endoscopic approach*
- *More ophthalmologists learning – and performing – these minimally invasive procedures may help more patients before devastating and irreversible damage occurs.*



appropriately to stimuli and maintain a healthy ocular surface. Furthermore, patients with neurotrophic keratopathy do poorly with corneal transplantation to replace the damaged tissue, because the same condition will recur in the corneal graft resulting in failure.

The traditional standard of care for severe cases is to suture the eyelids together to protect the surface of the eye – a disfiguring procedure, which at best limits the patient's field of vision and may lead to functional blindness if the entire palpebral aperture is closed. Some patients end up with permanently closed eyelids because corneal decompensation recurs upon re-opening. A novel surgical treatment has been described – corneal neurotization (1) – but the original techniques involve a significant undertaking. They involve either a coronal (ear-to-ear) incision with peeling the scalp and forehead tissues down to the level of the eye socket, or use of a nerve autograft harvested from a patient's leg. Why? To route supraorbital and supratrochlear nerves from the contralateral side, tunnel them across the bridge of the nose, and to the corneoscleral limbus of the affected 'anesthetic' eye (1). These techniques for corneal neurotization have demonstrated successful outcomes – patients developed

improved corneal sensibility, corneal health, and vision in some cases. But the means of getting there involve quite an invasive surgery with potential for significant donor site morbidity.

The sentinel patient with neurotrophic keratopathy who sparked my interest in this procedure presented to my clinic with severe corneal decompensation. In the four months following a retinal detachment repair surgery, she developed a non-healing corneal epithelial defect, thinning, and progressive loss of vision in her left eye despite maximal medical therapy. With hand motion vision, she was miserable and desperate. I wasn't satisfied that there was nothing we could do besides suturing her eyelids together, and after extensive research to see if any other options were in existence, I stumbled across the paper by Terzis et al (1), which described the original corneal neurotization technique – four years after it was published.

My cornea colleague and I decided to perform the procedure using a slightly modified technique – see Figure 1. The surgery took five hours and involved a large incision and extensive surgical manipulations. Fortunately, the patient ended up doing very well; her corneal sensation was restored with complete healing of her epithelial defect and

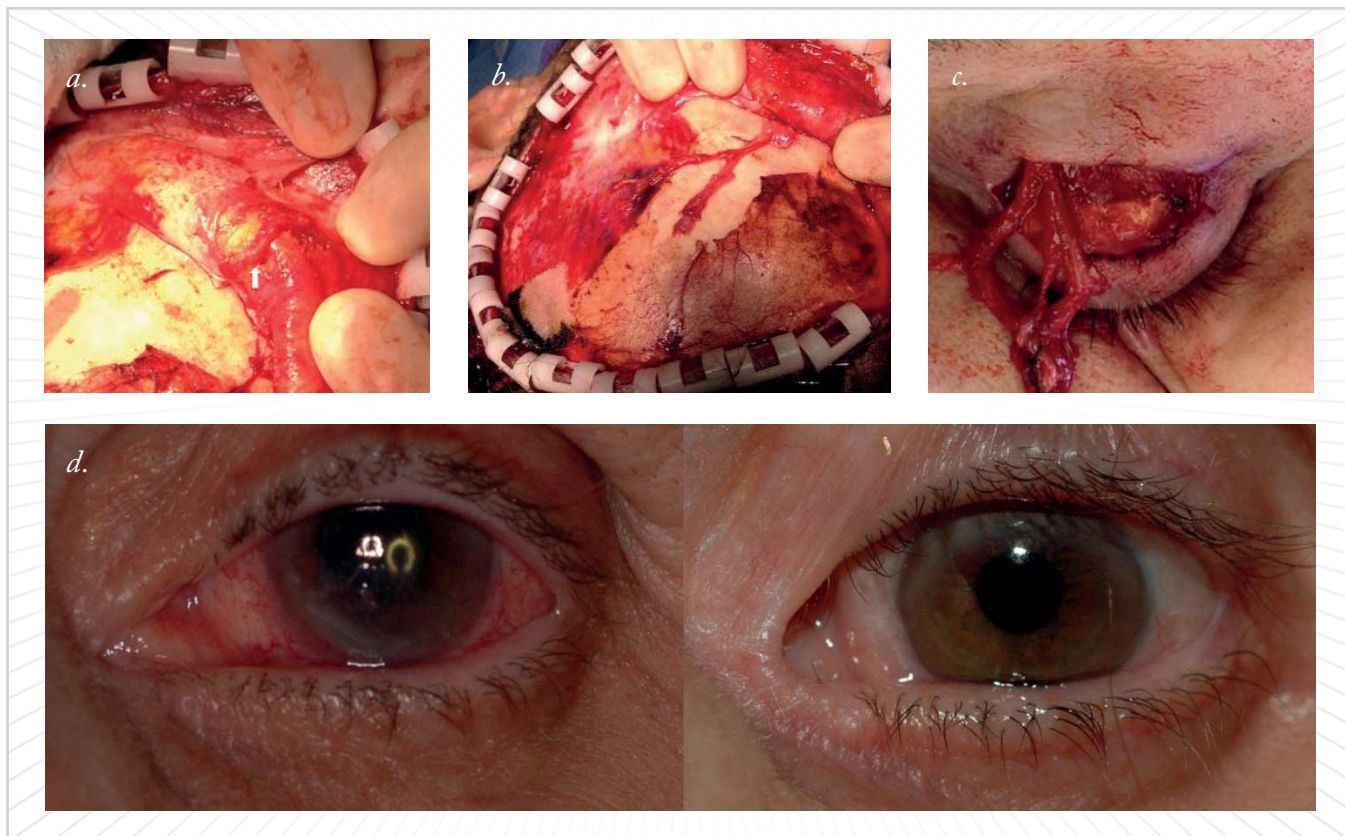


Figure 1. Direct corneal neurotization procedure in a 61-year old female with neurotrophic keratopathy. An ipsilateral hemi-coronal incision was performed and the supraorbital nerve was dissected (a, white arrow). The entire dissected nerve can be seen in (b). The supraorbital nerve branches were tunneled through an upper eyelid crease incision (c). Before and after (two years) pictures can be seen in (d).

improved visual acuity from hand motions to 20/30. I was able to open her eyelids, which were initially sutured together to protect her cornea (2). We were only the second center in the US to perform corneal neurotization; more groups have now reported performing similar procedures (3–5).

It was a revolutionary concept for me because it worked so well, but I thought there had to be a better – and less-invasive – way. One group reported using a sural nerve autograft to restore corneal sensation through coaptation with the supraorbital or supratrochlear nerves (4, 5). Although less invasive than the procedure we and Terzis et al had performed, I still wanted to find an option that would avoid another donor site morbidity. My goal became creating a less invasive procedure that would still provide good results.

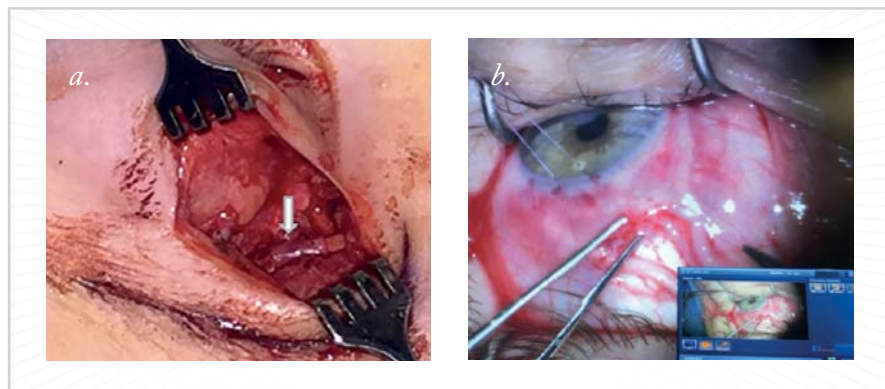


Figure 2. Use of cadaveric nerve graft for corneal neurotization. (a) Anastomosis (arrow) between the supraorbital nerve (left) and cadaveric nerve graft (right) through a an upper eyelid crease incision. (b) Nerve graft tunneled into the subconjunctival space and inset around the corneoscleral limbus.

Tackling invasiveness

Surgeons use cadaveric nerve grafts to repair nerve injuries in other areas of the body, so I thought why not use them to restore corneal sensation? It would circumvent the need for more invasive

surgery to harvest grafts from the patient. Using de-cellularized and processed cadaver nerves (AxoGen, Alachua, Florida), I've performed the corneal neurotization procedure in five patients (Figure 2). Within three months of surgery,

Box 1. Neurotrophic keratopathy pathology

- Neurotrophic keratopathy is a degenerative corneal disease characterized by decreased corneal sensibility and corneal healing.
- It has a prevalence of 1/2,000 – but it is likely under-diagnosed.
- It is a potentially blinding disease that can involve persistent epithelial defects, corneal scarring, neovascularization, corneal ulceration, perforation, or even loss of an eye.
- Clinical findings of neurotrophic keratopathy result from multiple mechanisms, including decreased sensory neuromediators, limbal stem cell compromise, epithelial compromise, decreased blink reflex and decreased reflex tearing.
- Etiologies of the disease include: infection (HSV, and so on), neoplastic and neurosurgical procedures, trauma (such as skull base fracture), ocular surgery, systemic disease (such as diabetes mellitus or multiple sclerosis), topical medication, chemical burns, congenital conditions, and advanced age.
- The most common cause is herpetic corneal infections; the second most common is intracranial pathology.

Box 2. An endoscopic approach (7)

- Following induction of general anesthesia and injection of local tumescent anesthesia, make an upper eyelid crease incision in the donor upper eyelid. Dissect around 1 cm of the supraorbital nerve segment cephalad from the supraorbital foramen (or notch).
- Make two 1 cm vertical incisions just behind the hairline (5 mm posterior to the trichion). One incision should be placed in the midline and the other at a tangent to the contralateral medial limbus.
- Using a blunt endoscopic elevator, develop a subgaleal plane, stopping just cephalad to the previously isolated segment of supraorbital nerve.
- Using endoscopic guidance, dissect the rest of the supraorbital nerve cephalad through the scalp incisions, isolating terminal branches of the nerve.
- Tunnel the nerve branches through the upper eyelid incision.
- Make an upper lid crease incision on the side of the affected eye.
- Tunnel a curved hemostat from the eyelid incision on the affected side, in subgaleal plane, under the nasal bridge, and to the contralateral eyelid incision.
- Transfer the nerve branches from there to the upper eyelid crease incision on the affected side. After making a blepharotomy incision in the superior medial conjunctival fornix tunnel the nerve branches into the fornix of the affected eye.
- Place the nerve branches in the sub-conjunctival space through a conjunctival incision 8 mm above the 12 o'clock position, and secure the epineurium of the nerve to the sclera followed by conjunctival closure.

most patients demonstrated restoration of corneal sensation and improved corneal healing. Some of the patients actually noted that they could feel eye drops in the operative eye for the first time since developing neurotrophic keratopathy. Using a Cochet-Bonnet esthesiometer we were able to track their progress objectively, and we're thrilled with the outcomes – our results have been submitted for publication. We're also starting a prospective study to examine and further understand the outcomes following procedure.

We've also developed a second minimally-invasive technique – harvesting nerves using an endoscopic approach. This procedure involves making two small incisions behind the hairline – rather than a coronal incision – as well as a small eyelid crease incision (See Box 2. An endoscopic approach). First, we demonstrated the feasibility of using an endoscope for supraorbital nerve transfer to the corneoscleral limbus in two cadaver heads (6). We've also performed our endoscopic procedure in an 83-year old female patient with neurotrophic keratopathy from herpetic disease (7) (Figure 3). The affected eye had a visual acuity of hand motion at one foot, and a persistent corneal epithelial defect with dense corneal stromal scarring. Five weeks after the surgery, her epithelial defect had healed completely; and within three months of surgery we were able to demonstrate improvement in corneal sensation.

The merits of minimally invasive surgery Both of our minimally invasive approaches have multiple advantages over the originally described corneal neurotization techniques. They're less invasive – you're not 'scalping' the patient or performing additional surgery elsewhere on the body to harvest a segment of nerve.

Another benefit of a minimally invasive procedure is that it makes corneal neurotization more accessible to ophthalmic surgeons who may not be as comfortable with previously described

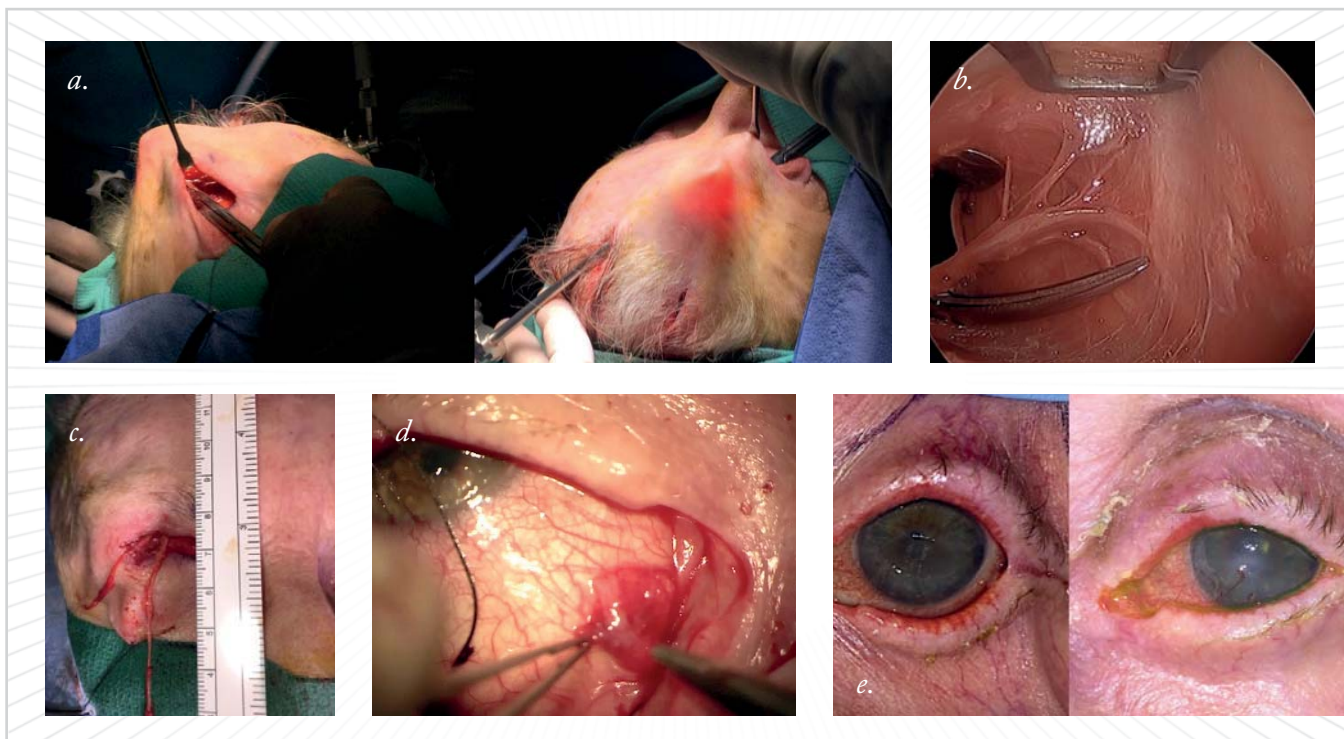


Figure 3. Endoscopic corneal neurotization. (a) Approach to the supraorbital nerve from a small scalp and eyelid crease incisions. (b) Dissection of the supraorbital nerve through an upper eyelid crease incision under direct endoscopic visualization. (c) Tunneled supraorbital nerve branches through an upper eyelid incision. (d) Inset of the supraorbital nerve into the subconjunctival space. (e) Resolution of persistent corneal epithelial defect five weeks after endoscopic neurotization procedure.

approaches. If there is a procedure that more ophthalmologists can perform, then more patients will be likely to receive treatment. We'll also be able to intervene earlier as patients will be more willing to undergo the procedure, rather than waiting until their disease becomes visually threatening. Currently, ophthalmologists who are aware of the procedure consider corneal neurotization a very morbid surgery. I am trying to change this perception – the minimally invasive procedures can be performed safely, with low complication rates, and are definitely within the scope of many ophthalmologists with proper training. The endoscopic approach is more technically challenging than grafting cadaveric nerves as it requires familiarity with using the endoscope, requires specialized equipment, and meticulous dissections in a small tunnel. Right now, corneal neurotization using cadaver nerve grafts is probably more

reproducible, and I hope that in the future it might be picked up by more surgeons. I want to see corneal neurotization become a new paradigm in the management of neurotrophic keratopathy, and I want to see more patients cured from this disease.

Ilya Leyngold is Assistant Professor of Ophthalmology at Duke University School of Medicine, Durham, North Carolina, USA. He specializes in cosmetic and reconstructive surgery of the eyelids, orbit, lacrimal system, and face.

References

1. JK Terzis et al., "Corneal neurotization: a novel solution to neurotrophic keratopathy", *Plast Reconstr Surg*, 123, 112–120 (2009). PMID: 19116544.
2. A Jacinto et al., "Ipsilateral supraorbital nerve transfer in a case of recalcitrant neurotrophic keratopathy with an intact ipsilateral frontal nerve: A novel surgical technique", *American Journal of Ophthalmology Case Reports*, 4, 14–17 (2016).
3. F Allevi et al., "Eyelid reanimation, neurotisation, and transplantation of the cornea in a patient with facial palsy", *BMJ Case Rep* (2014). PMID: 25139921.
4. U Elbaz et al., "Restoration of corneal sensation with regional nerve transfers and nerve grafts: a new approach to a difficult problem", *JAMA Ophthalmol*, 132, 1289–1295 (2014). PMID: 25010775.
5. RD Bains et al., "Corneal neurotization from the supratrochlear nerve with sural nerve grafts: a minimally invasive approach", *Plast Reconstr Surg*, 135:397e–400e (2015). PMID: 25626824.
6. M Tabor et al., "Endoscopic corneal neurotization: cadaver feasibility study", *Ophthal Plast Reconstr Surg*, [Epub ahead of print], (2017). PMID: 28472009.
7. I Leyngold et al., "Endoscopic corneal neurotization: technique and initial experience", *Ophthal Plast Reconstr Surg*, 34, 82–85 (2018). PMID: 29194285.

the Ophthalmologist™

Register now at

www.theophthalmologist.com/register

**It is quick and easy
and completely FREE**

As a fully registered user
you will benefit from:

- Unlimited access to ALL articles
- Full access to digital and archived copies of every issue of The Ophthalmologist
- Print (and PDF) copies delivered direct to you
- Email news alerts
- Networking opportunities

There are many good reasons to register to
The Ophthalmologist. Here are just a few:

- We bring intelligent journalism and a sense of community to all ophthalmologists
- We cover some of the greatest stories by working with the brightest and best in the field, sharing motivations and opinions in the process
- We educate, inform, influence and entertain doctors, providing genuine insight thanks to our talented team that “gets it”

Bringing intelligent
journalism and a sense
of community to all
ophthalmologists

Register now at www.theophthalmologist.com/register





Profession

Your career
Your business
Your life



46–49

Addressing Needs Beyond Disease
John D. Shepherd shares how a life transition brought him to the world of low vision rehabilitation – and the role that ophthalmologists can play in best serving their patients.

Addressing Needs Beyond Disease

Ophthalmologists can do a great deal to help meet the needs of patients with low vision... And it only requires one initial question

By John D. Shepherd

Three years out of residency as a comprehensive ophthalmologist, I developed severe back pain shortly followed by a knee injury. After years of seeing several different medical professionals, trying numerous different pain medications – as well as months of physical therapy and two operations – I was still in a lot of pain. And I was struggling. My work schedule had been interrupted so many times that I had to make the ultimate decision – for both my own and my practice’s sake – to stop doing surgery. It was the most difficult decision I have ever had to make. Imagine being

At a Glance

- *I am a low vision rehabilitation specialist, but I started my career as a comprehensive ophthalmologist*
- *I’d like to share the story of my transition into my current career, as I believe it can help ophthalmologists address what other care patients might need*
- *It isn’t all about the eye and the disease; many patients with irreversible vision loss also suffer a psychological impact*
- *We must best address the current needs of patients, as well as what the future may hold.*



an early career ophthalmologist again, and consider how you would feel!

What I didn’t realize, was that it would fuel an identity crisis. I found myself asking, “What is an eye surgeon that doesn’t do surgery?” Combined with the activities I could no longer do – or enjoy – at home, I felt like I was living a less-than-normal existence. I felt a tremendous sense of abandonment, and ended up being treated for two years as an outpatient for depression. It was a very dark chapter in my life. But why am I telling you this? Because I believe my story can help fellow ophthalmologists understand what their patients with irreversible vision loss might be going through.

An epiphany

When a cure exists, patients don’t tend to be labored by thoughts of what they can no longer do; once the problem is solved, they can return to their normal routine. But when pain or symptoms persist, and there is no cure, the activities that are no longer possible become increasingly noticeable. Going about daily life becomes a continual struggle. Such patients need to learn to live with their condition. Are there ways to live with chronic pain? Yes – that’s what pain management clinics are all about. There are exercises that can be done and approaches that can be taken to minimize the disability; in short, there is a way to move forwards. But no

physician during my treatment journey had ever mentioned this option to me, nor addressed the issue of how I could live with my condition.

“Patients still have to live with the blurred vision that is making their day-to-day life difficult.”

Going back to my career, I became a medical ophthalmologist by default. And I had an epiphany. When taking care of patients with AMD, I recognized similarities to what I had been through. But instead of back and knee pain, their symptoms were blurred and impaired vision. After months of dealing with their visual symptoms, these patients were realizing all the things they could no longer do: reading, driving, even recognizing their children’s faces... But did I ask them if they were struggling with any of their activities? No – because I was looking at the eye and not them. Our patients might receive medical and surgical treatments, the best glasses, eye vitamins to help slow the disease progression, and so on, but none of these things are a cure. These patients still have to live with the blurred vision that is making their day-to-day life difficult. Just as the physicians who took care of me were insensitive to the realities of living with chronic pain, I started to realize that

I was being insensitive to my patients who were living with the reality of irreversible vision loss.

After my epiphany, I asked myself whether patients with irreversible vision loss get depressed. And they do; two studies have demonstrated that around 30 percent of patients with AMD have depression (1, 2), and the incidence of depression and anxiety is higher in patients with visual impairment compared with the general population (3).

But there is help available for patients with irreversible vision loss – low vision rehabilitation. Many ophthalmologists may think that low vision rehabilitation is all about magnifiers, but it is so much more than that.

Looking beyond the disease

Low vision rehabilitation is the branch of care concerned with providing the necessary optical devices, visual skills training, environmental adaptations and counseling to minimize vision-related disability when no restorative process is possible. Through assessing functional history we learn what impairments patients are experiencing in their daily activities – such as managing finances, working in the kitchen or hobbies – and look at how patients can minimize their disability so that they can resume those activities. It can be something as simple as using their vision in a different way, or using optical devices or apps for assistance. The number one reason patients come to see a low vision specialist is because of problems with reading, but because many patients have scotomas, simply making the print larger doesn’t solve the problem. Specially-trained occupational therapists can work with patients to provide scotoma-compensating strategies, so that they might navigate those areas and minimize the interference.

Assessing depression is also an important aspect of our care. Although most clinicians recognize that psychiatric

medication and counseling can be helpful for patients suffering with depression, low vision rehabilitation itself has been found to help prevent depression in patients with low vision (4). It can be difficult, however, to recognize depression in patients, which is why it is often missed. Patients often get frustrated at irreversible vision loss because they may not be able to do things, but depression is very different to frustration. A depressed patient is more likely to withdraw, and upon examination it can be difficult to identify they are depressed unless you are specifically looking for it. This is where the environment of the low rehabilitation specialist is key, as we can identify the problem, address the patient’s visual impairment and get them into the hands of others who can address the mental health aspects.

“Low vision rehabilitation has been found to help prevent depression in patients with low vision.”

But despite the benefits of low vision rehabilitation, low numbers of patients are being referred – under 15 percent. Why? Perhaps it is a combination of a lack of patient and physician awareness of the available help, as well as the increasing demands upon eyecare providers. It could also be because low vision rehabilitation is an area that needs to be grown and developed. A change is needed, and I



think that ophthalmologists have an important role to play; ultimately, that role will be born out of a discussion about how we as an eyecare community can address the issue.

The road ahead

The key point I really want to share with ophthalmologists is that if we place all our attention on managing an incurable disease then we risk overlooking the importance of managing the impairments caused by the disease. Over the next 30 years, we're facing an increased prevalence of impaired vision (5), and we must be better equipped to

address patient needs.

I presently serve as Chair of the AAO Vision Rehabilitation Committee, which among other activities raises awareness of vision rehabilitation issues at meetings. However, ophthalmologists attend meetings to learn the latest research, procedures and techniques, and their mind is not on addressing the impairment in their patients. But if David W. Parke II, the CEO of the AAO, is behind the issue, shouldn't more ophthalmologists join him?

Like most ophthalmologists, I wasn't aware of the issue when I was in

residency training. But, in my view, it shouldn't take what I went through to recognize that we need to do something about this. The Vision Rehabilitation Committee is currently assessing how our residents are taught, and whether they are being provided with resource materials on assessing impairment – this is key.

When I embarked on my career I never had any desire of being a low vision specialist – it wasn't my area of expertise. But a life transition called me to explore the area, and I realized how underserved and challenging it is. I am highly passionate and motivated because it ties

What Can I Do?

Identify those at need

- If you have a patient in your practice who has permanent vision loss (BCVA 20/40 or 20/50 or worse) you – or your technician – need to ask one question. “Does your vision loss make it difficult for you to participate in your day-to-day activities?” If at that point they answer “yes,” and the ‘floodgates’ open and they start to talk about what they are no longer able to do, you need to get them in the hands of someone who will address the impairment. These patients need to understand that while there is no present cure for their vision loss, there are ways to manage the impact caused by the impairment.

Recognize depression

- If patients answer the one question with a “yes” then ophthalmologists should refer them to a low vision specialist. Many low vision specialists

screen for depression in their patients. There are many available depression screening tests and some are as simple as two questions. When a patient shows elevated results for depressive symptoms, it prompts a supportive conversation to let them know how common depression is with low vision and emphasizing what can be done to help them.

Avoid the dreaded ‘B’ word

- I encourage all ophthalmologists to tell their patients with AMD that they will never lose all of their eyesight. People need to know there is always going to be vision they can use – throwing out the ‘B’ word doesn’t offer hope or encouragement because it doesn’t suggest how to move forwards. It is more valuable to tell them that they will retain some vision rather than saying they’ll go blind.
- It is always best to stress what can be done, rather than what cannot:
- “You will never go blind”

- “There is a lot that can be done to improve your quality of life”
- “You are much more than your disease”
- Share success stories of individuals living full lives despite vision loss

Refer to external sources

- There are plenty of external sources available to guide you with helping – or finding help – for patients who need it. There is a good listing of such resources on the AAO website (aao.org) by entering “low vision resources” in the search bar.
- The AAO’s Vision Rehabilitation Committee has created a short video titled “There is something you can do” (available at: <http://bit.ly/AAOVision>). As David W. Parke II says in the video: “Vision rehabilitation is now the standard of care for patients who are losing their vision. This is something that all of us as ophthalmologists should keep in mind every day in our offices.”

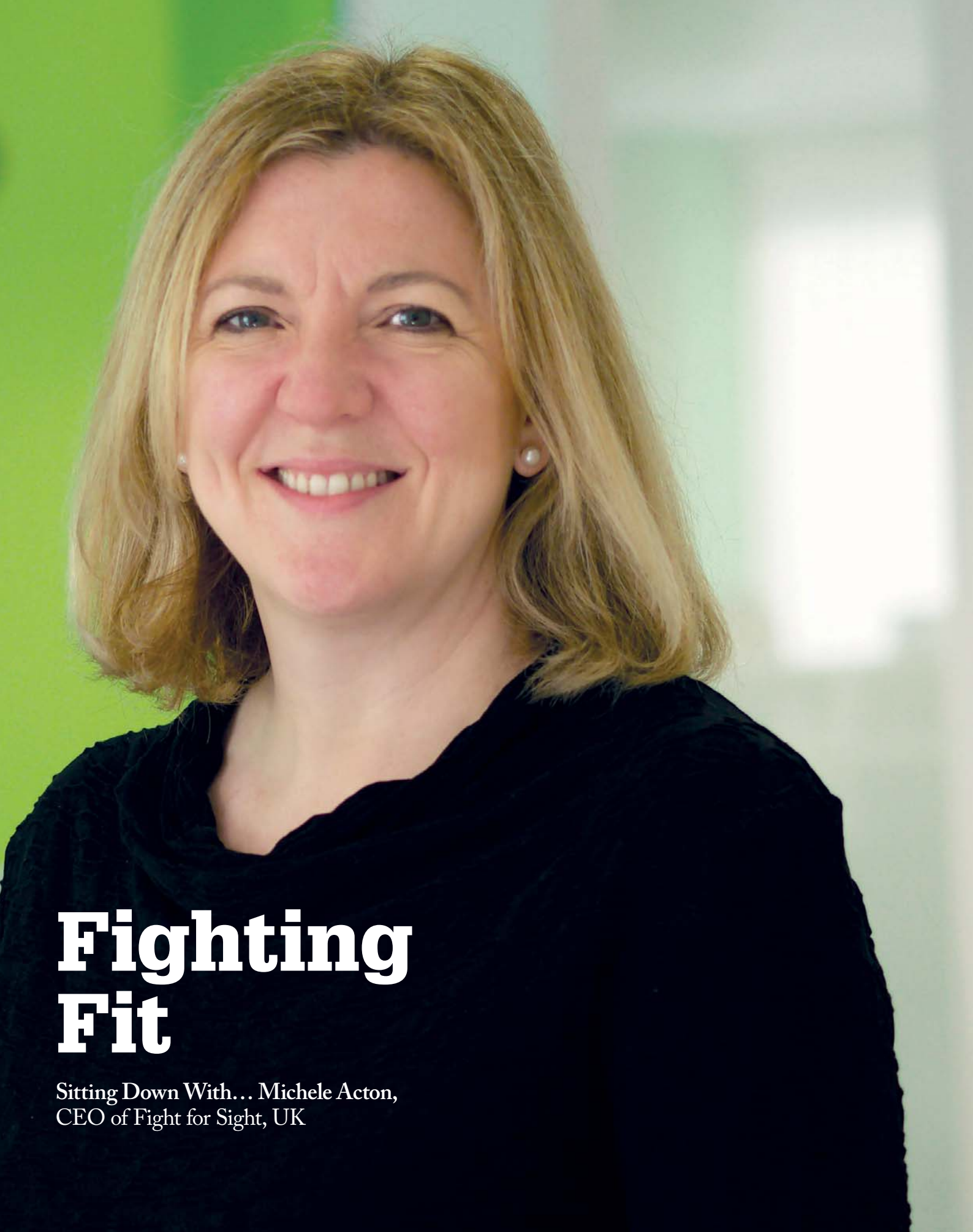in with the difficulties I experienced with totally different symptoms. Although we have a long journey ahead, we’re making inroads, and I am optimistic we can meet the needs of this increasing patient population over the next few decades.

Our care for patients must go further; we must look at the person behind the eye and resolve to never forget the impairments that can be caused by their disease. As Sir William Osler – one of the founding physicians of Johns Hopkins Hospital, Baltimore – once said, “The good physician treats the disease; the great physician treats the patient who has the disease.”

By John D. Shepherd, Director of the Weigel Williamson Center for Visual Rehabilitation and Assistant Professor of Ophthalmology at the University of Nebraska Medical Center in Omaha, USA.

References

1. BL Brody et al., “Depression, visual acuity, comorbidity, and disability associated with age-related macular degeneration”, *Ophthalmology*, 108, 1893–1900 (2001). PMID: 11581068.
2. BW Rovner et al., “Effect of depression on vision function in age-related macular degeneration”, *Arch Ophthalmol*, 120, 1041–1044 (2002). PMID: 12149057.
3. HP van der Aa et al., “Major depressive and anxiety disorders in visually impaired older adults”, *Invest Ophthalmol Vis Sci*, 56, 849–854 (2015). PMID: 25604690.
4. BW Rovner et al., “Low vision depression prevention trial in age-related macular degeneration: a randomized clinical trial”, *Ophthalmology*, 121, 2204–2211. PMID: 25016366.
5. R Varma et al., “Visual impairment and blindness in adults in the United States: demographic and geographic variations from 2015 to 2050”, *JAMA Ophthalmol*, 134, 802–809 (2016). PMID: 27197072.



Fighting Fit

Sitting Down With... Michele Acton,
CEO of Fight for Sight, UK

Your background is in investment banking...

It's funny, isn't it! I spent 15 years in investment banking, mostly advising UK and African companies on raising money, and on mergers and acquisitions. I decided that I wanted to do something different, and something I was passionate about, so I made a major life change and went to run the charitable foundation at University College London Hospitals. I discovered how excited and passionate I was about the medical research we were funding, and I found the difference it could make to people's lives utterly fascinating. My parents had always supported sight loss charities, so when I saw an advert for the role of CEO at Fight for Sight, it all just seemed to fall into place. I could see a huge unmet need in terms of actually being able to stop people losing their sight, yet the UK is perfectly placed to help. We have fantastic and highly committed clinicians and academic researchers, but it was absolutely clear to me that they needed more financial support to deliver outcomes for patients. I feel thrilled and privileged that I have been able to take on this role.

One of the biggest changes from investment banking was not so much moving to a charity, but moving to a much smaller organization. It was an enormous shock to go from a bank that employed thousands of people to working for an organization of three. Now, we employ 25 people and are funding research at 44 different universities and hospitals, having started by funding just two main institutions. Actually being able to develop Fight for Sight as a national charity and see the breadth and variety of research that is being funded, as well as the impact it can have, is tremendously exciting and rewarding.

What is most exciting you right now?

Over my 11 years in this role, I have seen huge changes and significant progress in being able to address sight loss. I think one of the biggest areas of excitement is around the development of potential treatments for people with inherited retinal diseases. Fight for Sight has invested millions in understanding these diseases, as well as investing in research that has helped lead to clinical trials – the first in the world. It's exciting to see the first gene therapy drug for an inherited eye disease, Luxturna, being approved by the FDA. At Fight for Sight, we not only want to fund the necessary research but we want to do all that we can to ensure that patients are able to access new treatments.

“It was an enormous shock to go from a bank that employed thousands of people to working for an organization of three.”

What is a typical day like?

There is no typical day... One of the great privileges of this job is the huge variety of people that I come into contact with – from the fantastic people who support Fight for Sight – many of whom are affected by sight loss – to the talented researchers we support and the charity

and government partners that we work with. My day could involve meeting committed supporters (perhaps watching them do a skydive!), researchers, representatives from government and other organizations, talking to the media and speaking at sector and industry conferences.

Any plans to skydive yourself?

We have a big team who are doing a skydive this year but it's not for me – I prefer things that involve stamina, such as trekking up a mountain or running a marathon. My first challenge for Fight for Sight was the London Marathon. I have also climbed Mount Kilimanjaro. I'm thinking about doing a triathlon next but I'll have to work on my swimming – I'm not sure I can do a triathlon with breaststroke!

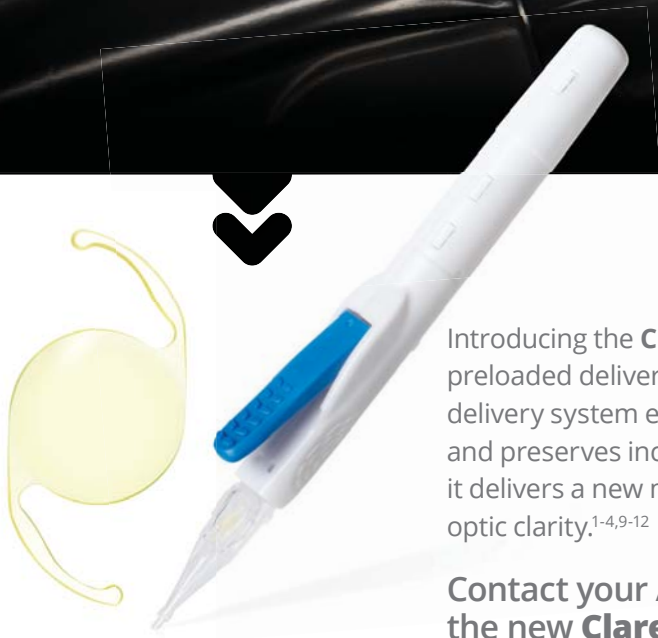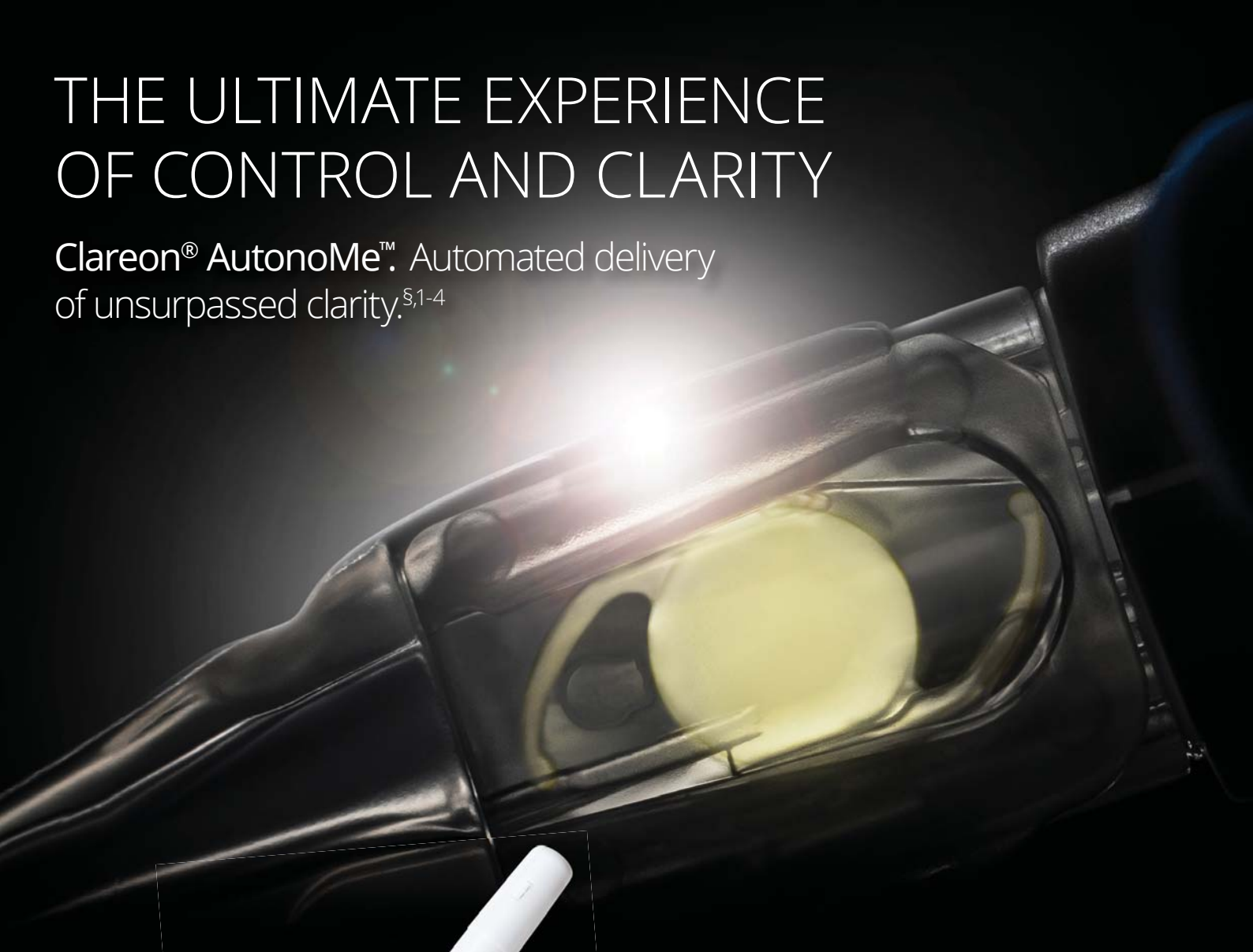Any personal missions for the next 10 years?

One personal mission is aligned with Fight for Sight; we launched our new strategy last year, and our ambition is to significantly increase our impact. To do this we need to increase our income in what is a difficult fundraising environment. We hear many people say that sight loss is inevitable. We need to change the narrative away from acceptance to the belief that research can and will deliver new and better treatments. The advances in science over the last 10 years are now showing that this is possible.

I'd also like to see women thriving in vision, by helping to support real change in the gender balance at senior levels across ophthalmology and optometry over the next 10 years – we need to utilize all talent to maximize outcomes for patients. Finally, I want to add some form of balance in my life and actually do some exercise – essential if I want to do a triathlon!

THE ULTIMATE EXPERIENCE OF CONTROL AND CLARITY

Clareon® AutoNoMe™. Automated delivery
of unsurpassed clarity.^{§,1-4}



Introducing the **Clareon® IOL** with the **AutoNoMe™** automated, disposable, preloaded delivery system. With its intuitive, ergonomic design, the **AutoNoMe™** delivery system enables easy, single-handed control of IOL advancement and preserves incisions as small as 2.2 mm.^{1,5-8} Preloaded with the **Clareon® IOL**, it delivers a new monofocal lens with an advanced design and unsurpassed optic clarity.^{1-4,9-12}

Contact your Alcon representative to learn more about
the new **Clareon® AutoNoMe™**.

1. Clareon® AutoNoMe™ Directions for Use. 2-12. Alcon Data on File.

§Based on aggregate results from *in vitro* evaluations of haze, SSNGs and glistenings compared to TECNIS^{SS} OptiBlue^{SS} ZCB00V (Abbott), TECNIS^{SS} ZCB00 (Abbott), Eternity Natural Uni^{iSS} W-60 (Santen), Vivinex^{SS} XY-1 (HOYA) and enVista^{SS} MX60 (B&L; Bausch & Lomb). §§Trademarks are the property of their respective owners.

Alcon A Novartis
Division

© 2018 Novartis 2/18 GL-CAM-17-MK-0486-EU

 Clareon. AutoNoMe™

 **Advancing**
CATARACT SURGERY