


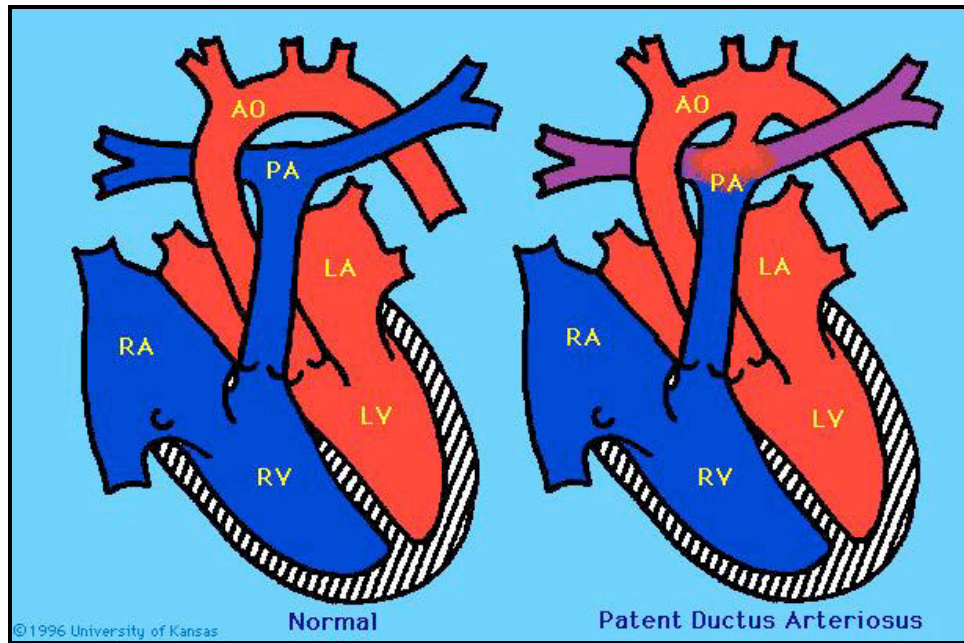
Congenital Heart Defects



Congenital Heart Defects

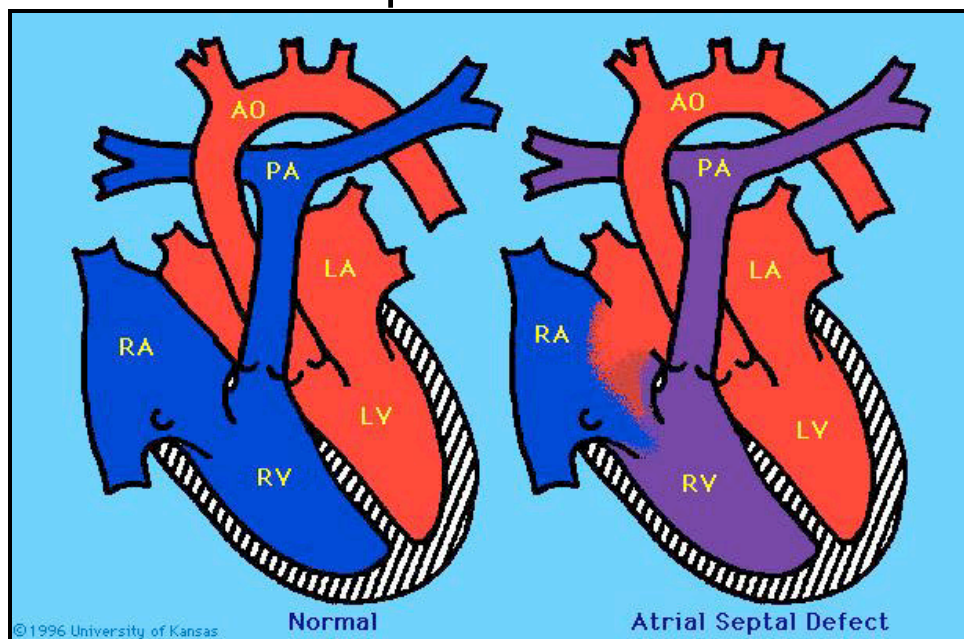
CHD with Increased Pulmonary Blood Flow	
Patent Ductus Arteriosus - PDA	3
Atrial Septal Defect - ASD.....	4
Ventricular Septal Defect - VSD	5
Aorto-Pulmonary Window	6
Truncus Arteriosus	8
D-Transposition of the Great Arteries.....	9
Partial or Total Anomalous Pulmonary Venous Return P-APVR/T-APVR	10
 CHD with Decreased Pulmonary Blood Flow	
Pulmonary Stenosis	12
Tetrology of Fallot	13
Tetrology of Fallot with Pulmonary Atresia	14
Tetrology of Fallot with Pulmonary Atresia & Major Aorto-Pulmonary Collateral's (MAPCA'S).....	15
Tricuspid Atresia	18
Double Outlet Right Ventricle - DORV.....	19
 CHD with Decreased Systemic Blood Flow	
Coarctation of the Aorta.....	22
Interrupted Aortic Arch.....	23
Aortic Stenosis.....	24
Hypoplastic Left Heart Syndrome	25
Ebstein's Anomaly.....	26
 Palliative Procedures	
Pulmonary Artery Banding	27
Blalock-Taussig Shunt.....	28
Bi-directional Glenn Shunt	29
Norwood.....	31
 Corrective Repair	
Rastelli	32
Damus-Kaye-Stansel.....	32
Fontan.....	33
Mustard	34
Senning.....	34
Rashkind Balloon Septostomy.....	34
Atrial Septectomy.....	34
Ross Procedure	35
Konno Procedure	35
 Congenital Cardiac Conditions	
L-Transposition of the Great Arteries	36
Anomalous Coronary Artery.....	37
Cardiac Malposition.....	38
Heterotaxy.....	38
Shones Complex.....	38
Syndromes	39
Hereditary Syndrome Cardiac Defect Clinical Features.....	39
Non-Hereditary Syndromes Associated with.....	40
Cardiovascular Anomalies	40
Syndrome Cardiac Defect Clinical Features	40

Patent Ductus Arteriosus - PDA



- Anatomy** The ductus arteriosus is a communication between the pulmonary artery and the aortic arch distal to the left subclavian artery. Patent ductus arteriosus (PDA) is the failure of the fetal ductus arteriosus to close after birth.
- Physiology** Left to right shunting of blood through the patent ductus results in an increase in pulmonary blood flow. The amount of blood that flows through the ductus, and the degree of symptoms exhibited, is determined by the differences in systemic and pulmonary vascular resistance, and in the circumference and the length of the PDA.
- NOTE: The PDA may be life-saving in infants with complex cyanotic heart defects or left sided obstructive defects, providing the only or major source of pulmonary or systemic blood flow. A continuous PGE infusion will maintain the ductal opening and sustain life until cardiac surgery can be performed. PDA's may be present in premature infants.
- Preop** The small or premature infant with a PDA is at risk for CHF, which may be treated with diuretics and/or digitalization. Surgical correction is recommended for all infants with CHF who have not responded to medical management, and for any child greater than 1 year of age. Prolonged left to right shunting can result in pulmonary vascular disease.
- Surgery** Surgery is accomplished via a left thoracotomy incision and without the use of cardiopulmonary bypass. The ductus may be ligated (tied) or divided (cut) and sewn. The timing of surgery depends on the severity of symptoms and the size of the defect. Some PDA's can be closed nonsurgically with coil placement via cardiac catheterization.
- Postop** Complications are rare. In the premature infant, other factors such as respiratory distress complicate recovery.

Atrial Septal Defect - ASD



Anatomy

An atrial septal defect (ASD) is a communication or opening between the atria that results in shunting of blood between the two chambers. There are 4 anatomic types:

Ostium primum - low in atrial septum, may involve a cleft mitral valve.

Ostium secundum - center of the atrial septum. Most common type of ASD.

Sinus venosus - high in the atrial septum. Associated with P-TAPVR.

Coronary sinus - large opening between the coronary sinus and left atrium.

Physiology

Because of higher pressure in the left atrium, blood is usually shunted from the left atrium across the ASD and into the right atrium. ASD's are restrictive when they are small enough to provide resistance to flow across the septum. ASD's are non-restrictive when the opening is large enough that equal pressures occur in both atria.

If the child has a cyanotic congenital heart defect, an ASD can provide an important shunt that allows mixing of oxygenated and venous blood within the atria. This may be necessary to sustain life.

Preop

Isolated ASD's rarely cause symptoms during infancy. A small percentage of infants and children present with CHF and are treated with digoxin and diuretics. Symptoms are related to the size of the left-to-right shunt. Surgery is generally performed electively at 3-4 years of age. Very few ASD's close spontaneously after the 1st year of life.

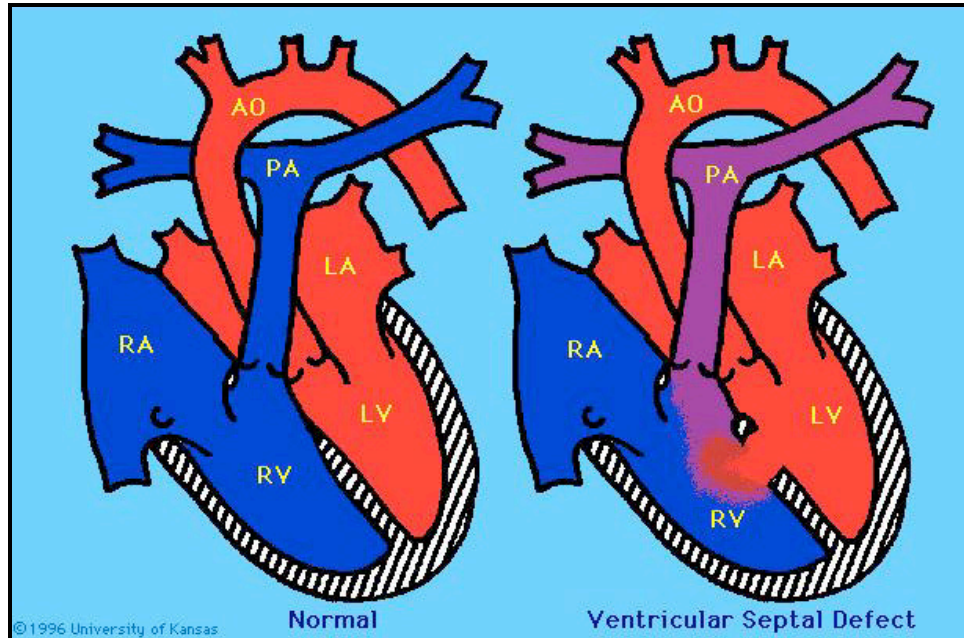
Surgery

Repair is via a median sternotomy incision with use of cardiopulmonary bypass. Lesions are primarily closed with sutures or a pericardial patch. Non-surgical closure of ASD's has been achieved via cardiac catheterization. The pericardial patch is folded like an umbrella or clamshell within a special catheter. This catheter is then threaded into the left atrium, where the umbrella-like patch is opened and drawn against the atrial septum.

Postop

SA node injury and dysrhythmias may develop in the immediate post-operative period. Post pericardiectomy syndrome can occur in the first few days or weeks after surgery. Symptoms include; fever, malaise, nausea, vomiting, or abdominal pain.

Ventricular Septal Defect - VSD



Anatomy

A ventricular septal defect (VSD) is a communication (or multiple communications) between the right and left ventricles. VSD's are classified by their location in the ventricular septum. There are 4 anatomic types:
Perimembranous - upper portion of septum (most common).
Subpulmonary - below pulmonary valve.
Muscular - muscle portion of ventricular septum. Usually low in the ventricular septum. Multiple muscular defects may be referred to as 'swiss cheese' defects.
Atrioventricular canal - located beneath the tricuspid valve. Also called an inlet VSD.

Physiology

Because of higher pressure in the left ventricle, blood is usually shunted from the left ventricle, across the VSD into the right ventricle, and into the pulmonary circulation. The risk of pulmonary hypertension depends on the size and location of the defect and the amount of pulmonary vascular resistance. Small VSD's restrict the amount of blood shunting from left to right. Large VSD's are non-restrictive, therefore a much higher degree of shunting occurs, and blood flow to the lungs is increased.

Preop

Identifying the type and size of the VSD is very important. The potential development of pulmonary hypertension needs to be followed closely to determine the timing of surgery. Children are often maintained on digoxin and diuretics for symptoms of CHF. These patients have an increased risk of developing pneumonia, and if a large VSD is present, they are at risk for development of subacute endocarditis. Surgery in early infancy may be recommended to prevent the development of pulmonary vascular disease.

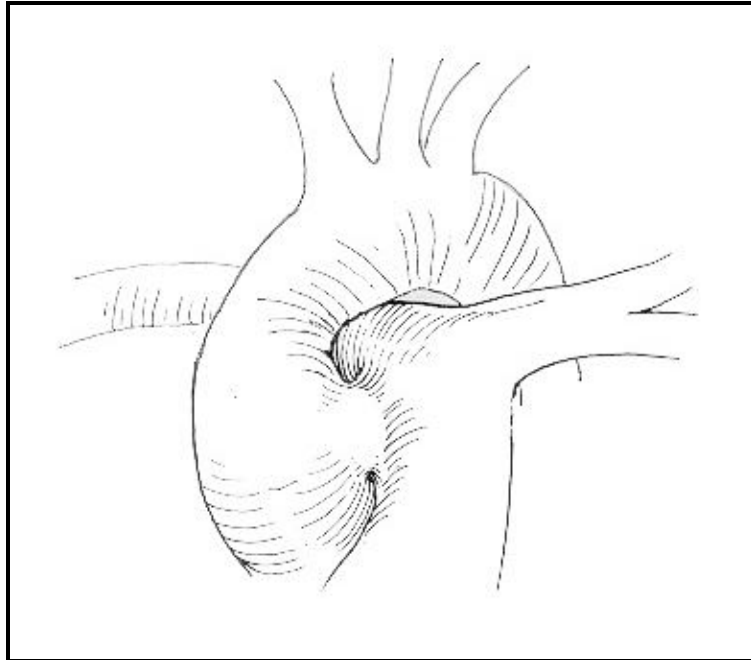
Surgery

Repair is via a median sternotomy incision with use of cardiopulmonary bypass. The septal wall may be closed directly with sutures, or with a pericardial patch.

Postop

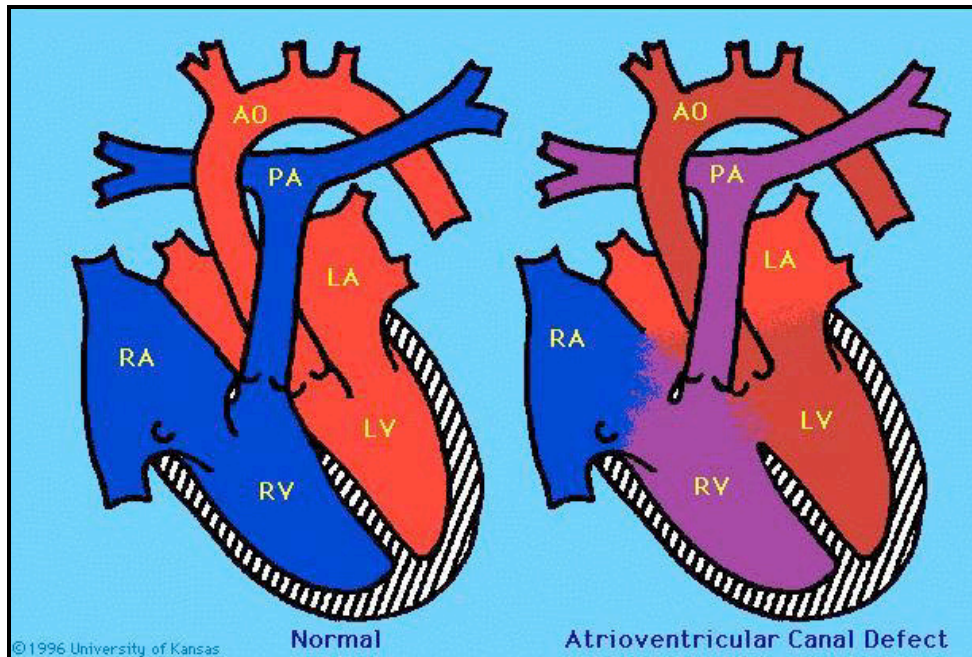
Complications may include heart block and junctional ectopic tachycardia (in infants). Residual VSD's may also remain.

Aorto-Pulmonary Window



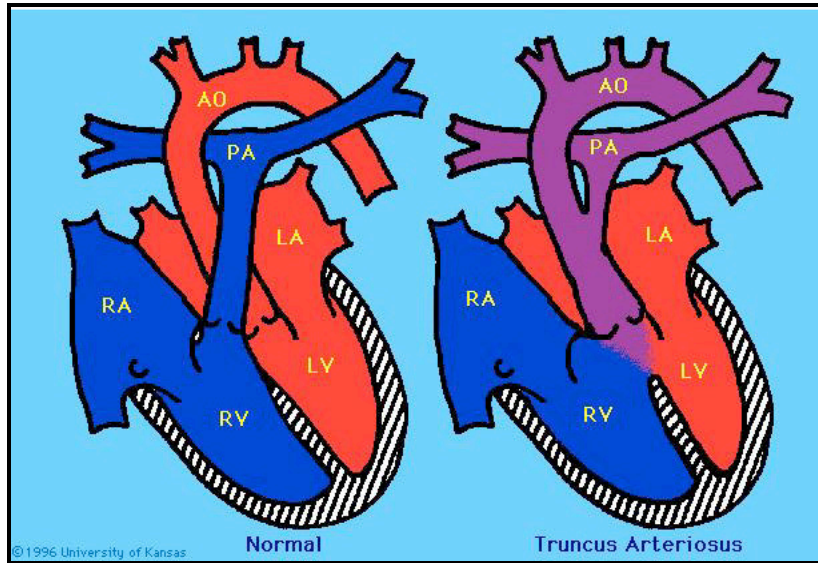
- Anatomy** Aorto-Pulmonary window is an opening between the ascending aorta and the main pulmonary artery. There must be two distinct and separate semilunar valves before this diagnosis can be made. The opening is of variable size and there are 3 anatomic types.
Type I - Proximal defect, is located midway between the semilunar valves and the pulmonary bifurcation.
Type II - Distal defect, involves both the main pulmonary artery and the origin of the right pulmonary artery.
Type III - Total defect, incorporates defects present in types I and II. This is a rare cardiac malformation and 50% of patients have associated lesions.
- Physiology** There is a left to right shunt, as with a VSD or a persistent PDA. As the pulmonary resistance decreases in the days and weeks after birth, there is an increase in left to right shunting of blood leading to CHF. Without repair, and depending on the size of the defect, varying degrees of irreversible pulmonary vascular disease develops.
- Preop** The potential for development of pulmonary hypertension is closely monitored. Signs and symptoms of CHF are controlled with digoxin and diuretics.
- Surgery** Surgical closure of the defect is indicated in all patients with aorto pulmonary window. Repair is via a median sternotomy incision and cardiopulmonary bypass. Patch closure of the defect is performed. Correction of associated defects, particularly arch anomalies, can be performed at the same time.
- Postop** Postoperative care of patients after repair is usually uneventful. Monitor for pulmonary hypertension.

Atrio-ventricular Canal - AVC



- Anatomy** Atrioventricular canal (AVC) may be complete or partial. Complete AVC is a communication between both the atria and the ventricles, as well as failure of the tricuspid and mitral valve rings to develop separately. There are often clefts in the septal valve leaflets. The term “canal” is used because the common AV valve orifice and the deficient atrial and/or ventricular septal tissue create a large opening in the center of the heart between the atria and ventricles. There are varying degrees of abnormality in the atrial and ventricular septum and the AV valves, resulting in many variations of severity and symptoms. In the partial form of AVC, only an ASD is present along with a cleft in the mitral valve.
- Physiology** Shunting occurs at the atrial and ventricular levels in a left-to-right direction. The right atrium also receives blood from the left ventricle via the insufficient mitral valve and ASD. Blood can also enter the right atrium via the incompetent tricuspid valve. The excessive volume load on the right side of the heart and subsequent increased blood flow to the lungs, creates a high risk for development of pulmonary vascular disease and pulmonary hypertension.
- Preop** Symptoms depend on the degree of shunting and AV valve regurgitation. Children are often maintained on digoxin and diuretics for symptoms of CHF. These patients have an increased risk of developing pulmonary hypertension.
- Surgery** Repair is via a median sternotomy incision with use of cardiopulmonary bypass. The ASD and VSD may be closed with a single pericardial patch or two separate patches. The tricuspid and mitral valve are reconstructed. Surgical repair is performed early in infancy to prevent complications from CHF and pulmonary vascular disease. NOTE: A-V Canal is the most common congenital heart lesion seen among children with Down’s Syndrome (trisomy 21).
- Postop** Atrioventricular valve insufficiency, tricuspid valve and/or mitral valve regurgitation may be seen. Keep atrial filling pressures normal/low, assess waveform for changes. Avoid excessive volume resuscitation to prevent dilation of the AV valves and AV valve regurgitation. Pacemaker therapy may be indicated for SA node and AV node dysfunction (junctional and heart block problems).

Truncus Arteriosus



Anatomy

Truncus arteriosus is a rare congenital heart defect in which a single great vessel arises from the heart, giving rise to the coronary, systemic and pulmonary arteries. This single vessel contains only one valve (truncal valve). The truncus arteriosus overlies a VSD that is almost always seen in conjunction with this defect.

There are
4 major types:

Type I: The most common; a single great vessel arises from the ventricles, and divides into an aorta and a main pulmonary artery (PA).

Type II: There is no main PA segment. The right and left PA's originate from the back of the truncus at the same level.

Type III: The right and left PA arise separately from the lateral aspect of the truncus. There is no main PA segment.

Type IV: No main PA. Pulmonary artery circulation is supplied from the systemic arterial circulation through collateral vessels of the bronchial arteries. This type is currently considered a form of Tetralogy of Fallot with pulmonary atresia.

Physiology

In virtually every case of truncus arteriosus there is a VSD and a single large semilunar valve. Oxygenated and de-oxygenated blood from both the right and left ventricles is ejected into the common great vessel. Both systemic and pulmonary circulations receive mixed venous blood from both ventricles. Pressures in both ventricles are identical. Pulmonary blood flow is increased, therefore pulmonary vascular disease and PHTN will develop over time. The amount of blood flow to the lungs varies, depending on the nature of the pulmonary arteries.

Preop

Infants have varying degrees of cyanosis and signs of CHF. Medical management is directed toward controlling CHF with digoxin and diuretics. Surgery is accomplished during the first weeks of life to prevent the development of pulmonary vascular disease. Evidence of Di George Syndrome is present in 33% of patients.

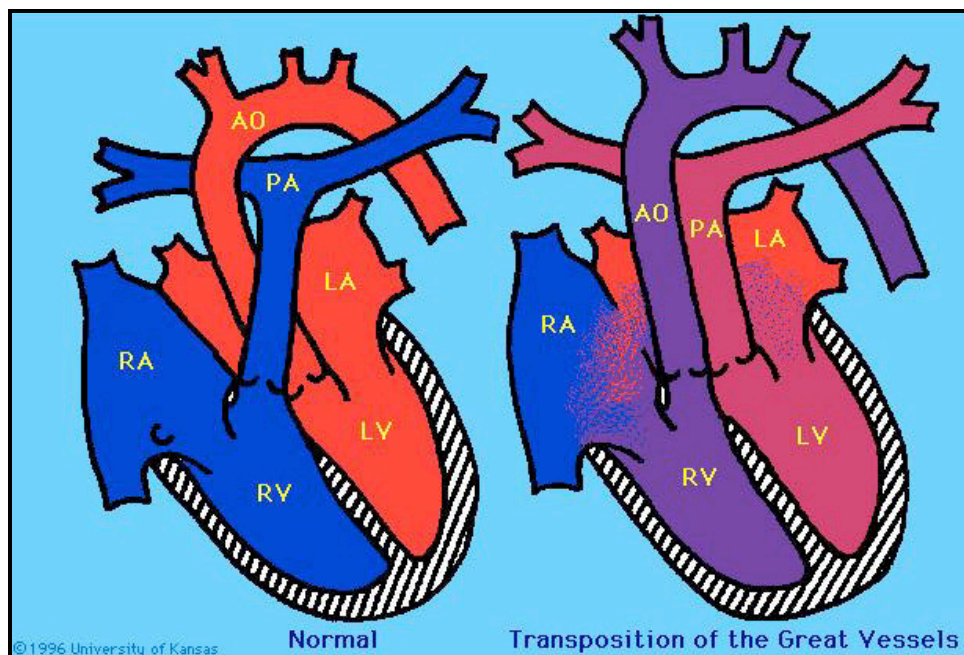
Surgery

Repair is via a median sternotomy incision with the use of cardiopulmonary bypass. The pulmonary arteries are separated from the common trunk and anastomosed to a valved conduit from the right ventricle. The VSD is patched in a way that locates the truncus arteriosus to the left of the septum, where it functions as the aorta only.

Postop

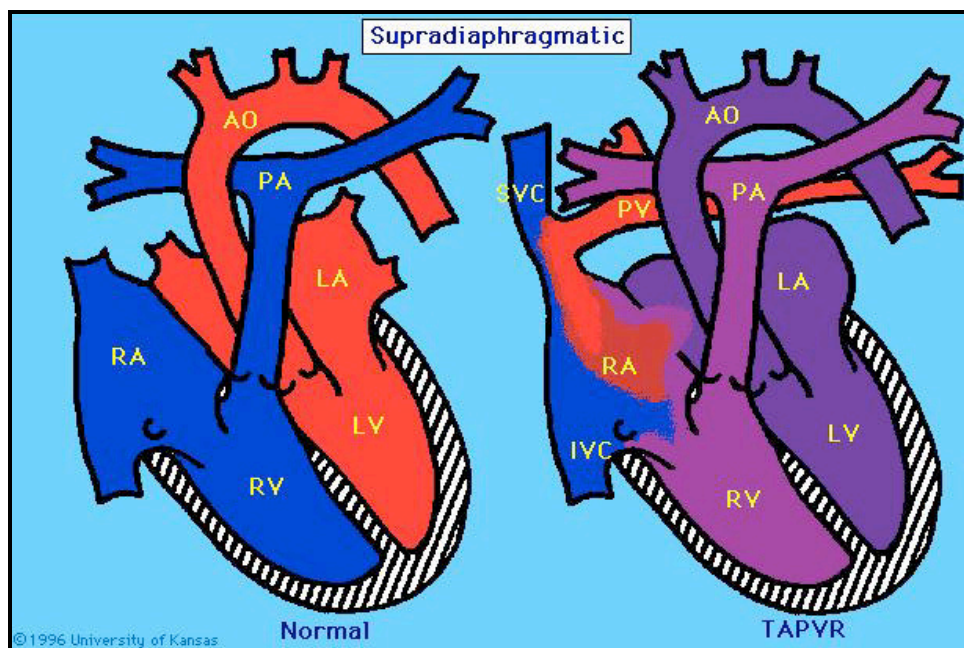
Truncal valve (aortic valve) insufficiency and pulmonary vascular reactivity (pulmonary hypertensive crisis) may occur. Cyanosis related to right ventricular dysfunction is typically present in the postoperative period. Because of the right ventricular incision, RBBB, junctional ectopic tachycardia (JET) and A-V block may also be present.

D-Transposition of the Great Arteries



- Anatomy** In D-Transposition of the Great Arteries (D-TGA) the aorta arises from the anatomic right ventricle and the pulmonary artery arises from the anatomic left ventricle. The most common form of transposition occurs when the ventricles are normally positioned and the aorta is malposed anteriorly and rightward above the right ventricle. A VSD is present in 40% of patients with D-TGA. Abnormal coronary artery patterns present in 33% of cases.
- Physiology** Blood flows from the RA to the RV and out through the aorta, carrying deoxygenated blood to the body. Blood flows from the LA to the LV and out through the PA, carrying oxygenated blood to the lungs. This results in two separate, parallel circulations that require mixing at the atrial, ventricular or ductus arteriosus level. The degree of desaturation present will depend primarily on the amount of mixing between systemic and pulmonary venous blood. The extent of inter-circulatory mixing in D-TGA depends on the number, size and position of the anatomic communications.
- Preop** Moderate to severe cyanosis is present. Preop management is aimed at increasing arterial oxygenation by starting a continuous PGE infusion, and/or balloon atrial septostomy to increase mixing at the atrial level. Diuretics are indicated if pulmonary edema is noted. Surgery is performed within the first 2 weeks of life.
- Surgery** *Rashkind Procedure (Palliative)*: Performed at the bedside under ECHO guidance. A deflated catheter is passed across the foramen ovale. The balloon is then inflated and pulled back - creating an ASD. This is done in the first few days of life to improve mixing at the atrial level.
- Arterial Switch Procedure (Corrective)*: Returns the great vessels to their normal anatomic relationship with the ventricles. A median sternotomy incision and use of cardiopulmonary bypass is utilized. Anatomic correction of transposition is performed by switching the aorta and PA back to the correct position. Any septal defects are closed. Once the great vessels have been switched, the coronary arteries are re-implanted in the 'new' aorta.
- Postop** Complications include; bleeding from high pressure on extensive suture lines (keep BP WNL), myocardial ischemia secondary to kinking or stenosis of the re-implanted coronary arteries and left ventricular dysfunction (potential L- VAD candidate). Observe for signs of myocardial dysfunction (obtain 12-lead ECG postoperatively) and assess for dysrhythmias (ST and JET), which may be a marker for coronary insufficiency. The most significant late complication is supra-valvular pulmonary stenosis.

Partial or Total Anomalous Pulmonary Venous Return P-APVR/T-APVR



Anatomy

Total Anomalous Pulmonary Venous Return (T-APVR) results from the failure of the pulmonary veins to join normally to the left atrium during fetal cardiopulmonary development. The pulmonary veins empty abnormally into the right atria via drainage into one of the systemic veins. The infant must have an ASD or a PFO to survive. There are 4 anatomic variations; defined according to the site of the anomalous connection of the pulmonary vein to the venous circulation and to the right atrium.

Supracardiac: The pulmonary veins join a common pulmonary vein behind the left atrium. This common vein ultimately enters the superior vena cava and right atrium.

Cardiac: The pulmonary venous blood drains into a common pulmonary vein that drains into the right atrium or coronary sinus.

Infradiaphragmatic: Pulmonary veins join to form a common pulmonary vein that descends below the diaphragm, through the portal system, then drains via the ductus venosus into the inferior vena cava and into the right atrium.

Mixed: Pulmonary veins join the systemic circulation at two different sites, or use any combination of systemic venous drainage.

Partial Anomalous Pulmonary Venous Return (P-APVR) results when one or more (but not all) pulmonary veins drain into the right atrium or its venous tributaries.

Physiology

There are two basic pathophysiologic states seen in T-APVR: unobstructed and obstructed. With unobstructed T-APVR, the entire pulmonary venous blood flow is returned to the systemic venous circulation, where there is mixing of the two venous returns in the right atrium. Mixing is virtually complete, each chamber of the heart receiving blood of almost identical oxygen concentration. Right atrial and ventricular dilation are present. The right to left shunting of blood across the PFO/ASD is essential for life. The amount of pulmonary blood flow is regulated by the pulmonary arteriolar resistance and by obstructions of the pulmonary veins. With obstructive T-APVR, the amount of pulmonary blood flow is reduced, causing cyanosis. This decreased flow, along with the systemic venous return, results in low arterial oxygen saturation and right heart failure.

Preop

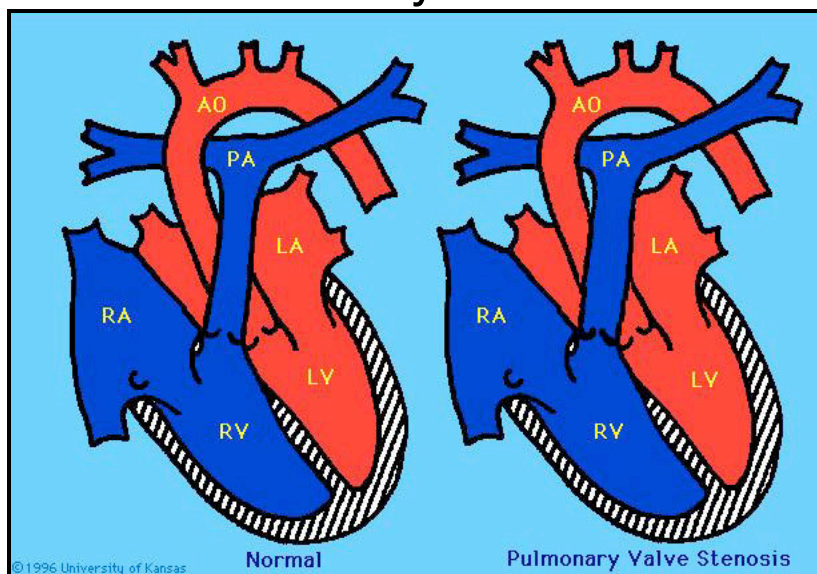
The timing for surgery and the preop management depends on the presence or absence of obstructive T-APVR. The neonate with obstructive T-APVR requires surgery immediately. The neonate with non-obstructive T-APVR has surgery performed electively early in infancy. With any form of partial or total anomalous pulmonary venous return an echocardiogram enables diagnosis and determination of the site of pulmonary venous connection. This defect is associated with asplenia, or polysplenia.

Surgery	Repair is via a median sternotomy incision with use of cardiopulmonary bypass and hypothermia. Surgical correction requires anastomosis of the common pulmonary veins to the left atrium, elimination of the anomalous pulmonary venous connection, and closure of any interatrial communication. If a PDA is present, it is ligated.
Postop	Myocardial dysfunction, especially in neonates with obstructed veins may occur. Neonates with obstructive T-APVR have very labile pulmonary vascular reactivity after surgery and are at increased risk for pulmonary hypertensive crisis. Avoid situations that result in increased pulmonary vascular resistance (use aggressive management of hypoxemia and acidosis). Careful management with sedation is indicated. Dysrhythmias may also occur (supraventricular tachyarrhythmias or heart block).

Scimitar Syndrome

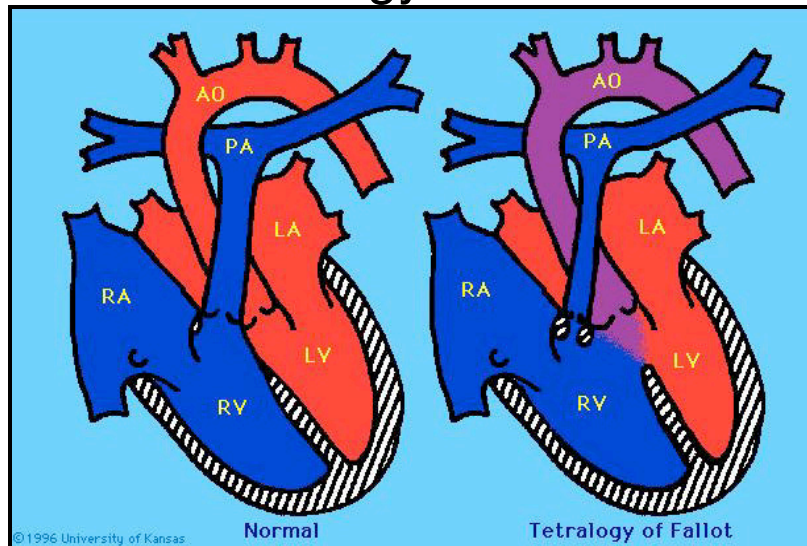
In Scimitar Syndrome, all or some of the pulmonary veins from the lower lobe and sometimes the middle lobe of the right lung drain anomalously into the inferior vena cava, making a peculiar scimitar-shaped vertical radiographic shadow along the right lower cardiac border. If the pulmonary veins are low on the inferior vena cava, the pulmonary veins are detached from their IVC connection and anastomosed to the wall of the right atrium. If the pulmonary veins are not low, they are left alone. A portion of the interatrial septum is then excised to create an atrial septal defect. These pulmonary veins then drain into the left atrium via an interatrial baffle that is created.

Pulmonary Stenosis



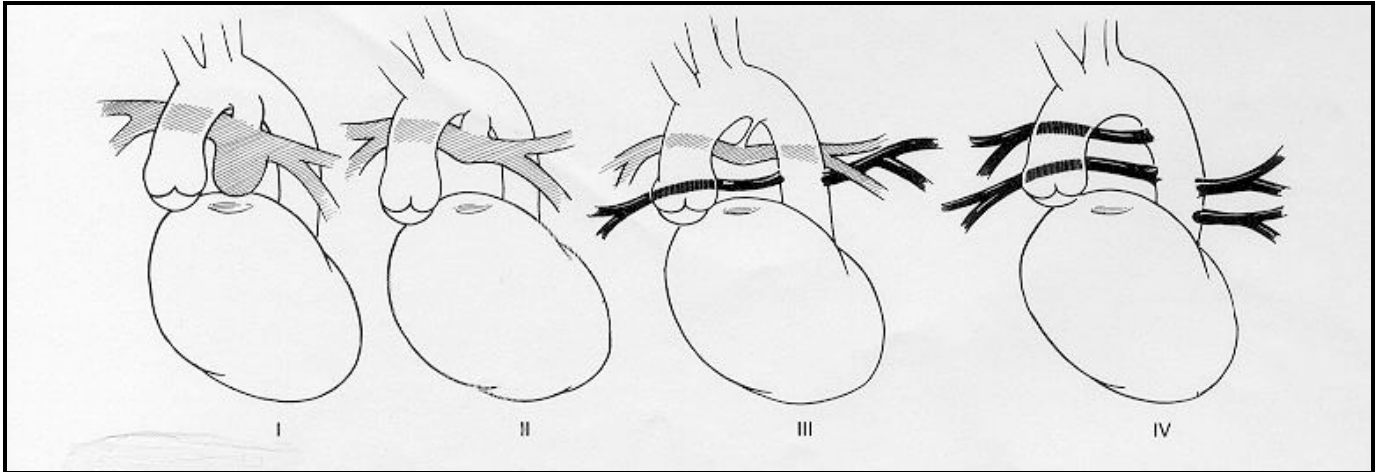
- Anatomy** Pulmonary stenosis (PS) is a narrowing that obstructs blood flow from the right ventricle. It may be subvalvular, valvular, supra-valvular or in the pulmonary arteries. When this presents in neonates, it is referred to as 'critical pulmonary stenosis'.
- Physiology** Pulmonary stenosis increases resistance to flow from the right ventricle. To maintain blood flow to the lungs, the right ventricle must generate higher pressures. The greater the pulmonary stenosis, the greater must be the pressure generated by the right ventricle. Because the pressure on the right side is higher, right ventricular hypertrophy is also present. Pulmonary stenosis may be mild, moderate or severe. When severe, the right ventricular hypertrophy may result in a right to left shunting through the foramen ovale.
- Preop** Children with pulmonary stenosis are followed closely to detect, as early as possible, progression of stenosis with growth.
- Surgery** Treatment depends on the location and severity of the obstruction. Options include observation, balloon dilatation and surgery.
MILD PULMONARY STENOSIS: Requires no surgical intervention. These infants and children are examined by cardiologists at regular intervals for signs of progression of the stenosis.
MODERATE TO SEVERE PULMONARY STENOSIS: The symptomatic child requires a balloon valvuloplasty or surgical valvotomy. In the neonatal period, PGE infusion is provided to maintain patency of the ductus arteriosus.
Pulmonary Balloon Valvuloplasty: Insertion of a balloon catheter through the stenotic pulmonary valve, during cardiac catheterization. The balloon is inflated and stretches the valve annulus. Successful valvuloplasty produces tears in the valve.
Surgical Valvotomy: This procedure is performed via a median sternotomy incision and with use of cardiopulmonary bypass. The pulmonary artery is opened and the fused valve leaflets are incised along the valve commissures. The valve is opened sufficiently to relieve the stenosis yet prevent regurgitation. If the valve is extremely deformed or bicuspid, part or all of the valve may be removed. Patch enlargement of the right ventricular outflow tract is occasionally necessary if the pulmonary valve annulus is extremely small. If the right ventricle is extremely small and pulmonary blood flow remains compromised, a systemic to pulmonary artery shunt (BT Shunt) may also be created at the time of the pulmonary valvotomy.
- Postop** Some degree of pulmonary valve insufficiency and regurgitation may be seen. Patients with significant right ventricular hypertension and hypertrophy may develop some degree of right ventricular failure in the postoperative period.

Tetralogy of Fallot



Anatomy	Tetralogy of Fallot (TOF) is a congenital heart defect characterized by the association of four cardiac abnormalities; malaligned VSD, subpulmonary stenosis, overriding aorta and right ventricular hypertrophy. There is a wide spectrum of right ventricular outflow tract obstruction (RVOTO) in TOF. It may be subvalvar, valvular and/or supravalvular. Typically, there is hypoplasia of the right ventricular outflow tract, stenosis of the pulmonary valve and hypoplasia of the pulmonary annulus and trunk. The right and left pulmonary arteries are usually normal in size. Some infants with TOF may be referred to as a 'pink' TET, if no cyanosis is present.
Physiology	The hemodynamic changes and the degree of cyanosis that occur as a result of Tetralogy of Fallot are directly proportional to the degree of subpulmonary stenosis (right ventricular outflow tract obstruction), and the resulting limitation to pulmonary blood flow. If RVOTO is mild, there is minimal shunting of blood from left to right across the VSD which may result in over circulation and signs of CHF. If severe RVOTO is present, a large amount of blood shunts from right to left, producing systemic arterial oxygen desaturation which can lead to severe hypoxemia and acidosis. As long as the ductus remains open, pulmonary blood flow is adequate. NOTE: "TET Spells" or hypercyanotic spells are acute episodes of arterial oxygen desaturation secondary to intermittent worsening of right ventricular outflow tract obstruction causing right to left shunting across the VSD. The infant may become extremely irritable, cyanotic and may lose consciousness.
Preop	Closely monitor for 'TET spells' which may lead to hypoxemia and acidosis. Symptoms depend on the degree of RVOTO and the amount of shunting. Coronary artery anomalies occur in 5% of patients with TOF, and may be highly significant surgically if the anomalous artery crosses the RVOT. This knowledge may lead to a decision to postpone surgical repair, or to construct a shunt if the infant is symptomatic.
Surgery	Timing of surgery remains controversial. At UCSF the approach is to avoid any palliative procedure and perform a complete repair in the neonatal or early infancy period. A median sternotomy incision and cardiopulmonary bypass is utilized. The ductus arteriosus is ligated if patent. Pericardium is excised prior to placing the infant on bypass for subsequent use in the reconstruction of the RVOT. The large malalignment type of VSD is closed with a Dacron patch and reconstruction of the right ventricular outflow tract is done. The hypertrophic pulmonary infundibular muscle is cut away and a pulmonary valvotomy is performed if needed. If the pulmonary artery is small, a patch is placed across the right ventricular outflow tract. If the pulmonary annulus is hypoplastic, a transannular patch is placed. Occasionally the PFO is left open as a 'pop off' for high right sided venous pressures, resulting in improved cardiac output at the expense of mild cyanosis.
Postop	Complications include dysrhythmias; RBBB, tachycardia and junctional ectopic tachycardia (JET), right ventricular dysfunction, and pulmonic valve insufficiency (more common if transannular patch is present). Evaluate for residual VSD, right ventricular outflow obstruction and dysfunction.

Tetralogy of Fallot with Pulmonary Atresia



Anatomy

This is an extreme variation of Tetralogy of Fallot and includes the 4 characteristic cardiac anomalies; malalignment type VSD, pulmonary stenosis, overriding aorta and right ventricular hypertrophy. But the coexistence of pulmonary atresia poses additional therapeutic challenges. There is no anatomic connection between the right ventricle and the pulmonary artery, and complete obliteration of the distal portion of the right ventricular - pulmonary outflow tract. The complexity of this lesion is dependent on the anatomy of the pulmonary circulation. There are four anatomic pulmonary subgroups.

Group I - The main, right and left pulmonary arteries are well developed, and the blood flow is supplied by a large PDA.

Group II - The main PA is absent. The right and left pulmonary arteries are well developed, and blood flow is supplied by a large PDA.

Group III - The ductus is either absent or very small. Both left and right pulmonary arteries are diminutive or hypoplastic. The major source of pulmonary blood flow is supplied by aorto pulmonary collaterals (APCAS).

Group IV - There are no true pulmonary arteries. Pulmonary blood flow is supplied entirely by APCAs.

Physiology

Since there is no blood flow from the right ventricle into the pulmonary artery, there is by force, an obligatory right to left shunting of all right ventricular blood through the VSD and into the aorta. Pulmonary blood flow is completely dependent on either a patent ductus arteriosus and/or aorto pulmonary collateral circulation. In TOF-PA with a ductus dependent circulation, closure of the duct can lead to rapid hypoxemia, acidosis and death during the neonatal period.

Preop

Closely monitor for 'TET spells' which may lead to hypoxemia and acidosis. Symptoms depend on the amount of shunting, the size of the PDA and branch pulmonary arteries and/or the APCAs.

Surgery

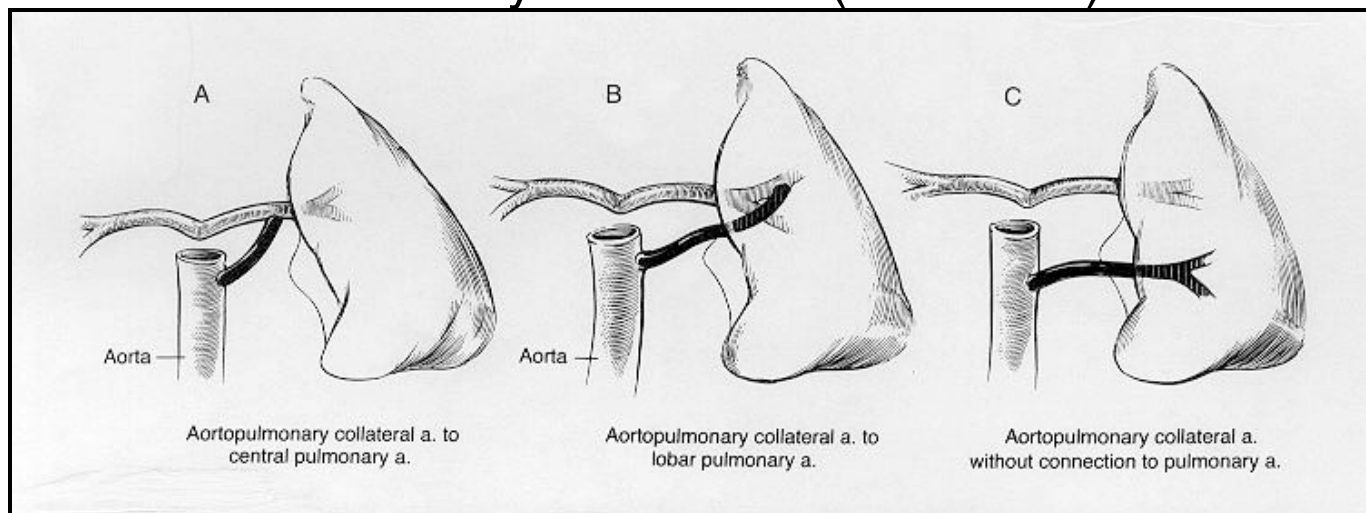
Palliative - If the pulmonary arteries are extremely small, a modified Blalock Taussig Shunt is performed to provide a reliable source of pulmonary blood flow until the infant grows and a corrective operation can be performed. If the neonate has small branch pulmonary arteries, a patch or homograft is placed across the RVOT and/or pulmonary valve annulus. The VSD is left open because it is unable to carry right ventricular output. The VSD is closed in a later operation.

Corrective - Surgical repair is via a median sternotomy incision and cardiopulmonary bypass is utilized. The ductus arteriosus is ligated if patent. The large malaligned VSD is closed with a Dacron patch and the RVOT is reconstructed. A patch is placed across the RVOT or, if necessary, a homograft conduit is placed between the right ventricle and pulmonary artery. Occasionally the PFO is left open as a 'pop off' for patients with borderline RV function.

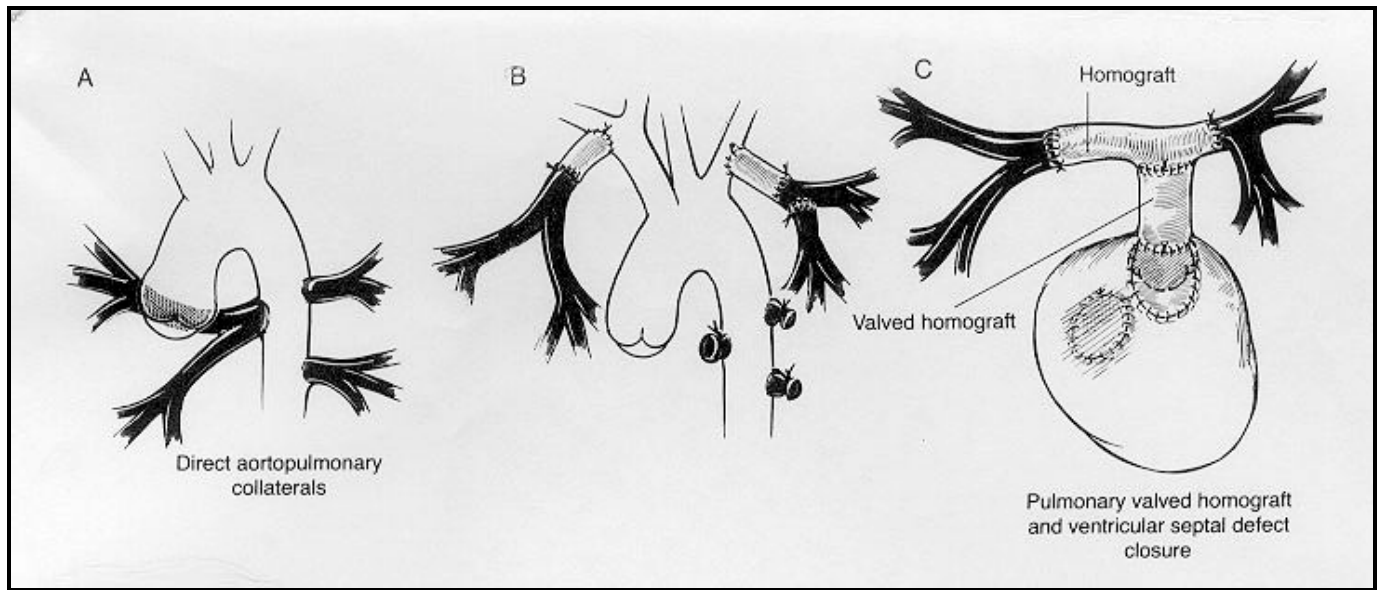
Post op

Complications include dysrhythmias; RBBB, tachycardia and junctional ectopic tachycardia (JET), right ventricular dysfunction, and pulmonic valve insufficiency (more common if transannular patch is present).

Tetralogy of Fallot with Pulmonary Atresia & Major Aorto-Pulmonary Collateral's (MAPCA'S)



- Anatomy** Tetralogy of Fallot with Pulmonary Atresia and MAPCA's is also referred to as Pulmonary Atresia with VSD and MAPCA's. This defect is a rare and complex lesion. The main, right, and left pulmonary arteries maybe hypoplastic. Blood flow to all bronchopulmonary segments is supplied solely by the major aortoplumony collaterals. MAPCA's may (1) connect outside the lung with central pulmonary arteries, (2) connect within the lung with lobar or segmental pulmonary arteries or (3) not connect with any pulmonary arteries but supply the lung independently. Approximately 60% of MAPCA's have some stenosis or obstruction.
- Physiology** Since there is no blood flow from the right ventricle to the pulmonary artery, there is an obligatory right to left shunting of blood through the VSD and into the aorta. Pulmonary blood flow is provided by the major aorto pulmonary collaterals. If the MAPCA's are unobstructed, the neonate or infant may have CHF due to a high volume of pulmonary blood flow.
- Preop** Diagnosis is made by cardiac catheterization and echocardiography. The aortopulmonary collaterals are identified and carefully examined. Details on size, number, course, origin, hemodynamics and morphologic characteristics, need to be mapped out for the surgeon. Significant effort is directed toward identifying the native pulmonary arteries which can range from normal size to complete absence. If diagnosis is made in the neonatal period, timing of surgery is between 3-6 months. If the diagnosis is made later, surgery is performed at the time of diagnosis. The surgical goal is to reconstruct the pulmonary arteries and separate the pulmonary and systemic circulations.
- Surgery** The type of surgical procedure depends on the specific individual anatomy. The overall goal of surgery is to perform a single stage complete repair, although this is not always possible. There are three surgical options.
One Stage Complete Repair with VSD Closure: Unifocalization of all MAPCA's, placement of a RV-PA conduit (homograft) and closure of the VSD. A median sternotomy incision is performed. The right and left pleura are opened and all the collaterals are identified, ligated one by one, and via anastomosis of collateral to collateral, the pulmonary arteries are 'unifocalized'. Tissue to tissue anastomosis is done via side to side, end to end, or end to side suturing. To decrease the adverse effects of prolonged bypass time, as many collaterals as possible are unifocalized prior to bypass. The pulse ox decreases as each collateral is taken off, thus the patient is placed on bypass. When true branch PA's are present, the MAPCA's are anastomosed to the PA's. Upon completion of the unifocalization, a homograft valved conduit is tailored to connect the right ventricle to the reconstructed 'unifocalized' pulmonary artery system. A flow study to measure PVR is done in the operating room. The VSD is closed if the PVR is measured to be low enough. Important concepts to assure a successful outcome include, aggressive mobilization of the collaterals, maximizing the length of the collaterals and flexibility regarding creative rerouting and reconstruction.



Complete Unifocalization leaving VSD open: A median sternotomy incision is performed. Unifocalization of all MAPCA's, followed by placement of a RV-PA conduit (homograft) is done. The VSD is left open due to elevated pulmonary vascular resistance. The VSD is closed in a 2nd surgical procedure.

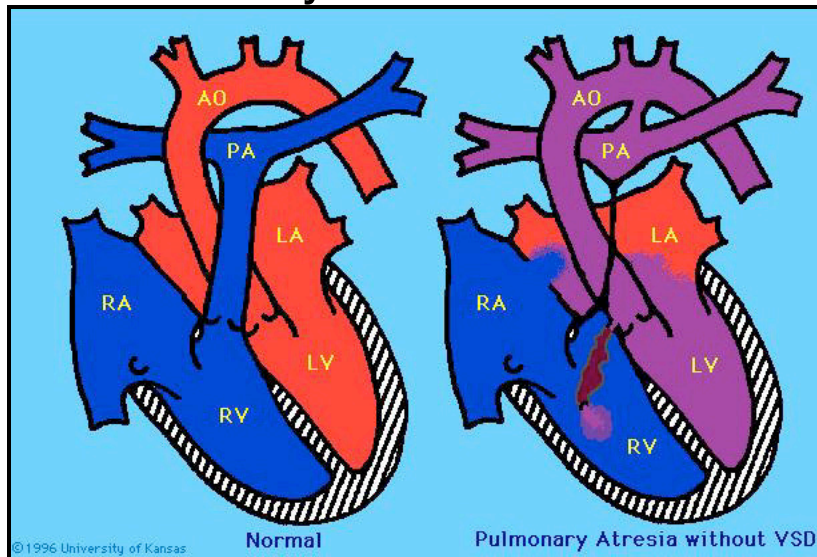
Staged Unifocalization: This approach may require multiple surgical procedures. The first surgery is via a thoracotomy incision and without the use of cardiopulmonary bypass. The MAPCA's which feed one lung are unifocalized. After three to six months, the patient is recatheterized and reevaluated for the next stage. The second surgery is via a thoracotomy incision and without the use of cardiopulmonary bypass. The MAPCA's which feed the other lung are 'unifocalized'. The third surgery is via a midline sternotomy and with cardiopulmonary bypass. Placement of a RV-PA homograft is accomplished and the VSD is closed.

Postop

Postoperative management following the unifocalization procedure is dependent on the patients individual anatomy, the type of surgical approach and subsequent length of cardiopulmonary bypass. Complications include:

- Right ventricular dysfunction; monitor for tachycardia, poor perfusion and high filling pressures (close observation of RA and RV pressures). Filling pressures >10 should raise concerns.
- Dysrhythmias; sinus tachycardia and junctional ectopic tachycardia (JET)
- Multisystem organ failure due to prolonged bypass time; monitor urine output and creatinine levels closely for signs of renal failure. Monitor LFT's and glucose closely for signs of liver failure. Obtain K+ levels every hour during initial 24hour postoperative period.
- Bleeding secondary to multiple suture lines; keep chest tubes patent, provide adequate sedation prior to noxious stimuli.
- Bronchospasm and tracheobronchomalasia

Pulmonary Atresia with I.V.S.



Anatomy

Pulmonary Atresia with an Intact Ventricular Septum (PA with IVS) includes a spectrum of defects that can include disorders of the tricuspid valve, right ventricle and coronary circulation. The term 'atresia' indicates failure of the pulmonary valve or pulmonary trunk vessel to develop, therefore there is no connection between the right ventricle and pulmonary artery. The pulmonary valve annulus may be very small or normal size. The main pulmonary artery may be well developed, absent or rudimentary. The right and left pulmonary arteries may be of normal size, or they may be extremely small. The size and structure of the RV is variable. The RV is usually extremely small (although can also be normal size), very hypertrophied, and the tricuspid valve is often stenotic and incompetent. The right atrium is enlarged and an ASD is present. Coronary artery anomalies are common.

Physiology

Systemic venous blood that enters the right heart quickly fills the right ventricle but has no outflow path. Regurgitation of blood into the right atrium increases right atrial pressure and shunts blood via a PFO or ASD, so that the systemic venous blood flows from the right to the left atrium and mixes with the pulmonary venous blood. The mixed blood enters the left ventricle and is ejected into the aorta. The entire pulmonary blood flow is supplied by the PDA. There must be a PDA and ASD to maintain mixing.

Preop

A continuous PGE infusion is initiated to maintain ductal patency and therefore maintain the infants only route of pulmonary blood flow. If flow is not adequate, a Rashkind balloon septostomy may be performed to enable better blood flow from the right to the left atrium. Correction and maintenance of acid-base balance, maintenance of adequate oxygenation and hemodynamic stabilization is essential. Cardiac catheterization may be needed to establish abnormalities in coronary circulation and presence of a fistula.

Surgery

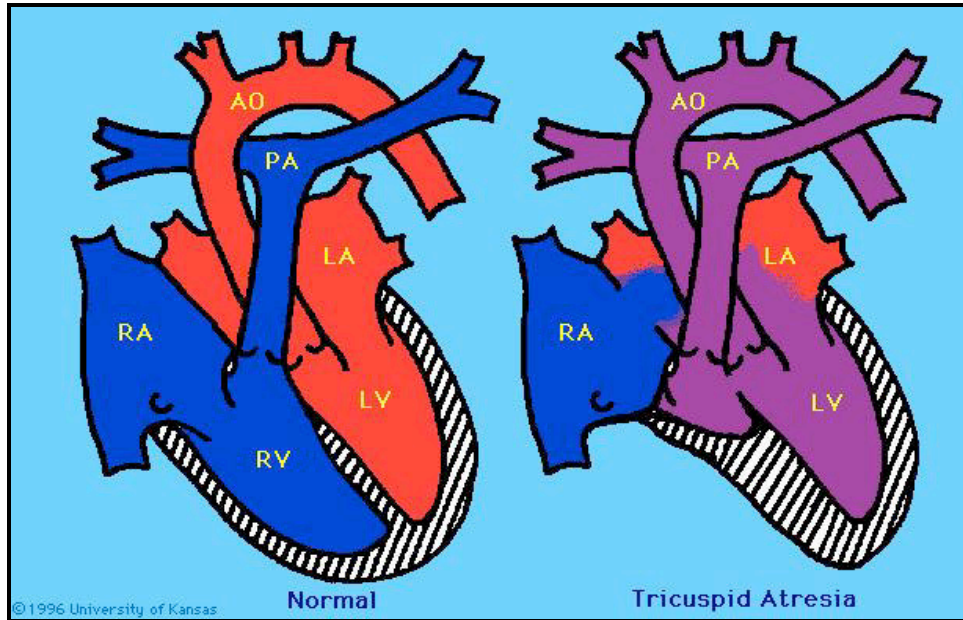
Palliative: The surgical procedure depends on specific anatomic variations. In the newborn period, the goal of surgery is to provide a reliable source of pulmonary blood flow. Even if RV to PA continuity can be provided by a surgical procedure, a Blalock-Taussig Shunt is almost always placed. The right ventricle is not normal, and the tricuspid valve is often hypoplastic, therefore a normal cardiac output cannot be delivered and a shunt is necessary to provide adequate pulmonary blood flow. A valvotomy is performed to establish continuity between the RV and the PA, allowing the RV to decompress and increase RV growth potential. If the RVOT is small, a patch is placed across the outflow tract to enlarge it. In patients with moderate to severe hypoplasia and inadequate RV development after palliative procedures, a staged Fontan procedure is considered the definitive operation.

Corrective: If the right ventricle, and right and left pulmonary arteries are of adequate size, total correction can be performed. A median sternotomy incision, cardiopulmonary bypass and hypothermia is utilized. A transannular patch or conduit is inserted between the right ventricle and the pulmonary artery. The ASD is closed.

Postop

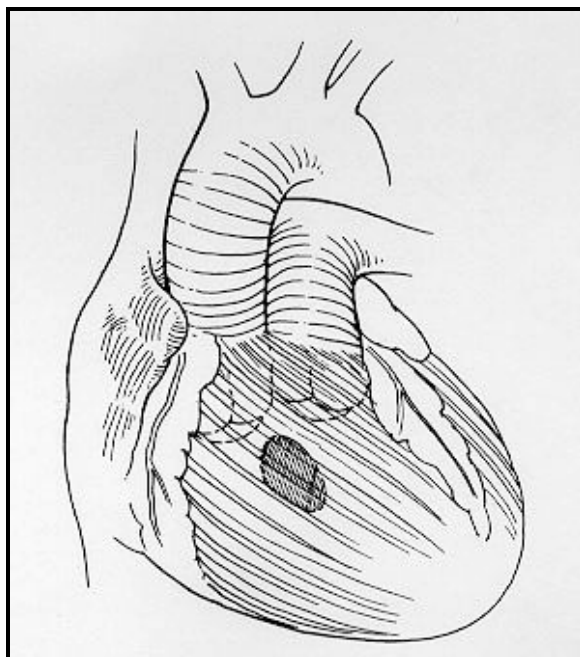
Careful assessment for symptoms of hypoxemia and decreased pulmonary blood flow after palliation is necessary to evaluate the effectiveness of the shunt and/or valvotomy.

Tricuspid Atresia



- Anatomy** Tricuspid atresia is the failure of development of the tricuspid valve, resulting in a lack of direct communication between the right atrium and the right ventricle. The floor of the right atrium is completely muscular. This defect is generally associated with a hypoplastic right ventricle and there is usually a ASD/PFO, VSD and/or PDA. Tricuspid atresia is often associated with some degree of right ventricular outflow tract obstruction.
- Physiology** Because there is no direct communication between the right atrium and the right ventricle, blood flow is across the atrial septum from right to left via a PFO or an ASD. This results in complete mixing of desaturated systemic venous blood and fully saturated pulmonary venous blood at the atrial level, which is then ejected by the left ventricle. The workload of the left heart is increased due to the volume overload. The oxygen saturation levels are equal in the aorta and the PA.
- Preop** Cyanosis is present and a continuous PGE infusion to maintain ductal patency and pulmonary blood flow is essential. A balloon atrial septostomy may be needed to maintain flow across the atrial septum.
- Surgery** The definitive procedure for patients with tricuspid atresia is to achieve a successful Fontan operation. This goal is performed in stages.
PALLIATIVE: Early palliation is done to provide a reliable source of pulmonary blood flow, improve arterial oxygen saturation and allow the infant to grow.
Modified Blalock-Taussig Shunt: This joins the subclavian artery to the right pulmonary artery (systemic to pulmonary shunt).
RECONSTRUCTIVE: Performed in two stages. Any type of correction requires that the patient's pulmonary vascular resistance be normal.
Glenn Shunt: This joins the superior vena cava to the right pulmonary artery.
Fontan: This joins the inferior vena cava to the pulmonary artery via a homograft conduit. The Fontan provides continuity between the SVC, IVC, RA, or some combination of these and the pulmonary arteries.
- Postop** The goal of post-operative care is to maintain the balance between systemic and pulmonary circulations.

Double Outlet Right Ventricle - DORV



Anatomy Double Outlet Right Ventricle (DORV) spans a wide spectrum of physiology from Tetralogy of Fallot to Transposition of the Great Arteries. DORV is a complex cardiac defect where both great vessels (aorta and pulmonary artery), either completely or nearly completely arise from the right ventricle. Most commonly they lie side by side in the same plane, and the aortic and pulmonary valves lie at the same level. A VSD is always present with DORV. The VSD may be subaortic, subpulmonary, or a combination of both. The classification of DORV is dependent on the location and type of VSD. The great vessels may be normally related or transposed. Some types of DORV have two adequately sized ventricles to allow a biventricular surgical repair. Other forms of DORV are associated with a severely underdeveloped left ventricle lending itself to a single ventricle pathway.

Preop Symptoms depend on anatomy and physiology. They range from CHF, cyanosis or no symptoms. DORV will never correct itself spontaneously, therefore, rather than medical management, surgery is done in the neonatal period.

Physiology The physiology is dependent on the specific anatomy. Because both vessels rise from the right ventricle, there must be a VSD present as an outlet for the left ventricle. In all forms of DORV, right ventricular hypertension and hypertrophy are present because the right ventricle ejects into both the PA and the aorta. The relationship between the VSD, the great arteries, the relative SVR and PVR determine the hemodynamics. Some amount of arterial desaturation is present. It is important to understand the patients individual anatomy in order to understand the physiology. The anatomy and physiology will determine the surgical procedure or repair. There are four main types of Double Outlet Right Ventricle.

1a. *DORV with subaortic VSD and without PS*: Most common type. Produces effects similar to those of a large VSD with pulmonary hypertension and CHF. The great vessels lie side by side, the VSD is located just below the aortic valve. There is no pulmonary stenosis. Oxygenated blood from the LV will flow through the VSD, directly into the aorta. Desaturated systemic venous blood is directed to the PA, thereby producing mild or no cyanosis.

Surgery: A median sternotomy and use of cardiopulmonary bypass is required. The VSD is closed so that the left ventricular outflow is diverted into the aorta. This creates an intraventricular tunnel between the VSD and the subaortic outflow tract and directs blood into the aorta.

1b. *DORV with subaortic VSD and pulmonary stenosis*: Results in physiology similar to that of Tetralogy of Fallot. If the PS is moderate to severe, the pulmonary blood flow is decreased and the systemic venous blood from the right ventricle enters the aorta in an amount proportional to the degree

of PS; the greater the stenosis, the greater the right to left shunt of blood into the aorta and the more cyanosis will be present.

Surgery: A median sternotomy and use of cardiopulmonary bypass is required. The PS is relieved by excision of the stenotic muscle, and a pulmonary valvotomy may also be performed. The VSD is closed, and an intrventricular tunnel is created between the VSD and the aorta. One or two patches may be used to enlarge the right ventricular outflow tract, minimizing residual pulmonic stenosis.

2. DORV with subpulmonic VSD (Taussig-Bing anomaly): Produces effects similar to those of Transposition of the Great Arteries. The VSD is closer to the pulmonary valve than to the aortic valve. Oxygenated blood from the LV flows into the PA through the VSD, and desaturated blood from the RV is directed to the aorta. Because of the large VSD and high degree of mixing, cyanosis may be absent and symptoms of CHF predominant.

Surgery: A median sternotomy and cardiopulmonary bypass is utilized. The VSD is closed, creating an intraventricular tunnel between the VSD and the PA. The correction of the transposition is done through an arterial switch procedure.

3. DORV with doubly committed VSD: The VSD is closely related to both semilunar valves. Blood flows into the aorta and the PA and a mild degree of cyanosis is present.

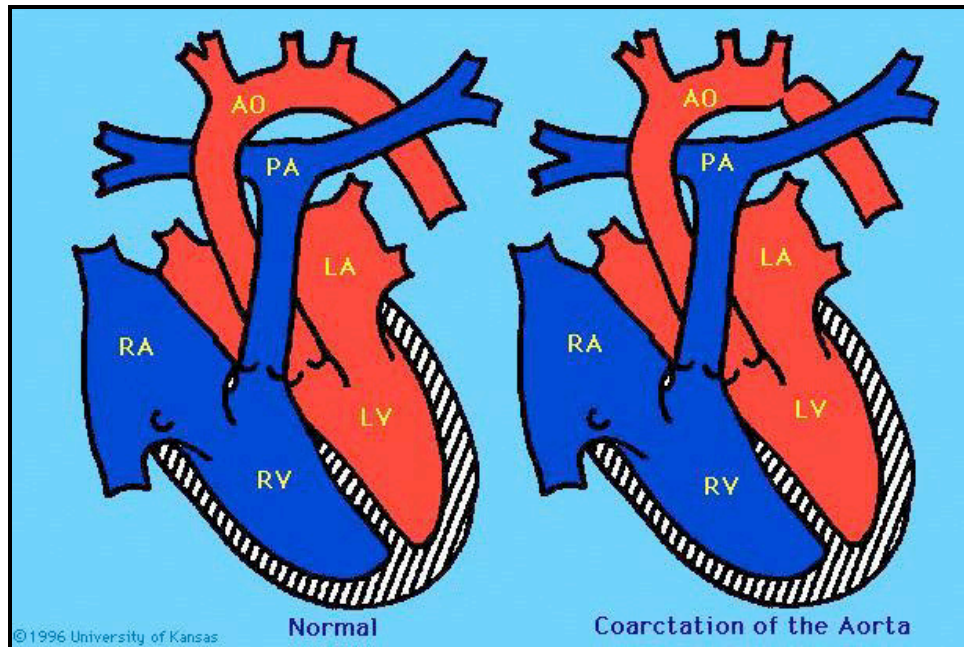
4. DORV with remote VSD: Produces effects similar to those of AV Canal. The VSD is not close to the aorta or PA. The VSD is isolated and occasionally muscular.

Surgery: For both doubly committed VSD and remote VSD types of DORV, staged management to an eventual Fontan operation should be considered.

Postop

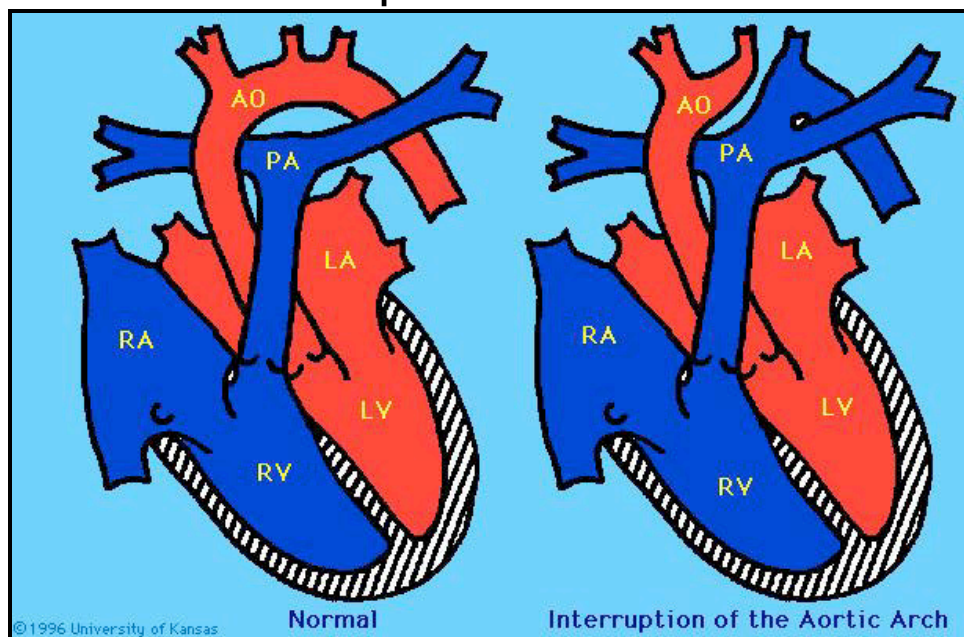
Depends on the specific anatomy, physiology, surgical procedure and if a single or biventricular repair was done.

Coarctation of the Aorta



- Anatomy** Coarctation of the aorta is a narrowing in the aortic arch. The coarctation may occur as a single lesion, as a result of improper development of the involved area of the aorta, or as a result of constriction of that portion of the aorta when the ductus arteriosus constricts. The coarctation is most often located near the ductus arteriosus; if narrowing is proximal to the ductus it is 'pre-ductal', if it is distal to the ductus it is 'post-ductal'.
- Physiology** Aortic narrowing increases resistance to flow from the proximal to the distal aorta. As a result, pressure in the aorta proximal to the narrowing is increased and pressure in the aorta distal to the narrowing is decreased. Collateral circulation can develop in older children and adults to maintain adequate flow into the distal descending aorta.
- Preop** Neonates and infants may present in shock when the ductus arteriosus closes. PGE must be started immediately to maintain ductal patency and surgery should be scheduled upon diagnosis. Some older children that present with CHF are maintained on digoxin and diuretics, and may be candidates for balloon dilation. Significant hypertension may also be seen, requiring anti-hypertensive therapy. A difference in blood pressure between upper and lower extremities helps identify this defect.
- Surgery** For isolated coarctation repair a left thoracotomy incision is performed. A median sternotomy incision is utilized when repaired along with associated defects. The aorta must be cross-clamped during coarctation repair. The narrowed segment is excised and the distal segment of the aorta is usually anastomosed to the side of the aortic arch. Occasionally a graft is necessary to patch the aorta.
NOTE: Coarctation of the aorta may also be associated with a VSD and/or other left sided lesions, or part of more complex defects.
- Postop** Postoperative management is aimed at controlling hypertension (more common in older children), to prevent undue stress and bleeding to the suture line. Control of postop pain and agitation are also important in maintaining an appropriate blood pressure. Afterload reducing agents may be required. 'Post coarctectomy syndrome' is a postoperative condition related to inadequate blood flow during aortic cross clamp, and/or introduction of pulsatile flow and subsequent vessel injury following repair. Symptoms include extreme abdominal pain and/or distention. Neonates are usually kept NPO for 48^o following surgery. A thorough assessment of lower extremity movement to rule out spinal cord ischemia following aortic cross clamp should be performed. Residual coarctation is postoperatively evaluated via right arm and lower extremity blood pressures (gradient >20mmHg may be significant).

Interrupted Aortic Arch



Anatomy

Interrupted Aortic Arch (IAA) refers to the congenital absence of a portion of the aortic arch. There are three types of IAA, and they are labeled according to the site of the interruption. IAA is always associated with a PDA and almost always with a VSD. Other cardiac defects may also be present.

Type A: The ascending aortic arch is intact. The interruption occurs just distal to the left subclavian artery (the isthmus of the arch).

Type B: The aorta is interrupted between the left carotid and the left subclavian artery, as a result the left subclavian artery arises from the descending aortic segment. This type is the most common.

Type C: The aorta is divided between the innominate and the left carotid arteries. This type is extremely rare.

Physiology

The ascending aorta receives blood from the left ventricle. The right ventricle perfuses the descending aorta through the ductus arteriosus. The infant will become acidotic and anuric when the ductus arteriosus closes. Ischemia to the liver, bowel and kidneys will occur. Profound ongoing acidosis will result in multi-system failure.

Preop

Signs and symptoms appear when the PDA begins to close. PGE must be initiated immediately to maintain ductal patency and lower body perfusion until surgery can be performed. Lower body perfusion is partly dependent on pulmonary vascular resistance (PVR) because of ductal dependency. A difference in blood pressure between upper and lower extremities helps identify this defect.

Surgery

A single stage neonatal complete repair is done via a median sternotomy incision, cardiopulmonary bypass, and circulatory arrest. A thoracotomy incision may also be utilized with type A & B repairs. The two separate portions of the aortic arch are reconstructed with or without patch augmentation in an end-to-side fashion.

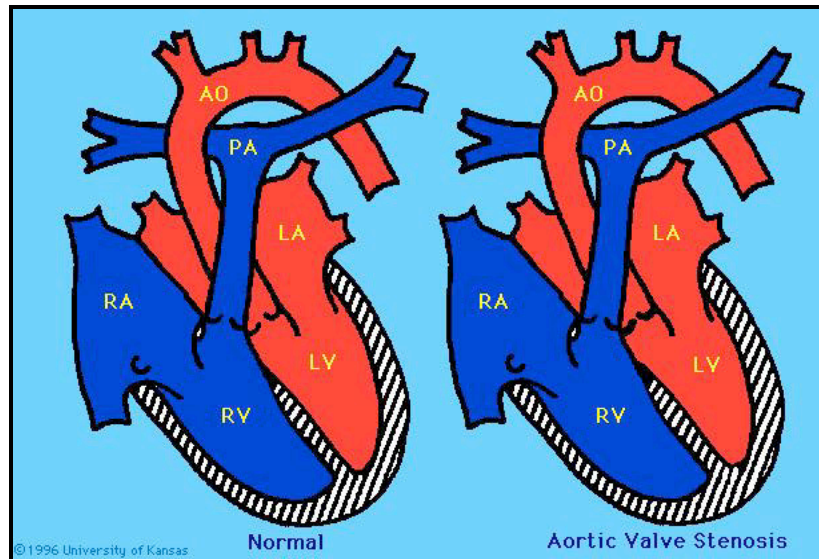
The VSD is closed.

NOTE: Nearly half of affected infants have additional non-cardiac anomalies, and 50% of infants with Interrupted Aortic Arch have Di George Syndrome.

Postop

Postoperative issues include low cardiac output related to myocardial dysfunction, and cerebral ischemia related to circulatory arrest. Closely monitor for bleeding related to extensive suture lines and fragile aortic tissue. Avoid systemic hypertension. Risk or damage to the left recurrent laryngeal and phrenic nerves is possible (watch for respiratory failure following extubation). Infants may require Ca^{+} supplement in the postoperative period secondary to Di George Syndrome. Residual arch obstruction following repair may require surgical re-intervention.

Aortic Stenosis



Anatomy

Aortic Stenosis (AS) is a narrowing that obstructs blood flow from the left ventricle, leading to left ventricular hypertrophy and/or aortic insufficiency. AS may be mild, moderate, or severe. When this condition presents in neonates, it is referred to as 'critical aortic stenosis'. There are three types of AS, classified according to the location of the stenotic area:

Valvar: Failure of the cusps to separate, creating fusion of the valve, or presence of a bicuspid valve instead of tricuspid. Accounts for 80% of AS.

Subaortic: Caused by the formation of a fibrous ring with a narrowed central orifice below the aortic valve. It may be discrete or diffuse and in infants is seen as a component of a more complex lesion.

Supravalvar: Caused by a fibromembranous narrowing of the aorta above the aortic valve and coronary arteries. Associated with Williams Syndrome.

Physiology

Whenever there is obstruction to the left ventricular outflow tract, the left ventricle will generate greater pressure to maintain flow beyond the area of resistance. As a result, left ventricular hypertension that is proportional to the degree of aortic obstruction develops, and systemic cardiac output may be compromised. Left ventricular hypertrophy, aortic insufficiency, and failure can develop.

Preop

Children are often managed on digoxin and diuretics for CHF. It is important to note, aortic stenosis is a progressive disease that requires serial evaluation. For neonates with 'critical aortic stenosis' a PGE continuous infusion should be started, as a patent ductus provides an increase in cardiac output by right to left shunting.

Surgery

The treatment for each form of aortic stenosis is somewhat different and depend on the severity of the obstruction, anatomy of the aortic valve and age of patient. It may include observation, balloon valvuloplasty and/or surgery. The goal of surgical intervention is relief of the aortic obstruction without creating a compromising degree of aortic insufficiency.

Valvar: For isolated AS, a surgical valvotomy is performed. For AS with insufficiency, a aortic valvuloplasty is performed. For AS with insufficiency and a bicuspid valve, an aortic valve replacement (Ross procedure) may be done. These all require a median sternotomy incision and use of cardiopulmonary bypass.

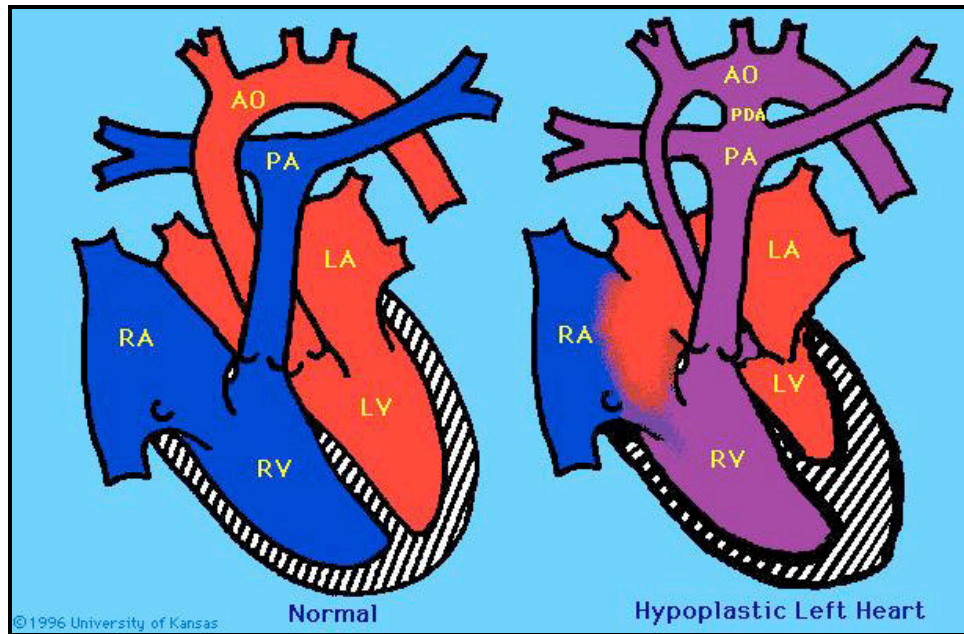
Subaortic: The subvalvular obstruction is resected through the aortic valve. If the stenosis is caused by a fibromuscular ring it is removed. The Konno procedure is required if obstruction is diffuse.

Supravalvar: Via a median sternotomy incision and the use of CPB, excision of the stenosed area is performed. If extensive narrowing is present, the aorta will be enlarged with a patch to increase the aortic diameter.

Postop

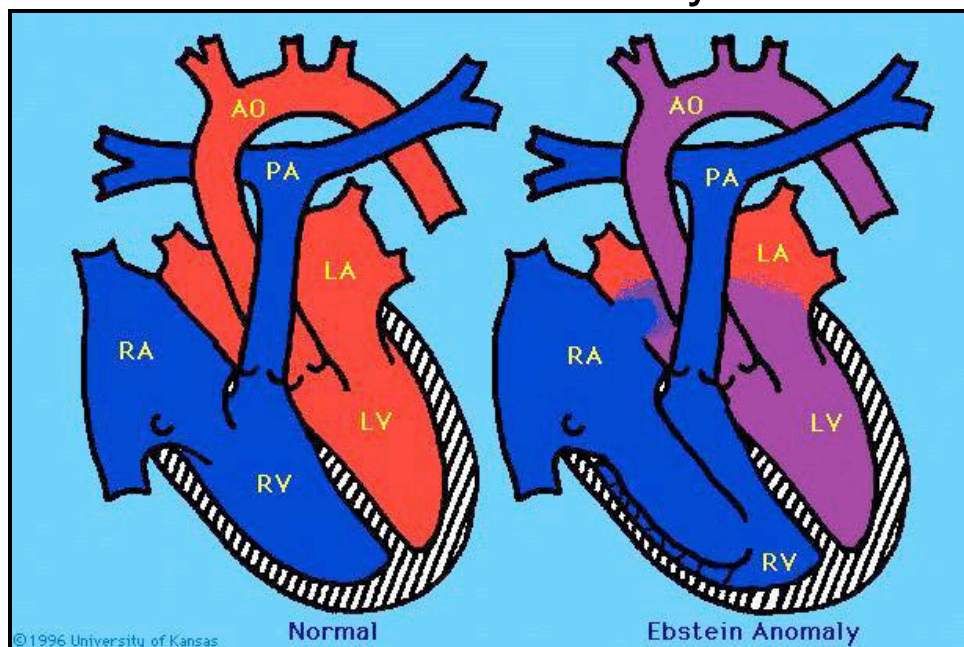
Postoperative issues include persistent stenosis, restenosis of the aortic lumen and insufficiency of the aortic valve. Aortic insufficiency is most often evidenced as the child matures, and valve replacement may be required. When extensive muscle is removed from the left ventricular outflow tract, left ventricular dysfunction and failure can develop.

Hypoplastic Left Heart Syndrome



- Anatomy** Hypoplastic Left Heart Syndrome (HLHS) is identified as a small, underdeveloped left ventricle usually with aortic and/or mitral valve atresia or stenosis and hypoplasia of the ascending aorta. A large ductus arteriosus is present. The right ventricle is dilated and hypertrophied, and an atrial septal defect is present. The entire systemic output is dependent on flow through the ductus arteriosus. This is a devastating diagnosis.
- Physiology** Because of its small size, the left ventricle is incapable of supporting the systemic circulation. Since outflow from the LV is either severely limited or absent, the systemic circulation must depend on mixed blood flow from the pulmonary artery through the PDA. The foramen ovale stays open and left to right shunting occurs. The neonate's right ventricle supports both pulmonary and systemic circulations. The PDA supplies the descending aorta with antegrade flow and the aortic arch with retrograde flow to the coronary circulation. Survival beyond birth is dependent on persistent patency of the ductus arteriosus to maintain systemic circulation.
- Preop** Immediate therapy is directed at restoring hemodynamic stability, management of CHF and correction of metabolic acidosis. PGE as a continuous infusion is started to maintain ductal patency.
- Surgery** This lesion is fatal without surgical intervention. Treatment options include reconstructive surgery (Norwood procedure), heart transplantation or comfort care. Reconstructive surgery is aimed at converting the cardiac anatomy from that of hypoplastic left heart syndrome to Fontan physiology.
Stage I Norwood: The goals of the 1st stage Norwood palliation are to provide adequate blood flow to the lungs and allow the single ventricle to pump mixed blood to the body, with the goal of later surgery to separate the systemic and pulmonary circulation.
Bi-directional Glenn: The Glenn Shunt is the 1st stage in separating the circulations. The superior vena cava is anastomosed to the right pulmonary artery.
Fontan: The goal of the Fontan is to complete systemic and pulmonary venous blood separation, and divert more systemic venous blood flow directly into the pulmonary circulation (to reduce the workload of the right ventricle). The inferior vena cava is joined to the pulmonary artery via a homograft conduit.

Ebstein's Anomaly



Anatomy

Ebstein's anomaly is a rare congenital defect of the tricuspid valve. The tricuspid valve leaflets do not attach normally to the tricuspid valve annulus. The leaflets are dysplastic and the septal and posterior leaflets are downwardly displaced, adhering to the right ventricular septum. The tricuspid valve may be incompetent or, less commonly, stenotic. The portion of the right ventricle above the valve leaflets becomes "atrialized", and as a result, right ventricular size is compromised and the right atrium is enlarged. There is always a patent foramen ovale or atrial septal defect. Ebstein's Anomaly presents one of the widest anatomic, physiologic, and symptomatic spectra of all congenital heart anomalies.

Physiology

The "atrialized" portion of the right ventricle may appear to be relatively normal myocardium, or may be extremely thin with little ability to contract. The function of the tricuspid valve varies widely. Abnormal leaflets result in tricuspid insufficiency or stenosis leading to ineffective blood flow through the right heart. Right atrial pressure is elevated and right to left shunting of blood occurs through the patent foramen ovale or atrial septal defect. Cyanosis is present.

Preop

Symptoms and management of the patient with Ebstein's anomaly varies significantly depending on the anatomy and physiology. Neonates who present may be ductal dependent for pulmonary blood flow. A continuous PGE infusion to maintain ductal patency may be needed. Older children with mild cyanosis may be managed symptomatically. Surgery is indicated for those patients with CHF, severe cyanosis or dysrhythmias.

Surgery

Surgical options depend on the specific anatomic features and the severity of ventricular dysfunction. When dysfunction is severe, a single ventricle palliative procedure may be performed. When ventricular function is good, a bi-ventricular repair with attempt to repair the tricuspid valve may be performed.

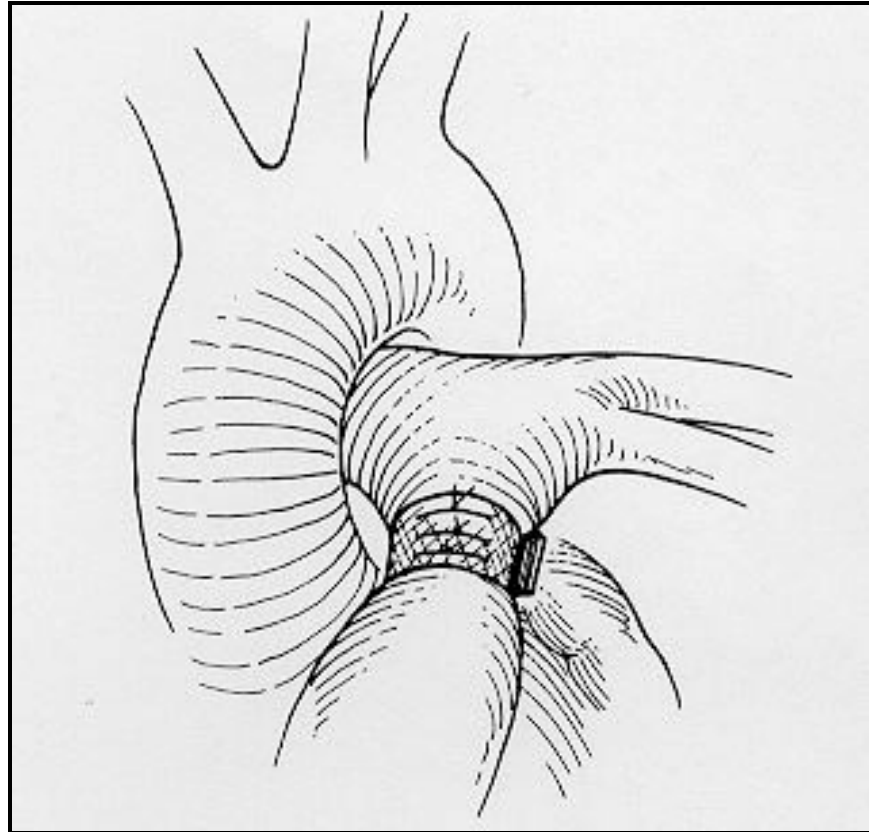
Palliative: Plication of right atrial tissue, atrial septectomy, insertion of an aortapulmonary shunt, and patch closure of the tricuspid valve annulus (thus surgically creating tricuspid atresia) is performed. This commits the neonate to future single ventricle palliations (bi-directional Glenn Shunt and /or Fontan)

Tricuspid Valvuoplasty: Through a median sternotomy incision and the use of CPB, the ASD is closed. Plication of the atrialized portion of the right ventricle and repair of the tricuspid valve, freeing it from the abnormal right ventricular attachments, is performed. Plication of the atrialized portion is accomplished through the insertion of sutures in the area of normal valve rings, the sutures are pulled together to pull the valve leaflets toward their normal position. A valvuloplasty is then performed to insure satisfactory tricuspid valve function. Replacement of the tricuspid valve may also be an option.

Postop

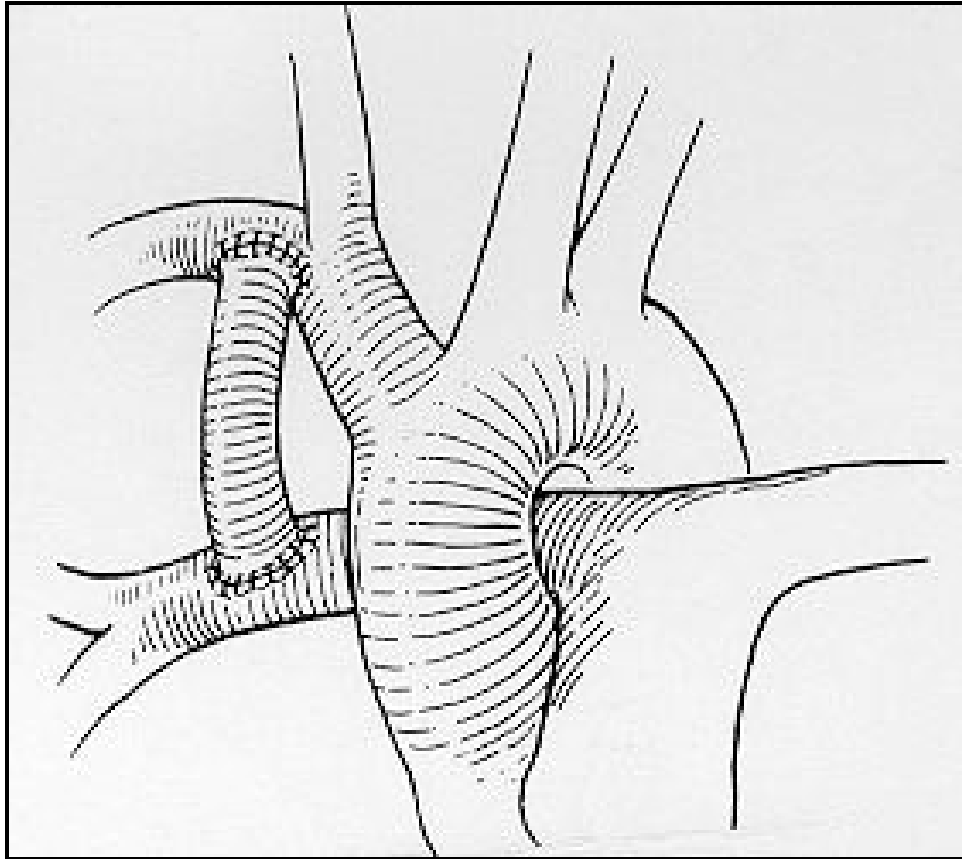
Closely monitor for low cardiac output, as tricuspid regurgitation leads to RV dilation and the LV may not adequately fill to provide sufficient cardiac output. Use volume judiciously. Closely monitor for dysrhythmias; SVT, V-tach and heart block.

Pulmonary Artery Banding



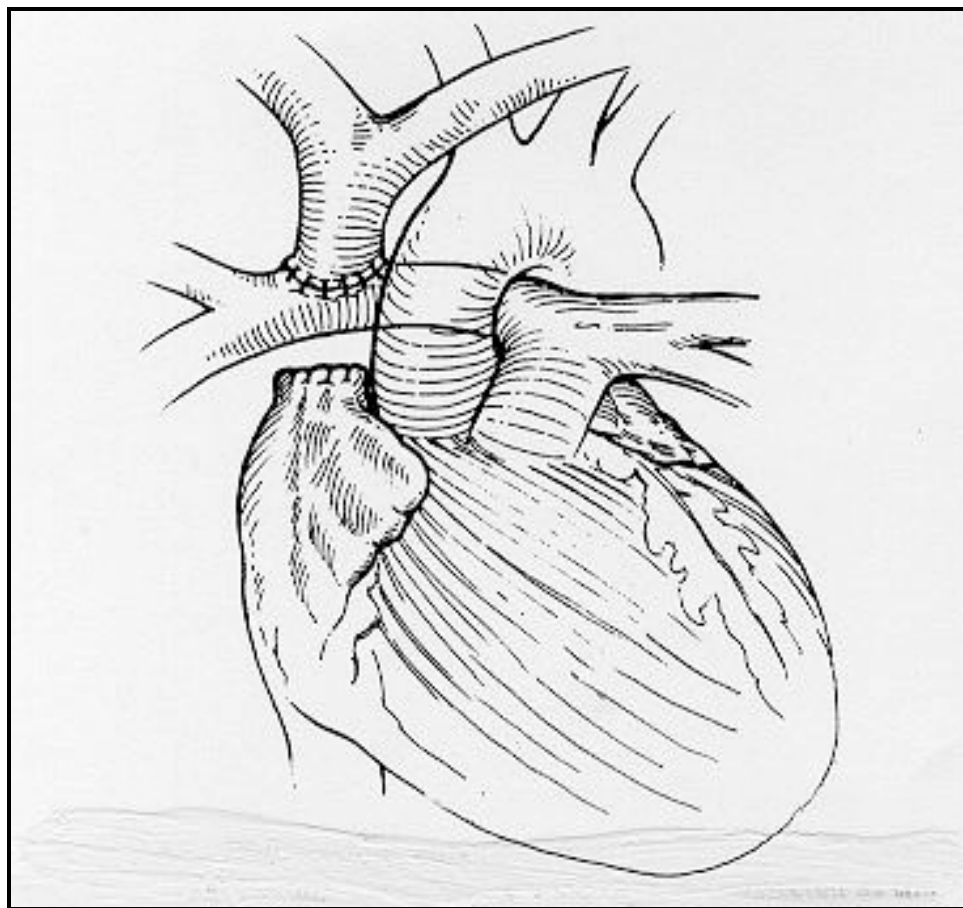
- Indications** This procedure is used as palliation for complex congenital heart defects with excessive pulmonary blood flow. Pulmonary artery banding is also used to prepare the left ventricle for increased afterload before the arterial switch correction in older patients who have had Senning or Mustard repairs.
- Surgery** Accomplished by means of a thoracotomy or sternotomy incision and does not require use of cardiopulmonary bypass. This surgery may be performed as part of a more complex procedure when cardiopulmonary bypass is utilized. A strip of woven prosthetic material is passed around the main pulmonary artery and used to constrict the artery. This procedure is used to reduce the volume of pulmonary blood flow, improve systemic blood flow, and protect the lungs from developing pulmonary vascular disease.
- Postop** Monitor for inadequate pulmonary blood flow (band too tight), by noting persistent decreased oxygen saturation's and increased systemic output. Monitor for excessive pulmonary blood flow (band too loose), by observing for increased oxygen saturation's and decreased systemic output. Right ventricular failure from increased afterload resistance can occur.

Blalock-Taussig Shunt



- Indications** Blalock-Taussig (B-T) Shunt placement is usually done in the first month of life. This is a palliative surgery aimed at improving pulmonary blood flow. This allows the infant to grow so a more definitive surgery can be performed. This procedure can be performed in isolation or as part of a more complex reconstruction, as with the 'Norwood procedure'.
- Surgery** A median sternotomy or a right thoracotomy incision is used. Cardiopulmonary bypass is typically not necessary, but is utilized when performed with a more complex operation. Synthetic material is sewn between the right subclavian artery and the right pulmonary artery. This procedure may result in 'steal' of subclavian blood flow into the pulmonary artery, but does not require sacrifice of the subclavian artery. The Blalock-Taussig Shunt allows for systemic arterial blood from the aorta to flow through the shunt into the pulmonary artery, resulting in a more reliable source of blood flow. Graft size (typically 3.0-4.0mm) is chosen to create an appropriate resistance so that the systemic and pulmonary blood flows will be balanced following the procedure. Blood flow through the shunt into the pulmonary blood flow is regulated by the graft diameter itself, and also by the proximal anastomosis position. If the proximal anastomosis is placed more centrally (on the ascending aorta, 'central shunt'), increased pulmonary blood flow will be achieved.
- Postop** Monitor for the balance of systemic and pulmonary circulation's in patients with single ventricle physiology. An acceptable balance between the pulmonary and systemic output provides enough PBF for adequate oxygen delivery to prevent acidosis without an excessive volume load to the single ventricle.
- Observe for symptoms of inadequate pulmonary blood flow related to a decrease in shunt patency (increase cyanosis, acidosis).
 - Observe for symptoms of excessive pulmonary blood flow and therefore inadequate systemic blood flow (decrease cardiac output, hypotension, metabolic acidosis, decreased urine output).
 - Closely monitor for atelectasis, pleural effusion and chylothorax.
 - Monitor for injury to the phrenic nerve; difficulty weaning from the ventilator, diaphragm up on affected side.
 - Pulses may be diminished postoperatively on shunt side.

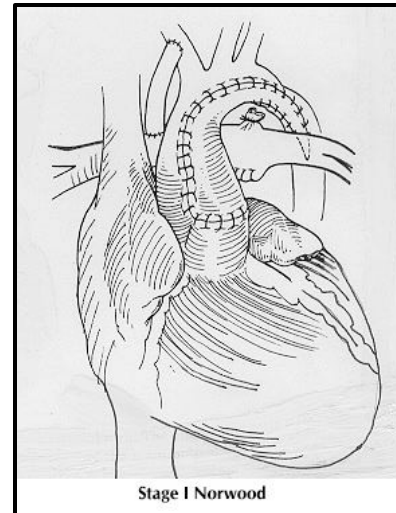
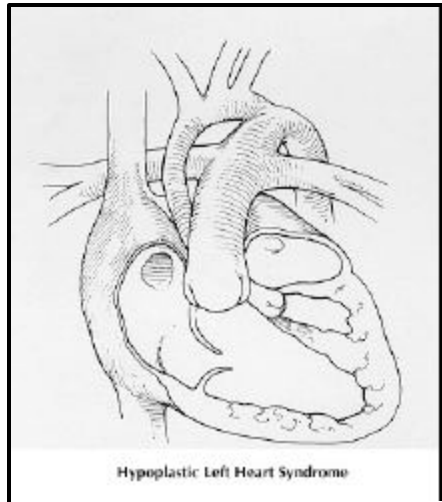
Bi-directional Glenn Shunt



- Indications** The Bi-directional Glenn procedure is the initial step in preparation for the Fontan operation for patients with single ventricle physiology. The eventual goal is to separate the systemic and pulmonary circulations. This operation is done at 6 months of age, although may be done earlier if cardiac function is poor or infant is desaturated.
- Surgery** The Bi-directional Glenn procedure is usually performed on cardiopulmonary bypass. The superior vena cava is ligated from the right atrium and anastomosed (end to side) to the right pulmonary artery. The right pulmonary artery is not separated from the pulmonary artery trunk therefore the branch pulmonary arteries are continuous. Superior vena cava flow is bi-directional providing venous blood flow from the head, neck and upper extremities to the right and left lung. When a left and right superior vena cava are present a bilateral Bi-directional Glenn procedure is performed.
- Postop** Postoperative management is aimed at promoting passive pulmonary blood flow and maintaining low pulmonary vascular resistance.
- Monitor for superior vena cava syndrome; facial and upper extremity edema and cyanosis. These patients may have obstruction at the anastomosis, distal PA distortion, or elevations in PVR (decreases PBF through Glenn). Significant elevations of pressure in the SVC can limit cerebral blood flow.
 - Maintain atrial pressure 6-8 during initial postop period.
 - Elevate HOB immediately upon arrival to promote passive venous drainage from the head and upper body to the lungs.
 - Avoid elevations in pulmonary venous return (PVR), as elevated PVR impedes the forward flow of blood through the pulmonary circulation and therefore decreases systemic cardiac output.
 - Monitor for inadequate pulmonary blood flow (increase in cyanosis, acidosis, hypoxemia).
 - Monitor for transient postoperative hypertension and bradycardia.
 - When hemodynamically stable and there is no evidence of bleeding, the patient can be rapidly weaned from the ventilator and extubated.
 - Closely monitor for atelectasis, pleural effusion and chylothorax.

- Neck lines should be avoided to prevent SVC thrombus formation.

Norwood



Surgery

Stage I Norwood - This is the first stage in the reconstructive repair for Hypoplastic Left Heart Syndrome, usually done in the first week of life. The goals of this procedure are to insure an effective route of systemic blood flow, and to provide a controlled volume of pulmonary blood flow.

The ductus arteriosus is ligated. The main pulmonary artery is transected and detached from the central and branch pulmonary arteries. The hypoplastic aorta is then opened and a patch of pulmonary artery homograft is used to reconstruct and enlarge the ascending aorta. The 'reconstructed' aorta is then connected to the trunk of the previously transected pulmonary artery. This creates a single great vessel that provides systemic blood flow. A right modified BT shunt is placed to provide pulmonary blood flow. An atrial septectomy is then done to insure mixing of blood between the left and right atrium.

Physiology

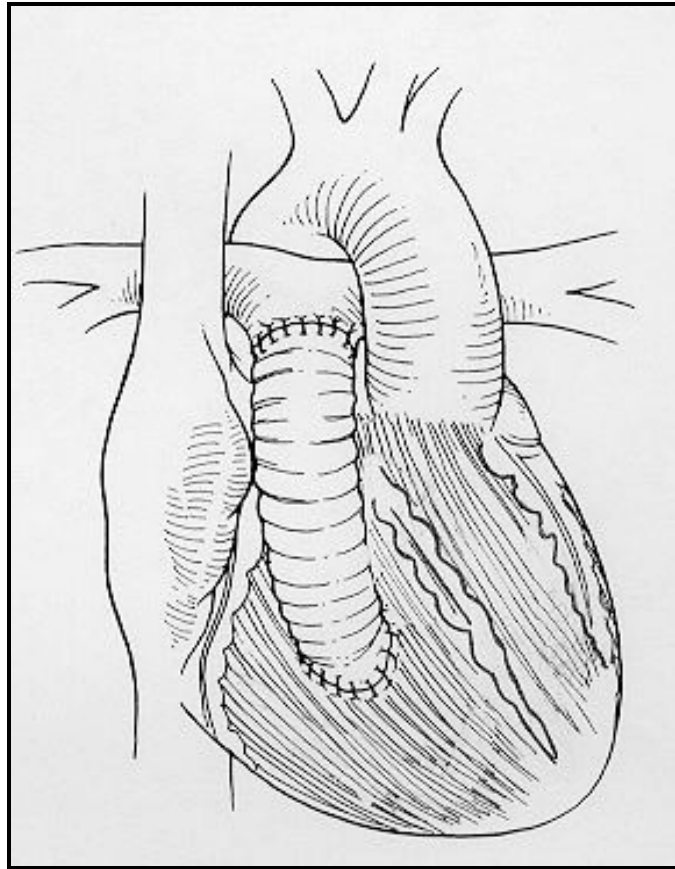
The right ventricle receives systemic and pulmonary venous blood and ejects that blood through the pulmonary valve into a reconstructed aorta, and out to the systemic circulation. Pulmonary blood flow occurs through the modified Blalock-Taussig shunt. Saturated pulmonary venous blood returns to the left atrium and crosses the open atrial septum and mixes with desaturated blood in the right atrium. This mixed blood passes through the tricuspid valve and into the right ventricle and out through the aorta and to the body.

Postop

In the initial 24 - 48 hours postoperatively it is critical to maintain the balance of systemic and pulmonary circulations. An acceptable balance between the pulmonary and systemic output provides enough PBF for adequate oxygen delivery to prevent acidosis without an excessive volume load to the single ventricle.

- Assess for excessive PBF; elevated O₂ saturations (>90%) can result in inadequate systemic perfusion and renal dysfunction.
- Assess for inadequate PBF; optimize PBF by providing adequate sedation (relaxes pulmonary beds), maintaining balanced fluid status and hematocrit level between 45-50.
- Assess for low cardiac output; tachycardia, hypotension, decreased urine output and metabolic acidosis. The effect of myocardial ischemia from aortic cross clamping can lead to decreased cardiac output in the first 12 - 24 hours postoperatively.
- Advanced preparation for Tx of acute hypotension and cardiac arrest (dwindle dose epi, CaCl at bedside).
- Assess for neurologic complications secondary to circulatory arrest.
- Absolutely no air can be allowed to enter any I.V. lines (may shunt into the cerebral or coronary circulation).
- Dysrhythmias

*** See bedside book: *postoperative care of infants with single ventricle physiology*



Rastelli

Indications The Rastelli operation is a combination of intraventricular repair and placement of an extracardiac right ventricular-to-pulmonary artery conduit. It is performed on infants born with D-TGA with VSD and Left Ventricular Outflow Tract Obstruction (Arterial Switch not possible) and for DORV with subpulmonary stenosis. This operation achieves complete bypass of the LVOTO and an anatomic correction of the transposition.

Surgery Surgery is accomplished via a median sternotomy incision and cardiopulmonary bypass. The main pulmonary artery is divided from the left ventricle. An intracardiac tunnel is placed between the large VSD and the aorta so that the left ventricle communicates with the aorta. The right ventricle is connected to the main pulmonary artery via a conduit. This approach requires a sizeable VSD, appropriately located so that a patch can be placed that will redirect the left ventricular outflow into the aorta.

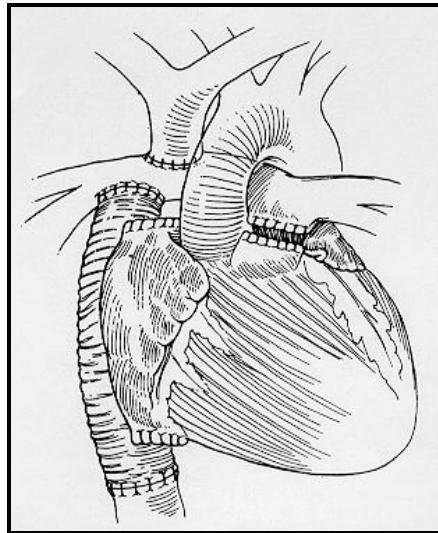
Damus-Kaye-Stansel

Indications The Damus-Kaye-Stansel is a first stage palliative procedure in patients with single ventricle with subaortic stenosis and distal arch obstruction – typically occurring in patients with single left ventricle and transposition of the great arteries.

Surgery The main pulmonary artery is transected and the trunk is anastomosed (end to side) to the ascending aorta to create a pulmonary artery-aortic anastomosis. This provides unobstructed systemic blood flow. An atrial septectomy is performed if restriction of the left atrioventricular valve is found. A right sided modified BT shunt is placed for pulmonary blood flow. The neo-aortic (native pulmonary) valve frequently has trivial to mild insufficiency following this procedure.

*** See bedside book: *postoperative care of infants with single ventricle physiology*

Fontan



- Indications** The Fontan procedure is the final reconstructive procedure for single ventricle physiology, the goal being to ‘complete’ the separation of the systemic and pulmonary circulations, resulting in normal (or near normal) oxygen saturations. It is performed following a Glenn procedure, when the patient is above 15kg in weight. Although many versions of the Fontan procedure exist, the extra cardiac conduit Fontan is usually performed at UCSF.
- Surgery** A median sternotomy and cardiopulmonary bypass is utilized. The inferior vena cava is removed from the right atrium and the cardiac end of the right atrium is oversewn. A homograft conduit is inserted and anastomosed end to end to join the inferior vena cava with the pulmonary artery to create a completely extracardiac conduit. Occasionally a fenestration is placed between the homograft and the right atrium to allow a right to left shunt. This ‘pop off’ mechanism may maintain systemic cardiac output even when pulmonary vascular resistance is elevated. As right to left shunting occurs, systemic arterial saturations decrease.
- Physiology** The Fontan separates the circulations and provides continuity between the systemic venous circulation and the pulmonary arterial circulation. It directs systemic venous return directly to the lungs without the use of the heart. Blood passively flows from the superior vena cava by means of the Glenn Shunt and from the inferior vena cava, now by means of the Fontan, to the pulmonary arteries and the lungs. Therefore the pulmonary circulation is separated from the systemic circulation.
- Postop** Postoperative management must be specifically tailored to the preoperative anatomy and physiology and is directed toward optimizing cardiac output at the lowest central venous pressure possible.
- Mechanical ventilation; since PBF in the Fontan population is passive, mechanical positive pressure ventilation with increased mean airway pressures may decrease PBF and ventricular filling. Rapid weaning and extubation may improve hemodynamics in the awake patient. Elevate HOB 30°.
 - Monitor for decreased cardiac output caused by inadequate preload (low LA & RA pressures), anatomic obstruction in the systemic venous pathway (low LA & high RA pressures), pump failure (high LA & high RA pressures). Maintain atrial pressures between 6-8mm/Hg. Monitor Fontan pressure, normal ~10-15mm/Hg. Notify physicians for elevations in Fontan pressure or a decrease in transpulmonary gradient (Fontan pressure minus atrial pressure).
 - Avoid elevations in pulmonary vascular return (PVR); elevated PVR impedes the forward flow of blood through the pulmonary circulation, decreasing systemic cardiac output. Treat metabolic acidosis, hypercapnia and hypoxemia aggressively to avoid elevations in PVR (low LA & high RA pressures).
 - Utilize vigorous pulmonary toilet to prevent atelectasis after extubation (incentive spirometry, ambulation, CPT). Monitor closely for increase in chest tube output and the development of pleural effusions and chylothoraces.
 - Dysrhythmias; pacemaker therapy may be necessary.

The Mustard and Senning Operations are physiologic repairs for D-Transposition of the Great Arteries. In 1975 surgeons perfected the technique of successfully transferring the coronary arteries. Around that same time, serious complications of the Mustard and Senning procedures were being reported. The main disadvantage is that the anatomical left ventricle continues as the pulmonary ventricle, while the anatomic right ventricle and tricuspid valve must continue to function as the systemic ventricle. As a child grows, right ventricle failure and symptomatic arrhythmia's are likely to develop.

Presently the arterial switch operation is performed within the first weeks of life. In the PICU, we will care for older patients who have had a Senning or Mustard repair and are returning for a switch operation.

Mustard

Surgery

Open heart procedure used to correct D-Transposition of the Great Vessels. The Mustard procedure requires a complete excision of any remaining atrial septum so that a large single atrium is temporarily present. A piece of pericardium or of woven prosthetic material is sewn within the atria as a baffle so that it deflects systemic venous blood to the mitral valve. This venous blood will then flow into the left ventricle and will be ejected into the pulmonary artery. The pulmonary venous blood is deflected by the baffle to the tricuspid valve. This oxygenated pulmonary venous blood then flows into the right ventricle and is ejected into the aorta.

Senning

Surgery

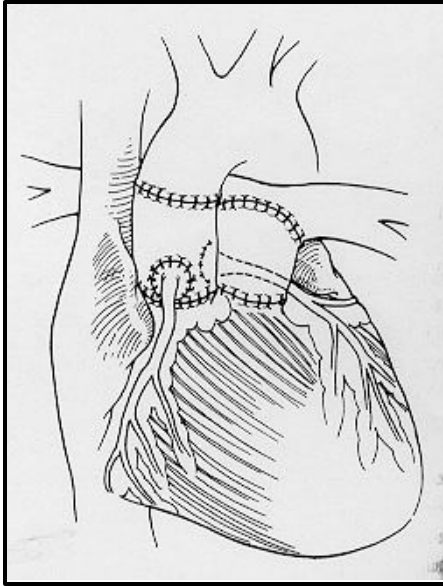
The Senning procedure is another open heart procedure used to correct D-Transposition of the Great Vessels. It also results in diversion of systemic and pulmonary venous blood in a manner similar to that accomplished by the Mustard procedure. The Senning uses portions of the atrial septal tissue and lateral atrial wall to create the intracardiac baffle. If this type of repair is done, the Atrial Septectomy will not be performed as a palliative procedure before the repair.

Rashkind Balloon Septostomy

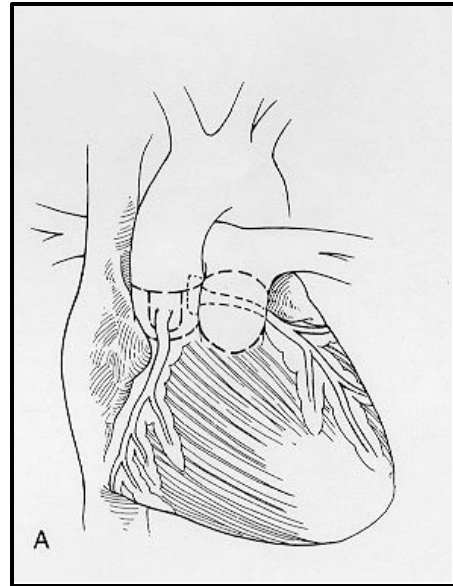
This procedure is performed either during cardiac catheterization or at the bedside under ECHO guidance. The goal is to create an opening in the atrial septum that provides improved mixing of venous and oxygenated blood. A standard venous catheterization is performed, and a balloon-tipped catheter is inserted. The catheter is passed from the right to the left atrium, the balloon is inflated, and pulled quickly back into the right atrium. This tears a hole in the atrial septum, and allows greater mixing of systemic and pulmonary venous blood. This is a desirable outcome in many first stage defect palliations, as it improves oxygen saturations. This is a temporary procedure and the defect created may close at any time.

Atrial Septectomy

Intraoperatively, a large atrial septal defect is created. This allows for greater mixing of oxygenated and deoxygenated blood within the heart. This procedure is frequently done as a palliation for Transposition of the Great Arteries.



Ross



Konno

Ross Procedure

Surgery

The Ross procedure is performed on patients diagnosed with aortic stenosis or severe aortic insufficiency, and is an alternative to prosthetic valve replacement. A median sternotomy incision and cardiopulmonary bypass is utilized. The patient's own pulmonary valve, together with the main trunk of the PA is removed and used to replace the diseased aortic valve and adjacent aorta. The coronary arteries are detached and implanted into the new aorta. The pulmonary autograft is very elastic and conforms easily to the new dimensions of the aortic root. This autograft has the advantage of documented long-term durability, does not require anticoagulation, and remains uncompromised by host reactions. There is evidence of the autograft's growth, making it an attractive option for aortic valve replacement in infants and children. The operation is completed by placing a homograft into the right ventricular outflow tract.

Postop

Complications include coronary ischemia, aortic insufficiency, ventricular dysfunction and right ventricular outflow tract obstruction.

Konno Procedure

Surgery

The Konno operation is performed on patients with valvar AS or subaortic AS who have severe annular narrowing or tunnel like narrowing of the left ventricular outflow tract and a small aortic valve annulus. Via a median sternotomy and under cardiopulmonary bypass the aortic annulus is reached via a right ventriculotomy. A prosthetic patch is placed to enlarge the entire left ventricular outflow tract and annulus. This aortic root enlargement allows room for insertion of an adequate prosthetic valve, or an aortic or pulmonary allograft. A pericardial patch is then used to close the right ventriculotomy.

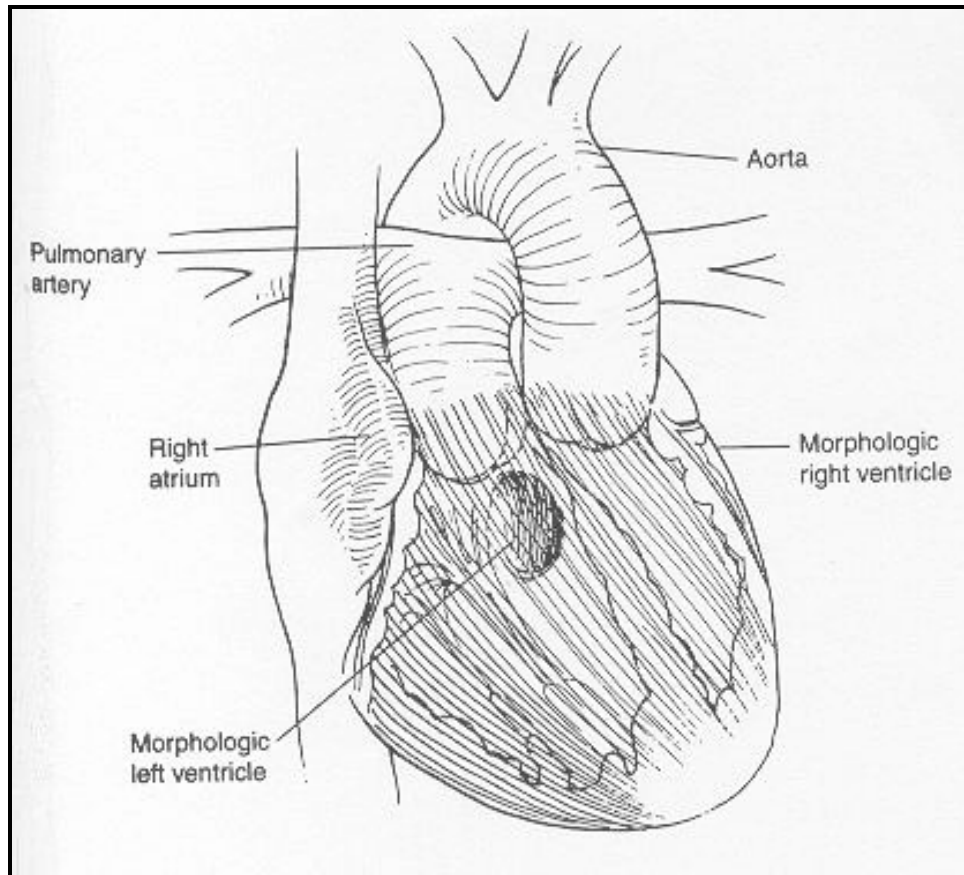
Postop

Complications include complete heart block, RBBB, residual VSD, right ventricular outflow tract obstruction and prosthetic valve problems.

Ross - Konno Procedure

Neonates with 'critical aortic stenosis' accompanied by left ventricular outflow tract obstruction and/or small left ventricular size may require a combined Ross-Konno procedure. The pulmonary artery and valve are resected and moved into the aortic position, and a homograft is inserted into the 'old' pulmonary artery site. Additionally, the LVOT is augmented by prosthetic patch. The postoperative course may be extremely critical, with complications including severe bleeding, coronary ischemia, RV/LV failure and cardiogenic shock.

L-Transposition of the Great Arteries



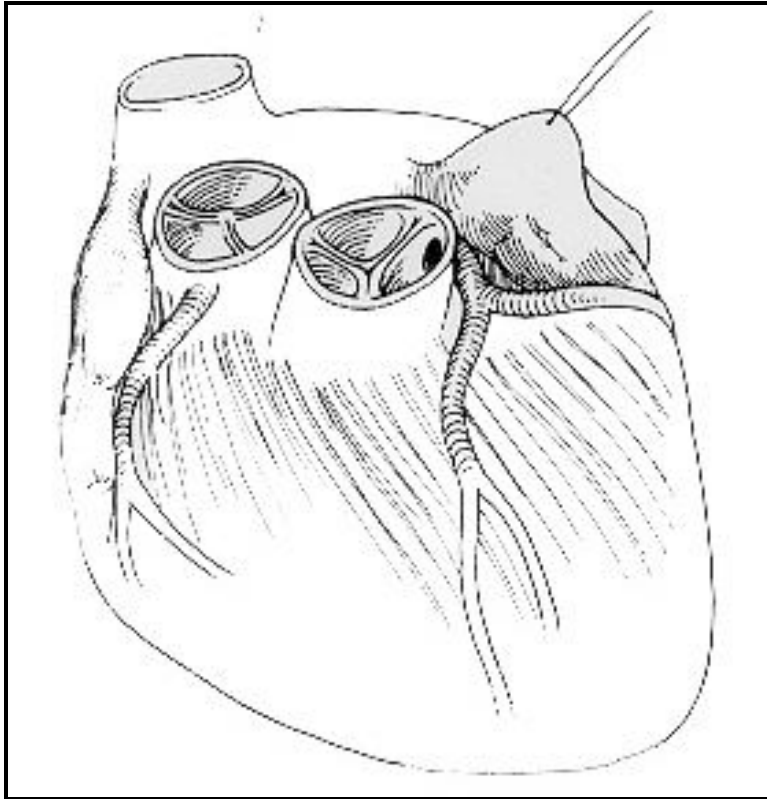
Anatomy

L-TGA, also known as congenitally corrected transposition or ventricular inversion is a defect characterized by atrioventricular and ventriculoarterial discordance. This lesion is caused by embryologic L-looping of the ventricles. The atrial relationship is normal; the RA is to the right of the LA. The ventricular relationship is switched; the morphologic LV is on the right side of the heart. The morphologic RV is on the left side of the heart. The great arteries are also switched so that overall the heart is 'balanced', or corrected. Most patients with L-TGA have associated cardiac defects (~80%), they include ventricular septal defect and valvar or subvalvar pulmonary stenosis. Patients are asymptomatic when L-TGA is not associated with other defects.

Physiology

Blood flow is functionally correct. Deoxygenated blood comes from the RA, flows to the anatomic LV, then to the lungs. Oxygenated blood comes into the LA, flows to the anatomic RV, then flows out the aorta and to the body. This is why the term 'corrected' is used to describe this condition. The atrioventricular discordance results in abnormalities of the conduction system, and a high incidence of heart block.

Anomalous Coronary Artery



Normal Coronary Artery

The blood supply to the heart muscle is provided by the coronary arteries, which arise in the aortic root just above the aortic valve and transverse the heart's surface in the epicardium. The major vessels are the right coronary artery and the left main coronary artery, which divides near its origin to form the left anterior-descending branch and the circumflex branch. The epicardial coronary arteries give off penetrating branches that perfuse the myocardium.

Anomalous Coronary Artery

The left coronary artery arises abnormally from the pulmonary artery. The patients usually are asymptomatic in the newborn period until the PA pressure falls in the first weeks of life. The left coronary artery fills with desaturated blood under less pressure, which leads to progressive myocardial ischemia and ventricular dilation. The right coronary artery, originating from the aorta, becomes the main source of coronary supply. The direction of blood flow is from the right coronary artery, through intercoronary collateral's, to the left coronary artery, and into the PA. Although the degree of left-to-right shunt is relatively small, the areas of the myocardium normally supplied by the left coronary artery are underperfused and become ischemic. With time, the left-sided chamber becomes progressively dilated.

Preop

The presenting features usually appear at 2 weeks to 6 months of age. Symptoms include episodes of distress (anginal pain), marked cardiomegaly, and CHF. All patients with this diagnosis need surgical repair.

Surgery

Surgery should be performed at time of diagnosis. A median sternotomy incision and cardiopulmonary bypass is utilized. Re-implantation of the left coronary artery into the aortic root or ascending aorta is accomplished. The anomalous coronary artery is excised from the PA along with a button of PA wall, and the artery is re-implanted into the anterior aspect of the ascending aorta.

Postop

Complications include poor cardiac output secondary to poor ventricular function, as well as moderate to severe left atrioventricular valve regurgitation. Even with surgery resulting in oxygenated blood supplying the myocardium, residual left ventricular dysfunction and increased left ventricular end-diastolic volume

persist for months after surgery. Decreased coronary blood flow associated with myocardial infarction should be closely monitored.

Cardiac Malposition

The term cardiac malposition indicates that the heart is abnormally located within the chest.

Levocardia - The heart is located in the left chest (normal).

Dextrocardia - The heart is located in the right chest.

Mesocardia - The heart is located in the middle of the chest.

The hemodynamics associated with cardiac malposition range from normal to those incompatible with life, and are a direct consequence of the intra cardiac defect. The diagnosis of cardiac malposition is made by chest x-ray.

Heterotaxy

Visceral Heterotaxy – This term implies that not only the heart but several of the abdominal viscera may be malpositioned. Patients with visceral heterotaxy show a high incidence of cardiac malformation. The primary characteristics include abnormal position of certain viscera and veins (lungs, liver, vena cava) and situs discordance between organ systems. The spleen is almost always affected in patients with visceral heterotaxy. The spleen may be absent (asplenia) or multi-lobed (polysplenia). Rarely is it of normal size or normally positioned.

Shones Complex

Shones complex is an anatomic collection of multiple left sided obstructive lesions including supra-aortic mitral ring, parachute mitral valve, subaortic stenosis and coarctation of the aorta.

Syndromes

The incidence of CHD in the general population is about 1%. This does not include PDA in premature infants. The repeated risk of CHD's associated with inherited diseases or with chromosomal abnormalities is related to the recurrent risk of the syndromes.

Hereditary Syndromes Associated with Cardiovascular Anomalies

Hereditary Syndrome	Cardiac Defect	Clinical Features
Apert's Syndrome	Occasional; VSD, TOF facial appearance	Irregular craniosynostosis, with peculiar head &
Carpenter's Syndrome	Occasional; PDA, VSD, PS, TGA	Variable craniosynostosis, severe syndactyly (mitten hands)
Crouzon's Disease	Occasional; PDA, COA	Ptosis with shallow orbits, cransynostosis
Ellis-van Creveld Syndrome	Frequent; single atrium	Neonatal teeth, short distal limbs, nail hypoplasia, polydactyly
Pompe's Disease	Common; cardiomyopathy	Large tongue, flabby muscles
Holt-Oram Syndrome	Frequent; ASD, VSD	Defects or absence of thumb or radius
Kartagener's Syndrome	Dextrocardia	Situs inversus, chronic sinusitis
LEOPARD Syndrome	Common; PS, long PR interval cardiomyopathy abnormal genitalia, retarded growth, deafness	Lentiginous skin lesion, ECG abnormalities, ocular hypertelorism, pulmonary stenosis,
Marfan's Syndrome	Frequent; aortic aneurysm, AR, MR	Archnodactyly (spider fingers), Long extremities
Hurler's Syndrome	Frequent; AR, MR, coronary artery disease	Coarse features, mental retardation, retarded growth, corneal opacity
Hunter's Syndrome	Frequent; AR, MR, coronary artery disease	Coarse features, mental retardation
Noonan's Syndrome	Frequent; PS	
Shprintzen's Syndrome	Common; VSD, TOF	Hearing loss, auricular anomalies, long face
TAR Syndrome	Occasional; ASD, TOF, dextrocardia	Thrombocytopenia, absent radius
Williams Syndrome	Frequent; AS, PA, PS	Mental retardation, 'elfin' facies, hypercalcemia, 'cocktail personality'

Non-Hereditary Syndromes Associated with Cardiovascular Anomalies

Syndrome	Cardiac Defect	Clinical Features
CHARGE Association	Common (65%); conotruncal anomalies, TOF, Truncus, IAA anomalies, ear anomalies, genital hypoplasia	Coloboma, heart defects, choanal atresia, growth/mental retardation, genitourinary anomalies
Congenital diaphragmatic hernia	Occasional (25%); VSD, TOF	Diaphragmatic hernia, pulmonary hypoplasia
Dandy-Walker Syndrome	Rare (3%); VSD	Hydrocephalus, cystic malformation in brain
DeLange's Syndrome	Occasional (30%); VSD	Prenatal growth retardation, microcephaly
DiGeorge Syndrome	Frequent; IAA, Truncus, VSD, PDA, TOF	Hypertelorism, hypoplastic thymus & parathyroid, hypocalcemia, deficient cell mediated immunity, downslant eyes
Fetal Alcohol Syndrome	Frequent (30%); VSD, PDA, ASD, TOF	Prenatal growth retardation, microcephaly, irritable
Pierre Robin Syndrome	Occasional (29%); VSD, PDA, ASD, TOF, COA	Deafness, cataracts, mental deficiency, hepatosplenomegaly, thrombocytopenia jaundice
Trisomy 13	Common (90%); VSD, PDA,	Multiple midline anomalies, severe mental dextrocardia retardation
Trisomy 18	Common (99%); VSD, PDA, PS	Severe mental retardation, multiple deformities
Trisomy 21 (Down's)	Frequent (50%); AVC, VSD eyes	Mental retardation, hypotonia, large tongue, slanted eyes
Turners Syndrome	Occasional (35%); COA, AS, ASD	Female, dwarfism, genital hypoplasia, web neck
Vater Association (VACTERL)	Frequent (50%); VSD, other defects	Vertebral defects, anal atresia, CHD, tracheoesophageal fistula, renal dysplasia, limb anomalies