

**FAA
NIM**

1010111010
1100101001
1100101001
00001100
0010
0000
10011
11001
00100
01000110100
00110001001

101000
0000110
0001
1101
0010
0000
0011
0111
0011
1100
0110

**WORLD
LEADING
MEETING**


VIRTUAL

PRE-CONGRESS SYMPOSIA:

OCT 4-13, 2021

MAIN CONGRESS:

OCT 20-23, 2021



**Continuing Medical Education -
CME Extended Abstracts Book**

TABLE OF CONTENTS

Letter of Invitation by the Congress Chair	6
--	---

CME Programme at a Glance	7
---------------------------	---

WEDNESDAY, OCTOBER 20, 2021

CME 1 - Oncology & Theranostics Committee: **Prostate Cancer - Greatest Hits**

Immunohistochemistry and PET Targeting Prostate Specific Membrane Antigen - Now You See Me? Daniela Ferraro (Zurich, Switzerland)	9
PSMA PET in Primary Staging - Ready for Prime Time? The Urologist's Perspective Otto Ettala (Turku, Finland)	10
PSMA PET After Primary Treatment - Anything New? Daniela-Elena Oprea-Lager (Amsterdam, Netherlands)	11
PSMA PET for Castration-Resistant Prostate Cancer - How Far Have We Come? Wolfgang Fendler (Essen, Germany)	12

CME 2 - Physics Committee: **AI in Radiomics**

Domain Shift, Data Scarcity and (Deep) Domain Adaptation in Medical Imaging Vincent Jaouen (Brest, France)	14
Potential Role of AI and Radiomics in Oncology Martina Sollini (Milan, Italy)	15
Potential Role of AI and Radiomics in Cardiac Imaging Christoph Rischpler (Essen, Germany)	16
What May the Combination of Radiomics and Deep Learning Bring to SPECT and PET of the Brain? Ralph Buchert (Hamburg, Germany)	17

CME 3 - Inflammation & Infection Committee: **The Battle Continues - WBC Scan vs FDG PET/CT**

Radiolabelled WBC Scintigraphy for Musculoskeletal Infections - Pros and Cons Edel Noriega (Ciudad Real, Spain)	19
FDG-PET for Musculoskeletal Infections - Pros and Cons Zohar Keidar (Haifa, Israel)	20
Radiolabelled WBC Scintigraphy for Cardiovascular Infections - Pros and Cons François Rouzet (Paris, France)	21
FDG-PET for Cardiovascular Infections - Pros and Cons Lucia Leccisotti (Rome, Italy)	22

CME 4 - Neuroimaging + Radiopharmacy Committee:

Imaging Neuroinflammation - Everything You Always Wanted to Know, But Were Afraid to Ask

Background of TSPO and Non-TSPO Targets and Their Radiotracers Matthias Brendel (Munich, Germany)	24
Imaging Neuroinflammation with TSPO Ligands - A Critical Reappraisal Bart van Berckel (Amsterdam, Netherlands)	25
Imaging Neuroinflammation - Beyond TSPO Donatienne van Weehaeghe (Leuven, Belgium)	26

THURSDAY, OCTOBER 21, 2021

CME 5 - Cardiovascular + Inflammation & Infection Committee:

Inflammation, Infection and Infiltrative Cardiovascular Diseases - Think Nuclear!

Cardiac Sarcoidosis Olivier Gheysens (Brussels, Belgium)	28
The Role of Nuclear Medicine in Cardiac Amyloidosis Tanja Kero (Uppsala, Sweden)	29
Endocarditis Asbjørn Scholtens (Amersfoort, Netherlands)	30
Vasculitis Lars Christian Gormsen (Aarhus, Denmark)	31

CME 6 - Oncology & Theranostics Committee: **Quo Vadis PET/MRI?**

Methodological Developments Harald Quick (Essen, Germany)	33
Where Does PET/MR Enhance PET for Oncologic Questions? Irene Burger (Baden, Switzerland):	34
Beyond Oncological Applications Alexander Hammers (London, United Kingdom)	35

CME 7 - Physics + Dosimetry Committee: **Developments and Challenges in Theranostics**

Where Are We with Theranostic Imaging Today? Lioe-Fee de Geus-Oei (Leiden, Netherlands)	37
Terbium Radioisotopes for Theranostics, What to Expect? Cristina Müller (Villingen, Switzerland)	38
Quantitative Theranostic Imaging - Challenges and Opportunities Mark Konijnenberg (Rotterdam, Netherlands)	39

CME 8 - Radiation Protection + Dosimetry Committee: **Pregnancy and Breastfeeding in the Context of Nuclear Medicine**

Status of Guidelines on Breastfeeding Sigrid Leide-Svegborn (Malmö, Sweden)	41
The Pregnant Patient - Risks for the Foetus François Jamar (Brussels, Belgium)	42
How to Estimate the Radiation Doses? Marta Cremonesi (Milan, Italy)	43

FRIDAY, OCTOBER 22, 2021

CME 9 - Radiopharmacy + Drug Development Committee:

Back to the Future - New Kit-Based Approaches for Labelling Radiopharmaceuticals (⁶⁸Ga, Al[¹⁸F],...)

Labelling Cold Kit With ⁶⁸Ga - The Future is Bright

Clément Morgat (Bordeaux, France) 45

Al[¹⁸F]: From Modules Toward a Kit-Based Radiofluorination?

Chiara Da Pieve (London, United Kingdom) 46

Regulatory Aspects of Cold Kit - Based Radiopharmaceuticals in the EU

Oliver Neels (Dresden, Germany) 47

CME 10 - Thyroid + Oncology & Theranostics Committee:

Radionuclide Therapies - Management of Side Effects and Complications

Radioiodine Therapy in Thyroid Cancer

Markus Luster (Marburg, Germany) 49

Peptide Receptor Radionuclide Therapy - Management Of Side Effects And Complications

Gopinath Gnanasegaran (London, United Kingdom) 50

¹⁷⁷Lu-PSMA and ²²⁵Ac-PSMA Therapy for Metastatic Castration-Resistant Prostate Cancer - A Game Changer?

Sarah M. Schwarzenböck (Rostock, Germany) 51

CME 11 - Bone & Joint Committee: **New Concepts for Imaging and Therapy of Bone Metastases**

Nuclear Imaging of Bone Metastases

Helle D. Zacho (Aalborg, Denmark) 53

Radionuclide Therapy of Bone Metastases

Ali Afshar-Oromieh (Bern, Switzerland) 54

Ablative Irradiation Of Bone Metastases

Piet Dirix (Antwerp, Belgium) 55

CME 12 - Paediatric Committee: **Nuclear Medicine in the Evaluation of Child Abuse**

Clinical Aspects Of Child Abuse

Hadas Yechiam (Kfar Saba, Israel) 57

Nuclear Medicine in the Evaluation of Child Abuse

Laura Drubach (Boston, United States of America) 58

Radiological Aspects of Child Abuse

Chiara Giraudo (Padua, Italy) 59

SATURDAY, OCTOBER 23, 2021

CME 13 - Translational Molecular Imaging & Therapy + Oncology & Theranostics Committee: **Immunotheranostics**

Immunotherapy and Nuclear Medicine diagnostics - Where do we Stand?

Elisabeth G. E. de Vries (Groningen, Netherlands) 61

Combining Immunotherapy and Radiation - Is the Whole More than the Sum of its Parts?

Fernanda Herrera (Lausanne, Switzerland) 62

Nuclear Medicine Immunotheranostics - Synergisms and Antagonisms

Niklaus Schaefer (Lausanne, Switzerland) 63

CME 14 - Drug Development + Translational Molecular Imaging & Therapy Committee:

Probing Tumour Metabolism - An Update

Imaging Nucleoside Transport for Monitoring Targeted Therapy in Cancer

Francesca Iommelli (Naples, Italy) 65

Illuminating Metabolic Heterogeneity and Vulnerabilities in Lung Cancer

David Lewis (Glasgow, United Kingdom) 66

Imaging Tumour Metabolism and its Heterogeneity with MRI

Ferdia Gallagher (Cambridge, United Kingdom) 67

EANM'22

69

A STREAMLINED CLINICAL CARE PATH ENABLED BY DIGITAL 360° SPECT/CT IMAGING

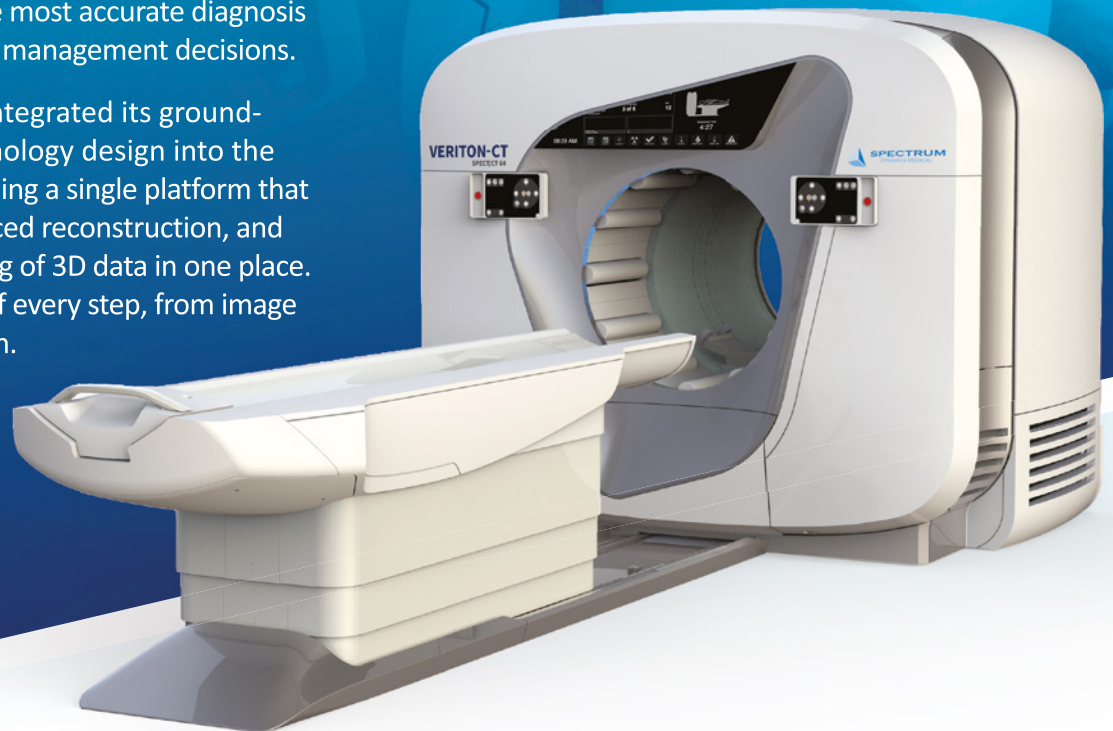
VERITON-CT[®]

DIGITAL SPECT/CT

Optimization of every step

For optimal patient outcomes, clinicians require access to imaging that ensures the most accurate diagnosis and appropriate treatment management decisions.

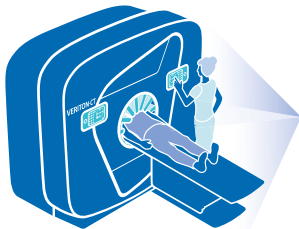
Spectrum Dynamics has integrated its groundbreaking Broadview Technology design into the VERITON-CT system, providing a single platform that handles acquisition, advanced reconstruction, and quantitative post-processing of 3D data in one place. The result is optimization of every step, from image acquisition to interpretation.



VERITON-CT digital SPECT/CT combines the best-in-class CZT detectors, novel system design, high resolution CT, and advanced software technology to elevate the performance of CZT digital SPECT.



Core technology
designed to generate superior image data



Workflow that is reproducible and not determined by operator, patient condition or scan

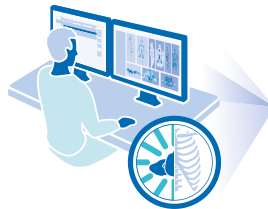

Image quality tools in TruView Console for advanced reconstruction and artifact reduction for both NM and CT data



Quantitative analysis combined with superior image quality inform decisions, ensuring an accurate scan interpretation that helps answer the clinical question



Comprehensive results from transformative technology that provides a greater volume of high quality data for informed decision-making



LETTER OF INVITATION

BY THE CONGRESS CHAIR



STEFANO FANTI

CONGRESS CHAIR 2020-2022

Dear Colleagues, dear Friends,

On behalf of the European Association of Nuclear Medicine, it is my honour to invite you to the 34th Annual EANM Congress. The event will run virtually from 20 to 23 October 2021.

Despite the difficult time we are experiencing due to the pandemic, nuclear medicine continues to grow both in diagnostic imaging and therapy. New radiopharmaceuticals which facilitate the study and treatment of new targets are being introduced, more and more protocols which cover unmet clinical needs and new applications are running, and the use of nuclear medicine procedures is increasingly being incorporated into clinical practice and guidelines. This success remains related to that very peculiar characteristic of our specialty, namely, its functional approach to medicine. This is mainly true with respect to imaging, but also for therapy.

In recent years we have proudly celebrated the status of the EANM Congress as the world's leading meeting for nuclear medicine. In 2019, for example, we reached almost 7000 participants, a truly memorable record. As we all know, the pandemic of 2020 forced all events to move to a virtual format and we did our best to prepare a great event. We succeeded in keeping all of our scientific programmes running with 11 parallel

channels and received excellent feedback from participants. As mentioned, we are unable to return to the complete live format we are used to and would have all hoped for in 2021. Therefore, we have planned a great event with a full scientific programme once more, but have arranged some significant improvements after the lessons learnt last year. In 2021, the pre-congress symposia will run a couple of weeks before the congress, which, as a result, has been shortened by one day. Furthermore, most of the several parallel tracks will not run according to the traditional time sequence but will always be available on demand to facilitate access and productivity for attendees.

In summary, we are working on providing you a congress with superb and comprehensive scientific content as well as a lot of other features to make your participation enjoyable whatever you are looking to achieve.

Stefano Fanti
EANM Congress Chair 2020-2022

CME PROGRAMME AT A GLANCE

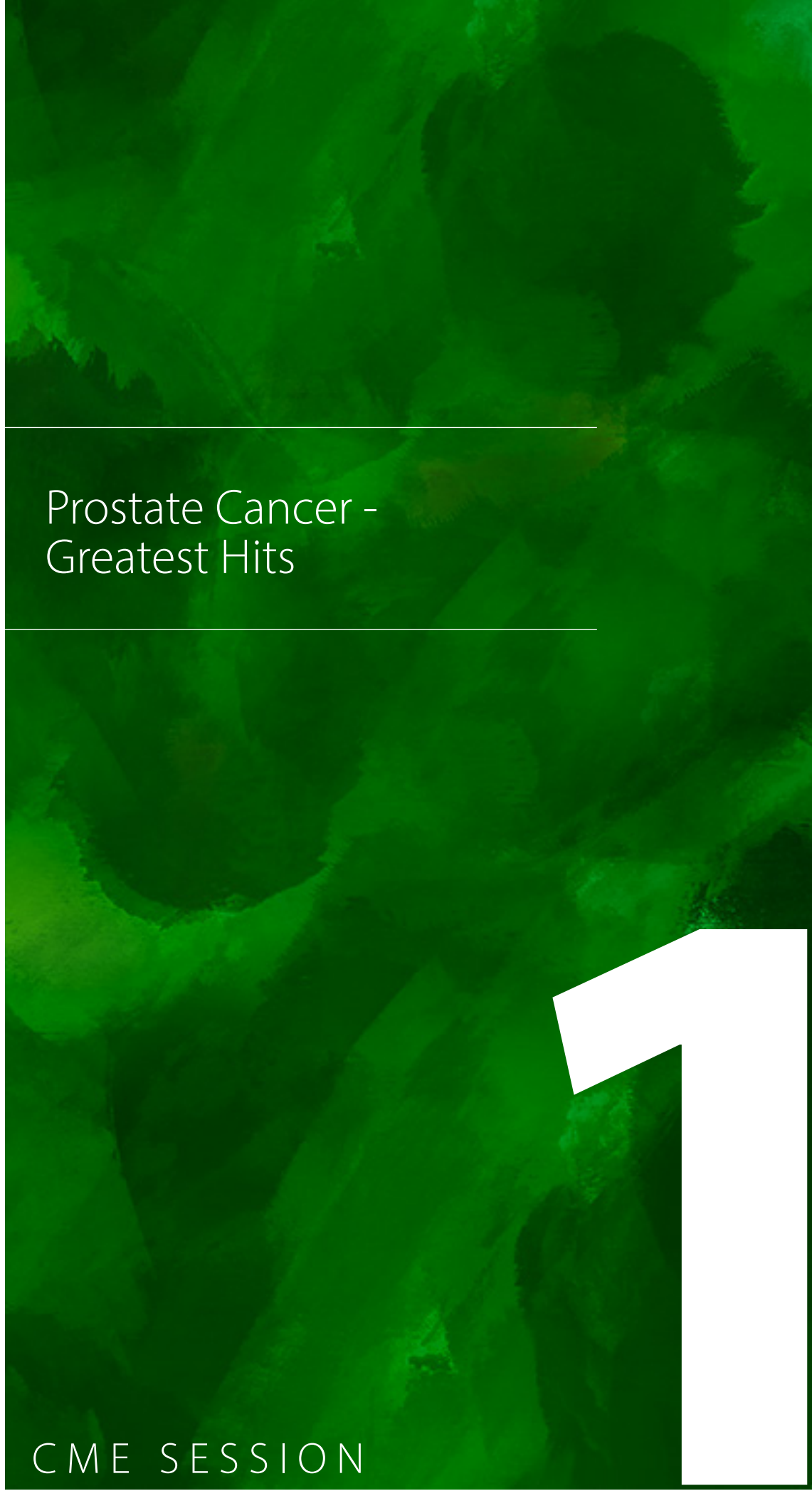
Wednesday, October 20	Thursday, October 21	Friday, October 22	Saturday, October 23
<p><i>201</i></p> <p>CME 1 (10:15-11:45) Oncology & Theranostics Committee</p> <p>Prostate Cancer - Greatest Hits</p>	<p><i>801</i></p> <p>CME 5 (09:00-10:30) Cardiovascular + Inflammation & Infection Committee</p> <p>Infiltration, Infection and Infiltrative Nuclear Cardiovascular Diseases - Think Nuclear!</p>	<p><i>1301</i></p> <p>CME 9 (09:00-10:30) Radiopharmacy + Drug Development Committee</p> <p>Back to the Future - New Kit-Based Approaches for Labelling Radiopharmaceuticals (⁶⁸Ga, Al[¹⁸F]F,...)</p>	<p><i>1801</i></p> <p>CME 13 (09:00-10:30) Translational Molecular Imaging & Therapy + Oncology & Theranostics Committee</p> <p>Immunotheranostics</p>
<p><i>301</i></p> <p>CME 2 (12:00-13:30) Physics Committee</p> <p>AI in Radiomics</p>	<p><i>901</i></p> <p>CME 6 (10:45-12:15) Oncology & Theranostics Committee</p> <p>Quo vadis PET/MRI?</p>	<p><i>1401</i></p> <p>CME 10 (10:45-12:15) Thyroid + Oncology & Theranostics Committee</p> <p>Radionuclide Therapies - Management of Side Effects and Complications</p>	<p><i>1901</i></p> <p>CME 14 (10:45-12:15) Drug Development + Translational Molecular Imaging & Therapy Committee</p> <p>Probing Tumour Metabolism - An Update</p>
<p><i>501</i></p> <p>CME 3 (16:15-17:45) Inflammation & Infection Committee</p> <p>The Battle Continues - WBC Scan vs FDG PET/CT</p>	<p><i>1101</i></p> <p>CME 7 (15:05-16:35) Physics + Dosimetry Committee</p> <p>Developments and Challenges in Theranostics</p>	<p><i>1601</i></p> <p>CME 11 (15:05-16:35) Bone & Joint Committee</p> <p>New Concepts for Imaging and Therapy of Bone Metastases</p>	
<p><i>601</i></p> <p>CME 4 (18:00-19:30) Neuroimaging Committee</p> <p>Imaging Neuroinflammation - Everything You Always Wanted to Know, But Were Afraid to Ask</p>	<p><i>1201</i></p> <p>CME 8 (16:50-18:20) Radiation Protection + Dosimetry Committee</p> <p>Pregnancy and Breastfeeding in the Context of Nuclear Medicine</p>	<p><i>1701</i></p> <p>CME 12 (16:50-18:20) Paediatrics Committee</p> <p>Nuclear Medicine in the Evaluation of Child Abuse</p>	

ALL SESSION TIMES REFER TO CENTRAL EUROPEAN SUMMER TIME (CEST)

CME SESSION 1

Prostate Cancer - Greatest Hits

CME SESSION



IMMUNOHISTOCHEMISTRY AND PET TARGETING PROSTATE- SPECIFIC MEMBRANE ANTIGEN: NOW YOU SEE ME?

CME Session

1



October 20
10:15 - 11:45

 DANIELA A. FERRARO (ZURICH, SWITZERLAND)

Prostate-specific membrane antigen (PSMA) is a type II transmembrane protein expressed in normal prostatic tissue and particularly overexpressed in the adenocarcinoma of the prostate. In the last decade, it has been in the spotlight with the development of PSMA ligands for positron emission tomography (PET) imaging and PSMA-targeted therapies for prostate cancer. PSMA-PET has a high detection rate for prostate cancer lesions both in the setting of initial staging and of biochemical recurrence. However, detectability of lesions depends on PSMA expression of the tumour tissue, which is markedly heterogeneous¹. It can be expressed in the cytoplasm and in the membrane of cells in higher or lower intensity, and the percentage of cells with significant PSMA expression

seems to be determinant for PET imaging^{2,3}. Around 6-10% of primary prostate adenocarcinoma are PSMA-negative on immunohistochemistry⁴ and around 10% of them are negative on PSMA-PET5. In patients with metastatic lesions, PSMA-expression can vary between lesions and metastasis sites as well as throughout the course of the disease with the development of castration-resistant prostate cancer¹ and with the use of androgen-deprivation therapy⁶. It has also been shown to correlate with parameters such as tumour grade⁷ and patient's serum PSA level⁴. In this presentation it will be discussed what is known about PSMA expression of prostate cancer that can have an effect on PSMA-PET imaging.

References:

1. Paschalis, A., et al., Prostate-specific Membrane Antigen Heterogeneity and DNA Repair Defects in Prostate Cancer. *Eur Urol*, 2019.
2. Ferraro, D.A., et al., Immunohistochemical PSMA expression patterns of primary prostate cancer tissue are associated with the detection rate of biochemical recurrence with (68)Ga-PSMA-11-PET. *Theranostics*, 2020. 10(14): p. 6082-6094.
3. Woythal, N., et al., Immunohistochemical Validation of PSMA Expression Measured by (68)Ga-PSMA PET/CT in Primary Prostate Cancer. *J Nucl Med*, 2018. 59(2): p. 238-243.
4. Hupe, M.C., et al., Expression of Prostate-Specific Membrane Antigen (PSMA) on Biopsies Is an Independent Risk Stratifier of Prostate Cancer Patients at Time of Initial Diagnosis. *Frontiers in Oncology*, 2018. 8.
5. Uprimny, C., et al., (68)Ga-PSMA-11 PET/CT in primary staging of prostate cancer: PSA and Gleason score predict the intensity of tracer accumulation in the primary tumour. *Eur J Nucl Med Mol Imaging*, 2017. 44(6): p. 941-949.
6. Vaz, S., et al., Influence of androgen deprivation therapy on PSMA expression and PSMA-ligand PET imaging of prostate cancer patients. *Eur J Nucl Med Mol Imaging*, 2020. 47(1): p. 9-15.
7. Bravaccini, S., et al., PSMA expression: a potential ally for the pathologist in prostate cancer diagnosis. *Sci Rep*, 2018. 8(1): p. 4254.

PSMA PET IN PRIMARY STAGING - READY FOR PRIME TIME? THE UROLOGIST'S PERSPECTIVE

CME Session

1



October 20
10:15 - 11:45

 OTTO ETTALA (TURKU, FINLAND)

PSMA-targeted PET imaging and radionuclide therapies have rapidly gained popularity in staging, restaging and treatment of men with prostate cancer. Currently the main indication of PSMA PET is restaging after biochemical recurrence (1). With the increasing scientific knowledge on the pearls and pitfalls of PSMA PET imaging, are we now ready to override whole body contrast enhance computed tomography (CT) and bone scintigraphy (BS) with PSMA PET in primary staging setting?

So far, there are only few trials demonstrating the superiority of PSMA PET compared to CT and BS in primary staging of prostate cancer, in terms of sensitivity, diagnostic accuracy and changes in

treatment decision (2,3). However, whether patients truly benefit from this increased sensitivity and earlier detection of metastases is of question. Due to lack of randomized trials showing the benefit of PSMA PET on improved patient outcomes i.e. development of metastatic disease, castration resistance or death, PSMA PET is still considered as experimental both in European and American urology guidelines (1,4).

Due to its superiority in prostate cancer detection PSMA PET is a very promising technique ready for prime time. However, as a standard in clinical practice, CT and BS still stand their ground in primary staging, until more evidence on the effect of PSMA PET on patient outcomes is available.

References:

1. Mottet N, Bellmunt J, Briers E., et al; members of the EAU - ESTRO - ESUR -SIOG Prostate Cancer Guidelines Panel. EAU - ESTRO - ESUR - SIOG Guidelines on Prostate Cancer. Edn. presented at the EAU Annual Congress Milan 2021. 978-94-92671-13-4. Publisher: EAU Guidelines Office. Place published: Arnhem, The Netherlands.
2. Hofman MS, Lawrentschuk N, Francis RJ, et al. Prostate-specific membrane antigen PET-CT in patients with high-risk prostate cancer before curative-intent surgery or radiotherapy (proPSMA): a prospective, randomised, multicentre study. *Lancet* 2020;395:1208-16.
3. Anttinen M, Ettala O, Malaspina S, et al. A Prospective Comparison of ¹⁸F-prostate-specific Membrane Antigen-1007 Positron Emission Tomography Computed Tomography, Whole-body 1.5 T Magnetic Resonance Imaging with Diffusion-weighted Imaging, and Single-photon Emission Computed Tomography/Computed Tomography with Traditional Imaging in Primary Distant Metastasis Staging of Prostate Cancer (PROSTAGE). *Eur Urol Oncol.* 2020 13:S2588-9311(20)30090-0.
4. Lowrance WT, Breau RH, Chou R, et al: Advanced Prostate Cancer: AUA/ASTRO/SUO Guideline PART I. *J Urol* 2021; 205: 14

PSMA PET AFTER PRIMARY TREATMENT - ANYTHING NEW?

CME Session

1



October 20
10:15 - 11:45

DANIELA-ELENA OPREA-LAGER (AMSTERDAM, NETHERLANDS)

Prostate-specific membrane antigen (PSMA) positron emission tomography/computed tomography (PET/CT) has been successfully implemented for the restaging of patients with prostate cancer after primary treatment. Several international guidelines recognize the indication for using PSMA PET/CT in biochemical relapse setting, based on the high accuracy of this technique to detect local recurrence and/or metastatic lesions, even at very low prostate-specific antigen (PSA) values.

Nevertheless, the clinical questions 'We see more, but do we treat better?' and 'Do our patients have

survival benefit using PSMA PET?' are more actual than ever. Therefore, this presentation will focus on the new insights regarding the PSMA PET, in an attempt to find the scientifically-proven answers. Aspects related to the accurate criteria for PSMA PET interpretation, the newly PSMA oligometastatic concept, the PSMA-induced shift in clinical management and the role of PSMA to guide metastasis-directed therapy will be discussed. Finally, new research ideas will be proposed to facilitate the interaction between the nuclear medicine community and our clinical partners, PSMA believers or not.

References:

1. Mottet N, van den Bergh RCN, Briers E, et al. EAU-EANM-ESTRO-ESUR-SIOG Guidelines on Prostate Cancer-2020 Update. Part 1: Screening, Diagnosis, and Local Treatment with Curative Intent. *Eur Urol*. 2021;79(2):243-262.
2. Trabulsi EJ, Rumble RB, Jadvar H, et al. Optimum Imaging Strategies for Advanced Prostate Cancer: ASCO Guideline. *J Clin Oncol*. 2020;38(17):1963-1996.
3. Ceci F, Oprea-Lager DE, Emmett L, et al. E-PSMA: the EANM standardized reporting guidelines v1.0 for PSMA-PET. *Eur J Nucl Med Mol Imaging*. 2021;48(5):1626-1638.
4. Farolfi A, Calderoni L, Mattana F, et al. Current and Emerging Clinical Applications of PSMA PET Diagnostic Imaging for Prostate Cancer. *J Nucl Med*. 2021;62(5):596-604.
5. Lecouvet FE, Oprea-Lager DE, Liu Y, et al. Use of modern imaging methods to facilitate trials of metastasis-directed therapy for oligometastatic disease in prostate cancer: a consensus recommendation from the EORTC Imaging Group. *Lancet Oncol*. 2018 Oct;19(10):e534-e545.
6. Calais J, Armstrong WR, Kishan AU, et al. Update from PSMA-SRT trial NCT03582774: a randomized phase 3 imaging trial of prostate-specific membrane antigen positron emission tomography for salvage radiation therapy for prostate cancer recurrence powered for clinical outcome. *Eur Urol Focus*. 2021;7(2):238-240.
7. Wondergem M, Jansen BHE, van der Zant FM, et al. Early lesion detection with 18F-DCFPyL PET/CT in 248 patients with biochemically recurrent prostate cancer. *Eur J Nucl Med Mol Imaging*. 2019;46(9):1911-1918.
8. Valle L, Shabsovich D, de Meerleer G, et al. Use and Impact of Positron Emission Tomography/Computed Tomography Prior to Salvage Radiation Therapy in Men with Biochemical Recurrence After Radical Prostatectomy: A Scoping Review. *Eur Urol Oncol*. 2021:S2588-9311(21)00031-6.

PSMA PET FOR CASTRATION-RESISTANT PROSTATE CANCER - HOW FAR HAVE WE COME?

CME Session

1



October 20
10:15 - 11:45

 WOLFGANG PETER FENDLER (ESSEN, GERMANY)

The addition of PSMA PET to conventional imaging of castration-resistant prostate cancer (CRPC) leads to the PCWG3 subgroup upstaging in 30% of patients [1]. PSMA PET detects more lesions and regions of disease in all subgroups, especially in patients with non-metastatic CRPC (nmCRPC) by conventional imaging [2]. Detection of metastases by PSMA PET was associated with short progression-free survival in patients with biochemically recurrent disease [3]. PSMA PET-guided oligometastases-directed therapy resulted in prolonged progression-free survival when compared with observation only [4]. Gafita et al. assessed the prognostic value of PSMA PET for outcome following ¹⁷⁷Lu-PSMA RLT in 270 patients from multi-center prospective and

retrospective patient cohorts [5]. PSMA expression and disease stage by PET were associated with biochemical progression-free survival and overall survival following ¹⁷⁷Lu-PSMA. PSMA PET findings and clinicopathologic parameters were combined in a nomogram for baseline prognostic assessment [5]. In addition, baseline to follow-up changes of PSMA PET are associated with PSA response under various types of systemic therapies for mCRPC. In summary, PSMA PET leads to considerable upstaging with higher accuracy for the detection of metastases in patients with oligometastatic, nmCRPC, or mCRPC by conventional imaging. Disease extent by PSMA PET is associated with short survival in patients with recurrent or advanced metastatic disease.

References:

1. Farolfi, A., et al., PSMA-PET identifies PCWG3 target populations with superior accuracy and reproducibility when compared to conventional imaging: a multicenter retrospective study. *J Nucl Med*, 2020.
2. Fendler, W.P., et al., Prostate-Specific Membrane Antigen Ligand Positron Emission Tomography in Men with Nonmetastatic Castration-Resistant Prostate Cancer. *Clin Cancer Res*, 2019. 25(24): p. 7448-7454.
3. Emmett, L., et al., 3-Year Freedom from Progression After (68)Ga-PSMA PET/CT-Triaged Management in Men with Biochemical Recurrence After Radical Prostatectomy: Results of a Prospective Multicenter Trial. *J Nucl Med*, 2020. 61(6): p. 866-872.
4. Phillips, R., et al., Outcomes of Observation vs Stereotactic Ablative Radiation for Oligometastatic Prostate Cancer: The ORIOLE Phase 2 Randomized Clinical Trial. *JAMA Oncol*, 2020. 6(5): p. 650-659.
5. Gafita A, Calais J, Grogan TR, Hadaschik B, Wang H, Weber M, Sandhu S, Kratochwil C, Esfandiari R, Tauber R, Zeldin A, Rathke H, Armstrong WR, Robertson A, Thin P, D'Alessandria C, Rettig MB, Delpassand ES, Haberkorn U, Elashoff D, Herrmann K, Czernin J, Hofman MS, Fendler WP, Eiber M. Nomograms to predict outcome after LuPSMA radionuclide therapy in men with metastatic castration-resistant prostate cancer: an international multicenter retrospective study. *Lancet Oncol*. 2021;in press.

CME SESSION 2

CME SESSION

AI in Radiomics

2

DOMAIN SHIFT, DATA SCARCITY AND (DEEP) DOMAIN ADAPTATION IN MEDICAL IMAGING

REFERS TO CME TALK: CHALLENGES IN MULTI-CENTER TRIALS USING RADIOMICS MODELS - THE ROLE OF AI BASED HARMONISATION

CME Session

2



October 20
12:00 - 13:30

VINCENT JAOUEN (BREST, FRANCE)

Deep learning is now ubiquitous in medical image analysis. Its success is due to unprecedented generalization ability, i.e. its capacity to make accurate predictions from samples not seen during model training. Two necessary conditions for generalization are: 1 - sufficient training samples to accurately capture the underlying true data distribution and 2 - deployment (testing) conditions sufficiently close to training conditions. These two requirements are generally not optimally met in medical imaging due to the relative scarcity of data and to multiple sources of heterogeneity regrouped under the term domain shift. In particular, multi-center studies, a typical way to address data scarcity, generally aggravate the

domain shift compared to single-center studies.

Driven by the popularity of deep learning in medical imaging, a growing number of works are recently being devoted to mitigating these issues through advanced domain adaptation techniques. This talk will provide a systematic overview of these methods and their associated challenges for various downstream applications including but not limited to image segmentation and radiomics analyses. Both conventional mitigation and advanced deep strategies at the image and the feature level will be discussed. Examples in quantitative molecular imaging will be given.

References:

1. Visvikis, D., Le Rest, C. C., Jaouen, V., & Hatt, M. (2019). Artificial intelligence, machine (deep) learning and radio (geno) mics: definitions and nuclear medicine imaging applications. *European journal of nuclear medicine and molecular imaging*, 46(13), 2630-2637.
2. Jansen, A., Ferreira, M., Lucia, F., Jaouen, V., Reinhold, C., Bonaffini, P., ... & Hatt, M. (2021). Convolutional neural networks for PET functional volume fully automatic segmentation: development and validation in a multi-center setting. *European journal of nuclear medicine and molecular imaging*, 1-13.
3. Castro, D. C., Walker, I., & Glocker, B. (2020). Causality matters in medical imaging. *Nature Communications*, 11(1), 1-10.
4. Hognon, C., Tixier, F., Gallinato, O., Colin, T., Visvikis, D., & Jaouen, V. (2019, October). Standardization of multicentric image datasets with generative adversarial networks. In *IEEE NSS/MIC 2019*.
5. Da-Ano, R., Visvikis, D., & Hatt, M. (2020). Harmonization strategies for multicenter radiomics investigations. *Physics in Medicine & Biology*, 65(24), 24TR02.

POTENTIAL ROLE OF AI AND RADIOMICS IN ONCOLOGY

REFERS TO CME TALK: AI AND RADIOMICS FOR ONCOLOGY APPLICATIONS

CME Session

2



October 20
12:00 - 13:30

MARTINA SOLLINI (MILAN, ITALY)

In the era of precision medicine, there is the need of noninvasively predict patients' outcome informing clinicians about the risks of recurrence, treatment effectiveness, and toxicity development. AI and radiomics, offering the advantage to explore and to non-invasively assess tumor biology through conventional medical imaging, can be extremely valuable in this regard [1]. Moreover, AI has been demonstrated to be a reliable strategy for model development, it is technically unbiased (it learns from experience, i.e. data), it may constantly improve working through automated and reproducible processes, ultimately requiring less human resources, and it constitutes a promising solution for AI-based research [2-4]. Therefore, it is not wonder that the clinical and scientific interest in AI and radiomics

has significantly increased in the recent years [2]. Nonetheless, we are far from the scenario projected by the experts in the field according to which AI and radiomics would have replaced doctors including imagers. Indeed, although AI and radiomics studies resulted promising, they are still not mature enough to be implemented in the clinical setting and be widely used [5,6]. To successfully implement AI and radiomics in the real-clinical world sustainable, rigorous, and multidisciplinary research plan are needed for study design, model development (image preprocessing), training (labeling and/or features extraction) and testing (reproducibility) [2,4-7]. In this CME session we will describe the potential role of AI and radiomics in oncology.

References:

1. Sollini M, Bandera F, Kirienco M. Quantitative imaging biomarkers in nuclear medicine: from SUV to image mining studies. Highlights from annals of nuclear medicine 2018. *Eur J Nucl Med Mol Imaging*. Springer Berlin Heidelberg; 2019;46:2737-45.
2. Sollini M, Bartoli F, Marciano A, Zanca R, Slart RHJA, Erba PA. Artificial intelligence and hybrid imaging: the best match for personalized medicine in oncology. *Eur J Hybrid Imaging*. 2020;4:24.
3. Kirienco M, Sollini M, Ninatti G, Loiacono D, Giacomello E, Gozzi N, et al. Distributed learning: a reliable privacy-preserving strategy to change multicenter collaborations using AI. *Eur J Nucl Med Mol Imaging*. *Eur J Nucl Med Mol Imaging*; 2021;
4. Sollini M, Cozzi L, Ninatti G, Antunovic L, Cavinato L, Chiti A, et al. PET/CT radiomics in breast cancer: Mind the step. *Methods*. 2021;188:122-32.
5. Sollini M, Antunovic L, Chiti A, Kirienco M. Towards clinical application of image mining: a systematic review on artificial intelligence and radiomics. *Eur J Nucl Med Mol Imaging*. 2019;46:2656-72.
6. Porenta G. Is There Value for Artificial Intelligence Applications in Molecular Imaging and Nuclear Medicine? *J Nucl Med*. *J Nucl Med*; 2019;60:1347-9.
7. Sollini M, Gelardi F, Matassa G, Delgado Bolton RC, Chiti A, Kirienco M. Interdisciplinarity: an essential requirement for translation of radiomics research into clinical practice - a systematic review focused on thoracic oncology. *Rev Española Med Nucl e Imagen Mol (English Ed. SEMNIM)*; 2020;39:146-56.

POTENTIAL ROLE OF AI AND RADIOMICS IN CARDIAC IMAGING

CME Session

2



October 20
12:00 - 13:30

CHRISTOPH RISCHPLER (ESSEN, GERMANY)

Myocardial perfusion imaging using SPECT remains one of the most frequently performed examinations in nuclear medicine. This fact and the fact that the examination protocols are often standardised make this application and nuclear cardiology in general particularly interesting for AI and radiomics (1).

One of the first applications of AI is likely to be to facilitate the work of doctors by relieving them of tedious and time-consuming steps. Possible promising applications in this field are the automatic determination of the valve plane during the reangulation of reconstructed image data (2). Even a fully automated evaluation of image data has already been described, which provides similarly good results compared to an assessment by experts (3). Furthermore, there are approaches to evaluate the image data together with other parameters

that arise in the clinic or during the examination (such as symptoms, ECG abnormalities or pump function in SPECT) in order to improve the diagnosis of obstructive coronary artery disease (4). Last but not least, there are first studies that evaluated the possibility of a prognostic prediction by means of AI with regard to the occurrence of e.g., major adverse cardiac events (MACE) with the aid of image data and other clinical parameters. In contrast to humans, who mainly evaluate the acquired imaging data, AI allows for the integration of a large number of different parameters. Initial studies show that the AI approach may thus be superior to humans in terms of predicting MACE (5).

This lecture will discuss these and other promising fields of application in nuclear cardiology and thus possibly provide a glimpse into the future.

References:

1. Nensa F, Demircioglu A, Rischpler C. Artificial Intelligence in Nuclear Medicine. *J Nucl Med.* 2019 Sep;60(Suppl 2):29S-37S.
2. Betancur J, Rubeaux M, Fuchs TA, Otaki Y, Arnsen Y, Slipczuk L, et al. Automatic Valve Plane Localization in Myocardial Perfusion SPECT/CT by Machine Learning: Anatomic and Clinical Validation. *J Nucl Med.* 2017 Jun;58(6):961-7.
3. Arsanjani R, Xu Y, Hayes SW, Fish M, Lemley M, Gerlach J, et al. Comparison of fully automated computer analysis and visual scoring for detection of coronary artery disease from myocardial perfusion SPECT in a large population. *Journal of Nuclear Medicine.* 2013;54(2):221-8.
4. Arsanjani R, Dey D, Khachatryan T, Shalev A, Hayes SW, Fish M, et al. Prediction of revascularization after myocardial perfusion SPECT by machine learning in a large population. *J Nucl Cardiol.* 2015 Oct;22(5):877-84.
5. Betancur J, Otaki Y, Motwani M, Fish MB, Lemley M, Dey D, et al. Prognostic Value of Combined Clinical and Myocardial Perfusion Imaging Data Using Machine Learning. *J Am Coll Cardiol Img.* 2018 Jul 2;11(7):1000-9.

WHAT MAY THE COMBINATION OF RADIOMICS AND DEEP LEARNING BRING TO SPECT AND PET OF THE BRAIN?

REFERS TO CME TALK: WHAT MAY AI AND RADIOMICS BRING IN NEUROIMAGING?

CME Session

2



October 20
12:00 - 13:30

 RALPH BUCHERT (HAMBURG, GERMANY)

Radiomics is based on the extraction of quantitative features from medical images and the subsequent mathematical analysis of these features to support the interpretation of the images [1]. The quantitative features used in radiomics often have a clear interpretation such as size, shape and textural features of structures in the image. The mathematical analysis of the extracted features often is based on statistical models derived by machine learning methods such as support vector machines.

Deep learning is an umbrella term for machine learning methods based on deep artificial neural networks with multiple layers resulting in a very large number of trainable parameters [2]. Fully data-driven approaches with deep convolutional neural networks (CNN) work end-to-end with no human knowledge built in, that is, without prior feature extraction (“image in, result out”). The CNN itself learns the relevant features from a sufficiently large number of training cases. Fully data-driven deep CNN have outperformed

conventional machine learning methods with engineered features in many medical imaging tasks [3]. However, deep CNN are often considered black-box models so that improved performance comes at the price of reduced transparency. Deep CNN can also be used for the mathematical analysis of radiomics features extracted from the medical images in a pre-processing step.

This talk will discuss strengths and limitations of radiomics and deep CNN in radionuclide brain imaging using the example of dopamine transporter SPECT in the diagnosis of clinically uncertain parkinsonian syndromes [4]. Particular emphasis will be placed on stability of the models with respect to variable site-, camera- or scan-specific image characteristics (“domain adaption”) [5] and on model transparency (“explainable AI”). Finally, the utility of using deep CNN for the analysis of predefined radiomic features will be discussed.

References:

1. Gillies RJ, Kinahan PE, Hricak H (2016) Radiomics: Images Are More than Pictures, They Are Data. *Radiology* 278, 563-577.
2. LeCun Y, Bengio Y, Hinton G (2015) Deep learning. *Nature* 521, 436-444.
3. Litjens G, Kooi T, Bejnordi BE, Setio AAA, Ciompi F, Ghafoorian M, van der Laak J, van Ginneken B, Sanchez CI (2017) A survey on deep learning in medical image analysis. *Med Image Anal* 42, 60-88.
4. Buchert R, Buhmann C, Apostolova I, Meyer PT, Gallinat J (2019) Nuclear Imaging in the Diagnosis of Clinically Uncertain Parkinsonian Syndromes. *Dtsch Arztebl Int* 116, 747-754.
5. Wenzel M, Milletari F, Kruger J, Lange C, Schenk M, Apostolova I, Klutmann S, Ehrenburg M, Buchert R (2019) Automatic classification of dopamine transporter SPECT: deep convolutional neural networks can be trained to be robust with respect to variable image characteristics. *Eur J Nucl Med Mol Imaging* 46, 2800-2811.

CME SESSION 3

CME SESSION

The Battle Continues -
WBC Scan vs FDG PET/CT

3

RADIOLABELLED WBC FOR MUSCULOSKELETAL INFECTIONS - PROS AND CONS

CME Session

3



October 20
16:15 - 17:45

 EDEL NORIEGA-ÁLVAREZ (CIUDAD REAL, SPAIN)

Musculoskeletal infections represent a serious medical challenge in healthcare, as establishing a correct diagnosis can be very complicated, and the spread of infection or sepsis can be life-threatening. In addition, these pathologies have a high morbidity and treatment can have a major impact on daily life, sometimes requiring prolonged surgeries that can lead to amputation in some cases^{1,2}. Since laboratory tests are relatively non-specific, imaging explorations are necessary to obtain the correct diagnosis, although morphological alterations take time to appear on radiological studies. For this reason, the different modalities of nuclear medicine are important as they provide functional/metabolic information in early stages of the disease, often before morphological changes appear³. They allow to study the pathophysiology of these processes and play an important role in the diagnosis, characterisation, and monitoring of musculoskeletal infectious diseases. Although PET/CT is emerging as a diagnostic tool in

musculoskeletal infection/inflammation, white blood cell scintigraphy (WBC) currently remains as the gold standard in nuclear medicine when infection is suspected, which is decisive for the differential diagnosis of infection/inflammation in peripheral osteomyelitis, diabetic foot, periprosthetic infection, etc⁴. In addition, the use of SPECT/CT provides the possibility to acquire anatomical and functional images in the same study improving the sensitivity and specificity of planar images, with better localization and relevant anatomical data for surgical treatment planning, obtaining detailed knowledge of bone status, implant integrity, as well as distribution/extension of infection with a sensitivity of 100% and a specificity of 89-97%⁵.

This presentation reveals the role of the WBC with its advantages/disadvantages and clinical indications, to achieve an adequate diagnosis of infection and inflammation.

References:

1. Gludemans AW, Prandini N, Di Girolamo M, Argento G, Lauri C, Lazzeri E, et al. Hybrid imaging of musculoskeletal infections. *Q J Nucl Med Mol Imaging*. 2018;62:3-13.
2. Signore A, Jamar F, Israel O, Buscombe J, Martin-Comin J, Lazzeri E. Clinical indications, image acquisition and data interpretation for white blood cells and anti-granulocyte monoclonal antibody scintigraphy: an EANM procedural guideline. *Eur J Nucl Med Mol Imaging*. 2018;45:1816-31.
3. Noriega-Álvarez E, Domínguez Gadea L, Orduña Díez MP, Peiró Valgañón V, Sanz Viedma S, García Jiménez R. Role of Nuclear Medicine in the diagnosis of musculoskeletal infection: a review. *Rev Esp Med Nucl Imagen Mol*. 2019;38:397-407.
4. Signore A, Sconfienza LM, Borens O, Gludemans AWJM, Cassar-Pullicino V, Trampuz A, et al. Consensus document for the diagnosis of prosthetic joint infections: a joint paper by the EANM, EBJIS, and ESR (with ESCMID endorsement). *Eur J Nucl Med Mol Imaging*. 2019;46:971-88.
5. Govaert GA, Ijpma FF, McNally M, McNally E, Reininga IH, Gludemans AW. Accuracy of diagnostic imaging modalities for peripheral post-traumatic osteomyelitis - a systematic review of the recent literature. *Eur J Nucl Med Mol Imaging*. 2017;44:1393-407.

FDG-PET FOR MUSCULOSKELETAL INFECTIONS - PROS AND CONS

CME Session

3



October 20
16:15 - 17:45

ZOHAR KEIDAR (HAIFA, ISRAEL)

Musculoskeletal infections are a serious health condition which is difficult to diagnose. Treatment of a musculoskeletal infection often requires a long time and/or costly procedures which can be avoided if musculoskeletal infection is excluded. Timely identification and precise localization of musculoskeletal infections by imaging techniques are critical for early initiation of treatment and can have a significant impact on patient outcome. Nuclear medicine plays a significant role in the evaluation of infection. While bone and labeled WBC scans are used traditionally for the investigation of bone infection, the contribution of FDG PET/CT in patients with suspicious musculoskeletal infections was also established. 18F-FDG is transported into cells via glucose transporters and is phosphorylated by hexokinase but not metabolized further. In infection and inflammation processes, there is an increased

number and expression of glucose transporters by activated inflammatory cells and an increased affinity of these transporters for 18F-FDG. PET/CT is a relatively high-resolution imaging test that provides precise radiopharmaceutical localization. The diagnostic performance of FDG PET or PET/CT was shown to be excellent in different groups of patients with suspicious osteomyelitis including patients with diabetic foot complications, hip and knee prosthetic infections and infectious spondylodiscitis. Overall, based on the available evidence, FDG PET/CT is considered as a good diagnostic tool for the detection of musculoskeletal infections. This CME presentation will provide a review of the current role of FDG PET/CT in the investigation of musculoskeletal infections, strengths, weaknesses, pitfalls and advantages over other imaging modalities.

References:

1. Iyengar KP, Jain VK, Awadalla Mohamed MK, Vaishya R, Vinjamuri S. Update on functional imaging in the evaluation of diabetic foot infection. *J Clin Orthop Trauma*. 2021 Jan 11;16:119-124.
2. Romanò CL, et al. The Role of Imaging Techniques to Define a Peri-Prosthetic Hip and Knee Joint Infection: Multidisciplinary Consensus Statements. *J Clin Med*. 2020.
3. Lauri C, Leone A, Cavallini M, Signore A, Giurato L, Uccioli L. Diabetic Foot Infections: The Diagnostic Challenges. *J Clin Med*. 2020 Jun; 9(6): 1779.
4. Treglia G. Diagnostic Performance of 18F-FDG PET/CT in Infectious and Inflammatory Diseases according to Published Meta-Analyses. *Contrast Media Mol Imaging*. 2019; 2019: 3018349.
5. Sollini M, Trenti N, Malagoli E, Catalano M, Di Mento L, Kirienko A, Berlusconi M, Chiti A, Antunovic L. [18F]FDG PET/CT in non-union: improving the diagnostic performances by using both PET and CT criteria. *Eur J Nucl Med Mol Imaging*. 2019 Jul;46(8):1605-1615.
6. Govaert GA, Ijzma FF, McNally M, McNally E, Reininga IH, Glaudemans AW. Accuracy of diagnostic imaging modalities for peripheral post-traumatic osteomyelitis - a systematic review of the recent literature. *Eur J Nucl Med Mol Imaging*. 2017 Aug;44(8):1393-1407.
7. Palestro CJ. Molecular Imaging of Infection: The First 50 Years. *Semin Nucl Med*. 2020 Jan;50(1):23-34.
8. Kulkarni SC, Padma S, Shanmuga Sundaram P. In the evaluation of patients with skull base osteomyelitis, does 18F-FDG PET CT have a role? *Nucl Med Commun*. 2020 Jun;41(6):550-559.

RADIOLABELLED WBC FOR CARDIOVASCULAR INFECTIONS - PROS AND CONS

CME Session

3



October 20
16:15 - 17:45

FRANÇOIS ROUZET (PARIS, FRANCE)

For a long time, radiolabelled white blood cells (WBC) SPECT/CT has been regarded as the mainstay of imaging in chronic infection of bones and joints. Thereafter, the technique has been applied to cardiovascular infections with consistently high specificity in the following settings:

1 - Prosthetic vascular graft infections: many studies support the excellent diagnostic value of WBC scintigraphy in this indication, with both excellent sensitivity and specificity.

2 - Infective endocarditis: studies that enrolled patients suspected of endocarditis on either native or prosthetic valves showed very good performances^{1, 2, 3}.

3 - Cardiac Implantable Electronic Devices (CIED) and Left Ventricular Assist Device (LVAD) infections: A large body of literature supports the use of WBC SPECT/CT to improve the diagnostic performances of the Duke-Li score, particularly when CIED infection was initially graded as possible⁴.

Consequently, WBC SPECT/CT is now part of the

diagnostic flowchart in European guidelines for infective endocarditis and CIEDs infections^{5,6}. In some clinical situations such as short delay after cardiac surgery, presence of surgical adhesives, intense host reaction against prosthetic material, the excellent specificity of WBC SPECT/CT allows to overcome the risk of false-positives that may occur with FDG PET.

However, the scan suffers some limitations. First of all the labelling procedure is long, cumbersome and requires a specific lab approved by health authorities due to the handling of blood products. In addition, the long acquisition procedure can be uncomfortable for patients in poor general condition. Third, the diagnostic sensitivity is somewhat lower compared to FDG PET/CT. Taken together, these limitations mean that WBC SPECT/CT should be considered a second line test after inconclusive FDG PET/CT⁷ most commonly. Finally, careful interpretation as well as early imaging in the course of the disease are critical to avoid false negative results and to achieve maximal impact on patients' management.

References:

1. Erba PA et al, J Nucl Med 2012; 53:1235-1243
2. Rouzet F et al, J Nucl Med 2014; 55:1980-1985
3. Holcman K et al, The International Journal of Cardiovascular Imaging (2019) 35:749-758
4. Calais J et al, Circ Cardiovasc Imaging 2019 Jul;12(7):e007188.
5. Habib G et al, European Heart Journal 36, 3075-3128
6. Blomström-Lundqvist C et al, Eur Heart J. 2020 Jun 1;41(21):2012-2032
7. Erba PA et al, Eur J Nucl Med Mol Imaging. 2018 Sep;45(10):1795-1815

FDG-PET FOR CARDIOVASCULAR INFECTIONS - PROS AND CONS

CME Session

3



October 20
16:15 - 17:45

LUCIA LECCISOTTI (ROME, ITALY)

Cardiovascular infections include a group of conditions associated with significant morbidity and mortality and involve a relevant burden of diagnostic workup. Early and accurate diagnosis is crucial for adequate patient management. FDG-PET is a well-established imaging modality in cardiovascular infection diagnosis. It is included in the investigation algorithms of different cardiovascular infections and is often performed in complex cases. In addition to defining the presence and extent of cardiovascular infection, whole body FDG-PET can demonstrate extra-cardiac embolic foci of infection or a primary source of infection. The use of FDG-PET for the

assessment of response to treatment in cardiovascular infections is also increasing over the years. However, interpretation of these studies can be challenging in light of possible false positive or negative cases and, occasionally, due to reader's unfamiliarity with typical cardiovascular findings.

The objective of this presentation is to review the current role, diagnostic criteria, optimal protocol and pitfalls of FDG-PET imaging in several clinical scenarios related to cardiovascular infections such as prosthetic and native valve, cardiac implantable electronic device, left ventricular assist device and vascular graft.

References:

1. Habib G, Lancellotti P, Antunes MJ et al. 2015 ESC Guidelines for the management of infective endocarditis: The Task Force for the Management of Infective Endocarditis of the European Society of Cardiology (ESC). Endorsed by: European Association for Cardio-Thoracic Surgery (EACTS), the European Association of Nuclear Medicine (EANM). *Eur Heart J*. 2015 Nov 21;36(44):3075-3128.
2. Jamar F, Buscombe J, Chiti A et al. EANM/SNMMI guideline for 18F-FDG use in inflammation and infection. *J Nucl Med*. 2013 Apr;54(4):647-58.
3. Chakfé N, Diener H, Lejay A et al. Editor's Choice - European Society for Vascular Surgery (ESVS) 2020 Clinical Practice Guidelines on the Management of Vascular Graft and Endograft Infections. *Eur J Vasc Endovasc Surg*. 2020 Mar;59(3):339-384.
4. Slart RHJA, Glaudemans AWJM, Gheysens O et al. 4Is Cardiovascular Imaging: a joint initiative of the European Association of Cardiovascular Imaging (EACVI); European Association of Nuclear Medicine (EANM). Procedural recommendations of cardiac PET/CT imaging: standardization in inflammatory-, infective-, infiltrative-, and innervation (4Is)-related cardiovascular diseases: a joint collaboration of the EACVI and the EANM. *Eur J Nucl Med Mol Imaging*. 2021 Apr;48(4):1016-1039.
5. Martineau P, Grégoire J, Harel F, et al. Assessing cardiovascular infection and inflammation with FDG-PET. *Am J Nucl Med Mol Imaging*. 2021 Feb 15;11(1):46-58.
6. Pelletier-Galarneau M, Abikhzer G, Harel F et al. Detection of Native and Prosthetic Valve Endocarditis: Incremental Attributes of Functional FDG PET/CT over Morphologic Imaging. *Curr Cardiol Rep*. 2020 Jul 9;22(9):93.
7. Mahmood M, Abu Saleh O. The Role of 18-F FDG PET/CT in Imaging of Endocarditis and Cardiac Device Infections. *Semin Nucl Med*. 2020 Jul;50(4):319-330.

CME SESSION 4

CME SESSION

4

Imaging Neuroinflammation -
Everything You Always
Wanted to Know,
But Were Afraid to Ask

BACKGROUND OF TSPO AND NON-TSPO TARGETS AND THEIR RADIOTRACERS

CME Session

4



October 20
18:00 - 19:30

MATTHIAS BRENDDEL (MUNICH, GERMANY)

This CME talk provides the molecular background of neuroinflammation radiotracer targets. A focus will be placed on the translocator protein (TSPO) and its known roles in cell biology and pathophysiology of neuroinflammatory diseases¹. Advantages and disadvantages of TSPO as a tracer target in neuroinflammatory conditions will be outlined according to the biological background. Moreover, the talk will provide an overview on existing TSPO PET tracers and their sensitivity to the rs6971

polymorphism. Established and recently explored non-TSPO targets² of neuroinflammation such as monoaminoxidases, cyclooxygenases³ and triggering receptor expressed on myeloid cells 2 (TREM2)⁴ will be outlined. Here, details of the talk will highlight gene expression and neuropathological findings⁵ related to non-TSPO targets in neurodegenerative diseases and other neuroinflammatory conditions. Novel opportunities to uncover the specificity of neuroinflammation tracers will be highlighted.

References:

1. Rupprecht R, Papadopoulos V, Rammes G, Baghai TC, Fan J, Akula N et al. Translocator protein (18 kDa)(TSPO) as a therapeutic target for neurological and psychiatric disorders. *Nature reviews Drug discovery* 2010; 9(12): 971.
2. Narayanaswami V, Dahl K, Bernard-Gauthier V, Josephson L, Cumming P, Vasdev N. Emerging PET Radiotracers and Targets for Imaging of Neuroinflammation in Neurodegenerative Diseases: Outlook Beyond TSPO. *Mol Imaging* 2018; 17: 1536012118792317.
3. Shrestha S, Kim MJ, Eldridge M, Lehmann ML, Frankland M, Liow JS et al. PET measurement of cyclooxygenase-2 using a novel radioligand: upregulation in primate neuroinflammation and first-in-human study. *Journal of neuroinflammation* 2020; 17(1): 140.
4. Suarez-Calvet M, Kleinberger G, Araque Caballero MA, Brendel M, Rominger A, Alcolea D et al. sTREM2 cerebrospinal fluid levels are a potential biomarker for microglia activity in early-stage Alzheimer's disease and associate with neuronal injury markers. *EMBO Mol Med* 2016; 8(5): 466-476.
5. Tong J, Rathitharan G, Meyer JH, Furukawa Y, Ang LC, Boileau I et al. Brain monoamine oxidase B and A in human parkinsonian dopamine deficiency disorders. *Brain : a journal of neurology* 2017; 140(9): 2460-2474.

IMAGING NEUROINFLAMMATION WITH TSPO LIGANDS - A CRITICAL REAPPRAISAL

CME Session

4



October 20
18:00 - 19:30

 **BART VAN BERCKEL (AMSTERDAM, NETHERLANDS)**

In vivo imaging of neuroinflammation with TSPO receptors (previously called PBR receptors) has been an active research topic in nuclear medicine for almost 50 years. Although substantial progress has been made, the field is still struggling with the question which tracer and quantitative method to use and for which clinical indications. In this CME

talk, we would like to go back to basics and review the steps that have to be taken to validate new PET tracers “from benchtop to bedside”. We will apply this pathway to the development of TSPO tracers and provide a review of the level of validation of current TSPO tracers. Specific TSPO imaging related caveats will be discussed.

References:

1. Meyer JH, Cervenka S, Kim MJ, Kreisl WC, Henter ID, Innis RB. Neuroinflammation in psychiatric disorders: PET imaging and promising new targets. *Lancet Psychiatry* 2020 Dec;7(12):1064-1074.
2. Kreisl WC, Kim MJ, Coughlin JM, Henter ID, Owen DR, Innis RB. PET imaging of neuroinflammation in neurological disorders. *Lancet Neurol*. 2020 Nov;19(11):940-950.
3. Wu C, Pike VW, Wang Y. Amyloid imaging: from benchtop to bedside. *Curr Top Dev Biol*. 2005;70:171-213.

IMAGING NEUROINFLAMMATION - BEYOND TSPO

CME Session

4



October 20
18:00 - 19:30

 DONATIENNE VAN WEEHAEGHE (LEUVEN, BELGIUM)

Neuroinflammation involves glial activation (astrocytes, oligodendrocytes and microglia) and infiltration of peripheral immune cells such as macrophages, monocytes and neutrophils. TSPO radioligands are currently the most widely used radioligands to visualize neuroinflammation, however they have some drawbacks. Also, the cellular source of neuroinflammation may differ across different diseases and in the different stages of the disease. For example, in amyotrophic lateral sclerosis a temporal pattern of glial type TSPO expression exists: in early phase most TSPOs are expressed on microglia, whereas this may shift to astrocytes in later phases of the disease [1]. So non-TSPO neuroinflammation-related radioligands targeting the entire range of immune cells are needed.

We will discuss the following neuroinflammation-related targets [2, 3]

- monoamine oxidase-B, mainly located in astrocytes

- cyclooxygenase, the rate limiting enzyme in the formation of prostaglandins from arachidonic acid

- the cannabinoid-2 receptor and colony-stimulating factor 1 receptor colocalized mainly with microglia

- the chemokine receptor CX3CR1 expressed in lymphocytes and microglia

- the purinergic receptors: P2X7 expressed on pro-inflammatory microglia and P2Y12 expressed on anti-inflammatory

- adaptive immune-cell imaging biomarkers as central nervous system-infiltrating B cells are key drivers of maladaptive immune responses in for instance multiple sclerosis

In this session we will focus on different non-TSPO radioligands with their respective cellular targets and the relevance in different diseases.

References:

1. Guilarte TR: TSPO in diverse CNS pathologies and psychiatric disease: A critical review and a way forward. *Pharmacol Ther* 2019, 194:44-58.
2. Jain P, Chaney AM, Carlson ML, Jackson IM, Rao A, James ML: Neuroinflammation PET Imaging: Current Opinion and Future Directions. *J Nucl Med* 2020, 61(8):1107-1112.
3. Narayanaswami V, Dahl K, Bernard-Gauthier V, Josephson L, Cumming P, Vasdev N: Emerging PET Radiotracers and Targets for Imaging of Neuroinflammation in Neurodegenerative Diseases: Outlook Beyond TSPO. *Mol Imaging* 2018, 17:1536012118792317.
4. Suarez-Calvet M, Kleinberger G, Araque Caballero MA, Brendel M, Rominger A, Alcolea D et al. sTREM2 cerebrospinal fluid levels are a potential biomarker for microglia activity in early-stage Alzheimer's disease and associate with neuronal injury markers. *EMBO Mol Med* 2016; 8(5): 466-476.
5. Tong J, Rathitharan G, Meyer JH, Furukawa Y, Ang LC, Boileau I et al. Brain monoamine oxidase B and A in human parkinsonian dopamine deficiency disorders. *Brain : a journal of neurology* 2017; 140(9): 2460-2474.

CME SESSION 5

CME SESSION

5

Inflammation, Infection and
Infiltrative Cardiovascular
Diseases - Think Nuclear!

CARDIAC SARCOIDOSIS

CME Session

5



October 21
09:00 - 10:30

 OLIVIER GHEYSSENS (BRUSSELS, BELGIUM)

Sarcoidosis is a systemic granulomatous disorder of unknown etiology characterized by significant clinical heterogeneity. Symptomatic cardiac involvement occurs in 2-5% of patients with systemic sarcoidosis and the clinical presentation (conduction abnormalities, tachy-bradyarrhythmia and heart failure) is dependent on the disease location, extent and activity. However, autopsy and imaging studies report a substantially higher prevalence of cardiac involvement ranging from 25% in North America to more than 50% in Japan. In addition, isolated cardiac sarcoidosis may be more prevalent than reported with estimates of 20%. Importantly, patients with cardiac involvement have a poorer prognosis and cardiac sarcoidosis (CS) account for up to 25 % of disease-related deaths.

The diagnosis of CS remains very challenging due to the non-specific clinical presentation and

the focal infiltration of the heart hereby limiting the diagnostic utility of endomyocardial biopsies. Several diagnostic criteria have been proposed with the most recent being the 2016 guidelines of the Japanese Circulation Society and the 2014 Heart Rhythm Society (HRS) criteria. Based on the available data [¹⁸F]FDG-PET/CT imaging is now included in both criteria as a useful technique to investigate suspected cardiac sarcoidosis. [¹⁸F]FDG-PET/CT combined with perfusion imaging to detect both inflammation and fibrous replacement of the myocardium provides important diagnostic and prognostic information and serves as a valuable tool to monitor treatment response.

This CME presentation will provide an overview of the current role of nuclear imaging in the diagnosis and management of patients with cardiac sarcoidosis.

References:

1. Okada DR et al. Isolated cardiac sarcoidosis: A focused review of an under-recognized entity. *J Nucl Cardiol.* 2018;25:1136-46.
2. Terasaki F, Yoshinaga K. New Guidelines for Diagnosis of Cardiac Sarcoidosis in Japan. *Ann Nucl Cardiol.* 2017;3:42-5.
3. Birnie DH et al. HRS Expert Consensus Statement on the Diagnosis and Management of Arrhythmias Associated With Cardiac Sarcoidosis. *Heart Rhythm.* 2014;11:1304-23.
4. Slart RHJA et al. A joint procedural position statement on imaging in cardiac sarcoidosis: From the Cardiovascular and Inflammation & Infection Committees of the EANM, the EACVI and the ASNC. *Eur Heart J Cardiovasc Imaging.* 2017;18:1073-89.
5. Osborne MT et al. Reduction in ¹⁸F-fluorodeoxyglucose uptake on serial cardiac positron emission tomography is associated with improved left ventricular ejection fraction in patients with cardiac sarcoidosis. *J Nucl Cardiol.* 2014;21:166-74.
6. Blankstein R et al. Cardiac Positron Emission Tomography Enhances Prognostic Assessments of Patients With Suspected Cardiac Sarcoidosis. *J Am Coll Cardiol.* 2014;63:329-36.
7. Kim S-J, Pak K, Kim K. Diagnostic performance of F-18 FDG PET for detection of cardiac sarcoidosis; A systematic review and meta-analysis. *J Nucl Cardiol.* 2020;27:2103-15.

THE ROLE OF NUCLEAR MEDICINE IN CARDIAC AMYLOIDOSIS

REFERS TO CME TALK: CARDIAC AMYLOIDOSIS

CME Session

5



October 21
09:00 - 10:30

 TANJA KERO (UPPSALA, SWEDEN)

Amyloidosis is a systemic disease in which different types of misfolded proteins, amyloid fibrils, are deposited extracellularly in various tissues, leading to progressive organ dysfunction (1). Radionuclide imaging plays a unique role in the non-invasive diagnosis of cardiac amyloidosis. ^{99m}Tc-labeled bone-seeking tracers (^{99m}Tc-PYP, -DPD and -HMDP) have been used for decades and have an established role in the diagnosis of ATTR cardiac amyloidosis (2). However, the uptake of the bone-seeking tracers is related to the patients' transthyretin amyloid fibril composition and can be negative in certain types of hereditary ATTR (3), they cannot be used in imaging of cardiac AL and they have not proven useful for

assessment of disease progression (4). Amyloid-binding PET tracers (¹¹C-PIB, ¹⁸F-florbetapir and ¹⁸F-florbetaben) can reliably image both AL and ATTR cardiac amyloidosis (5), including ATTRv where bone-seeking SPECT tracers have been negative (6) and the PET tracers can more readily be used in quantification of the amyloid deposits. Radionuclide imaging has also been used in assessment of pathophysiology in cardiac amyloidosis: ¹²³I-mIBG has shown sympathetic cardiac denervation in patients with ATTR (7), PET myocardial perfusion imaging have shown reduced stress myocardial blood flow (8) and ¹¹C-acetate PET has shown impaired myocardial oxidative metabolism and external efficiency (9).

References:

1. Merlini G, Bellotti V. Molecular mechanisms of amyloidosis. *N Eng J Med.* 2003;349(6):583-96.
2. Dorbala S, Ando Y, et al. ASNC/AHA/ASE/EANM/HFSA/ISA/SCMR/SNMMI expert consensus recommendations for multimodality imaging in cardiac amyloidosis: Part 1 of 2-evidence base and standardized methods of imaging. *J Nucl Cardiol.* 2019;26(6):2065-123.
3. Pilebro B, Suhr OB, et al. (^{99m}Tc)-DPD uptake reflects amyloid fibril composition in hereditary transthyretin amyloidosis. *Ups J Med Sci.* 2016;121(1):17-24.
4. Castano A, DeLuca A, et al. Serial scanning with technetium pyrophosphate (^{99m}Tc-PYP) in advanced ATTR cardiac amyloidosis. *J Nucl Cardiol.* 2016;23(6):1355-63.
5. Kim YJ, Ha S, Kim YI. Cardiac amyloidosis imaging with amyloid positron emission tomography: A systematic review and meta-analysis. *J Nucl Cardiol.* 2020;27(1):123-32.
6. Pilebro B, Arvidsson S, et al. Positron emission tomography (PET) utilizing Pittsburgh compound B (PIB) for detection of amyloid heart deposits in hereditary transthyretin amyloidosis (ATTR). *J Nucl Cardiol.* 2018;25(1):240-8.
7. Slart R, Glaudemans A, et al. Imaging cardiac innervation in amyloidosis. *J Nucl Cardiol.* 2019;26(1):174-87.
8. Dorbala S, Vangala D, et al. Coronary microvascular dysfunction is related to abnormalities in myocardial structure and function in cardiac amyloidosis. *JACC Heart failure.* 2014;2(4):358-67.
9. Clemmensen TS, Soerensen J, et al. Myocardial Oxygen Consumption and Efficiency in Patients With Cardiac Amyloidosis. *J Am Heart Assoc.* 2018;7(21):e009974.

ENDOCARDITIS

CME Session

5



October 21
09:00 - 10:30

 ASBJØRN M. SCHOLTENS (AMERSFOORT, NETHERLANDS)

Endocarditis is an infection of the inner lining of the heart. Its initial presentation is diverse with non-specific symptoms such as fever and malaise, and diagnosis can be challenging. The presence of prosthetic materials (e.g. valve replacements, grafts and implantable devices and associated leads) is a predisposing factor.

In the past years a growing body of evidence has cemented the role of ¹⁸F-FDG PET/CT for the diagnosis of endocarditis, especially in challenging cases and when prosthetic material is present.

In native valve endocarditis, ¹⁸F-FDG PET/CT has a relatively poor sensitivity for valve infection in the order of 30%^{1,2}, but is of value in diagnosing metastatic infectious foci and portes d'entrée.

In prosthetic valve endocarditis, ¹⁸F-FDG PET/CT is more accurate in diagnosing valve infection with a pooled sensitivity of 86% in a recent meta-analysis³.

In endocarditis involving implantable electronic devices, the pooled sensitivity was 72%³ although lead endocarditis is more difficult to diagnose than device pocket infection.

For correct interpretation of findings it is important to be aware of a number of known confounders^{4,5}, and in cases where ¹⁸F-FDG PET/CT is equivocal radiolabeled leukocyte scintigraphy can be of additional value⁶.

Multimodality imaging including echocardiography and CT angiography is almost always involved in endocarditis, and an “endocarditis team” consisting of cardiologists, cardiac surgeons, microbiologists and imaging specialists working together is recommended to ensure swift diagnosis and treatment⁷.

References:

1. Albano et al. *JACC Cardiovasc Imaging*. 2021 May;14(5):1063-1065. doi: 10.1016/j.jcmg.2020.09.021.
2. Kamani et al. *Diagnostics (Basel)*. 2020 Sep 25;10(10):754. doi: 10.3390/diagnostics10100754.
3. Wang et al. *Circ Cardiovasc Imaging*. 2020 Jun;13(6):e010600. doi: 10.1161/CIRCIMAGING.120.010600.
4. Scholtens et al. *JACC Cardiovasc Imaging*. 2016 Dec;9(12):1462-1465. doi: 10.1016/j.jcmg.2016.01.024.
5. Scholtens et al. *J Nucl Cardiol*. 2018 Dec;25(6):2172-2173. doi: 10.1007/s12350-017-1176-5.
6. Rouzet et al. *J Nucl Med*. 2014 Dec;55(12):1980-5. doi: 10.2967/jnumed.114.141895.
7. Hyafil et al. *J Nucl Cardiol*. 2017 Feb;24(1):207-211. doi: 10.1007/s12350-015-0369-z.

VASCULITIS

CME Session

5



October 21
09:00 - 10:30

LARS CHRISTIAN GORMSEN (AARHUS, DENMARK)

Large vessel vasculitis (LVV) is increasingly recognized as a common systemic inflammatory disease with considerable morbidity and mortality. The most prevalent forms of LVV are Giant Cell Arteritis (GCA), and Takayasu's Arteritis (TA), both of which cause progressive luminal narrowing of large arteries with subsequent tissue ischemia and constitutional and/or localized symptoms. In LVV and TA, the vessel walls are infiltrated by glucose consuming macrophages and can therefore be readily visualized by 18F-Fluorodeoxyglucose (FDG) PET/CT (1). However, the disease burden, severity and extent at presentation vary greatly, and timely treatment by immunosuppressive therapy is necessary to mitigate the complications associated with the disease. These issues pose particular problems for the imaging physician. First, LVV in smaller cranial arteries (c-GCA) surrounded by tissues with at least some FDG uptake may be hard to detect due to poor signal-to-noise ratios (2). Second, the pattern of disease varies

greatly from affecting the entire aortic vasculature to limited segments of the cranial arteries rendering pattern recognition difficult. Third, large vessel low grade inflammation is frequently encountered in older patients with cardiovascular disease making it harder to discriminate between LVV and more benign variants of vascular disease (3). Fourth, newer PET/CT reconstruction algorithms tend to overestimate FDG uptake in smaller structures such as vessel walls (4). Fifth, patients have often been treated with corticosteroids prior to their FDG PET/CT resulting in acutely inhibited macrophage FDG uptake and reduced sensitivity to diagnose LVV (5).

This presentation will therefore focus on the initial diagnosis of LVV including the most frequent patterns of disease, pathology thresholds of vessel wall-background ratios, and the effects of corticosteroid treatment on FDG PET/CT diagnostic accuracy. Finally, some potential image interpretation pitfalls will be highlighted.

References:

1. Nielsen BD, Gormsen LC. 18F-Fluorodeoxyglucose PET/Computed Tomography in the Diagnosis and Monitoring of Giant Cell Arteritis. *PET Clinics*. 2020;15(2):135-145.
2. Nielsen BD, Hansen IT, Kramer S, et al. Simple dichotomous assessment of cranial artery inflammation by conventional 18F-FDG PET/CT shows high accuracy for the diagnosis of giant cell arteritis: a case-control study. *European journal of nuclear medicine and molecular imaging*. 2019;46(1):184-193
3. van der Valk FM, Verweij SL, Zwinderman KA, et al. Thresholds for Arterial Wall Inflammation Quantified by (18)F-FDG PET Imaging: Implications for Vascular Interventional Studies. *JACC Cardiovascular imaging*. 2016;9(10):1198-1207
4. Munk OL, Tolbod LP, Hansen SB, Bogsrud TV. Point-spread function reconstructed PET images of sub-centimeter lesions are not quantitative. *EJNMMI Phys*. 2017;4(1):
5. Nielsen BD, Gormsen LC, Hansen IT, Keller KK, Therkildsen P, Hauge EM. Three days of high-dose glucocorticoid treatment attenuates large-vessel 18F-FDG uptake in large-vessel giant cell arteritis but with a limited impact on diagnostic accuracy. *European journal of nuclear medicine and molecular imaging*. 2018;45(7):1119-1128.

CME SESSION 6

CME SESSION

6

Quo Vadis PET/MRI?

METHODOLOGICAL DEVELOPMENTS

CME Session

6



October 21
10:45 - 12:15

HARALD H. QUICK (ESSEN, GERMANY)

Whole-body hybrid PET/MR imaging has been used since its introduction in 2010 in clinical and research settings for diagnosis, staging and restaging, assessment of response to treatment, and radiation therapy planning [1]. While clinical application today is at full swing, on the methodological side, PET/MR demanded for new techniques and innovative solutions [2]. Particularly attenuation correction (AC) and scatter correction (SC) have been hot topics of debate and they continue to be [1,2].

Latest methodological developments in PET/MR attenuation and truncation correction help to further improve the robustness of PET/MR examinations and, furthermore, improve quantification of PET data [3-5]. The application of PET/MR in prostate cancer

diagnostics has profited from improved scatter correction methods [6,7]. Recently, deep-learning methods have successfully been used to generate pseudo-CT AC maps from MR data for accurate AC in pelvic imaging applications [8].

The integration of radiofrequency coils with appropriate hardware attenuation correction methods broadens the spectrum of oncologic PET/MR applications further [9]. Recent technical developments aim towards the integration of PET/MR into the concept of radiation therapy treatment planning [10]. This presentation will provide an overview and outlook of the aforementioned current methodological developments.

References:

1. Catana C, Quick HH, Zaidi H. Current commercial techniques for MRI-guided attenuation correction are insufficient and will limit the wider acceptance of PET/MRI technology in the clinic. *Med Phys*. 2018 May 14. doi: 10.1002/mp.12963. [Epub ahead of print].
2. Quick HH. Integrated PET/MR. *J Magn Reson Imaging*. 39:243-58, 2014
3. Paulus DH, Quick HH, Geppert C, et al. Whole-Body PET/MR Imaging: Quantitative Evaluation of a Novel Model-Based MR Attenuation Correction Method Including Bone. *J Nucl Med*. 56:1061-1066, 2015
4. Lindemann ME, Oehmigen M, Blumhagen JO, et al. MR-based truncation and AC in integrated PET/MR hybrid imaging using HUGE with continuous table motion. *Med Phys*. 44:4559-4572, 2017
5. Oehmigen M, Lindemann ME, Gratz M, et al. Impact of improved AC featuring a bone atlas and truncation correction on PET quantification in whole-body PET/MR. *EJNMMI*. 45:642-653, 2018
6. Wangerin KA, Baratto L, Khalighi MM, et al. Clinical evaluation of 68Ga-PSMA-II and 68Ga-RM2 PET images reconstructed with an improved scatter correction algorithm. *AJR*. 211:655-660, 2018
7. Lindemann ME, Guberina N, Wetter A, et al. Improving ⁶⁸Ga-PSMA PET/MRI of the Prostate with Unrenormalized Absolute Scatter Correction. *J Nucl Med*. 60:1642-1648, 2019
8. Torrado-Carvajal A, Vera-Olmos J, Izquierdo-Garcia D, et al. Dixon-VIBE Deep Learning (DIVIDE) Pseudo-CT Synthesis for Pelvis PET/MR Attenuation Correction. *J Nucl Med*. 60:429-435, 2019
9. Oehmigen M, Lindemann ME, Lanz T, Kinner S, Quick HH. Integrated PET/MR breast cancer imaging: Attenuation correction and implementation of a 16-channel RF coil. *Med Phys*. 43:4808-4820, 2016
10. Paulus DH, Oehmigen M, Grüneisen J, Umutlu L, Quick HH. Whole-body hybrid imaging concept for the integration of PET/MR into radiation therapy treatment planning. *Phys Med Biol*. 61:3504-3520, 2016

WHERE DOES PET/MR ENHANCE PET FOR ONCOLOGIC QUESTIONS?

REFERS TO CME TALK: ONCOLOGICAL APPLICATIONS

CME Session

6



October 21
10:45 - 12:15

 IRENE A. BURGER (BADEN, SWITZERLAND)

PET/MR has the potential to introduce new applications for PET imaging. With the increasing number of studies looking into the added value of MRI information for PET examinations molecular imaging with PET/MR can improve not only the local staging but also the assessment of tumor heterogeneity in one exam, examples are:

Primary tumor detection: Initial data showed that PSMA PET/MR can successfully be used to guide biopsies, with a significantly higher specificity compared to mpMRI [1]. Others also confirmed the improved accuracy of PSMA PET/MR over mpMRI for tumor detection [2]. More recent work with direct combination of PSMA PET and mpMRI in correlation with histopathology and immunohistochemistry now allows us to go a step further and increase our understanding of tumor heterogeneity and behavior; this could be the base for further improvement of our diagnostic tools in the detection of prostate cancer.

Improved staging: The superior soft tissue contrast of PET/MR over PET/CT enables an improved T-staging in a variety of tumor entities. Prostate cancer is an example where the added information

of PSMA-PET did even further improve the sensitivity for extracapsular extension or seminal vesicle involvement compared to mpMRI in intermediate to high risk prostate cancer patients [3]. Improved local staging with PET/MR over was also suggested for cervical cancer e.g. with the combination of Radiomics analysis to accurately predict nodal stage [4]. Also in head and neck cancer the improved local assessment of a directly combined PET/MR over PET/CT has been shown in the past. Now new tracers, such as the FAPI ligand have been investigated in this setting as well, showing that FAPI PET/MR might even outperform FDG PET/MR [5].

Improved tumor assessment: Patient selection for therapy is becoming more and more important with the success of internal radiotherapy. An early study combining hepatobiliary MRI contrast with ⁶⁸Ga-DOTATOC showed an improved lesion detection over PET alone, and might in the future be instrumental for the detection of SSTR-2 negative disease that will not respond well to therapy. PET/MR has the potential to become a one-stop shop modality for patient selection for internal radiotherapy.

References:

1. Ferraro DA, et al. Diagnostic performance of (68)Ga-PSMA-11 PET/MRI-guided biopsy in patients with suspected prostate cancer: a prospective single-center study. *Eur J Nucl Med Mol Imaging*. 2021. doi:10.1007/s00259-021-05261-y.
2. Park SY, et al. Gallium 68 PSMA-11 PET/MR Imaging in Patients with Intermediate- or High-Risk Prostate Cancer. *Radiology*. 2018;288:495-505. doi:10.1148/radiol.2018172232.
3. Muehlematter UJ, et al. Diagnostic Accuracy of Multiparametric MRI versus (68)Ga-PSMA-11 PET/MRI for Extracapsular Extension and Seminal Vesicle Invasion in Patients with Prostate Cancer. *Radiology*. 2019;293:350-8. doi:10.1148/radiol.2019190687.
4. Umutlu L, et al. Radiomics Analysis of Multiparametric PET/MRI for N- and M-Staging in Patients with Primary Cervical Cancer. *Rofo*. 2020;192:754-63. doi:10.1055/a-11100-0127.
5. Qin C, et al. A head-to-head comparison of (68)Ga-DOTA-FAPI-04 and (18)F-FDG PET/MR in patients with nasopharyngeal carcinoma: a prospective study. *Eur J Nucl Med Mol Imaging*. 2021. doi:10.1007/s00259-021-05255-w.

BEYOND ONCOLOGICAL APPLICATIONS

CME Session

6



October 21
10:45 - 12:15

ALEXANDER HAMMERS (LONDON, UNITED KINGDOM)

PET-MR was developed with the success of PET-CT in mind, a dual (albeit not simultaneous) modality which had revolutionised oncological imaging from 2000 onwards: for example, the commercially available scanners all have wide bores suitable for body scanning.

However, many centres have seen much if not all their neuroscience (and sometimes clinical neurological) imaging migrate towards simultaneous PET-MR scanners. The underlying reasons are practical (an MRI is virtually always required for research brain PET) and scientific (MR allows truly simultaneous assessment of physiological parameters like blood flow, EEG can be more easily integrated than for PET-CT). Methodological issues like appropriate attenuation correction have largely been addressed (1, 2), and new fields have been facilitated, e.g.

MR-informed PET reconstruction (3). In the neurosciences, simultaneous PET-MR has enabled novel insights that would not previously have been possible to obtain in the same subject at the same time, for example the relationship between blood flow changes and receptor binding time-activity curves (4) and intercomparison between methods (5).

In cardioscience, PET-MR has obvious potential for motion correction which is starting to be exploited (e.g. 6). Novel fields include inflammation (brain, vessels, musculoskeletal).

Across all fields, machine learning supported by artificial intelligence is making inroads, particularly around the technical aspects (attenuation (2) and motion correction, ultra-low-dose imaging). It is to be expected that this will be extended to parametric mapping and clinical questions.

References:

1. A multi-centre evaluation of eleven clinically feasible brain PET/MRI attenuation correction techniques using a large cohort of patients. Ladefoged CN, Law I, Anazodo U, St Lawrence K, Izquierdo-Garcia D, Catana C, Burgos N, Cardoso MJ, Ourselin S, Hutton B, Mérida I, Costes N, Hammers A, Benoit D, Holm S, Juttukonda M, An H, Cabello J, Lukas M, Nekolla S, Ziegler S, Fenchel M, Jakoby B, Casey ME, Benzinger T, Højgaard L, Hansen AE, Andersen FL. *Neuroimage*. 2017 Feb 15;147:346-359.
2. AI-driven attenuation correction for brain PET/MRI: Clinical evaluation of a dementia cohort and importance of the training group size. Ladefoged CN, Hansen AE, Henriksen OM, Bruun FJ, Eikenes L, Øen SK, Karlberg A, Højgaard L, Law I, Andersen FL. *Neuroimage*. 2020 Nov 15;222:117221.
3. Intercomparison of MR-informed PET image reconstruction methods. Bland J, Mehranian A, Belzunce MA, Ellis S, da Costa-Luis C, McGinnity CJ, Hammers A, Reader AJ. *Med Phys*. 2019 Nov;46(11):5055-5074.
4. [¹¹C]PBR28 radiotracer kinetics are not driven by alterations in cerebral blood flow. Sander CY, Bovo S, Torrado-Carvajal A, Albrecht D, Deng H, Napadow V, Price JC, Hooker JM, Loggia ML. *J Cereb Blood Flow Metab*. 2021 Jun 23:271678X211023387
5. Reliability of task-specific neuronal activation assessed with functional PET, ASL and BOLD imaging. Rischka L, Godbersen GM, Pichler V, Michenthaler P, Klug S, Klöbl M, Ritter V, Wadsak W, Hacker M, Kasper S, Lanzenberger R, Hahn A. *J Cereb Blood Flow Metab*. 2021 Jun 2:271678X211020589
6. MR-guided motion-corrected PET image reconstruction for cardiac PET-MR. Munoz C, Ellis S, Nekolla SG, Kunze KP, Vitadello T, Neji R, Botnar RM, Schnabel JA, Reader AJ, Prieto C. *J Nucl Med*. 2021 May 28:jnumed.120.254235

CME SESSION 7

Developments and Challenges in Theranostics

CME SESSION



WHERE ARE WE WITH THERANOSTIC IMAGING TODAY?

CME Session

7



October 21
15:05 - 16:35

LIOE-FEE DE GEUS-OEI (LEIDEN, NETHERLANDS)

Nuclear medicine thrives by continuous changes. The current decade a wave of new theranostic compounds, targeting the same receptor for imaging and therapy, will change the oncology therapeutic arsenal [1,2]. This CME session will review the current status of theranostics from a clinical perspective and identify key clinical needs to be addressed with future developments. The first part of this lecture deals with theranostic applications for radionuclide treatments. In nuclear medicine we have several applications, where we make use of the same set of molecules. The molecule can either be coupled to a SPECT or PET radionuclide, or to an α or β -emitter to perform radionuclide treatment (such as ^{131}I , ^{131}I -MIBG, ^{90}Y - or ^{166}Ho -microspheres, ^{177}Lu -Dotatate, ^{223}Ra , ^{177}Lu -PSMA or ^{225}Ac -PSMA etc) [3-5]. There are, however, also nuclear medicine theranostic applications for non-radionuclide treatments, which is addressed in the second part of this lecture (such as ^{18}F -FES, ^{89}Zr -trastuzumab, ^{89}Zr -nivolumab, ^{89}Zr -atezolizumab, ^{89}Zr -bevacizumab, ^{89}Zr -girentuximab etc) [6-8]. PET imaging with tumour specific tracers, has the potential to select the most suitable therapy for each

individual patient. Up-front or early detection of non-responding patients might aid to select the right patients for the right drug at early time points. As a prerequisite for future successful clinical translation, properly designed randomized clinical trials need to be performed and phase 3 clinical trials exploiting target visualization with PET and individualized therapies will help to realize the full potential of clinical theranostics. The oncological treatment triangle currently consists of (1) surgery and other local treatments, (2) systemic treatments including chemo-, hormone-, targeted- and immunotherapy and (3) external beam radiation therapy. Radioligand therapy, however, also deserves a place in the oncological treatment triangle (which will become a quadrilateral). The time is ripe to work on a strategy how to roll out radioligand therapy in different national contexts and how to set up theranostic centers in Europe and beyond. What does the cancer community have to do to boost readiness for implementation of radioligand therapy in standard cancer care and to prepare the policy environment to be ready for this?

References:

1. The Future of Nuclear Medicine, Molecular Imaging, and Theranostics, *J Nucl Med.* 2020 Dec;61(Suppl 2):2635-2725.
2. Future of Theranostics: An Outlook on Precision Oncology in Nuclear Medicine. *J Nucl Med.* 2019 Sep;60(Suppl 2):135-195.
3. Phase 3 Trial of ^{177}Lu -Dotatate for Midgut Neuroendocrine Tumors. *N Engl J Med.* 2017 Jan 12;376(2):125-135
4. [^{177}Lu]Lu-PSMA-617 versus cabazitaxel in patients with metastatic castration-resistant prostate cancer (TheraP): a randomised, open-label, phase 2 trial. *Lancet.* 2021 Feb 27;397(10276):797-804.
5. Nuclear Medicine beyond VISION. *J Nucl Med.* 2021 Apr 23;jnumed.121.262441. doi: 10.2967/jnumed.121.262441.
6. ^{89}Zr -atezolizumab imaging as a non-invasive approach to assess clinical response to PD-L1 blockade in cancer. *Nat Med.* 2018 Dec;24(12):1852-1858.

TERBIUM RADIOISOTOPES FOR THERANOSTICS, WHAT TO EXPECT?

CME Session

7



October 21
15:05 - 16:35

 CRISTINA MÜLLER (VILLINGEN, SWITZERLAND)

The concept of radiotheranostics has been realized with ^{68}Ga - and ^{177}Lu -labeled tumor targeting agents for PET imaging and targeted radionuclide therapy, respectively. The success of the “matched pair” principle is undisputed, yet, in an ideal case, the diagnostic and therapeutic radiometal would have equal chemical properties resulting in chemically identical radiopharmaceuticals characterized by equal distribution profiles.

Among a variety of emerging radionuclides currently employed or proposed for radiotheranostics, terbium has attracted the attention of the community, as it comprises four medically interesting radioisotopes (terbium sisters) for all four modalities in nuclear medicine (1). Terbium-152 and terbium-155 are the diagnostic radioisotopes with decay characteristics suitable for positron emission tomography (PET) and single photon emission computed tomography (SPECT) imaging, respectively (1). They may be particularly useful for dosimetry purposes to enable

prospective therapy planning. Terbium-149 and terbium-161 are suitable for targeted α -therapy and for a combined β^- and Auger electron therapy, respectively (2,3).

Due to the chemical similarities to lutetium, terbium radioisotopes can be stably coordinated with a DOTA chelator. In preclinical studies, it was confirmed that the tissue distribution of a particular radiopharmaceutical remains the same irrespective of whether lutetium-177 or any of the terbium radioisotopes is employed (3). This situation opens new perspectives for various applications of the terbium sisters with existing tumor-targeting agents.

This CME lecture will shed light on the current stage of all four terbium sisters from production to preclinical research and first-in-man application (4,5). In particular, the opportunities and challenges of radiotheranostics based on the use of terbium radioisotopes will be discussed.

References:

1. Müller C, Zhernosekov K, Köster U, Johnston K, Dorrer H, Hohn A et al. A unique matched quadruplet of terbium radioisotopes for PET and SPECT and for α - and β^- - radionuclide therapy: an in vivo proof-of-concept study with a new receptor-targeted folate derivative. *J Nucl Med.* 2012, 53(12):1951-9.
2. Umbricht C.A., Köster U, Bernhardt P, Gracheva N, Johnston K, Schibli R et al. Alpha-PET for prostate cancer: preclinical investigation of ^{149}Tb -PSMA-617. *Sci Report.* 2019, 9(1):17800-17810
3. Müller C., Umbricht C.A., Gracheva N., Tschan V.J., Pellegrini G., Bernhardt P. et al. Terbium-161 for PSMA-targeted radionuclide therapy of prostate cancer. *Pharmaceutics.* 2019;46(9):1919.
4. Müller C, Singh A, Umbricht CA, Kulkarni HR, Johnston K, Benešová M et al. *EJNMMI Res.* Preclinical investigations and first-in-human application of ^{152}Tb -PSMA-617 for PET/CT imaging of prostate cancer. 2019 Jul 25;9(1):68.
5. Baum RP, Singh A, Kulkarni HR, Bernhardt P, Rydén T, Schuchardt C et al. First-in-human application of terbium-161: a feasibility study using ^{161}Tb -DOTATOC. *J Nucl Med.* 2021;jnumed.120.258376.

QUANTITATIVE THERANOSTIC IMAGING - CHALLENGES AND OPPORTUNITIES

CME Session

7

 MARK KONIJNENBERG (ROTTERDAM, NETHERLANDS)



October 21
15:05 - 16:35

Dosimetry forms an integral part of theranostics, ideally a pre-therapeutic diagnostic scan will provide guidance on options for successful therapy and a prediction of the doses that can be safely achieved. In most cases pre-therapy PET diagnostic scans merely indicate specific uptake of the tracer in the volumes to be treated. The most commonly used PET radionuclides ^{18}F and ^{68}Ga cannot provide additional information on long-term retention of the radiopharmaceutical, essential for dosimetry estimates using longer-lived alpha- or beta-particle

emitters. Specific activity may differ considerably between diagnostic and therapeutic applications leading to variance in the pharmacokinetics depending on the molar amounts of ligand administered. The most reliable theranostic imaging is provided by peri-therapeutic imaging; quantitative imaging at various time-points after the first cycle of therapy. Clinical examples in ^{177}Lu -PSMA therapy will be presented on the options for peri-therapeutic dosimetry and the predictive value of single time-point PET imaging with ^{68}Ga -PSMA.

CME SESSION 8

CME SESSION

8

Pregnancy and Breastfeeding
in the Context of Nuclear
Medicine

STATUS OF GUIDELINES ON BREASTFEEDING

CME Session

8



October 21
16:50 - 18:20

 SIGRID LEIDE-SVEGBORN (MALMÖ, SWEDEN)

Administration of radiopharmaceuticals to mothers who are breastfeeding is generally avoided because the activity may be secreted into the breast milk, which results in unnecessary irradiation of the infants. Breastfeeding is very important for the infant as well as for the mother [1] and when a nuclear medicine procedure of a breastfeeding mother is of vital importance it may be necessary to temporarily interrupt breastfeeding. Unfortunately, it is often terminated even though it is not necessary. On the other hand, in situations when a necessary cessation is ignored, there is a risk of serious harm to the infant. Thus, it is important to have access to proper, clear, and easily accessible recommendations on the duration of an appropriate interruption.

Systematically collected data on the secretion of radionuclides into breast milk are rare [e.g. 2]. Data are often published in the form of case reports [e.g. 3] or as reviews [4, 5] based on compilation of data published earlier. Recommendations on breastfeeding of specific radiopharmaceuticals are given in the Summaries of Product Characteristics (SPC). These often recommend termination even though it is not necessary. More explicit guidelines on breastfeeding interruption are available via international radiation

protection bodies, such as ICRP [6] and IAEA [7]. Their recommendations are similar but with some obvious differences. Most importantly, the recommendation to terminate breastfeeding after administration of radioiodide are consistent. A minor difference is the recommendation for most radiopharmaceuticals labelled with ^{99m}Tc ; no interruption necessary (ICRP) or a possible four-hours' interruption (IAEA). Another difference is that IAEA has subgroups of recommendations for some radiopharmaceuticals used for different indications with different activity levels. Since the recommendations of these two organisations were published, 2015 (ICRP) and 2018 (IAEA) new radiopharmaceuticals have been introduced and additional data on radionuclides in breast milk for previous substances, have been published. Also, the current recommendations from The European union, EU [8] need to be updated. The contribution to the infant dose from external irradiation due to close contact with the mother is often insignificant compared to the dose due to ingestion but there are examples, ^{18}F -FDG among others, where the external dose significantly exceeds the dose due to ingestion, which should be kept in mind when recommendations are given.

References:

1. Victora CG, Bahl R, Barros AJD et al., for The Lancet Breastfeeding Series Group. (2016) *The Lancet*. 387, 475-490.
2. Leide Svegborn S, Ahlgren L, Johansson L et al. (2016) *Eur J Nucl Med Mol Imaging*.43, 808-821.
3. Saenz RB. (2000) *J Hum Lact*. 16:44-6.
4. Mountford, PJ, Coakely, AJ. (1989) *Nucl Med Commun*. 10, 15-27
5. Stabin MG, Breitz HB. (2000) *J Nucl Med*. 41, 863-73
6. Mattsson S, Johansson L, Leide Svegborn S et al., ICRP 2015. ICRP Publication 128. *Ann. ICRP* 44(2S) 2015
7. IAEA, International Atomic Energy Agency. Vienna. Series: IAEA safety standards series, ISSN 1020-525X; no. SSG-46: International Atomic Energy Agency) 2018
8. European Commission. Radiation Protection 100: Directorate-General. Environment, Nuclear Safety and Civil Protection. 1998

THE PREGNANT PATIENT - RISKS FOR THE FOETUS

CME Session

8



October 21
16:50 - 18:20

FRANÇOIS JAMAR (BRUSSELS, BELGIUM)

Administration of radiopharmaceuticals to pregnant women raises several problems, i.e., i) what is the risk for the foetus, ii) what recommendations can be made to mitigate them and iii) how should we communicate about this?

Risks to the foetus can be distributed into deterministic and stochastic risks. The first are related to relatively high doses, namely 50 or more mSv. This level of effective dose is never reached in nuclear medicine diagnostic procedures. It can be reached in nuclear therapies, which are strictly to be avoided in pregnant women, unless the benefit for both the mother and child-to-be is higher than the abstention of therapy, which is most unlikely. In all cases, the advice of the local ethic committee must be sought in such circumstances.

The risks for the embryo and foetus vary with time. In the very early stage of the pregnancy, after conception, the no/all effect applies, which means that there will be no consequence to the conceptus but alive or not. In the embryonic period, doses above 100 mSv may lead to congenital malformation by virtue of linear affect with a threshold. Effects on the foetal development or intellectual quotient (IQ) can also be expected (i.e., 30 points/gray).

Besides, the stochastic risks, for lower doses, may exist: they are based on the linear-non-threshold

effect, which is the conservative way of dealing with low doses. Effective doses in diagnostic NM are in the range of 0.2 to 10 mSv, well below the threshold for deterministic effects. Doses to pregnant women are as such not relevant but are a rough method to estimate the dose to the foetus.

The most important issue is to identify the risk. When a nuclear medicine procedure is needed, an estimate of the exposure to the embryo/foetus should be available, and discussed with the patient, mainly in terms of stochastic risk, which is essentially a minimal increase in childhood cancer: it must be remembered here that this effect is totally independent of the time of pregnancy, being the same for instance at 12 or 36 weeks. There should be no issue about deterministic risks for diagnostic nuclear medicine, regardless of the tracers used nowadays.

Communication with the patient is essential with regards to i) the risk of pregnancy and its screening and ii) the risks in case of known pregnancy. Efforts should be dedicated to identifying the risk of pregnancy especially in the youngest and most vulnerable patients. Direct questioning is of utmost importance whenever possible.

References:

1. ICRP: The 2007 Recommendations of the International Commission on Radiological Protection. ICRP Publication 103. Ann.ICRP 37:2-4
2. Protection of Pregnant Patients during Diagnostic Medical Exposures to Ionising Radiation. Health Protection Agency 2009. <https://www.hpa.org.uk/publication/protection-pregnant-patients-during-diagnostic-medical-exposures-ionising-radiation>
3. Mountford PJ, O'Doherty MJ. Exposure of critical groups to nuclear medicine patients. Appl. Radiat Isot, 1999; 50: 89-111.
4. James DJ, Warren-Forward HM. Development of consensus statements for pregnancy screening in diagnostic nuclear medicine: a Delphi study. J Nucl Med Technol. 2015 Mar;43(1):74-9.
5. Zanotti-Fregonara P, Hindie E. Performing nuclear medicine examinations in pregnant women. Phys Med. 2017; 43:159-164.

HOW TO ESTIMATE THE RADIATION DOSES?

CME Session

8



October 21
16:50 - 18:20

 MARTA CREMONESI (MILAN, ITALY)

Administration of radiopharmaceuticals to pregnant and breastfeeding women is generally avoided. Exceptional cases that include the administration during unknown pregnancy or the priority for the mothers' health, require the evaluation of absorbed doses to the foetus or the nursing. Radiation dose estimates to the foetus or the infant offer information that can guide decisions and alleviate psychological stress. Two main scenarios can be considered: i) specific data collection can be planned for personalized dosimetry; ii) only the amount of injected activity (and/or imaging) is available. Accordingly, specific dosimetry methods can be applied depending on the radiopharmaceutical, or dosimetry can be extrapolated from available biokinetic models, phantoms, population data, and/or software tools. The absorbed dose to the uterus may be a substitute for the absorbed dose to the embryo in the first 2-3 months of pregnancy. For radioactive substances with placental transfer, the absorbed doses to organs of the mother may be taken as representative of

those to the foetus organs. Some authors provided more detailed radiation dose estimates for the foetus at various stages of pregnancy, and other studies evaluated the biokinetics and dosimetry to infants by analysing radioactivity concentrations in the breast milk and the effective half-life. These kinds of data are available for several radiopharmaceuticals. Some dosimetry software incorporates phantoms of pregnant women.

This presentation will overview the practical methods to estimate radiation doses to the unborn baby, pregnant/nursing mother, and infant during breastfeeding. Examples will be provided considering most common radiopharmaceuticals for PET, cardiac, and pulmonary diagnostic examinations, sentinel lymph node for breast surgery, and treatment for thyroid cancer. Considering situations i) and ii), the data required for dose estimates will be highlighted, models and /or dosimetry data available from the literature indicated, and sources of uncertainty highlighted.

References:

1. Xie T, Zaidi H. Fetal and maternal absorbed dose estimates for positron-emitting molecular imaging probes. *J Nucl Med* 2014;55(9):1459-66.
2. Leide-Svegborn S, Ahlgren L, Johansson L, et al. Excretion of radionuclides in human breast milk after nuclear medicine examinations. Biokinetic and dosimetric data and recommendations on breastfeeding interruption. *Eur J Nucl Med Mol Imaging*. 2016;43(5):808-821.
3. Andersson M, Johansson L, Mattsson S, et al. Organ doses and effective dose for five PET radiopharmaceuticals. *Radiat Prot Dosimetry*. 2016;169(1-4):253-8.
4. Dorbala S, Di Carli MF, Delbeke D, et al. SNMMI/ASNC/SCCT guideline for cardiac SPECT/CT and PET/CT 1.0. *J Nucl Med* 2013;54(8):1485-507.
5. Isidoro J, Gil P, Costa G, et al. Radiation dose comparison between V/P-SPECT and CT-angiography in the diagnosis of pulmonary embolism. *Phys Med*. 2017;41:93-96.
6. Han SN, Amant F, Cardonick EH, et al. Axillary staging for breast cancer during pregnancy: feasibility and safety of sentinel lymph node biopsy. *Breast Cancer Res Treat*. 2018;168(2):551-557.

CME SESSION 9

CME SESSION

Back to the Future - New
Kit-Based Approaches for
Labelling Radiopharmaceuticals
(^{68}Ga , $\text{Al}[^{18}\text{F}]\text{F}$,...)

9

LABELING COLD KIT WITH ⁶⁸GA - THE FUTURE IS BRIGHT

CME Session

9



October 22
09:00 - 10:30

 CLÉMENT MORGAT (BORDEAUX, FRANCE)

The availability of radiopharmaceuticals for molecular imaging is critical to improve patient care. To disseminate radiopharmaceuticals, ready-to-use lyophilized kits are prerequisites for the rapid and reproducible preparation of radiopharmaceuticals while avoiding the need for complex syntheses and formulations using automated synthesizers [1]. ^{99m}Tc-kits for SPECT imaging illustrate well the potential of standardized preparations of radiopharmaceuticals. In PET, ⁶⁸Ga has deeply modified our practices in PET radiopharmacy during the last decade and similar achievements of kit-based formulation of ⁶⁸Ga-radiopharmaceuticals are expected with current clinical applications in neuroendocrine tumors patients and prostate cancer patients. ⁶⁸Ga-kits are unique because of the acidic behavior of the gallium ion which requires strong electron donors provided by (un)specific chelators associated

with the biomolecule [2]. ⁶⁸Ga is available through marketed ⁶⁸Ge/⁶⁸Ga generators which provide gallium 3+ ion in different reactional volume making radiolabeling standardization challenging. Recently, ⁶⁸Ga production was also reported to be feasible in cyclotron and high activities up to several gigabecquerels have been obtained [3] questioning the systematic use of scavengers in ⁶⁸Ga-kits [4]. Finally, the discovery of novel targets on tumors cells and the increasing availability of the corresponding ⁶⁸Ga-radiopharmaceuticals decorated with various chelate, would increase the number of cold kits available in clinics for PET imaging. Therefore, in this CME dedicated to labeling cold kits with ⁶⁸Ga, aspects of development with respects to chelators, cold kit composition, radiolabeling procedures and present and future clinical applications will be discussed.

References:

1. Mukherjee A. An Update on Extemporaneous Preparation of Radiopharmaceuticals Using Freeze-Dried Cold Kits. *Mini Rev Med Chem.* 2020; .
2. Spang P, Herrmann C, Roesch F. Bifunctional Gallium-68 Chelators: Past, Present, and Future. *Semin Nucl Med.* 2016;46:373-94.
3. Thisgaard H, Kumlin J, Langkjær N, Chua J, Hook B, Jensen M, et al. Multi-curie production of gallium-68 on a biomedical cyclotron and automated radiolabelling of PSMA-11 and DOTATATE. *EJNMMI Radiopharm Chem.* 2021;6:1.
4. Baudhuin H, Coussaert J, Vanwolleghem P, Raes G, Caveliers V, Keyaerts M, et al. ⁶⁸Ga-Labeling: Laying the Foundation for an Anti-Radiolytic Formulation for NOTA-sdAb PET Tracers. *Pharmaceuticals (Basel).* 2021;14.

AL[¹⁸F]F - FROM MODULES TOWARD A KIT-BASED RADIOFLUORINATION?

CME Session

9



October 22
09:00 - 10:30

CHIARA DA PIEVE (LONDON, UNITED KINGDOM)

Because of its high positron emission (97%), low positron energy ($\beta^+_{\text{max}} = 0.64$ MeV) and its half-life (108.9 min), fluorine-18 is often considered the “ideal” PET radioisotope. Generally, the incorporation of fluorine-18 into molecules is achieved through the formation of a carbon-fluorine bond. This process is usually designed uniquely for each new molecule, requires ¹⁸F drying, multiple steps, high temperatures (>100°C) and the use of anhydrous organic solvents. Unfortunately, these conditions are unsuitable for molecules such as peptides and proteins. In 2009, McBride et al. reported a one-pot direct radiofluorination (in aqueous medium) of biomolecules with the Al[¹⁸F]F moiety based on the formation of the very strong bond between ¹⁸F and aluminium¹. Briefly, a solution of aluminium chloride in a pH 4 buffer is mixed with an aqueous solution of ¹⁸F and an organic co-solvent. This is then added to the chelator-biomolecule ensemble and incubated for 15 min¹. Importantly, this novel radiolabelling protocol does not affect the biological properties of the biomolecule. The choice of chelator is essential for the preparation of stable (i.e. no defluorination) Al[¹⁸F]F-labelled products in physiological conditions. To date, the most stable Al[¹⁸F]F-labelled molecules contain cyclic chelators such as NOTA or NODA. However, acyclic chelators (e.g. HBED and RESCA)

have been recently investigated and showed encouraging results and applicability especially for thermosensitive biomolecules². The rapid (25-45 min) and straightforward Al[¹⁸F]F approach has since been used for an increasing number of peptides/small proteins (e.g. RGD, PSMA, affibody molecules) and also small molecules such as clickable tags and inhibitors (e.g. folate, FAPI)^{2,3}. With clinical applications in mind, a lyophilized kit, prepared and reported by McBride et al., showed great potential and versatility for the preparation of Al[¹⁸F]F-labelled peptides⁴. Additionally, several automated procedures have been developed on a variety of modules (e.g. Trasis AiO, GE TRACERlab) which are usually implemented in the production of small molecule-based ¹⁸F-tracers (e.g. FDG)^{2,5}. As a matter of fact, the one-pot procedure for direct ¹⁸F-labelling of biomolecules shows great compatibility with either cassettes or lyophilized cold kit formulations (e.g. a vial containing the biomolecule, aluminium chloride, bulking agent, buffer components, similar to the ones used for the GMPc preparation of ^{99m}Tc and ⁶⁸Ga radiopharmaceuticals). Importantly, with their pros and cons, both the cold kit and the automated module approaches represent an important and strong argument in favour of the clinical translation of the convenient Al[¹⁸F]F radiofluorination technique.

References:

1. McBride W.J., Sharkey R. M., Karacay H, et al., J Nucl Med, 2009, 50, 991
2. Fersing C., Bouhlef A., Cantelli C, et al., Molecules, 2019, 24, 2866
3. Giesel F., Adeberg S., Syed M., et al., J Nucl Med, 2021, 62, 201
4. McBride W.J., D'Souza C.A., Karacay H., et al., Bioconjugate Chem. 2012, 23, 538
5. Allott L., Da Pieve C., Turton D., et al., React. Chem. Eng., 2017, 2, 68

REGULATORY ASPECTS OF COLD KIT-BASED RADIOPHARMACEUTICALS IN THE EU

CME Session

9



October 22
09:00 - 10:30

OLIVER NEELS (DRESDEN, GERMANY)

Kit-based radiopharmaceuticals, in particular those bearing ^{99m}Tc as radionuclide, played and are playing a pivotal role in Nuclear Medicine in Europe over the last decades. Kits are also described in the EU directive 2001/83 on the Community code relating to medicinal products for human use [1]. Many approaches have been made to prepare kits

for radiolabeling with other radionuclides [2-9], but so far only one kit for radiolabeling with ^{68}Ga has received marketing authorization in Europe, namely SomaKit TOC [10], despite the fact that theranostic radiopharmaceuticals are on the rise. Do these promising methods fit into the current legislation or do we need change?

References:

1. European Commission. Directive 2001/83/EC of the European Parliament and of the Council of 6 November 2001 on the Community code relating to medicinal products for human use.
2. Wangler B, Quandt G, Iovkova L, Schirmmacher E, Wangler C, Boening G, et al. Kit-like ^{18}F -labeling of proteins: synthesis of 4-(di-tert-butyl[^{18}F]fluorosilyl)benzenethiol ($[\text{Si}^{18}\text{F}]_{\text{FA-SH}}$) labeled rat serum albumin for blood pool imaging with PET. *Bioconjug Chem.* 2009;20(2):317-21.
3. McBride WJ, D'Souza CA, Karacay H, Sharkey RM, Goldenberg DM. New lyophilized kit for rapid radiofluorination of peptides. *Bioconjug Chem.* 2012;23(3):538-47.
4. Ma MT, Cullinane C, Waldeck K, Roselt P, Hicks RJ, Blower PJ. Rapid kit-based ^{68}Ga -labelling and PET imaging with THP-Tyr 3 -octreotate: a preliminary comparison with DOTA-Tyr 3 -octreotate. *EJNMMI Res.* 2015;5(1):52.
5. Fersing C, Bouhlef A, Cantelli C, Garrigue P, Lisowski V, Guillet B. A Comprehensive Review of Non-Covalent Radiofluorination Approaches Using Aluminum [^{18}F]fluoride: Will [^{18}F]AIF Replace ^{68}Ga for Metal Chelate Labeling? *Molecules.* 2019;24(16).
6. Mukherjee A. An Update on Extemporaneous Preparation of Radiopharmaceuticals Using Freeze-Dried Cold Kits. *Mini Rev Med Chem.* 2020.
7. Man F, Khan AA, Carrascal-Minino A, Blower PJ, de Rosales RTM. A kit formulation for the preparation of [^{89}Zr]Zr(oxinate) $_4$ for PET cell tracking: White blood cell labelling and comparison with [^{111}In]In(oxinate) $_3$. *Nucl Med Biol.* 2020;90-91:31-40.
8. Giesel FL, Adeberg S, Syed M, Lindner T, Jimenez-Franco LD, Mavriopoulou E, et al. FAPI-74 PET/CT Using Either ^{18}F -AIF or Cold-Kit ^{68}Ga Labeling: Biodistribution, Radiation Dosimetry, and Tumor Delineation in Lung Cancer Patients. *J Nucl Med.* 2021;62(2):201-7.
9. Satpati D. Recent Breakthrough in ^{68}Ga -Radiopharmaceuticals Cold Kits for Convenient PET Radiopharmacy. *Bioconjug Chem.* 2021;32(3):430-47.
10. European Medicines Agency (EMA). European public assessment report (EPAR) for SomaKit TOC.

CME SESSION 10

CME
SESSION

10

Radionuclide Therapies -
Management of Side Effects
and Complications

RADIOIODINE THERAPY IN THYROID CANCER

CME Session

10



October 22
10:45 - 12:15

 MARKUS LUSTER (MARBURG, GERMANY)

Differentiated thyroid carcinoma (DTC) is a malignancy with increasing incidence and a favorable prognosis. Thus, there is growing concern about long-term side effects of DTC treatment, most notably radioactive iodine (RAI) therapy, but results of previous studies are conflicting and cohorts appear heterogenic. Side effects of RAI treatment may include nausea and vomiting, radiation thyroiditis and in rare cases sialadenitis and xerostomia, bone marrow suppression, gonadal dysfunction, second primary malignancies (SPM) and pulmonary fibrosis in presence of widespread pulmonary disease. As long-term adverse effects are a substantial part of

patient-relevant outcomes, any risk-benefit-ratio has to consider the risk of SPM occurrence. Regarding the latter, the impact of RAI is the subject of an ongoing debate and the existing evidence is conflicting. The limitations concerning any kind of synthesis of results originate from lacking comparability between the studies. The cohorts may present a vast heterogeneity in itself and between each other based on exposure to lifestyle-factors and carcinogens, ethnicity or different screening practice. These confounders are not routinely recorded in most studies. Additionally, it is crucial to include appropriate control groups.

References:

1. Yu CY, Saeed O, Goldberg AS, et al: A Systematic Review and Meta-Analysis of Subsequent Malignant Neoplasm Risk After Radioactive Iodine Treatment of Thyroid Cancer. *Thyroid official journal of the American Thyroid Association* 28:1662-73, 2018 (12)
2. Subramanian S, Goldstein DP, Parlea L, et al: Second primary malignancy risk in thyroid cancer survivors: a systematic review and meta-analysis. *Thyroid* 17:1277-88, 2007 (12)Reference
3. Clement SC, Peeters RP, Ronckers CM, et al: Intermediate and long-term adverse effects of radioiodine therapy for differentiated thyroid carcinoma—a systematic review. *Cancer treatment reviews* 41:925-34, 2015 (10)
4. Silva-Vieira M, Carrilho Vaz S, Esteves S, et al: Second Primary Cancer in Patients with Differentiated Thyroid Cancer: Does Radioiodine Play a Role? *Thyroid* 27:1068-76, 2017 (8)
5. Rubino C, Vathaire F de, Dottorini ME, et al: Second primary malignancies in thyroid cancer patients. *British Journal of Cancer* 89:1638-44, 2003 (9)
6. Sawka AM, Thabane L, Parlea L, et al: Second primary malignancy risk after radioactive iodine treatment for thyroid cancer: a systematic review and meta-analysis. *Thyroid* 19:451-7, 2009 (5)
7. Brown AP, Chen J, Hitchcock YJ, et al: The risk of second primary malignancies up to three decades after the treatment of differentiated thyroid cancer. *The Journal of clinical endocrinology and metabolism* 93:504-15, 2008 (2)
8. Hirsch D, Shohat T, Gorshtein A, et al: Incidence of Nonthyroidal Primary Malignancy and the Association with (131I) Treatment in Patients with Differentiated Thyroid Cancer. *Thyroid* 26:1110-6, 2016 (8)
9. Khang AR, Cho SW, Choi HS, et al: The risk of second primary malignancy is increased in differentiated thyroid cancer patients with a cumulative (131I) dose over 37 GBq. *Clinical endocrinology* 83:117-23, 2015 (1)

PEPTIDE RECEPTOR RADIONUCLIDE THERAPY - MANAGEMENT OF SIDE EFFECTS AND COMPLICATIONS

REFERS TO CME TALK: PEPTIDE RECEPTOR RADIONUCLIDE THERAPY IN
NEUROENDOCRINE TUMOURS

CME Session

10



October 22
10:45 - 12:15

 Gopinath Gnanasegaran (London, United Kingdom)

Peptide Receptor Radionuclide Therapy (PRRT) is an established treatment option for patients with metastatic, unresectable, progressive, somatostatin receptor (SSTR)-positive Gastroenteropancreatic-Neuroendocrine Tumours (GEP-NETs) and is recommended in clinical practice guidelines. Patients with NETs demonstrating adequate tumoral uptake on radionuclide somatostatin receptor imaging are eligible for PRRT. PRRT agents act via a 'Trojan horse' mechanism to enter and destroy NET cells. Currently, the most widely used PRRT is ¹⁷⁷Lu-DOTATATE. Other developed PRRT agents include ⁹⁰Y in complex with either DOTATATE or DOTATOC and other ¹⁷⁷-Lu labeled ligands (DOTATOC or DOTANOC). Monitoring of acute and delayed side effects and complications is of paramount importance. Patients should be monitored during, in-between, and after PRRT treatment cycles. This presentation will discuss the evidence-based management of side effects and complications, and related challenges. Side effects of PRRT are usually mild, and the most commonly reported adverse events include

nausea and vomiting, diarrhea, fatigue/asthenia, and musculoskeletal pain, which are mostly mild or moderate in intensity. Most nausea and vomiting cases are often related to amino acid administration and usually resolve after completing the infusion. In general, these can be prevented by avoiding electrolyte imbalances and ensuring adequate hydration. Irradiation of the hematopoietic tissue can lead to dose-limiting myelosuppression, manifesting clinically as anemia, lymphopenia, neutropenia, and/or thrombocytopenia, which may occur in isolation. PRRT might exacerbate the syndromes related to the respective functional tumors due to the sudden massive release of the hormones and receptor stimulation. Vital signs such as blood pressure and pulse should be monitored before and after PRRT, especially in symptomatic patients. Therapeutic interventions should be undertaken to treat the functional syndrome effects or exacerbation. The kidneys are the dose-limiting organs, and adequate kidney protection is mandatory.

References:

1. Hicks RJ, et al. ENETS Consensus Guidelines for the Standards of Care in Neuroendocrine Neoplasia: Peptide Receptor Radionuclide Therapy with Radiolabeled Somatostatin Analogues. *Neuroendocrinology*. 105(3), 295-309 (2017).
2. Strosberg J, et al. Phase 3 Trial of ¹⁷⁷Lu-Dotatate for Midgut Neuroendocrine Tumors. *N. Engl. J. Med.* 376(2), 125-135 (2017).
3. Hörsch D, et al. Effectiveness and side-effects of peptide receptor radionuclide therapy for neuroendocrine neoplasms in Germany: A multi-institutional registry study with prospective follow-up. *Eur. J. Cancer*. 58, 41-51 (2016).
4. Bodei L, et al. The joint IAEA, EANM, and SNMMI practical guidance on peptide receptor radionuclide therapy (PRRT) in neuroendocrine tumours. *Eur J Nucl Med Mol Imaging*. 2013;40(5):800-16.

¹⁷⁷LU-PSMA AND ²²⁵AC-PSMA THERAPY FOR METASTATIC CASTRATION-RESISTANT PROSTATE CANCER - A GAME CHANGER?

REFERS TO CME TALK: ¹⁷⁷LU AND ²²⁵AC PSMA THERAPY FOR PROSTATE CANCER

CME Session

10



October 22
10:45 - 12:15

 **ISABEL RAUSCHER (MUNICH, GERMANY),
PRESENTED BY SARAH M. SCHWARZENBÖCK (ROSTOCK, GERMANY)**

Castration-resistant prostate cancer (CRPC) treatment is an evolving challenge. Prostate-specific membrane antigen (PSMA)-targeted radioligand therapy (PRLT) with either the beta-particle-emitting radionuclide lutetium-177 (¹⁷⁷Lu) or the alpha-emitting radionuclide actinium-225 (²²⁵Ac) are promising new therapeutic approaches, however, the knowledge of side effects/toxicities is crucial. The results of a recently published meta-analysis including 1192 patients showed that approximately 46% of CRPC patients being treated with >1 cycle of ¹⁷⁷Lu-PSMA PRLT have PSA reductions of ≥50% (1). In their meta-analysis, the pooled estimated proportion of patients with grade 3 or 4 adverse events for all evaluated toxicities was <10%. Here, the estimated proportions ranged from 0.01 for nausea, fatigue, diarrhea, and elevated aspartate transaminase to 0.08 for the highest reported complication anemia. Thus, the relatively high number of PSA responders alongside the low rate of toxicity reflects the potentially promising role of PRLT in treating CRPC.

Further, the recently published prospective, multi-center, randomized Phase II trial (TheraP) reported a significantly higher treatment response and less toxicity in patients receiving Lu-PSMA-617 versus cabazitaxel (2). However, some patients may not respond to ¹⁷⁷Lu-PSMA-PRLT or the antitumor effect of ¹⁷⁷Lu-PSMA PRLT can decrease over time. Such patients may respond to an alpha particle-emitting PRLT characterized by high linear energy transfer and short travel distances which may cause potent and local cytotoxicity to PSMA-expressing tumor cells (3). A recently published analysis evaluating Ac-225-PSMA-617 showed measurable antitumor effect after Lu-177-PSMA failure in late-stage mCRPC (4). However, grade 3/4 hematological side effects were observed in up to one-third of patients (anemia 35%, leucopenia 27%, and thrombocytopenia 19%) while all patients experienced grade 1/2 xerostomia leading to toxicity-associated treatment discontinuation in a relevant number of patients. Thus, theranostic agents in CRPC have to be selected carefully.

References:

1. Sadaghiani MS, Sheikhabahaei S, Werner RA, et al. A Systematic Review and Meta-analysis of the Effectiveness and Toxicities of Lutetium-177-labeled Prostate-specific Membrane Antigen-targeted Radioligand Therapy in Metastatic Castration-Resistant Prostate Cancer. *Eur Urol*. 2021.
2. Hofman MS, Emmett L, Sandhu S, et al. [(177)Lu]Lu-PSMA-617 versus cabazitaxel in patients with metastatic castration-resistant prostate cancer (TheraP): a randomised, open-label, phase 2 trial. *Lancet*. 2021;397:797-804.
3. De Vincentis G, Gerritsen W, Gschwend JE, et al. Advances in targeted alpha therapy for prostate cancer. *Ann Oncol*. 2019;30:1728-1739.
4. Feuerecker B, Tauber R, Knorr K, et al. Activity and Adverse Events of Actinium-225-PSMA-617 in Advanced Metastatic Castration-resistant Prostate Cancer After Failure of Lutetium-177-PSMA. *Eur Urol*. 2021;79:343-350.

CME SESSION 11

New Concepts for Imaging and Therapy of Bone Metastases

CME
SESSION

11

NUCLEAR IMAGING OF BONE METASTASES

CME Session

11



October 22
15:05 - 16:35

HELLE D. ZACHO (AALBORG, DENMARK)

For more than five decades bone scintigraphy with ^{99m}Tc -labelled bisphosphonates has been the preferred imaging modality for the evaluation of metastases in the skeletal system. The clinical value has been greatest in cancer types with osteoblastic metastases as seen in patients with prostate cancer¹ and patients with breast cancer. Bone scintigraphy has been used for all stages of prostate cancer from primary staging, over recurrent disease to response assessment during therapy¹. Bone scintigraphy has proven to be a robust method with an adequate diagnostic accuracy, it is cheap and widely available.

Technical advancements in camera technique with the addition of SPECT/CT and PET/CT to the diagnostic armamentarium combined with the introduction of new and disease specific tracers have changed the landscape of nuclear imaging of bone metastases.

In prostate cancer, specific tracers such as choline², ^{18}F -Fluciclovine (FACBC) and particularly prostate-specific membrane antigen (PSMA)^{3,4} have increased the diagnostic accuracy significantly for the detection of bone metastases and the tracers have gained widespread clinical use. In breast cancer the estrogen-receptor-tracer (FES) has shown very promising diagnostic properties⁵. Moreover, common PET-tracers such as ^{18}F -FDG⁶ and ^{18}F -Sodium-fluoride (NaF)^{2,7} can be used for the assessment of bone metastases in numerous types of cancer. Most of the PET-tracers possess the inherent advantage of evaluating not only the skeletal system but also the extend of the primary tumor, lymph node metastases and soft tissue metastases.

References:

1. EAU-ESTRO-ESUR-SIOG Guidelines on Prostate Cancer. <https://uroweb.org/guideline/prostate-cancer/>
2. Wondergem M, van der Zant FM et al. A literature review of ^{18}F -fluoride PET/CT and ^{18}F -choline or ^{11}C -choline PET/CT for detection of bone metastases in patients with prostate cancer. *Nucl Med Commun.* 2013;34:935-45. 62.
3. Afshar-Oromieh A, Haberkorn U et al. ^{68}Ga -labelled PSMA ligand as superior PET tracer for the diagnosis of prostate cancer: comparison with ^{18}F -FECH. *Eur J Nucl Med Mol Imaging.* 2012;39:1085-6.
4. Hofman MS, Lawrentschuk N et al. Prostate-specific membrane antigen PET-CT in patients with high-risk prostate cancer before curative-intent surgery or radiotherapy (proPSMA): a prospective, randomised, multicentre study. *Lancet.* 2020;395:1208-16.
5. Kurland BF, Wiggins et al. Whole-Body Characterization of Estrogen Receptor Status in Metastatic Breast Cancer with $^{16}\alpha$ - ^{18}F -Fluoro- $^{17}\beta$ -Estradiol Positron Emission Tomography: Meta-Analysis and Recommendations for Integration into Clinical Applications. *Oncologist* 2020 Oct;25:835-844.
6. C Spick, K Herrmann, J Czernin. ^{18}F -FDG PET/CT and PET/MRI Perform Equally Well in Cancer: Evidence from Studies on More Than 2,300 Patients. *J Nucl Med.* 2016 Mar;57:420-30.
7. Even-Sapir E, Metser U et al. The detection of bone metastases in patients with high-risk prostate cancer: ^{99m}Tc -MDP Planar bone scintigraphy, single- and multi-field-of-view SPECT, ^{18}F -fluoride PET, and ^{18}F -fluoride PET/CT. *J Nucl Med.* 2006;47:287-97

RADIONUCLIDE THERAPY OF BONE METASTASES

CME Session

11



October 22
15:05 - 16:35

 ALI AFSHAR-OROMIEH (BERN, SWITZERLAND)

Various malignant diseases can give rise to bone metastases, for which the most relevant accompanying symptoms are pain, fractures, and bone marrow suppression. Radionuclide therapy is a useful palliative option among other treatments for bone metastases. Since metastatic malignant diseases are usually incurable, radionuclide therapy for bone metastases aims at pain reduction, delaying disease progression, and reducing of complications such as pathologic fractures.

Radionuclide therapy uses bone seeking radiopharmaceuticals. Their accumulation in metastases has an association with increased skeletal metabolic activity, also described as osteoblastic activity and calcification. A baseline bone scan with [^{99m}Tc]-labeled bisphosphonates prior to therapy is mandatory to substantiate increased skeletal metabolic activity. Lytic bone metastases are not treatable by radionuclide therapy since they do not show increased skeletal metabolic activity.

Charles Pecher introduced strontium-89 (⁸⁹Sr) in 1939 as the first application of bone-seeking radiopharmaceuticals in medical therapy procedures. ⁸⁹Sr is a beta-emitting radionuclide that substitutes for calcium for incorporation into the bone matrix. In Europe, [⁸⁹Sr]-chloride is approved for use in patients with bone metastases of prostate cancer, whereas samarium ¹⁵³Sm (another beta-emitter) bound to the bisphosphonate EDTMP is approved for the treatment of pain from osteoblastic bone metastases of any type of malignant diseases.

During the last two decades, the demand of

radionuclide therapy with bone-seeking beta-emitters has declined due to improvements in cancer and pain treatment as well as other factors. In addition, the alpha-emitter Xofigo (²²³Radium-dichloride) was clinically introduced as an alternative for treatment of symptomatic metastatic castration resistant prostate cancer (mCRPC), following upon its approval in 2013 by the EMA and FDA. Xofigo is another calcium mimetic, which also selectively binds to zones of increased bone turnover in bone metastases. In a phase-3 clinical trial, Xofigo significantly improved overall survival of men with mCRPC and bone metastases when compared to placebo (median OS 14.0 months vs. 11.2 months). In 2018, the EMA placed certain restrictions on the use of this therapeutic agent, namely that it must not be used in conjunction with Zytiga (abiraterone acetate) or the corticosteroids prednisone or prednisolone, since these combinations increased the risk of earlier death or bone fractions as compared to placebo treatment.

Since 2011, radioligand therapy with PSMA-ligands is available for patients with mCRPC. In contrast to bone-seeking radiopharmaceuticals, PSMA-ligands (labelled with beta- or alpha-emitters) seek all metastases that have elevated PSMA-expression, irrespective of their location (bone, lymph nodes, organs, etc.). Although there has been no direct comparison between Xofigo and PSMA-radioligand therapy, several retrospective studies suggest that PSMA-radioligand therapy can be more effective.

ABLATIVE IRRADIATION OF BONE METASTASES

REFERS TO CME TALK: RADIATION THERAPY OF BONE METASTASES

CME Session

11



October 22
15:05 - 16:35

 PIET DIRIX (ANTWERP, BELGIUM)

Radiation therapy (RT) is an established treatment for painful and/or complicated bone metastases. The goal is to ease or prevent debilitating symptoms such as pain, fractures, and spinal cord compression. Usually, a single fraction of 8.0 Gy is delivered, as no other fractionation schedule is superior regarding pain relief, preservation of function, or maintenance of skeletal integrity [1, 2]. Typically, such palliative RT is delivered with conventional techniques, broadly encompassing the intended target volume. Over the last decades, RT delivery has improved considerably through the use of intensity-modulation (IMRT) as well as image-guidance (IGRT). These innovations have resulted in the introduction of stereotactic body radiation therapy (SBRT), delivering very high doses in a limited number of fractions in a highly conformal manner. In principle, SBRT allows for the “ablation”, i.e.

total eradication of all disease, of bone metastases, with few side-effects.

SBRT for bone metastases has been initially tested in oligometastatic disease (OMD). Considerable evidence shows that SBRT for OMD is safe with acceptable toxicity, as well as efficient with high rates of local control [3-6]. Because of the clear success of SBRT in OMD, it seems reasonable to also investigate this technique in a more palliative setting. The highly conformal delivery of SBRT is expected to result in an improved acute toxicity profile. Moreover, it is now possible to deliver significantly escalated doses to the metastases, potentially resulting in higher symptomatic efficacy and less re-irradiation need. The results so far have been mixed, and several randomized controlled trials are still recruiting [7, 8].

References:

1. Rich SE, et al. Update of the systematic review of palliative radiation therapy fractionation for bone metastases. *Radiother Oncol* 2018; 126(3): 547-57.
2. Hoskin PJ, et al. Effect of single-fraction vs multifraction radiotherapy on ambulatory status among patients with spinal canal compression for metastatic cancer. *JAMA* 2019; 322(21): 2084-94.
3. Poon I, et al. Evaluation of definitive stereotactic body radiotherapy and outcomes in adults with extracranial oligometastasis. *JAMA Netw Open* 2020; 3(11): e2026312.
4. Lehrer EJ, et al. Safety and survival rates associated with ablative stereotactic radiotherapy for patients with oligometastatic cancer: a systematic review and meta-analysis. *JAMA Oncol* 2021; 7(1): 92-106.
5. Chalkidou A, et al. Stereotactic ablative body radiotherapy in patients with oligometastatic cancers: a prospective, registry-based, single-arm, observational, evaluation study. *Lancet Oncol* 2021; 22(1): 98-106.
6. Palma DA, et al. Stereotactic ablative radiotherapy for the comprehensive treatment of oligometastatic cancers: long-term results of the SABR-COMET phase II randomized trial. *J Clin Oncol* 2020; 38(25): 2830-38.
7. Nguyen QN, et al. Single-fraction stereotactic vs. conventional multifraction radiotherapy for pain relief in patients with predominantly nonspine bone metastases. *JAMA Oncol* 2019; 5(6): 872-78.
8. Mercier C, et al. A phase III randomized-controlled, single-blind trial to improve quality of life with stereotactic body radiotherapy for patients with painful bone metastases (ROBOMET). *BMC Cancer* 2019; 19(1): 876.

CME SESSION 12

CME
SESSION

12

Nuclear Medicine in the
Evaluation of Child Abuse

CLINICAL ASPECTS OF CHILD ABUSE

REFERS TO CME TALK: CHILD ABUSE CLINICAL FEATURES, DIAGNOSIS AND MANAGEMENT

CME Session

12

October 22
16:50 - 18:20

HADAS YECHIAM (KFAR SABA, ISRAEL)

Child abuse and neglect (CAN) includes all types of physical and/or emotional ill-treatment, sexual abuse, neglect, negligence, and commercial or other exploitation, which results in actual or potential harm to the child's health, survival, development or dignity in the context of a relationship of responsibility, trust or power.

The incidence of CAN, when evaluated directly from the children, is close to 20%.

In many countries reporting on child abuse to child protective services is mandatory. In some for all citizens and in some only for designated personnel (such as healthcare or education).

Risk factors relate to the community, the parents and the child.

The manifestations of physical abuse are most likely to involve skin injuries, followed by bone fractures

and head trauma. The identification of physical abuse can be difficult. It is important to be aware of red flags in the clinical history, the physical exam and the behavior of the child and parents/caretakers.

The workup in cases of suspected CAN includes comprehensive history taking, performing a meticulous physical exam, evaluation by a social worker and ancillary testing. The ancillary tests usually include imaging and laboratory tests to support the suspicion of abuse and to rule out alternative diagnoses.

In cases where there is concern for the safety of a child in his home there is need to implement a protection plan, either by hospitalizing the child or by finding an alternative safe environment, with the help of the child protective services.

References:

1. WHO. <https://www.who.int/news-room/fact-sheets/detail/child-maltreatment>
2. Afifi TO, Mather A, Boman J, et al. Childhood adversity and personality disorders: results from a nationally representative population-based study. *J Psychiatr Res.* 2011;45(6):814-82
3. Cindy W. Christian, MD, FAAP, COMMITTEE ON CHILD ABUSE AND NEGLECT. CLINICAL REPORT, Guidance for the Clinician in Rendering Pediatric Care The Evaluation of Suspected Child Physical Abuse . 2015. American Academy of Pediatrics

NUCLEAR MEDICINE IN THE EVALUATION OF CHILD ABUSE

CME Session

12



October 22
16:50 - 18:20

 LAURA DRUBACH (BOSTON, UNITED STATES OF AMERICA)

Child abuse is a social problem that requires a multidisciplinary approach. Bone fractures are often encountered in cases of child abuse, being second in incidence only to soft tissues injuries. Skeletal injuries are present in approximately 55% of children that are physically abused (1). Nuclear Medicine imaging plays an important role in the detection and characterization of skeletal fractures.

In a study performed by Kemp et.al. in 2008 it was found that rib fractures had the highest probability for abuse. (71% of cases) (2). Long bone fractures had a lower incidence than rib fractures but were also common, with humeral fracture 48% of cases and femoral fractures 28%. The probability for skull fractures was 30%, being most commonly a linear fracture. Certain types of fractures, because of the mechanism of injury needed to produce them, are known for the

high specificity to be secondary to child abuse. Some other fractures are commonly seen in accidental injuries and do not raise the suspicion for child abuse (3).

According to the American Academy of Pediatrics and the American College of Radiology, the imaging method of choice for evaluation of fractures of children younger than 2 years at the time of presentation is the skeletal survey (4).

Nuclear Medicine imaging has a complementary role due to the high sensitivity for detection of fractures in infants being evaluated for child abuse, especially for the detection of rib fractures. This is of particular importance since these are the most common fractures found in child abuse (5).

References:

1. Loder RT, Bookout C. Fracture patterns in battered children. *J Orthop Trauma* 1991;5:428-33.
2. Kemp AM, Dunstan F, Harrison S, et al. Patterns of skeletal fractures in child abuse: systematic review. *BMJ* 2008;337:a1518.
3. Kleinman P. K. Skeletal Trauma: General Considerations. In: Kleinman PK, ed. *Diagnostic Imaging of Child Abuse*. 2nd. ed. St. Louis: Mosby; 1998:8-25.
4. Diagnostic imaging of child abuse. *Pediatrics* 2009;123:1430-5.
5. Drubach LA, Sapp MV, Laffin S, Kleinman PK. Fluorine-18 NaF PET imaging of child abuse. *Pediatr Radiol* 2008;38:776-9.

RADIOLOGICAL ASPECTS OF CHILD ABUSE

CME Session

12



October 22
16:50 - 18:20

 CHIARA GIRAUDO (PADUA, ITALY)

It is well known that radiological imaging can significantly contribute to the diagnostic process and investigation in cases of non-accidental pediatric traumas and this lecture will provide a comprehensive overview of the role and appropriateness of different radiological techniques including x-ray, CT, and MRI in this field. In particular, the main characteristics of fractures at skeletal survey, the application of CT for

head and visceral injuries as well as the use of MR and WBMRI will be reviewed.

Lastly, the application of advanced imaging techniques like machine learning and artificial intelligence for the detection of fractures and their potential use in children victims of abuse will also be addressed.

References:

1. Lonergan GJ et al. Child Abuse: Radiologic-Pathologic Correlation. *RadioGraphics* 2003;23:811-845.
2. Kleinman P. Diagnostic Imaging in infant abuse. *AJR* 1990;155:703.
3. Karmazyn B et al. The Prevalence of Uncommon Fractures on Skeletal Surveys Performed to Evaluate for Suspected Abuse in 930 Children: Should Practice Guidelines Change? *AJR* 2011; 197:W159-W163.
4. Offiah A, et al. Skeletal imaging of child abuse (non-accidental injury). *Pediatr Radiol* 2009; 39:461-470.
5. Li-Chun Hsieh et al. Revisiting Neuroimaging of Abusive Head Trauma in Infants and Young Children. *AJR* 2015;204:944-952.
6. Ruda MT, et al. Use of whole body MRI in detecting body injuries in suspected child abuse: A case report. *Journal of Forensic Radiology and Imaging* 2016;5:59-61.
7. Perez-Rossello JM et al. Whole-Body MRI in Suspected Infant Abuse. *AJR* 2010 195:744-750.
8. Rayan et al. Binomial Classification of Pediatric Elbow Fractures Using a Deep Learning Multiview Approach Emulating Radiologist Decision Making. *Radiology: Artificial Intelligence* 2019; 1:e180015.
9. Zhang et al. Diagnostic Accuracy of 3D Ultrasound and Artificial Intelligence for Detection of Pediatric Wrist Injuries. *Children* 2021; 8:431.

CME SESSION 13

CME
SESSION

13

Immunotheranostics

IMMUNOTHERAPY AND NUCLEAR MEDICINE DIAGNOSTICS - WHERE DO WE STAND?

CME Session

13



October 23
09:00 - 10:30

ELISABETH G. E. DE VRIES (GRONINGEN, NETHERLANDS)

Immune checkpoint inhibitors have substantially changed the field of oncology over the past few years. Immune checkpoint inhibitors offer an alternative treatment strategy by exploiting the patients' immune system, resulting in a T cell-mediated anti-tumor response. These therapies are effective in multiple different tumor types. Unfortunately, a substantial group of patients does not respond to immune checkpoint inhibitors. Molecular imaging, using positron emission tomography (PET), can

provide non-invasive whole-body visualization of tumor and immune cell characteristics and might support patient selection or response evaluations for ICI therapies. In this session, recent advances in PET imaging of immune checkpoints and immune cells will be presented. These studies are, until now, mainly exploratory, but the first results suggest that molecular imaging biomarkers could have a role in the evaluation of immune checkpoint inhibitor therapy.

References:

1. Li W, et al. PET/CT imaging of ⁸⁹Zr-N-sucDf-pembrolizumab in healthy cynomolgus monkeys. *Mol Imaging Biol.* 2021;23:250-259.
2. van der Veen EL, et al. ⁸⁹Zr-pembrolizumab biodistribution is influenced by PD-1-mediated uptake in lymphoid organs. *J Immunother Cancer.* 2020;8:e000938.
3. Giesen D, et al. Probody therapeutic design of ⁸⁹Zr-CX-072 promotes accumulation in PD-L1-expressing tumors compared to normal murine lymphoid tissue. *Clin Cancer Res.* 2020;26:3999-4009.
4. Moek KL, et al. Accumulation in CD3-rich tissues and clear, heterogeneous tumor uptake. *Clin Cancer Res.* 2019 15;25:3517-3527.
5. Bensch F, et al. ⁸⁹Zr-atezolizumab imaging as a non-invasive approach to assess clinical response to PD-L1 blockade in cancer. *Nat Med.* 2018;24:1852-1858.
6. van der Veen EL, et al. Molecular imaging to enlighten cancer immunotherapies and underlying involved
7. processes. *Cancer Treat Rev.* 2018;70:232-244.
8. Vries EGE, et al. Integrating molecular nuclear imaging in clinical research to improve anticancer therapy. *Nat Rev Clin Oncol.* 2019;16:241-255.
9. van de Donk PP, et al. Interleukin-2 PET imaging in patients with metastatic melanoma before and during immune checkpoint inhibitor therapy. *Eur J Nucl Med Mol Imaging.* 2021 Jun 2.

COMBINING IMMUNOTHERAPY AND RADIATION - IS THE WHOLE MORE THAN THE SUM OF ITS PARTS?

CME Session

13



October 23
09:00 - 10:30

 FERNANDA HERRERA (LAUSANNE, SWITZERLAND)

The discovery of new methods for inflaming tumors is critical for increasing immunotherapy response. (1-3)

We found that low-dose radiation reprogrammed the tumor microenvironment of advanced murine ovarian tumors with low immune infiltration and, when combined with immunotherapy, induced simultaneous mobilization of innate and adaptive immunity, primarily via effector T cells, to achieve tumor control. Treatment efficacy was dependent on new states of CD4, CD8, as well as dendritic cells discovered by single cell RNA sequencing. The benefit of low dose irradiation to all metastatic deposits

in combination with immunotherapy was seen in patients with metastatic immune-cold tumors.

High doses of fractionated whole abdominal irradiation were used in the past as an effective postsurgical adjuvant therapy in the management of ovarian cancer, however, fell out of favor due to its high toxicity to the intestine and inability to be combined with chemotherapy. (4) According to our findings, lower doses of whole abdominal irradiation should be further investigated in conjunction with immunotherapy in order to increase immune infiltration in otherwise cold-insensitive tumors. (4)

References:

1. Herrera FG, Bourhis J, Coukos G. Radiotherapy combination opportunities leveraging immunity for the next oncology practice. *CA Cancer J Clin* 2017;67(1):65-85 doi 10.3322/caac.21358.
2. Klug F, Prakash H, Huber PE, Seibel T, Bender N, Halama N, et al. Low-dose irradiation programs macrophage differentiation to an iNOS(+)/M1 phenotype that orchestrates effective T cell immunotherapy. *Cancer cell* 2013;24(5):589-602 doi 10.1016/j.ccr.2013.09.014.
3. Lanitis E, Dangaj D, Irving M, Coukos G. Mechanisms regulating T-cell infiltration and activity in solid tumors. *Ann Oncol* 2017;28(suppl_12):xii18-xii32 doi 10.1093/annonc/mdx238.
4. Herrera FG, Irving M, Kandalaft LE, Coukos G. Rational combinations of immunotherapy with radiotherapy in ovarian cancer. *Lancet Oncol* 2019;20(8):e417-e33 doi 10.1016/S1470-2045(19)30401-2.

NUCLEAR MEDICINE IMMUNOTHERANOSTICS - SYNERGISMS AND ANTAGONISMS

CME Session

13



October 23
09:00 - 10:30

 NIKLAUS SCHAEFER (LAUSANNE, SWITZERLAND)

Nuclear Medicine immunotheranostics means to visualize, modulate or eradicate barriers against anti-cancer immunotherapies by nuclear medicine theranostic techniques (1). To understand how to implement Nuclear Medicine immunotheranostics successfully from research trials to clinical routine we have to understand its antagonisms and synergisms a) in a biological and mechanistic sense, b) in the sense of how to design the most useful clinical trials and c) at the level of the physicians' interactions in both intrinsically interacting fields, Nuclear Medicine and Medical Oncology. First, on the level of cancer biology and immunology, we have to understand antagonism and synergism of the different treatment strategies on a molecular, biological level (2). Here, our classical theranostic concept "search the target - eliminate the target" needs to be put into context of the constantly changing and highly complex tumor microenvironment. Second, at the level of

clinical trial design we have to address the problem of who would support large randomized trials, i.e. if and where academia and pharmaceutical industry can synergize, and what could be antagonistic forces for having such trials (3). We have also to think of ethical problems like how to cope with patients having inconsistent results in imaging and biopsy or how to design endpoints to be able to convince e.g. health economists of expensive diagnostic methods such as molecular imaging (4). Third, "synergism and antagonism" also touches on how nuclear medicine specialists and oncologists collaborate. It is therefore of utmost importance to invest in an efficient training at the interface of - especially our younger - nuclear medicine specialists with medical oncologists. Only if we address all of the above three dimensions we will implement Nuclear Medicine Theranostics successfully in the future for the good of our patients.

References:

1. Schaefer, N., Prior, J.O. & Schottelius, M. From Theranostics to Immunotheranostics: the Concept. *Nucl Med Mol Imaging* 54, 81-85 (2020)
2. Waldman, A.D., Fritz, J.M. & Lenardo, M.J. A guide to cancer immunotherapy: from T cell basic science to clinical practice. *Nat Rev Immunol* 20, 651-668 (2020).
3. Schaefer N, Ma J, Huang P, Buchanan J, Wahl RL. Radioimmunotherapy in non-Hodgkin lymphoma: opinions of U.S. medical oncologists and hematologists. *J Nucl Med.* 51:987-94 (2020)
4. Flight, L., Julious, S., Brennan, A. et al. How can health economics be used in the design and analysis of adaptive clinical trials? A qualitative analysis. *Trials* 21, 252 (2020).

CME SESSION 14

CME
SESSION

14

Probing Tumour
Metabolism - An Update

IMAGING NUCLEOSIDE TRANSPORT FOR MONITORING- TARGETED THERAPY IN CANCER

CME Session

14



October 23
10:45 - 12:15

 **FRANCESCA IOMMELLI (NAPLES, ITALY)**

Targeting oncogene drivers is one of the most promising treatment strategies in oncology and several targeted agents are currently approved or are under clinical development for therapy. The inhibition of oncogene drivers is usually followed by growth arrest and apoptosis causing tumor regression. However, in response to a prolonged inhibition of oncogene drivers, cancer cells may become resistant due to target mutations or adoption of compensatory pathways that maintain the mitogenic cascade as persistently activated. Imaging of proliferation by radiolabeled nucleosides may provide an early detection of sensitivity and resistance of cancer cells to inhibitors of oncogene drivers allowing the selection of patients for targeted therapy and evaluation of drug effects. Furthermore, the ability of new agents to inhibit oncogene drivers may be tested by imaging of proliferation in animal models thus promoting their moving from laboratory to clinical settings. EGFR is a well-recognized oncogene driver of non-small cell lung carcinoma (NSCLC) and has been considered as a paradigm of targeted therapy in cancer. Animals bearing sensitive tumors subjected to PET/CT with 3'-deoxy-3'-¹⁸F-fluorothymidine (¹⁸F-FLT) showed

a marked reduction of ¹⁸F-FLT uptake early after treatment with EGFR tyrosine kinase inhibitors (TKIs). Conversely, refractory tumors showed an unchanged or even increased tracer uptake at the same time points. Moreover, treatment with agents capable of reversing the specific mechanism of resistance caused a significant decrease of ¹⁸F-FLT uptake in resistant tumors as compared to baseline scan thus indicating treatment efficacy. In order to prevent or overcome resistance, current strategies of targeted therapy include the rational combination of selective inhibitors of oncogene driver and adaptive pathways. Monitoring tumor response to combined therapy using ¹⁸F-FLT PET/CT allowed us to detect and quantify the enhanced effects of two inhibitors as compared to single agent treatment on proliferation. These results are clinically relevant since no other non-invasive imaging method allows the early detection of drug synergy in vivo. The present talk will focus on the role of imaging with radiolabelled nucleosides in all clinically relevant steps of targeted therapies including patient selection, early monitoring of drug effects, reversal of drug resistance and dual target inhibition.

References:

1. Iommelli F et al. Monitoring reversal of MET-mediated resistance to EGFR tyrosine kinase inhibitors in non-small cell lung cancer using 3'-deoxy-3'-[¹⁸F]-fluorothymidine positron emission tomography. *Clin Cancer Res* 2014; 20:4806-15
2. Grassberger C et al. Patient-specific tumor growth trajectories determine persistent and resistant cancer cell populations during treatment with targeted therapies. *Cancer Res* 2019; 79: 3776-3788.
3. Iommelli F et al. Inositol Trisphosphate Receptor Type 3-mediated Enhancement of EGFR and MET Cotargeting Efficacy in Non-Small Cell Lung Cancer Detected by ¹⁸F-fluorothymidine. *Clin Cancer Res* 2018;24:3126-3136.
4. De Rosa V. et al. Reversal of Warburg Effect and Reactivation of Oxidative Phosphorylation by Differential Inhibition of EGFR Signaling Pathways in Non-Small Cell Lung Cancer. *Clin Cancer Res* 2015;21:5110-20.

ILLUMINATING METABOLIC HETEROGENEITY AND VULNERABILITIES IN LUNG CANCER

CME Session

14



October 23
10:45 - 12:15

DAVID LEWIS (GLASGOW, UNITED KINGDOM)

Tumour heterogeneity contributes intrinsic drug resistance leading to treatment failure and poor outcomes in lung cancer [1]. We have developed imaging approaches to dynamically identify regional metabolic heterogeneity and used these signatures to guide spatial molecular profiling and target local vulnerabilities.

To evaluate metabolic heterogeneity we have developed several radionuclide multiplexed technologies with radiolabelled probes [¹⁸F]FDG and [1-¹¹C/¹⁴C]acetate in the “humanised” *Kras*^{G12D/+} *p53*^{-/-} genetically engineered mouse model of lung cancer [2, 3]. We non-invasively identified two spatially heterogeneous metabolic subtypes, one with high [¹⁸F]FDG and the other with high [1-¹¹C] acetate uptake. Molecular profiling of these two imaging phenotypes showed distinct transcriptional, proteomic and metabolic profiles. Regions of lung adenocarcinoma with higher glucose consumption are more proliferative, with activation of cell cycle genes, *Myc* targets and unfolded protein response. While regions of high acetate consumption have

signatures for fatty acid metabolism, reactive oxygen species, TCA cycle and oxidative phosphorylation. Isotopologue tracing with [U-¹³C]glucose and [U-¹³C] revealed that FDG-avid tumours utilise glucose for synthesis of serine and glycine while using acetate to replenish the TCA cycle. In contrast, acetate-avid tumours use glucose for TCA anaplerosis, amino acid biosynthesis, and acetate for fatty acid synthesis.

We went on to determine if these phenotypes have distinct vulnerabilities by targeting fatty acid synthase (FASN) using a novel inhibitor (GSK2194069) [4]. FASN inhibition is currently under investigation for efficacy in a subset of patients with oncogenic KRAS driven lung cancer (NCT03808558) [5]. Our results show that using [1-¹¹C]acetate PET imaging can both identify and measure response in lung tumours dependant on the fatty acid synthesis pathway.

Metabolic imaging can identify distinct cancer phenotypes with different biology and response to treatment suggesting that metabolic imaging could guide treatment of heterogeneous tumours in lung cancer.

References:

1. Dagogo-Jack, I. and A.T. Shaw. *Nat Rev Clin Oncol*, 2018. 15(2): p. 81-94.
2. DuPage, M., A.L. Dooley, and T. Jacks. *Nat Protoc*, 2009. 4(7): p. 1064-72.
3. Lewis, D.Y., et al. *J Nucl Med*, 2014. 55(7): p. 1144-9.
4. Hardwicke, M.A., et al. *Nat Chem Biol*, 2014. 10(9): p. 774-9.
5. Falchook, G., et al. *EClinicalMedicine*, 2021. 34: p. 100797.

IMAGING TUMOUR METABOLISM AND ITS HETEROGENEITY WITH MRI

CME Session

14



October 23
10:45 - 12:15

 FERDIA GALLAGHER (CAMBRIDGE, UNITED KINGDOM)

There is increasing evidence to support the role of metabolism in tumour development: deregulation of cellular energetics is a key hallmark of cancer. Changes in this metabolism have been shown to be early biomarkers of successful response to both chemotherapy and radiotherapy. This talk will focus on the role of MR in probing tumour metabolism.

Proton MR spectroscopy (¹H-MRS) has been used to detect oncometabolites - or metabolites that promote cancer formation - which are present in some tumours due to mutations in mitochondrial enzymes. For example, ¹H-MRS can be used to detect fumarate and succinate secondary to mutations in the enzymes fumarate hydratase and succinate dehydrogenase respectively. These mutations are found in a range of tumours including renal cell carcinoma, gastrointestinal stromal tumours and paragangliomas. We have shown that fumarate levels may change over time with treatment as a biomarker of response.

Hyperpolarized carbon-13 MRI (¹³C-MRI) is an emerging molecular imaging method for studying cellular metabolism. This technique allows non-invasive measurements of tissue metabolism in real-time. To date, the most promising probe used in conjunction with hyperpolarized MRI has been ¹³C-labelled pyruvate: pyruvate is metabolized into lactate in normal tissue in the absence of oxygen, but in tumours this occurs very rapidly even in the presence of oxygen. Results from many animal models have shown that there is a reduction in the metabolism of pyruvate following successful treatment with chemotherapy. Tumour lactate labelling has also been shown to correlate with the grade of some tumour types such as breast and prostate cancer and can be used to monitor treatment response.

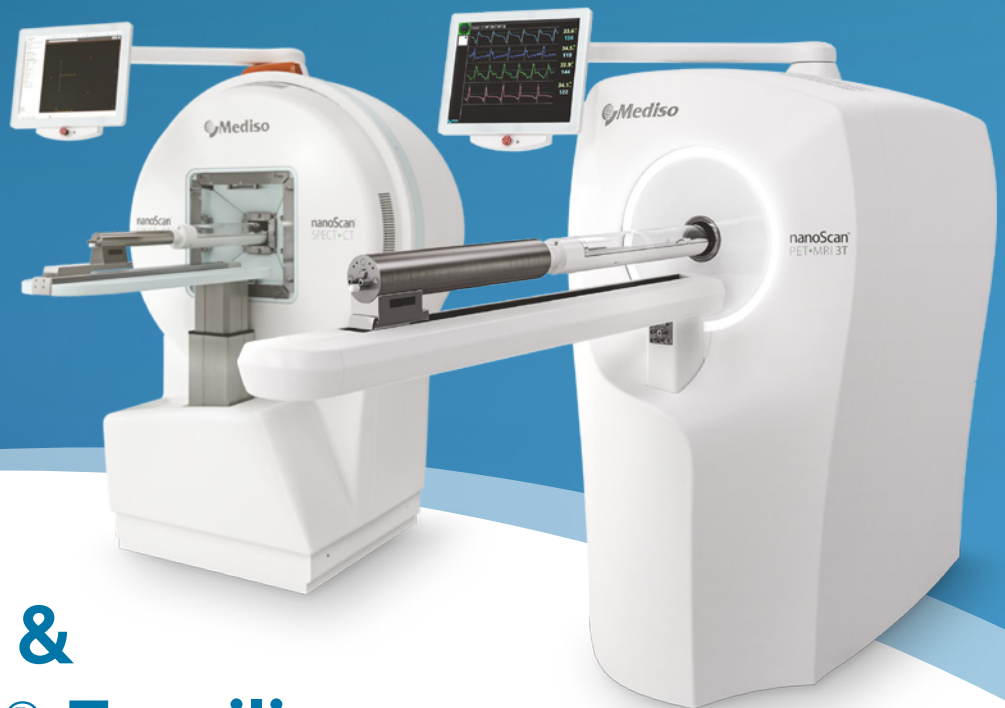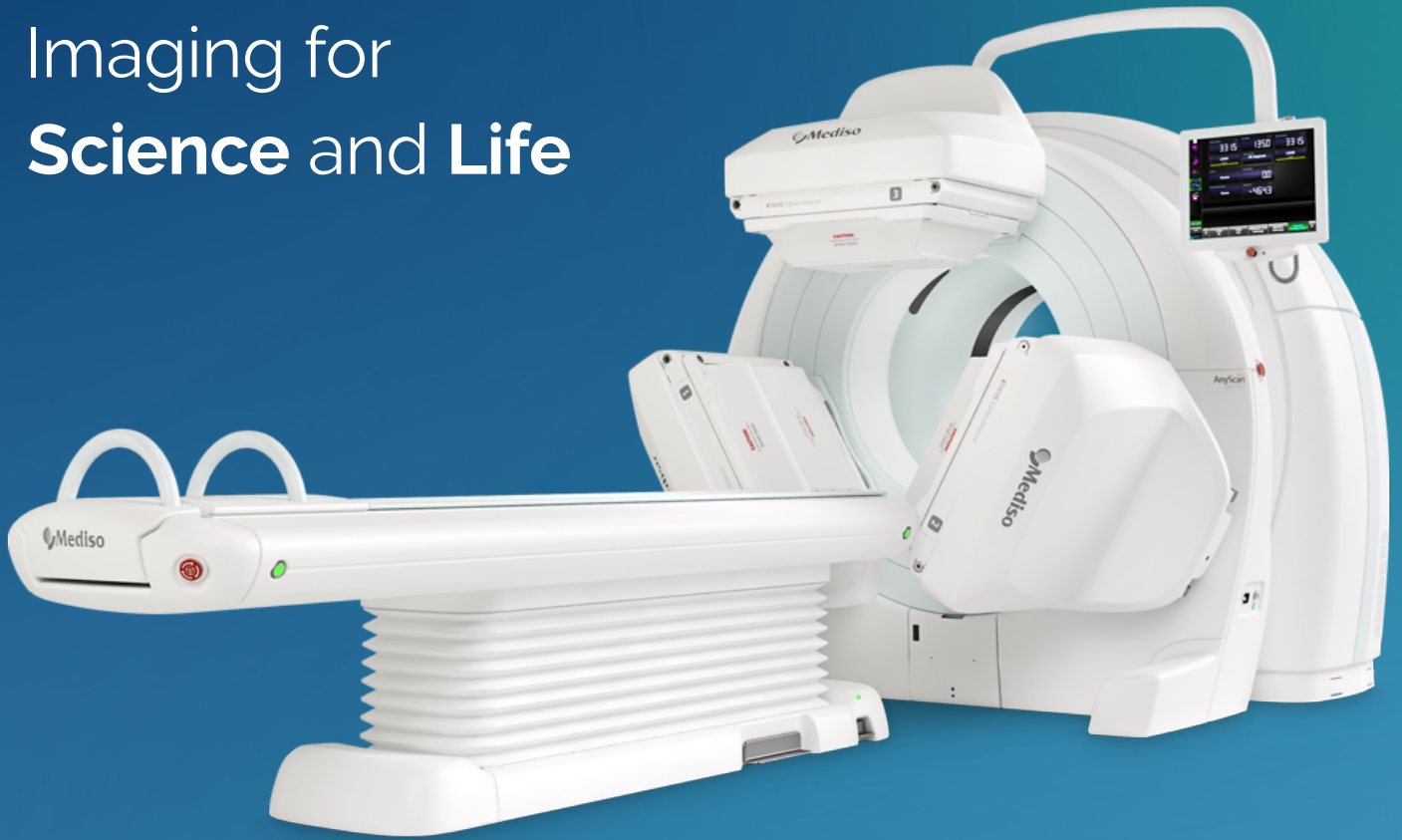Imaging methods to probe tumour metabolism could play an important role in stratifying tumours and detecting response to therapy.

References:

1. Day SE et al. Nat Med. 2007 Nov;13(11):1382-7.
2. Albers MJ et al. Cancer Res. 2008 Oct 15;68(20):8607-15.
3. Choi C et al. Nat Med. 2012 Jan 26;18(4):624-9.
4. Nelson SJ et al. Sci Transl Med 2013 Aug 14;5(198):198ra108.
5. Casey RT et al. JCO Precis Oncol. 2018 Mar 29;2:1-12.
6. Kurhanewicz J et al. Neoplasia 2019 Jan;21(1):1-16.
7. Granlund KL et al. Cell Metab. 2020 Jan 7;31(1):105-114.e3.
8. Casey RT et al. Clin Cancer Res. 2020 Jan 15;26(2):391-396.
9. Gallagher FA, Woitek R et al. Proc Natl Acad Sci U S A. 2020 Jan 28;117(4):2092-2098.
10. Woitek R & Gallagher FA. Br J Cancer. 2021 Mar;124(7):1187-1198.



Imaging for
Science and Life




AnyScan[®] & nanoScan[®] Families

Imaging solutions for clinical and preclinical applications

EANM 22
**WORLD
LEADING
MEETING**

35th Annual Congress of the
European Association of
Nuclear Medicine



BARCELONA

Oct 15 - 19, 2022

— eanm22.eanm.org —

PUBLISHER

European Association of Nuclear Medicine
Schmalzhofgasse 26, 1060 Vienna, Austria
Phone: +43 1 890 44 27 | Fax: +43 1 890 44 27 - 9
Email: office@eanm.org | URL: www.eanm.org

EDITORS

EANM Executive Office

CONTENT

No responsibility is taken for the correctness of this information. Information as per date of printing (August 2021).

LAYOUT & DESIGN

Olga Dogadina, EANM Executive Office
Christoph Sebel, EANM Executive Office