



Euroacademia Multidisciplinaria
Neurotraumatologica

2nd Annual Meeting of
Serbian Neurosurgical Society
SNSS Annual meeting 2016

in Conjunction with

21st Congress of Euroacademia
Multidisciplinaria
Neurotraumatologica

5th Congress in the
Danube-Carpathian Region



Joint Meeting with
Southeast Europe
Neurosurgical Society

**FINAL PROGRAM &
ABSTRACT BOOK**

Under the auspice of the President of the Republic of Serbia H. E. Mr Tomislav Nikolić

Endorsed by

Ministry of health of the Republic of Serbia
Government of the Autonomous Province of Vojvodina
Serbian Academy of Sciences and Arts
University of Novi Sad
Medical Faculty University of Novi Sad
Clinical Center of Vojvodina
Society of Physicians of Vojvodina of the Medical Society of Serbia

CONTROVERSIES IN NEUROTRAUMATOLOGY

Hosted and organized by Serbian Neurosurgical Society
and Southeast Europe Neurosurgical Society

October 20th-22nd 2016, Master centar, Novi Sad, Serbia

EACCME
18 CME credits
SHC
15 CME credits

<http://snss-seensns2016.talkb2b.net>



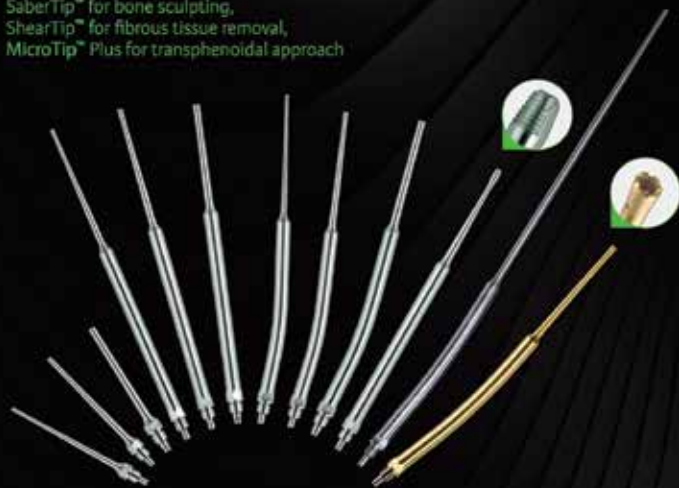Integra®

Neurosurgery Solutions

Limit uncertainty in Neurosurgery with the CUSA® Excel+ system

TipSelect™ : 12 tips, 12 solutions

Including 3 specialty tips:
SaberTip™ for bone sculpting,
ShearTip™ for fibrous tissue removal,
MicroTip™ Plus for transphenoidal approach



TissueSelect™ feature

Increases selectivity near critical structures

36 kHz Handpiece

Compact and light



Integra®

Neurocritical Care

Limit Uncertainty with Continuous ICP, P_tO₂ and Temperature Monitoring in One Platform



Design for Multimodality solution



Platform

with Camino ICP & Licox P_tO₂ Monitors

Introducer

with a single drill hole for ICP-P_tO₂-ICT parameters



Camino Catheters



Licox Probes and Introducers

Exclusive distributor:



DENTA BP PHARM

Južni bulevar 19, 11000 Belgrade, Serbia
Tel: +381 11 240 49 90, +381 11 240 48 60,

Fax: +381 11 240 43 35

e-mail: office@dentapharm.co.rs

www.dentapharm.co.rs

CONTROVERSIES IN NEUROTRAUMATOLOGY

2nd Annual Meeting of Serbian Neurosurgical Society
and
21st Congress of Euroacademia Multidisciplinaria Neurotraumatologica
in conjunction with
5th Congress in the Danube Carpathian Region
and
Joint Meeting with Southeast Europe Neurosurgical Society

October 20th–22nd 2016
Master centar, Novi Sad, Serbia

Hosted by
Serbian Neurosurgical Society (SNSS)
Southeast Europe Neurosurgical Society (SeENS)

Organized by
Serbian Neurosurgical Society (SNSS)
Southeast Europe Neurosurgical Society (SEENS)
Euroacademia Multidisciplinaria Neurotraumatologica
Danube Carpathian region

WELCOME ADDRESSES

Dear colleagues and friends,

It is my privilege, honour and pleasure to invite you to take part in the exciting journey of discovery at the Second Annual Meeting of the Serbian Neurosurgical Society conjoined with the 21st Congress of Euroacademia Multidisciplinaria Neurotraumatologica, the 5th Danube Carpathian Region Congress and Joint Meeting with Southeast European Neurosurgical Society, to be held in Novi Sad, Serbia, October 20–22, 2016.

Leaning upon the strong foundations of tradition and experience and following contemporary professional accomplishments, trends and innovations, all of us strive for neurosurgery and neuroscience without frontiers and aim at building bridges of knowledge and understanding across disciplines, institutions, individuals and generations.

In pursuit of enhancing knowledge, sharing and support through borderless cooperation, this unique interdisciplinary event focuses on one all-important and everlasting theme – **CONTROVERSIES IN NEUROTRAUMATOLOGY** – with the aim of bringing our fields of expertise closer in a true scholarly dialogue for the advancement of humanity within constant medical care for all our patients, particularly with head, spinal and peripheral nerve injuries starting at the site of the accident up to reintegration of patients into the society and their occupation following successful rehabilitation.

We are delighted to announce as the keynote speakers and faculties distinguished experts of all aspects in the field of neurotraumatology worldwide. The academic programme will be centred around the following thematic strands from basic considerations and research up to rehabilitation and quality of life:

- **Craniocerebral injuries**
- **Spinal injuries**
- **Peripheral nerve injuries**

Continuing the good practice established at The First Annual Meeting of the Serbian Neurosurgical Society held in Belgrade in 2015, we are pleased to announce the annual Serbian Neurosurgical Society Best Young Neurosurgeon Paper Award for 2016, this time with international participation. Eligible for the award are scientific papers by young neurosurgeons from Serbia and abroad (up to 40 years of age). The papers submitted for the award will be presented by their authors and assessed by a jury of national and international experts. The award is Full Participation in WFNS Congress 2017 in Istanbul, Turkey. EMN will provide awards for 5 best abstracts in the Young neuroscientist contest, selected by EMN Scientific Committee.

We are also pleased to announce Young Neurosurgeons' Forum as a special segment of the academic programme of the Congress.

Remaining dedicated to our long-term aim of building bridges of knowledge and understanding across disciplines, institutions, individuals and generations, always keeping in mind that the essence of our profession is above all the well-being of every individual patient, we look forward to further scientific, professional, academic, educational and social networking and exchange of expertise, experience and ideas.

You are welcome in Novi Sad, exciting city, with rich tradition and turbulent history, well known as midpoint of cultures and religions, multinational, multicultural and multiconfessional city with notable influence in science, culture and art of Southeast Europe. We are convinced that each of you will have memorable scientific and social moments in Novi Sad.

Prof. dr Lukas Rasulic

Lukas Rasulić

SNSS President

SeENS Vice President

Honorary President of the Congress



WELCOME ADDRESSES

Distinguished Colleagues,

As President of EMN, I have the distinct honor of welcoming you to the 21st EMN Congress, organized here in conjunction with the 2nd Annual Meeting of the Serbian Neurosurgical Society. We are also pleased to continue the tradition of the Congress in the Danube–Carpathian Region with its 5th edition under the auspices of SeENS, an initiative that we have set in motion 10 years ago, with the purpose of further growing our regional collaboration.

Organizing this joint meeting with an encompassing topic, "Controversies in Neurotraumatology" in Novi Sad, a multicultural and multiconfessional city, situated on the Danube shore has countless advantages. Not only does it have a symbolic value, as the Danube works as a liaison between nations, disseminating history, art and culture from its springs right up to its river mouths in the Black Sea, but it also fully respects all the values which EMN stands for: multidisciplinary, cooperation, friendship.

The remarkable interest this scientific event has stirred, the impressive participation and the topics that will be tackled, allow us to believe that we are going to take part in a certainly successful event.

Therefore, I must extend our gratitude towards the local organizing committee, enthusiast, hard-working, dedicated people who have ensured excellent venues for the unraveling of an unique scientific and social event in European neurotraumatology.

I am looking forward to meeting you all at the Congress in Novi Sad, where we will have the opportunity not only to enrich our knowledge in the distinctly complex field of neurotraumatology, but also to create new networks and friendships.

Prof. dr Ioan Stefan Florian



**EMN President
Honorary President of the Congress**



WELCOME ADDRESSES

Dear Colleagues,

The Southeast Europe Neurosurgical Society is proud to be co-organizer and has the pleasure and honor to invite You to the 21th Congress of the Euroacademia Multidisciplinaria Neurotraumatologica (EMN), the 5th Danube Carpathian region Congress and 2nd Annual meeting of the Serbian Neurosurgical Society in Novi Sad, October 20–22 2016.

The scope of this Joint Congress named Controversies in neurotraumatology is the medical care for the patients with head and spinal injuries, starting at the site of the accident to reintegration of patients into the society and into their occupation following successful rehabilitation.

This issue can only be solved within the scope of scientific, multidisciplinary dialogue and mutual professional cooperation. The congress topics will reflect the rapid development and continuous breakthrough in the field of neurotraumatology.

This Congress is going to take place in the beautiful city of Novi Sad that offers so many attractions to visit in order to strengthen our friendship and exchange experience during the social events.

We are looking forward to welcome you in Novi Sad.

Sincerely,

Prof. dr Kresimir Rotim



**SeENS President
Honorary President of the Congress**



WELCOME ADDRESSES

Dear colleagues and friends,

We are privileged to have opportunity to organize an international conjoined event in the field of neurotraumatology that is evolving and globally relevant in many aspects.

Controversies in Neurotraumatology will be international meeting of medical professionals leading the research in brain, spinal cord and peripheral nerves injury, from the basic sciences over translational research to clinical application and everything else in between.

The congress program will include opening lecture, Klaus von Wild lecture and plenary lectures by invited speakers, presentation of accepted papers and session for young investigators in neurotrauma science.

We are excited and proud to host the Controversies in Neurotraumatology in Novi Sad, Serbia in October 2016. Join us to make this event the best possible, to provide cutting edge science, learn from each other, and give yourself the opportunity to build friendships and foster international collaboration. What we can promise you are unforgettable social events and traditional Serbian hospitality which could transform this scientific meeting into once in a lifetime experience.

Judging by archaeological findings, Novi Sad has been a good place to live in for five thousand years already. Novi Sad is currently a cultural, economic, political and administrative center of Vojvodina (Autonomous Province of Serbia), modern university city that has grown on the tradition of continuity of cultural development. Together with you, we would like to put Novi Sad this autumn on the map of modern neurotraumatology community.

Welcome,

Prof. dr Petar Vulekovic



**President of the Organizing Committee
Head of Clinic of Neurosurgery
Clinical Center of Vojvodina, Novi Sad, Serbia**



Honorary Presidents of Congress



Prof. dr Ioan Stefan Florian
President, EMN



Prof. dr Kresimir Rotim
President, SeENS



Prof. dr Lukas Rasulic
President SNSS

Organizing Committee



Prof. dr Petar Vulekovic
President



Prof. dr Tomislav Cigic
Vice President



Asist. dr Djula Djilvesi
Secretary

Asist. dr Mladen Karan
Cashier

Doc. dr Ivan Levakov
Member

Scientific committee

Professor Robert Riener, MD, PhD, Zürich, Switzerland - President

Professor Klaus von Wild, MD, PhD, Munster, Germany

Professor Ioan Stefan Florian, MD, PhD, Cluj, Romania

Professor Ulrich Kunz, MD, PhD, Ulm, Germany

Professor Branko Djurovic, MD, PhD, Belgrade, Serbia

Professor Sanja Stojanovic, MD, PhD, Novi Sad, Serbia

Professor David Mendelow, MD, PhD, Newcastle, UK

Professor Alexander Potapov, MD, PhD, St. Petersburg, Russia

Professor Jean-Luc Truelle, MD, PhD, Paris, France

Honorary Committee

H.E. Mr. Tomislav Nikolic
President of the Republic of Serbia

Ass. dr Zlatibor Loncar
Minister of Health of the Republic of Serbia

Mr Igor Mirovic
President of the Government of the Autonomous Province of Vojvodina

Mr Zoran Gojkovic
Secretary of Health Autonomous Province of Vojvodina

Mr Milos Vucevic
Major of the City of Novi Sad

Prof. dr Zoltan Horvat
Member of the City Council for Health, The City of Novi Sad

Prof. dr Vladimir Kostic
President of the Serbian Academy of Sciences and Arts

Dr Dusan Nikolic
Rector of the University of Novi Sad

Prof. dr Snezana Brkic
Dean, University of Novi Sad

Prof. dr Petar Slankamenac
Director of the Clinical Center of Vojvodina

Prof. dr Dragan Dankuc
President of the Society of Physicians of Vojvodina
of The Medical Society of Serbia

FACULTY

Acar Feridun, Turkey
 Andelic Nada, Norway
 Andreev Alexander, Ukraine
 Andreou Alexandros, Greece
 Arafat Raed, Romania
 Arnautovic Kenan, USA
 Banczerowski Peter, Hungary
 Biloshytsky Vadym, Ukraine
 Bozic Boris, Croatia
 Buki Andras, Hungary
 Caparoski Aleksandar, Macedonia
 Ciurea Alexandru-Vlad, Romania
 Czernicki Zbigniew, Poland
 De Reuck Jacques, Belgium
 Delitala Alberto, Italy
 Demetriades Andreas, UK
 Devecerski Gordana, Serbia
 Djuraskovic Slavko, Montenegro
 Enchev Yavor, Bulgaria
 Filipce Venko, Macedonia
 Florian Ioan Stefan, Romania
 Foroglou Nicolas, Greece
 Fountas Konstantinos, Greece
 Gabrovsky Nikolay, Bulgaria
 Grotenhuis Andre, Nederland
 Hodzic Mirsad, BiH
 Horia Ples, Romania
 Hutchinson Peter, UK
 Iacoangeli Maurizio, Italy
 Klamroth-Marganska Verena, Switzerland
 Kolic Zlatko, Croatia
 Kolundzija Ksenija, Serbia
 Kopnitzky Zsolt, Hungary
 Kozic Dusko, Serbia
 Kunz Ulrich, Germany
 Lafuente Jesus, Spain
 Leon-Carrion Jose, Spain
 Likhterman Leonid, Russia
 Lubillo Santiago, Spain
 Maas Andrew, Belgium
 Masahiro Okuma, Japan

Mauer Uve Max, Germany
 Meixensberger Jurgen, Germany
 Milakovic Branko, Serbia
 Olldashi Fatos, Albania
 Omerhodzic Ibrahim, BiH
 Paterno Vincenzo, Germany
 Paul Esposito Domenic, Italia
 Rasulic Lukas, Serbia
 Rotim Kresimir, Croatia
 Saftic Robert, Croatia
 Sajko Tomislav, Croatia
 Samii Madjid, Germany
 Samii Amir, Germany
 Sanver Remzi, Turkey
 Selviaridis Panagiotis, Greece
 Servadei Franco, Italy
 Solaroglu Ihsan, Turkey
 Splavski Bruno, Croatia
 Michalakis Spyrou, Cyprus
 SteudelWolf Ingo, Germany
 Stojanovic Sanja, Serbia
 Stojanovic Nebojsa, Serbia
 Tomasello Francesco, Italy
 Truelle Jean-Luc, France
 Unterberg Andreas, Germany
 Velinov Nikolay, Bulgaria
 Vester Johannes, Germany
 Vickovic Sanja, Serbia
 Vitanovic Dusan, Hungary
 Vorsic Matjaz, Slovenia
 Vulekovic Petar, Serbia
 Winkler Peter, Austria
 Zaytsev Oleg, Russia

Special guest:

M. Remzi Sanver

CNRS, LAMSADE,

Université Paris Dauphine, Paris, France

"Thoughts on social sciences and the brain"

CONTINUOUS MEDICAL EDUCATION (CME) ACCREDITATION

"Controversies in Neurotraumatology" 2nd Annual Meeting of Serbian Neurosurgical Society and 21st Congress of Euroacademia Multidisciplinaria Neurotraumatologica, In conjunction with 5th Congress in the Danube Carpathian Region and Joint Meeting with Southeast Europe Neurosurgical Society is granted by the European Accreditation Council for Continuing Medical Education (EACCME), with the following number of points:

18 European CME credits (ECMEC)

The Congress is accredited by the Health Council of the Republic of Serbia as an International Congress, decision No.: 153-02-2768/2016-01 dated on August 18th 2016, document number A-1-1811/16, with the following number of points:

Lecturers:	15 points
Oral presentations:	13 points
Poster presentations:	11 points
Passive participation:	10 points
Oral and poster presentations coauthors: (maximum 3 coauthors)	0,5 points

The Nurses Symposium is accredited by the Health Council of the Republic of Serbia as a National Symposium, decision No.: 153-02-2768/2016-01 dated on August 18th 2016, document number D-1-948/16, with the following number of points:

Lecturers:	8 points
Oral presentations:	7 points
Poster presentations:	5 points
Passive participation:	4 points

FACTS ABOUT SERBIA

- **Name of state:** Republic of Serbia
- **Capital city:** Belgrade, population more than 1,600,000
- **Autonomous regions:** Autonomous Province of Vojvodina, Autonomous Province of Kosovo and Metohija
- **Geographic location:** Southeastern and Central Europe, Balkan Peninsula, Western Balkans
- **Area:** 88,509 km²
- **Climate:** moderate continental
- **Longest river:** Danube, Serbian section, 588 km
- **Highest mountain peak:** Djeravica (in the Prokletije range), 2656 m
- **International dialing code:** +381
- **Official currency:** the dinar (RSD)
- **National Internet domain:** .rs
- **National vehicle code:** SRB
- **Population (excluding Kosovo and Metohija):** more than 7,000,000, 83% Serbs
- **Official language:** Serbian
- **Official script:** Cyrillic
- **Faiths:** 85% Eastern Orthodox Christian, 5.5% Roman Catholic Christian, 3.2% Muslim
- **National holiday:** 15th February – Serbian National Statehood Day
- **Time zone:** central European, CET (GMT + 1 hour)
- **Electricity:** 220 – 230V, 50 Hz
- **Tap water from public mains:** Safe to drink



GENERAL INFORMATION ABOUT NOVI SAD

- **Location:** Serbia, Province Vojvodina
45°15' N, 19°51' E
- Located in the southern part of the Pannonian Plain, on the left bank of the Danube river, facing the northern slopes of Fruška Gora mountain
- **Time:** Central–European time (GMT+1)
- **Climate and Weather:** Moderate continental climate, with four seasons.
- **Currency:** RSD (subject to change)
 - 1 EUR = 123,00 RSD
 - 1 USD = 111,87 RSD
 - 1 GBP = 146,68 RSD
 - 1 CHF = 113,45 RSD
- The capital of Vojvodina, northern province of Serbia
- The city has a population of 250 000, the city region of 340 000

HOW TO GET TO NOVI SAD

- **By plane**
Novi Sad does not have an international airport and the closest one is Nikola Tesla Airport (IATA: BEG) near Belgrade (about 70 kilometers). Provide your flight details to local agency Panacomp earlier, and they will organize transfer for you by TAXI – special price for this transfer is 30€. Check point for faculty and participants of the Congress will be available on Belgrade airport.
- **By car**
E-75 highway that connects Belgrade and Budapest passes by Novi Sad, E-70 highway which is some 40km south/west of Novi Sad connects Ljubljana, Zagreb and Belgrade.
- **By train**
Novi Sad is on the international railway route Vienna – Budapest – Novi Sad – Belgrade – Istanbul, from Belgrade there are also railway routes to Timisoara and Bucharest (Romania) as well as to Zagreb (Croatia), Ljubljana (Slovenia) and further to Italy and Austria.
- **By Danube river**
Between 1252 and 1262 kilometers of the Danube watercourse.



VENUE

Master centar – Congress Centre

Hajduk Veljkova 11
Novi Sad 21000

Phone: +381 (0)21 4830000

www.sajam.net/live/Kongresni+centar/Info



ACCOMMODATION

Hotel Master *****

www.a-hotel-master.com



Hotel Park *****

www.hotelparkns.com/



Hotel Best Western President *****

www.prezidenthotel.com



Hotel Centar ****

www.hotel-centar.rs



Hotel Sajam ***

www.hotelsajam.co.rs



Tourist resort "Ribarsko ostrvo" *****

<http://ribarskoostrvo.rs>



IMPORTANT CONGRESS INFORMATION

AWARDS

EMN AWARD

EMN will provide awards for Young neuroscientist contest. The best 5 abstracts will be selected by EMN Scientific committee. All of them will be awarded with 250€ for travel expenses, and the best presentation in special session will be awarded with additional 250€.

ANNUAL SERBIAN NEUROSURGICAL SOCIETY (SNSS)

BEST YOUNG NEUROSURGEON PAPER AWARD

Eligible for the award are scientific papers by young neurosurgeons from Serbia, which will be assessed by a jury of national and international experts. The papers submitted for the award will be presented by their author.

Award: Full participation in XVI World Congress of Neurosurgery–WFNS 2017, in Istanbul, Turkey.

It should be clearly specified in application form and e–mail message with abstract submission how old author is. All authors younger than 40 years can apply for EMN and SNSS awards.

TOPICS

The congress will have three main topics: **Traumatic brain injury, spinal cord injury and peripheral nerves injury**. Regarding this topics, following issues will be debated:

1. Basic research and clinical trials
2. Diagnostics
3. Treatment
4. Rehabilitation and outcome
5. Medico–legal aspects and litigation

SNSS & SeENS PCO

MIROSS TRAVEL AGENCY

Address: Majke Jevrosime 19/1

11000 Belgrade, Serbia

Tel: +381.11.30 33 225

+381.11.30 33 226

Fax: +381.11.30 34 615

Web: www.miross.rs

E–mail: sns–seensns2016@miross.rs



LOCAL AGENCY

PANACOMP WONDERLAND TRAVEL

Address: Bulevar Cara Lazara 96,

21000 Novi Sad, Serbia

Tel: +381 21 466 075

+381 21 466 076

+381 21 466 077

Skype: [panacomp.travel](https://www.skype.com/panacomp.travel)

Web: www.panacomp.net



Partners / Sponsors / Exhibitors / Friendship & Support

Novi Sad 2016

One Region, One Neurosurgery

INDUSTRY AMBASSADOR



DENTA BP PHARM-INTEGRA

INDUSTRY PREMIER PARTNER



INDUSTRY ALLIES COUNCIL

MAC's MEDICAL Group

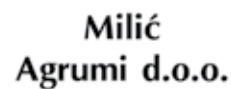
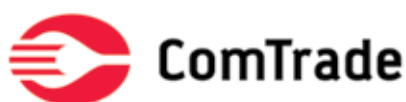
kasios®



INDUSTRY SUPPORTER



FRIENDSHIP & SUPPORT




Partners / Sponsors / Exhibitors / Friendship & Support



Under the auspice of the President of the Republic of Serbia
H. E. Mr Tomislav Nikolic

CONGRESS ENDORSED BY

- Ministry of Health of the Republic of Serbia
- Government of the Autonomous Province of Vojvodina
- Serbian Academy of Sciences and Arts
- University of Novi Sad
- Medical Faculty University of Novi Sad
- Clinical Center of Vojvodina
- Society of Physicians of Vojvodina of the Medical Society of Serbia
- National tourism organisation of Serbia
- Serbia Convention Bureau

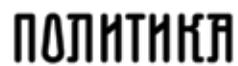

NATIONAL TOURISM ORGANISATION of SERBIA



SERBIA CONVENTION BUREAU

MEDIA PARTNERS

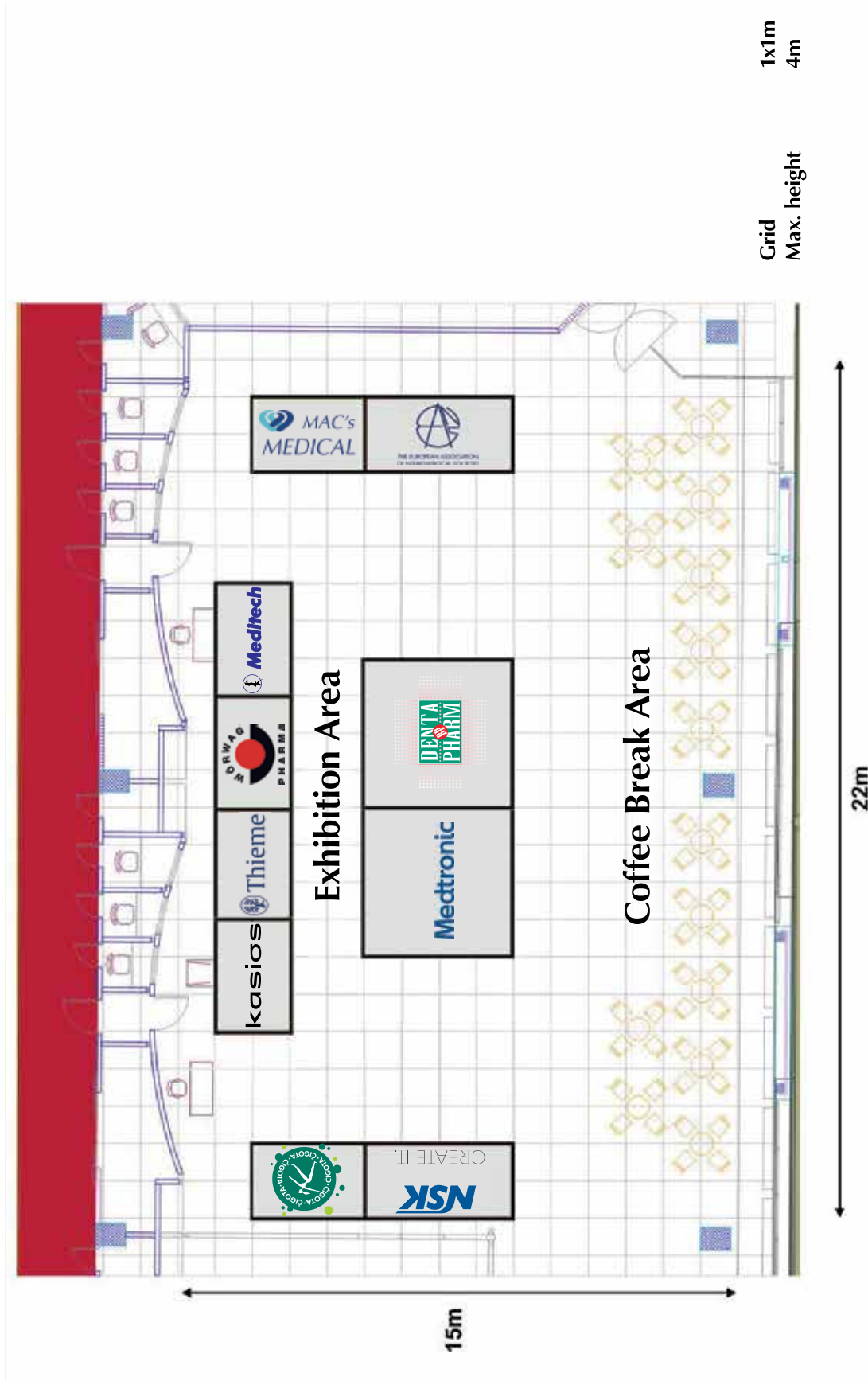


SERBIAN NEUROSURGICAL SOCIETY OFFICIAL
PHOTO & VIDEO PARTNER AND ARCHIVE



MAR ARTIKS KODAK Digital Solutions

EXHIBITION FLOOR PLAN & LIST OF EXHIBITORS



SOCIAL PROGRAM

Wednesday, October 19th 2016

20:00–22:00 **Welcome faculty reception**
Hotel Master
Brace Popovic bb, Novi Sad
by invitation only

Thursday, October 20th 2016

19:00–20:00 **Welcome reception**
City Hall

20:00–23:00 **Presidential dinner**
Restaurant Pancetta,
Njegoseva 12, Novi Sad
City Hall walking distance
by invitation only

Friday, October 21th 2016

16:30–18:30 **Trip to Petrovaradin Fortress**

20:30–00:00 **Networking dinner**
Restaurant Ribarac, Alaska Barka
Ribarsko ostrvo, Novi Sad

PROGRAM AT GLANCE

WEDNESDAY, October 19th 201620:00-22:00 Welcome faculty reception - *by invitation only*THURSDAY, October 20th 2016

07:00 Registration

Hall 1

Opening Ceremony

- *Lukas Rasulic, SNSS President*
- *Tomislav Nikolic, President of the Republic of Serbia*
- *Zlatibor Loncar, Minister of Health of the Republic of Serbia*
- *Igor Mirovic, President of Government of the Autonomous Province of Vojvodina*
- *Zoran Gojkovic, Secretary of Health Autonomous Province of Vojvodina*
- *Vladimir Kostic, President of the Serbian Academy of Sciences and Arts*
- *Dusan Nikolic, Rector of the University of Novi Sad*
- *Snezana Brkic, Dean of the Medical Faculty*
- *Petar Slankamenac, Director of the Clinical Center of Vojvodina*
- *Dragan Dankuc, President of the Physicians Association of Vojvodina*
- *Ioan Stefan Florian, EMN President*
- *Kresimir Rotim, SeENS President*
- *Petar Vulekovic, OC President*

08:00-09:00

09:00-10:20 Key note lectures / Hall 1

10:20-10:30 Coffee break

10:30-10:50 Special guest lecture / Hall 1

10:50-12:35 Plenary session 1 / Hall 1

12:35-13:50 Plenary session 2 / Hall 1

13:50-14:30 Lunch on symposium - *Medtronic - Critical care and spine trauma portfolio*

14:30-16:15 Main session 1 / Hall 1

16:15-16:35 Coffee break

16:35-18:15 Oral presentations and free topics / Hall 1

Hall 2

13.50-14.30 SEENS EC Meeting and SEENS General Assembly / Hall 2

14.30-16.15 Main session 2 / Hall 2

16.15-16.35 Coffee break

16.35-18.15 Young neurosurgeons SNSS and EMN award with international participation / Hall 2

18.45 Shuttle bus for Welcome reception

19.00-20.00 Welcome reception – City Hall - *Petar Vulekovic, Milos Vucevic, Zoltan Horvat*20.00-23.00 Presidential dinner - Restaurant Pancetta
Njegoseva 12, Novi Sad
City Hall walking distance - *by invitation only*

PROGRAM AT GLANCE

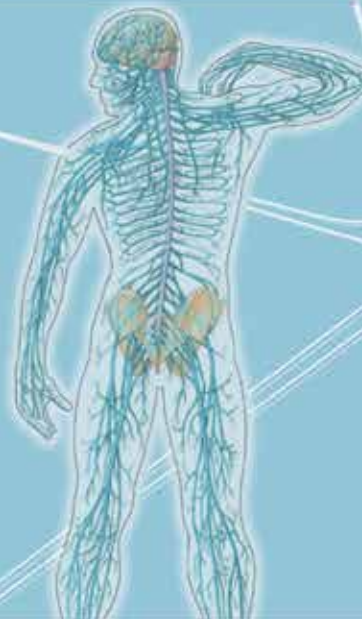FRIDAY, October 21 th 2016	
07:00	Registration
	Hall 1
08:30-09.30	Key note lectures / Hall 1
09.30-09.40	Coffee break
09.40-11.40	Plenary session 1 / Hall 1
11.40-11.50	Coffee break
11.50-13.50	Plenary session 2 / Hall 1
13.50-14.30	Lunch on symposium - <i>Integra</i>
14.30-15.55	Main session 1 / Hall 1
	Hall 2
09.30-12.00	Nurses Symposium / Hall 2
12.00-12.15	SeENS Nursing Section meeting
12.15-13.00	SNSS EC Meeting and General Assembly
13.00-14.00	Poster session / Area for posters
11.30-13.00	EMN Presidium meeting / Master center Conference room
13.00-14.30	EMN Members meeting / Hall 2
14.30-15.55	Main session 2 / Hall 2
16.15	Shuttle transportation for Petrovaradin Fortress from Master Center
16.30-18.30	Petrovaradin Fortress sightseeing
18.30	Shuttle transportation to hotels
20.00	Shuttle transportation to Restaurant Ribarac - Networking dinner
20.30-00.00	Networking dinner - Restaurant Ribarac
23.30-00.00	Shuttle transportation to hotels
SATURDAY, October 22 th 2016	
07:00	Registration
	Hall 1
08.00-09.20	Key note lectures / Hall 1
09.20-11.20	Plenary session / Hall 1
11.20-11.35	Coffee break
11.35-13.45	Main session / Hall 1
	Hall 2
11.35-13.45	SeENS Young Neurosurgeons forum Oral presentations and free topics / Hall 2
	Hall 1
13.45-14.00	CONTROVERSIES IN NEUROTRAUMATOLOGY NOVI SAD 2016 Final remarks and closing ceremony / Hall 1
14.30-19.00	Trip to Sremski karlovci - Optional



Southeast Europe Neurosurgical Society - S^eENS

- Background
- Past events
- Current activities
- Looking forward to
- Up to date

EDITORIAL



DOWNLOAD LINK:

http://www.seens.eu/userfiles/file/Southeast_European_Neurosurgical_Society_SeENS_EDITORIAL_1_res.pdf

http://snss.rs/Editorijal_2016.pdf

http://snss-seensns2016.talkb2b.net/upload/Attachment/File/2016_10/Editorijal_2016.pdf

CONTROVERSIES IN NEUROTRAUMATOLOGY

**October 20th–22nd 2016
Master centar, Novi Sad, Serbia**

PROGRAM

<http://snss-seensns2016.talkb2b.net>



Wednesday, October 19th

20.00–22.00 **Welcome faculty reception**

Thursday, October 20th

07.00 **Registration**

08.00–09.00 **Opening Ceremony**

Lukas Rasulic, SNSS President
 Tomislav Nikolic, President of the Republic of Serbia
 Zlatibor Loncar, Minister of Health of the Republic of Serbia
 Igor Mirovic, President of Government of the Autonomous Province of Vojvodina
 Zoran Gojkovic, Secretary of Health Autonomous Province of Vojvodina
 Vladimir Kostic, President of the Serbian Academy of Sciences and Arts
 Dusan Nikolic, Rector of the University of Novi Sad
 Snezana Brkic, Dean of the Medical Faculty
 Petar Slankamenac, Director of the Clinical Center of Vojvodina
 Dragan Dankuc, President of the Physicians Association of Vojvodina
 Ioan Stefan Florian, EMN President
 Kresimir Rotim, SeENS President
 Petar Vulekovic, OC President

Hall 1

KEY NOTE LECTURES

09.00–09.20 **Milivoje Kostic lecture**
Management of traumatic brachial plexus injury
 Madjid Samii, Germany
INTRO Lukas Rasulic

09.20–09.40 **Quality of Life after Traumatic Brain Injury: new developments**
 Jean-Luc Truelle, France
INTRO Ulrich Kunz

09.40–10.00 **New directions in TBI research**
 Andrew Maas, Belgium
INTRO Petar Vulekovic

10.00–10.20 **Management of chronic subdural hematomas**
 Panagiotis Selviaridis, Greece
INTRO Lukas Rasulic

10.20–10.30 *Coffee break*

Hall 1

Special guest lecture

10.30–10.50 **Thoughts on social sciences and brain studies**
 Remzi Sanver, France
INTRO Lukas Rasulic

Hall 1**PLENARY SESSION 1***Moderators: Kresimir Rotim, Petar Vulekovic, Lukas Rasulic*

- | | |
|-------------|---|
| 10.50–11.05 | The Organization of the Emergency Response System in Romania
Dr. Raed Arafat, Secretary of State at the Ministry of Internal Affairs, Romania |
| 11.05–11.20 | Decompressive Craniectomy – Why we still perform it after the DECRA trial?
Ioan Stefan Florian, Romania |
| 11.20–11.35 | The auditory midbrain implant – a new prosthesis for hearing restoration in neuronal deafness
Amir Samii, Germany |
| 11.35–11.50 | Traumatic Extracranial and Intracranial Dissections. Diagnosis and Therapeutic management
Alexandros Andreou, Greece |
| 11.50–12.05 | Microsurgical anatomy of the thoracic spine: the fundamentals of the thoracic spinal stability
Kenan Arnautovic, USA |
| 12.05–12.20 | Paradigm shift in traumatic brain injury: Does "minimal" require maximal attention?
Andras Buki, Hungary |
| 12.20–12.35 | The NOSTRA Trial in severe TBI
Andreas Unterberg, Germany |

Hall 1**PLENARY SESSION 2***Moderators: Andrew Maas, Ioan Stefan Florian, Kenan Arnautovic*

- | | |
|-------------|--|
| 12.35–12.50 | How much decompression, and how fast, should be done in cervical spine fracture with neurologic deficit
Ulrich Kunz, Germany |
| 12.50–13.05 | Epidemiology and prevention of TBI in Europe: New facts
Wolf Ingo Steudel, Germany |
| 13.05–13.20 | The influence of post traumatic hypopituitarism on recovery after traumatic brain injury
Kresimir Rotim, Croatia |
| 13.20–13.35 | Controversies in nerve transfers for upper brachial plexus palsy due to traction injuries
Lukas Rasulic, Serbia |
| 13.35–13.50 | Decompressive Craniectomy: A Life Saver? Myths & Facts
Konstantinos Fountas, Greece |

- | | |
|--------------------|--|
| 13.50–14.30 | Lunch on symposium
<i>Medtronic – Critical care and spine trauma portfolio</i> |
|--------------------|--|

Hall 1**MAIN SESSION 1**

Moderators: Wolf Ingo Steudel, Mauer Uve Max, Konstantinos Fountas

- | | |
|-------------|---|
| 14.30–14.47 | Lobar haematomas: neuropathological and 7.0-tesla magnetic resonance imaging evaluation
Jacques De Reuck, Belgium |
| 14.47–14.59 | The management of craniocerebral trauma
Fatos Olldashi, Albania |
| 14.59–15.11 | Abnormal Cognitive Aging
José León–Carrión, Spain |
| 15.11–15.23 | Decompressive vs hinge craniectomy: difference in technique and outcome
Ibrahim Omerhodzic, Bosnia and Herzegovina |
| 15.23–15.35 | Monitoring of posttraumatic cerebral hemodynamics by transcranial Doppler sonography – a novel perspectives
Bruno Splavski, Croatia |
| 15.35–15.47 | Radiological Approach to Neurotraumatology
Sanja Stojanovic, Serbia |
| 15.47–15.59 | The Clinical and Neuropsychological Evaluation of the Brain Injured Professional (NFL) Athlete
Domenic Paul Esposito, USA |
| 15.59–16.15 | <i>Discussion</i> |
| 16.15–16.35 | <i>Coffee break</i> |

Hall 1**ORAL PRESENTATIONS AND FREE TOPICS**

Moderators: Ibrahim Omerhodzic, Fatos Olldashi, Venko Filipce

- | | |
|-------------|--|
| 16.35–16.43 | What is the exact time interval to perform the decompressive craniectomy in traumatic brain injury?
Matijaz Vorsic, Slovenia |
| 16.43–16.51 | Computerized static posturography and vestibular dysfunction in acute period of concussion
Alexander Andreev, Ukraine |
| 16.51–16.59 | The effect of early and postponed decompressive craniectomy on time spent in ICU and outcome in traumatic brain injury patients
Djula Djilvesi, Serbia |
| 16.59–17.07 | Decompressive craniectomy in the treatment of complex severe traumatic brain injury
Boris Bozic, Croatia |
| 17.07–17.15 | Exogenous and endogenous factors that modulate opportunities for reemployment of persons living with sequels following spinal cord injury
Aurelian Anghelescu, Romania |
| 17.15–17.25 | <i>Discussion</i> |

- 17.25–17.33 **The incidence of chronic subdural hematoma with patients on anticoagulant therapy**
Vesna Nikolov, Serbia
- 17.33–17.41 **Additive technologies in skull defect reconstruction new porous and mesh Titanium composite implants**
Alexander Kravchuk, Ukraine
- 17.41–17.49 **Controversion at the head injury**
Milan Popovic, Slovenia
- 17.49–17.57 **Unstable ICP in severe brain injury: a bad omen**
Maurizio Gladi, Italy
- 17.57–18.05 **Psychological and psychiatric care for children with severe spinal cord injury**
Ekaterina L'vova, Russia
- 18.05–18.15 *Discussion*

Hall 2

**13.50–14.30 SEENS EC Meeting and
SEENS General Assembly**
MAIN SESSION 2
Moderators: Santiago Lubillo, Tomislav Cigic, Ihsan Solaroglu

- 14.30–14.47 **Management of craneocervical fractures**
Jesus Lafuente, Spain
- 14.47–14.59 **Cognitive and Emotional Disturbances after TBI**
Ksenija Kolundzija, Serbia
- 14.59–15.11 **Ruptured Anterior Communicating Artery Aneurysms.
An experience of 513 cases treated using open microsurgery &
a comparative view on management policies in two centers**
Horia Ples, Romania
- 15.11–15.23 **The role of functional brain cleavage in consciousness disorders**
Oknina Ljubov, Russia
- 15.23–15.35 **Surgery versus Conservative Treatment in Patients with Traumatic
Intracerebral Hemorrhage**
Mirsad Hodzic, Bosnia and Herzegovina
- 15.35–15.47 **When decompressive craniectomy improves the outcome of TBI patients**
Zbigniew Czernicki, Poland
- 15.47–15.59 **Cranial head trauma in newborn infants**
Zlatko Kolic, Croatia
- 15.59–16.15 *Discussion*
- 16.15–16.35 *Coffee break*

Hall 2

**YOUNG NEUROSURGEONS SNSS AND EMN AWARD
WITH INTERNATIONAL PARTICIPATION**
International jury and moderators:
*Ulrich Kunz, Verena Klamroth–Marganska, Amir Samii,
Nebojsa Stojanovic, Branko Djurovic*

- 16.35–16.43 **Surgical vs nonsurgical treatment of intracranial traumatic haemathoma,
single center experience**
Marko Samardzic, Serbia
- 16.43–16.51 **Endoscope–assisted evacuation of chronic subdural haematomas –
121 Minimally–invasive procedures**
Bogomil Iliev, Bulgaria
- 16.51–16.59 **Selective brain hypothermia transiently improves the neurological recovery
in the mouse model of decompressive craniectomy after closed head injury**
Jacek Szczygielski, Germany

- 16.59–17.07 **Influence of anticoagulant therapy on development of chronic subdural haematomas in Province of Vojvodina**
Antun Azasevac, Serbia
- 17.07–17.15 **CT scoring scales at the early outcome predictors in patients with TBI: which one to use?**
Jagos Golubovic, Serbia
- 17.15–17.23 **Diffusion tensor imaging and neuropsychological examination in mild traumatic brain injury**
Mladen Karan, Serbia
- 17.23–17.31 **Differences in admission findings, mechanism of injury and CT scan findings between pediatric and adult TBI patients**
Miroslav Fimic, Serbia
- 17.31–17.39 **Results od distal nerve transfers in nerve injuries of the upper extremity over 3 year period**
Andrija Savic, Serbia
- 17.39–17.47 **Endovascular treatment of post-traumatic direct carotid cavernous fistulas**
Filip Vitosevic, Serbia
- 17.47–17.55 **Intraventricular intracranial pressure monitoring and it's role in treatment in patient with TBI**
Aleksandar Miljkovic, Serbia
- 17.55–18.03 **Clinical prediction rules for positive Computed Tomography scan in patients with mTBI**
Bojan Jelaca, Serbia
- 18.03–18.15 *Discussion*
- 18.45 Shuttle bus for Welcome reception**
TBA
- 19.00–20.00 Welcome reception – City Hall**
Petar Vulekovic, President of the Organizing Comittee
Milos Vucevic, Mayor of the city of Novi Sad
Zoltan Horvat, Secretary of health, city of Novi Sad
- 20.00–23.00 Presidential dinner – Restaurant Pancetta**
Njegoseva 12, Novi Sad – City Hall walking distance – by invitation only

Friday, October 21st

07.00 Registration

Hall 1

KEY NOTE LECTURES

08.00–08.20 **Medico–legal aspects of alleged traumatic disc herniation**
 Andre Grotenhuis, Nederland
INTRO Kresimir Rotim

08.20–08.40 **Multimodal Neuromonitoring: Possibilities and Impact on treatment of severe TBI patients**
 Jurgen Meixensberger, Germany
INTRO Tomislav Sajko

08.40–09.00 **The Cybathlon – Moving People and Technology**
 Verena Klamroth–Marganska, Switzerland
INTRO Djula Djilvesi

09.00–09.30 **Klaus won Wild lecture – New horizons in brain trauma management**
 Peter Hutchinson, UK
INTRO Ioan Stefan Florian

09.30–09.40 Coffee break

Hall 1

PLENARY SESSION 1

Moderators: Peter Hutchinson, Alexandros Andreou, Andras Buki

09.40–09.55 **Head trauma management in infants (0 –1 year old)**
 Alexandru–Vlad Ciurea, Romania

09.55–10.10 **Concomitant Craniospinal trauma**
 Andreas Demetriades, UK

10.10–10.25 **Reconstruction of the calvarial defects using 3D CAD–CAM cranioplasty**
 Dusan Vitanovic, Hungary

10.25–10.40 **Is a so–called mild whiplash injury always a mild cervical spine injury?
 A study with motor evoked potentials**
 Jacque De Reuck, Belgium

10.40–10.55 **Common sense and scientific knowledge in neurotraumatology:
 contradicting or mutually complementing?**
 Leonid Likhterman, Russia

10.55–11.10 **Outcome from mild traumatic brain injury –
 Predicting value of mri**
 Petar Vulekovic, Serbia

11.10–11.25 **Management of neurosurgical intensive patients with post traumatic
 decompressive craniectomy**
 Vincenzo Paterno, Germany

11.25–11.40 **Epidural hematomas of posterior fossa**
 Danilo Radulovic, Serbia

11.40–11.50 Coffee break

Hall 1**PLENARY SESSION 2***Moderators: Andreas Unterberg, Feridun Acar, Oleg Zaitsev*

- 11.50–12.05 **The risk factor of blunt cerebrovascular injury in patients with cervical spine injury: the SIMC experience**
Okuma Masahiro, Japan
- 12.05–12.20 **Current concept in treatment of mild traumatic brain injuries**
Petrela Mentor, Albania
- 12.20–12.35 **Is it time to change our conventional osmotic diuretics in patients with intracranial hypertension?**
Santiago Lubillo, Spain
- 12.35–12.50 **Percutaneous transpedicular fixation in spinal trauma**
Nikolay Gabrovsky, Bulgaria
- 12.50–13.05 **Management of Cervical Spine and Spinal Cord Injuries**
Ihsan Solaroglu, Turkey
- 13.05–13.20 **Indication for ICP monitoring in brain injury**
Uve Max Mauer, Germany
- 13.20–13.35 **The influence of anticoagulation therapy on traumatic brain injury patient outcome**
Tomislav Sajko, Croatia
- 13.35–13.50 **Efficacy of DREZ lesioning in managing pain following spinal cord injury**
Milan Spaic, Serbia
- 13.50–14.30 **Lunch on symposium – Integra – Multi-modal monitoring of the brain – INTEGRA Solution**

Hall 1**MAIN SESSION 1***Moderators: Nikolay Velinov, Mirsad Hodzic, Andreas Demetriades*

- 14.30–14.42 **What and why should be monitored in sever traumatic brain injuries?**
Zsolt Kopniczky, Hungary
- 14.42–14.54 **Neuromonitoring in Critical Care Unit**
Branko Milakovic, Serbia
- 14.54–15.06 **Anaesthesia for Head Trauma**
Sanja Vickovic, Serbia
- 15.06–15.18 **The simple interrupted skin suture versus the running subcutaneous suture in cranial surgery**
Yavor Enchev, Bulgaria
- 15.18–15.30 **Peripheral Nerve Injuries Strategies for Reconstruction**
Lucian Fodor, Romania
- 15.30–15.42 **Management of the posttraumatic seizures**
Slavko Djuraskovic, Montenegro
- 15.42–15.55 *Discussion*

Hall 2**NURSES SYMPOSIUM***Moderators: Vladimir Papic, Novka Lipovcan, Arsen Uvelin*

08.30–09.30	Registration
09.30–10.00	OPENING CEREMONY Kresimir Rotim Petar Vulekovic Ioan Stefan Florian Lukas Rasulic Sandra Milosevic Biljana Kurtovic Mirsada Custovic
10.00–10.10	The basics of health care process for neurotrauma: planning, individualization and documenting Dragana Nikolic, Serbia
10.10–10.20	Contemporary algorithms in neurotraumatized patients – treatment from the aspect of a neuro–nurse Mirsada Custovic, Bosnia and Herzegovina
10.20–10.30	The value of predictiveness in following the state of consciousness Ivana Dondo, Serbia
10.30–10.40	The nurse competencies in implementing the care protocol for patients with intracranial haemorrhage Ivan Havrlisan, Croatia
10.40–10.50	Guidelines for pre–hospital care management for patients with neurotrauma Biljana Kurtovic, Croatia
10.50–11.00	Validation of the outcome of treating alcoholized patients with head injury, case report Mirjana Sestak, Croatia
11.00–11.10	The standard clinical operational procedures for patients with traumatic injury of cervical spine Cecilija Rotim, Croatia
11.10–11.20	The characteristics of interdisciplinary approach to cervicocranial traction in treating cervical spine fracture and luxation Anita Brblic, Croatia
11.20–11.30	The human factor: the critical importance of effective team work and communication in providing safe treatment in operating theatre Vesna Svircevic, Croatia
11.30–11.40	The protocol of operational technique of invasive intracranial pressure measurement Sandra Milosevic, Serbia
11.40–11.50	An analytical presentation of scrub nurse procedures in neurosurgical treatment of subdural haematoma Ivana Strbac, Serbia
11.50–12.00	Perioperational treatment of patients with epidural haemorrhage: A five–year retrospective study of the Neurosurgery Clinic, KBC Osijek Sanja Moser, Croatia
12.00–12.15	SEENS NURSING SECTION MEETING

Hall 2

12.15–13.00 **SNSS EC Meeting and
SNSS General Assembly**

Area for posters

13.00–14.00 **POSTER SESSION**

*Moderators: Peter Banczerowski, Bruno Splavski, Milan Spaic,
Boris Bozic*

**Blepharospasm as a consequence of chronic subdural haematoma:
an interesting case**

Tomaz Velnar, Slovenia

**Indications, cautions & limits of interdisciplinary approach: physical &
rehabilitation medicine – orthopedics, in patients with severe neurological
pathology (preliminary data)**

Aurelian Anghelescu

**Craniocerebral trauma as result of a compressor tube explosion:
a case report**

Tomaz Velnar, Slovenia

**Depressed and Open Skull Fractures Over the Superior Sagittal Sinus.
Presentation of Three Cases and Literature Review**

Haralampos Gatos, Greece

Posterior Fossa Skull Fractures, Two Illustrative Cases and Literature Review

Haralampos Gatos, Greece

Le Fort type 3 fracture or not? – CT scan reliability

Vuk Aleksic, Serbia

**Dural metastasis misdiagnosed as a bilateral subdural hematoma – a case
report and a review of literature**

Vuk Aleksic, Serbia

**The use of Mini–Mental State Examination in the assessment of mental status
of patients with mild traumatic brain injuries – yes or no?**

Zeljka Nikolasevic, Serbia

Executive functions in patients with mild traumatic brain damage

Vojislava Bugarski, Serbia

Post-traumatic leptomenigeal cyst in a 9 month old infant – case report

Boris Djurovic, Montenegro

Death after concussion – case report

Arsenije Radunovic, Montenegro

**Transarterial endovascular treatment of carotid–cavernous fistula –
case report and review of literature**

Aleksandar Spasic, Serbia

**Surgical removal of intracranial fragments after gunshot injury – mandatory
or not? Intracranial and chest bullets retained for 35 years – a case report
and a review of literature**

Vuk Aleksic, Serbia

Surgical treatment of growing skull fracture in children

Bojana Zivkovic, Serbia

Craniotomy or craniectomy for acute subdural hematoma

Luka Borovinic, Montenegro

Neuroimaging after mild traumatic brain injury in Clinic of neurosurgery in Belgrade – is it really mild?

Jelena Taskovic, Serbia

Evaluation of neuroradiological parameters in the revised CT score as a predictor of outcome in patients with traumatic brain injury

Filip Pajicic, Serbia

Early outcome in patients with severe traumatic brain injury

Dragan Jankovic, Croatia

Employment of persons with disabilities in Romania

Aurelian Anghelescu, Romania

Decompressive craniectomy for severe traumatic brain injury: case report and literature overview

Igor Horvat, Serbia

Growing skull fractures in children a 10 year follow up study from a single center

Milan Mrdak, Serbia

Traumatic intracranial pseudoaneurysms treated by endovascular embolisation

Filip Vitosevic, Serbia

Case report of a rare foreign object embedded in brain tissue for 38 years

Irena Cvrkota, Serbia

Our involvement in CENTER–TBI Study

Jagos Golubovic, Serbia

Traumatic subarachnoid hemorrhage: does it affect early outcome and what are the possible risk factors? A single center experience

Jagos Golubovic, Serbia

Cranioplasty for relief of chronic pain – 70 years after the debridement of the WWII penetrating craniocerebral injury

Igor Popovic, Serbia

Trauma induced eosinophilic granuloma in a child with tuberous sclerosis

Fahrudin Alic, Bosnia and Herzegovina

The role of robots in the (re)habilitation of children with brain injury

Rastislava Krasnik, Serbia

Nerve grafting in peripheral nerves injuries in children

Novak Lakicevic, Montenegro

Depression in patients with mild traumatic brain damage

Vojislava Bugarski, Serbia

Quality of life assessment in patients with mild traumatic brain damage

Zeljka Nikolasevic, Serbia

Master center Conference room

11.30–13.00 EMN Presidium meeting

Hall 2

13.00–14.30 EMN Members meeting

Hall 2

MAIN SESSION 2

Moderators: Domenic Paul Esposito, Horia Ples, Djula Djilvesi

- | | |
|--------------------|--|
| 14.30–14.42 | Endoscopic spine surgery for traumatic disc herniation
Robert Saftic |
| 14.42–14.54 | Surgical management of subaxial cervical fractures
Fatos Olldashi, Albania |
| 14.54–15.06 | Basic principles of the instrumentalization of old post-traumatic changes in the cervical spine
Nebojsa Stojanovic, Serbia |
| 15.06–15.18 | The influence of anterior interbody fusion with allograft onto cervical spine functional outcome
Goran Lakicevic, Bosnia and Herzegovina |
| 15.18–15.30 | Spinal injury, modern aspect and Cyprus reality
Michalakis Spyrou, Cyprus |
| 15.30–15.42 | Assessment of outcome in patients with severe traumatic brain injury with intraaxial compressive hemathoma treated with decompressive craniectomy. A one centre retrospective study
Venko Filipce, Macedonia |
| 15.42–15.55 | <i>Discussion</i> |
| 16.15 | <i>Shuttle transportation for Petrovaradin Fortress from Master center</i> |
| 16.30–18.30 | <i>Petrovaradin Fortress sightseeing</i> |
| 18.30 | <i>Shuttle transportation to hotels</i> |
| 20.00 | <i>Shuttle transportation to Restaurant Ribarac – Networking dinner</i> |
| 20.30–00.00 | <i>Networking diner – Restaurant Ribarac</i> |
| 23.30–00.00 | <i>Shuttle transportation to hotels</i> |

Saturday, October 22nd

07.00 **Registration**

Hall 1

KEY NOTE LECTURES

- 08.00–08.20 **ICP monitoring: a controversial issue for the Neurosurgeon**
Franco Servadei, Italy
INTRO Ioan Stefan Florian
- 08.20–08.40 **Reconstruction of the severely injured limbs**
Marko Bumbasirevic, Serbia
INTRO Lukas Rasulic
- 08.40–09.00 **New challenges for neurosurgical education and research in the global scenario: an European perspective**
Francesco Tomasello
INTRO Lukas Rasulic
- 09.00–09.20 **Trends and challenges in rehabilitation following traumatic brain injury**
Nada Andjelic, Norway
INTRO Djula Djilvesi

Hall 1

PLENARY SESSION

Moderators: Francesco Tomasello, Alexandru Vlad Chiurea, Peter Winkler

- 09.20–09.35 **Towards a new gold standard to improve TBI clinical research – CAPTAIN trial design and rationale**
Johannes Vester, Germany
- 09.35–09.50 **Endoscopic management of optic neuropathy in craniofacial trauma**
Nicolas Foroglou, Greece
- 09.50–10.05 **Mood disturbances after severe traumatic brain injury**
Oleg Zaitsev, Russia
- 10.05–10.20 **Severe head injury: looking for solutions... Finding new problems?**
Alberto Delitala, Italy
- 10.20–10.35 **The modern concept of medical rehabilitation in patients after traumatic brain injury**
Gordana Devecerski, Serbia
- 10.35–10.50 **DBS for Cognitive Neuromodulation**
Feridun Acar, Turkey
- 10.50–11.05 **A perforating gunshot injury treated with decompressive craniectomy. A case report**
Aleksandar Caparoski, Macedonia
- 11.05–11.20 **"Extreme" indication of the endoscopic endonasal approach for treatment of complex c2 odontoid fractures**
Maurizio Iacoangeli, Italy
- 11.20–11.35 *Coffee break*

Hall 1

MAIN SESSION

Moderators: Franco Servadei, Jacques De Reuck, Nada Andjelic

- | | |
|-------------|--|
| 11.35–11.47 | Functional Aspects for Complete Decompressive Craniectomy: Microsurgical Neuroanatomy with Respect to Venous Drainage
Peter Winkler, Austria |
| 11.47–11.59 | Treatment of unstable thoracolumbar junction burst fractures: short–segment pedicle fixation with inclusion of the fracture level versus long–segment instrumentation –excluding the fracture level
Maurizio Iacoangeli, Italy |
| 11.59–12.11 | The impact of cerebrospinal fluid shunting on mental recovery in patients with post–traumatic hydrocephalus
Yaroslav Latyshev, Russia |
| 12.11–12.23 | Delayed cerebral vasospasm following traumatic acute subdural hematoma. Case presentation
Kaima Suzuki, Japan |
| 12.23–12.35 | Cerebral venous thrombosis as a rare complication of traumatic brain injury
Dusko Kozic, Serbia |
| 12.35–12.47 | Sciwora or what else?
Rasim Skomorac, Bosnia and Herzegovina |
| 12.47–12.59 | Prognostic factors for mortality in surgically treated patients with moderate to severe traumatic brain injury
Maria Laleva, Bulgaria |
| 12.59–13.11 | New trends in diagnosis management of TBI in children
Alexandru Tascu, Romania |
| 13.11–13.23 | Neuroanatomy of coma due to traumatic axonal injury
Evgenia Alexandrova, Russia |
| 13.23–13.35 | Neurotrauma in sport
Tomislav Madzar, Croatia |
| 13.35–13.45 | <i>Discussion</i> |

Hall 2

SEENS YOUNG NEUROSURGEONS FORUM
ORAL PRESENTATIONS AND FREE TOPICS*Moderators: Tomislav Sajko, Aleksandar Caparoski, Yavor Enceev*

11.35–11.43	Olfactory groove meningiomas (OGM): a multicentric perspective regarding planning, surgical approaches, quality of life and global outcome Alexandru–Vlad Ciurea, Romania
11.43–11.51	Unusual traumatic injury of high cervical spinal cord as a result of degeneration and oscillation Tomaz Velnar, Slovenia
11.51–11.59	Surgical treatment and remarkable outcome after severe trauma brain injury Fahrudin Alic, Bosnia and Herzegovina
11.59–12.07	Neonatal head and spine injuries Zvonimir Dzelebdzic, Serbia
12.07–12.15	Skull fractures in newborn children a 10 year review from a single center Mirjana Raicevic, Serbia
12.15–12.23	Illustrative Case and Literature Review of Bone Resorption after Autologous Bone Cranioplasty Haralampos Gatos, Greece
12.23–12.31	Brain temperature – an undervalued vital parameter of brain tissue hemostasis after brain injury. Can we monitor brain tissue temperature non-invasively in patients? Matthias Menzel, Germany
12.31–12.39	Acute Management of Thoracolumbar Burst Fractures. How we do it. Deyan Handzhiev, Bulgaria
12.39–12.47	The impact of ICP monitoring on the degree of recovery of patients with severe brain trauma Aleksandar Kostic, Serbia
12.47–12.55	Cranio–cerebral injuries caused by captive bolt gun in suicide attempt Vladimir Papic, Serbia
12.55–13.03	The histopathological and biochemical parameters of chronic subdural hematoma Boban Jelenkovic, Serbia
13.03–13.11	Upper extremity peripheral nerve injuries caused by gunshot Vladimir Puzovic, Serbia
13.11–13.19	Susceptibility Weighted Imaging in diagnostics of mild traumatic brain injury Alma Brakus, Serbia
13.19–13.27	Evaluation of the proximal stump in the C5 and C6 lesions Andrija Savic, Serbia
13.27–13.35	Infection after combat related penetrating head injuries Goran Pavlicevic, Serbia
13.35–13.45	<i>Discussion</i>

Hall 1

13.45–14.00

CONTROVERSIES IN NEUROTRAUMATOLOGY NOVI SAD 2016
Final remarks and closing ceremony

14.30–19.00

Trip to Sremski Karlovci – Optional

CONTROVERSIES IN NEUROTRAUMATOLOGY

**October 20th-22nd 2016
Master centar, Novi Sad, Serbia**

ABSTRACT BOOK

Thursday, October 20th

ABSTRACTS

KEY NOTE LECTURES

Hall 1

Novi Sad 2016

One Region, One Neurosurgery

Thursday, October 20th / Hall 1



**Prof. dr Milivoje Kostic
(1883-1974)**

Milivoje Kostic was born in 1883 in Sarajevo. He studied medicine in Vienna, where he graduated in 1906. From 1909 to 1914 he studied surgery at renowned clinics in Hamburg, Paris and Berlin. In Berlin, he stayed with the famous Fedor Krause, and that stay initiated his later interest in neurological surgery.

In March 1921, Milivoje Kostic was elected for associate professor of general surgery. Three years later, Dr. Kostic was elected for professor of general and specialist surgery. After the death of Professor Vojislav Subbotic, since 1924. Milivoje Kostic became head of the Department of surgery and head of the Surgical Clinic, and he stayed at that position until his retirement in 1956.

Milivoje Kostic was a surgeon with dazzling technique and sparkling but rational mind. Almost without any medical infrastructure and with little medical scientific personnel, he managed to follow the development of neurosurgery in Europe. Although primarily general and abdominal surgeon, Milivoje Kostic, from the beginning of his career, was aware of importance of Neurotraumatology and neurosurgery, as well as the necessity to treat them as a separate and specific surgical disciplines

Milivoje Kostic since 1923 practically introduced neurosurgical departments in the Surgical Clinic of the Medical Faculty in Belgrade, and that was much earlier than has been done in other centers of the former Yugoslavia. So with Milivoje Kostic began a planned and systematic development of this surgical discipline. His frequent lectures and presentations of operated cases in the Serbian Medical Society had influence on other medical authorities of the time to convince them in need for the establishment of neurosurgery in our country. On October 31st, 1938 Milivoje Kostic established special Department of Neurosurgery in "The First Surgical Clinic" in Belgrade, the first in Yugoslavia, only three years after the first neurosurgical department was established in Germany, in Wurzburg.



Madjid Samii, M.D., Ph.D.

President of the International Neuroscience Institute (INI) at Otto-von-Guericke-University
 President of China INI
 Chairman (Retired) of Neurosurgical Departments
 Hannover School of Medicine and Klinikum Hannover Nordstadt
 Honorary President of the World Federation of Neurosurgical Societies

Professor Samii is the world renowned neurosurgeon. He was the founding president and founding member of several national and international foundations and societies. During his scientific life, Professor Samii received many honorary professorships, honorary doctorates and visiting professorships from all over the world. Has also given many honorary and memorial lectures. Professor Samii is honorary member of many national academies of medical science and national, international and continental societies of neurosurgery. He has received several prestigious national and international awards, honors and medals. He was also guest of honor in many neurosurgical meetings and had given more than 1000 lectures as special and invited lecturer in international congresses.

Professor Samii is Editor, member of editorial board and honorary editor of many medical journals. He has ever published 17 books in the field of neurosurgery. His scientific works are also published in more than 500 scientific articles.

A major aspect of Professor Samii's scientific career was his devotion to education and enhancement of neurosurgery. From the beginning of his career as the professor of neurosurgery, he put a major emphasis on education of neurosurgeons from all over the world. One of the most important achievements of professor Samii is education of more than a thousand neurosurgeons around the world. Most of these neurosurgeons are in leading positions in their countries. In 2002, his pupils and friends founded an international neurosurgical society under the name of "Madjid Samii Congress of International Neurosurgeons (MASCIN)" which was later changed its name to "Madjid Samii Society of International Neurosurgeons (MASSIN)".

Prof. dr Milivoje Kostic lecture
SERBIAN NEUROSURGICAL SOCIETY TRIBUTE

MANAGEMENT OF TRAUMATIC BRACHIAL PLEXUS INJURY

Madjid Samii
International Neuroscience Institute GmbH
Hannover, Germany

Brachial plexus injuries affect usually young people and lead to devastating socioeconomic and psychologic sequelae. Unfortunately their number has increased in recent decades. Current brachial plexus management aims at improving the usefulness of the affected extremity even after the most severe injuries, such as avulsions of the plexus. The introduction of new surgical techniques allows achieving the goal in increasing numbers.

In the presentation we will present our treatment principles of such injuries. Current brachial plexus treatment relies on precise neurological and neuroradiological evaluation and diagnosis. Once the decision for operative treatment has been taken the paramount questions that have to be answered are when and how to operate. The main steps of our decision-making process, as well as our operative technique and outcome will be shown.



Prof. dr Jean Luc Truelle

Honorary Professor of Neurology
University Hospital of 92380 Garches France

Professor Jean-Luc was born on July 6, 1939 in Paris. He is an Honorary Professor of the Faculty of Medicine of Angers, a former head of the Neurology Department of the Hospital Foch and a neurologist expert at the Court of Appeal of Versailles. He is a member of the French Society Neurology, European Brain Injury Society (past president 1989, 1993) and the Rotary Club Paris (vice president 1997). Jean-Luc received his Doctor of Medicine in Neurology, Paris V University, Paris, 1969.

1989 he founded the European Brain Injury Society; European Research Contract: “Traumatic Brain Injury Evaluation, Epidemiology and Service Delivery”

1996 Creating 32 French Transitional Units for Evaluation, Retraining, and Social-Vocational reentry for Persons with Acquired Brain Injury

He was the President of the Paris International Congress “Traumatic Brain Injury”, the consensus conference «Traumatic Brain Injury: coma to awareness » , Chairman of the QOLIBRI Task Force on TBI quality of life and many others.

He was Vice-President of EMN, EBIS, France Traumatisme Crânien and Consultant to the Neurorehabilitation Dept University Hospital Garches

2014 he founded a university degree on TBI in La Réunion

QUALITY OF LIFE AFTER TRAUMATIC BRAIN INJURY: NEW DEVELOPMENTS

Professor Jean-Luc TRUELLE

Neurorehabilitation Department, University Hospital, Garches, France

Objective: To report new developments of the QOLIBRI, a 37-item disease-specific tool of health-related quality-of-life (HRQoL) after traumatic brain injury (TBI).


Methods: The QOLIBRI was validated in seven languages (Dutch, Finnish, English, French, German, Italian, and Portuguese). In addition, four studies were completed on a 6-item Overall Scale (QOLIBRI-OS), on a comparison with SF-36, with GOSE and ICF, and on a QOLIBRI relative's proxy version

Results: 1. The reliability of the QOLIBRI-OS was good (Cronbach 0.86, test-retest reliability 0.81) and correlates with the total score from the full QOLIBRI scale (r 0.87). Relationships were found among the QOLIBRI-OS and the GOSE, SF-36, and HADS (r 0.54 to -0.76). 2. Shannon H' index informativity was higher and more homogenous for the QOLIBRI as compared to the SF-36 subscales. 3. The QOLIBRI was linked to 42 and the GOSE to 57 two-level ICF categories covering 78% of the categories on the ICF brief core set for TBI. 4. A relative's proxy QOLIBRI version is useful to better discriminate, especially in the low self-aware patients, how actually is their quality of life.

Conclusion: The QOLIBRI enlightens patient's subjective perception of his/her HRQoL which supplements measures of functional outcome. It allows the identification of personal needs, the prioritization of therapeutic goals and the evaluation of individual progress. It may also be useful in clinical trials and in longitudinal studies of TBI recovery. Further versions adapted to child and stroke are in course.

The QOLIBRI-OS can be used as a brief index of HRQoL for TBI. QOLIBRI can be recommended as the preferable instrument, as compared to the generic SF-36. QOLIBRI and GOSE are useful and complementary outcome measures for

TBI, well-linked with the ICF. The QOLIBRI proxy version can evaluate relative's suffering and burden and patient's self-awareness.



Andrew I.R. Maas MD PhD

Andrew I.R. Maas is Professor and Chairman of the department of Neurosurgery at the Antwerp University Hospital and University of Antwerp. He holds positions as Chairman of the Neurotraumatology Committee of the World Federation of Neurosurgical Societies, Chairman of the section on Neurotrauma and Critical Care of the EANS, Co-Chairman of the European Brain Injury Consortium and Past President of the International Neurotrauma Society.

He is a general neurosurgeon with specific interest in Traumatic Brain Injury and neuro-intensive care. His main research interests are:

- Clinical trial design and analysis in Traumatic Brain Injury
- Prognosis in Traumatic Brain Injury
- Individualized Targeted Management in Neurocritical care
- Quality of Life after brain injury
- Standardization of data collection.

Professor Maas was the principal investigator of the IMPACT study group (International Mission on Prognosis and Clinical Trial design in TBI), that was awarded an NIH grant (2003-2011) on the research project: 'Clinical Trial Design and Analysis in Traumatic Brain Injury'. The IMPACT project consisted of a collaborative venture between the Erasmus University Rotterdam, Antwerp University Hospital, the University of Edinburgh and the Medical College of Virginia, Richmond USA. The IMPACT studies have resulted in 50 publications and recommendations for improved trial design, have set the standard for prognostic analysis in TBI and proposed formats for standardization of data collection in TBI studies. Dr Maas has also received funding from the Flemish Institute for Science and Technology for a project concerning Individualized Targeted Management in Neurocritical care (2009-2011). Currently he is Coordinator of the large collaborative project CENTER-TBI: Collaborative European NeuroTrauma Effectiveness Research in TBI, supported by the Framework 7 program of the European Union.

He received an Honorary doctoral degree at the Burdenko Institute of Neurosurgery in Moscow in 2013 and Lifetime Achievement Award for his work on traumatic brain injury from the International Brain Injury Association in 2016.

Dr Maas is member of various editorial boards, review committees and is a reviewer for over 35 international journals. In total he has authored over 200 publications in peer reviewed international journals, most of these focusing on research in Traumatic Brain Injury.

NEW DIRECTIONS IN TBI RESEARCH

Andrew I.R. Maas
 Department of neurosurgery,
 Antwerp University Hospital and University of Antwerp, Belgium

Traumatic Brain Injury (TBI) is a major cause of death and disability, leading to great personal suffering to victim and relatives, as well as to huge direct and indirect costs to society. Strong ethical, medical, social and health economic reasons therefore exist for improving treatment. Despite these strong incentives, the evidence underpinning treatment recommendations is weak. This is not because of a lack of studies. A recent systematic review identified a total of 207 clinical trials conducted on the acute management of TBI¹. However, only 25 of these were considered robust. Most studies have been substantially underpowered. Specific challenges in TBI research relate to the heterogeneity of the disease and the lack of early mechanistic endpoints which can serve as intermediate outcome markers. Conventional approaches to clinical TBI research have been reductionistic, attempting to isolate out one single factor which is treated and by attempting to limit heterogeneity by the use of strict enrolment criteria. These approaches do not reflect the clinical reality of TBI heterogeneity and substantially limit generalizability of results. International collaboration and data sharing are fundamental to achieving these aims. Modern computational techniques facilitate more holistic approaches allowing us to broaden the scope of current reductionistic thinking.

Shifts of research are occurring in two directions: first, towards personalized treatment which would require better characterization of the disease TBI in individual patients, and secondly, towards broader approaches with greater generalizability. A comparative effectiveness research (CER) framework offers opportunities for addressing both directions. This requires high quality contemporaneous data. International collaborations, such as InTBIR (International Initiative for Traumatic Brain Injury Research: <http://intbir.nih.gov>) offer vast opportunities both in terms of concentration of knowledge and in terms of increased numbers. Pivotal studies performed in Europe under the umbrella of InTBIR include CENTER-TBI (www.center-tbi.eu)² and CREACTION (www.creative.marionegri.it). Center-tbi has now recruited over 3000 patients throughout Europe and is well on track to reach the final goal of 5000 patients next year. Results of preliminary explorative analysis, showing quite different population characteristics compared to those of pivotal clinical trials, will be presented. The main strength of studies such as CENTER-tbi, lies in their generalizability and collaborative design based on data sharing. InTBIR is now moving on towards global collaborations, making it truly “more than the sum of its parts”.

1 Bragge Peter, Synnot Anneliese, Maas Andrew I, Menon David K., Cooper D. James, Rosenfeld Jeffrey V., and Gruen Russell L.. *Journal of Neurotrauma*. March 2016, ahead of print. doi:10.1089/neu.2015.4233

2 Maas AI, Menon DK, Steyerberg EW, et al. Collaborative European NeuroTrauma Effectiveness Research in Traumatic Brain Injury (CENTER-TBI): a prospective longitudinal observational study. *Neurosurgery*. 2015 Jan;76(1):67-80. PubMed PMID: 25525693.



Prof. dr Panagiotis Selviaridis

Professor of Neurosurgery at AHEPA University Hospital

Panagiotis Selviaridis was born in Northern Greece. He graduated from the Medical School of the Aristotle University of Thessaloniki with distinction. After finishing his residency programme in the AHEPA University Hospital he presented his PhD thesis on Hydrocephalus in the same University. He trained in minimally invasive techniques-neuroendoscopy in Mainz and Nijmegen (professors Perneczky and Grotenhuis).

He is full Professor of Neurosurgery at AHEPA University Hospital and he received the JRAAC Accreditation for the residency training programme, as program director in 2007.

Main fields of interest and research include neuro-oncology, skull base surgery, minimally invasive techniques, spine surgery and neuroendoscopy. Member and Senior Officer in several Professional Societies: past president – member of executive and scientific committees of the Hellenic Neurosurgical Society, National delegate in the UEMS, National Delegate and member of the liaison committee/training committee/research committee of the EANS, member of the Spine Committee WFNS. He organized 14 international workshops and seminars and was the local organizer of the EANS Research course in 2005 and EANS Training course in 2010. He was local organizer of the EANS Congress of 2016 in Athens.

MANAGEMENT OF CHRONIC SUBDURAL HEMATOMAS

Panagiotis Selviaridis

St Luke's Hospital, Department of Neurosurgery, Thessaloniki, Greece

Introduction: Chronic subdural hematoma is one of the most frequent clinical entities encountered in daily neurosurgical practice. Nevertheless, its proper management remains controversial with numerous techniques applied, ranging from twist drill trepanation, single or double burr hole evacuation, craniostomy or craniotomy combined with simple drainage or irrigation of hematoma, insertion of catheters etc.

Patients-Method: We present our experience with burr-hole evacuation and closed drainage system under local anesthesia. Briefly, an ordinary burr hole is opened over the centre of the hematoma. A catheter is inserted into the cavity and the hematoma is left to drain slowly into the system. Special care is taken to avoid massive drainage and air trapping. Using this method, 91 patients (59 males, 22 females, mean age of 71yrs), have been operated in our department during the last 6 years.

Results: For the 25 among them, who were receiving antiplatelet or anticoagulants, operation was delayed for 5 days, which was feasible in nearly all cases. Trauma preexisted in 75 cases, among which 6 were post-craniotomy for tumour resection and 1 after a VP shunt. Hematoma was unilateral in 71 and bilateral in 10 patients. The mean postoperative hospitalization was 4.64 ± 4.07 days. No statistical significance was found between the coagulation status and the duration of the hospitalization. It is important to highlight, that although the immediate postoperative CT disclosed a remnant in the majority of the patients, this was totally resorbed in the first month follow-up. In 5 patients, reintervention was necessary. Complications included 1 contralateral hematoma, an acute subdural hematoma inside the drained cavity necessitating craniotomy, 1 catheter reinsertion due to malpositioning and 1 conversion to hygroma which eventually led to a subdural-peritoneal shunt.

Conclusion: We believe that the burr-hole evacuation is a safe and effective method for the management of chronic subdural hematomas.

**M. Remzi Sanver**

Professor of Economics, Director of Research at CNRS

Prof. Sanver received a BS degree in Industrial Engineering and a Ph.D. in Economics at Boğaziçi University. Following the completion of his Ph.D. in 1998, Prof. Sanver developed his whole professional career at Istanbul Bilgi University, a young but distinguished higher education institution of Turkey. There, he has been the founding director of the Murat Sertel Center for Advanced Economic Studies which is a center of excellence in mathematical social sciences. He has also served as the rector of University between 2011 and 2015.

Since October 2015, he is a director of research at CNRS, working at LAMSADE, Université Paris Dauphine.

SPECIAL GUEST LECTURE

THOUGHTS ON SOCIAL SCIENCES AND BRAIN STUDIES

M. Remzi Sanver
CNRS, LAMSADE, Université Paris Dauphine, Paris, France

With the development of game theory, the usage of mathematical models in analyzing social systems exhibits a substantial increase, hence leading to a domain that could be broadly entitled as mathematical social sciences. These models need to adopt postulates on human behavior which are subject to empirical testing, which initiated a productive collaboration between brain studies and mathematical social sciences. My talk will make an informal presentation of some major concepts that underlie this collaboration.

Novi Sad 2016

One Region, One Neurosurgery

Thursday, October 20th / Hall 1

Thursday, October 20th

ABSTRACTS

PLENARY SESSION I

Hall 1 / Hall 2

Novi Sad 2016

One Region, One Neurosurgery

Thursday, October 20th / Hall 1

THE ORGANIZATION OF THE EMERGENCY RESPONSE SYSTEM IN ROMANIA

Raed Arafat MD. M. Sc. D. M.

Head of the Department of Emergency Situations
Ministry of Internal Affairs, Secretary of State, Bucharest, Romania

In Romania, the emergency medical system is undergoing continuous development. Since 1990, we started building up a pilot project which became a model for a national system. In 2007, we started implementing the model, copied initially by 7 counties, into a national system backed by a strong legislation on emergency medical care that we developed in 2006. The basis for our concept is integration of prehospital emergency services and emergency care at the level of hospital based emergency departments. The target is to shorten the response time and to bring to the scene, where needed, highly qualified personnel to deal with critical cases. On the other hand we developed a strong first response component based on the fire department to be able to arrive fast and deliver first aid including defibrillation in case of cardiac arrest and fast evacuation if an advanced medical team is not available. In 2014, by governmental decision, we brought all emergency response services under one umbrella at the Department for emergency Situations which became part of the Ministry of Internal Affairs. Under this department we coordinate the Fire Service and Civil Protection, the medical emergency response, the hospital based emergency departments, the air rescue and the mountain rescue. We use a general directorate for emergency medical care under the Department for Emergency Situations to deal with the medical emergencies. During the presentation, we will detail the way we organize our emergency response system.

DECOMPRESSIVE CRANIECTOMY – WHY WE STILL PERFORM IT AFTER THE DECRA TRIAL

IS Florian, C Aldea, C Magan , R Pop

University of Medicine and Pharmacy “Iuliu Hatieganu” Cluj-Napoca, Cluj County Emergency Hospital, Department of Neurosurgery, Cluj, Romania

Evidence of decompressive craniectomy (DC) for severe traumatic brain injury has been discovered dating more than 5000 years, but the actual understanding of the role of DC in order to decrease intracranial pressure and its deleterious consequences is less than one century old. Despite the large number of published studies within the last two decades arguing in favor of DC, the DECRA trial tremendously quaked the neurosurgical community with its conclusion that “early bifrontotemporoparietal decompressive craniectomy decreased intracranial pressure and the length of stay in the ICU but was associated with more unfavorable outcomes”. Since then, much criticisms to this study has aroused in the literature, and many expectations to clarify the unanswered questions are related to the upcoming results of RESCUE-icp trial. In fact, the entire neurotraumatological community is in search for the best therapeutical solution for the severe traumatic brain injured patient. Consequently, we are trying to standardize what is almost impossible to standardize: on one hand, the individual traumatic conditions and individual responses of every single patient to trauma, and the other hand, less discussed, the individual factors related to surgery (surgeon related factors, surgical related lesions, complications of DC, consequent surgical interventions and their complications etc.) and intensive care (invasive monitoring and subsequent complications, long term ventilation related complications, anticoagulation, general infections, consumptions etc.). Despite every standardization and unfavorable prognostic factors, there are, in the experience of every surgeon or intensive care physician, cases that not only survive, but are also doing well. Along with our experience related to DC since 2013, we are presenting a few case reports with almost no chance of survival, according to actual prognostic criteria. These are the cases that demonstrate that we are far from understanding the complex mechanisms of TBI and are obliged to do our best in every single case. What is “the best” remains a mater of debate.

THE AUDITORY MIDBRAIN IMPLANT - A NEW PROTHESIS FOR HEARING RESTAURATION IN NEURONAL DEAFNESS

Amir Samii

International Neuroscience Institute GmbH Hannover, Germany

Many essential functions, such as movement, vision, hearing or sensation, may be impaired due to various diseases and injuries. Neurorestoration with various neural prostheses aims at restoring lost function with leading-edge technologies and new rehabilitation methods. One of the most successful neural prostheses is known as the cochlear implant (CI), which is designed for implantation into the cochlea for electrically stimulating the auditory nerve fibers for hearing restoration. The CI has been remarkably successful in restoring hearing to many deaf individuals and over 320,000 patients have received a CI. The prerequisite for this technique is the existence of a functioning auditory nerve or implantable cochlea. Those patients in whom these structures are damaged (e.g., due to a head injury or tumor removal surgery, or being born without a nerve) need a device that would stimulate more central auditory structures, beyond the auditory nerve.

The first device, known as the Auditory Brainstem Implant (ABI), was implanted as early as 1979 on the surface of the cochlear nucleus in the brainstem (Fig.2). Since then it has been implanted in over 1200 patients worldwide with hearing loss due to Neurofibromatosis Type 2, (NF2), nerve aplasia/avulsion or cochlear ossification. Still, despite the technological progress and development of newer implant types, the degree of hearing restoration with the ABI does not match that achieved after CI implantation, especially in those with NF2 tumors.

A promising alternative to improve outcome is by stimulating within the inferior colliculus (IC). This structure lies in the midbrain at a higher level of the hearing transmission pathway. Unlike the brainstem, the midbrain is directly visible during surgery and is not surrounded by distorted or damaged brain structures caused by an NF2 tumor and/or its removal. During the first AMI clinical trial (5 patients), the safety of the technique was proven. Moreover, very promising results in regards to the hearing restoration have been observed. Optimal results were achieved in the patient, in whom the electrode was positioned along the tonotopic gradient of the nucleus. The next step is to utilize a new electrode concept - the two-shank electrode- and to optimize its positioning in the target nucleus using neuronavigational guidance. The approval for the new clinical trial was given by the authorities in September 2016. Thus the next patients will be operated by the end of 2016.

TRAUMATIC EXTRACRANIAL AND INTRACRANIAL DISSECTIONS. DIAGNOSIS AND THERAPEUTIC MANAGEMENT

Alexandros Andreou

HYGEIA Hospital, Department of Neurosurgery and Interventional Neuroradiology,
Athens, Greece

Arterial dissections is the result of disruption of the internal elastic lamina. Frequently, extra/intra-cranial dissections is the result of head and/or neck trauma. In some occasions, spontaneous dissections may occur.

Dissecting vascular lesions may be the source of either thromboembolic or hemorrhagic cerebral insult, often devastating. Therefore, dissecting lesions should attract meticulous medical attention and treatment. Treatment could be medical (i.e. anticoagulation therapy), or surgical. Conservative treatment is an effective treatment for extracranial dissections, when there is no cerebral perfusion compromise. In case the extracranial dissection reduces the perfusion in the brain, angioplasty and stenting is the treatment of choice.

Intracranial dissections are rare lesions and can be located in both anterior and posterior circulation. They are very fragile lesions and very often rupture, producing subarachnoid hemorrhage. In this case, occlusion of the dissected vessel should be performed to prevent re-bleeding. In most cases, flow replacement is necessary prior to the diseased vessel occlusion. Endovascular selective occlusion of the lesion with preservation of the parent vessel flow is an alternative technique, applied in non-ruptured lesions, although exceptionally can be used in ruptured ones.

Treatment complications are associated to blood flow compromise, related to the occlusion of small vessels (perforators), arising from the dissected segment.

In conclusion, extra- or intra-cranial dissecting lesions, although rare, are threatening lesions and may be associated to severe cerebral ischemia or hemorrhage and they should be treated as soon as possible after diagnosis.

MICROSURGICAL ANATOMY OF THE THORACIC SPINE: THE FUNDAMENTALS OF THE THORACIC SPINAL STABILITY

Kenan Arnautovic MD, PhD, FAANS, FACS
Professor of Neurosurgery
Semmes-Murphey Clinic and Department of Neurosurgery
University of Tennessee
Memphis, TN, USA

Biomechanical spinal stability has been defined as the ability of spine to resist damaging mechanical forces. Consequentially, the cervical spine has been the most vulnerable part of the spine to traumatic injury. This is due to its mobility and the fact that it is carrying the weight of the head. The lumbar spine is the second most commonly injured portion of the spine. On the contrary, the thoracic spine possesses significant stability despite the fact that it involves longest amount of spinal vertebrae. We have analyzed the anatomy of the thoracic spine in order to understand better the elements of its stability.

Thoracic vertebrae are mutually connected with intervertebral disks and anterior and posterior longitudinal ligaments. In addition, there are 2 articular facet joints connecting posteriorly. Finally, there are yellow, interspinous, and supraspinal ligaments re-enforcing the posterior spinal column. There is also an intricate network of ligamentous connections that re-enforces the rib/vertebral articulations. Numerous bone, ligamentous, blood vessel and neural anatomic features are included as well.

The complex anatomy of the thoracic spine enforces the biomechanical stability of this spinal segment. Knowledge of spinal anatomy is important for proper surgical preoperative decisions, such as the indications for treatment, types of operative approaches, and overall understanding of the mechanisms implicated in traumatic spinal involvement.

PARADIGM SHIFT IN TRAUMATIC BRAIN INJURY: DOES “MINIMAL” REQUIRE MAXIMAL ATTENTION?

András Büki^{1,2,3}, Noémi Kovács¹, Krisztina Amrein^{1,2}, Péter Tóth¹, Viktória Tamás¹,
Endre Czeiter^{1,2,3}

1) Department of Neurosurgery,

2) János Szentágothai Research Centre,

3) MTA-PTE Clinical Neuroscience MR Research Group; University of Pécs; Pécs, Hungary

Traumatic brain injury (TBI) is a major challenge in health care – the third most frequent cause of death worldwide. In Europe, 2.5 million people suffer a TBI each year, of whom 1 million are admitted to hospital and 75,000 die. It is also proven that TBI hits societies even decades after brain injury with consequences like posttraumatic epilepsy, hypopituitarism and early cognitive decline. Contemporary scope of TBI research has been substantially altered by recent data from the TRACK-TBI study and other reports leading to the recognition that our appreciation of mild brain injury (mTBI) might be wrong and even a single episode of CT-negative mTBI may lead to structural damage in the brain demonstrated by routine MRI and such injury may result in long term functional consequences. Furthermore morphometric and functional MRI could identify subtle alterations in victims of mTBI despite of negative CT and routine MRI exams. While a recent systematic review indicates that premorbid mental health is the most important determinant of outcome after mild brain injury the “jury is still out” on how those patients who are at risk after mTBI should be identified and what measures should be employed in their case.

In this presentation we particularly would like to draw attention to repeated/sport related mTBI that could lead to long term endocrine deficit as well as neuro-cognitive decline. While further hard evidence should necessarily be presented the available data more and more clearly associate such injuries with tau- pathology and chronic traumatic encephalopathy.

Hungarian Brain Research Program - Grant No. KTIA_13_NAP-A-II/8. supported this work.

THE NOSTRA TRIAL IN SEVERE TBI

Andreas W. Unterberg

Department of Neurosurgery, University of Heidelberg, Germany

Within the last decades, little progress has been made in the treatment of severe traumatic brain injury (TBI). Still, there is no neuroprotective agent that might improve the outcome of TBI patients, although several compounds have been tested clinically. The reasoning for a role of nitric oxide in the pathophysiology after TBI is ambiguous. Nevertheless there is experimental evidence that NO-synthase inhibitors may have neuroprotective beneficial effects. A strong inhibitor of NO-synthase is VAS203, a biopterin. After controlled cortical impact, administration of VAS203 leads to a sustained decrease of intracranial pressure. Moreover, VAS203 was capable to diminish posttraumatic brain edema under experimental conditions. As a next step, VAS203 has been tested in TBI patients in a tolerability and safety study. Apart from moderate renal side effects in higher concentrations, the tolerability was good. Furthermore, ICP was decreased in treated patients and the therapy intensity level (TIL) trended to be lower. Meanwhile, a phase III-trial with VAS203 has been initiated (NOSTRA). In October of this year, the first patient will recruited. The NOSTRA trial will be the only prospective randomized controlled trial with a neuroprotective substance following TBI in Europe. It is planned to recruit patients in 35 European centers. 220 patients shall be randomized in a 1:1 ratio. The extended Glasgow Outcome Score at 6 months after TBI is the primary efficacy parameter. Quality of life, ICP/CPP and microdialysis data are representing secondary and tertiary efficacy parameters. The trial is expected to include patients for 2-3 years.

Novi Sad 2016

One Region, One Neurosurgery

Thursday, October 20th / Hall 1

Thursday, October 20th

ABSTRACTS

PLENARY SESSION 2

Hall 1

HOW MUCH DECOMPRESSION, AND HOW FAST, SHOULD BE DONE IN CERVICAL SPINE FRACTURE WITH NEUROLOGIC DEFICIT

Ulrich Kunz, René Mathieu, Simon Mayer
Neurosurgical Department, Bundeswehr Hospital Ulm, Ulm, Germany

Object: In head trauma it is common use to decompress if there is a severe brain injury and an edema is expected.

The aim of our study was to compare the neurological outcome after a ventral discectomy and an anterior cervical corpectomy in patients with severe spinal cord trauma.

Methods: From September 2009 to May 2016 we performed a decompression of the cervical spine via corpectomy in 12 patients and via ventral discectomy in 8 patients with a severe cervical spine trauma and initial neurological deficit. A pre- and postoperative MRI was performed to show a sufficient decompression of the injured spinal cord and the change of the edema. We also measured the size of the decompression and combined this data with the follow-up data of the neurological function from our patient records.

Results: No Patient had a worsening of the neurological deficit due to the surgery, independently from the surgical technique used. In 34 % (4 patients) a corpectomy led to an improvement of the initial deficit. 66 % (8 patients) had no neurological benefit from the corpectomy. In the group of the patients who underwent a ventral discectomy 50 % (4 patients) had a better neurological function after the surgery. Due to our data, time from trauma to the surgery (ranging from 3 to 120 hours) had no significant influence to the outcome. Beside an initial complete tetraparesis the preoperative size of the edema was the only adverse prognostic factor. We could not find a clear correlation between the size of the decompression and the increase of the edema.

Conclusion: The spinal decompression in trauma patients with initial neurological deficit is a safe procedure. According to our experience the chance for an improvement in patients with an incomplete neurological deficit is good and no patient had a worsening of the initial deficit.

We could not find a difference in the increase of the edema and the neurological outcome between a corpectomy and a ventral discectomy. Also the time from trauma to the surgery made no difference. From our experience we suggest to perform the surgery as soon as possible within the first 24 hours. The technique should be adapted to the skills of the surgeon and the conditions of the fracture. Furthermore we have some hints that a corpectomy is indicated when the edema is larger than 17mm.

EPIDEMIOLOGY AND PREVENTION OF TBI IN EUROPE: NEW FACTS

Wolf-Ingo Steudel

Universität des Saarlandes, Department of Neurosurgery, Homburg, Germany

Introduction: The purpose of epidemiology is disease control and prevention. In addition epidemiological data offer a tool of quality control and support the comparison between different conditions and health systems. There exist a large variety of data mostly drawn from local and regional studies in Europe and rarely from nationwide registers.

Methods: The sources of data are the OECD Health Statistics and the EUROSTAT Statistics database. The data in Germany are provided by the Federal Bureau of Statistics (DESTATIS). These data of hospitalized patients and fatal cases were correlated with population data to calculate incidences and mortality rates since 1972.

Results: There is a marked change concerning the most dangerous conditions causing TBI in Europe and in some countries worldwide. There has been an essential decrease of severe traffic accidents in most European countries over the last decades probably due to the increase of age of the population. But there is an increase of severe and fatal injuries at home mostly caused by falls of any kind. The mortality rate as well as the increasing age of the population is highest among those who are older than 75, whereas most of all neurosurgical procedures have to be done in patients between 70 and 75.

Conclusions: An analysis of the data reveals surprising views of incidence, morbidity and mortality rates of TBI in Europe. Both adequate laws and sophisticated technical standards in vehicles have surely been a good way to avoid severe traffic accidents. Less severe TBI caused by traffic accidents occur to the increasing age of the population. Whereas it is the aging population who is involved in the increasing number of domestic accidents. Trying to reduce this kind of accidents too, will be our great challenge for the future.

THE INFLUENCE OF POST TRAUMATIC HYPOPITUITARISM ON RECOVERY AFTER TRAUMATIC BRAIN INJURY

Krešimir Rotim, Darko Stipić

UHC Sisters of Charity, Neurosurgery Department, Zagreb, Croatia

Objective: To report the rate of hormon deficiencies after moderate traumatic brain injury (TBI).

Introduction: Post-traumatic hypopituitarism (PTHP) after TBI was recognized more than 90 years ago, but it was considered rare. Today, clinical evidence demonstrates that TBI may frequently cause hypothalamic-pituitary dysfunction contributing to a hampered recovery. PTHP entails physical, psychological, and social changes, and it has significant implications for recovery after TBI. PTHP may be observed during the acute phase of recovery or in later stages, anytime after the TBI. In early stages of recovery, clinically most important are hypocorticism and antidiuretic hormone (ADH) abnormalities. In the late stage, the most common chronic hormone deficiencies are somatotropin and gonadotropin deficits.

Methods: Endocrinological testing was performed on 20 patients, 2 days after admittance for moderate TBI. The serum levels of T3, T4, TSH, ACTH, GH, IGF-1, PRL, LH, FSH, testosterone and cortisol in 24-hour urine was measured. The presence of ADH abnormalities were evaluated according to urine specific weight and volume, and electrolyte values.

Results: Hypocorticism was detected in 6 patients (30%), diabetes insipidus in 4 (20%) and syndrome of inappropriate ADH secretion in 1 patient (5%). Hypotireoidism was present in 1 patient (5%), gonadotropin deficiency in 10(50%), GH deficit in 1(5%) and hiperprolactinemia in 4 patients (20%).

Conclusion: In the early stages after TBI it is of outmost importance to detect and treat hypocorticism and ADH abnormalities since they can pose a life threat. In order to improve outcome and quality of life after TBI, an adequate replacement therapy is crucial. Our data is similar to what is reported in the literature.

Key words: traumatic brain injury, posttraumatic hypopituitarism, neuroendocrine dysfunction, hormone deficiency

CONTROVERSIES IN NERVE TRANSFERS FOR UPPER BRACHIAL PLEXUS PALSY DUE TO TRACTION INJURIES

Lukas Rasulic

School of Medicine, University of Belgrade, Belgrade, Serbia
Clinic of Neurosurgery, Clinical Center of Serbia, Belgrade, Serbia

Background: In the past, nerve transfers were the treatment of choice in cases with spinal nerve root avulsion, or those with directly irreparable proximal lesions and very proximal or injuries without a nerve available for grafting. Recently, indications for nerve transfers have been extended to high level nerve injuries with extensive gap for grafting and delayed nerve repairs, significant bony or vascular injuries in the region of direct repair and previously failed proximal nerve repair. The main advantage of this procedure over nerve grafting is a conversion of proximal high-level injury to a low-level one.

Nerve transfers in cases of directly irreparable, or high level extensive brachial plexus traction injuries are performed using a variety of donor nerves with various success but an ideal method has not been established.

Methods: The purpose of this study was to analyze the results of nerve transfers in patients with traction injuries to the brachial plexus using the thoracodorsal and medial pectoral nerves as donors. Most frequently used nerve transfer modalities for upper brachial plexus palsy due to traction injuries were evaluated. This study included 40 patients with 25 procedures using the thoracodorsal nerve and 33 procedures using the medial pectoral nerve as donors for reinnervation of the musculocutaneous or axillary nerve.

Results: The total rate of recovery for elbow flexion was 94.1%, for shoulder abduction 89.3%, and for shoulder external rotation 64.3%. The corresponding rates of recovery using the thoracodorsal nerve were 100%, 93.7% and 68.7%, respectively. The rates of recovery with medial pectoral nerve transfers were 90.5%, 83.3% and 58.3% respectively.

Conclusion: Although there are multiple controversies in nerve transfer for upper brachial plexus palsy due to traction injuries, Oberlin procedure is currently the first choice in nerve transfer, where it is possible, in cases with upper brachial plexus palsy due to the traction injuries. According to findings in this series, nerve transfers using collateral branches of the brachial plexus in cases with upper palsy offer several advantages and yield high rate and good quality of recovery.

DECOMPRESSIVE CRANIECTOMY: A LIFE SAVER? MYTHS & FACTS

Kostas N. Fountas, MD, PhD, Haralampos Gatos, MD

Department of Neurosurgery, School of Medicine, University of Thessaly, Larisa, Greece

Learning Objective: The participant will be exposed to the controversies of employing Decompressive Craniectomy (DC) for managing patients with severe Closed Head Injuries. Moreover, the results, the conclusions, and the weaknesses of the two published Randomized Controlled Trials regarding DC will be presented and discussed.

ABSTRACT

Background: The management of patients with medically intractable intracranial hypertension secondary to severe closed head injuries (CHI) remains challenging, despite all recent advances in neuromonitoring and intensive care therapeutic strategies. Decompressive craniectomy (DC) has been considered a second-tier treatment for managing patients with uncontrollable intracranial pressure after CHI. However, its efficacy and the overall outcome of patients undergoing DC remain highly controversial. The current presentation aims at the critical review of the pertinent literature, as well as at the delineation of those crucial factors, which may affect the efficacy of DC in the management of CHI.

Material & Methods: A systematic search of the PubMed, Embase, and the Cochrane Central Register of Controlled Trials databanks was performed. The key words and heading terms “brain edema”, “brain injury”, “craniectomy”, “decompressive”, “head injury”, “intracranial hypertension”, and “traumatic” were used in any possible combination. The search was limited to the period from 1995 to present, and only articles fully published in English were included. Furthermore, the references of the retrieved articles were thoroughly reviewed for any additional pertinent articles.

Results: A total of 247 articles matching our search criteria were retrieved, and were reviewed. Two randomized controlled trials (RCT) were identified among the retrieved articles. One of them (DECRA study) failed to demonstrate a significant advantage for DC to reduce an unfavorable outcome in adults suffering severe CHI. The other RCT (RESCUE-ICP study) demonstrated that DC may reduce morbidity in adult patients with sCHI, however increases the associated morbidity among the survivors. Despite the publication of these RCTs, several issues regarding the surgical technique, the optimal time of performing DC, the most efficacious surgical technique, and the optimal time for the DC-associated reconstructive cranioplasty remain controversial.

Conclusions: The clinical efficacy of DC in managing patients with medically refractory intracranial hypertension secondary to severe CHI remains ill defined. The pavement of a totally new way to approach patients with CHI may be necessary for improving these patients overall outcome.

Thursday, October 20th

ABSTRACTS

MAIN SESSION 1

Hall 1

LOBAR HAEMATOMAS: NEUROPATHOLOGICAL AND 7.0-TESLA MAGNETIC RESONANCE IMAGING EVALUATION

Jacques De Reuck, Charlotte Cordonier, Vincent Deramecourt, Florent Auger, Nicolas Durieux, Didier Leys, Florence Pasquier, Claude-Alain Maurage, Regis Bordet
Université Lille 2, INSERM 1171, Lille, France

Background: Lobar haematomas (LHs) are frequently associated to cerebral amyloid angiopathy (CAA). In “vivo” MRI studies show that in CAALHs are frequently associated to cortical microbleeds and both predominate in the posterior part of the cerebral hemispheres. These MRI findings are used as the Boston criteria for CAA. However, a neuropathological examination is still needed for a definite diagnosis.

Purpose of the study: To validate the Boston criteria for CAA in post-mortem brains with LHs and to evaluate the age-related changes on T2 and T2* MRI.

Patients and methods: 17 post-mortem brains with LHs due to CAA are compared to 13 non-CAA ones. The location and the recurrence rate of the LHs are determined. Also a semi-quantitative evaluation of the associated cerebrovascular lesions is performed. In fifteen brains the age-related image changes in the LHs are evaluated on T2 and T2*-weighted 7.0-tesla MRI.

Results: Recurrent haematomas are found in 24% of the CAA brains compared to 8% in the non-CAA ones ($p = 0.05$). LHs in the parieto-occipital region are observed in 60% of the former compared to 7% in the latter group ($p = 0.002$). White matter changes are more severe, and cortical microbleeds and microinfarcts more frequent in the CAA brains ($p < 0.05$). The T2 and T2* MRI sequences show during the hyperacute stage an intense homogenous hyperintensity in the haematoma core. With time a progressive resolution of the hyperintensity in the core occurs with a progressive increase in the haematoma borders. Superficial siderosis and collapse of the haematoma appear in the latest stages.

Discussion: This post-mortem study validates the Boston criteria for CAA. The high recurrence rate of LHs could be added as a new criterion. MRI allows dating of the age of the LHs.

THE MANAGEMENT OF CRANIOCEREBRAL TRAUMA

Fatos Olldashi

University Hospital of Trauma, Tirana, Albania

In this presentation we give our experience in the management of craniocerebral trauma. Our clinic is known as the only one in the country specializing for the treatment of traumatic brain and spinal injuries. The number of patients treated per year is 1200, while the number of patients consulting in the emergency is around 10000 per year.

International algorithms and protocols are used in all the craniocerebral trauma patients. However, we have to adapt those protocols in our conditions. The specifics of our country are: We have only one neurotraumatologic center for the whole country. The neurosurgical service lacks the level of consultancy in all regional hospitals. Most of the regional hospitals have the possibility for examinations like CT-Scan, but they do not have neuroradiologist available. We present the use of telemedicine network as part of neurotrauma management. Monitoring of ICP and posttraumatic cerebral edema is not available. Therefore, we do CT scan examination to monitor cerebral edema.

ABNORMAL COGNITIVE AGING

Jose Leon-Carrion

University of Seville, Experimental Psychology, Seville, Spain

Executive functions are highly sensitive to the effects of aging and other conditions affecting frontal lobe function. Executive deficits pose significant functional disability in both aging and brain damaged populations. As humans age, the brain undergoes the accumulative effects of biological wear and tear. Although neuroplasticity allows the brain to change throughout life, a breakdown in brain plasticity may be a key pathological event of Alzheimer's or neurovascular disease. Alzheimer's disease (AD) is a progressive, multifactorial, degenerative form of dementia. Normally, the first stage shows amyloid plaques on the brain while the second, or prodromal stage, reflects cognitive alterations seen in mild cognitive impairment (MCI). The final stage is characterized by functional impairment resulting in dementia, with no known pharmacological treatment. Between five to ten percent of people 65 and older show signs of dementia, as do approximately fifty percent of those over 85. For highly accomplished individuals, the first sign of cognitive deterioration is the need for more time and effort to carry out a task. Dementia diagnosis is based on: 1) a history of persistent and progressive decline; 2) cognitive scores that fall beyond 2 SD's from age and education-matched ranges; 3) changes in scores that exceed 1 SD within a 6-12 month period; 4) scores below 36 in the Mini-mental State Exam; 5) patients retesting in 12-18 months. Our studies and experience show that older adults significantly improved on both examiner-rated performance analogues of real life tasks and on self-rated executive functioning after specific cognitive rehabilitation designed to increase real life goal attainment. The success of this complex rehabilitation presents possibilities for therapeutic intervention in aging populations.

DECOMPRESSIVE VS HINGE CRANIECTOMY: DIFFERENCES IN TECHNIQUE AND OUTCOME

Ibrahim Omerhodzic

Clinical Center University of Sarajevo, Department of neurosurgery,
Sarajevo, Bosnia and Herzegovina

Decompressive craniectomy (DC) is still wide accepted a life-saving procedure for the surgical treatment of intractable intracranial hypertension in cases in which medical management fails. In the recent years we know more about the functional outcomes of those patients on long-term follow-up. In centers where craniectomy has not gained acceptance, there is a notion that DC procedure is too aggressive and results are not so satisfactory. Even some neurosurgeons conclude that DC rendering the procedure futile and wasteful. But otherwise, the assumption that most patients remain in a vegetative state after this intervention is not confirmed yet.

In this meaning, we tried to find less aggressive technique with comparable result, to avoid hemicraniectomy and complication connected with it. During the last seven years we utilized more conservative and less invasive surgical option so called Hinge craniotomy (HC) which means to decompress only most dangerous area of compromised brain, usually brain stem.

We found that HC is sufficient technique for the treatment of patients with high ICP suffering TBI and massive MCA insult in thoughtfully selected group of patients. In this article we present surgical technique and difference in outcome between DC and HC, based on series with more than 70 cases.

**MONITORING OF POSTTRAUMATIC CEREBRAL HEMODYNAMIC BY
TRANSCRANIAL DOPPLER SONOGRAPHY – A NOVEL PERSPECTIVES**

Splavski B, Kovačević M, Mužević D.

Department of Neurosurgery, Osijek University School of Medicine,
Clinical Hospital Center, Osijek, Croatia

Intracranial hypertension and secondary brain tissue ischemia are the decisive consequences of a severe brain injury. The ischemic profile of posttraumatic cerebral contusions presents the potential risk of secondary insults due to enlargement of perifocal astrocytic swelling, what may explain further deterioration usually seen in patients suffering such an injury. The decrease of cerebral perfusion pressure (CPP) is responsible for early decline in cerebral blood flow velocity, having an effect on the management outcome. Following a severe brain injury, it is possible to record stereotypic patterns of posttraumatic cerebral hemodynamic disturbances by using a bedside, portable transcranial Doppler (TCD) sonography. The method can be employed for measuring the middle cerebral artery (MCA) blood flow velocity and for estimating the pulsatility index (PI), as well as to enable the measurements comparison in different groups of surgically treated patients. It may also allow anticipation of potential benefits of decompressive surgery in recovering cerebral circulation and influencing the outcome of patients suffering a severe brain injury.

In conclusion, a disorder of early posttraumatic cerebral circulation, created soon after a severe brain injury, is transmitted into slower velocity and higher pulsatility, what could be measured by TCD, providing precious information for evaluating responses to early decompressive surgery and influencing the functional management outcome. The clinical employment of this non-invasive and undemanding procedure on a daily basis might improve management protocol and patient care system, and could be well engaged in the every day monitoring of traumatic brain injury.

RADIOLOGICAL APPROACH TO NEUROTRAUMATOLOGY

Sanja Stojanovic

Clinical Center of Vojvodina, Center for Radiology, Novi Sad, Serbia

Introduction: In head trauma imaging is the cornerstone in decision making process. Pathological changes seen on different imaging modalities are of crucial significance for determining patients place in therapeutic algorithm.

Teaching points: Computerized tomography (CT) with short acquisition time, good depiction of brain parenchyma, intracranial blood and skull fractures is advanced imaging initial method of choice for head trauma. Blood is immediately after its coagulation being recognized as hyperdense formation whether it is extra- or intraaxial by location. Skull fractures can be recognized on multiplanar and volume rendered reconstructions, and when direct signs of fracture without dislocation are not recognizable suspicion can be made by imaging appearance of surrounding structures (blood/liquid in paranasal sinuses or mastoid cells etc).

Magnetic resonance imaging (MRI) is advanced imaging method for further evaluation of traumatic changes of endocranium. More sensitive demarcation of several pathologic phenomena can be obtained on MRI: 1. hemorrhagic contusions of the brain on susceptibility weighted imaging and T2* sequences, 2. axonal damage on diffusion tensor imaging, 3. traumatic subarachnoid hemorrhage and brain edema on fluid attenuated inversion recovery sequence etc.

Further analysis of imaging modalities and appearance of pathologic changes will be discussed.

Conclusion: Knowledge of physical principles behind these imaging methods is essential for proper evaluation of images. Interpreted in such manner macro- and sometimes microscopic level of detection of pathological changes can be obtained.

THE CLINICAL AND NEUROPSYCHOLOGICAL EVALUATION OF THE BRAIN INJURED PROFESSIONAL (NFL) ATHLETE

Esposito D***, Katz H**, Esposito II D, Iacoangeli M*

* Department of Neurosurgery, Università Politecnica delle Marche,
Umberto I General Hospital, Ancona, Italy

**Gulf States Physical Medicine and Rehabilitation, Jackson, USA

The National Football League (NFL) has accepted the relationship between repetitive traumatic head impacts and the subsequent development of neurological impairment. The NFL concussion settlement accepts that participation in football on a professional level provides sufficient proof of causation if a player subsequently develops symptoms of Chronic Traumatic Encephalopathy (CTE). In addition, a recent pathologic analysis of the brains of 94 former NFL players, 90 tested positive for CTE.

The role of the brain injury specialist has changed in this subset of patients. Often, one of the principle elements in the assessment of the post TBI patient is establishing the causal relationship between the traumatic injury/injuries, and the subsequent clinical picture. This is primarily important in cases where medical and legal implications of the injury/injuries may result in financial compensation to the patient and/or the family for medical expenses and other forms of compensation.

This presentation will concentrate on the clinical evaluation of 50 former NFL patients with suspected CTE. We will outline our referral patterns, examination techniques, reporting vehicles and possible implications of our evaluations. All players had detailed general medical, concussion and subconcussive event, and sports medicine histories. All patients had detailed neurological examinations including mini-mental status exams and clinical dementia rating scores. In addition, each patient underwent an extensive (approximately 4 hour) session of neuropsychological testing.

The authors' methods, results, and recommendations for future considerations in this patient population will be discussed. Graphic analysis of pertinent historical events, deficits found on neurological examination, clinical mental status testing and detailed neuropsychological scores will be presented.

Thursday, October 20th

ABSTRACTS

**ORAL PRESENTATIONS AND
FREE TOPICS**

Hall 1

WHAT IS THE EXACT TIME INTERVAL TO PERFORM THE DECOMPRESSIVE CRANIECTOMY IN TRAUMATIC BRAIN INJURY?

Matjaz Vorsic¹, Tomaz Velnar¹, Gorazd Bunc¹, Janez Ravnik¹, Tadej Strojnik¹

1) University Medical Centre Maribor, Department of Neurosurgery, Maribor, Slovenia

Objectives: In 10% to 15% of patients after severe traumatic brain injury (STBI) the intracranial pressure (ICP) rises significantly and does not react to the medical treatment. Patients with ICP higher than 20 mm Hg not responding to intensive care treatments show higher morbidity and mortality. The decompressive craniectomy (DC) may be employed in these cases lowering the elevated ICP. The aim of the study was to analyze our results with DC in the treatment of STBI with special emphasis on the precise timing for performing the DC.

Methods: The retrospective study was conducted and patients with STBI were included - Glasgow Coma Scale (GCS) from 3 to 8, in whom DC was performed due to an elevated ICP, not responsive to any other intensive care treatments. Treatment outcome was rated by Glasgow Outcome Scale Extended (GOSE) score during follow-up. The time from injury to DC was investigated and GOSE was compared to the initial GCS and patients age.

RESULTS:

From 2012 to 2015, 178 patients with STBI were treated. DC was employed in 64 patients. Of all the patients with DC, 39% of them died, 14% remained in persistent vegetative state and 9% severely disabled. A favorable treatment outcome was achieved in 37.5 % (average GOSE 6.5) and poor treatment outcome in 62.5 % (average GOSE 1.4). Patients treated by DC later than 24 hours after injury, those with GCS rated from 6 to 8 and those younger than 50 years, had a better treatment outcome. Patients with DC performed 24h after the injury had worse outcome (GOSE Score 2,2) than those with late DC: on average 6 days after the injury (GOSE Score 4).

CONCLUSIONS:

DC effectively reduces the rise in ICP following a STBI. To date, no prospective, randomized and controlled studies relating to DC in severe brain injuries were performed. Using GOSE, a successful outcome was observed in 36% and a poor outcome in 64%. Patients with lower neurological dysfunction and patients younger than 50 years benefit the most from the procedure. In our study the DC performed in acute stage resulted in poorer outcome then DC performed in the late stage of the STBI.

COMPUTERIZED STATIC POSTUROGRAPHY AND VESTIBULAR DYSFUNCTION IN ACUTE PERIOD OF CONCUSSION

Andreev A., Skobska O., Kadzhaya N.
Institute of neurosurgery named after academic A. Romodanov
Ukrainian Academy of Medical Science, Kiev, Ukraine

Introduction: It is well known that concussion (C) affect balance; for this reason, tasks involving balance and coordination are commonly used to determine neurological function in concussion. A major limitation of most balance measuring methods and instruments, commonly used in clinical and research applications, is the fact that they cannot detect small changes in a person's postural control such as those caused by minor impacts. Computerized Static Posturography (CSP) instruments could overcome these limitations.

Materials and methods: This retrospective analysis included 32 patients (age = $34,1 \pm 1,3$ years: 22 males, 10 females) with C. A standardized clinical protocol for the examination was used. Postural control function was assessed with "Stabiloanalyzer 01-03" ("Rhythm" RF), using open and closed eye Romberg test, in terms from immediately after the event to 10 days after brain injury. For the control group 15 healthy persons were used.

Results: $14.4 \pm 0,4$ mean Glasgow coma scale was during hospitalization. 90.6% of patients reported the presence of headaches and general weakness, 59.3% - noise and light sensitivity, 37.5% - double vision, 46.8% - dizziness. 28 (87.5%) patients showed errors in Finger-to-nose task and instability in Romberg test. Almost at 78.1% of inspected patients, a spontaneous nystagmus during first days after trauma was exposed and also his complete disappearance by 7-10 day after a trauma was marked. All patients showed specific stabilometric changes and among them the extension of surface of the ellipse area to $235,3 \pm 13,7$ mm² was marked as the most prominent. The fluctuations of pressure center were more significant in the sagittal plane.

Conclusions: CSP is extremely sensitive and accurate method to detect even minute changes in balance that might provide an early indication of changes in a person's body before these become evident and difficult to reverse. The use of CSP in patients with C opens new opportunities for evaluation of vestibular dysfunction.

Key words: concussion, vestibular disorders, Computerized Static Posturography

THE EFFECT OF EARLY AND POSTPONED DECOMPRESSIVE CRANIECTOMY ON TIME SPENT IN ICU AND OUTCOME IN TRAUMATIC BRAIN INJURY PATIENTS

Djula Djilvesi^{1,2}, Petar Vulekovic^{1,2}, Tomislav Cigic^{1,2}, Vladimir Papic^{1,2}, Nenad Krajinovic¹, Igor Horvat^{1,2}, Mladen Karan^{1,2}, Bojan Jelaca^{1,2}, Antun Azasevac¹, Jagos Golubovic^{1,2}

1) Clinical Centre of Vojvodina, Clinic for Neurosurgery, Novi Sad, Serbia

2) University of Novi Sad, Medical Faculty, Novi Sad, Serbia

Introduction: In terms of controlling raised ICP after traumatic brain injury, decompressive craniectomy is performed world-wide, but there is no consensus on if and when to proceed with the surgery or will there be improvement of outcome after surgery has been performed.

Objectives: To assess the effect of decompressive craniectomy performed within or after the first 36 hours post trauma on time spent in ICU and outcome.

Methods and Materials: Retrospective study was conducted involving 50 patients treated in Clinical Centre of Vojvodina from 1st August 2010 to 31th July 2015. Patients were divided into groups depending on the time of their surgery performance. First group underwent decompressive craniectomy in the first 36 hours and the other treated after 36 hours.

Results: 73% patients were male and 27% female. 49% patients were sent from other hospitals to Clinical Centre of Vojvodina. Patients sustained trauma after car or motorcycle accident (22%), bicycle accident (11%), pedestrian accident (5%), fall accident (29%), fall from the height (22%). Median Glasgow Coma Scale was 6 on admission. 86% of patients underwent surgery in the first 36 hours, and 14% after 36 hours. There was no significant statistical difference (T-test) in the time spent in ICU (7,6 and 7,9 days respectively) or difference in the outcome between two groups. Patients who had craniectomy in the first 36 hours had 56% mortality, 15% were in vegetative state, 15% had severe disability and 11% mild disability on Glasgow Outcome Score on discharge. Good recovery had 3% of patients. There was 33% mortality in the group of patients treated after 36 hours, 33% had severe disability, 17% vegetative state and 17% mild disability. There were no patients with good recovery in this group.

Conclusion: Time of decompressive craniectomy performance has no effect on time spent in ICU or outcome.

DECOMPRESSIVE CRANIECTOMY IN THE TREATMENT OF COMPLEX SEVERE TRAUMATIC BRAIN INJURY

Božić B., Rotim K., Šumonja I.
UHC Sisters of mercy, Zagreb, Croatia

Aim: Authors present 4 interesting cases of severe traumatic brain injuries (TBI) treated by decompressive craniectomy in our emergency service and give a short review of literature on decompressive craniectomy.

Introduction: In modern medical era, decompressive craniectomy (DC) has been used since Bergmann first described the technique in 1880. DC can be performed in combination with evacuation of extra-axial collection, removal of intraparenchymal haematoma, diffuse brain oedema, following the debridement of penetrating wounds and evacuation of foreign body, removal of necrotic brain parenchyma or open impressive fractures. It was proven that time in which ICP is over 20 mm Hg correlates directly with the outcome of the patients and that early decompression (within 4 hours from the injury) results in improved functional outcome within 6 months.

Patients and methods: We present 4 cases with complex severe TBI admitted through our emergency service.

Results: Three out of four patients significantly improved after the surgery and were discharged from hospital for further rehabilitation.

Conclusion: In the period of 2011-2014. in UHC Sisters of mercy Zagreb, 154 decompressive craniectomies have been performed in patients with severe TBI. We present some of our interesting cases and their postoperative outcomes.

EXOGENOUS AND ENDOGENOUS FACTORS THAT MODULATE OPPORTUNITIES FOR REEMPLOYMENT OF PERSONS LIVING WITH SEQUELS FOLLOWING SPINAL CORD INJURY

Aurelian Anghelescu^{1,2}, Lucia Ana-Maria Anghelescu³, Magdoiu Anca Magdalena⁴

- 1) Teaching Emergency Hospital “Bagdasar-Arseni”, Bucharest, Romania
- 2) University of Medicine and Pharmacy “Carol Davila” Bucharest, Romania
- 3) Anthropology department, of the Sociology and Social Work University of Bucharest
- 4) CMI Magdoiu Anca Magdalena, Bucharest, Romania

Background: Spinal Cord Injury (SCI) is a major life event, medically complex life-disrupting condition, leading to serious physical disability and secondary medical problems. Many persons become jobless as a result of their disabilities and as consequence are further disadvantaged.

Objectives: Socio-medical analysis of the variable exogenous (external) barriers vs. facilitators and endogenous (personal) factors that modulate the (re-)employment of chronically SCI persons in Romania, integrated in the European legislative frame.

Methods: Questionnaire technique and electronic search of the legislation for the protection of the disabled persons' rights in Romania, investigated return to work and productive activities, following SCI.

Results: Reemployment rate of these disabled persons in Romania is 15%.

Discussion: The greatest hindrances for the reemployment of the chronically (medically stable) persons living with SCI are their physical inability, motivation and inaccessibility at work (problems due to the transportation and architectural barriers).

Conclusions: Reemployment (shifting from a consumer actual state, to a an active productive member of the society) and optimal participation, based on the individual's skills, psychomotor performances and educational background, represent major objectives of the social health politics and legislative work strategy in Romania. Return to work of people living with SCI should not represent an economic burden towards European Community, keeping in mind that the global prevalence of SCI is about 350,000 persons (under 0.1 % of the European population). Further extensive research should explore interventions focused on facilitating people with SCI to obtain and sustain productive work in Romania.

Key words: Spinal cord injury (SCI), consumer, productive activity, barriers, facilitators, social protection, reemployment.

THE INCIDENCE OF CHRONIC SUBDURAL HEMATOMA WITH PATIENTS ON ANTICOAGULANT THERAPY

V. Nikolov, A. Kostić, B. Jelenković, L. Berilažić, P. Milošević
Clinical Centre of Nis, Neurosurgery Clinic, Nis, Serbia

The chronic subdural hematomas usually occur as a result of minor trauma with older people. However, it has been noted that there is an increase in the number of patients with chronic subdural hematoma who were on a regular anticoagulant therapy.

The research has been conducted on the Department of Neurosurgery, in Clinical Center Nis in the period from January 2010 until December 2015.

The aim of this study is to determine the justification of the use of anticoagulants, as well as the responsibility of the patients in terms of dosing and monitoring of blood parameters (INR and prothrombin time).

Key words: Chronic subdural hematoma, anticoagulants, prothrombin time, INR

**ADDITIVE TECHNOLOGIES IN SKULL DEFECT RECONSTRUCTION:
NEW POROUS AND MESH TITANIUM COMPOSITE IMPLANTS**

A.D.Kravchuk¹, V.S.Komlev², S.M.Barinov², V.A.Okhlopkov¹, V.E.Mamonov³,
A.Yu.Fedotov², Y.A.Latyshev¹, A.D.Maryakhin¹

- 1) N.N.Burdenko Neurosurgery Research Institute,
- 2) The Institute of Metallurgy and Materials Sciences,
- 3) Hematological Scientific Centre, Moscow, Russia

Introduction: Additive technologies increase the potential for making individual implants. There are no ideal implants at present, despite a long history of cranioplasty. Development of new osteointegrative materials is still an existing problem in reconstructive neurosurgery

Materials and methods: A new technique for making individual porous and mesh Titanium composite implants with calcium phosphate-based bioactive ceramics has been developed. Individual implants are being formed based on CAD (computer-aided design) technology. CAM (computer-aided manufacturing) technology includes: 3D printing (Arcam Q10), E-beam processing of Pulvar Titanium (mark Ti6al4Eli) with making porous and mesh implants. The Titanium implant surface was covered by studied by precursors of apatite crystallization using reaction-related, biomimetic approaches (impulse laser ablation) for improving osteointegrative qualities of implants. There was performed in vitro biological testing of Titanium implant surface activated by octacalcium phosphate. Expressed matrix qualities of Titanium implant surface were revealed during cell proliferation.

Results and conclusion: Individual porous and mesh Titanium implants with bioactive ceramics and expressed matrix qualities have been developed.

This work supported by grant of Russian Fund of Fundamental Investigations, project № 15-29-04817.

CONTROVERSION AT THE HEAD INJURY

Milan Popovic*

Health Care Novo mesto

*Emergency center, Hospital Novo mesto

Novo mesto, Slovenia

Background: By head injuries it's can be injured: scalp, skull and brains.

In the clinical condition scalp injuries are usually visible, while injuries of the skull, like fractures of the skull, are rarely visible and brains injured are visible exceptional.

When brains are injured, it's mean simultaneously disturbances in circulation of the blood and cerebrospinal fluid (CSF).^{1,2,5,6}

For the scalp wounds are significant strong bleeding, which can cause transition state of the collapse or shock, and sometimes are dangerous for the life.

If the scalp injury caused by a fall or a blow and the patient's consciousness is disturbed, always we ask ourself about possible an alteration of the brains.^{1,2,3,4,6,7} At the moment a numerous dilemmas are appeared particularly if is detected alcohol abuse.

Material and method: Male, old 65 years, fell from the tractor suffered injury of the head and chest. At the head were scalp lacerations, bleeding from the nose and ear. The skin was blue, cold, and the mouth full of blood, which is accumulated in the throat and it's suffocated him. Breathing was very difficult.

At the monitor have shown following parameters:

R 12/min.

P 120/min.

SpO₂ 51%

NIBP 98/63

Glucose 7.3 mmol/l

T of 33°C

During the examination of neurological it was found that the patient was without reaction to the pain, in the condition of atony and iris were completely narrow and no reaction to the light.

The result of the Glasgow Coma Scale (GCS) was 3. So it was necessary immediately aspiration and intubation with all procedures rescue for the life. After tamponade of the nose and with accompanying of the condition at the monitor, the patient has been hospitalized. Then was made CT of the head and chest.

Conclusion: It often happens that the clinical condition is not liable to the actual state, therefore, a numerous dilemmas, or the disturbance of consciousness consequence of bleeding from the scalp and aperture on the head, or consequence of brains injury.

Keywords: Head injury, Unconsciousness, Controversion

UNSTABLE ICP IN SEVERE BRAIN INJURY: A BAD OMEN?

Gladi M., Iacoangeli M., Di Rienzo A., Donati A.*, Martorano P.***, Punzo S.*,
Barboni E.***, Vaira C., Ghisellini G., Marini A., Scerrati M.

Department of Neurosurgery, Università Politecnica delle Marche, Ospedali Riuniti, Ancona

*Department of Anesthesia and Reanimation, Università Politecnica delle Marche,
Ospedali Riuniti, Ancona

** Department of Neuroanesthesia, Università Politecnica delle Marche, Ospedali Riuniti, Ancona

Introduction: ICP monitoring through an invasive method still remains strategic in neurotraumatology. In severe TBI patients under primary tier therapy, high initial or progressive increasing ICP values, unresponsive to resuscitation measures, associated to neuroradiological worsening, may lead to decompressive craniectomy (DC). We studied a small number of patients with an atypical ICP trend to analyze the significance of this pathoetiologic course of ICP and its possible consequences on the choice of the best therapeutic management.

Material and Methods: We analysed a series of 348 patients who underwent DC for high ICP values from January 2008 until June 2015. We observed a sudden changeable trend of ICP without real persistent pathological values in 34 patients. In 7 patients this trend was more slowly progressive, serial CT scan were performed every 24-36 hours to exclude a pre-clinical acute neuroradiologic evolution. These patients were submitted, at first, to an external ventricular drain (EVD) implant with CSF subtraction followed by an initial ICP values normalization. However, usually after 6-12 hours, they showed again, now constant, a progressive raising of ICP values with persistent pathological values, requiring DC. In 27 patients, instead, after the initial unstable phase, we performed immediately a DC with subsequent persistent normalization of ICP.

Results and conclusion: In 34 patients with severe TBI and sudden changeable ICP values, we observed that this was a bad prognostic factor because all the patients were then submitted to DC for uncontrollable increasing of ICP, even those in which we attempted treatment by EVD. Our experience showed that unstable ICP values can be the initial expression of cerebral derangement and loss of autoregulation leading to the pathoetiologic course of malignant intracranial hypertension. In our opinion, but further verifications are needed, to broke this circle a relatively precocious DC may offer a better outcome.

PSYCHOLOGICAL AND PSYCHIATRIC CARE FOR CHILDREN WITH SEVERE SPINAL CORD INJURY

L'vova EA, Sidneva YG

Research Institute of Emergency Children's Surgery and Traumatology, Moscow, Russia

Annotation: Recovering from a severe spinal cord injury is different in children. Joint psychological and psychiatric support for children at an early stage of rehabilitation will allow time to conduct a differentiated assessment of the emotional and motivational disturbances with development of tactics maintenance and treatment of patients after neurotrauma.

An important role in the complex rehabilitation of patients after a serious spinal injury in the early stage of rehabilitation takes psychological and psychiatric support. Changes in emotional and personal background from injury hinder the effectiveness of rehabilitation. One of the common effects of spinal cord injury is considered to be reactive depression. It is characterized by a decrease in mood, activity and motivation. Depression after a severe spinal cord injury (TPSMT) in children leads to apathy, reducing the motivation for rehabilitation, poor "quality of life". But whether all patients with TPSMT faced with depression? The issue remains controversial. In the literature you can find a variety of information about the frequency of occurrence of depression in TPSMT, but these studies relate to adult patients. The literature is rare to find clinical trials in children, especially those associated with pharmacotherapy, no data on psychopharmacology TPSMT. Until now, you can find the opinion when invite to the rehabilitation team of a psychiatrist, that it is necessary only when the child identifies emotional disturbances in the most severe forms of depression. The psychiatrist is not invited because: 1) emotional expressions correspond to the stages of grief residence, it is believed that a psychologist to cope; 2) parents are opposed to a psychiatrist because there is a misconception about the mental health care; 3) do not need a psychiatrist - the fear of a specific psychotropic medication. There are many questions. What a way to assist? When needed a psychiatrist? You can treat the child with TPSMT?

Objective: To determine the severity of depression in children after TPSMT early rehabilitation and to develop an algorithm of psychological and psychiatric care.

Material and Methods: 35 children (8-18 years) with TPSMT received treatment at the Institute. All patients were examined by a psychiatrist and a psychologist in the dynamics. We used the diagnostic scales and questionnaires: Spielberger anxiety scale for children from the age of 14; scale of anxiety (for children from 8 years); Hospital Anxiety and Depression Scale HADS. Psychological support of patients was carried out using the Gestalt method of correction. Psychotropic treatment performed with antidepressant group of serotonin reuptake inhibitors (sertraline).

Results: There were three groups of patients: 1. 17.1% of children with depression (2 males, 4 females, mean age 15.5 years). 2. 31.4% of children with emotional features of high anxiety, decreased motivation (4 girls, 7 boys, mean age 14 years). 3. 51.4% - normal (15 boys, 3 girls, mean age 12.5 years). As a result of the study, we have identified the basic emotional characteristics of children in early rehabilitation: 1. A high level of anxiety had 9 children, the average - 7, 16 children low. 2. Severe depression in 6 children, the average severity of depression -10 children and there is no depression in 16 children. 3. High motivation to restore the - 17 children, average - 9, low 6. Children in the first group, where obvious signs of depression are diagnosed in the first place was needed correction psychiatric, psychological support is secondary. Children from the second group, which identified high anxiety and low motivation, but depressive tendencies are not pronounced, it was necessary psychological support and consulting psychiatrist recommended. In the second group according to our practice, psychologists, but experience has shown to achieve the pronounced effect of psychotherapy in the formation of stable motivation hospitalization time (25-45 days) is not always enough, so we asked for help from a psychiatrist. Psychological correction with medical support gave positive results. Children from the third group was recommended psychological

support. Patients with high trait anxiety, combined with low motivation, were especially pronounced difficulty in adapting to motor rehabilitation. This was manifested in a variety of situations, such as patients showed difficulty verticalization, did not want to change in a wheelchair and perceived exercise as insurmountable difficulties. Depression in the classical variant occurs in children from the age of 14, which is possible due to the peculiarities of the nervous system in children and their mental development. A depressive tendency can be identified already at a young age (from 12 years). All children with a high level of alarm and a low level of motivation needed psychiatric and psychological correction. Mental health care is needed with treatment in groups 1 and 2.

Conclusion: After the child's spinal cord injury requires a combination of psychological and psychiatric management of patients. This will: 1) the time to identify children with severe depressive tendencies, a high degree of anxiety, combined with low background motivations; 2) to provide expert psychological help; 3) adequately apply to specialized mental health care psychopharmacology. Differentiated psychological and psychiatric help increase the effectiveness of rehabilitation programs, improves the mood of children for the recovery and social inclusion in a normal environment, improves the "quality of life".

Keywords: spinal cord injury, rehabilitation, psychological counseling, depression, anxiety, decreased motivation, treatment, sertraline, Zoloft, quality of life.

Thursday, October 20th

ABSTRACTS

MAIN SESSION 2

Hall 2

MANAGEMENT OF CRANIOCERVICAL FRACTURES

Jesus Lafuente, LMS, FRCSEd, PhD
Presidente Electo de la EANS
Neurocirugia
Cirugia de Columna
Clinica CIMA, Barcelona, Spain

Introduction: Evaluation of the management of craneocervical fractures in the trauma setting.

Materials & Methods: Personal experience through cases in our Spine center and comparison with other series published in current literature. Most of the discussed cases are retrospective with OGS.

Results: We discussed the results on patients that had sustained a craneocervical fracture and its implications in survival and returning to normal activities.

Conclusions: This lecture presents a general overview on the management of craneocervical fractures using evidence based medicine as support to our current lines of treatment.

COGNITIVE AND EMOTIONAL DISTURBANCES AFTER TBI

Ksenija Kolundzija

Clinical Center of Vojvodina, Clinic of Psychiatry, Novi Sad, Serbia

Head injuries are interesting and dynamic part of neuropsychology, forensic psychiatry and forensic psychology. All psychopathological manifestations caused by the brain injury, which persist one year after the injury, can be considered permanent consequences. Presence of permanent psychological consequences is unambiguous in severe craniocerebral injuries and is easy to diagnose and assess. However, the question of persistence of consequences in mild cerebral traumas remains open even today. Psychological consequences of closed head injuries include: cognitive disturbances and changes on the level of personality, emotions and behaviour. Cognitive disturbances include deficit of attention, memory, learning, intelligence, language, perception and speed of processing information, while changes on the level of emotional functioning refer to mood disorders, low social interest, damaged self-control, increased dependence on environment and behavioural rigidity. In clinical and forensic practice, a battery of neuropsychological tests is used for the assessment of cognitive functioning and emotional-behavioural consequences of MBTI. Results obtained through neuropsychological assessment necessarily have to be interpreted in the context of examinees age, educational level, socio-economic status, and cultural milieu, history of the disease (onset and course of symptoms), motivation and especially effort invested in meeting test requirements. Assessment of simulation of MBTI consequences in forensic context, apart from being a great challenge, is also a very complex task during the neuropsychological evaluation. Using different strategies, symptoms that are most frequently simulated are pain, rigidity, dizziness, depression, problems with the memory, poor concentration, changes on personality level, loss of vision, restricted mobility, amnesia. In MBTI, neuropsychological assessment of simulation is difficult since there is no typical “simulative profile” which can be obtained with neuropsychological tests, so clinicians and forensic expert witnesses must rely on indirect indicators of simulation.

RUPTURED ANTERIOR COMMUNICATING ARTERY ANEURYSMS AN EXPERIENCE OF 513 CASES TREATED USING OPEN MICROSURGERY & A COMPARATIVE VIEW ON MANAGEMENT POLICIES IN TWO CENTERS

^{1,2}Assoc. Prof. H. Ples MD., PhD., ^{3,4}Prof. AV Ciurea MD., PhD., MSc. Dr.h.c. Mult.,

^{1,2}S. Ples MD., PhD., ^{1,2}A. Rata MD., PhD, ⁵A. Mohan MD., PhD, ^{4,6}H. A. Moisa MD.

- 1) "Victor Babes" University School of Medicine, Timisoara, Romania
- 2) Timis County Emergency Teaching Hospital, Timisoara, Romania
- 3) "Sanador Medical Center" Hospital, Dept. of Neurosurgery, Bucharest, Romania
- 4) "Carol Davila" University School of Medicine, Bucharest, Romania
- 5) Bihor County Emergency Teaching Hospital, Oradea, Romania
- 6) Bucharest Emergency Teaching Hospital, Bucharest, Romania

Background: Intracranial aneurysms have a prevalence between 0.2 and 7.9% in the literature.

Material and methods: The authors present two surgical management strategies for ruptured AComA aneurysms. The study group consisted of two cohorts:

The patients in Cohort A were all operated on. The cohort included Hunt-Hess I-III (while Hunt-cases only. Cohort B included random cases, graded Hunt-Hess I-V. All patients were immediately operated on after diagnosis.

Cohort A (Bucharest): was composed of 182 cases, operated between January 1998 and December 2015 - 18 years. Most patients were Hunt and Hess grade I-III (166 patients, 91.2%). There were 16 (8.7%) cases in H&H IV. **Cohort B (Timisoara):** Consisted of 331 cases operated between January 2000 and December 2015 (15 years). There were 16 patients in H&H I (5%), 173 patients in H&H II (52%), 79 patients in H&H III (24%), 46 patients in H&H IV (14%) and 17 patients in H&H V (5%). In both cohorts (513 cases) most patients were between 41 and 50 years old, Males were preponderant (68%) (with a M/F ratio of 1.46 : 1). The symptoms were dominated by: headache (98%), neck stiffness (94%), focal neurologic deficits (71%), seizures (52%) impaired consciousness (15.3%). All cases received early microsurgery.

Results: The GOS at 6 months postop.

In Cohort A: GR - 103 cases (56.73%), MD - 61 cases, SD - 9 cases, PVS - 2 cases, D - 7 cases (3.89%).

For Cohort B the results show: GR: 127 cases (38.3%), MD: 81 cases, SD: 63 cases, D - 52 patients (15.7%).

Conclusions: By comparing the two studied series, we notice that: Patient selection - exclusion of Hunt&Hess IV and V aneurysms increases the value of the prognosis in such situations.

Keywords: Intracranial aneurysm, personal experience, management strategy, multicentric study.

THE ROLE OF FUNCTIONAL BRAIN CLEAVAGE IN CONSCIOUSNESS DISORDERS

L.B.Oknina¹, D.I.Pitschilauri², O.S.Zaitsev², E.V.Sharova¹, E.L.Masherov²

1) Institute of Higher Nervous Activity and Neurophysiology,

2) Burdenco Neurosurgery Institute, Moscow, Russia

Recently the leading role of the brainstem, along with cortex, in consciousness recovery and sustentation is widely discussed. However, there is no rigorous evidence that cortex-brainstem integration is required for consciousness recovery, due to the impossibility of recording brain activity using implant electrodes in healthy subjects.

EEG and ERPs were recorded in 22 patients in vegetative state or mutism after a severe brain injury and in 6 patients with a tumor of periaqueductal grey matter, to whom a ventricular catheter with electrodes was implanted into the aqueductus cerebri, at the final stage of oncotomy. EEG and ERP were recorded simultaneously from scalp electrodes and from deep electrodes. The study was designed according to an oddball paradigm consisting of standard and target tones.

Under anesthesia, ERPs were recorded during the listening to tones without instruction. In clear consciousness, obnubilation and posttraumatic unconsciousness state ERPs were recorded without instruction and with the instruction to count target tones. The wavelet-synchronization between cortex-cortex and brainstem-cortex electrodes was calculated by Brain Connection (Russia).

The wavelet-synchronization between both cortex-cortex and brainstem-cortex electrodes are detected in patients with clear consciousness. A stronger wavelet-synchronization between cortex electrodes and no wavelet-synchronization between cortex and brainstem electrodes were detected in obnubilation. Both tendencies were more prominent while the patient was counting tones. The decrease of wavelet-synchronization between the cortex and brainstem was detected before and just after waking-up, whereas a pronounced wavelet-synchronization was detected when the patient came back to clear consciousness.

Due to the disintegration between the cortex and brainstem, the cortex seems to have a stronger and more stable activation not being integrated with brainstem. These data are discussed in terms of cortex-brainstem integration disorders, affecting the emergence of the pathological local area activation, which is typical for unconsciousness state.

The study was supported by RGNF N15-06-10836.

SURGERY VERSUS CONSERVATIVE TREATMENT IN PATIENTS WITH TRAUMATIC INTRACEREBRAL HEMORRHAGE

Mirsad Hodžić

Department of Neurosurgery, University Clinical Center Tuzla, Bosnia and Herzegovina

Background: Traumatic intracerebral hemorrhages occur in a proportion of severe traumatic brain injury patients. Rationale underlying the choice of treatment modality of traumatic intracerebral hemorrhages is usually unclear, as there is little good quality evidence available. Controversy regarding the best therapeutic strategy in these patients exists between two competing treatment options; surgery or conservative therapy.

Methods: We present our experience in treatment of severe traumatic brain injury. Clinical status upon arrival using the Glasgow Coma Scale, CT scan, clinical outcome using the Glasgow Outcome Scale and patient related factors were evaluated. The study population consisted of 42 patients surgically treated for severe traumatic brain injury identified prospectively in two years.

Results: The average age of the patients was 44 years, between 9 and 78. Of the 42 patients, there were 16 patients with subdural hemorrhage, 14 patients with impressive skull fracture, 6 patients with extradural hemorrhage and 6 patients with traumatic intracerebral hemorrhage.

Conclusion: The patients who are alert or just confused (GCS 13–15) can probably be watched carefully for any deterioration. There is a strong case for operating on patients with deterioration and patients with lower GCS.

Key words: traumatic brain injury, intracerebral hemorrhage, craniotomy

WHEN DECOMPRESSIVE CRANIECTOMY IMPROVES THE OUTCOME OF TBI PATIENTS

Zbigniew Czernicki¹, Piotr Jasielski²

1) Second Faculty of Medicine, Medical University of Warsaw, Poland

2) Mossakowski Medical Research Centre, Polish Academy of Sciences, Warsaw, Poland

Introduction: Some of TBI patients are diagnosed with intracranial haematomas and they are qualified for the surgical treatment. After removal of haematomas one can observe the brain enlargement. Whether to replace the bone flap, to remove the flap or to do the decompressive craniectomy remains still an open question.

Material and Methods: 49 patients were studied, mean GCS 7 age from 21 to 86. Craniectomy diameter varied from 5,9 cm to 12,2 cm. Volumes of different intracranial compartments were measured using computer programme Praezis Plus-Tatra Med Company and Pax Station – Compart Medical System Company.

Results: The extra space gained by decompressive craniectomy was found in a volume from 4 ml to 148,9 ml with ambient cistern volume changes from 0,48 ml before operation to 0,96 ml after operation.

Conclusion: If after removal of traumatic intracranial haematoma, the brain tissue enlargement is observed, the removal of bone flap turned out to be not enough. Instead a sufficient decompressive craniectomy (diameter > 12 cm) should be performed.

CRANIAL HEAD TRAUMA IN NEWBORN INFANTSKolić Zlatko¹, Vukas Duje², Karlović – Vidaković Marijana³

1) Special Surgical Hospital Medico - Rijeka

2) Clinical Hospital Centre Rijeka, Department of Neurosurgery

3) University Hospital Mostar, Department of Radiology

Birth trauma is a rare adverse event during childbirth. It occurs particularly in a long and difficult instrumental delivery, labor caesarean section or fetal malposition. The incidence of birth trauma varies between 0,2 and 34,2 per 1000 birth. Birth injuries have decreased over time with improved obstetric care and perinatal diagnosis. Rate of birth trauma is about 2% in normal vaginal delivery with cephalic presentation and 1,1% in cesarean section. Birth injuries may include soft tissue injuries, head injury, spinal cord and peripheral nerve injury, musculoskeletal injury, and hypoxic injury. In most studies cranial and musculoskeletal injury were the most frequent birth injuries.

Cranial head injuries in newborn are intracranial hemorrhages usually presented as intracerebral or subdural hematoma. Epidural hematoma is rare, but when it occurs it is often a complication of instrumental assisted delivery. Perinatal epidural hematomas in absence of instrumental delivery are in association with some comorbidities such as Prader–Willi syndrome, Chiari malformation, hemophilia or other coagulopathy disorders. Vascular malformations are not a cause of epidural hematomas. Epidural hematoma was most frequently located in the parietal area. The presence of fracture is not a rule. Clinical signs of neonatal epidural hematoma such as seizures, anaemia, and hypovolemia, are unspecific. The most common symptoms are pallor, decrease of the haematocrit and an increasing head circumference. The onset of clinical symptoms is within the first 24 hours after delivery. Following clinical symptoms epidural hematoma is detected by CT or MRI scans. Indications for surgical treatment of epidural hematoma were based on the thickness of the hematoma, the shift of the brain, and an eventual associated depressed cranial fracture or hydrocephalus.

In conclusion, it has been suggested that the rate of cranial head trauma was higher in infants by instrumented delivery or caesarean section with labor than in infants delivered spontaneously or by caesarean section without labor. Epidural hematoma is a rare complication of birth and can follow in a delivery without instrumental assistance. Prognosis and outcome of perinatal epidural haemorrhage is generally good, when is diagnosed in an early stage.

Thursday, October 20th

ABSTRACTS

**YOUNG NEUROSURGEONS SNSS
AND EMN AWARD WITH
INTERNATIONAL PARTICIPATION**

Hall 2

SURGICAL VS NONSURGICAL TREATMENT OF INTRACRANIAL TRAUMATIC HAEMATOMA-SINGLE CENTER EXPERIENCE

Marko Samardžić¹, Milan Spaić¹, Radomir Benović¹, Milenko Stanić¹, Miljan Bulatović¹,
Igor Popović¹, Nenad Živković¹, Vuk Aleksić¹

1) Department of Neurosurgery, Clinical Hospital Center Zemun, Belgrade, Serbia

Intracranial traumatic hematoma (ITH), which means epidural hematoma (EDH) and acute subdural hematoma (aSDH), is a surgically prevented cause of secondary damage in traumatic brain injury. In the literature there are sufficient data on the indications for surgical treatment based on the clinical status of the patient and radiological characteristic of ITH. The objectives of the study was to analyze and displays a series of borderline cases, in addition to clinical and radiological factors, age, presence of co morbidity, association between other types of craniocerebral injuries and type of surgical treatment when deciding on the treatment of patients with ITH. We retrospectively analyzed a series of cases of patients treated due to ITH in the period from 2000 until 2015 in KBC Zemun. Data were collected from medical history and protocol of the patient operated for a given period. Indications for surgical treatment were set on the basis of valid guides to good clinical practice; clinical lead is mainly clinical picture and radiological characteristics of ITH. Among them, in addition to clinical and radiological characteristics analyzed in the presence of co morbidity, age, associated brain injuries and time of operative treatment. A total of 164 patients included in this study. Out of these, 111 (67, 7%) patients treated surgically and 33 (32, 3%) nonsurgical. There was no statistically significant difference in terms of age, associated brain injuries and associated co morbidities in two groups of patients. A special group of patients, 15 of them (9.1 %) were the ones where we initially opted for no surgery treatment but who subsequently underwent surgery. By comparing the series of borderline cases with surgically treated group of patients, we concluded that radiological factors predicting method of treatment.

Key-words: Intracranial traumatic haematoma, treatment, surgery, nonsurgical treatment

ENDOSCOPE-ASSISTED EVACUATION OF CHRONIC SUBDURAL HAEMATOMAS- 121 MINIMALLY-INVANSIVE PROCEDURES

Y. Enchev^{1,2}, B Iliev^{1,2}, T. Kondev¹, T. Avramov^{1,2}, Pl. Trendafilov¹, E. Zaharieva¹,
M. Moinov¹, St. Todorova²

1) Department of Neurosurgery, MUniversity Hospital "St. Marina," Varna, Bulgaria

2) Department of Neurosurgery, Medical University of Varna, Varna, Bulgaria

Introduction: The endoscope-assisted evacuation of chronic subdural haematomas (SDH) currently is not a generally accepted technique of neurosurgical treatment. The aim of our prospective study was to verify the effectiveness of the endoscope-assisted evacuation of chronic subdural haematomas.

Material and Methods: The study was performed based on a preliminary developed protocol. During the period of 4 years (2012- 2015), endoscope-assisted evacuation was performed in 121 cases of chronic subdural haematoma. Minimal invasive procedure consists of -a linear skin incision, burr-hole, incision of the dura and subsequent endoscope-assisted evacuation. The degree of SDH evacuation was evaluated by comparison between pre- and postoperative CT scans. The patients were followed-up clinically and radiologically as morbidity, mortality, and rebleeding rates were specified. Glasgow Outcome Scale (GOS) scores were assessed 1 month postoperatively.

Results: The mean operative time in the series was 65 minutes. 18 patients underwent bilateral burr-hole procedures. An external subdural drainage was inserted in all procedures for 12 hours. The hematoma evacuation average to 95%. The rebleeding rate was 1.2 %. The mortality rate was 0%, and surgery-related morbidity- 1.2 % (1 case). The mean GOS score was 5 at 1-month follow-up.

Conclusion: Endoscope-assisted SDH evacuation represents safe and effective treatment option. The morbidity, mortality, and rebleeding rates surpass the rates for SDH evacuation by the conventional method reported in the literature. As disadvantage is considered the prolonged duration of the procedure.

Key words: chronic subdural haematomas, endoscope-assisted evacuation, minimally invasive procedures

SELECTIVE BRAIN HYPOTHERMIA TRANSIENTLY IMPROVES THE NEUROLOGICAL RECOVERY IN THE MOUSE MODEL OF DECOMPRESSIVE CRANIECTOMY AFTER CLOSED HEAD INJURY

Jacek Szczygielski MD¹, Vanessa Hubertus¹, Eduard Kruchten¹, Andreas Müller MD²,
 Angelika E. Mautes MD, PhD¹, Karsten Schwerdtfeger MD, PhD¹,
 Wolf-Ingo Steudel MD, PhD¹, Joachim Oertel MD, PhD¹
 1) Department of Neurosurgery, 2) Department of Radiology,
 Saarland University Medical Center and Saarland University Faculty of Medicine,
 Homburg /Saar, Germany

Background: In the series of previous short-term animal experiments, the effectiveness of selective brain hypothermia has been presented (considering both the structural damage and neurological outcome). However, facing the negative results of recent clinical randomized trials, the use of hypothermia in neurotrauma remains controversial. We intended to analyze the long-term impact of hypothermia in our murine model of focal brain cooling through decompressive craniectomy window after closed head injury.

Methods: Male CD-1 mice were randomly assigned into the following groups (n=8 each): sham, decompressive craniectomy (DC), closed head injury (CHI), CHI followed by craniectomy (CHI+DC), CHI and DC followed by focal hypothermia (CHI+DC+H). The neurological assessment according to Beam Balance Score (BBS) test has been performed 24h, 3d, 7d, 14d and 28d after trauma. Here, the neurological outcome was specified as impairment score BBS (0-5 points) and as total balancing time during three balancing attempts. One-way ANOVA was used for statistical analysis.

Results: During the early posttraumatic period (24h, 3d and 7d) the beam balance performance was significantly worse in animals subjected both to trauma and craniectomy, compared to sham animals. Interestingly, this negative impact effaced, if focal hypothermia has been applied. Nevertheless, the protective effect of hypothermia could not be documented at 14d and 28d posttrauma.

Conclusion: In our model, focal brain hypothermia resulted in short-term improvement of neurological recovery after traumatic insult. However, this phenomenon should be defined as delay in posttraumatic neurodegeneration rather than permanent neuroprotective effect. Our observation is sound with the negative results of clinical studies. The issue, why the beneficial effect of hypothermia subsides in later course after trauma remains controversial. We believe, that our experimental paradigm would be suitable for answering this question.

INFLUENCE OF ANTICOAGULANT THERAPY ON DEVELOPMENT OF CHRONIC SUBDURAL HAEMATOMAS IN PROVINCE OF VOJVODINA

Antun Azaševac¹, G. Mitić², N. Krajčinović¹, M. Karan¹, B. Jelača¹, J. Golubović¹,
M. Fimić³, P. Vuleković¹

1) Clinic for Neurosurgery, Clinical Center of Vojvodina, Novi Sad, Serbia

2) Department of Haematology, Haemostasis, and Prevention of Thrombosis,
Clinical Center of Vojvodina, Novi Sad, Serbia

3) Institute for Child and Youth Health Care of Vojvodina,
Department of Neurosurgery, Novi Sad, Serbia

Introduction: Chronic subdural haematoma (CSDH) is an encapsulated collection of blood, mostly or totally liquefied, located in subdural space. It often occurs without recognized head trauma. Advanced age is followed by cerebral atrophy, intracranial hypotension and increased use of oral anticoagulants due to higher cardiovascular and cerebrovascular morbidity rate.

Aim: To investigate influence of previous use of anticoagulant agents on development of CSDH in different age groups.

Material and methods: The study was a retrospective review which included all of 122 patients with surgically treated CSDH at the Clinic for Neurosurgery, Clinical Center of Vojvodina during the period from January 1st, 2013 to June 30th, 2016. Patients were divided into two groups according to their age – younger group (<65 years) and older group (≥ 65 years). Age, gender and use of anticoagulants prescribed due to preexisting comorbidities were analysed. Statistical significance between the use of oral anticoagulants and the development of CSDH was estimated by χ^2 -test.

Results: The patient population consisted of 90 (74%) men and 32 (26%) women with a mean age of 71.5 years. Older group of patients consisted of 96 (79%) patients. In this group anticoagulants were used in 9 (9%) of cases. Younger group consisted of 26 (21%) patients and 4 of them (15%) used anticoagulant therapy. According to data provided by the Department of Haematology, Haemostasis, and Prevention of Thrombosis, Clinical Center of Vojvodina, 18 500 of patients (1% of population of Vojvodina) used oral anticoagulants in Vojvodina during the observed period. Computed value of χ^2 -test is 126 ($\chi^2 = 3.841$, $p=0,05$).

Conclusion: The use of oral anticoagulants is one of the most important factors in development of CSDH in population of Vojvodina.

Key words: chronic subdural hematoma, oral anticoagulants

CT SCORING SCALES AS THE EARLY OUTCOME PREDICTORS IN PATIENTS WITH TBI: WHICH ONE TO USE?

Golubović J¹, Karan M^{1,2}, Jelača B¹, Azaševac A¹, Fimić M³, Vuleković P^{1,2}

1) Clinical centre of Vojvodina, Clinic of neurosurgery, Novi Sad, Serbia

2) University of Novi Sad, Faculty of medicine, Novi Sad, Serbia

3) Institute for child and youth health care of Vojvodina, Clinic of pediatric surgery, Novi Sad, Serbia

Purpose: Essential tool in traumatic brain injury (TBI) diagnosing and treatment is computer tomography (CT). Marshall CT classification, Rotterdam and Helsinki CT score were consecutively developed as prediction outcome scales by computing TBI CT abnormalities. None of them classifies the pathological CT findings in the same way. Our aim was to determine which one is the most accurate and has the best grading discriminatory power in determining the early outcome.

Methods: A retrospective, single-center study was designed to include 800 consecutive TBI patients who underwent CT head scan in the ER department of a single tertiary care center. After calculating all of the three scores, comparison between scales performances as well as their accuracy in predicting patients' early outcome (by using Glasgow outcome scale-GOS) was made. Area under the receiver operating characteristic curve (AUC) was used as the discriminatory power of each system while the statistical correlation was the instrument of comparison between all three scales.

Results: All patients who had negative CT results (Marshall I, Rotterdam 1 and Helsinki 0) with no major body trauma had good outcome results. Of the group that did have positive CT TBI findings the mean age was 56.6 (± 20.1) years, overall mortality was 15.4%, average GOS was 3.00 (± 1.4) and mean Glasgow coma score-GCS was 12.0 (± 3.94). More deaths did occur among patients with higher CT scores (all $P < 0.01$, Kruskal-Wallis H test). The areas under the receiver operating characteristic curve (AUCs) indicated that all scoring systems had similarly high discriminative power in predicting early death/early unfavorable outcome (Marshall, AUC = 0.74/0.86 vs. Rotterdam, AUC = 0.80/0.82 vs. Helsinki, AUC=0.77/0.84). High correlation was found between Marshall and Rotterdam grading, $r=0.78$, and moderate correlation between the other two pairs, Marshall vs. Helsinki, $r=0.62$ and Rotterdam vs Helsinki, $r=0.51$. Valuable predictors of early death and outcome also turned out to be low GCS and high injury severity score-ISS.

Conclusion: All classifications have similarly strong predictive power for early outcome, but even greater discrimination results could be obtained if GCS and ISS were incorporated in the calculation. Helsinki CT score has around same predictability as the other two scales, but has the least correlation with them. Marshall's CT classification, although being the oldest, and the simplest one, has at least the same prediction power as the newer scoring scales and therefore it should remain in use. Rotterdam system, having the high predictability and also including characteristic like subarachnoid hemorrhage, should be scale of choice as it incorporates multivariate factors into the equation should result in more accurate predictability.

Key words: Marshall CT classification, Rotterdam CT score, Helsinki CT score, Early outcome, Traumatic brain injury

DIFFUSION TENSOR IMAGING AND NEUROPSYCHOLOGICAL EXAMINATION IN MILD TRAUMATIC BRAIN INJURY

Karan M, Vuleković P

Clinic of Neurosurgery, Clinical Centre of Vojvodina Novi Sad

Introduction: Mild traumatic brain injury (mTBI) is characterized by broad spectrum of clinical, neurological and psychological disturbances. Novel imaging techniques, such as Diffusion Tensor Imaging (DTI), can be applied to detect discrete changes in brain white matter integrity in absence of macroscopic structural lesions.

Aim: The aim of this study was to analyse DTI findings in acute phase of mTBI and their correlation with results of neuropsychological examination.

Material and methods: A cohort of 37 patients with mTBI and normal CT scan findings has been analysed. All of them had MRI examination included DTI in first 72 hours after injury. We placed region of interest in predefined places (genu, body and splenium of corpus callosum and both genu of internal capsule) to measure diffusion parameters - fractional anisotropy (FA) and mean diffusivity (MD). In 25 patients we performed neuropsychological testing in one month and 6-9 months after injury. Neuropsychological testing was designed to assess cognitive disturbances, presence of depressive disorder and to assess quality of life.

Results: We did not find statistically significant differences in mean values of FA and MD between patients with complicated and uncomplicated mTBI. We found significant negative correlation between some cognitive measures and diffusion parameters in examined regions. In smaller number we also found strong positive correlation between cognitive measures and diffusion parameters in genu of internal capsule bilaterally. Regarding presence of depressive disorder, we found significant positive correlation with values of diffusion parameters in corpus callosum. Some aspects of satisfaction with quality of life was positively correlated with diffusion parameters measured in genu of internal capsule.

Conclusion: Great diversity in DTI findings in previously published researches suggests necessity for larger, but more similarly designed and comparable studies in order to provide new insight in subtle connection between clinical presentation and intracellular processes behind mTBI.

DIFFERENCES IN ADMISION FINDINGS, MECHANISM OF INJURY AND CT SCAN FINDINGS BETWEEN PEDIATRIC AND ADULT TBI PATIENTS

M. Fimić ¹, A. Milojević ¹, I. Meljnikov ¹, J. Golubović ², P. Vuleković ^{2,3}, T. Cigić ^{2,3}

1) Institute for child and youth health care of Vojvodina, Clinic of pediatric surgery,
Department of neurosurgery

2) Clinical centre of Vojvodina, Clinic of neurosurgery

3) University of Novi Sad, Medical faculty

PURPOSE: Traumatic brain injury (TBI) is a leading cause of death among pediatric patients. Admission findings, mechanism of injury and initial CT scans play important roles in classifying TBI and further treatment. The differences between pediatric and adult group of patients are not often researched. The aim of this study was to determine if differences between adult and pediatric group of patients exist and their characteristics.

METHODS: The authors retrospectively analyzed TBI registry data from 619 consecutive patients with TBI who underwent CT head scan and were treated at a Level 3 adult and pediatric trauma center over a 1-year period.

RESULTS: The distribution of sex, and Glasgow Coma Scale (GCS) score was not significantly different between the adult and pediatric populations. More children were injured while riding a bicycle and by falling from height compared to adults, whereas adults were more often injured in road traffic accidents, assaults and fall from standing height ($p < 0.05$). There is a significant statistical difference in referrals where children were more often secondarily referred from other hospitals. Pediatric patients with TBI were more likely to have positive CT scan ($p < 0.01$) for skull fractures ($p < 0.01$) and epidural hematomas ($p < 0.01$). Pediatric TBI was less likely to be associated with contusion, subdural hematoma, subarachnoid hemorrhage, or compression of the basal cisterns ($p < 0.01$). Rotterdam CT scores were significantly lower in the pediatric group ($p < 0.01$) and so was the outcome more favourable.

CONCLUSION: Despite statistical similarities regarding to clinical severity of injury measured by GCS, there are significant differences in the CT findings in pediatric versus adult TBI, which may be due to anatomical characteristics, the biomechanics of injury, and/or differences in injury mechanisms. Differences in referrals between pediatric and adult TBI can be explained by inexperience in pediatric TBI in 1st/2nd trauma care centers. The unique characteristics of adult vs. pediatric TBI should be taken in considerations when predicting functional outcome in children, making prognostics and decision on further treatment steps.

KEY WORDS: traumatic brain injury, computed tomography, pediatric, adult

RESULTS OF DISTAL NERVE TRANSFERS IN NERVE INJURIES OF THE UPPER EXTREMITY OVER 3-YEAR PERIOD

Savic A.¹, Matic S.¹, Bascarevic V.^{1,2}, Micovic M.^{1,2}, Rasulic L.^{1,2}

1) Clinical Center of Serbia, Clinic of Neurosurgery

2) University of Belgrade, Faculty of Medicine

Introduction: Distal nerve transfer represents the use of terminal branches of the brachial plexus and their lateral branches, which function is intact, as donors. In the other side recipient nerves are also terminal branches of the brachial plexus and their lateral branches, located very close to the muscles which we want to reinnervate.

Indications for distal nerve transfers in nerve injuries of the upper extremity are: upper brachial plexus palsy (C5, C6±C7), lower brachial plexus palsy (C8, T1±C7), isolated injuries of n. axillaries and n. musculocutaneus, proximal irreparable isolated injuries of n. radialis, n. medianus and n. ulnaris.

Methods: The aim of our study is to describe results of distal nerve transfers in nerve injuries of the upper extremity over 3-year period, from January 1, 2011 to December 31, 2013.

This study included 37 patients that received distal nerve transfer at the Clinic of Neurosurgery in Belgrade after having been diagnosed with upper extremity nerve injury. This study included all patients that satisfied this criteria over a period of 3 years.

The final outcome evaluation was performed 2 years after surgical treatment.

Results: In 11 patients with upper brachial plexus palsy (C5, C6) we did Oberlin procedures and in 10 patients (90,9%) satisfactory neurological outcome (M3-M5 elbow flexion) was found. Also in all these patients (C5, C6) we performed nerve transfer of n. accessorius to n. suprascapularis with posterior approach and Somsak procedure and successful results (M3-M5 shoulder abduction) were achieved in 9 of them (81,8%).

We had 2 patients with lower brachial plexus palsy (C8, T1) and in both of them we performed nerve transfer of branch of the n. musculocutaneus for m. brachialis to n. interosseus anterior for reconstruction of the finger flexion and nerve transfer of branch of the n. interosseus posterior for m. supinator to n. interosseus posterior for reconstruction of the finger extension. In terms of finger flexion we achieved one M4 and one M2, on the other side in terms of finger extension we achieved two M3.

In 9 patients with isolated injury of the axillary nerve we performed Somsak procedure and satisfactory neurological outcome was achieved in 8 of them (88,8%)

In 3 patients with isolated lesion of the n. musculocutaneus we performed "double fascicular nerve transfer" and achieved excellent results (M5 elbow flexion) in all of them (100%)

In 5 patients with irreparable isolated proximal injury of the radial nerve we did transfer of branch of the median nerve to m. flexor carpi radialis to n. interosseus posterior and transfer of branch of the median nerve for m. flexor digitorum superficialis to branch of the radial nerve for m. extensor carpi radialis brevis. Successful outcome was found in 4 cases (80%) in terms of finger extension and in 5 cases (100%) in terms of wrist extension.

In 7 patients with isolated proximal ulnar nerve damage we did nerve transfer of branch of the n. interosseus anterior for m. pronator quadratus to ulnar motor branch and obtained satisfactory neurological outcome in 4 patients (57,1%)

We haven't got patient with isolated proximal irreparable injury of the median nerve that is appropriate for nerve transfer ECRB-AIN and supinator branch of the PIN-FDS.

Conclusion: Careful selection of appropriate donor and recipient is mandatory for the success of the distal nerve transfer . Donor must be the nerve which function is intact, which has an adequate number of axons for donating and which can stand the loss of part of its axons without the occurrence of subsequent functional deficit. Recipient nerve must be located close to the targeted muscle in order to maximally reduce the distance and time required for the reinnervation and to achieve more efficient recovery of the damaged function.

Other prognostic factors affecting the final outcome include:, timing of the surgery, age of the patient, his or her general condition, associated diseases, skillfulness and experience of the surgeon.

ENDOVASCULAR TREATMENT OF POST-TRAUMATIC DIRECT CAROTID CAVERNOUS FISTULAS

Filip Vitošević

Neuroradiology Department, Center for Radiology and MRI,
Clinical Center of Serbia, Belgrade, Serbia

Carotid cavernous fistulas are abnormal arteriovenous connections between carotid artery and cavernous sinus. They are considered direct when there is direct connection between the internal carotid artery and cavernous sinus, and these cases are generally traumatic and occur after blunt or penetrating injuries of the head. These are high-flow lesions and manifest with a visual loss, proptosis, chemosis, corneal exposure or even fatal epistaxis. They are usually accompanied with skull-base fracture and intracranial bleeding.

Thus, treatment of these lesions is always recommended and fundamental principle is to exclude the fistula from circulation preserving the carotid flow.

Endovascular treatment of post-traumatic direct carotid cavernous fistulas was conducted on ten patients in our Institution, in the last ten years. They have received periodic clinical and angiographic follow-up to evaluate the patency and stability of clinical results.

All procedures were performed via transarterial, transfemoral, approach. Detachable coils were used for occlusion in all procedures, in one case together with neurovascular stent as a support, in one case with neurovascular flow-diverting stent for better occlusion, and in one case together with liquid embolization agent. In seven patients, carotid cavernous fistula was occluded completely, and symptoms related to them have been regressed after treatment and did not reoccur in the follow-up. In two cases fistula was formed between traumatic aneurysm in cavernous segment of internal carotid artery and cavernous sinus. There were no major complications following embolization procedures. Spontaneous resolution of this direct carotid cavernous fistulas is extremely rare and direct surgical repair with preservation of distal part of internal carotid artery is challenging due to the relative inaccessibility of this structure. This can be transposed using various endovascular treatment techniques and endovascular treatment represents an effective method for complete occlusion of these fistulas with favorable long-term outcomes.

INTRAVENTRICULAR INTRACRANIAL PRESSURE MONITORING AND IT'S ROLE IN TREATMENT IN PATIENT WITH TBI

A.Miljković¹, B. Živković¹, A. Radunović², S. Matić¹, V. Janošević², I. Jovanović^{1,3}, L.Rasulić^{1,3}

1) Clinic of neurosurgery, Clinical Center of Serbia, Belgrade

2) Clinic of neurosurgery, Clinical Center of Montenegro, Podgorica

3) University of Belgrade, Faculty of medicine

Introduction: Trauma is the leading cause of death in people under the age of 40. Head injury is much more common in young adults than in the elderly. Patients with severe head injury will be admitted to an intensive care unit for close neurological monitoring. Patients that remain unconscious and have low GCS scores (less than 8) will often be monitored in the intensive care unit for signs of increased intracranial pressure (ICP). A device called an ICP monitor is placed within the brain to record pressure within the skull.

High pressures correlate with poor outcome, thus prompt recognition of elevated ICP is important. Treatment consists of surgery if there is significant brain swelling or bleeding.

Objective: To determine the role of intracranial pressure (ICP) monitoring in management of patients with severe traumatic brain injury (TBI) admitted to an Emergency center in Belgrade, Serbia.

Methods: This was a cohort study performed during a 3-year period (2012-2014) in an Emergency center in Belgrade, Serbia including all adult patients (>18 years) with severe TBI (Glasgow Coma Scale [GCS] score, 3–8) who underwent ICP monitoring through ventriculostomy. The management was based on the recorded ICP values with threshold of 20 mm Hg. Decompressive craniectomy was performed in patients with persistent ICP ≥ 25 mm Hg. In patient with GCS below 4, barbiturate coma was induced. The determinants of favorable and unfavorable outcome were also determined.

Results: We included 45 patients with mean age of 34.6 ± 16.6 years, among whom there were 38 men (85%) and 7 women (15%). Fourteen patients (30%) had favorable and 31 (70%) unfavorable outcomes. Those with favorable outcome had significantly lower age ($P = 0.004$), higher GCS score on admission ($P < 0.001$), lower Rotterdam score ($P = 0.035$), fewer episodes of intracranial hypertension ($P < 0.001$), and lower maximum recorded ICP ($P = 0.041$).

Conclusions: ICP monitoring is very important „tool“ for correcting therapy in patients with severe TBI. Constant monitoring with age, GCS score on admission, Rotterdam score, intracranial hypertension, we can predict outcome in patients with severe TBI.

Key words: traumatic brain injury, ICP monitoring, Rotterdam score

CLINICAL PREDICTION RULES FOR POSITIVE COMPUTED TOMOGRAPHY SCAN IN PATIENTS WITH MTBI

B. Jelača^{1,2}, Jagoš Golubović^{1,2}, M. Karan^{1,2}, A. Azaševac¹, F. Pajičić², M. Loc², V. Papić^{1,2},
P. Vuleković^{1,2}

1) Clinic of Neurosurgery, Clinical Center of Vojvodina, Novi Sad, Serbia

2) Faculty of Medicine, University of Novi Sad, Novi Sad, Serbia

Introduction: There is much controversy about the use of computed tomography (CT) and it is very difficult to define prediction factors for positive head CT findings among the patients with mild traumatic brain injury (mTBI). We aimed to identify predictors of positive head CT scan findings in terms of presence of any kind of intracranial hemorrhage after mTBI.

Materials and Methods: We carried out retrospective cohort study for a period of a one year in the Emergency department of Clinical centre of Vojvodina and included consecutive adults who presented with a Glasgow Coma Scale (GCS) score of 13-15 after head injury. We did standardized clinical assessments before the CT scan (CT scan indicated after Canadian head CT rule). The variables used for detection of positive head CT scan were age, gender, cause of injury, coexisting severe diseases, anticoagulation therapy use, antiplatelet therapy use and GCS score. SPSS was used as a statistical tool with the application of Chi Square, Logistic regression and T test.

Results: A total of 658 patients were included in the study and 21% of all patients analysed had positive CT findings. Average age was 56.02 years and there were more male than female patients. Majority of patients were hurt by falls and RTAs. 24% of patients were hospitalised and 6 of them underwent craniotomy for haematoma evacuation. 10.1/10.5% of the examined group was taking anticoagulant/antiplatelet therapy. Higher age, male sex, coexisting severe diseases and lower GCS score at the point of admission have found to be statistically significant in predicting positive CT result. Cause of injury, anticoagulation therapy and antiplatelet therapy did not show significant statistical correlation with prediction of positive CT finding.

Conclusion: Combinations of history and physical examination features in clinical decision rules can identify patients with mTBI at high risk of presence of intracranial injuries on head CT scan. Well known Canadian CT Head Rule is a highly sensitive tool for the use of CT.

Key words: Mild Traumatic Brain Injury, Computed Tomography, Indications, Prediction

Novi Sad 2016

One Region, One Neurosurgery

Thursday, October 20th / Hall 2

Friday, October 21st

ABSTRACTS

KEY NOTE LECTURES

Hall 1



Dr Andre Grotenhuis

EANS President
Radboud University Medical Centre,
Department of Neurosurgery,
Nijmegen, Netherlands

Dr. Andre Grotenhuis has been appointed full Clinical Professor of Neurosurgery in 2001 at the Department of Neurosurgery at the Radboud UMC (Radboud University Medical Centre) Nijmegen, the Netherlands and from 1999-2010 he has been the chairman of the department and the training program director.

Since 2010 his focus is now away from management and more to clinical work, teaching and research in neurosurgery. The Neurosurgical Centre Nijmegen (NCN) is a bilocation centre located at Radboudumc and the Canisius-Wilhelmina-Hospital (CWZ), a large general hospital in Nijmegen.

Not only a lecturer at the University of Twente, Enschede for Technical Medicine since 2004, he currently sits as President of the EANS (European Association of Neurosurgical Societies), Chairman of the Committee of Medico-Legal Expertise, Chairman of the Consilium Neurochirurgicum and member of the Accreditation Committee of the NVvN (Dutch Neurosurgical Society).

He holds multiple memberships including the AANS, CNS, EANS, European Skull Base Society, Nederlandse Vereniging voor Neurochirurgie (Dutch Neurosurgical Society), Deutsche Gesellschaft für Neurochirurgie (German Society for Neurosurgery), Nederlandse Vereniging voor Schedelbasischirurgie (Dutch Society for Skull Base Surgery) and the Academia Eurasiana Neurochirurgica. Moreover, he is the Medical Advisor for Nederlandse Hypofyse Stichting (Dutch Foundation of Pituitary Diseases) and has been the delegate for the Netherlands in the EANS Training Committee for ten years and he is also the delegate for the Netherlands at the WFNS.

While co-founder and member of the editorial board for the journal 'Minimally Invasive Neurosurgery' for many years and now for 'Innovative Neurosurgery', he likewise is an active reviewer for several journals including Neurosurgery, Journal of Neurosurgery, Central European Neurosurgery, Clinical Neurology and Neurosurgery, Neurosurgical Review, Acta Neurochirurgica, to name a few. He has authored two books, 21 book chapters, more than ninety peer-reviewed scientific publications and given more than 400 (international) lectures and presentations.

THE MEDICO-LEGAL ASPECTS OF ALLEGED TRAUMATIC DISC HERNIATION

André Grotenhuis

Radboud University Medical Centre, Department of Neurosurgery, Nijmegen, Netherlands

In the past two decades there has been an increasing demand for neurosurgical expertise by courts and insurance companies and one of the most common questions is that of the relationship between an accident and a disc herniation. Although there is much to be found in the literature, most neurosurgeons still rely on the criteria according to Junghanns or Breslau, which were formulated in the late fifties of the last century. While it is true to say that an accident can never lead to an isolated injury of a healthy intervertebral disc without accompanying osseous or ligament injury, it is not adequate to rule out any connection between the accident and herniation in advance solely based upon this assumption. As disc degeneration occurs already at early age, one may assume that this was already present in many people at the time of an accident. But very much of the visible disc degeneration at imaging is completely asymptomatic. With MRI, we are able to assess the condition of the discs and this should be taken into account in the assessment whether or not a trauma is an essential factor in a herniation becoming symptomatic. If an MRI scan is made within a period of six months after the accident, one should weigh the findings in evaluating whether the trauma has attributed to the demonstrated herniation in a relevant way or not. If the herniated fragment of the disc and the disc itself has still high intensity on T2, it will mean that at the time of herniation this was more or less a healthy disc and trauma has most probably attributed essentially to the occurrence of the herniation, while if the herniated fragment and the disc itself has a low intensity, it is an already advanced degeneration of the disc and the relevance of the trauma is less in the occurrence of herniation. Case examples will be discussed during the presentation.



Prof. Dr. med. Jürgen Meixensberger

President of the “German Society of Neuro-Intensive Care”
Director of the Department of Neurosurgery, University Hospital Leipzig, Germany

Since April 2001 Prof. Dr. med. Jürgen Meixensberger is Professor of Neurosurgery and Director of the Department of Neurosurgery, University Hospital Leipzig, Germany.

He is also President of the “German Society of Neuro-Intensive Care” (2015–2017), Scientific board member of CURAC (since 2011) and Vice dean of “Medical Education” at the Faculty of Medicine at Leipzig University (2013–2016).

As for his editorial functions Prof. Meixensberger is Editor of “Neurochirurgie Scan, Notfallmedizin”, Member of Editorial board: “International Journal of Computer Assisted Radiology and Surgery (CARS)” and Member of Advisory board: “Journal of Neurological Surgery” and Advisory board: “Neurosurgery Research”

MULTIMODAL NEUROMONITORING: POSSIBILITIES AND IMPACT ON TREATMENT OF SEVERE TBI PATIENTS

Jürgen Meixensberger

Department of Neurosurgery, University Hospital Leipzig, Germany

Prevention of secondary brain damage after initial primary brain injury is an important goal in treatment of traumatic brain injury (TBI) to improve the individual prognosis of every severe ill trauma patient. Nowadays different invasive continuous bedside monitoring tools are available at the ICU to unmask critical cerebral impairment following TBI. They may help to guide therapy avoiding cerebral insults leading to further secondary brain damage and poor prognosis.

Besides monitoring of intracranial pressure (ICP), continuous assessment of calculated cerebral perfusion pressure (CPP) is part of basic neuromonitoring in severe TBI. In addition, advanced neuromonitoring includes continuous assessment of cerebral oxygenation e.g. using local brain tissue monitoring (ptiO₂) with or without temperature measurement to detect episodes of cerebral insults. Further metabolic disturbances could be detected by local cerebral microdialysis. However changes in metabolic parameter like lactate, pyruvate or glutamate should be judged together with all other parameters like ICP, CPP and brain tissue oxygenation in a multimodal setup. At least monitoring of cerebral autoregulation using e.g. pressure reactivity index (PRX) allows detection of impaired brain pathophysiology and is helpful to target optimized individual cerebral perfusion pressure during time course after TBI.

In summary there is some evidence that extended neuromonitoring can help to identify e.g. optimal patient specific daily CPP, guide oxygenation and ventilation as well as optimal timing of decompressive craniotomy.



Dr Verena Klamroth-Marganska

Department of Health Sciences and Technology
Institute of Robotics and Intelligent Systems
ETH Zurich

Dr Verena Klamroth-Marganska is Senior Scientist at ETH Zurich, Department of Health Sciences and Technology, Institute of Robotics and Intelligent Systems

Verena Klamroth studied Human Medicine at Freie Universität and Humboldt-Universität in Berlin, Germany. She received her doctoral degree from Westfälische Wilhelms-Universität Münster, Germany in 2004 for the investigation of the variation in the number of TSPY gene copies in the male genome.

She gained medical experience in Spain (Universidad Computense de Madrid), the U.S. (Tripler Army Medical Center, HI) and England (Pilgrim Hospital, Boston). From 2000 to 2006, she worked as a Clinical Geneticist at the Universitätsklinikum Münster - Institute of Human Genetics - and from 2006 to 2007 as intern in the Department of Neurology, MEDIAN KLINIK Berlin.

Verena Klamroth joined the SMS team in April 2008 as a medical advisor and leader of a clinical study with the robot ARMin III.

THE CYBATHLON - MOVING PEOPLE AND TECHNOLOGY


Verena Klamroth-Marganska^{1,2}, Robert Riener^{1,2}

1) Sensory-Motor Systems (SMS) Lab, Institute of Robotics and Intelligent Systems (IRIS),
ETH Zurich, Switzerland”

2) Spinal Cord Injury Center, Balgrist University Hospital, Medical Faculty,
University of Zurich, Switzerland

The Cybathlon is a one-day championship for athletes with disabilities who use advanced assistive devices including robotic technology. On October 8, 2016 the first-ever Cybathlon is organized by the ETH Zurich, Switzerland. Athletes will compete in six disciplines using modern assistive technologies: climbing stairs in the latest wheelchairs or proving skill using most advanced prostheses. Devices have been developed at some of the world’s leading technical universities. Each winning team will get two medals - one for the pilot and one for the developer. Eighty teams from 24 different countries ranging from the US to Japan and Iceland to Australia registered for the Cybathlon and it will be broadcast live on television and via the internet. The event should increase the awareness and uptake of advanced technical systems and remove barriers between people with disabilities, the public and technology developers. Furthermore, it will provide a platform for the development of novel assistive technologies that are useful for daily life.

The EMN conference is taking place only a few days after the Cybathlon, and EMN participants will be the first scientific audience to get an overview of the event.



Prof. dr Klaus von Wild

Honorary President of EMN

Professor (apl) of Neurosurgery Medical Faculty Westf. Wilhelms-University Münster
 Prof. of Neurorehabilitation and Re-engineering of brain and spinal cord lesions at the
 International Neuroscience Institute Hannover - University Magdeburg, Germany
 Professor honoris causa Physical Medicine & Rehabilitation Al Azhar University, Cairo
 Visiting Consultant China Rehabilitation Research Centre, CRRC, Beijing, PRCh;
 Visiting Consultant Armed Force and Rheumatic Rehabilitation Hospital El Agouza Military
 Hospital and Rehabilitation Centre, Cairo, Egypt

Dr von Wild, as neurosurgeon in charge, personally performed more than 5000 major operations of all kind on central and peripheral nervous system lesions by applying state of art surgical techniques, e.g. minimal invasive, endoscopic & stereotactic procedures, interdisciplinary reconstructive nerve grafting, skull base approaches and in spine pathologies.

Dr. von Wild was the organizer and acted as Congress President or Co-Chairman of numerous international and national congresses, symposia, workshops and teaching courses on functional reconstructive neurosurgery, neurotraumatology, neurorehabilitation, and neural repair by propagating a multidisciplinary access for scientific exchange and clinical application following acute and chronic traumatic damage of the brain, spinal cord, and peripheral nerves.



Prof. Peter Hutchinson

Professor of Neurosurgery
NIHR Research Professor
Director of Clinical Studies Robinson College
University of Cambridge
EANS Secretary

Peter Hutchinson BSc (hons), MBBS, PhD, FRCS (Surg Neurol) holds a Readership and Academy of Medical Sciences / Health Foundation Senior Surgical Scientist Fellowship within the Department of Clinical Neurosciences, University of Cambridge and Honorary Consultant Neurosurgeon post at Addenbrooke's Hospital. He has a general neurosurgical practice with a sub-specialist interest in the management of neuro trauma.

He has a research interest in traumatic brain injury (PI of the MRC / NIHR funded www.RESCUEicp decompressive study), multimodality monitoring in neuro-critical care and functional imaging. He was the previous chair of the EANS Research Committee, has co-authored over 150 publications and is joint editor of the book 'Head Injury – A Multidisciplinary Approach'.

He is currently chair of the Society of British Neurosurgeons Neurotrauma Group and a member of the SBNS council, Director of Clinical Studies and Fellow at Robinson College Cambridge, and Deputy Chief Medical Officer for the British Grand Prix.

Prof. dr Klaus Von Wild lecture

EUROACADEMIA MULTIDISCIPLINARIA NEUROTRAUMATOLOGICA TRIBUTE**NEW HORIZONS IN BRAIN TRAUMA MANAGEMENT**

Peter Hutchinson

Division of Academic Neurosurgery, University of Cambridge, UK

Brain trauma is the leading cause of death and disability in young adults. In Europe, 2.5 million people suffer a traumatic brain injury (TBI) each year, 1 million are admitted to hospital and 75,000 die. An estimated 7.7 million people live with a TBI-related disability. While advances in management including the introduction of advanced trauma life support, NICE head injury guidelines, and protocol driven therapy have improved outcome major gains are still needed in terms of increasing our understanding of the pathophysiology of this heterogeneous condition and defining and optimising treatment strategies. In the past there has been a failure to translate advances in pre-clinical studies into enhanced patient treatment despite many randomised controlled trials. We therefore need to better understand the pathophysiological mechanisms in humans and undertake improved clinical studies relevant to the heterogeneity of this condition.

The fundamental pathophysiology of TBI evolves from both primary insult (occurring at the ictus) and secondary insults (particularly hypoxia and hypotension). The result of both processes is brain swelling within the tight confines of the skull resulting in increase in intracranial pressure (ICP), reduction in cerebral blood flow, cerebral hypoxia, energy failure with cerebral oedema and further brain swelling culminating in poor outcome for the patient. The goal of intensive care and surgical treatment is to intercept this vicious cycle.

Novel approaches are required with the implementation of technology to improve our interrogation of the pathophysiology and to guide treatment. Such technology includes multimodality monitoring techniques (ICP, autoregulation, cerebral blood flow, oxygenation, and metabolism) and advanced imaging (MRI and PET). Clinical trial design requires refinement with randomised studies of medical and surgical interventions running in parallel with other approaches e.g. comparative effectiveness research. Overall, treatment protocols need to be flexible to meet the requirements of individual patients giving them the best chance of good quality survival.

This lecture will present an update and new horizons in terms of monitoring technology and clinical trials.

Friday, October 21st

ABSTRACTS

PLENARY SESSION 1

Hall 1

HEAD TRAUMA MANAGEMENT IN INFANTS (0 -1 YEAR OLD) (CLINICAL DATA, NEUROIMAGING FINDINGS, NEUROTRAUMA SCALES, MANAGEMENT, FOLLOW UP AND GLOBAL OUTCOME)

Prof. A.V. Ciurea MD., PhD.^{1,3}, Aurel Mohan MD., PhD.², Ionut Luca-Husti MD.¹,
Vincentiu Seceleanu MD., PhD.⁴

- 1) Sanador Medical Center – Bucharest, Romania,
- 2) Emergency County Hospital Bihor – Oradea, Romania,
- 3) Medicine and Pharmacy University „Carol Davila” Bucharest, Romania,
- 4) Emergency County Hospital Sibiu – Sibiu, Romania

Introduction: Traumatic pathology in the first 3 years of life is completely different by comparison with that of adults. Raimondi (1998) highlighted the importance of the differences between adult and pediatric pathology concluding that “children are not young adults”. During the early childhood, there is a specific traumatic pathology linked primarily to early stages of learning gait, with frequent traumas, usually minor, determined by falls from the same level, without significant posttraumatic injury of the cervical spine. In patients younger than 1 year, etiology is related to traumatic episodes, mostly minor injuries, by falls from another level (usually from low heights, from bed or from trays) or due to accidental impact trauma. There are also cases in which traumatic head injuries are more complex. Sometimes, there are more severe cases represented frequently by falls from great height, road accidents, assaults etc.

Material and method: The authors conducted a study over a period of 16 years (between 1 January 2000 and 31 December 2015). They included in their study 509 patients, aged between 0 and 3 years, from the Pediatric Neurosurgery Department from Bagdasar-Arseni Hospital and Sanador Medical Center from Bucharest. Among them, 111 patients (21.8%) were under 1 year of age. All patients (0-1 year) had at least 24 hours hospitalization for monitoring their progress and 52 patients of them (46.8%) were diagnosed with at least one traumatic injury (fracture or intra- and extracranial hemorrhagic lesions) visible on imaging tests performed. The clinical status of patients is dominated by palor, irritability, agitation, crying, bulging fontanel and seizures. Seldom are noticed motor deficits, that are seen in case of posttraumatic lesions located near motor areas. This behavior is according to the main traumatic lesion seen at this age: Posttraumatic cerebral edema. Plain radiological examinations could serve only as screening immediately posttraumatic (can highlight a fracture) but requires further examination by CT scan to view a possible associated intracranial injury. X-ray add more exposure with a minimal efficiency without a major clinical utility. Imaging examinations type MRI are less useful because that cannot highlight efficiently a posttraumatic lesion. There are at least three limits of this technique: a longer examination time, the need to sedate the patient and the poor accessibility in emergency situations. The authors emphasize that the evolution of this kind of patients can be unpredictable and requires an unified approach for an appropriate management, in order to maximize the potential of favorable course due to higher functional resources that this group of patients could have. To establish the consciousness state of patients, the authors use a variant of the Glasgow Coma Scale (GCS) adapted to this age - Pediatric Glasgow Coma Scale (PGCS). As an example, they present an illustrative case with an evolution that proved to be favorable without affecting child development.

Conclusion: Prevention is the key to good results in terms of therapy of cranio-cerebral traumas, “events” that can cause incapacitating injuries in this age group. Any brain injury must be carefully observed and pursued clinically and by CT scans imaging.

Keywords: traumatic brain injury, infants (0-1 year old), neurotrauma scale, GCS, PGCS, CT - scan, falls, accidental trauma, neurosurgery

CONCOMITANT CRANIOSPINAL TRAUMA

Andreas K. Demetriades FRCS
Consultant Neurosurgeon and Spinal Surgeon
Western General Hospital, Edinburgh, United Kingdom

There are a limited number of studies addressing the presence of concomitant cranial and spinal trauma. This talk will address the Epidemiology of spinal injury in the presence of Traumatic Brain Injury (TBI), and try and differentiate between the coexistence of TBI with Spinal Cord Injury (SCI) versus the coexistence of TBI with spinal column injury.

The clinical assessment, investigations for and diagnosis of spinal trauma in TBI will be discussed, as will be the treatment of craniospinal injury in polytrauma.

RECONSTRUCTION OF THE CALVARIAL DEFECTS USING 3D CAD-CAM CRANIOPLASTY

Vitanovics D, Banczerowski P.

National Institute of Clinical Neurosciences,
Departement of Spinal Neurosurgery, Budapest, Hungary

Objective: In our practice 42% of cranial defects are results of trauma. The defect must be covered within reasonable period of time usually after 4-6 week given the fact that the replacement of bone improve the brain circulation. Numerous of surgical techniques and materials are available to perform cranioplasty. Due to favorable properties we chosed ultra high molecular weight polyethylene as a material. In this presentation the authors show a procedure which allows tailore-made artificial bone replacement using state of art medical and engineering techniques.

Methods: between 2004 and 2016, 26 patients were operated on cranial bone defect because of trauma and a total of 30 3D custom-designed implants were implanted. The 3D design was made using the original CT images (1 mm resolution) and with design program. Computer controlled lathe was used to prepare a precise-fitting model. During surgery, the defect was exposed and the implant was fixed to normal bone using titanium plates and screws. All of our patients had control CT at 6 weeks, 6 and 12 months after surgery and at the same time neurological examination.

Results: 30 polyethylene implants were inserted. No intraoperative implant modifications had to be made. Each of the 30 implant exactly matched the bone defect proved by CT scan. No one of our patients reported aesthetic problems and we did not notice any kind of aesthetic complication. We had short term complication in three cases due to cranioplasty, and in one case the implants had to be remove due to empyema developed one year after the defect coverage.

Conclusion: Polyethylene is in all respects suitable for primary and secondary cranioplasty. Combined with 3D CAD-CAM method excellent aesthetic and functional result was achieved. Proper preoperative preparation is important.

**IS A SO-CALLED MILD WHIPLASH INJURY ALWAYS A MILD
CERVICAL SPINE INJURY?
A STUDY WITH MOTOR EVOKED POTENTIALS**

Jacques De Reuck

Department of Neurology, University Hospital, Ghent, Belgium

Background: Common whiplash injuries of the neck remain an enigma as the relation between the accident and the neck injury is frequently unclear. It is common believe that psychological problems and pending litigation influence the persistence of complaints in the absence of objective clinical and imaging findings.

Patients and methods: 20 consecutive patients with persistent neck pain, headache and paraesthesias in the upper extremities for more than 6 months due to an acceleration-deceleration of the neck during a motor vehicle collision were studied. Magnetic resonance imaging (MRI) revealed only mild disc bulging C5-C6 in 8 patients. No hyper-signals were seen within the cervical spinal cord on T2 weighted images. Magnetic stimulation (MEP) of the contralateral pre-motor and motor cortex at the level of the skull (cortical) and of the homolateral magnetic cervical root stimulation (peripheral) were performed with registration at the level of the biceps brachii muscle (C5-C6) and in the abductor digiti minimi muscle (C7-C8-Th1).

Results: 13 patients had prolonged central MEPs at the level of C7-C8-Th1 in 85% and of peripheral MEPs at the level of C5-C6 in 38%. Normalisation of the MEPs after one year occurred only in 40% of them. The patients with prolonged MEPs were on average older than those with normal MEPs.

Conclusions: No conclusions can be made concerning the frequency of MEP disturbances at the level of the cervical spinal cord as there is a bias in the selection of the patients in this study. MEP examination is more sensitive than MRI to detect mild cervical spinal cord injury. SSEP and BAER are less useful to detect spinal cord lesions. Disturbed MEPs are influenced by age. It should be recommended to perform MEPs in patients with persistent complains after whiplash injury, even in the absence of visible structural lesions on neuroimaging.

COMMON SENSE AND SCIENTIFIC KNOWLEDGE IN NEUROTRAUMATOLOGY: CONTRADICTING OR MUTUALLY COMPLEMENTING?

Leonid B. Likhterman, Alexander D. Kravchuck,
Vladimir A. Okhlopkov, Natalia A. Pestovskaya
N.N.Burdenko Neurosurgery Research Institute, Moscow, Russia

Introduction: Making a decision to choose this or that surgical technique based on the common sense (i.e. “linear” decision making) often turns to be risky in clinical neurotraumatology. Use of principally different approaches to treating brain pathology provides most favourable outcomes, if based on the scientific knowledge (i.e. “non-linear” decision making).

Material and methods: About 5000 verified cases of acute head injury and its sequelae treated at Burdenko neurosurgical institute are reported. There were used different neuroimaging modalities: CT, MRI and Angiography, and patients’ follow-up was thoroughly studied.

Results and their discussion: Let us consider the situation based on the example of posttraumatic chronic subdural hematomas (CSH). The common sense suggests a radical problem solution – an instant and complete CSH capsule resection by using extensive osteoplastic trepanation. At the same time, it may cause serious complications, with mortality reaching 12-18 %. However, we’ve proved that the main cause of CSH existence is hyperfibrinolysis of its content as a result of accumulation of fibrin degradation products. Hence, instead of performing a major surgery, it is quite sufficient to use twist-drill rinsing of the hematoma cavity by physiological solution in order to launch the process of CSH sanogenesis. According to MRI findings, CSH with its capsule was totally resorbed in 1,5-3 months. Usually, a 5-year follow-up showed good recovery of patients. Mortality made up 1% (due to extracranial problems).

Conclusion: Hippocrates’ key principle “First, do no harm” remains vitally important in modern medicine, playing in each particular situation either on the part of common sense or scientific knowledge. These are two mutually complementary segments of clinical thinking of a neurotraumatologist, as any other doctor.

OUTCOME FROM MILD TRAUMATIC BRAIN INJURY - PREDICTING VALUE OF MRI

Vuleković P, Karan M, Cigić T, Papić V, Đilvesi Đ, Krajčinović N, Horvat I,
Jelača B, Azaševac A, Golubović J
Clinic of Neurosurgery, Clinical Centre of Vojvodina, Novi Sad

Introduction: Our understanding of mild traumatic brain injury (mTBI) significantly changed after introduction of MRI in the field of neurotraumatology. Place of MRI in diagnostic algorithm and predicting value in outcome assessment after mTBI is not clearly defined.

Objectives: The aim of our study was to assess value of early MRI examination in patients with mTBI in order to predict overall outcome and development of neurobehavioral deficits

Methods and Materials: In two years period we included 34 patients with mTBI who had normal initial CT scan at admission. We prospectively analyzed clinical data, early MRI (72 hours) data and results of neuropsychological assessment one month and 6 months after injury. During the MRI examination T1, T2, FLAIR, T2*,SWI and DTI sequence has been performed. Battery of neuropsychological tests and questionnaires has been employed in order to detect presence of cognitive impairments, depressive disorders and assess quality of life.

Results: All of 34 patients had amnesia, (76%) had headache and (56%) vegetative disturbances. Most common causes of injury were traffic accidents, fall from heights and assaults respectively. 40% of patients had some form of lesions discovered by MRI examination and most of them were on SWI sequence. Only specific forms of learning and memory difficulties have been found in patients with lesions on MRI comparing with patients with normal MRI findings ($p<0,032$). No difference in presence of depressive disorders and in quality of life has been found between groups.

Conclusion: MRI examination is more sensitive, but expensive and less available method comparing to CT scan. MRI alone, in this point of time, is not sufficient method for prediction of outcome after mild TBI but certainly has a role in further investigations of mTBI. Forthcoming studies using state of the art MRI possibilities can provide new useful insight in mTBI.

EPIDURAL HEMATOMAS OF POSTERIOR FOSSA

Radulović D., Joković M., Đurović B., Bogosavljević V,
Cvrkota. , Ilić R. Jovanović N, Aleksić V
Clinical center of Serbia, Clinic for Neurosurgery, Belgrade, Serbia

Introduction: Posterior fossa epidural hematomas represent 7-4 % of all traumatic intracranial epidural hematomas. They are most frequently encountered postraumatic mass lesions in the posterior fossa.

Objective: The aim of this study was to identify clinical features that could lead to the early diagnosis of posterior fossa epidural hematoma.

Methods: During the 25-th years period of time (between 1991 -2015), 31 patients with epidural hematoma of posterior fossa were operated at the Clinic for neurosurgery in Belgrade. Clinical course, neuroradiological investigations, and the results of surgical treatment of the patients with posterior fossa epidural hematomas were analyzed retrospectively.

Results: Almost two thirds of patients were younger than 16 years of age. In 21 cases injury was caused by a fall, in 8 cases by a traffic accident, and 2 by assault. Clinical course was subacute or chronic in two thirds of the patient. Admission GCS was 7 or less in 10 patients, 8-14 in 16, and 15 in 5 injured patients. Linear fractures of the occipital bone was radiographically evident in 22 patients, but in was intraoperatively encountered in all patients except for a 4-year old child. All the patients were operated through suboccipital craniotomy. Four injured patients who were preoperatively comatose had lethal outcome. Postoperatively 27 patients were with sufficient neurological recovery.

Conclusion: Posterior fossa epidural hematoma should be suspected in cases of occipital injury, consciousness disturbances and occipital bone fracture. In such cases urgent CT scan is mandatory. Early recognition, early diagnosis and prompt treatment are crucial for good neurological recovery after surgery.

Key words: head injuries, epidural hematoma, neurological manifestation, survival

Friday, October 21st

ABSTRACTS

PLENARY SESSION 2

Hall 1

THE RISK FACTOR OF BLUNT CEREBROVASCULAR INJURY IN PATIENTS WITH CERVICAL SPINE INJURY: THE SIMC EXPERIENCE

Masahiro Okuma, Hiroyuki Nakajima, Toshiki Ikeda, Hiroki Uramaru, Kouichi Uramaru, Akio Teranishi, Ririko Takeda, Yuichiro Kikkawa, Hiroki Kurita
Departments of Cerebrovascular Surgery,
International Medical Center, Saitama Medical University, Hidaka, JAPAN

Background & Purpose: Despite the recent advancement in the diagnosis of blunt cerebrovascular injury (BCVI), the population at risk remains to be elucidated. Literatures suggested that BCVIs occur in approximately 1% of all trauma patients and remain as potentially fatal complication. The purpose of this study was to predict the risk factor relevant to BCVIs and to standardize the screening protocol.

Method: Medical charts of 92 patients with cervical spine injury (CSI) transferred to our institution from April 2007 to March 2015 were retrospectively reviewed. The evaluation of BCVI was available in 40 patients with magnetic resonance angiography (MRA) or multi-detector computed tomography angiography (MDCTA). The results were statistically analyzed by logistic regression to detect the risk factor for BCVI, blunt carotid artery injury (BCAI), and blunt vertebral artery injury (BVAI).

Results: BCVI was observed in 10 patients (25%; BCAI 2, CVAI 9, both 1). There were no significant difference in patients' characteristics, cause of injury, and neurological status (Franckel's grading), and presence of traumatic intracranial hemorrhage between BCVI and non-BCVI patients. Univariate analyses disclosed foramen transversarium fracture, facet fracture and dislocation of vertebral body (more than 5mm) were significantly associated with BCVI. But independent predictor on multivariate analysis was dislocation of vertebral body.

Conclusions: Patients with dislocation of vertebral body are at high risk of BCVI and should be screened with MRA and/or MDCTA.

IS IT TIME TO CHANGE OUR CONVENTIONAL OSMOTIC DIURETICS IN PATIENTS WITH INTRACRANIAL HYPERTENSION?

Santiago Lubillo, University Hospital of Candelaria,
Intensive Care Department, Tenerife. Canary Islands, Spain

Intracranial hypertension (ICH) is the most important modifiable factor with negative predictive value in traumatic brain injury patients. Osmotherapy is the most important first-level specific measure in the treatment of ICH. Mannitol 20%, and 3, 7.5, 10, and 23% hypertonic sodium chloride (HSC) are the most commonly used osmotic agents in the neurocritical care setting.

Two decades of experimental and human investigations have convincingly shown that lactate stands as a major actor of cerebral metabolism. Glutamate-induced activation of glycolysis stimulates lactate production from glucose in astrocytes, with subsequent lactate transfer to neurons (astrocyte-neuron lactate shuttle). Based on these pathophysiological concepts, over the past few years, half-molar sodium lactate has been introduced as a new osmotic agent to be administered in the critically ill. Furthermore, hypertonic sodium lactate (HSL) could prevent hyperchloremia, as well as its adverse effects such as hyperchloremic acidosis, systemic inflammation, and acute kidney injury, although there are studies where these complications are infrequent with conventional osmotic diuretics especially with hypertonic saline. Half-molar sodium lactate would also have a more potent and long-lasting effect, decreasing intracellular osmolarity and inhibiting neuronal volume control mechanisms. Pioneering research in patients with traumatic brain injury have shown that HSL has a more significant effect than mannitol for the prevention and control of ICH.

More recently, the use of vasopressin antagonists (the vaptans) has shown some encouraging preliminary results to limit cerebral edema and to control ICH. The objective of this lecture is to analyse and make known new solutions in osmotherapy for the neurocritical patient. However, future research is necessary to corroborate or not these promising results.

PERCUTANEOUS TRANSPEDICULAR FIXATION IN SPINAL TRAUMA

Gabrovsky N., Laleva M., Velinov N., Uzunov K., Ilkov P., Gabrovsky St.
University Hospital Pirogov, Department of Neurosurgery, Sofia, Bulgaria

Introduction: We present our experience with a minimally invasive percutaneous technique in treating traumatic pathology in the thoracolumbar segment of the spine.

Material and methods: For the period 04.2013-03.2016 in the Dept. of Neurosurgery in University Hospital Pirogov, a percutaneous transpedicular fixation alone or in combination with decompression was performed in 79 patients with traumatic fractures of the thoracolumbar spine. The selection of cases for doing a percutaneous technique was performed according to the findings on the imaging data, hence presence of a compressive or burst vertebral fracture without a significant stenosis of the vertebral canal.

Results: We treated 79 fractured vertebrae in 79 patients (24 thoracic and 55 lumbar vertebrae). Long segment transpedicular spinal fixation was the preferred method of choice for treatment of 20 fractures. In all cases the applied percutaneous transpedicular stabilization using the capacity of the instrumentation for distraction and fixation lead to a reduction of the duration of surgery and consequently to an earlier rehabilitation and lack of complications during a shorter period of hospitalization. The clinical and imaging follow-up demonstrated good short term results and lack of technique associated complications. The follow up of the first patients included in our series for a period of 24 months suggests also good long term results.

Conclusion: The minimally invasive transpedicular percutaneous fixation technique is a reasonable and plausible alternative to the standard technique and allows an adequate decompression in a promising stability.

MANAGEMENT OF CERVICAL SPINE AND SPINAL CORD INJURIES

Prof. Dr. Ihsan Solaroğlu
Koç University, Department of Neurosurgery, Istanbul, Turkey

Traumatic spinal cord injury (TSCI) is a catastrophic event that is sudden and unexpected and exacts an extensive burden on the injured individual, their family and carers, and society as a whole. TSCI in developed and developing countries primarily affects young males, and in developed countries, due to an ageing population, males and females over the age of 65 years. Although the overall prevalence of spine injury is not known, the range of reported global prevalence is between 236 and 1009 per million. Management of traumatic cervical spinal cord injuries with all evidence-based guidelines is crucial in neurosurgical practice to improve overall mortality and morbidity of the patients. In this lecture, updated guidelines for the management of acute cervical spine and spinal cord injury will be discussed to help clinicians make important decisions in the care of SCI patients.

INDICATION FOR ICP MONITORING IN BRAIN INJURY

Mauer Uwe Max

Armed Forces Hospital, Department of Neurosurgery, Ulm, Germany

Introduction: Monitoring of intracranial pressure (ICP) has been recorded with increasing frequency in the acute management of comatose patients after head injury. The method has been implemented in several national and international guidelines. Which evidence do we have for ICP monitoring?

Method: Analysing actual literature and guidelines.

Results: There is no evidence from a prospective randomised controlled study that ICP monitoring has a relevant favourable effect on outcome. Several recent cohort studies and clinical practice, however, indicate its practical value in neurosurgical intensive care. The practical benefit for the patient from thus invasively obtained data is controversial. Doubtless there also relevant risks, like haematoma and infection.

Conclusions: For pathophysiological reasons the recording of ICP appears useful, since the clinical monitoring of many cerebral functions is limited in the comatose and sedated patient and may give early warning of an impending herniation from swelling or intracranial hematomas and thus may allow for preventive measures in time. But physicians must be aware of limitations and risks.

THE INFLUENCE OF ANTICOAGULATION THERAPY ON TRAUMATIC BRAIN INJURY PATIENT OUTCOME

Sajko T, Vrban F, Rotim K

Department of Neurosurgery, Sestre milosrdnice University Hospital Center, Zagreb, Croatia

Aim: A prospective analysis of the effect of anticoagulation therapy on the traumatic brain injury and treatment outcome in patients with acute traumatic intracranial haematoma

Materials and methods: Patients on anticoagulation therapy admitted at the Department of Neurosurgery Sestre milosrdnice UHC due to traumatic brain injury were enrolled in a prospective study that started January 2016. The post-injury clinical condition (Glasgow Coma Scale), incidence of haemorrhagic contusions, intracranial haematoma progression, particularly when surgery was indicated, incidence of re-operations and treatment outcome (Glasgow Outcome Scale - GOS) were the study parameters. The control group included patients with post-traumatic intracranial haematoma with normal coagulation.

Results: The median age and initial status evaluated by the Glasgow Coma Scale were similar in the anticoagulated patients and the control group. A comparison of anticoagulated and normal coagulation patients did not show any statistically significant differences in the incidence of patients operated on, in the incidence of haemorrhagic contusions requiring surgery as a marker of the severity of brain parenchyma injury, intracranial haemorrhage progression with time, particularly when requiring surgery, and the rate of re-operations

Conclusion: The results did not confirm any statistically significant adverse effects of anticoagulation therapy on the severity of traumatic brain injury outcome and risk of intracranial bleeding progression.

EFFICACY OF DREZ LESIONING IN MANAGING PAIN FOLLOWING SPINAL CORD INJURY

Milan Spaic, MD, MSc, DSc

Department of Neurosurgery, University Clinical Centre Zemun, Serbia

Paraplegia due to spinal cord trauma is one of the most devastating injuries in human pathology. Even more severe than the paraplegia itself is the one accompanied with the persistent, incapacitating, posttraumatic neuropathic chronic pain that occurred in 10 - 30% of injured. The loss of the motoric transmission is the one and obvious sequel of the injury. However, the loss of the sensory inflow is the other, although less obvious, consequence of such injury termed as the process of deafferentation. The interruption of the sensory inflow - results in readaptation of the previously balanced and integrated sensory system that is still not well understood. Some of those changes might result in its mysterious consequence – chronic, unbearable neuropathic pain that could have different forms of the expressions with respect to its rhythm, topography, and quality. The understanding of the underlying neuropathic mechanism of the pain is being of utmost importance when consider the DREZ operation – performed in the cord dorsal horn that is hazardous surgery that could successfully relieve pain as well as it might failed.

The operation could be successful only if it interrupts the neuropathic mechanism of the pain.

The prediction of the pain mechanism based on the subjective sensory pain expression proved to be of utmost importance for the codifying the indications for DREZ operation.

It appears that different pain patterns have its separate underlying neuropathic mechanism probably related to the disturbed of either cord sensory transmission system or supraspinal, proximal thalamocortical sensory transmission structures.

The pain of intermittent rhythm and mechanical sensory expression on confined territory is the pain pattern that proved to be the most responsive to DREZ surgery.

The patophysiology of the pain, its clinical expressions and indications for the DREZ Operation are discussed.

Friday, October 21st

ABSTRACTS

MAIN SESSION 1

Hall 1

WHAT AND WHY SHOULD BE MONITORED IN SEVER TRAUMATIC BRAIN INJURIES?

Zsolt Kopniczky

Central Hospital of Békés County, Neurosurgical Department, Gyula, Hungary

There is an abundance of monitoring protocols and methods to follow in case of severe traumatic brain injuries (TBI). Almost all of them has been challenged during the last couple of years, which often causes confusion in the clinical practise, in the communication with fellows of other subspecialties and also in teaching.

The lecture attempts to give an overview of modalities involved in monitoring TBI patient and to set up a practical framework into which the different monitoring methods can be inserted and appreciated. Any data on their own can only be helpful if they allow to understand some part of the pathophysiological events. Also, these abnormalities are interdependent and physicians can get easily confused about how to interpret the data and what to treat.

Monitoring techniques might be prioritised based on their reliability and feasibility. Everyday neurotraumatological practise and teaching of the new generation of neurosurgeons are all begging for sound, practical guidelines regarding monitoring protocols. „Controversies” of different clinical studies need to be reassessed and sound, coherent messages should be agreed.

NEUROMONITORING IN CRITICAL CARE UNIT

Branko Milaković

Clinical Centre of Serbia, Clinic for Neurosurgery

Department of Anesthesiology and Reanimatology, Belgrade, Serbia

Excited and agitated patient presents itself as a significant therapeutic problem, whereas the possibilities for diagnosing and treatment of primary cause of disease (injury) are diminished, inasmuch as the real nature of detected situation could be hidden by symptomatic treatment of agitation itself.

Irrespective of impossibility to measure the awareness directly, we are capable to assess it reliably, in acceptable manner, by the analysis of neurophysiological information in the form of an electroencephalographic signal (EEG). Today such form of analysis has been made possible by: spectral analysis of EEG signal – bispectral index (BIS), or evoked potentials – especially brainstem auditory evoked potentials (BAEP).

The intracranial pressure (ICP) has been determined by the interaction of brain parenchima, cerebral blood volume and cerebrospinal fluid volume. Increased ICP is the most essential single factor influencing the clinical features, morbidity and mortality of neurosurgical patient. The intracranial hypertension (ICH) could be defined as ICP greater than 20 mmHg with no tendency for return to normal values.

The monitoring of CNS functions, in the CCU, was implemented by using: ICP monitoring, BIS monitoring, NIRS monitoring (INVOS), and monitoring of evoked potentials – motor (MEP), and somatosensory (SSEP), upon occasion of determining the possible brain death.

Results: Our clinical results have been presented through case reports of patients whose awareness and a quality of applied treatment had been followed up by some of the continuous CNS monitoring techniques.

Conclusion: Continuous neuromonitoring, in CCU, could be applied, not only to obtain the optimal treatment protocol, but to achieve the optimal balance between dose regimens of intravenous hypnotics and opiate analgesics, to benefit the diagnosis of neurological deterioration, as well as to help in differential diagnosis of systemic arterial hyper- or hypotension. The last but not the least benefit could be in using neuromonitoring techniques in diagnosis of brain death?

ANAESTHESIA FOR HEAD TRAUMA

S. Vicković^{1,2}, S. Maričić Prijić¹, S. Stanisavljević^{1,2}, A. Plećaš-Đurić¹, N. Ikonić¹

1) Department of Anesthesia, Clinical Centre of Vojvodina, Novi Sad, Serbia

2) Faculty of Medicine, University of Novi Sad, Novi Sad, Serbia

Traumatic brain injury (TBI) is a leading cause of death and disability worldwide. TBI is classified as mild (Glasgow Coma Scale 15 - 13), moderate (GCS 13 - 9), and severe (GCS < 8). TBI can be divided into primary and secondary brain injury. The primary injury is due to irreversible mechanical injury. Secondary injury leads to cerebral ischemia and results from raised intracranial pressure (ICP), hypotension, hypoxia, anemia, seizures, hyper- or hypoglycemia, hyper or hypocapnia and hyperthermia. The aim of management of severe head injury is preventing or minimizing secondary injury. Outcome can be improved by strategies that improve oxygen delivery to the brain and prevent cerebral ischemia. About one-third of patients with severe TBI need neurosurgical intervention.

Rapid treatment is crucial. Perioperative management should be a continuation of the resuscitation process already begun and an opportunity to correct pre-existing secondary insults. Surgery and anesthesia predispose the patient to additional risks such as hypotension because of blood loss or the effect of anesthetic agents. Management of anesthesia and choice of anesthetic agents have a significant influence on blood supply to the brain and, therefore, on neurological outcome. The priorities are to prevent hypoxia and hypotension. Support of cardiorespiratory function is, therefore, highly important when anesthetizing patients with TBI. Choice of anesthetic agent is determined by the extent of brain injury and intracranial pressure (ICP) elevation. Factors that should be considered when anesthetizing head trauma patients include the effects of anesthetic agents on the cardiac and respiratory systems, their effects on cerebral blood flow (CBF), ICP, and possible their neuroprotective benefits.

In conclusion, the goal of anesthesia is optimization of cerebral perfusion pressure (CPP) and prevention of intracranial hypertension, adequate anesthesia and analgesia, prevention of secondary insults by adequate oxygenation, normocapnia, and avoidance of hyper or hypoglycemia and hyperthermia.

THE SIMPLE INTERRUPTED SKIN SUTURE VERSUS THE RUNNING SUBCUTANEOUS SUTURE IN CRANIAL SURGERY

Prof. Yavor Enchev¹, MD, PhD, DrMedSci, MHA, FRCS(Eng), Pl. Trendafilov¹, MD, B. Iliev¹, MD, PhD, T. Kondev¹, MD, Ivan Dimitrov², MD, PhD, Assoc. Prof. T. Avramov¹, MD, PhD, Elena Zaharieva¹, MD, Martin Moinov¹, MD, MD, Simeon Georgiev³, MD, Stephanie Todorova¹

- 1) Clinic of Neurosurgery, University Hospital "St. Marina",
Medical University of Varna, Varna, Bulgaria
- 2) Clinic of Neurology, University Hospital "St. Marina",
Medical University of Varna, Varna, Bulgaria
- 3) Clinic of OMS, University Hospital "Alexandrovska",
Medical University of Sofia, Sofia, Bulgaria

Introduction. The type of skin suture in cranial neurosurgery has not been a subject of scientific studies.

Aim. The purpose of this study was to compare the conventional simple interrupted skin suture and the running subcutaneous suture in patients with primary cranial neurosurgical procedures. The comparison targeted the complication rate of wound healing (CSF leakage, wound dehiscence and wound infection), the term of hospital stay and the resulting cosmetic effect.

Materials and Methods. The study included all 842 patients which underwent primary cranial (infra- and supratentorial) neurosurgical procedure within the period of 4 years (January, 2012- December, 2015). These patients received cosmetic running subcutaneous suture. The age of the patients varied from 2 months to 88 years and male to female distribution was 492 to 350. The patient population was divided in 4 groups- 1) craniotomy with watertight dural suture; 2) craniotomy without watertight dural suture; 3) craniectomy with watertight dural suture; 4) craniectomy without watertight dural suture. The follow-up period was 3 months. The complication rate of wound healing, the term of hospital stay and the cosmetic effect were evaluated and compared with the literature data for the conventional simple interrupted skin suture.

Results. The complication rate of wound healing of the running subcutaneous suture is lower or equal with the complication rate of wound healing of the conventional simple interrupted skin suture. The term of hospital stay of the patients with the running subcutaneous suture is significantly shorter compare to these with the classical one. The cosmetic effect of the running subcutaneous suture obviously is surpassing the conventional one

Conclusion. The running subcutaneous suture outrival the conventional simple interrupted skin suture regarding the complication rate of wound healing (CSF leakage, wound dehiscence and wound infection), the term of hospital stay and the cosmetic effect.

Key words: Running subcutaneous suture, Simple interrupted skin suture, Comparison, Complication rate of wound healing, Term of hospital stay, Cosmetic effect.

PERIPHERAL NERVE INJURIES. STRATEGIES FOR RECONSTRUCTION

Lucian Fodor¹ MD, PhD; Horatiu Rotaru², M.D, PhD; Stefan Floria³ MD, PhD
Emergency District Hospital, Cluj Napoca, Romania

1) Department of Plastic Surgery

2) Department of Maxillo Facial Surgery

3) Department of Neurosurgery

Most of the severe extremities injuries are encountered during war time, but even in our regular days many accidents lead to the same problem. Upper limb injuries are the most common injuries present in the emergency room. Over time it was present an increasing rate of limb injuries, especially accidental ones. This increased rate can be attributed to modernization, and increased rate of violence. After war injuries, the most frequent causes of severe limb traumas are road traffic accidents followed by work accidents. The three mechanisms responsible for these type of injuries are: as a primary mechanism we find direct force, as secondary factor we have bone fragment mobilization, and the third mechanism responsible is high energy, all of these leading to multiple injuries, among them peripheral nerves also.

Life before limb. Initial evaluation should be addressed according to the associated injuries. When life is not in danger, a thorough examination can be performed. Identifying the nerve injuries in the initial phase can be sometimes tricky, especially when the patient is unconscious or it has compartment syndrome.

Strategies for reconstruction including timing and technique made the results to be better and better over the time. Herein we present an algorithm for evaluation and treatment of such injuries.

MANAGEMENT OF THE POSTTRAUMATIC SEIZURES

Slavko Đurašković, Novak Lakićević
Clinical centre of Montenegro, Clinic for Neurosurgery, Podgorica

According to statistics, approximately 2% of all the head trauma patients, will develop post-traumatic seizures (PTS). However, the incidence is dependent on how severe injury has been. The TBI has been observed as the leading cause of epilepsy in adolescents. Based on the time onset after the injury, posttraumatic seizures are divided into early (occurring within 7 days) and late seizures (occurring after 7 days). The incidence of early PTS in severe head injury is high and account 30%. In mild to moderate brain injuries, the risk for early posttraumatic seizures is low and account approximately 1%. The incidence of late PTS is 10- 13 % in a severe head injury in the first two year after the injury. Use of antiepileptic drugs in the patients already having the PTS is a standard practice. There was a strong controversy regarding the use of the antiepileptic drugs in antiseizure prophylaxis. The Brain Trauma Foundation published recommendations for anti-seizure prophylaxis in 2007. (Table 1.)¹

Level 1	There are insufficient data to support a level 1 recommendations for this topic.
Level 2	Prophylactic use of phenytoin or valproate is not recommended for preventing late posttraumatic seizures. Anticonvulsants are indicated to decrease the incidence of early PTS (within 7 days after injury). However, early PTS is not associated with worse outcomes.

Table 1. Recommendations for antiseizure prophylaxis. (Bullock R et al. "Guidelines for the management of severe traumatic head injury", 2007.)

Phenytoin significantly reduces the incidence of the early PTS. Valproate has the similar effects to phenytoin, but may have a higher mortality and can't be routinely used for seizure prophylaxis. Levetiracetam demonstrates comparable effects to phenytoin for PTS prophylaxis and can be reasonable alternative to phenytoin.

Novi Sad 2016

One Region, One Neurosurgery

Friday, October 21st / Hall 2

Friday, October 21st

ABSTRACTS

NURSES SYMPOSIUM

Hall 2

**OSNOVE PROCESA ZDRAVSTVENE NEGE KOD NEUROTRAUME:
PLANIRANJE, INDIVIDUALIZACIJA I DOKUMENTIRANJE**

Dragana Nikolić
Klinički centar Niš, Niš, Srbija

Proces zdravstvene nege kod neurotraumatizovanih bolesnika podrazumeva sagledavanje bolesnika kroz pojedinačne faze koje su međusobno povezane i jedna drugu nadograđuju. Kod neurotraumatizovanih bolesnika procena stanja svesti igra važnu ulogu, započinje u prvom kontaktu sa pacijentom i nastavlja se kroz sve faze. Spinalna neurotrauma podrazumeva povredu kicmenog stuba i kičmene moždine, koje prate neurološki ispadi. Potrebno je poznavanje kliničke slike i komplikacije bolesti kako bi se uspešno realizovala zdravstvena nega bolesnika. Obzirom na visokospecijalizovane potrebe neurotraumatizovanih bolesnika medicinska sestra ima složene zadatke u timu. Komunikacija bolesnika sa posebnim osvrtom na neverbalnu komunikaciju. Medicinska sestra u rešavanju problema koristi kauzalno i analitičko mišljenje u postavljanju sestrinske dijagnoze i rešavanju problema. Mora da poznaje medicinsku terminologiju, i da poznaje Rankin skalu, Glazgov koma skor skalu, Skalu za bol, Waterlou skalu.

AKTUELNI ALGORITMI U TRETMANU NEUROTRAUMATIZIRANIH PACIJENATA SA ASPEKTA NEUROSESTRE

Mirsada Čustović, diplomirana medicinska sestra

Emina Selimović, diplomirana medicinska sestra

Mr. dr. Ibrahim Omerhodžić

Klinički Centar Univerziteta u Sarajevu, Sarajevo, Bosna i Hercegovina

Uvod: Traumatsko oštećenje mozga nije degenerativne ili kongenitalne naravi, nego je uzrokovano vanjskom fizičkom silom koja dovodi do smanjenog stanja svijesti. Traumatska povreda mozga (TPM) vodi privremenom i trajnom oštećenju kognitivnih i fizičkih funkcija. Trauma je vodeći uzrok smrti u prve 4 dekade života, a trauma mozga implicira u najmanje polovini broja uzroka. Najvažnija komplikacija TPM je razvoj intrakranijalnog hematoma (IKH). Bez efektivnog hirurškog menadžmenta IKH se može transformirati u drugom pravcu. Zbog toga uticaj neurohirurga u tretmanu takvih pacijenata je enorman, i možda, više nego u bilo kojoj drugoj vrsti urgentne medicine, agresivnost, brzina i vještina kojom se obezbjeđuje tretman intrakranijalnog hematoma, determinirajuće ishod. Bolesnici s traumatskim ozljedama predstavljaju velik dijagnostički i prognostički izazov u rehabilitaciji. Traumatska povreda mozga je moždani insult koji vodi privremenom i trajnom poremećaju kognitivnih i fizičkih funkcija. Povreda glave, nastala usljed pada ili saobraćajne nesreće, signifikantno učestvuje u polovini svih smrti nastalih kao rezultat traume. Godišnja prevalenca u Evropi je 700 000 slučajeva, a ukupno koštanje oko 3 milijarde eura. Teška trauma mozga je vodeći uzrok smrti mladih ljudi u BiH. Zdravstvena njega pacijenata sa neurotraumom obuhvata sve postupke vezane uz bolesnika od dolaska na odjel, pripreme za operativni zahvat, postoperativnog praćenja stanja i sprečavanja komplikacija, pa do njegovog odlaska kući ili u drugu zdravstvenu ustanovu. Postupci zdravstvene njege su usmjereni na: intenzivnu zdravstvenu njegu, redovnu kontrolu stanja svijesti, zjenica, vitalnih funkcija, procjenu motornih i senzornih funkcija, održavanje plasiranih arterijskih i venskih puteva, PEG-a, traheostome, UK, traheobronhalnog stabla, previjanje rana, procjenu afazije, kontrolu balansa tečnosti, praćenje i mjerenje intrakranijalnog pritiska, kontrolu drenažnog sadržaja, primjenu terapije, održavanje lične higijene, uzimanje kontrolnih briseva, UK, bronhoaspirata, prevencija dekubitusa, masiranje predilekcionih mjesta, redovne stolice, te prevenciju komplikacija.

Cilj 1. Prikazati terapijske postupke i mjere u konzervativnom i perioperativnom tretmanu komatoznog neurohirurškog pacijenta (neselektirane i poredane proizvoljnim redoslijedom)

Cilj 2. Prikazati ishode pacijenata koji su tretirani po sumiranom protokolu tretmana komatoznog pacijenta sa traumatskim intrakranijalnim krvarenjem u postoperativnom periodu u Neurohirurškoj intenzivnoj jedinici.

Zaključak: Prognoza pacijenata sa neurotraumom je neizvjesna, i varira od visoke stope smrtnosti i u najrazvijenijim centrima preko značajnog broja vigilnih koma, pa do odličnog ishoda. Savremena tehnološka dostignuća i kolaborativan pristup neurotraumatiziranom pacijentu, između neurohirurga i neurointenziviste i neurosestre, značajno su reducirali smrtnost pacijenata sa TPM. Usprkos svim ohrabrujućim dostignućima u poboljšanju tretmana sa izrazitom i teškom traumatskom povredom mozga i intrakranijalnim traumatskim krvarećim lezijama, ostalo je još prostora za poboljšanje ishoda.

VREDNOST PREDIKTIVNOSTI KOD PRAĆENJA STANJA SVESTI

Dipl. Org. zdr. nege master Ivana Dondo
Klinički centar Vojvodine, Klinika za neurohirurgiju, Novi Sad, Srbija

Kraniocerebralne povrede predstavljaju traumatska oštećenja tkiva poglavine, kosti lobanje I endokranijalnih struktura. KCP imaju veliki socioekonomski značaj usled učestalosti, visoke smrtnosti I posledica koje ostavljaju. Traumatizam je danas na trećem mestu po učestalosti odmah iza kardiovaskularnih I onkoloških bolesti. Od svih smrtnih slučajeva usled traumatizma čak 26% su posledica KCP. Poseban problem je život nakon neurotraume. Česta su trajna motorna I neurološka oštećenja, deformiteti, invalidnost, psihički poremećaji I nakaznost. Najčešći uzroci KCP su: saobraćajne nesreće, padovi, fizički sukobi, ranjavanja vatrenim oružjem. Sva traumatska oštećenja mogu biti primarna I sekundarna, a po težini se dele na lake KCP, srednje teške I teške. Kada govorimo o poremećajima stanja svesti razlikujemo kvantitativne I kvalitativne poremećaje. Kvalitativni poremećaji stanja svesti su oni u kojima nema poremećaja stanja budnosti: konfuzije, delirijum, sumračno stanje, somnambulizam, fuga, hipnoza, halucinacije, iluzije.

Kvantitativni poremećaji stanja svesti su: somnolencija, sopor i koma. Da bi se procena stanja svesti mogla standardizovati I numerički vrednovati, Tizdejl I Dženet su 1974. godine uveli Glazgov koma skalu. Za brzu procenu stanja svesti u upotrebi je I AVPU skala. Kod nekih oboljenja I povreda stanje svesti može postepeno da se pogoršava I da traje jedno izvesno vreme, dok kod nekih oboljenja I povreda stanje svesti može da se promeni u roku od svega par sekundi od potpuno budnog stanja do stanja kome.

KOMPETENCIJE MEDICINSKE SESTRE U IMPLEMENTACIJI PROTOKOLA SKRBI KOD BOLESNIKA S INTRAKRANIJALNIM KRVARENJEM

Ivan Havrlišan, Matija Poropat
KB Dubrava, Zagreb

Kraniocerebralne ozljede su teška i po život opasna stanja koja prate brojne komplikacije. Povećanjem broja stanovništva te njihovim dnevnim kretanjima posebice u tranzicijskim i turističkim zemljama, raste broj prometnih nesreća te samim time kraniocerebralnih ozljeda koje su unatoč brojnim upozorenjima i edukacijama u konstantnom porastu.

Kompetencije medicinske sestre kao važnog člana neurokirurškog tima temelje se na kontinuiranoj edukaciji, usavršavanju te poznavanju brojnih parametara i načina liječenja koja se koriste u ovako kompleksnim situacijama. Medicinske sestre imaju stalni nadzor nad bolesnikom, procjenjuju stanje te su odgovorne za dokumentiranje svih pojava koje upućuju na promjenu stanja bolesnika i o tome izvještavaju liječnika.

Sestrinska skrb u liječenju intrakranijskih krvarenja je vrlo zahtjevna; od perioperativne pripreme, sudjelovanja pri samom operativnom zahvatu, sestrinske skrbi u jedinici intenzivnog liječenja te oporavka na odjelu. Od medicinskih sestara se očekuje visoki stupanj educiranosti, a procjena i sestrinske aktivnosti moraju imati temelje visokog stručnog znanja uz sudjelovanje ostalih članova multidisciplinarnog tima.

SMJERNICE MENADŽMENTA PREDHOSPITALNOG ZBRINJAVANJA BOLESNIKA S NEUROTRAUMOM

Biljana Kurtović, mag.med.techn.
Klinika za neurokirurgiju, KBC Sestre milosrdnice

Ozljede glave su jedan od najvećih zdravstvenih problema razvijenih zemalja svijeta. Napredak medicine i zdravstvene zaštite omogućuje skrb većeg broja ozlijeđenih u svim područjima: od ispravne i pravovremene pomoći na mjestu nesreće do odgovarajućeg liječenja i učinkovite prevencije sekundarnog oštećenja mozga. Ozljede glave su glavni uzrok smrtnosti i invaliditeta. Učestalost ozljeda glave iznosi od 100 do 300 slučajeva na 100.000 stanovnika godišnje. Optimalno rješenje kod svake ozljede glave je hitan prijevoz do bolnice gdje se može osigurati definitivno zbrinjavanje. Nema sumnje da je rana evakuacija intrakranijalnog hematoma iznimno važna za bolesnika i značajno poboljšava ishod. Sustav treba biti tako ustrojen da osigura što raniji prijevoz bolesnika do odjela neurokirurgije. Cilj izvanbolničkog zbrinjavanja je osigurati dovoljno kisika mozgu pomoću optimalne oksigenacije krvi i održavanja tlaka perfuzije mozga. Treba pretpostaviti da je prisutna ozljeda vratne kralješnice i primjereno je zbrinuti. Bolesnika prevesti u bolnicu, koja ima mogućnost zbrinjavanja neurokirurških bolesnika. Mnoge posljedice ozljeda glave mogu se spriječiti, uspješno liječiti ili barem ublažiti odgovarajućim pravovremenim mjerama na mjestu nesreće i daljnjim kontinuitetom skrbi. Presudne su prve minute na terenu, a sati ili dani koji slijede u Jedinici intenzivnog liječenja i sve mjere medicinskog osoblja u bolničkom okruženju sprječavaju sekundarna oštećenja mozga.

Medicinska sestra mora djelovati u okvirima svojih kompetencija, relevantnim obrazovanjem, osposobljenosti za navedeno radno mjesto, cjeloživotnim učenjem a sve u svrhu kvalitetnog zbrinjavanja bolesnika s ozljedom glave i djelovanjem unutar interdisciplinarnog tima.

VALIDACIJA KVALITETE ISHODA SKRBI ALKOHOLIZIRANOG BOLESNIKA S OZLJEDOM GLAVE – PRIKAZ SLUČAJA

Mirjana Šestak

Klinika za neurokirurgiju, KBC Sestre milosrdnice, Zagreb, Hrvatska

Traumatska ozljeda mozga je veliki zdravstveni problem, zahvaćena su oba spola i nije važna dob, vodeći je uzrok smrti kod djece, odraslih i starijih. Najveći je mortalitet s ozljedom glave uslijed prometnih nesreća te nešto manji u ozljedama na radu i padovima. Također je, prema studijima smrtnost od ozljede glave u prometnoj nesreći veća noću, vikendom te ljeti.

Konzumacija alkohola znatno smanjuje stupanj samokontrole, sposobnost koordinacije pokreta i brzinu reakcije te je neposredni uzrok 50% prometnih nesreća koje rezultiraju ozljedom glave. Prema istraživanju provedenom na Medicinskom fakultetu u Chicagu konzumiranje alkohola smanjuje povezanost između dva područja mozga koja zajedno rade kako bi ispravno protumačili socijalne signale, te na njih odgovorili, riječ je o amigdali i prednjem korteksu, te se zbog toga smatra da je vožnja pod utjecajem alkohola najkraća vožnja jer većinom završava prometnim nesrećama.

Traumatska ozljeda mozga je tjelesna ozljeda koja povremeno ili trajno oštećuje moždanu funkciju. Dijelimo ih na otvorene i zatvorene, prema integritetu kože. U početku većina bolesnika s traumatskom ozljedom mozga gubi svijest obično na nekoliko sekundi ili minuta, nakon pružene adekvatne prve pomoći na mjestu prometne nezgode ili pada ili bilo koje druge ozljede, bolesnik dolazi u bolnicu u jedinicu intenzivnog liječenja gdje se procjenjuje njegovo stanje. Glavni dio dijagnostičke procjene jest neurološki pregled bolesnika. Procjena dubine kome temeljni je postupak u bolesnika s teškom traumatskom ozljedom mozga. Najpoznatija, koja se svakodnevno koristi je Glasgow koma skala koja mjeri tri parametra: otvaranje očiju, verbalni odgovor i motorički odgovor, a najniža vrijednost zbroja je 3 te najveća 15. Neurološki status se procjenjuje svakodnevno, a bolesnika se potiče da sudjeluje odmah u rehabilitaciji, ukoliko mu to opće stanje dopušta, a kako bi se spriječilo nastajanje neuroloških deficita.

KLINIČKI STANDARDNI OPERATIVNI POSTUPCI KOD BOLESNIKA S TRAUMATSKOM OZLJEDOM VRATNE KRALJEŽNICE

Cecilija Rotim, mag. med. techn.

KBC Sestre milosrdnice

Ured za osiguranje i unapređenje kvalitete zdravstvene zaštite

Standardni operativni postupci (SOP) su detaljno napisane upute u svrhu postizanja poboljšanja kvalitete zdravstvene zaštite te smanjenje štetnih ishoda. Uvođenje SOP u Kliniku za traumatologiju KBC "Sestre Milosrdnice" pridonijelo je kvalitetniju i sigurniju zdravstvenu skrb.

Ozljede kralježnice obuhvaćaju širok raspon različitih ozljedbenih struktura kralježnice pri čemu nastaju brojne komplikacije koje su po život opasne za samog ozljeđenika. Prijelomi, luksacije, subluksacije, dislokacije i protuzije vratnih kralježaka i njegovih dijelova spadaju u vodeće javno zdravstvene probleme današnjice s visokim brojem smrtnosti u svijetu.

Cilj rada je predočiti pravilnu hitnu obradu ozljeđenika s prijelomom vratne kralježnice prema algoritmu zbinjavanja i standardnim operativnim postupcima. Prijelom vratnog kralješka najčešće nastaje tijekom prometnih nezgoda, sportskih aktivnosti i padova s visine. Pravilna i pravodobna dijagnostika omogućuje nam uvid u samu ozljedu kojom dobivamo mogućnost odabira pravilne metode liječenja (konzervativno liječenje, operativni zahvat, Chritchfield ekstenzija i kortikosteroidi). Daljnje liječenje i rehabilitacija bolesnika svodi se na metode sprječavanja komplikacije same ozljede (spinalni šok, infekcija operativne rane, komplikacije dugotrajnog ležanja, depresija, anksioznost...). Medicinska sestra/tehničar, član multidisciplinarnog tima, ima važnu zadaću u samom procesu dijagnostike, liječenja i rehabilitacije bolesnika kod prijeloma vratnog kralješka. Stanje spinalnog šoka kao jedno od najtežeg, ali i najčešćeg stanja komplikacije ove ozljede zahtjeva 24 - satni monitoring, punu stručnost, vještinu i znanje od medicinske sestre/tehničara. Stalnim promatranjem i bilježenjem vitalnih funkcija, neurološkog statusa i integriteta kože dobiva uvid u stanje bolesnika, ali i učinkovitost svog rada.

ULOGA CERVIKOKRANIJALNE TRAKCIJE U LIJEČENJU PRIJELOMA I IŠČAŠENJA VRATNE KRALJEŽNICE

Anita Brblić, prvostupnica sestrinstva
Đurđica Ponjan, prvostupnica sestrinstva
Mira Paver, prvostupnica sestrinstva
Zavod za kirurgiju kralježnice Klinike za traumatologiju
Klinički bolnički centar Sestre milosrdnice, Zagreb, Hrvatska

U indikacije za primjenu cervikokranijalne trakcije ubrajamo privremenu stabilizaciju nestabilnih cervikalnih ozljeda te zatvorenu repoziciju prijeloma i/ili iščašenja vratne kralježnice. Pritom valja obratiti pažnju na kontraindikacije, a to su okcipitocervikalna dislokacija i traumatska spondilolisteza tipa IIA. Mehanizam djelovanja ekstenzije ostvaruje se putem sila koje se sa postavljenih utega preko lubanje prenose na kranijalni segment vratne kralježnice, čime dolazi do istežanja u ozlijeđenom području. Na taj način dolazi do repozicije prijeloma i/ili iščašenja, čime se postiže i dekompresija neuroloških struktura. Postavljanje sustava za kraniocervikalnu trakciju počinje pripremom kože na mjestu aplikacije (brijanje, dezinfekcija, lokalna anestezija). Potom se u vanjski korteks parijetalne kosti, oko 1 cm iznad vrška uške, zabodu dva za to predviđena šiljka (prethodno je neophodno isključiti prijelom lubanje). Postavljeni šiljci potom se pričvrste za Gardner-Wells kliješta, na koja se potom aplicira uteg (čija masa obično iznosi oko 10% TT). Učinak trakcije svakodnevno se radiološki kontrolira standardnim radiogramima ili CT-om, a postoje i novija kliješta koja su kompaktibilna s MR-om. Kada je postignut cilj, tj. kada je kralježnica reponirana, pacijent je spreman za operativni zahvat sa ciljem stabilizacije kralježnice. Medicinska sestra mora biti dobru upoznata sa svrhom i načinom postavljanja sustava za cervikokranijalnu trakciju te poznavati zdravstvenu njegu bolesnika, pridržavajući se pritom svih pravila asepse i antiseptike. Na taj će način biti pripravna i za sve neželjene komplikacije, koje se mogu dogoditi prilikom samog zahvata ili tijekom daljnjeg liječenja.

LJUDSKI FAKTOR: KRITIČNA VAŽNOST UČINKOVITOG TIMSKOG RADA I KOMUNIKACIJE U PRUŽANJU SIGURNE SKRBI U OPERACIJSKOJ SALI

Vesna Svirčević, mag.med,techn.
Klinika za neurokirurgiju
KBC Sestre milosrdnice, Zagreb, Hrvatska

Sigurnost bolesnika jedan je od najvećih izazova i imperativa u sustavu zdravstva jer se kvaliteta zdravstvene zaštite najbolje ogleda upravo na razini bolesnikove sigurnosti.

Svjetska zdravstvena organizacija definira sigurnost pacijenata kao „prevenciju, otklanjanje i unapređenje zaštite od neželjenih događaja tijekom procesa zdravstvene skrbi“.

Medicinske sestre instrumentarke u svom svakodnevnom radu prvenstveno brinu o sigurnosti bolesnika u okruženju operacijske dvorane kako bi operacijski zahvat za njih protekao sigurno i bez komplikacija. Upotreba kirurške kontrolne liste jedan je od načina kako unaprijediti sigurnost pacijenta u operacijskoj dvorani. Ona pomaže da svi koji su uključeni u tim slušaju i usredotočeni su na pacijenta i planirani zahvat. U slučaju hitnih operacija koje se izvode kod pacijenata sa neurotraumom kada se mnogi postupci paralelno odvijaju kako bi se skratila perioperativna priprema bolesnika, KKL-a pomaže u sinkronizaciji uključenih u sve postupke oko pacijenta kao i detekciju razvoja bilo kakvog problema.

Jedan od osnovnih preduvjeta sigurnosti bolesnika je edukacija svih zdravstvenih djelatnika koji su izravno ili neizravno uključeni u proces liječenja. Sustav edukacije zdravstvenih djelatnika u operaciji, mora se prilagoditi tehnološkom napretku i informatizaciji. Ne treba zanemariti niti edukaciju bolesnika, jer dobro educirani i pravilno informirani bolesnici predstavljaju najboljeg partnera zdravstvenim djelatnicima u postupcima liječenja.

PROTOKOL OPERATIVNE TEHNIKE INVAZIVNOG MERENJA INTRAKRANIJALNOG PRITISKA

Sandra Milošević, Branislava Sirar, Dragica Najdanović,
Klinički Centar Vojvodine, Novi Sad, Srbija

Intrakranijalni pritisak je rezultat kombinovanog efekta atmosferskog i hidrostatskog tkivnog pritiska. Sadržaj intrakranijalnog prostora je pod stalnim pritiskom i on iznosi od 0-10mmHg.

IKP se može meriti iz intraventrikularnog, intraparenhimskog, subarahnoidalnog, subduralnog i epiduralnog prostora.

Za operaciju merenja IKP se spremaju bazični set instrumenata, za kraniotomiju kraniotom, kao i neophodan potrošni i šavni materijal, a u zavisnosti u koji se prostor plasira odgovarajući kateter i sistem za merenje IKP. Po protokolu u operacionoj Sali su dve instrumentarke, i to: sterilna, ona koja instrumentira i pomoćna tj. Cirkularna. Kada je po usvojenoj proceduri i protokolu hirurški oprala ruke i posušila ih, oblači sterilan mantil i sterilne rukavice. Zatim garnira dva instrumentarska stola, instrumentirajući i pomoćni po usvojenoj proceduri i protokolu. Pomoćna instrumentarka joj otvara sterilne instrumente i sve što je potrebno i spremno za operaciju. Hirurzi nameštaju položaj pacijenta i nakon toga pripremaju operativno polje. Kada je operativno polje spremno hirurzi i instrumentarka ga izoluju sterilnim kompresama i čaršavima.

Sterilna instrumentarka prilazi sa instrumentirajućim stolom operativnom polju, do pomoćna priključuje svu neophodnu aparaturu čija je ispravnost proverena i čekirana pre operacije. Tek nakon što je utvrđeno da je sve na adekvatan način i nesmetano pripremljeno, negirane smetnje i uz dozvolu anesteziologa i instrumentarke, operacija može da počne.

Veoma je važno da instrumentarka poznaje operativnu tehniku plasiranja katetera i sistema za merenje intrakranijalnog pritiska, kako bi pripremila neophodan instrumentarijum i na zavidnom nivou uz nesebičnu podršku hirurgu instrumentirala operaciju.

ANALITIČKI PRIKAZ POSTUPKA INSTRUMENTARKE KOD NEUROHIRURŠKOG LEČENJA SUBDURALNOG HEMATOMA

Ivana Štrbac, Novka Lipovčan

Klinički centar Vojvodine, Služba operacionih sala, Novi Sad, Srbija

Uvod: Mozak može biti povređen direktnim ili indirektnim dejstvom sila povređivanja. Povrede tada mogu biti lokalizovane na jednom, nekoliko ili mnogo mesta u mozgu. Uzrok nastanka subduralnog hematoma je najčešće traumatska povreda glave. Subduralni hematomi su krvarenja koja se nalaze ispod tvrde moždane opne. Lečenje je u najvećem procentu slučajeva hirurško, naročito kod postojanja akutnog subduralnog hematoma.

Cilj: Prikaz operativnog zbrinjavanja subduralnog hematoma, pripreme i uloge instrumentarke.

Metodologija: Zbog pritiska hematoma na moždano tkivo može doći do edema, što izaziva znakove povećanog intrakranijalnog pritiska što direktno ugrožava život pacijenta. Hitnom evakuacijom hematoma može se sprečiti ili izlečiti hernijacija i kompresija mozga.

Zaključak: Rad instrumentarke je složen i odgovoran posao, aktivan od početka do kraja operativnog zahvata. Instrumentarka je ravnopravan član tima u operativnom zbrinjavanju povreda.

**NEUROSURGICAL PATIENT WITH EPIDURAL HAEMATOMA
PERIOPERATIVE CARE: FIVE YEARS RETROSPECTIVE STUDY,
DEPARTMENT OF NEUROSURGERY UHC OSIJEK**

Moser S, Vuković A, Horvat AM

Department of Neurosurgery, Osijek Clinical Hospital Centre, Osijek, Croatia

Introduction. Acute compressive epidural hematoma is a neurosurgical emergency, requesting urgent surgical management. The aim of this paper is to describe the role of perioperative nursing staff in this setting.

Material and Methods. We have retrospectively analyzed perioperative data for patients surgically treated for epidural hematoma during five-year period (2011-2015) in a single institution.

Results. Surgical management of acute epidural hematoma was usually performed in emergency setting, after working hours, and with limited staff. Standard craniotomy set of instruments, trephine and craniotome were used in all cases. All patients were operated on with head fixed by three-point fixation. Surgery most commonly required use of absorbable haemostatic materials and non-absorbable atraumatic sutures for dural suspension. Linear fractures dividing bone flap and comminutive fractures were reconstructed using titanium plates and screws.

Conclusion. Surgical management of acute compressive epidural hematoma requires prompt setup of operative theatre, preparation of standard craniotomy set, haemostatic material, abundance of non-absorbable sutures and bone flap fixation devices.

Novi Sad 2016

One Region, One Neurosurgery

Friday, October 21st / Hall 2

Friday, October 21st

ABSTRACTS

POSTER SESSION

Hall 2

BLEPHAROSPASM AS A CONSEQUENCE OF CHRONIC SUBDURAL HAEMATOMA: AN INTERESTING CASE

Tomaz Velnar, Janez Ravnik, Gorazd Bunc, Matjaz Vorsic

University Medical Centre Ljubljana, Department of Neurosurgery, Ljubljana, Slovenia

Objectives: Chronic subdural haematomas are well known pathology and are frequently encountered in neurosurgical practice. However, blepharospasm in connection with chronic subdural haematoma is an uncommon pathology. Different mechanical as well as vascular factors may play a role by affecting dopaminergic transmission in basal ganglia, resulting in various extrapyramidal symptoms.

Methods: Clinical presentation of a 72-year old patient is described, who developed transient blepharospasm as a result of a chronic subdural haematoma. All the symptoms regressed after standard surgical evacuation of haematoma.

Results: A classical surgical evacuation of chronic subdural haematoma was performed through two burr holes. Subdural drainage was inserted. Patient's clinical condition has improved after brain decompression.

Conclusions: Extrapyramidal symptoms in the setting of chronic subdural haematoma are rare and they are usually reversible. They subside quickly after evacuation of haematoma.

INDICATIONS, CAUTIONS & LIMITS OF INTERDISCIPLINARY APPROACH: PHYSICAL & REHABILITATION MEDICINE – ORTHOPEDICS, IN PATIENTS WITH SEVERE NEUROLOGICAL PATHOLOGY (PRELIMINARY DATA)

Gelu onose^{1,2}, Aurelian Anghelescu^{1,2}, Florin BICA^{1,3},
Ionut COLIBASEANU (Kt)², Raluca POGANCEANU (Kt)³

- 1) (State) University of Medicine and Pharmacy “Carol Davila” – Bucharest,
- 2) Physical (Neural-muscular) and Rehabilitation Medicine Clinic Division of the Teaching Emergency Hospital “Bagdasar-Arseni” – Bucharest, Romania
- 3) Orthopedics and Traumatology Clinic Division of the Teaching Emergency Hospital “Bagdasar-Arseni” – Bucharest, Romania
(Kt = kineto therapist)

Background: Preformed excitable tissue structures (nervous cells, specialized receptors, muscle cells) synergically interact in extensive cinematic mechanisms and subtle sensorial tuning loops for complex modulation of bipedal walk, balance recovery and control. The modern concept of “Neuro-Myo-Artro-Kinetic” system is composed at segmental levels by: Nerve – Muscle(-s) – Joint.

Material and methods: Between 2005-2015, in the Teaching Emergency Hospital “Bagdasar-Arseni”, Neuromuscular Rehabilitation and the Orthopedic Clinic, were admitted and have underwent surgery 12 patients with multiple articular stiffness, deposturing sequelae secondary to critical cranio-cervical trauma. Among them, all 12 had critical bilateral knee stiffness, 2 associated hip ankylosis in complete extension, and 2 patients had elbow stiffness (in 90 degrees of flexion). Surgical techniques (tenotomies, capsulotomies, teno-muscular transpositions, arthrolysis) used in the treatment of the severe deposturing sequelae after central neurologic disorders were: 12 pes anserinus and femoral biceps tendon transpositions, respectively 8 posterior capsulotomies. Patients were assessed with the Gross Motor Function Classification Scale (GMFCS).

Results: All cases had severe knee stiffness: 76.96% of subjects were severely limited in their walking ability, being in wheelchair (4th degree GMFCS), respectively 23.04% were non-ambulate, being totally dependent in all aspects of care (5th GMFCS). Post knee orthopedic serial interventions, coupled with iterative, subsequent, individualized rehabilitation treatments, 50% of the subjects walked independently (quoted as 2nd GMFCS, having difficulty with uneven surfaces,), respectively 50% walked with assistive devices (3th GMFCS).

Conclusions: Adequate prophylaxis, comprehensive, inter- /multidisciplinary therapeutically approach represent essential objectives for neurorehabilitation of patients with severe deposturing sequelae after cerebro-nevraxial traumatic lesions.

CRANIOCEREBRAL TRAUMA AS RESULT OF A COMPRESSOR TUBE EXPLOSION: A CASE REPORT

¹Tomaz Velnar, ²Matjaz Vorsic, ¹Rado Pregelj, ²Gorazd Bunc

1) Department of Neurosurgery, University Medical Centre Ljubljana, Slovenia

2) Department of Neurosurgery, University Medical Centre Ljubljana, Slovenia

Objectives: Traumatic brain injury is frequently encountered in neurosurgical practice. Although penetrating trauma is less common than closed injuries, it is more often lethal. Cavitation effect, vascular and neuronal damage, secondary brain injury and infection are the main causes of poor outcome.

Methods: Clinical presentation of a 35-year old patient is described, who suffered explosion head injury. During the explosion of a construction machine, a foreign body (a part of high-pressure compressor air tube, 6cm in length, made of steel wires and plastic mantle) penetrated the basal parts of frontal lobes through maxilla, medial orbit and ethmoid. It was embedded in the vessels of the anterior communicating complex, elevating it to the lower falx. At the admission, GCS was rated at 14. No paresis was evident.

Results: Through the interhemispheric approach, the foreign body was removed, debridement and reconstruction were done and all vessels were spared. The initial recovery was good and sedation was gradually discontinued. However, patient's clinical condition deteriorated after one week due to vasospasm induced brain infarction and meningitis and he died of infection and multiorgan failure.

Conclusions: Penetrating injury to the brain has a poor prognosis and high disability among the survivors. Minimising secondary insults to the brain tissue, strict adherence to the brain trauma guidelines and infection prevention are imperative. The deterioration may appear also late in the treatment course, after initial promising recovery.

DEPRESSED AND OPEN SKULL FRACTURES OVER THE SUPERIOR SAGITTAL SINUS. PRESENTATION OF THREE CASES AND LITERATURE REVIEW

Gatos H., Paschalis Th., Tasiou A., Fountas KN
University Hospital of Larissa, Department of Neurosurgery, Thessaly, Greece

Skull fractures overlying the dural sinuses pose a great challenge to neurosurgeons, while they require, most of the time, emergent surgical intervention due to mass effect caused by a hematoma or elevated intracranial hypertension. We present three interesting and illustrative cases of skull fractures (2 depressed and 1 open), which presented with an acute neurological clinical picture (intracranial hypertension, and coma due to a vertex epidural haematoma). The review of the pertinent literature indicates that these injuries are a rare variant of skull fractures, and their associated morbidity and mortality is much greater than other head trauma cases. This is mainly caused by the involvement of the superior sagittal sinus and a wide spectrum of complications associated with its injury, such as hematoma, embolism, and cerebral venous infarction. Moreover, the literature suggests that in cases of conservative management, close observation is mandatory, and any rapid neurologic deterioration should alert the surgeon for emergent surgical intervention. Surgical management of these injuries remains a real challenge for managing often profound hemorrhage.

Key words: TBI, SSS, Mass effect, Neurological decline

POSTERIOR FOSSA SKULL FRACTURES: TWO ILLUSTRATIVE CASES AND LITERATURE REVIEW

Gatos H., Georgiadis I., Tasiou A., Fountas KN
University Hospital of Larissa, Department of Neurosurgery, Thessaly, Greece

Trauma of the posterior fossa, although rare compared to supratentorial injuries, constitutes a challenging and technically demanding condition even for busy level I trauma centers. We present two illustrative cases of severe TBI with posterior fossa skull fractures, which were surgically managed and had fatal outcome. Skull base fractures can be of predictive value in traumatic cases. They occur in 3.5 - 24% of head injuries, and are often related to an underlying brain parenchymal injury, in up to 50% of the cases. It has been reported that 70% of the skull base fractures occur in the anterior fossa, 20% in the middle central skull base, and only 5% in the posterior fossa. Traumatic injury to the posterior fossa is a complex pathologic condition because of the great heterogeneity of the occurring lesions. They can be intra-axial lesions such as contusions, hematoma or diffuse axonal injury, and extra-axial lesions such as epidural and subdural hematoma, as well as subarachnoid hemorrhage. The importance of early recognition and proper management of any posterior fossa injuries cannot be overemphasized. The management algorithm, as well as the pros and cons of surgical versus conservative management of these challenging injuries will be discussed.

Keywords: TBI, posterior fossa, mass effect, blood loss, GCS

LE FORT TYPE 3 FRACTURE OR NOT? – CT SCAN RELIABILITY

Vuk Aleksić¹, Milan Spaić¹, Nenad Živković¹, Radomir Benović¹, Marko Samardžić¹,
Miljan Bulatović¹, Igor Popović¹, Milenko Stanić¹

1) Department of Neurosurgery, Clinical-Hospital Center Zemun, Belgrade, Serbia

Introduction: Axial non-contrast CT scan is the standard technique in patients with head and/or face injury. The three dimensional CT imaging reconstruction is becoming a gold standard in trauma of maxillofacial region enabling a clear perception of fracture lines and resulting displacement of fracture fragments. Le Fort fractures are fractures of the midface. In Le Fort type 3 fracture the craniofacial disjunction is present.

Case presentation: A 91-year-old female had a mild facial trauma with skin abrasion as a result of accidental fall, without clinical signs of fracture. Axial CT scan showed artifacts, but 3D CT imaging reconstruction showed typical Le Fort type 3 fracture. Since clinical and 3D CT reconstruction finding were in complete contradiction, we repeated CT scan, which showed normal finding.

Conclusion: This case shows that in era of incredible progress of neuroradiology, clinical examination still remains inevitable diagnostic tool.

Key words: Le Fort type 3, midface fractures, 3D CT;

Figures

Figure 1. The 3D CT imaging reconstruction with typical finding of Le Fort type 3 fracture.

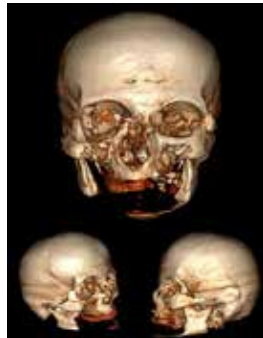

Figure 2. Axial CT scan showing artifacts

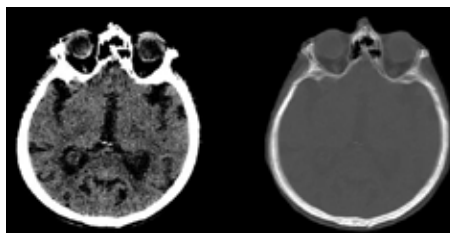
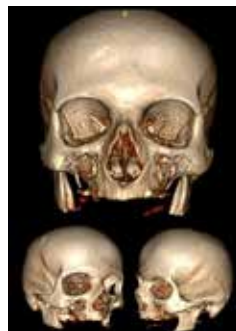

Figure 3. The control three dimensional CT imaging reconstruction presenting normal finding.



DURAL METASTASIS MISDIAGNOSED AS A BILATERAL SUBDURAL HEMATOMA - A CASE REPORT AND A REVIEW OF LITERATURE

Vuk Aleksic¹, Milenko Stanic¹, Nenad Zivkovic¹, Marko Samardzic¹, Igor Popovic,
Miljan Bulatovic¹, Milan Spaic¹, Radomir Benovic¹

1) Department of Neurosurgery; Clinical Hospital Center Zemun, Belgrade, Serbia

Dural metastases originating from prostate cancer are exceedingly uncommon and may clinically imitate a subdural hematoma. Additionally, head CT scan findings can be mistaken for meningioma or subdural hematoma. We present a 75-year-old male patient with dural metastasis of prostate cancer misdiagnosed as bilateral subdural hematoma. Also, a review of literature is presented.

Key words: Dural metastases; Subdural hematoma;

Figures

Figure 1. Initial CT head scan with subdural hematoma over the right hemisphere and minor chronic subdural hematoma on the left side (A); Subdural collection with oval, nodular mass on the right side (B); Multinodular collections on the left side (C); The tumor with adjacent dura (D).

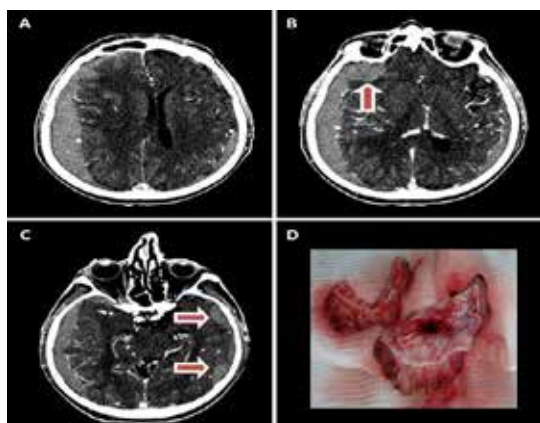
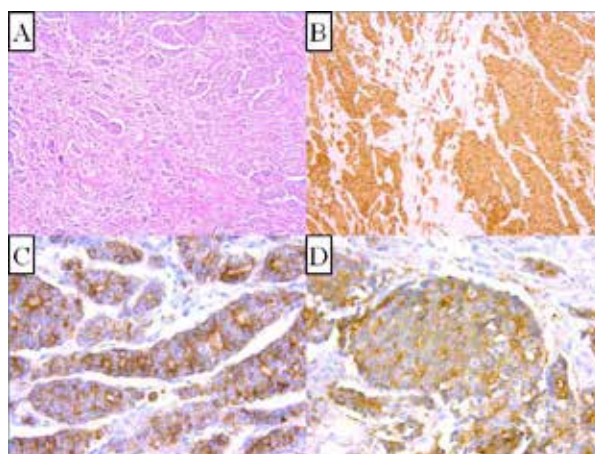


Figure 2. Pathohistologic and immunohistochemical examination of the removed tissue. Tumor proliferation with poorly differentiated glandular structures and with fields of dural infiltration. A degree of cellular pleomorphism was noted, as well as, visible nucleoli (A). The tumor did not react to antiLCA, neurofilament, cytokeratin 7, cytokeratin 20, desmin, RCC, NSE, synaptophysin, CEA, CD56, CD99, ER, PR, GFAP and vimentin antibodies, but was clearly positive for anti pancytokeratin (B), AMACR (C) i PSMA (D) antibodies.



THE USE OF MINI-MENTAL STATE EXAMINATION IN THE ASSESSMENT OF MENTAL STATUS OF PATIENTS WITH MILD TRAUMATIC BRAIN INJURIES - YES OR NO?

Nikolašević, Ž.¹, Bugarski Ignjatović, V.², Karan, M.³, Vuleković, P.³, Nikolić, M.¹, Jelača, B.³

1) Department of Psychology, Faculty of Philosophy, University of Novi Sad

2) Neurology Clinic, Faculty of Medicine, University of Novi Sad

3) Neurosurgery Clinic, Faculty of Medicine, University of Novi Sad

Introduction: The use of cognitive screening can allow initial recognizing of patient groups that require further cognitive status follow-ups or extensive neuropsychological assessment. The Mini-Mental State Examination (MMSE) often represents the “golden standard” for use in the neurological patient populations. Although the MMSE is broadly used, questions about its usefulness and sensitivity beyond this setting are still raised. Critics suggests that the instrument, assesses memory and language abilities, which are usually the least affected by traumatic lesions. Also, tasks that assess abilities such as executive and visual-perceptive functions, which are much more sensitive to traumatic lesions, are not included in this scale. In compliance with this, researching the usefulness of the MMSE in patients with mild traumatic brain damage emerges as an important goal.

Method: The research sample consisted of 25 patients of both sexes, aged 18-64, with mild traumatic brain damage. The patients were subjected to the assessment via MMSE twice, one and six months after the injury.

Results: The Wilcoxon Rank-Sum test showed no significant difference between the first and second measurement of cognitive status, assessed using the MMSE. The results of the study also suggest that one month, as well as six months after the injury, 100% of the patients could be categorized as disorder-free, using the more rigorous cut-off score criteria.

Conclusion: The results of the study suggest low sensitivity of the scale when used for the assessment of cognitive functions in patients with mild traumatic brain damage. In other words, the MMSE can be seen as a rough cognitive status diagnostic tool, unable to detect subtle neuropsychological changes, or mild forms of cognitive dysfunctions, commonly associated with mild traumatic brain damage. These results suggest that the MMSE is not an adequate cognitive screening tool for the type of cognitive damage that accompanies traumatic pathology.

Key words: quick cognitive status assessment, Mini-Mental State Examination, mild traumatic brain damage.

EXECUTIVE FUNCTIONS IN PATIENTS WITH MILD TRAUMATIC BRAIN DAMAGE

Bugarski Ignjatović V.¹, Nikolašević Ž.², Karan M.³, Vuleković P.³, Nikolić M.¹, Djilvesi Đ.³

1) Neurology Clinic, Faculty of Medicine, University of Novi Sad

2) Department of Psychology, Faculty of Philosophy, University of Novi Sad

3) Neurosurgery Clinic, Faculty of Medicine, University of Novi Sad

Introduction: Executive functions comprise a number of abilities necessary for successful functioning in daily activities, such as organization, planning, problem solving, activity control, multitasking, mental plasticity etc. Therefore, the assessment of executive functions in patients with mild traumatic brain damage is one of the main goals in the area of neuropsychological diagnostics and in tracking the recovery process of patients. Recognizing executive functions deficits timely can contribute to the timely application of therapeutic procedures, such as cognitive rehabilitation, aimed at maximizing the remaining cognitive capacities and restituting the existing deficits.

Method: Research was conducted on a sample of 25 patients with mild traumatic brain damage, of both sexes, aged 18 - 64. Executive functions were assessed in two phases after the injury, one month and six months after the injury. Executive functions were assessed via the Wisconsin card sorting test, Trail Making test, form A and B and phonemic fluency tasks.

Results: The Wilcoxon Rank-Sum test showed a significant difference between the first and second assessment on the test of phonemic fluency and on the number of persevering answers on the Wisconsin test. Results of this study suggest there is a gradual improvement of phonemic fluency six months after the injury, and a gradual decrease of persevering answers, in comparison to the initial assessment, or the period of one month after the occurrence of the injury.

Conclusion: The phonemic fluency deficits and perseverance seem to be executive functions aspects most sensitive to mild traumatic brain damage. However, these aspects show gradual improvement as time passes. Also, the registered deficits seem to reverse over time, which can suggest the role of frontal brain regions and their capacity to compensate the initial deficit even in cases of traumatic brain damage. This result is in adherence with the findings of previous studies.

Key words: executive functions, mild traumatic brain damage

POST-TRAUMATIC LEPTOMENINGEAL CYST IN A 9 MONTH OLD INFANT - CASE REPORT

Boris Đurović, Novak Lakićević*, Momir Jovanović**, Slavko Đurašković*,
Ana Savićević*, Milena Roganović *

*Neurosurgery Clinic of the Clinical Centre of Montenegro, Podgorica, Montenegro

**General hospital Čuprija, Serbia

Introduction: Sometimes called a “growing fracture.” This is a rare complication of skull fracture (incidence <1% of pediatric skull fractures) that may develop when there is a linear fracture of the skull with separation of the fracture edges and dural laceration. The arachnoid membranes can be trapped between the edges of the fracture. In such cases, the natural brain pulsation causes skull erosion. This complication can occur in adults, but it is most often seen following fracture of the skull in infants and young children (usually <3 years). The condition is usually detected by parents who notice a soft, cystic mass developing on skull of child. Initially, the condition can be confused with cephalhaemathoma. Children can present with enlarging scalp mass, seizures, focal neurological deficit, and/or headache.

Case report: The child aged 9 months was admitted to the Clinic for Neurosurgery due to a head injury caused by the fall from the father’s arms. Initially, the child lost consciousness. Sent from Regional Medical Center, intubated, sedated, hemodynamically stable, defends the target flexion. Shortly after admission in our hospital the child was extubated and was in good neurological condition. Local findings: epicranial hematoma frontally on both sides and periorbital hematoma on the right side. X-ray of the skull showed a linear fracture of the frontal bone. CT brain noted the linear fracture of the frontal bone on the left side, contusion focus and laminar subdural hematoma left frontal, which was later confirmed by MRI. Seven days after injury, frontal subdermal localized collection is magnified and was punctured, and cerebrospinal fluid under high pressure was obtained. Pressure bandage was put, but did not give effect as the collection began to increase again. Operation under general anesthesia indicated existence of subgaleatical CSF collection and leptomeningeal cyst in the region of large fontanelle.

Material and methods: In the region of large fontanelle dural defect was plastificated using periosteum, neuropatch and biological glue.

Results: Good cosmetic result without neurological deficit

Conclusion: Early surgical treatment of dural defect gives the best results

Key words: leptomeningeal cyst, pediatric skull fracture, “growing fracture”

DEATH AFTER CONCUSSION – CASE REPORT

Radunović A¹, Lakićević N¹, Miljković A², Zivković B², Mićović M^{2,3},
Milojević T², Rasulić^{2,3}

1) Clinic of neurosurgery, Clinical centre of Montenegro, Podgorica

2) Clinic of neurosurgery, Clinical centre of Serbia, Belgrade

3) University of Belgrade, Faculty of medicine

Introduction: Concussion is considered as mild brain injury, however increasing number of papers report about not so rare permanent consequences of this so-called „mild injury“. Second-impact syndrome (SIS) is rare condition that could provoke most serious complication of concussion occurring when a person suffers another concussion before symptoms from an earlier one have subsided. The first concussion disrupts normal brain metabolism and function, and it is believed that brain is left in a vulnerable state and that even a much smaller force than the one that caused the first injury can lead to catastrophic brain swelling and death. The mortality rate for SIS approaches 50% and disability is almost 100%.

Case report: We report a case of a previously healthy 4-year –old girl that was injured during a car accident. The girl was examined in the Emergency Center, Clinical Centre of Serbia, two hours after injury. She had a poor recollection of the injury, and vomited twice before examination. CT showed no signs of brain or bone trauma. The diagnosis of concussion was made, and the girl was admitted for observation for the next 12 hours. The following day girl was brought in the Emergency Center by her parents. On the way to the bathroom, girl fell and had hit her head again. At the time she was brought in the ER for the second time, girl localized painful stimuli, but did not open her eyes and gave verbal response to painful stimuli (GCS 7). First control CT scan was normal but on the following one diffuse brain swelling was detected. Usual battery of biochemical analysis was done, and it showed severe electrolyte imbalance. The patient was intubated and attached to ventilator machine. All treatment measures were attempted, however after three days, patient died.

Conclusion: While repeated concussion is not necessarily associated with cerebral swelling and SIS –nevertheless clinicians need to be aware of the possibility that this grave complication may occur following a head injury. This is especially important in sports, and that is the reason that presence of any symptoms should mandate restriction from further sports participation until symptoms fully resolve.

TRANSARTERIAL ENDOVASCULAR TREATMENT OF CAROTID-CAVERNOUS FISTULA: CASE REPORT AND REVIEW OF LITERATURE

Authors: Aleksandar Spasić¹, Dragan Anđelić¹, Nikola Boban¹, Andrej Petreš¹,
Viktor Till^{1,2}, Sanja Stojanović^{1,2}

1) Clinical Center of Vojvodina, Center for Radiology;

2) Medical Faculty, University of Novi Sad.

Introduction: Patient (male, 61 years old) after head trauma presented with left eye chemosis and exophthalmos. On CT examination left orbital veins enlargement, orbital fatty tissue edema, exophthalmos and zygomatic bone and maxillary sinus fractures were noted. On Time of flight MR angiography carotid-cavernous (CC) fistula was proven. Endovascular therapy was indicated.

Material and methods: Direct arterial microcatheterisation of arterial wall defect was performed. Tip of the microcatheter was advanced into cavernous sinus, where three coils were deployed.

Results: Control angiograms demonstrated stop of direct arteriovenous communication with swift decline of symptoms.

Discussion: Review of the literature, imaging findings on different modalities and rationale for therapy approach are evaluated.

Conclusion: Endovascular transarterial coiling of cavernous sinus is one among methods of choice for treatment of CC fistula.

SURGICAL REMOVAL OF INTRACRANIAL FRAGMENTS AFTER GUNSHOT INJURY – MANDATORY OR NOT? INTRACRANIAL AND CHEST BULLETS RETAINED FOR 35 YEARS – A CASE REPORT AND A REVIEW OF LITERATURE

Vuk Aleksic¹, Slobodan Savic², Dragan Jecmenica², Milenko Stanić¹, Milan Spaić¹

1) Department of Neurosurgery, Clinical Hospital Center Zemun, Belgrade, Serbia

2) Institute for Forensic Medicine, University of Belgrade, School of Medicine, Belgrade, Serbia

Gunshot injury to the head is usually fatal. Some citizens may survive penetrating head injury, since some low velocity bullets produce much less damage to brain. We present a case of elderly male patient with mild head injury due to accidentally fall. Patient died a few hours after admission to Emergency Department. Autopsy finding revealed one strayed projectile in the posterior horn of left lateral ventricle and one in the soft tissue of right VIII intercostal space. Later we obtained information that patient suffered multiple gunshot wounds 35 years earlier. However, the cause of death was deterioration of long-term and severe hypertensive and atherosclerotic heart disease. We conducted a literature review about significance of intracranial fragments removal after gunshot injury.

Key words: Head injury; Gunshot injury;

FIGURES

Figure 1.

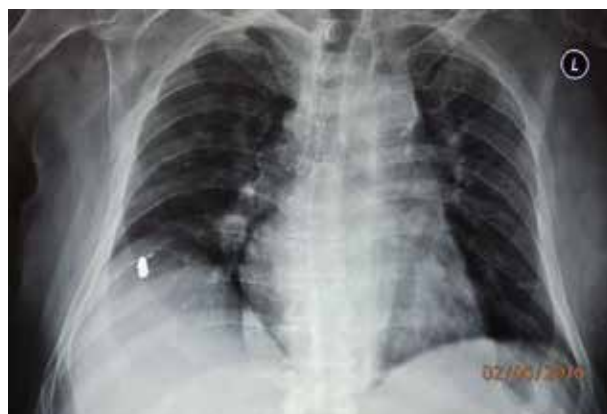

Figure 2.

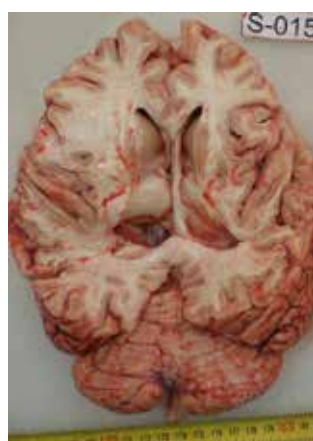

Figure 3.

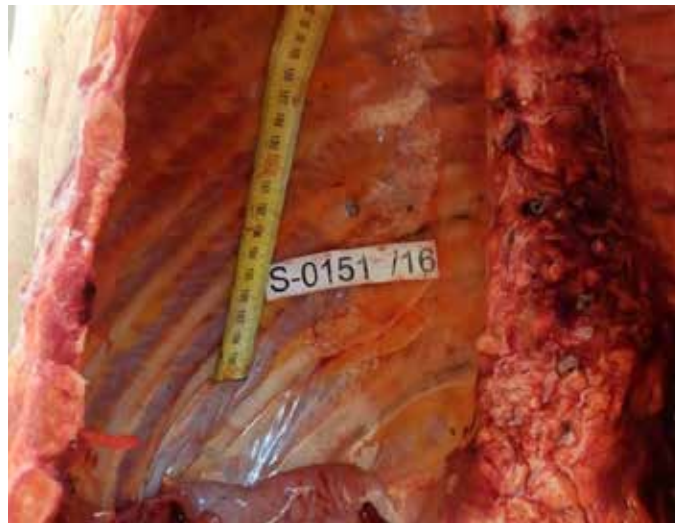
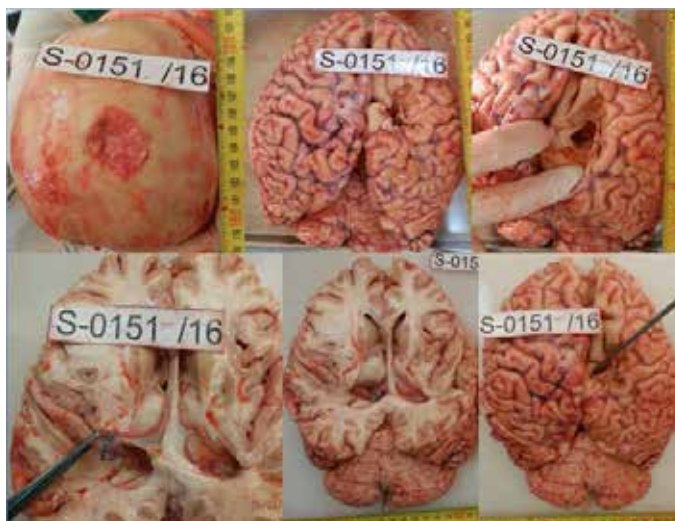
Figure 4.




Figure 5.



SURGICAL TREATMENT OF GROWING SKULL FRACTURE IN CHILDREN

Zivkovic B.¹, Borovinic L.², Taskovic J.¹, Milojevic T.¹,
Jovanovic I.^{1,3}, Micovic M.^{1,3}, Rasulic L.^{1,3}

- 1) Clinical Center of Serbia, Clinic of Neurosurgery
- 2) Clinical Center of Montenegro, Clinic of Neurosurgery
- 3) University of Belgrade, Faculty of Medicine

Introduction: Growing skull fracture is a rare complication of skull fractures usually seen in children. It is categorized as progressive diastatic enlargement of the fracture line. Sometimes, brain tissue and/or CSF filled cyst protrude through this gap, hence this complication is also called leptomenigeal cyst. We present current surgical treatment principles for growing skull fracture in Clinic of Neurosurgery in Belgrade.

Case report: A 3-year-old girl was injured in a car accident one month before admittance in our hospital. She was diagnosed contusion and frontal skull fracture on the right side, that extended into right orbital roof. On admission she was soporous, with no verbal contact, she localized appropriately on painful stimuli, but had a right sided hemiparesis. Neurologically, she recovered slowly, but periorbital edema became more pronounced, instead of subsiding with time, so the child was referred to our institution. On admission in our hospital, periocular and conjunctival edema was extremely pronounced, so the bulb could not be visualized. MRI showed small part of frontal lobe tissue extended through the fracture gap into the orbit 10x7mm in diameter. We decided to operate using fronto-temporal approach. Fracture was shown, approx. 5mm wide on the orbital roof and large dural defect was detected with brain tissue protruding through the gap and into the orbit, about 10mm in diameter. Dissected tissue was removed and duraplasty was performed. After dural suspensions, bone flap and soft tissues were closed in anatomic layers. On the follow-up exam edema resolved completely and girl could open her eyes with some ptosis.

Conclusion: Growing skull fracture is a relatively rare complication of skull fracture. However, it can lead to significant neurological disorders that can be prevented with appropriate treatment. Surgery is essential to prevent the development of neurological complications – neurological deficit and seizures, and cranial asymmetry.

CRANIOTOMY OR CRANIECTOMY FOR ACUTE SUBDURAL HEMATOMA?

Borovinic L.¹ Lakićević N.¹ Radunović A.¹ Miljković A.² Savić A.²
Baščarević V.^{2,3} Rasulić L.^{2,3}

- 1) Clinical center of Montenegro, Clinic for Neurosurgery
- 2) Clinical center of Serbia, Clinic for Neurosurgery
- 3) University of Belgrade, Faculty of Medicine

Introduction: An acute subdural hematoma (SDH) is usually caused by severe head injuries. SDH thicker than 1 cm generally require surgical treatment, to reduce pressure on the brain. Two surgical methods are used to treat acute SDHs - decompressive craniectomy (DC) and craniotomy (CO). The aim of our study is to show which treatment gives better outcome, based on our series of patients treated in Emergency Center, Clinical Center of Serbia.

Methods: Our study included 144 consecutive patients treated surgically in Emergency Center, Clinical Center of Serbia from January 2011 until January 2013. Data was acquired using patient history's – age, gender, neurological status on admission using Glasgow Coma Scale, pupil's size and responsiveness, neuroradiological features (hematoma thickness, midline shift), type of surgical procedure (CO or DC) and finally, outcome evaluated using Glasgow Outcome Scale.

Results: There were 82 patients treated using osteoplastic craniotomy and 62 cases where decompressive craniotomy was performed. Initial neurological status was worse in the DC group (lower overall GCS and higher percent of Hutchinson's pupil). There was no significant statistical difference between these groups concerning age and gender. Surgical outcome was evaluated 4 months after injury, and we found that satisfactory outcome (Glasgow outcome scale 4-5) was achieved in 42% in the CO group and in 23% in the DC group. Statistical analysis showed significant difference between the groups ($p < 0.05$, $p = 0.003$). Also, patients in the DC group had higher mortality rate than the CO group (25.2% vs. 8.1%).

Conclusion: Our study concluded that decompressive craniectomy after acute SDH evacuation was not associated with a better outcome and lower mortality, and that according to our data, craniotomy may be the surgical method of choice. However, additional research is necessary for the final conclusion since our study was performed on relatively small number of patients.

NEUROIMAGING AFTER MILD TRAUMATIC BRAIN INJURY IN CLINIC OF NEUROSURGERY IN BELGRADE - IS IT REALLY MILD?

Tašković J¹, Radunović A², Janković D³, Arsov J¹, Baščarević V^{1,4}, Rasulić L^{1,4}

Clinic of neurosurgery, Clinical Center of Serbia, Belgrade

Clinic of neurosurgery, Clinical Center of Montenegro, Podgorica

Clinic of neurosurgery, Clinical Centar Osijek, Croatia

University of Belgrade, Faculty of medicine

Introduction: Prevalence of mild traumatic brain injury (TBI) is estimated as 70% of all head injuries. A traumatically induced physiologic disruption of brain function in patient with mild TBI is manifested by a loss of consciousness, amnesia, mental deterioration, and/or transient or permanent focal neurologic deficit. Initially GCS is greater than 13, there are no abnormalities on CT scan and disorientation period is less than 30 minutes. In some cases patients will later develop clinically or surgically significant intracranial lesion. The aim of our study is to analyse the prevalence of delayed brain injury using neuroimaging techniques.

Methods: Our retrospective study included 94 consecutive patients that have been treated at the Neurotrauma Department of Emergency Center, Clinical Center of Serbia for mild TBI during a period of one year (January 2015-January 2016). We used computed tomography and magnetic resonance imaging during our neuroradiological evaluation. Data used in these study was extracted from patients histories.

Results: Injuries were caused by fall (56%), assault (29%) and traffic accident (15%). All patients had normal CT scans on admission to the hospital. Hospitalization duration varied from 1 to 15 days. During that time control imaging was performed. In 36 cases CT and/or MRI showed brain injury. We detected following lesions : In 20% cases diffuse edema, in 8% brain contusion, in 2% acute subdural, in 1% intracerebral, and in 1% epidural hematoma. Three of these patients required surgical treatment. Additionally one patient developed hydrocephalus that required shunt implantation. The majority of patients recovered completely, however 4% of all 94 patients in our study had permanent focal neurological deficit and 2% developed epilepsy. One patient died because of uncontrollable diffuse brain edema.

Conclusion: Our study showed that most of the patients diagnosed with a mild TBI recovered completely, but not so small percentage experienced serious permanent complications, some even requiring surgical treatment. Based on all this we can conclude that term mild brain injury is not always appropriate.

EVALUATION OF NEURORADIOLOGICAL PARAMETERS IN THE REVISED CT SCORE AS A PREDICTOR OF OUTCOME IN PATIENTS WITH TRAUMATIC BRAIN INJURY

Filip Pajičić¹, Đula Đilvesi^{1,2}, Bojan Jelača^{1,2}, Petar Vuleković^{1,2}

1) Clinical Centre of Vojvodina, Clinic of Neurosurgery, Novi Sad, Serbia

2) University of Novi Sad, Faculty of Medicine, Novi Sad, Serbia

Introduction: Traumatic brain injuries are critical socio-epidemiological problem in the world as they represent a leading cause of death due to trauma among the working population. In order to predict outcomes in patients with traumatic brain injury, scientists have developed two scoring systems that use group of findings on the initial CT scans - Marshall and Rotterdam score. Both scores have good performances but also some flaws which is why revision of the existing scores could be a step toward better outcome prediction.

Objectives: Evaluation of neuroradiological parameters in the new revised CT score as a predictor of death outcome in patients with craniocerebral injuries.

Methods and Materials: TBI patients who met the criteria for entering the study were divided into two groups – dead or alive depending on their outcome, and their CT scans were evaluated. If the thickness of optic nerve was greater than 4.5 mm one point was given, and if less – zero points were given. Presence of traumatic subarachnoidal haemorrhage was appraised with one point while the absence of one with no points. Midline shift over 5 mm was evaluated as one point while the shift less than 5 mm as zero points. Volume of traumatic hematoma and the volume of intradural supratentorial space were measured in comparison to ellipsoid using ABC/2 formula so that the hematoma volume would be estimated as the percentage in the supratentorial intradural space. If the percentage of hematoma was greater than 12% - two points were given, percentage less than 12% and greater than 5% was marked as one point, and the percentage less than 5% as zero points. For each patient score could be on a scale from 0 to 5.

Results: The average score in survivors group was 1 ± 1.2 while in the group of deaths the score was 4.4 ± 1 . Mann - Whitney U test showed that the total score was significantly ($p < 0.01$) higher in patients with death outcome. The area under the ROC curve indicates that the scoring system has excellent predictive value (AUC = 0.96, 95% CI between 0.89 and 1, with statistical significance of $p < 0.01$).

Conclusion: Evaluation of neuroradiological parameters within this revised CT score has a high predictive value in relation to outcome in patients with craniocerebral trauma.

KEY WORDS:

Marshall, Rotterdam CT score, Outcome, Traumatic brain injury,

EARLY OUTCOME IN PATIENTS WITH SEVERE TRAUMATIC BRAIN INJURY

Jankovic D¹, Taskovic J², Kovacevic V³, Savic A², Bascarevic V², Rasulic L²

1) Clinic of Neurosurgery, Clinical Center Osijek, Osijek, Croatia

2) Clinic of Neurosurgery, Clinical Center of Serbia, Belgrade, Serbia

3) Center for Neurosurgery, Clinical Center Kragujevac, Kragujevac, Serbia

INTRODUCTION: Severe traumatic brain injury (sTBI) constitutes a major health and socioeconomic problem throughout the world. sTBI is defined as a brain injury resulting in a loss of consciousness of greater than 6 hours and a Glasgow Coma Scale of 3 to 8. Epidemiology of traumatic brain injury is changing, due to increased motorization in developing countries and due to frequent falls in the elderly. The aim of our study is to analyse course and outcome of patients with sTBI.

METHODS: The retrospective study included all patients with severe traumatic brain injury treated at the Emergency Center, Clinical Center of Serbia during a three year period (July 2012 – July 2015). The following variables were analyzed: demographics characteristics (age, gender), Glasgow Coma Scale (GCS), Glasgow Outcome Scale (GOS) and mechanism of injury. GCS was assessed at hospital admission and patient were followed up for maximum of 30 days.

RESULTS: The study included 757 patients. Median age was 34 years (age range from 9 months to 89 years) with male to female ratio of 1.7:1. The most common causes of sTBI were road traffic accidents (71.27 %) and falls (16.82 %). At admission to hospital 21.57 % of patients were rated GCS 8, 24.41 % GCS 7, 33.30 % GCS 6, 10.35 % GCS 5, 6.84 % GCS 4 and 3.53 % GCS 3. At 30 days follow-up, 259 patients showed good recovery, 139 had moderate deficits, 189 had severe deficits and 6 were in a vegetative state. 7-days mortality rate was 21.26 %. The outcome significantly correlated with the GCS at admission. Younger patients had favorable outcome as opposed to the older patients. Among younger patients, leading cause of injury were road crashes. Falls were the leading cause of injury among older patients.

CONCLUSION: Patients age, severity of trauma, and GCS score at hospital admission are strong predictors of the outcome and prognosis of sTBI patients.

EMPLOYMENT OF PERSONS WITH DISABILITIES IN ROMANIA

Aurelian Anghelescu^{1,2}, Mihai BUSCA³, Adina CONSTANTIN⁴, Ioana ANDONE¹,
Lucia Ana Maria ANGHELESCU⁵, Gelu ONOSE^{1,2}

1) Teaching Emergency Hospital “Bagdasar-Arseni”, Bucharest

2) “Carol Davila” University of Medicine and Pharmacy, Bucharest

3) SC Fiatest SRL, Legal adviser, Bucharest

4) General Directorate of Social Assistance and Child Protection, District 3, Bucharest

5) Anthropology department of the Sociology and Social Work University of Bucharest

Background: Promoting optimal social integration of people with disabilities, as active citizens, represents a major objective of Romanian health, social and political strategies.

Methods: Review of the official data and studies on employment of disabled people, actualized to 2015.

Results: The total number of disabled people was 759,019 (3.41% of the Romanian population). About 415,852 (59.58%) were aged between 18 and 64. Rate of employment of disabled persons is very small (14%). People with somatic disability represent the most employed category (38.4%); least employed were the mental (3.1%) and psychiatric (5.2%) categories. The number of authorized protected units (sheltered employment) increased up to 722 units (recorded in 2015).

Discussion: A terminology clarification and unification approach, at national level (between concepts of disability vs. handicap) has become a necessity. Romanian legal frame regarding labour policy and working with disabilities imposes material obligations for employers (the 4% quota system) but also offers fiscal facilities for them. Disabled persons (with accentuated and severe disability/handicap) are exempt from income tax and complementary cumulate the non-taxable income and disability benefits.

Conclusion: This original paper is an updated integrative approach to the Romanian strategy and policy of (re-)employment of people with disabilities. It underlines the main achievements, improvements and limitations in the continuous endeavor of implementation of the legislative framework on the protection, integration and inclusion of disabled persons in Romania.

Key words: disability, handicap (type, degree), inclusion, social assistance, law (no. 448)

DECOMPRESSIVE CRANIECTOMY FOR SEVERE TRAUMATIC BRAIN INJURY: CASE REPORT AND LITERATURE OVERVIEW

Igor Horvat, Petar Vuleković, Tomislav Cigić, Đula Đilvesi, Mladen Karan
Institution: Clinic of Neurosurgery, Clinical Center of Vojvodina, Novi Sad, Serbia

Introduction: Intracranial hypertension is the largest cause of death in young patients with severe traumatic brain injury. Decompressive craniectomy is part of the second level measures for the management of increased intracranial pressure refractory to medical management as barbiturate coma. Many reviews have been written discussing the relevant data for and against the use of decompressive craniectomy for severe traumatic brain injury, with the overwhelming conclusion being that randomized controlled trials are needed to resolve these disputes.

Aim: To assess the relation between clinical variables and outcome in surgically treated patients.

Material and Methods: We reviewed the cases of severe traumatic brain injuries treated with decompressive craniectomy reported in the literature and analysed potential predictors of outcome after decompressive craniectomy, including sex, age, Glasgow Coma Scale (GCS) and presence of mass lesion. We also present one case of adult male patient underwent decompressive craniectomy at our clinic, due to intracranial hypertension after severe traumatic brain injury.

Results: There is a significant improvement in favorable outcomes in patients subjected to a decompressive craniectomy. Among adult patients, studies have shown a 61% incidence of favorable outcomes after decompressive craniectomy. In our case of adult male patient, this surgical procedure have been associated with very good outcome.

Conclusion: Despite the overall degree by which different patients may benefit from decompressive craniectomy remains controversial, there are a significant evidences that decompressive craniectomy is an effective adjunct in the management of severe post traumatic brain edema. Many authors state there is no significant benefit in performing this procedure after a certain age limit, with most placing the limit at 30-50 years of age. If it is done at the right time, it improves outcomes in patients with severe traumatic brain injury.

Key words: Decompressive craniectomy, traumatic brain injury, intracranial hypertension, outcome

GROWING SKULL FRACTURES IN CHILDREN: A 10-YEAR FOLLOW UP STUDY FROM A SINGLE CENTER

Milan Mrdak¹, Mirjana Raičević¹, Dževad Sebečević², Srđan Nikolovski¹

1) Pediatric Surgery Department, University Children's Hospital, Belgrade, Serbia

2) General hospital, Novi Pazar, Serbia

Growing skull fractures (GSF) are rare clinical outcome of linear fractures in pediatric population. According to reviewed literature, the incidence of this type of fracture is 0.05-3.3%. The most of the patients are under three years of age. The most common period between initial head trauma and first symptoms of GSF is a few weeks to few months with 14 years as the longest period described so far. The most common localization is parietal region, and the most common cause described is blunt trauma to the head causing appearance of GSF on the site of applied force and with a fall as the most common mechanism of injury. According to these facts, the most important criteria for appearance of GSF is age of patient under three years, a large force applied directly to the head and dyastatic gap between bone fragments of minimum four milimeters. The most common sequellae of GSF is herniation of leptomeninges, and rarely encephalocoele. Signs and symptoms varies mostly according to the site of GSF appearance, but common nonspecific symptomathology include headache and palpabile pulsatile scalp mass.

During last ten years, seven patients were treated in our institution under diagnosis of GSF. In all cases mechanism of head injury is a blunt trauma with high force applied. Localisation of primary linear fracture was parietal region on the site of force action. In one case, there were two growing skull fractures: one on the site on force action and other on the opposite site. A fracture line gap was at least several milimeters and growing skull fracture symptoms and signes occured up to one year after primary head injury. Our results gain by desriptive analysis are similar to those shown in earlier studies.

TRAUMATIC INTRACRANIAL PSEUDOANEURYSMS TREATED BY ENDOVASCULAR EMBOLISATION

Vitošević Filip¹, Milošević Medenica Svetlana¹, Vukašinović Ivan¹,
Nestorović Dragoslav¹, Rasulić Lukas^{2,3}

1) Neuroradiology Department, Center for Radiology and MRI,
Clinical Center of Serbia, Belgrade, Serbia

2) Faculty of Medicine, University of Belgrade, Belgrade, Serbia

3) Clinic for Neurosurgery, Clinical Center of Serbia, Belgrade, Serbia

Traumatic intracranial pseudoaneurysms are rare complication of head injury, occurring in less than 1% of all patients with cerebral aneurysms and most cases are associated with fracture of the skull. Rupture of these traumatic aneurysms occur in up to 50% of all cases and are typically delayed from days to weeks following the initiating trauma. Traumatic pseudoaneurysms are often called a pulsating hematoma, which occurs when the arterial wall is ruptured by trauma and bleeding is confined only by the adventitia or surrounding tissues. Unlike the structure of a true aneurysm, that has all anatomical layers, the wall of a traumatic intracranial pseudoaneurysm is composed mainly of blood clot and a small amount of fibrous tissue.

Difficult diagnosis, delayed presentation and catastrophic outcomes contribute to overall prognosis of these traumatic intracranial aneurysms.

We present two cases with traumatic intracranial aneurysms treated with endovascular embolization in our Institution, within the last five years, and we discuss their etiology, classification, clinical characteristics and presentation, diagnosis, and treatment options and outcomes.

As traumatic intracranial aneurysms may present both diagnostic challenges and surgical difficulties, especially after polytrauma cases, rarely being appropriate for conservative treatment, early and precise diagnosis with cerebral angiography and prompt treatment are essential for good prognosis. Due to its nature to be fragile and prone to rupture, careful and precise endovascular embolization is thus a method of choice for treatment of this pseudoaneurysms.

CASE REPORT OF A RARE FOREIGN OBJECT EMBEDDED IN BRAIN TISSUE FOR 38 YEARS

Cvrkota I., Joković M, Savic D, Jovanovic N.
Clinical Center of Serbia, Clinic for neurosurgery, Belgrade, Serbia

We present a rare case of a 64 year old male who had a foreign object embedded in brain tissue that showed symptoms after 38 years of head injury.

On the admission the patient has motor dysphasia, with the right sided hemiparesis, he was able to walk with a help of another person. We got the information that the patient had a head trauma after the car accident in 1977 and was operated.

Upon the admission the CT and MRI of the brain was performed and it showed the previous craniotomy with the zone of gliosis in the left frontal lobus, and with cystic, necrotic, multicentric expansive formation in frontal lobus on the left side (superior and middle frontal gyrus), that mostly looks like primary glial tumor, or metastatic tumor.

We operated and found encapsulated foreign object - car filter originated from previous injury. The foreign object was not visible on any kind of imaging (Ct, MRI, plain radiography).

Patient was discharged from the hospital on the 20th day after the operation.

Neurological outcome was improved.

OUR INVOLVEMENT IN CENTER-TBI STUDY

Jagoš Golubović¹, T. Cigić^{1,2}, V. Papić^{1,2}, Đ. Đilvesi^{1,2}, N. Krajčinović¹, I. Horvat^{1,2}, M. Karan^{1,2}, B. Jelača¹, A. Azaševac¹, M. Fimić³, F. Pajičić¹, I. Meljnikov³, K. Kolundžija⁴, P. Vuleković^{1,2}

1) Clinic of Neurosurgery, Clinical Center of Vojvodina, Novi Sad, Serbia

2) Faculty of Medicine, University of Novi Sad, Novi Sad, Serbia

3) Clinic of Pediatric surgery, Institute for child and youth health care of Vojvodina, Novi Sad, Serbia

4) Clinic of Psychiatry, Clinical Center of Vojvodina, Novi Sad, Serbia

Introduction: Collaborative European neurotrauma effectiveness research in traumatic brain injury (CENTER-TBI) represents a focused European effort to advance the care of patients with TBI, within the broader international framework. The Clinical center of Vojvodina, Serbia is the only medical center in the region currently actively participating in this project, where multidisciplinary professionals work hard 24/7 in order to contribute to the revolution in the TBI management and care guidelines.

Aim: By evaluating study personnel's personal experiences on the aforementioned project, this paper aims to focus on advantages and disadvantages we encounter on a daily basis, to ensure that in the future the most effective work entity could be designed and conducted.

Material and Methods: We prospectively collected and analyzed data from registry data collection, core study, oral interviews and written questionnaires (for the professionals involved) which have been continuously conducted since our involvement in the project started.

Results: The analyzed information has shown that participation in this study requires on average extra 17 minutes per workday per person, while the extra effort is subjectively estimated to be 2,3-11,9%. All the participants agreed that the benefits outweigh the extra workload involved, citing: advances in TBI care, possible scientific breakthroughs, social networking opportunities and further care and professional skills development as the most valuable advantages observed after enrolling in this study.

Conclusion: Although involvement in CENTER-TBI project requires some extra time and effort, the data collected and later analyzed will undoubtedly change the way TBI is treated, resulting in better patient outcome.

Well-educated, confident professionals participating in this project will be equipped, to use their knowledge and skills to treat TBI effectively, utilizing the comprehensive database in further scientific research.

Key words: CENTER-TBI, Traumatic brain injury, Personal experiences

TRAUMATIC SUBARACHNOID HEMORRHAGE: DOES IT AFFECT EARLY OUTCOME AND WHAT ARE THE POSSIBLE RISK FACTORS? A SINGLE CENTER EXPERIENCE

Jagoš Golubović¹, B. Jelača¹, M. Fimić², S. Golubović³, V. Karan³, S. Stošić⁴,
K. Kolundžija^{3,5}, P. Vuleković^{1,3}

- 1) Clinic of Neurosurgery, Clinical Center of Vojvodina, Novi Sad, Serbia
- 2) Clinic of Pediatric surgery, Institute for child and youth health care of Vojvodina, Novi Sad, Serbia
- 3) Faculty of Medicine, University of Novi Sad, Novi Sad, Serbia
- 4) Center of Radiology, Clinical Center of Vojvodina, Novi Sad, Serbia
- 5) Clinic of Psychiatry, Clinical Center of Vojvodina, Novi Sad, Serbia

Introduction: Traumatic subarachnoid hemorrhage (tSAH) is a poor prognostic factor for traumatic brain injury (TBI). The authors aimed to investigate early outcome as well as risk factors among TBI patients by examining the prognostic values of computed tomography (CT) confirmed tSAH.

Methods: The study was conducted using a database at our institution (Clinical centre of Vojvodina, Novi Sad, Serbia). Data had been retrospectively collected in consecutive trauma patients during a 12-month period. Patients included in the study had significant head injury (as defined by a head Abbreviated Injury Scale [AIS] score of 2 or more) with admission CT. Initial CT characteristics, demographic data, GCS and anamnestic data were analyzed. The patients were divided into 4 groups: isolated tSAH, tSAH combined with other intracranial lesions, intracranial lesions without tSAH and normal CT scan-control group. Early outcome was observed at the moment of hospital demission. Multivariate Analysis of Variance (MANOVA) and Independent sample t test in SPSS were used to assess differences in outcome and to determine risk factors in TBI patients.

Results: A total of 800 TBI patients who underwent CT head scan were admitted to ER department of the Clinical centre of Vojvodina, Novi Sad, Serbia. 524 patients were male and 276 were female (65:35%), with a mean age of 56.6 (\pm 20.1) years. 270 patients had positive CT finding, of which 38 (4.7%) had isolated tSAH on admission CT, 160 (20%) had tSAH combined with other traumatic intracranial lesions and 72 (9%) had intracranial lesions without tSAH. There were 530 (66.2%) patients in control group. The mortality rate was significantly greater and early unfavorable outcome was significantly more frequent in patients with traumatic SAH, especially in group where tSAH was not the only traumatic intracranial lesion, when compared to control and intracranial lesions without tSAH groups. Glasgow coma scale showed to be significantly statistically different between groups with tSAH and control group. There was no such statistical difference between tSAH groups and intracranial lesions without tSAH group. Age, sex and comorbidities are found to play an important role in development of tSAH, while antiaggregational/antiplatelet therapy showed no significant difference between tSAH and control group.

Conclusions: Traumatic SAH was a strong independent prognostic factor for death and early clinical outcome. Higher age, male sex and additional comorbidities are risk factors for the occurrence of tSAH.

Key words: Traumatic Brain Injury, Traumatic Subarachnoid Hemorrhage, Computed Tomography, Early Outcome

CRANIOPLASTY FOR RELIEF OF CHRONIC PAIN - 70 YEARS AFTER THE DEBRIDEMENT OF THE WWII PENETRATING CRANIOCEREBRAL INJURY

Igor Popović, Vuk Aleksić, Milan Spaić

Department of Neurosurgery, University Clinical Centre Zemun, Zemun-Belgrade 11080, Serbia

We report the case of the 75 yeras old woman who suffered penetrating craniocerebral injury in the age of 5 years, caused by the explosive shrapnel wound in the parietal right side region at 1944. in WWII combat in the Kingdom of Yugoslavia. She was comatose after the injury and was treated by employing primary surgical debridement in teritorial hospital. She eventually recovered and lived normal life for 70 yeras until development of severe pain syndrome in the skin in the region of injury. The CT scan showed the cranial defect with diameter of 8 cm over the right parietal region, with cystic formation in the underlying brain consistent with sequel of the primary brain debridement. The patient suffered from severe pain, VAS /10, it was most intense on the cutaneous zone on the posterior border of the cranial defect. The skin over the cranial defect was infolded inside the skull and stretched over the bony ridge. Diagnostic local anesthetic infiltration of the skin over the posterior ridge of the craniectomy defect was done that relieved pain completely indicating the stretching of the nerves over the bony edge as the underlying mechanism of the pain. The cranioplasty that restore cranial vault convexity thus reversing the infolded skin over the craniectomy area relieved pain completely. The CT examination showed the brain tissue expanded and filled former porencefalic postdebridement cystic space. This case revealed that the cranial defect was a dynamic condition that undergone changes driven by the aging process, brain atrophy and constant atmospheric pressure across the skin over the cranial defect. The debridement technic, timing of cranioplasty are discussed. We recommend routine cranioplasty after the primary debridement of penetrating gunshot or explosive craniocerebral wound.

TRAUMA INDUCED EOSINOPHILIC GRANULOMA IN A CHILD WITH TUBEROUS SCLEROSIS

Aldin Jusić, Mirza Pojskić, Rasim Skomorac, Hakiija Bečulić, Fahrudin Alić
Department of Neurosurgery, Cantonal Hospital Zenica, Bosnia and Herzegovina

Aim To present an unusual case of trauma induced eosinophilic granuloma in a child with previous history of tuberous sclerosis.

Case report This case reports a two-years old boy with previous history of tuberous sclerosis who developed eosinophilic granuloma after a mild head trauma first considered as a subgaleatic hematoma. Previous existence of the granuloma has been excluded both clinically and neuroradiologically due to regular pediatric and MRI follow up of his main disease.

Conclusion Mild head trauma is possible cause of rapid progression of eosinophilic granuloma.

Key words: eosinophilic granuloma, mild head trauma, tuberous sclerosis

THE ROLE OF ROBOTS IN THE (RE)HABILITATION OF CHILDREN WITH BRAIN INJURY

Krasnik R^{1'3}, Mikov A^{1'3}, Golubovic S¹, Borovac B², Milojevic A³, Meljnikov I³

1) Medical Faculty, University of Novi Sad, Serbia,

2) Faculty of Tehnical Sciences, University of Novi Sad, Serbia,

3) Institute of Children and Youth Health Care of Vojvodina, Novi Sad, Serbia

Introduction. The rehabilitation process involves a whole team of experts who participate in it over a long period of time. Development of Robotics and its Application in Medicine. The Intensive development of science and technology has made it possible to design a number of robots which are used for therapeutic purposes and participate in the rehabilitation process. Robotics in Medical Rehabilitation. During the long history of technological development of mankind, a number of conceptual and technological solutions for the construction of robots have been known. By using robots in medical rehabilitation it is possible to implement the rehabilitation of central motor neurons by increasing the motivation of patients for further recovery and effectiveness of therapy. The paper presents some technological solutions for robot-assisted rehabilitation of patients of different age groups and some possibilities of its use in the treatment. Also, it will be present robot MARKO which is specially design for (re)habilitation of children.

Conclusion. Using robots in standard physiotherapy protocols that involve a number of repetitions, exact dosage, quality design and adaptability to each individual patient leads to the significant progress in the rehabilitation of patients.

NERVE GRAFTING IN PERIPHERAL NERVES INJURIES IN CHILDREN

Author: Novak Lakićević, PhD, Clinic of Neurosurgery, Clinical Centre of Montenegro (Ljubljanska bb, Podgorica, Montenegro);

Co-authors: Irena Cvrkota**, Slavko Đurašković*, Boris Đurović*

Institutions: * Clinic of Neurosurgery, Clinical Centre of Montenegro (Podgorica, Montenegro);

**Clinic of Neurosurgery, Clinical Centre of Serbia (Belgrade, Serbia)

Introduction: The results of reconstructive procedures after nerves injuries in children are generally better than in adults, presumably due the brain plasticity and nerve repair potential. There are no important differences regarding diagnostic and management approach to peripheral nerve injuries among the pediatric and adult patients.

Aim: The aim of this study was to analyze the outcome of nerve repair in patients less than 16 years old, previously faced with peripheral nerve transections and lacerations.

Method: We analyzed 27 children who underwent surgery after nerves injuries. Patients follow up after the surgery was 2 to 5 years. The evaluation of motor and sensor function was achieved by using the scale of Hightet and Millesi. Final results were classified into three groups: good, fair and bad. Additionally, factors that influenced microsurgery outcome and nerve recovery were analyzed, such as: timing of surgery, site and type of nerve injury, presence of associated injuries, length of nerve gap and type of microsurgical techniques.

Results: Out of 27 patients who underwent surgery, 19 was treated by interfascicular grafting and 8 by cable grafting. The mean patients age was 11.26 years. The motor outcome following the surgery was: good 77.8%, satisfactory 14.8% and bad 7.4%. The sensor outcome following the surgery was: good 85.2%, satisfactory 7.4% and bad 7.4%. Good motor outcome regarding the time of surgery was: <3 weeks 100%, between 3 weeks and 3 months 77.8%, between 3-6 months 84.6%, between 6-12 months 50% and after 12 months 0%.

Conclusion: End to end anastomosis is the superior method for nerve reconstruction, but in the cases where the tension on the anastomosis could be severe, nerve grafting is the treatment of choice. Major conditions of functional recovery after nerve reconstruction are: early timing of surgery (in first three months) nerve gap length below 5 cm and physical therapy. Importance of early and adequate treatment of peripheral nerve injuries in childhood is to enable normal growth and development of the child and to prevent permanent disability.

Key words: nerves grafting, nerves injuries in children, recovery outcome

DEPRESSION IN PATIENTS WITH MILD TRAUMATIC BRAIN DAMAGE

Bugarski Ignjatović V.¹, Nikolašević Ž.², Karan M.³,
Vuleković P.³, Nikolić M.¹, Azaševac A.³

¹Neurology Clinic, Faculty of Medicine, University of Novi Sad

²Department of Psychology, Faculty of Philosophy, University of Novi Sad

³Neurology Clinic, Faculty of Medicine, University of Novi Sad

Introduction: Mild traumatic brain damage is often accompanied by depression symptoms within one year of the injury. The prevalence of depression disorders in traumatic brain injuries is significantly higher than the incidence of depression disorders in the general population. Research suggests that this prevalence can be as high as 35%. The manifestation of depression symptoms often remains unrecognized due to certain similarities between these symptoms and mild traumatic brain injury. Consequently, there is more and more need for timely diagnostic and therapy considering the negative influence of depression symptoms on life quality, working capability and the recovery process.

Method: The research sample consisted of 25 patients of both sexes, aged 18 to 64, with mild traumatic brain injury. The patients' affective status was assessed in two phases, one and six months after the injury. The presence of depression symptoms was assessed using form II of Beck's scale constructed for the assessment of depression.

Results: The results of the study suggest that one month after the traumatic brain damage, 12% of patients developed mild depression symptoms, while 4% of patients developed moderate symptoms of depression. 84% of patients did not develop clinically significant depression symptoms. Six months after the injury, 92% of patients did not show clinically significant presence of depression symptoms, while 4% showed mild symptoms, and 4% developed symptoms of severe depression.

Conclusion: Mild traumatic brain injury is accompanied by mild to moderate depression symptoms in 16% of patients one month after the injury. However, six months after the injury, 8% of patients developed mild to severe depression symptoms. The results of this study are in accordance with previous studies and suggest that the depression symptoms gradually decrease within six months of the injury, and that these symptoms can persist in a number of patients after this period.

Key words: depression, mild traumatic brain damage, Beck's Depression Scale

QUALITY OF LIFE ASSESSMENT IN PATIENTS WITH MILD TRAUMATIC BRAIN DAMAGE

Nikolašević, Ž.¹, Bugarski Ignjatović, V.², Karan, M.³, Vuleković, P.³, Nikolić, M.¹, Đilvesi, Đ.³

¹Department of Psychology, Faculty of Philosophy, University of Novi Sad

² Neurology Clinic, Faculty of Medicine, University of Novi Sad

³ Neurosurgery Clinic, Faculty of Medicine, University of Novi Sad

Introduction: Quality of life reflects the subjective experience of a person as the illness and treatment affect physical, psychological and social aspects of a person's life. Assessing life quality is recognized as a significant outcome of traumatic brain damage, primarily because it provides information about the tempo of recovery, frequency, nature and predictive factors that lead or contribute to disability. General/Generic, questionnaires are the most frequently used for the assessment of life quality of these patients.

Method: The research sample consisted of 25 patients with mild traumatic brain injury, of both sexes, aged 18 - 64. Life quality was assessed using the General/generic questionnaire for assessing life quality, the SF-36, in two turns, one and six months after the injury. Eight aspects of life quality were assessed: Physical functioning, Emotional and Social well-being, Limitations due to physical health, Limitations due to emotional issues, Pain, Energy/Fatigue and General health.

Results: The Wilcoxon Rank-Sum test showed no significant difference between the first and second measurement in all eight variables. Results showed no significant improvement or decrease in all aspects of life quality six month after the injury.

Conclusion: These results can be interpreted from two different perspectives. For one, mild traumatic brain damage initially doesn't interfere with the life quality of these patients, at least not as much as moderate or significant traumatic damage would, which could explain the absence of the expected improvement in the life quality six months after the injury. On the other hand, the choice of generic questionnaires for assessing life quality is not adequate, because they are not sensitive enough to detect specific aspects and consequences of traumatic damage. Assessment via specific life quality questionnaires could be more sensitive to certain aspects specific for trauma, and could prove to be more adequate for assessing the trauma effects on general life quality.

Key words: Quality of life, general SF-36 questionnaire, mild traumatic brain injury.

Novi Sad 2016

One Region, One Neurosurgery

Friday, October 21st / Hall 1

Friday, October 21st

ABSTRACTS

MAIN SESSION 2

Hall 2

ENDOSCOPIC SPINE SURGERY FOR TRAUMATIC DISC HERNIATION

Robert Saftić

Aksis - special hospital for spine surgery and orthopaedics,
Neurosurgery Department, Zagreb, Croatia

An analysis of the carefully taken histories of 800 patients whose disc lesion was verified at operation showed that 5% of them gave a history of trauma at the onset of pain syndrome. The forces were usually strong and the mechanism of injury can be divided in sport injury and lifting injury. Out of 40 analysed patients there were 18 patient coming from sport injury and 12 patients with lifting injury. All patient presented with strong pain resistant to pain medication and conservative treatments. Besides strong anamnestic data all patients were presented with T2 MRI high signal intensity mass in spinal canal.

All patients were operated with transforaminal endoscopic approach in local anaesthesia. Operation time, x-ray exposure, VAS score and Oswestry score (ODI) were measured.

Average operation time was 50 minutes and fluoroscopy exposure was 20 seconds. Success rate was 94%. There was no neurological deficit. There were no reherniation in one year follow up.

To achieve good result and to use endoscope with certain amount of confidence in traumatic disc herniation, we need previous training. I like to divide training period in theoretical phase, practical cadaveric training, practical training with tutor and sufficient period of self-performing surgery starting with smaller herniation and simple cases. At the beginning crucial stuff are previous experience with all around spine surgery and awareness of self-limitation which will help you to protect yourself and your patient.

SURGICAL MANAGEMENT OF SUBAXIAL CERVICAL FRACTURES

Olldashi F, Hodaj I, Selaj A, Bendo N, Spaho E, Hodo P.
University Hospital of Trauma, Tirana, Albania

This study was a retrospective review of the surgical management of subaxiale cervical fractures in the Neurosurgery Clinic of the University Hospital of Trauma during the period of 2006-2015. In the following 10 year, in our clinic have been treated about 220 cases, from which 180 males and 40 females. The patients age range from 14-78 old, with an average of 35 years old. Trauma is usually caused by car accident, falls from altitude, jumps into the sea with head, fall from stairs or bicycle. The neurological state of the hospitalized patients has been conducted based on ASIA scale. 114 of patients were hospitalized with ASIA E, 54 ASIA: A, 8 ASIA: C, 5 ASIA: D, 5 ASIA: B, 30 patients were hospitalized with the central cord syndrome and 4 patients with brown sequard syndrome. Only 205 patients were treated with anterior and 15 with posterior approach. 71 patients underwent anterior corpectomy and 134 were treated only with anterior decompressive discectomy. In 55 patients PEEK CAGE and 150 patients iliac bone was used. The surgical management of subaxiale cervical fractures aims the decompression of the nerve structure and fixation of the cervical spine in the correct and stable position. This procedure may be realized with anterior approach, which is an effective, safe, and less expensive method in our case. In addition, anterior approach is associated with minimum of complications and high probability of bony fusion.

BASIC PRINCIPLES OF THE INSTRUMENTALIZATION OF OLD POST-TRAUMATIC CHANGES IN THE CERVICAL SPINE

Nebojša Stojanović

Clinic of Neurisurgery Niš, Clinical Centre Niš, Serbia

The modern way of life and a better diagnostic approach led to a significant increase in the detection of disease in the cervical spine. Adequate access to timely diagnosis and treatment are the basis for a positive outcome and prevention of complications.

Present neck pain without neurological prolapses after a neck injury, not always adequately considered. At a later stage, because of the compression Syndrome may develop cervical myelopathy. Solving late post traumatic lesions of the cervical spine often require complex surgical technique, a combination of anterior-to-posterior or posterior-anterior approach, but in some cases it is necessary and triple operational approach, anterior-posterior-anterior or -posteriorni-anterior -posterior approach.

Changing medical doctrine towards resolving the compressive changes in cervical kičmekičme may be a prerequisite for preventing the development of severe neurological deficits, and to prevent long-term socio-economic relations in this group of patients

THE INFLUENCE OF ANTERIOR INTERBODY FUSION WITH ALLOGRAFT ONTO CERVICAL SPINE FUNCTIONAL OUTCOME

G. Lakicevic, B. Splavski, I. Bulic

Department of Neurosurgery, Mostar University School of Medicine, Mostar, Bosnia and Herzegovina, and Osijek University School of Medicine, Osijek, Croatia

Aim: To analyze the influence of anterior interbody fusion with allograft onto clinical status and surgical management outcome of patients with the cervical spine disease.

Material and methods: A cohort of 60 consecutive patients who were operated on by the anterior interbody fusion with allograft at one cervical level during a four-year period was prospectively analyzed. Monosegmental cervical disc herniation was diagnosed by magnetic resonance imaging (MRI) and surgery was performed in all patients. The analyzed parameters were: age, gender, level of intervertebral disc herniation, duration and intensity of pain in the neck and arms (VAS, ODI), personal habits, postoperative quality of life (ODI) and surgical outcome (Odom). The data were obtained by a structured questionnaire of all patients who were voluntarily interviewed before and 3 months after surgery.

Results: They were most often operated on at C5/C6 cervical level (51.7%). Following surgery, the minimum degree of disability (0-20%) was seen in the majority of patients (75%). There was a significant decrease in number of patients having everyday severe disability (from 61.7% preoperatively to 1.7% postoperatively) or total disability (from 13.3% preoperatively to 0% postoperatively). A noteworthy pain relief in the neck (78.4%) and arms (81.6%) was recorded in the largest number of patients after surgery. According to Odom criteria, the outcome of surgical management was mainly excellent (43.3%) or good (41%). The outcome was not dependent on gender, age, occupation, affected level or duration of hospitalization.

Conclusion: A significant reduction in disability, as well as a relief of the pain in the neck and arms was recording in most patients who also expressed overall satisfaction with the treatment outcome at a 3-month postoperative follow-up. Therefore, the anterior interbody fusion with allograft is a safe and valuable surgical method having a positive influence onto cervical spine functional outcome.

SPINAL INJURY, MODERN ASPECT AND CYPRUS REALITY

M. Spyrou

Ygia, Private Hospital, Limassol, Cyprus

Aim: The elaboration of conceptual approach and differential methods of preventing and treatment patients with spinal injuries.

Material and Methods: From January 2010 to 30 of June 2015. We identify 7605 patients that attended to casualty with suspicious of spinal injury. 3740 of them were admitted to the Cyprus hospitals with verified diagnose of spinal injury (spine and/ or spinal cord), (49, 1%). Among them were 3029 male (81%) and 711 female (19%). 483 had had spinal cord injury that means 8, 78 per 100.000 population/year. 3257 had vertebral injuries, that means 59, 2 case per 100.000 population /year. 288 were died, that means 5, 2 case per 100.000 population / year.

The causes of the injury were as follow: RTA 1664 (44, 5%), fall 829 (22, 1%), sport 474 (12, 7%), violence 134 (3, 6%), others 639 (17, 1%).

According to the clinical picture and the MRI results, 720 patients had had injury on the cervical spine, 1132 on the dorsal, 1597 on the lumbar and 748 had multilevel injuries.

Results: From conservative treated patients 1152 declared satisfied (all with light injuries and without complications). 88 patients with conservative treatment were died due to the complications (combine trauma). From the patients were operated 50 cases remained with tetraplegia, 83 with paraplegia, 150 with deep paresis and 200 with light paresis. All these patients were with spinal cord injury. From the patients who had surgical treatment 2367 declared satisfied.

288 patients were died, all with combine trauma, severe condition. Between them 200 were with spinal cord injury and 88 without spinal cord damage (5.2 per 100.000 populations).

The pick of traumatism was between the young people from the RTA at late night time and on the elderly women from falls, due to the osteoporosis.

The average stage in the hospital was 38, 5 days.

Conclusions: People with spinal injuries need emergency diagnose and care them in order to avoid further complications.

**ASSESSMENT OF OUTCOME IN PATIENTS WITH SEVERE TRAUMATIC
BRAIN INJURY WITH INTRAAXIAL COMPRESSIVE HEMATHOMA,
TREATED WITH DECOMPRESSIVE CRANIECTOMY.
A ONE CENTRE RETROSPECTIVE STUDY**

Filipce V.1, Caparoski A.1, Shuntov B1
University clinic of Neurosurgery,
Medical faculty University St. Cyril and Methodius Skopje,
Mother Theresa No.17, 1000 Skopje, R.of Macedonia

Abstract

INTRODUCTION.Decompressive craniectomy is widely used to treat intracranial hypertension following traumatic brain injury (TBI). The patient with severe traumatic brain injury though with less prevalence in the main population represents a great challenge in management for every neurosurgical institution and the later is followed with poorer prognosis, numerous perioperative and postoperative surgical complications and in certain cases followed by a severe disability.

OBJECTIVES. In this article we present a retrospective review of 25 cases of patients with severe traumatic brain injury treated with decompressive craniectomy for a period of one year.

METHODS. This is a retrospective study in which 25 patients were included, 11 were women and 14 were man. They all presented on admission in comatose state with signs and symptoms of severe traumatic brain injury. Patients underwent CT scan and magnetic resonance imaging on admission. All patients underwent uni- or bilateral frontotemporoparietal decompressive craniectomy with evacuation of an intraaxial haemathoma. Outcome was assessed at an interval of at least 6 months following injury using the Glasgow Outcome Scale (GOS) score.

RESULTS. A total of 25 patients underwent decompressive craniectomy for raised and refractory ICP. Three patients (12%) underwent bilateral and 22 (88%) unilateral frontotemporoparietal craniectomy. Out of all nine (36%) presented on admission with GCS score 4, six patients (24%) presented with GCS score 5 and ten patients (40%) with GCS score 8. At follow-up, 13 (52%) patients had a favorable outcome (good recovery or moderate disability), 7 (28%) remained severely disabled, and 5 (20%) died. Two patients were left in a vegetative state.

CONCLUSION. In adults with severe diffuse traumatic brain injury and refractory intracranial hypertension, early bifrontotemporoparietal decompressive craniectomy decreased intracranial pressure and the length of stay in the ICU but was associated with more unfavorable outcomes.

Novi Sad 2016

One Region, One Neurosurgery


Friday, October 21st / Hall 2

Saturday, October 22nd

ABSTRACTS

KEY NOTE LECTURES

Hall 1



Franco Servadei

President-Elect, WFNS
Director of Neurosurgery - Neurotraumatology
Maggiore Hospital University of Parma, Italy

Prof. Servadei completed his Neurology residency in 1980 in the University Hospital of Bologna, Italy, and then his Neurosurgical residency in the Bellaria Hospital of Bologna, Italy. He has served as an attending neurosurgeon in the Bellaria Hospital in Bologna, Italy, in the Royal Infirmary in Edinburgh, Scotland, in the Bufalini Hospital in Cesena, Italy. He has served as a Professor of Neurosurgery in the University Hospital of Ancona, Italy, the University Hospital of Catania, Italy, and the Bufalini Hospital of Cesena, Italy.

He is currently the Director and the Chairman of the Departments of Neurosurgery and the Emergency Medicine of the University Hospital of Parma, Italy. He has been honorably served as a member of the executive committee of the European Brain Injury Consortium, as Chairman of the Neurotrauma Committee of the World Federation of Neurosurgical Societies, as National Official Delegate of the Neurotrauma Committee of the World Federation of Neurosurgical Societies, as well as a member of a selected group of experts of the Brain Trauma Foundation. Prof. Servadei has contributed more than 150 high-impact articles in various, highly prestigious peer-reviewed journals, several monographies, and chapters in well-respected neurosurgical textbooks, and has been awarded with numerous grants and honors. He has served as the Director of the Trauma System Committee of the Regione Emilia Romagna, as the Director of Trauma Care of Region Emilia Romagna, as Member of the Italian National Commission for Guidelines Development, while he was the organizer and the Chief Clinical Officer for the development of the telemedicine system of the Regione Emilia Romagna.

ICP MONITORING : A CONTRAVERSIAL ISSUE FOR THE NEUROSURGEONS

Franco Servadei

Director Neurosurgery and Neurotraumatology
University Hospitals of Parma and Reggio Emilia
Parma, Italy
President Elect WFNS

The first set of published guidelines on severe head injuries management (BTF 1996, confirmed , 2003 and 2007) contained a class 2 statement about when to insert an ICP Monitoring in TBI patients : comatose cases (GCS 3 to 8) with an abnormal CT . There was also an option grade 3 to insert the monitoring in a subset of normal CT patients but this was never followed in Europe. As far as the treatment cut off , it was established (class 2) at 20 mm of Hg . Anyway as grade 3 suggestion , it was already stated that a combination of ICP values and clinical and brain CT findings may be used to make management decisions , therefore reducing the value of ICP monitoring “per se “ .

Unfortunately the last sentence was disregarded and ICP insertion and treatment of ICP values above 20 mmHg became “per se” an index of quality in managing severe TBI patients in spite of the fact that no study clearly demonstrated an association between ICP treatment and better outcomes.

From 2003 a number of papers were published questioning the value of ICP driven management of TBI patients . More, two recent randomized prospective studies showed : 1) The DECRA study that the outcomes of patients with reduced ICP was even worse that of patients with higher ICP and 2) the Best trip Trial that severe TBI patients treated with or without ICP monitoring had similar outcomes.

The pathophysiology of severe traumatic brain injured patients is complex and it is hard to believe that the treatment of a single magic number (ICP level) would be the only base for management.

We agree with many comments that ICP is one part of the TBI management , whereas the other ones are clinical evolution, radiological evolution, CBF studies, Tissue Oxygen studies

The Milano Consensus conference on ICP management contained new indications for ICP monitoring including NO indications in patients with normal CT scan and in patients with small pethechial hemorrhages and / or isolated SAH .

In conclusion we believe that ICP monitoring is a life saving procedure especially in cases where the surgeons is in doubt about surgical indications (evolving contusions, decision about secondary decompressive craniectomies...) . The use of ICP with a wrong cut off in patients with limited risk of intracranial hypertension has been proved to be unffective for the patients' prognosis



Prof. dr Marko Bumbaširević

Professor of Orthopaedic Surgery and Traumatology
 Chair of Orthopaedic Surgery Department, School of Medicine University of Belgrade
 Head of the Department of Reconstructive Surgery and Microsurgery at Clinic of Orthopaedic
 Surgery and Traumatology, Clinical Centre of Serbia, Belgrade

Prof. dr Marko Bumbaširević is Professor of Orthopaedic Surgery and Traumatology, Founder and President of Serbian Orthopaedic Trauma Association (SOTA), Founder and President of Serbian Association for Hand Surgery (SAHS) and Founder and President of Serbian Association for Reconstructive Microsurgery (SARM)

He is also a National Delegate of European Federation of National Associations of Orthopaedics and Traumatology (EFORT), Member of EFORT Finance Committee, Chairman of SICOT Orthopaedic Microsurgery Subspecialty Committee, National Delegate of International Society of Orthopaedic Surgery and Traumatology (SICOT).

He published more than 350 publications and he is on many editorship positions, such as Assistant Editor in Chief European Journal of Orthopaedic Surgery & Traumatology (EJOST), Reviewer of The Journal of Bone and Joint Surgery, Member of Editorial Boards: Orthopaedics and Trauma (former Current Orthopaedics), Romanian Journal of Reconstructive Microsurgery.

Professor Bumbaširević is honorary member of many professional association in the field of Orthopaedic and Traumatology.

RECONSTRUCTION OF THE SEVERELY INJURED LIMBS

Marko Bumbaširević
Clinical Centre of Serbia,
Clinic of Orthopaedic Surgery and Traumatology,
Belgrade, Serbia

Severely limb injury is caused by cutting, tearing, or crushing making it unrecognizable. There are two treatment options, amputation or salvage reconstruction. With advances in our understanding of human physiology and basic science, and with the development of new fixation devices, modern microsurgical techniques and the possibility of different types of bony and soft tissue reconstruction, the clinical and functional outcomes are often good, and certainly preferable to those of contemporary prosthetics. Early or even immediate (emergency) complete upper extremity reconstruction appears to give better results than delayed or late reconstruction and should be the treatment of choice where possible. Before any reconstruction is attempted, injuries to other organs must be excluded. Each step in the assessment and treatment of a mangled extremity is of utmost importance. These include radical tissue debridement, prophylactic antibiotics, copious irrigation with a lavage system, stable bone fixation, revascularization, nerve repair, and soft tissue coverage. Nerve repair is very important because without return of good sensibility and motor function, limb reconstruction cannot be considered as a successful one. Well planned and early rehabilitation leads to a better functional outcome. Despite the use of scoring systems to help guide decisions and predict outcomes, the decision to reconstruct or to amputate still ultimately lies with the surgical judgment and experience of the treating surgeon.



Prof. Francesco Tomasello

Second Vice-President, WFNS (EANS)
Clinica Neurochirurgia, A.O. Universitaria “G. Martino”, Messina, Italy

Francesco Tomasello, MD (University of Messina, School Medicine, 1970) was most recently Dean of the Faculty of Medicine, University of Messina, Italy, until 2004. Previously he was Director, Residency in Neurosurgery Program, Neurosurgical Clinic, University of Messina Medical School. From 2004-2013, he was Rector of the University of Messina

In 2004, Professor Tomasello was President of the Italian Society of Neurosurgery.

From 1995–1999, he was Vice-President of the European Association of Neurosurgical Societies (EANS). Professor Tomasello was also a consultant to the Italian Ministry of Health in 2003, and in 2004 was elected a member of the Congress of Neurological Surgeons (USA). He is currently WFNS Second Vice-President for Europe.

Prof. Tomasello is author of over 150 reviewed international publications in MEDLINE and 4 monographs in English.

He has performed more than 10,000 neurosurgical interventions. He has also been president of numerous neurosurgical congresses and meetings.

NEW CHALLENGE FOR NEUROSURGICAL EDUCATION AND RESEARCH IN THE GLOBAL SCENARIO: AN EUROPEAN PERSPECTIVE

Francesco Tomasello
University of Messina, ITALY

Training in neurosurgery is changing very rapidly with reference to the fundamental knowledge, scientific application, diagnostic skill and surgical technique. Apart the cadaver labs, new technologies are introduced in the training programs as virtual reality and simulators. Residents demand a more effective learning curve according to changing paradigms in the neurosurgical treatment. An insight in research and innovation is an important aspect in the training programs because residents should be introduced to creativity applied to standard neurosurgical procedures, without expectations exceeding the reality.

Research and training in Neurotraumatology run a great advance due to investigation of biomolecular markers and potential neuroprotective agents and to state-of-art in neurosurgical critical care.

The European educational programs achieved a high standard profile and can be driver of cooperation with low income countries.



Nada Andelic, MD; PhD

Dr. Andelic is a physiatrist and senior researcher at the Department of Physical Medicine and Rehabilitation, Oslo University Hospital (OUH) and the CHARM - Research Centre for Habilitation and Rehabilitation Models and Services, University of Oslo, Norway. She is a Head of Research and Development and a PI and/or co-PI in several large TBI studies such as Collaborative European NeuroTrauma Effectiveness Research in TBI, CENTER-TBI at Oslo site, the Norwegian Multicentre Study on severe TBI and regional longitudinal studies on mild, moderate and severe TBI.

Dr. Andelic has an extensive professional career, where she has been involved in different areas of Physical Medicine, Rehabilitation and Rheumatology both in Montenegro (1982-1992) and Norway (since 1993). Since 1997, she has worked in the field of specialized multidisciplinary rehabilitation of patients with multiple trauma and brain injuries. Alongside this, she has had several positions such as Chief Physician and Head of Department, as well as a leader position of a multidisciplinary rehabilitation team.

Her main research areas are risk factors of TBI, short and long-term functional outcomes and HRQL, rehabilitation trajectories and health service utilization. Dr Andelic has authored and coauthored more than 50 research articles. She serves as peer reviewer for more than 20 journals and several Granting Agencies and Foundations worldwide.

TRENDS AND CHALLENGES IN REHABILITATION FOLLOWING TRAUMATIC BRAIN INJURY

Nada Andjelic

Oslo University Hospital, Physical Medicine and Rehabilitation Department, Oslo, Norway

Significant numbers of patients with traumatic brain injury (TBI) have long-lasting disabilities following injury. In order to understand the extent of disability, it is necessary to identify an accurate documentation of acute and rehabilitation TBI care, outcomes and needs for health care services. However, the rehabilitation care often is limited to a clinical examination, advice and in some cases physical therapy. There is a limited literature on the effectiveness of rehabilitation care pathways in TBI. US estimates suggest that the treatment and conventional rehabilitation after TBI is expensive, and new models are needed to evaluate the effectiveness of different treatment and rehabilitation strategies. Greater knowledge on this issue may improve the prioritization and development of treatment and rehabilitation programs for TBI.

In recent years, the global trend toward evidence-based medicine has inspired many new efforts in TBI rehabilitation in Scandinavian countries. There is a growing body of knowledge showing that intensive interventions may lead to gains in the acute phase, and that early rehabilitation is associated with better outcomes and overall cost savings. An effective combination of medical and rehabilitation efforts appears to produce shorter hospital stays, and better living situations for patients with severe TBI. The current trends in rehabilitation care and effectiveness of care pathways in patients with TBI will be discussed at the congress, and illustrated by data collected in the Trauma Referral Center in South-East part of Norway.

Novi Sad 2016

One Region, One Neurosurgery

Saturday, October 22nd / Hall 1

Saturday, October 22nd

ABSTRACTS

PLENARY SESSION

Hall 1

TOWARDS A NEW GOLD STANDARD TO IMPROVE TBI CLINICAL RESEARCH – CAPTAIN TRIAL DESIGN AND RATIONALE

Dafin F. Muresanu^{1,2}, Stefan Florian¹, Dana Slavoaca², Johannes Vester^{2,3}

1) “Iuliu Hatieganu” University of Medicine and Pharmacy Cluj-Napoca, Romania

2) RoNeuro Institute for Neurological Research and Diagnostic

3) Senior Consultant Biometry and Clinical Research,
idv Data Analysis and Study Planning, Germany

Is TBI clinical research stifled by backward oriented designs? Recent reports from interdisciplinary working groups consisting mostly from neurologists, neurosurgeons, neuropsychologists, and biostatisticians, state that to create improvements in TBI treatment, important methodological lessons from the past must be taken into account in future clinical research. An evaluation of neuroprotection intervention studies conducted in the last 30 years has determined that methodological design flaws are major reasons why pharmacological agents fail to demonstrate efficacy.

Almost all the inconclusive studies used a single outcome measure approach. This classic approach in clinical TBI trials cannot capture all clinical relevant functional information in survivors of any kind of TBI. Even survivors of mild to moderate TBI may experience lifelong disturbances in the physical, behavioral, emotional, cognitive (memory, attention, reasoning, communication and planning), motor, sensory, perception and social domains of life that may affect specific or global functioning.

Leading interdisciplinary research groups recently highlighted the multidimensional nature of TBI, such as, e.g., the International Mission on Prognosis and Clinical Trial Design in TBI (IMPACT), stating that “outcome after TBI is by definition multidimensional” or the US Traumatic Brain Injury Clinical Trials Network Group, pointing out that “multiple measures are necessary to address the breadth of potential deficits and recovery following TBI”.

Multidimensional analysis opens a completely new direction for clinical and statistical thinking and is perhaps much closer to the complicated reality of outcome after traumatic brain injury than the previous “one-criterion paradigm” which ruled clinical research on neuroprotective treatments for the last decades. It is thus fortunate that new data analysis procedures are available that are appropriate for this important new multidimensional approach.

Currently, the most promising TBI Clinical Trial, with cutting edge state of the art protocol design, is CAPTAIN Trial.

A brief overview on protocol design and current status of the trial will be also presented.

ENDOSCOPIC MANAGEMENT OF OPTIC NEUROPATHY IN CRANIOFACIAL TRAUMA

Nicolas Foroglou

Aristotle University of Thessaloniki, 1st Department of Neurosurgery, AHEPA University Hospital, Thessaloniki, Greece

Optic Neuropathy (ON) occurs in up to 5% of all closed head injuries and up to 10% of craniofacial fractures. A variety of surgical approaches have been proposed for decompression of the optic nerve within the optic canal, like craniotomy \ un-roofing of the canal, extranasal transtethmoidal, transorbital, transantral and intranasal microscopic approaches. The introduction of rigid endoscopes and image guided surgery in recent years, have open a new therapeutic window in the management of traumatic ON. Endoscopic Optic Nerve Decompression (EOND) is becoming the procedure of choice given its reduction in morbidity, preservation of olfaction, superior cosmetic result, rapid recovery time and less operative stress for the poly-trauma patients.

The procedure is indicated in patients with persistent visual loss, failure of trial with high dose steroids and presence of fracture in the optic canal, hematoma of the optic nerve sheath or compressive hematoma of the orbital apex demonstrated on CT. Patients without fracture or hematoma are sometimes considered for EOND when nerve oedema in the canal is demonstrated in MR. The only absolute contra-indication is long-standing complete optic nerve atrophy on funduscopy as vision restoration is not possible.

Thorough preoperative study of a high resolution CT imaging is imperative for preoperative planning. The procedure consists of a standard fashion endoscopic ethmoidectomy followed by diamond drilling of the medial and inferior wall of the optic canal. The optic nerve sheath is decompressed 1800 medio-inferiorly. Further decompression of the nerve from a sheath incision is not advocated due to a high risk of nerve or ophthalmic artery injury and CSF leak.

In conclusion EOND is a relatively straightforward procedure for the experienced endonasal endoscopist. The procedure appears to have a high rate of vision restoration in the setting of ON in cranial trauma not responding to high dose steroids.

MOOD DISTURBANCES AFTER SEVERE TRAUMATIC BRAIN INJURY

Zaitsev O.S., Maksakova O.A., Khrenkova E.S., Kormilitsina A.N., Kamenetskaya M.I.
Burdenko Neurosurgical Institute, Psychaitric studies Department, Moscow, Russia

Relevance of the research is explained by high frequency of emotional disorders after severe traumatic brain injury (TBI), their influence on the rehabilitation process, patients' quality of life.

Objective: To study variants of emotional pathology in the process of recovery of mental activity after severe TBI.

Material and methods: Clinical dynamic registrations of emotional disorders in 153 patients with severe TBI admitted to hospital in coma (Glasgow Coma Scale score 3-7 in the first days after trauma) who survived in the first six months after injury and emerged from unconsciousness are presented.

Results: Probability of occurrence of different emotional disorders in the studied group was found as follows: apathy (46%), euphoria (33%), dysphoria (26%), depression (48%), anxiety (38%) and hyperthymia (6%). The most common sequence of their occurrence after coma was: apathy – euphoria – dysphoria – depression – anxiety. We found out that marked depression, mania and anxiety were rarely observed in patients with deep brain structure lesions (subcortical and brainstem). Based on the relationship between localization of post-traumatic brain changes and the probability of occurrence of different variants of emotional disorders, the following tendencies were marked: apathy was more frequent in cases of left frontal lobe lesions, euphoria – in cases of right frontal lobe lesions, depression was most expected for lesions in the posterior part of the right hemisphere, while anxiety – of the left one.

According to our analysis, patients with apathy and dysphoria showed poor recovery, while patients with depression and hyperthymia – good recovery.

Changes in the emotional state have proved to be not only a valuable diagnostic and prognostic sign, but the signal to modify the rehabilitation program, including relevant psychotherapeutic techniques and special team interventions. The set of cognitive problems in patients, in particular, the lack of understanding of their own deficits as well as possible misinterpretation of certain behavioral pattern motives by medical staff and relatives should be specially considered.

Pharmacotherapy should be individualized for each patient with emotional pathology after posttraumatic coma, and tricyclic antidepressants and benzodiazepines should be excluded.

SEVERE TRAUMATIC BRAIN INJURY: LOOKING FOR SOLUTIONS... FINDING NEW PROBLEMS?

Alberto Delitala, M.D., Stefano Signoretti, M.D.

Dept. Neurosciences-Head and Neck, San Camillo-Forlanini Hospital, Roma, Italy

Traumatic Brain Injury (TBI) is an important public health issue and one of the leading causes of death and disability around the world, as well as it is the primary cause of disability in people under age 40. An estimated 57 million people worldwide have been hospitalized with one or more TBIs, but the proportion living with TBI-related disability is not known. The leading causes of TBI are nowadays falls, followed by motor vehicle crashes, and assaults. Blasts are a leading cause of TBI among active duty military personnel in war zones.

The best management of such an enormous number of patients is continuously under debate and modern strategies either focused on the centralization of all patients in one neurosurgical hospital, or on the selection of the patients in a previous general hospital through tele-counselling. The "Hub & Spoke" system provides one high specialized trauma center (Hub) and several peripheral hospitals (Spokes) all connected with telemedicine systems and equipped with shared protocols for the management of the patients. However, the quality of the imaging, the feasibility of the sharing-pictures and the software play a tremendously important role on the efficacy of this last organization. Despite a net, undisputed amelioration of the surgical techniques, the timing of the surgical intervention and the post-operative intensive care, the prognosis of severe TBI has not much changed in the last 30 years and in terms of "dicotomized" outcome we are still facing a 50% of poor outcome (including deaths and severe disability).

The influences of using intracranial pressure (ICP) monitoring on the prognosis of patients with severe TBI has been recently challenged, however it still remains a pivotal parameter to monitor in the acute phase, and what needs to be modified is rather the treatment protocol. When ICP elevation is due to mass effects from hematomas, or acute hydrocephalus, surgery is generally the best way of treatment; however diffuse brain swelling still poses formidable problems of management, considering that in the last 50 years not even one drug or combination of them has revealed to be efficacious. Within this dramatic scenario, decompressive craniectomy (DC) has become a routine procedure, demonstrating promising results in reducing ICP. Primary DC, consisting in leaving a large part of the skull out, usually after the evacuation of an intracranial hematoma, is essentially a preventive act, aimed to overcome the eventual brain swelling, while secondary DC is often undertaken during the ICU staying as part of a tiered therapeutic protocol for refractory intracranial hypertension. It is undeniable, however, that both these procedure need to be sustained by scientific evidence, still lacking in the current times. On the other hand the possible complications and the risks of performing inappropriate DCs is rather evident. Ultimately, survivors after DC must undergo the Cranioplasty, a surgical procedure encumbered by 20-25 % of serious, even life-threatening complication. Last, but not least, severe TBI is responsible for hydrocephalus, a condition that significantly contributes to poorer prognosis. The controversy on its origin and pathophysiology are again in continuous upgrading and still we do not know if we're shunting too few or too many of these patients. Again, when the benefit is still unknown, the possible complications are instead very well addressed.

The 21st century has been marked by the effort of developing the evidence base for ICP monitoring, DC, Cranioplasty and Post-traumatic Hydrocephalus, but sometimes it looks like every solutions conceals new problems.

THE MODERN CONCEPT OF MEDICAL REHABILITATION IN PATIENTS AFTER TRAUMATIC BRAIN INJURY

Gordana Devecerski

Faculty of Medicine, University of Novi Sad, Clinic for Medical Rehabilitation, Clinical Center of
Vojvodina, Novi Sad, Serbia

The need for specialist rehabilitation services after traumatic brain injury (TBI) continues to emerge and was given especial emphasis during the 1990s because life expectancy is often near normal, the role of rehabilitation is potentially crucial if it can maximise quality of life. TBI is an insult to the brain stemming from an external physical force and resulting in either temporary or permanent impairment, functional disability, or psychosocial maladjustment. Beside the neurologic examination, the examination should also evaluate muscle strength, tone, and coordination and mobility. After the acute phase, it is important that the clinician review the potential pharmacologic management and combine this with an interdisciplinary group of therapies. Rehabilitation is important for the restoration of range of motion of the lower extremities, issues of wheelchair use may be important for those with sufficient impairment of mobility and ambulation training with the appropriate assistive device. Occupational therapy addresses the preservation of joints when a lack of strength or an excess in tone or spasticity threatens a joint. The issues of self-care, including daily activities must pay attention and emphasize the need for a planning strategy for the patient. Early in the care of the patient, the ability to swallow safely may need to be addressed. In addition, the speech pathologist, ideally working with the neuropsychologist, identifies focal cognitive needs of the patient and addresses these over a length of time. Vocational rehabilitation counselors can evaluate a patient's skills and determine the need for training. For spasticity, local injections with phenol or botulinum toxin may be preferable to oral medications, or in severe cases an intrathecal pump may be considered for continuous infusion of baclofen into the cerebrospinal fluid.

DBS FOR COGNITIVE NEUROMODULATION

Acar Feridun,
Pamukkale University, Department of Neurosurgery, Denizli, Turkey

It is known more than a half century that the effect of central thalamic deep brain stimulation to restore consciousness in patients within coma and vegetative state by changing the arousal state. Also, Central thalamus has been related in working memory by the effects of lesions in this part of the brain. We review the history of early experimental and clinical studies and the results of a recent single-subject human studies.

In this presentation we briefly outline the all these efforts which are closely linked to both the basic neurophysiologic functions of the DBS targets in forebrain arousal regulation mechanisms and the underlying pathology of chronically impaired cognitive function following severe brain injury.

We conclude that central thalamic deep brain stimulation may have therapeutic potential to improve behavioral functioning in patients with severe traumatic brain injury or unconscious patients.

A PERFORATING GUNSHOT INJURY TREATED WITH DECOMPRESSIVE CRANIECTOMY. A CASE REPORT

Caparoski A.¹, Filipce V.¹, Shuntov B¹

University clinic of Neurosurgery, Medical faculty University St. Cyril and Methodius Skopje,
Mother Theresa No.17, 1000 Skopje, R.of Macedonia

Abstract

INTRODUCTION. The perforating injury to the head though with less prevalence in the main population compared with the closed head injuries is a condition that represents a great challenge in management for every neurosurgical institution and the later is followed with poorer prognosis, numerous perioperative and postoperative surgical complications and in certain cases followed by a severe disability.

OBJECTIVES. In this article we present a case of a patient with opened, perforating head injury inflicted with a firearm from a relative proximity treated in our neurosurgical institution.

METHODS. The patient we present is a 35 y/o male injured with a single gun-shoot perforating wound inflicted in relative proximity. GCS score on admission was 6, pupils equal and reactive, with left sided hemiparesis with central pyramidal characteristics. CT scan showed a depressive comminutive fracture on the right parietal bone with bone debris located deeply in the right parietal lobule region, hemorrhagic contusions and compressive acute subdural hemathoma located in the right temporoparietooccipital region.

RESULTS. Postoperatively we observed a complete restoration of consciousness with residual left sided hemiparesis without any postoperative complications.

CONCLUSION. Among adults with severe diffuse traumatic brain injury and refractory intracranial hypertension in the ICU, we found that decompressive craniectomy decreased intracranial pressure, the duration of mechanical ventilation, and the time in the ICU.

“EXTREME” INDICATION OF THE ENDOSCOPIC ENDONASAL APPROACH FOR TREATMENT OF COMPLEX C2 ODONTOID FRACTURES

Iacoangeli M., Esposito D., Salvinelli F.*, Re M.**, Nocchi N., Casale M.*, Greco F.***, di Somma L., Liverotti V., Della Costanza M., Scerrati M.

Department of Neurosurgery, Università Politecnica delle Marche, Umberto I General Hospital, Ancona, Italy

*Department of Otorhinolaryngology, Università Campus Biomedico, Rome, Italy

** Department of Otorhinolaryngology, Università Politecnica delle Marche, Ospedali Riuniti, Ancona, Italy

***Department of Otorhinolaryngology, Ospedale Murri, Fermo, Italy

Objective: Odontoid fracture stabilization through a combined anterior endonasal endoscopy-assisted approach (EEA) could represent a minimally invasive alternative to traditional surgical procedures in case of type II Anderson-D’Alonso C2 fractures with pseudoarthrosis following conservative treatment. In case of old non healed odontoid fractures, especially in the elderly, anterior screw fixation may often fail. Consequently, a posterior stabilization is preferred, despite some drawbacks such as: loss of articular mobility, muscle dissection, risk of vertebral artery injuries and post-operative pain. In our opinion, a more rational alternative could be the combination of EEA, with removal of the inflammatory pannus, and the classical anterior screw fixation.

Methods: From January 2014 to September 2015, 4 patients (3 males and 1 female, mean age 68) underwent, in the same surgical session, a combined anterior screws fixation plus EEA for old non healed odontoid fractures. During EEA the inflammatory pannus of odontoid bone stumps was removed and bone chips were placed at the fracture line. Finally, the anterior screw was inserted up to the odontoid tip and the fracture reduced. During the follow-up the regular bony healing and the full range of motion preservation were evaluated, both clinically and by cervical CT scan and dynamic X-ray.

Results: There were no complications and the median hospital stay was 6 days. A follow-up evaluation revealed bony fusion without any instance of hardware failure and/or breakage. None of the patients required a subsequent posterior fixation. The post-operative course was painless and at the time of follow-up the full functional range of motion was preserved.

Conclusions: Our preliminary experience with this combined approach in old non healed odontoid fractures is so far positive and could represent the alternative solution for complex problems. This technique allows a more effective anterior screw fixation aiming at overcoming the problems of pseudoarthrosis and the need for posterior approach.

Novi Sad 2016

One Region, One Neurosurgery

Saturday, October 22nd / Hall 1

Saturday, October 22nd

ABSTRACTS

MAIN SESSION

Hall 1

**FUNCTIONAL ASPECTS FOR COMPLETE DECOMPRESSIVE
CRANIECTOMY: MICROSURGICAL NEUROANATOMY WITH
RESPECT TO VENOUS DRAINAGE**

Peter A. Winkler

Christian Medical Center, Department of Neurosurgery, Salzburg, Austria

Objective: The indications for decompressive craniectomy are the removal of space occupying lesions and the reduction of pharmacologically not curable intracranial hypertension. The decision about the extent of decompressive craniectomy is sometimes still controversial, and the size of the skin- and bone-flap not everywhere standardized.

Methods: In our Laboratory for Microsurgical Neuroanatomy we studied 52 hemispheres in order to define the first order anastomotic veins according to our proposed classification.

Results: Five groups of first order anastomotic veins were found and classified according to our proposed classification I – V .

Conclusions: Decompressive craniectomy carried out with respect to the above mentioned patterns of the dominant cerebral veins avoids the risk of venous obstruction and secondary congestion and intracranial hypertension.

TREATMENT OF UNSTABLE THORACOLUMBAR JUNCTION BURST FRACTURES: SHORT-SEGMENT PEDICLE FIXATION WITH INCLUSION OF THE FRACTURE LEVEL VERSUS LONG-SEGMENT INSTRUMENTATION EXCLUDING THE FRACTURE LEVEL

Iacoangeli M., Esposito D., di Somma L., Nasi D., Colasanti R., Brunozzi D., Benigni R., Grillo G.*, Mancini F., Scerrati M.

Department of Neurosurgery, Università Politecnica delle Marche,
Umberto I General Hospital, Ancona, Italy

*Department of Neuroanesthesia, Università Politecnica delle Marche,
Umberto I General Hospital, Ancona, Italy

Background: The length of instrumented stabilization for thoracolumbar burst fractures is still controversial. We compared the long segment fixation (at least two levels above and two levels below excluding the fracture level, LSF EFL) with the short segment fixation (one level above and one level below) including the fracture level (SSFIFL).

Methods: In 4 years time-lapse, 60 patients with traumatic fractures of T11-L2 junction were treated with posterior pedicle screw fixation and fusion. Patients were divided into two groups: Group I included 30 patients treated by SSFIFL while Group II included 30 patients treated by LSF. To compare the two groups we evaluated: local kyphosis angle (LKA), sagittal index (SI), anterior body height (ABH), posterior body height (PBH), hardware failure occurrence, needs for anterior approach and clinical outcome.

Results: The groups were homogeneous. The follow-up were similar for both groups (mean 32.5 months for Group I and mean 30.8 months for Group II). Reduction of post-traumatic kyphosis (assessed with LKA) and restoration of fracture-induced wedge shape of the vertebral body (assessed with SI, ABH e PBH) at immediate post-operative period were not significantly different between the Groups ($P = 0.234$, $P = 0.551$, $P = 0.12$, $P = 0.754$), as the correction loss at the last follow-up. At the most recent follow-up, the LKA was $15.97^\circ \pm 5.62^\circ$ for Group I (SSFIFL) and $17.76^\circ \pm 11.22^\circ$ in Group II. Correction loss in Group II (0.63°) was slightly less than in Group I (1.74°) without statistically significance ($P = 0.427$).

Conclusions: This study demonstrated that inclusion of fracture level in a short segment fixation for thoraco-lumbar junction fractures results in a kyphotic correction and in a maintenance of the sagittal alignment similar to long segment fixation. However, SSFIFL has two main advantages: preserving motion's segments and, in some cases, it eliminates an anterior approach for column reconstruction.

THE IMPACT OF CEREBROSPINAL FLUID SHUNTING ON MENTAL RECOVERY IN PATIENTS WITH POST-TRAUMATIC HYDROCEPHALUS

A. Kravchuk, O. Zaitsev, Y. Latyshev, N. Zakharova, L. Likhterman,
E. Sharova, S. Abuzaid, A. Kormilitsina.
The Burdenko Neurosurgical Institute,
Neurotrauma Department, Moscow, Russian Federation

Introduction Mental recovery is considered to be the most important goal in rehabilitation of patients after traumatic brain injury (TBI). The positive effect of surgical treatment of post-traumatic hydrocephalus (PTH) is often unpredictable and dissatisfactory. Vegetative state (VS) and minimally conscious state (MCS) mostly complicate decision-making and treatment.

Materials and methods: Among 206 patients examined and treated for PTH in the Burdenko Institute 31 patients were in VS and 46 in MCS. Mean surgery time after trauma in these groups was $5,6 \pm 4,01$ months. All patients were initially assessed by Glasgow Outcome Scale (GOS) and by evaluating psycho-pathological stages of mental recovery after prolonged coma (introduced by O.Zaitsev, T.Dobrokhotova). All patients underwent various shunting procedures.

Results Mental improvement, regarded as a positive effect of treatment, was achieved in 20 (64,5%) patients in the VS group and 34 pts (73,9%) in the MCS group. However, only 3 pts were formally in clear consciousness. Unfavorable outcomes were observed in 11 pts (VS) and 12 pts (MCS) with mortality rate of 9,6% and 4,3% respectively in these groups. Infectious complications were encountered in 7 cases (9,09%), 13 reoperations were performed in 77 pts (16,8%).

Conclusions and discussion Shunting procedures can trigger mental recovery in patients with PTH even in VS and MCS, thus advancing their further rehabilitation. However, the number of unsatisfactory results is high due to absence of strict indications for surgery and decision-making protocol.

DELAYED CEREBRAL VASOSPASM FOLLOWING TRAUMATIC ACUTE SUBDURAL HEMATOMA: CASE PRESENTATION

Kaima Suzuki, Yuichiro Kikkawa, Toshiki Ikeda, Ririko Takeda, Hiroyuki Nakajima, Masahiro Okuma, Koichi Uramaru, Akio Teranishi, Hiroki Sato, Taro Yanagawa, Hiroki Kurita
Department of Cerebrovascular Surgery,
Saitama Medical University International Medical Center, Hidaka, JAPAN

Background: Traumatic vasospasm (TVS) is a rare but known ischemic damage after severe traumatic brain injury that independently predicts patients' outcome. Although the pathogenesis and risk factors have not been elucidated, some reports describe relationship between TVS and traumatic SAH. Here, we report extremely rare case of TVS after ASDH in which traumatic SAH was not recognized both surgically and radiologically.

Case Report: A 60-year-old man was evaluated for head trauma. Neurologically, he was somnolence and showed left hemiparesis. CT scan revealed large acute subdural hematoma in the left side associated with midline-shift. He underwent urgent craniotomy and hematoma evacuation. Postoperatively, he recovered well with resolution of neurological symptoms. CT scan showed total removal of hematoma. However, his level of consciousness deteriorated on the 5th day after surgery. CT scan showed ischemic lesion, but 3D-CT angiography revealed diffuse vasospasm in the right middle cerebral artery. Subsequently, his neurological condition recovered gradually and discharged ambulatory on the 9th day after the surgery. Follow-up angiography showed the spasm had disappeared completely.

Discussion: Cerebral vasospasm is known to occur after head injury. But delayed neurological deterioration secondary to vasospasm in head injury is a rare occurrence. Especially, the presented case is unique its gradual onset without associated traumatic subarachnoid hemorrhage (SAH). Hypothalamic dysfunction secondary to increased intracranial pressure and blood degradation products of acute subdural hematoma (ASDH) seem to play some role in the development of the vasospasm. Serial 3D-CTA & perfusion CT image is useful in predicting vasospasm in such patients. **Conclusions:** TVS without traumatic SAH was described. The etiology and pathogenesis of this fairly rare condition associated with head trauma is proposed.

CEREBRAL VENOUS THROMBOSIS AS A RARE COMPLICATION OF TRAUMATIC BRAIN INJURY

Duško Kozić

University of Novi Sad, Faculty of Medicine, Oncology Institute of Vojvodina, Novi Sad, Serbia

Introduction: Thrombosis of the cerebral veins and sinuses is an emergency condition associated with intracranial venous congestion and consequent regional ischemia and cortical infarcts, most frequently hemorrhagic. Development of cerebral venous sinus thrombosis secondary to closed head injury with or without skull fractures, detected or unrecognized during radiologic evaluation, is being increasingly reported in the recent literature.

Purpose: The aim of the presentation is to evaluate the presence of radiologic error in reporting cerebral venous thrombosis (CVT).

Methods: Computerized tomography (CT) and/or magnetic resonance imaging (MRI) of the brain were reevaluated in 10 patients with CVT, affecting cerebral sinuses, deep intracranial veins or cortical veins.

Results: Correct diagnosis was established immediately in only 40% of patients with CVT, while the mistake in the final report was evident in 30% of patients. In 10% of reports inconclusive finding was noted, while in 20% of patients with CVT initial report was wrong, associated with the correction in the final report. The disease was associated with two lethal outcomes while permanent neurological deficit was noted in one patient. Application of MRI with susceptibility-weighted imaging or T2 gradient-echo sequence was the most important in detection of the cortical veins thrombosis.

Conclusion: Education of both radiology and neurology residents in detecting both direct and indirect signs of cerebral venous thrombosis is extremely needed in order to decrease the rate of fatal outcome. Inclusion of susceptibility-weighted imaging or T2 gradient-echo sequence as obligate part of protocol, especially in patients with acute or subacute headaches may significantly improve the detection of thrombus within the cortical veins.

SCIWORA OR WHAT ELSE?

Rasim Skomorac

Cantonal Hospital Zenica, Neurosurgical Department, Zenica, Bosnia and Herzegovina

The acronym SCIWORA (Spinal Cord Injury Without Radiographic Abnormality) was first developed and introduced by Pang and Wilberger in 1982. This occurs predominantly among the paediatric population, where its reported incidence ranges from 4%-66% of all spinal cord injuries. Magnetic resonance imaging, made it possible to detect damages. SCIWORA can have a wide spectrum of neurological dysfunction, ranging from mild, transient spinal cord concussive deficits to permanent, complete injuries of the spinal cord. The incidence and severity of injury are related to the patient's age. Almost all of thoracic injuries are complete. The injury to the spinal cord is caused by a contusion or ischemia due to temporary occlusion of vertebral arteries followed by a spontaneous return of vertebrae to their original position. The onset of clinical symptoms is delayed from a few minutes to 48 hours after injury in about 50% of patients. The delays in deficits can be to 4 days after injury.

We are presenting a well documented case of polytraumatized 9 years old girl with delayed onset of paraplegia. MRI showed lesion of the thoracic spinal cord without any signs of spinal column or ligamentous lesion. Lesion was surgically explored due to possibility of removable intradural haematoma.

PROGNOSTIC FACTORS FOR MORTALITY IN SURGICALLY TREATED PATIENTS WITH MODERATE TO SEVERE TRAUMATIC BRAIN INJURY

M. Laleva, N. Gabrovsky, N. Velinov, G. Jurykov, G. Poptodorov, St. Gabrovsky
University Hospital Pirogov, Department of Neurosurgery, Sofia, Bulgaria

Introduction: In the recent years many authors have focused on the predictive value of various factors related to the mortality of patients with traumatic brain injury (TBI). We present our retrospective analysis of patients who underwent surgical treatment for intracranial hematomas with moderate to severe TBI.

Material and methods: For the period 01.2007-12.2011 in the Dept. of Neurosurgery in University Hospital Pirogov, 249 adult patients with GCS 3-13 underwent surgical treatment for a traumatic intracranial hematoma. Epidural hematoma (EDH) was the main reason for surgery in 55 (19.4 %), subdural hematoma (SDH) - in 121 (42.8 %) and intracerebral hemorrhage (ICH) - in 73 patients (25.8 %). We studied the prognostic value of the different factors using both univariate and multivariable analysis.

Results: The univariate analysis revealed that the following several factors have prognostic significance: age ($p < 0.001$, HR 1.028, CI 1.020-1.036); gender ($p = 0.002$, HR 1.752, CI 1.222-2.513), GCS on admission ($p < 0.001$, HR 0.858, CI 0.821-0.897); pupil reactivity at admission ($p < 0.001$, HR 1.897, CI 1.653-2.176); pupil size at admission ($p < 0.001$, HR 2.210, CI 1.729-2.825); Rotterdam CT score of preoperative CT scan ($p < 0.001$, HR 1.553, CI 1.383-1.744) and type of surgical lesion - EDH ($p < 0.001$, HR 0.392, CI 0.258-0.595), SDH ($p = 0.036$, HR 1.364, CI 1.021-1.822), ICH ($p = 0.022$, HR 1.433, CI 1.053-1.950).

The multivariable analysis confirmed prognostic value only for age ($p < 0.001$, HR 1.025, CI 1.016-1.034); pupil reactivity at admission ($p < 0.001$, HR 1.521, CI 1.213-1.907); Rotterdam CT score of preoperative CT scan ($p = 0.028$, HR 1.190, CI 1.019-1.389) and type of surgical lesion ($p = 0.003$, HR 1.478, CI 1.144-1.908).

Conclusion: The most powerful independent prognostic variables for mortality were age, pupil reactivity on admission, Rotterdam CT score of preoperative CT scan and surgical lesion type.

NEW TRENDS IN DIAGNOSIS MANAGEMENT OF TBI IN CHILDRENAlexandru Taşcu^{1,2}, Iulia Bălălaşu-Vapor²

1) UMF „Carol Davila”, Bucureşti, Romania

2) Spitalul Clinic de Urgenţă „Bagdasar-Arseni”, Bucureşti, Romania

Objective: Craniocerebral trauma affects, usually, a prior healthy child and can lead to important sequelae in a growing person with a long life expectancy. First problem in the management of a pediatric cases of TBI appears from the moment of initial radiologic investigations, due to the growing fear of parents and doctors of radiation consequences.

Material and methods: In Pediatric Neurosurgical Clinic of “Bagdasar-Arseni” Hospital are admitted annually about 650 children with TBI, from approximately 2000 presentations in emergency room. The main investigation in these cases is CT-scan. This is a useful, fast and accessible tool for establishing an accurate diagnosis and an adequate decision. Despite its proved utility, CT-scan is a method of investigation increasingly disputed because of ionizing radiations, incriminated more often in the medical literature of inducing neoplasms. This leads to a wrong advice from general practitioners and a growing percent of parents witch refuses performing a CT in cases of TBI in children. In cases of moderate and severe craniocerebral trauma is a firm indication of performing CT. The main problem is in mild craniocerebral trauma. Considering these problems, there are international recognized protocols. The most important protocols are: CATCH, CHALICE and PECARN. In our clinic we use PECARN protocol, which is the most accurate.

Results: In this paper we will expose our experience in the management of craniocerebral trauma in children, focusing on smart use of neuroimaging, correlated with clinical exam and trauma history, taking into account the fact that may be cases with few or no symptoms at admittance but with brain lesions rapidly evolving and the neurological decline can be rapid and irreversible.

Conclusions: Smart management of pediatric craniocerebral trauma enforces to a fast and accurate diagnosis of surgical lesions with rational using of radiological investigations that uses ionizing radiations.

NEUROANATOMY OF COMA DUE TO TRAUMATIC AXONAL INJURY

Alexandrova EV, Zakharova NE, Tonoyan AS, Potapov AA
Burdenko NSI, Neurotrauma Department, Moscow, Russia

Introduction: Close interactions between the brainstem, subcortical structures and cortex play a crucial role in consciousness recovery. Deep brain structures damage evaluation may have a crucial role in outcome prediction and development a new treatment strategy in severe traumatic brain injury (TBI).

Methods: This study enrolled 61 survived patients with severe TBI (GCS<8) characterized by diffuse axonal injury (DAI). Brain damage localization was verified by 3T MRI (T1, T2, FLAIR, T2 GRE/SWI, DWI). We analyzed the damage of Globus Pallidus interna (GPi) and externa (GPe), nucleus caudatus (NC), putamen (Put), Thalamus, Meynert nucleus area and brainstem (Ventral and Central Tegmental Area, Substantia Nigra, Locus Coeruleus, Pedunculo pontine Nucleus, Laterodorsal Tegmental Nucleus zones). Coma depth was ranged with GCS. DAI was ranged by Firshing R. (2001) classification on four grades.

Results: Prolonged (≥ 13 days) and deep (3-4 GCS) coma was associated with damage of dorsolateral part of pons (LCA, PPN and LDT areas), CTA, more often GP and Tha injury. Coma duration in patients with diffuse axonal injury I-II grades didn't depend on brainstem and subcortical structures damage. Coma duration in patients with diffuse axonal injury III-IV grades was accompanied by frequent injury of dorsolateral pons (LCA, PPN and LDT areas) or Central Tegmental Area.

Conclusions: Deep brain structures damage evaluation may provide a key to better unconsciousness pathophysiology understanding, which leads to more accurate outcome prediction in severe TBI (supported by RFBR grant № 16-04-01472, 16-29-08304).

Saturday, October 22nd

ABSTRACTS

**SEENS YOUNG
NEUROSURGEONS FORUM**

Hall 2

OLFACTORY GROOVE MENINGIOMAS (OGM): A MULTICENTRIC PERSPECTIVE REGARDING PLANNING, SURGICAL APPROACHES, QUALITY OF LIFE AND GLOBAL OUTCOME

^{1,2} Prof. A.V. Ciurea, MD., PhD. MSc., ³ Kalinovsky A. MD., PhD, ³ J. Rzaev MD., PhD, ⁴ S. Schernov MD., PhD., ^{2,5} H. Moisa MD, ⁶ A. Mohan MD., PhD.

- 1) Department of Neurosurgery, Sanador Medical Center Hospital, Bucharest, Romania,
- 2) „Carol Davila” University School of Medicine, Department of Neurosurgery, Bucharest, Romania,
- 3) Department of Neurosurgery, “Federal Neurosurgical Center”, Novosibirsk, Russia, 4) Department of Neurooncology, “Federal Neurosurgical Center”, Novosibirsk, Russia,
- 5) Department of Neurosurgery, Bucharest Emergency University Hospital, Bucharest, Romania,
- 6) Bihor County Emergency Hospital. Department of Neurosurgery, Oradea, Romania.

Introduction: OGMs represent 8 - 10 % of all intracranial meningiomas. The aim of the authors is to compare the subfrontal and lateral supraorbital approaches and to reveal the best surgical strategy which facilitates total quality of life and Global Outcome.

Materials and methods: The authors present a retrospective study consisting of 125 OGM patients operated in two neurosurgical centers - in Bucharest (A) and Novosibirsk (B).

Center A, 68 cases, operated between 1990 and 2016 (26 years). The patient age ranges between 20 to 76 years (F/M = 1.5/1). The clinical features were represented by: Headache - 61 cases (90.5 %), Anosmia - 45 cases (66,1 %), Personality disturbances - 44 cases (64.2 %). Tumor size was larger than 4 cm in diameter in 47 cases (69.8%) and smaller than 4cm in 21 cases (30.1%). Microsurgical resection: bilateral subfrontal approach (46 cases - 68%), unilateral subfrontal approach (16 cases- 23,6%) or pterional approach (6 cases – 9,4%).

Center B, 57 cases of OGM operated between 2013 and 2016 (3 years and 5 months). The patient age ranges between 25 and 70 years (F/M = 3.07/1). The clinical features were represented by Headache in 51 patients (89.5%), Visual impairment in 22 patients (38.6%) etc. Tumor size was larger than 4cm in 37 cases (64.9%) and less than 4cm in 20 cases (35.1%). 52 patients were operated using the lateral supraorbital approach (91.2%), the bilateral subfrontal approach in 2 cases (3.5%) and 3 cases using the eyebrow approach (5.3%).

Results:

Center A: The resection degree (Simpson scale): grade I - 4 cases (5.88 %), grade II - 36 cases (52,9 %), grade III - 18 cases (26,4 %) and grade IV – 10 cases (14,7 %). No biopsy was done (grade V). Histology was benign in 66 cases (97%) and anaplastic in 2 cases (3%). Postoperative complications: anosmia – 62 cases (91.1%), seizures - 34 cases (50%), worsening of visual impairment – 9 cases (13.2%), CSF Fistulas – 9 cases (13.2%). Follow-up: 6-192 months. GOSE illustrates: 8p – 19 cases (28.9%); 7p – 23 cases (33.8%); 6p – 14 cases (20.5%); 5p – 9 cases (13.2%); 4p – 1 case (1.4%); 1p – 2 cases (2.9%). Late recurrences: 10 cases (14.7 %)

Center B (Novosibirsk): The resection degree (Simpson scale): grade I – 4 cases (7%), grade II – 46 cases (80.7%), grade III – 4 cases (7%), grade IV – 3 cases (5.3%). Histology: benign in 56 cases (98.25%) and anaplastic in 1 case (1.75%) Postoperative complications: postoperative hematomas – 2 cases (3.5%), CSF Fistulas – 2 cases (3.5%), worsening of visual impairment – 3 cases (13.6%). Follow-up: 6-40 months. GOSE illustrates: 8p – 17 cases (42.5%); 7p-17 cases (42.5%); 6p – 5 cases (12.5%); 4p – 1 case (2.5%). No recurrences were described.

Conclusions: OGMs are most of the times benign tumors with a silent evolution. The surgical techniques range from limited approaches to wide approaches and should be tailored for the patient's pathology with the goal of total tumor removal and good quality of life.

Key words: Surgical Approach, Olfactory Groove Meningioma, Simpson Scale, Quality of Life

UNUSUAL TRAUMATIC INJURY OF HIGH CERVICAL SPINAL CORD AS A RESULT OF DEGENERATION AND OSCILLATION

¹Tomaz Velnar, ²Vladimir Smrkolj, ³Ognjen Cerovic

- 1) University Medical Centre Ljubljana, Department of Neurosurgery, Ljubljana, Slovenia
- 2) University Medical Centre Ljubljana, Department of Traumatology, Ljubljana, Slovenia
- 3) University Medical Centre Ljubljana, Department of Anaesthesiology, Ljubljana, Slovenia

Introduction: Trauma to the spinal cord is frequently associated with damage to other surrounding structures. However, spinal cord lesions can be sometimes found in patients demonstrating no radiological abnormalities. Injury to the spinal cord without osseous damage is well documented in the paediatric population and is infrequently reported in adults. Due to the rarity and absence of demonstrable osseous damage on radiograph the diagnosis and management are aggravated. Causes of sudden and unexplained quadriplegia after oscillating injury of the spinal cord during jumping on a trampoline are discussed in the report.

Methods: A 68-year old gentleman suddenly collapsed following a trivial trampoline jump and was unconscious. No associated injuries to the head and neck or unusual movements were observed. CPR was started instantly. The pulse was palpable with no respiration observed, GCS was rated at 3. On regaining consciousness, the patient was quadriplegic.

Results: Degenerative changes and vertebral osteophytes typical for Morbus Bechterew were seen on all vertebrae on the spinal CT. A MRI showed a ruptured posterior longitudinal ligament, a central contusion from C1 to C3 with a 4mm mid-cord haematoma and a 1.2cm epidural haematoma at C1 with no cord compression. Slight anterior subluxation of dens axis and degenerative canal narrowing at C3/4 were seen. The patient was conscious but required continuous artificial ventilation. During the hospitalisation, recurrent cardiac arrests were experienced by the patient and were successfully solved with CPRs. Neurological status did not improve.

Conclusions: Isolated spinal cord injuries are rare in patients with no traumatic radiological abnormalities of the spine. Spinal stenosis and degenerative changes may be the predisposing factors for the injury in combination with the oscillation. Respiratory arrest and quadriplegia in described patient point to mechanical spinal cord injury. No radiological abnormalities were observed and isolated spinal cord injury was managed conservatively.

SURGICAL TREATMENT AND REMARKABLE OUTCOME AFTER SEVERE TRAUMA BRAIN INJURY

Fahrudin Alić, Aldin Jusić, Hakija Bečulić, Rasim Skomorac

Department of Neurosurgery, Cantonal hospital Zenica, Bosnia and Herzegovina

Introduction: Severe traumatic brain injury (TBI) is defined as head trauma associated with the Glasgow Coma Scale (GCS) score of 3 to 8. Incidence of severe TBI is approximately 14 cases per 100,000 people with mortality rate of about 33%. Over the past twenty five years several guidelines on management of severe TBI have been published in order to improve outcomes such as mortality rate, functional outcome scores and length of hospital stay. Initial rapid trauma assessment includes neurologic examination with special emphasis on GCS and CT scan which detects primary craniocerebral changes. Surgical decompressive craniotomy has been suggested as a promising therapeutic approach for patients with acute severe TBI. The early prediction of outcome after TBI is important. A few predictive models of 6-month outcomes after severe TBI have been proposed such as age, motor score, pupillary reactivity, hypoxia, hypotension, computed tomography classification, and traumatic subarachnoid hemorrhage.

Case report: A 28-year old Caucasian was struck as a pedestrian in motor vehicle accident. Paramedics immobilized the patient, established IV access, administered oxygen therapy and referred him to the Emergency Department (ED). Upon his arrival, physical exam revealed blood pressure 130/100mmHg, heart rate 120/min, weight over 100 kg, a large laceration over the right parietal region of scalp, several abrasions on the face, left iliac and knee area. He was intubated with GCS 4 (V2; M1; O1), both pupils were isochoic, responding sluggish on light stimuli with gaze fixed on the right. CT scan showed interhemispheric and right frontotemporoparietal acute subdural hematoma, traumatic subarachnoid hemorrhage with midline shift. The patient was taken to the operating room where large frontotemporoparietal craniotomy was performed, dura was opened and hematoma was removed. Patient was sent to intensive care unit, kept intubated and ventilated for three days. The patient made a remarkable recovery and was discharged from our department after three weeks.

Conclusion: The management of severe TBI includes multi-model, protocolized approach by neurosurgeon and neuroanesthesiologist involving possible surgical treatment and meticulous postoperative hemodynamic support, respiratory care, fluid management, and other aspects of therapy, aimed at resolving primary and preventing secondary brain injuries.

Keywords: Traumatic brain injury, Glasgow Coma Scale (GCS), craniotomy, TBI outcomes

NEONATAL HEAD AND SPINE INJURIES

Zvonimir Dzelebdzic

KC Nis, Clinic of neurosurgery, Nis, Srebia

Neonatal head and spine injuries (NNHSI) are of the greatest importance due to its high frequency and therapeutic and prognostic significance. It consists of the wide range of lesions, some of them are benign requiring no therapy (caput succedaneum) and some require immediate treatment. The most common site of fatal and threatening NNHSI is intracranial space; symptomatology of these lesions is very nonspecific. Spinal cord injuries are of special interest because they are not as rare as once thought. Newborns spinal cord is not as flexible as spinal column and therefore more prone to injuries. CT, MRI, US together with clinical assessment enlighten these injuries.

Objective is to show the most common NNHSI and their clinical manifestations as well as to point out the best diagnostic methods and define therapeutic guidelines.

Our one-year retrospective study included all neonates treated at the Clinic for Pediatric Surgery in Clinical Center Niš for NNHSI.

NNHSI occurred in 120 newborns, kefalhematoma was diagnosed in 116, caput succedaneum in 3, and one baby only had a fracture of the head (which did not require surgical treatment). All of these newborns were successfully treated conservatively and followed as outpatients. A case of newborn with NNHSI is presented in this paper. It had a multiple injury (including intraventricular hemorrhage and spinal cord lesions as well) and later on developed hydrocephalus and due to it, the urgent operation was performed.

It is very important that NNHSI are diagnosed promptly and accurately as otherwise many complications could occur.

SKULL FRACTURES IN NEWBORN CHILDREN: A 10-YEAR REVIEW FROM A SINGLE CENTER

Mirjana Raičević¹, Milan Mrdak¹, Dževad Sebečevac², Srđan Nikolovski¹, Dragana Pantić¹

1) Pediatric Surgery Department, University Children's Hospital, Belgrade, Serbia

2) General hospital, Novi Pazar, Serbia

Background: Skull fractures in neonatal period are uncommon and can be manifested through variety of clinical and radiological signs. Often they are associated with cephalematoma with no or mild neurological symptoms. It is well known that impressive skull fractures requires surgical intervention. In most other cases, only conservative treatment is included.

Material and methods: We retrospectively reviewed medical charts of 20 newborn children referred at our clinic in a period of ten years diagnosed with skull fracture.

Results: Out of 20 children with diagnosed skull fracture during ten-year tracking period 13 (65.0%) were boys. The mean age of patients was 9.4 days. In 18 patients (90.0%) parietal bone was fractured. Linear fractures occurred in 70% of cases, and impressive/depressive fractures occurred in 15% each. In 80% of cases injury occurred in postpartal period, whereas in four cases injury was a part of a birth trauma. Neither one of this four cases had difficulties during birth (there are no forceps or vacuum extractor used), although two children were born by Cesarean section and one of them was a preterm infant. The most common mechanism of injury was fall (60.0%), and child abuse detected in two cases. Eight children had an epidural hematoma as a most common radiological sign. All children with impressive fractures and two with depressive fractures required surgery as a part of treatment. Other patients were treated conservatively. During a five-year follow up period after the trauma there was no evidenced case with posttraumatic neurological deficit.

Conclusion: The most of our results are in a positive correlation with data from earlier studies. We confirmed that parietal bone is the most common fractured skull bone in neonatal period and that bone dyslocation and depression/impression of the fractured fragment is the most common indication for a surgical intervention.

ILLUSTRATIVE CASE AND LITERATURE REVIEW OF BONE RESORPTION AFTER AUTOLOGOUS BONE CRANIOPLASTY

Gatos H., Georgiadis I., Tasiou A., Fountas KN
University Hospital of Larissa, Department of Neurosurgery, Thessaly, Greece

In the case of severe traumatic brain injury (TBI), decompressive craniectomy (DC) is an established, potentially lifesaving neurosurgical procedure for emergent treatment of medically refractory raised intracranial pressure (ICP). Autologous or heterologous bone grafts have been used for restorative cranioplasty, with variable success rates. Resorption of autologous bone graft is a potential complication of using autologous bone graft in cranioplasty.

We describe a case involving a pediatric cranial reconstruction after DC for severe bicycle accident, using an autologous bone graft. Four months after the DC, the patient underwent a second operation for cranioplasty, and four months after this, came to the emergency department of our hospital complaining for a skull deformity, without any neurological deficit.

Although autologous bone is still considered by many neurosurgeons the ideal material for restorative cranioplasty, cases of bone resorption have been reported in 7-50%, thus causing skull disfiguration with severe cosmetic and psychological consequences, especially among pediatric patients. The identification of any factors predisposing to bone resorption is of paramount importance.

Keywords: Complications, cranioplasty, decompressive craniectomy, resorption

BRAIN TEMPERATURE – AN UNDERVALUED VITAL PARAMETER OF BRAIN TISSUE HEMOSTASIS AFTER BRAIN INJURY. CAN WE MONITOR BRAIN TISSUE TEMPERATURE NON-INVASIVELY IN PATIENTS?

Matthias Menzel

Community Hospital Wolfsburg, Anesthesia Department, Wolfsburg, Germany

The injured brain is sensitive to variations in temperature. Hypothermia protects, while hyperthermia exacerbates, ischemic and traumatic brain damage [Neeraj Badjatia: Crit Care Med 2009 Vol. 37, No. 7 (Suppl.)]. For clinical purposes, rectal temperature has generally been assumed to be representative of brain temperature. Recent studies, however, have consistently shown that in brain-injured patients, the brain temperature can be significantly higher than the core body temperature [Verlooy J et al. Acta Neurochir 1995; 134:76-78]. Thus, monitoring of brain tissue temperature invasively in brain tissue or cerebrospinal fluid has become part of multimodal neuromonitoring set up in many centers. However, in patients without opening of the cranium e.g. stroke, cerebral hemorrhage or different forms of neuronal damage it would be favorable to have a monitoring tool for monitoring brain tissue temperature non-invasively.

We tested a new non-invasive single use sensor that has to be placed on patient's forehead. Creating a zone of perfect insulation eliminates heat loss to the environment, resulting in the formation of an isothermal pathway. Through this pathway, the patient's core temperature rises to the skin surface where it can be non-invasively measured, captured and continuously reported. We measured simultaneously with the new non-invasive sensor additionally to brain tissue temperature monitoring with a thermocouple probe in 6 patients. The results showed 1.: that brain temperature was consistently higher than core body temperature in all patients at any time. 2: The skin surface sensor was measuring temperatures distinctively lower than brain tissue results. The sensor readings were comparable with the temperatures measured within the urinary bladder.

Conclusions: Brain temperature in patients with neuronal damage is an important parameter that is under most circumstances missed in patient monitoring. Thus many patients will experience brain tissue hyperthermia unrecognized by clinicians. The newly available sensor set "Spot on" (3M Company) is not feasible of monitoring brain tissue temperature non-invasively.

ACUTE MANAGEMENT OF THORACOLUMBAR BURST FRACTURES. HOW WE DO IT

Deyan D. Handzhiev, Svetoslav K. Kalevski
University Hospital "St. Anna", Clinic of Neurosurgery,
Department of Neurosurgery, Varna, Bulgaria

Traumatic spinal fractures can cause spinal instability with neurologic deficits. The majority of such fractures occur at the thoracolumbar junction (T11–L2), largely due to regional biomechanics in which the rigid, kyphotic thoracic spine is juxtaposed with the more mobile, lordotic lumbar spine. Burst fractures account for 30 to 64% of the thoracolumbar spinal fractures. The etiology is typically related to powerful axial compression forces, such as in falls from heights (34 to 54%), motor vehicle accidents (51 to 65%), or high-intensity sports (9%).

Traumatic thoracolumbar burst fractures remain a challenge to treat, and optimal operative and nonoperative techniques have not yet been established. The goals of treatment are to obtain early patient mobilization and a painless, balanced, stable vertebral column with maximum spine mobility and optimal neurologic function.

If a patient is determined to require surgery, there is no general consensus on the appropriate technique to be used.

We present you our experience with surgical treatment of traumatic burst fractures in thoracolumbar region.

The inclusion criteria included: (1) burst fractures resulting from traumatic mechanism in TH11-L2 segment.

The exclusion criteria were: (1) osteoporotic fractures, (2) pathologic burst fractures, (3) cervical, thoracic or lumbar fractures - all those outside TH11-L2 range.

For last five years (2011-2016) in our clinic-219 patients undergo surgery that match that criteria.

Our purpose is immediately (until 6th hour) single stage posterior surgery, (with or without decompression, with or without ligamentotaxis, with or without vertebroplasty) with long segment pedicle instrumentation, without fusion.

Unfortunately according today's medical, economic and social conditions not all of our purposes are achievable.

Key words: burst fracture, thoracolumbar, surgery

THE IMPACT OF ICP MONITORING ON THE DEGREE OF RECOVERY OF PATIENTS WITH SEVERE BRAIN TRAUMA

Aleksandar Kostić, Ivan Stefanović, Vesna Nikolov, Nebojša Stojanović,
Zvonimir Dželabdžić, Ivan Cvetković, Jelenković Boban
Clinical Center Nis, Clinic for Neurosurgery, Nis, Serbia

Prognostic value of ICP monitoring in patients with severe brain injury remains controversial. Most of the studies consider survival of traumatized patients, but only a few consider their functional recovery.

We have followed clinical and functional status and the degree of recovery of 25 patients with severe brain trauma during a 6 months period of time after they were discharged from the Clinic for Neurosurgery.

ICP monitoring was used in 17 of the patients during initial treatment, and in 8 it was not (control group). Clinical examinations and telephone interviews were performed after 3 and 6 months in all of them in order to assess their functional recovery and it was presented in Glasgow Outcome Scale and Disability Rating Score. In the group of patients that had ICP monitored GOS was 3,18 after 3 months and 4,06 6 months after discharge from hospital. In the control group it was 3,62 after 3 months, and 4,25 6 months after discharge. In the group of patients that had ICP monitored DRS was 13,24 3 months after discharge from hospital and 9,53 after 6 months. In the control group DRS was 9,13 3 months after discharge, and 5,50 after 6 months. There were no significant differences between ICP monitored patients and the ones in the control group in functional recovery ($p>0,05$).

Therefore, ICP monitoring in early stages of treatment is not beneficial in assessing convalescence of patients with severe brain injury.

CRANIO-CEREBRAL INJURIES CAUSED BY CAPTIVE BOLT GUN IN SUICIDE ATTEMPT

V. Papić^{1,2}, B. Jelaca^{1,2}, M. Karan^{1,2}, Dj. Djilvesi^{1,2}, J. Golubović¹

1) Clinical center of Vojvodina, Clinic for neurosurgery, Novi Sad, Serbia

2) University of Novi Sad, Faculty of Medicine, Novi Sad, Serbia

Introduction: The captive bolt gun is a tool used to stun animals as first act in killing animals in butchery industry. Sometimes it is used with the intent of suicide, causing very serious brain injuries.

Aim of study: Analysis of extend of brain injuries, type of surgical treatment, complications and outcome after attempting suicide by captive bolt gun

Material: Patient that attempt suicide by captive bolt gun treated at neurosurgical clinic Novi Sad from January 2006. to June 2016.

Results: We analyzed 10 self-inflicted head injuries by captive bolt gun. All cases were male from 44 to 92 years of age. At admission GCS 4 was in 2 patients, GCS 6 in 4 patients, GCS 7 in 2 patients, GCS 13 in 1 patient and GCS 14 in 1 patient. Entry wound was in frontal region in 4 patients, sphenotemporal on right side in 4 patients and in 2 patients was frontoparietal close to midline. All patients were got triple wide spectrum antibiotics. Two patients were treated with primary care of epicranial wound; all others have craniotomy, hematoma evacuation, hemostasis and dural repair. All but two patients have infection complication, meningitis. Two of them had brain abscess that demanded another operation. Half of all patients had liquorrhoea treated with lumbar drainage. Despite all treatment modalities 4 patients died up to 20 days, 2 patient were in vegetative state, 2 patient were severely disabled and 2 patient were moderate disabled. One patient suffered blindness due to right optical nerve injury; one patient has left hemiparesis and psychosindrom.

Conclusion: suicide attempt by captive bolt gun is not primary effective but finally cause death due to extensive brain damage, hemorrhage and complications or leave patients severely disabled.

Keywords: cranio-cerebral injury, captive bolt gun, suicide, slaughterer gun, penetrating head injury

THE HISTOPATHOLOGICAL AND BIOCHEMICAL PARAMETERS OF CHRONIC SUBDURAL HEMATOMA

Boban Jelenkovic, Nebojsa Stojanovic, Aleksandar Kostic,
Ivan Cvetkovic, Luka Berilazic, Predrag Milosevic
Clinical Centre of Nis, Neurosurgery Clinic, Nis, Serbia

Chronic subdural hematoma (CHSH) is defined as the progressive accumulation of blood in the space between the dura and arachnoidea as a result of often minor trauma to the head, which is not subject to the expected processes of coagulation and in the long term acts as a space compressive lesion. A series of biochemical reactions that involve the presence of increased levels relative to serum PIGF and VEGF with the activation of VEGF-1 receptor, thrombomodulin activation and expansion of the gap junction leads to the proliferation of blood vessels in the capsule and increase endothelial permeability which results in hematoma growth.

The aim of our study was to show the influence of osmolality and an increase in the number of sinusoids, blood vessels in the capsule of hematoma to the hematoma enlargement.

During the work we used fragments of capsules that are observed by light microscopy in which blood vessels were counted millimeters per square and then we noted the osmolality of evacuated hematoma with monitoring serum and CSF osmolality. We also measured the thickness of the hematoma on brain CT. Followed up findings in 11 operated patients who had not previously been on anticoagulant therapy.

Statistical analysis led to the conclusion that the age of patients and the number of vessels on 1mm² have a coefficient of less than 0.05 and therefore represent a significant determinant of the largest diameter of hematoma. Osmolality of hematoma does not play a role in its hydration and increasing.

Keywords: chronic subdural hematoma capsule, sinusoids, VEGF, PIGF, thrombomodulin, osmolality, hematoma growth.

UPPER EXTREMITY PERIPHERAL NERVE INJURIES CAUSED BY GUNSHOT

Vladimir Puzovic¹, Andrija Savic², Bojana Zivkovic², Mirko Micovic^{2,3}, Vladimir Bascarevic^{2,3},
Miroslav Samardzic^{2,3}, Lukas Rasulic^{2,3}

Faculty of Medical Sciences, University of Kragujevac, Kragujevac, Serbia

Clinic of Neurosurgery, Clinical Center of Serbia, Belgrade, Serbia

Medical Faculty, University of Belgrade, Belgrade, Serbia

Introduction: Peripheral nerve injuries (PNI) of upper extremities, although rare, can end with devastating and lifelong consequences. Majority of gunshot or missile PNI are occurring during the wars, while in the peace they are very rare.

The aim of this study was to present gunshot caused PNI of upper extremities together with their associated injuries.

Methods: This is retrospective epidemiological study, which included 25 patients operated at Clinic of Neurosurgery, Clinical center of Serbia, in Belgrade, during the period of 10 years, from January 1st, 2000 to December 31st, 2010. Study included only patients surgically treated after upper extremity PNI caused by gunshot. All the data were collected from the medical history of patients and they included demographic data, anatomical location of the lesion, injured nerve elements and associated injuries.

Results: Out of 25 patients included in our study, 23 were males and 2 were females. All of the patients were between 20 and 50 years of age. Brachial plexus elements together with the nerves of upper arm region were injured in 19 patients while the nerves in elbow region and forearm were injured in 6 patients. Most commonly injured nerve was median nerve in 16 patients and most common associated injuries were long bone fractures and vascular traumas, in 12 and 11 patients respectively.

Discussion: PNI of upper extremities caused by gunshot, beside their often unsatisfactory functional outcome, might be associated with other injuries which require multidisciplinary approach in their treatment. Considering that they affecting working age population, consequences of these injuries have also the strong economical character.

SUSCEPTIBILITY WEIGHTED IMAGING IN DIAGNOSTICS OF MILD TRAUMATIC BRAIN INJURY

A. Brakus, M. Karan, S. Stojanović, K. Petrović, V. Karan, P. Vuleković

Introduction: 20-30% of patients with clinical presentation of mTBI and normal findings on head CT examination have signs of traumatic brain lesions if MRI exam is performed. CT is superior in detection of bony lesions and large haemorrhages demanding surgical removal or hospital treatment. MRI, especially SWI and T2 FLAIR sequences, is more sensitive in detection of small foci of blood and oedema which are specific for this type of injury.

Aim: The aim of this study was to analyse sensitivity of SWI in detection of complicated mTBI when CT examination revealed no signs of trauma.

Material and methods: We analysed clinical data and MRI findings in 34 patients suffering mTBI and admitted at Clinic for neurosurgery Clinical centre of Vojvodina in two years period. All patients had initial CT examination without signs of trauma. MRI examination including SWI sequence was performed in all patients in first 72 hours from trauma.

Results: Analysing MRI data we found lesions in 15 patients (44%). On SWI 41% of patients had small haemorrhagic lesions. One patient (7%) had lesions visible only on T2 FLAIR (pure oedematous lesions). In patients with positive MRI findings 60% of them had pure haemorrhagic lesions and 33% had mixed lesions. We failed to establish connection between any clinical findings, such as GCS score, duration of amnesia or presence of vegetative disturbances, and presence of MRI detected signs of trauma.

Conclusion: Unusually high percentage of positive MRI findings can be explained with selection bias because analysed patients had more pronounced clinical presentation of mTBI led to admission to hospital. SWI prove itself as most sensitive sequence in detection of haemorrhagic lesions. MRI should be considered as diagnostic tool in patients with more severe clinical presentation.

EVALUATION OF THE PROXIMAL STUMP IN THE C5 AND C6 LESIONS

Savic A.¹, Matic S.¹, Borovinic L.², Bascarevic V.^{1,3}, Micovic M.^{1,3}, Rasulic L.^{1,3}

1) Clinical Center of Serbia, Clinic of Neurosurgery

2) Clinical Center of Montenegro, Clinic of Neurosurgery

3) University of Belgrade, Faculty of Medicine

Introduction: The nerve repair of the brachial plexus injuries, remains a difficult and challenging problem. The use of different diagnostic procedures and detailed evaluation is necessary for correct diagnosis and successful treatment. One of the factors influencing outcome of the nerve repair is the viability of the nerve stump. In this paper we will present current principles used for evaluation of proximal stumps in treatment of C5 and C6 lesions in Clinic of neurosurgery in Belgrade.

Methods: Data from 54 consecutive patients operated for brachial plexus injury (C5 and C6) in our Clinic was obtained using patient histories. Information on all diagnostic procedures used to determine type, level and extent of nerve injury was attained. Beside clinical examination, electrophysiological and radiological evaluation was performed. In two cases where all acquired data was inconclusive, brachial plexus was surgically explored. Comparison was made, between data gained using different diagnostic procedures and histological assessment of proximal stump viability.

Results: Cervical myelography was performed in 68.7%, electromyoneurography in 86.5%, SSEPs in 46.5% cases of spinal nerve root avulsion and in 73.7% of cases with combined lesions. The combined use of preoperative diagnostic procedures was done in 80% of all traction injuries, 75% of traction injuries with spinal nerve roots avulsion and 91.7% of avulsed roots.

Intraoperative neurophysiological evaluation was performed in every case. Histological examination confirmed neurophysiological diagnosis of dysfunction of resected nerve segments, for no neurofibers or only a little degenerated neurofibers were observed in these specimens under microscope.

Conclusion: Intraoperative electrophysiological evaluation in combination with visual inspection of the proximal stump showed highly valuable in evaluating usefulness of proximal stump. According to our experience use of IEE with skillful electrophysiologist in OR is of utmost importance regarding to evaluation of the proximal stump of the brachial plexus.

INFECTION AFTER COMBAT RELATED PENETRATING HEAD INJURIES

Goran Pavlicevic

Medical Military academy, Neurosurgery Department, Belgrade, Serbia

Introduction/Objective: Combat related penetrating head injuries are considered contaminated both superficially and deep and one of the main goals of surgical treatment is preventing infection.

Materials and Methods: Clinical retrospective study on 202 patients with combat related penetrating head injuries with initial GCS more than 8, treated in our institution between 1991-1999. We tested the influence on postoperative infection of the following 7 factors: age, mechanism of injury (bullet or explosive injury), localization of injury, dura (autograft or allograft), communication with paranasal cavities, retained metal or bone fragments (larger than 10mm), postoperative liquorrhea. We have also analysed influence of postoperative infection on Glasgow outcome score.

Results: Postoperative infection occurred in 36 patients, meningitis (n=4) epidural infection (n=1), cerebritis or brain abscess (n=31). Retained metal or bone fragments ($p<0,005$) and localization had a significant influence on postoperative infection. Postoperative liquorrhea was complicated with meningitis in 40% (4/10) of the patients. Type of dural graft was not a statistically significant factor for infection, but some influence existed, since patients treated with dural autograft had lower incidence of infection than with allograft (10,36% vs 20%). Other tested factors had no influence on infection. According to GOS good recovery had 5,17%, moderate disability 32,72% and 38,7% severe disability patients with postoperative infection.

Conclusion(s): Retained metal and bone fragments and postoperative liquorrhea carries increasing risk for postoperative infection. Removal of metal and bone fragments using advantages of minimally invasive operative technique and navigation, as well as watertight dural closure, preferably with autograft, can lower incidence of postoperative infection.

“ROMAXTRADE“ LLC

“ROMAX TRADE“ LLC company with headquarters in Novi Sad is founded on March 8th 1993 as company registered for production, trade and services. Core business is wholesale trade of energetics and automatics electric material and equipment, measuring and control equipment, as well as design and construction works in the field of electric maintenance.

Company has professional and skilled manpower. At this moment company has 17 (seventeen) full time employees of electro, mechanical engineering, economics and law profession.

Company mainly operates in markets of former Yugoslav republics and as most important customers in region.

“ROMAX TRADE“ LLC constantly improves management quality which is proven by: ISO 9001, ISO 14001, OHSAS 18001, ISO/IEC 27001 and ISO 50001.

“ROMAX TRADE“ LLC has modern office space, as well as storage capacity needed for quick and efficient work.

”ROMAX TRADE” LLC ~ SPECIAL PROJECTS DIVISION

SPECIAL PROJECTS DIVISION, Belgrade branch of ROMAX TRADE LLC company is engaged in distribution of controlled and dual-purpose goods needed by the Ministry of Defense of the Republic of Serbia and the Ministry of the Interior of the Republic of Serbia, as well as their maintenance services, institutes and agencies.

Besides this, SPECIAL PROJECTS DIVISION deals with the export of special purpose goods manufactured by both domestic factories and factories of the region (former Yugoslav republics and Balkan countries) that are needed by the ministries of defense, police and other government organizations of numerous countries throughout the world.

SPECIAL PROJECTS DIVISION also offers professional consulting for numerous military, civil and development projects.

In 2013, in accordance with law and regulations, ROMAX TRADE LLC got registered for the foreign trade in controlled goods (Decision No. 355-080-00031/2013-5).

”ROMAX TRADE” LLC ~ INOX PROGRAM CROMNIK

Withing the framework of INOX PROGRAM CROMNIK distribute:

- GASTRO PROGRAM (refrigeration equipment, ovens and other equipment thermal or neutral)
- MEDICAL PROGRAM (furniture and equipment from stainless steel - INOX)
- URBAN PROGRAM (interior and exterior)
- FENCES AND GATES (and staircases, benches, bins, lamps, sculptures, ...) from stainless steel (INOX)



Miross
TRAVEL AGENCY

IATA Code: 95-2 2167 4

Leader in Congress and Business Tourism
SNSS & SEENS PCO Agency

Belgrade Office:

A: Majke Jevrosime 19/I,
11000 Belgrade, Serbia

T: +381 (11) 30-33-225, 30-33-226

F: +381 (11) 30-34-615

M: office@miross.rs

W: www.miross.rs

Podgorica Office:

A: Marka Miljanova 1,
81000 Podgorica, Crna Gora

T: +382 (20) 231-654

F: +382 (20) 231-383

M: office@miross.me

W: www.miross.me

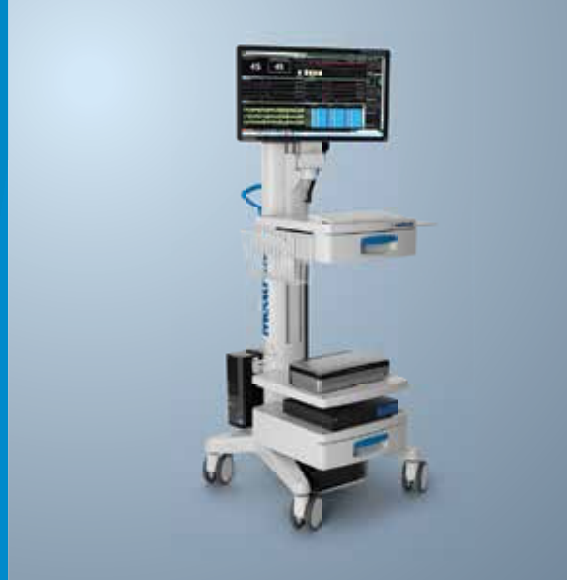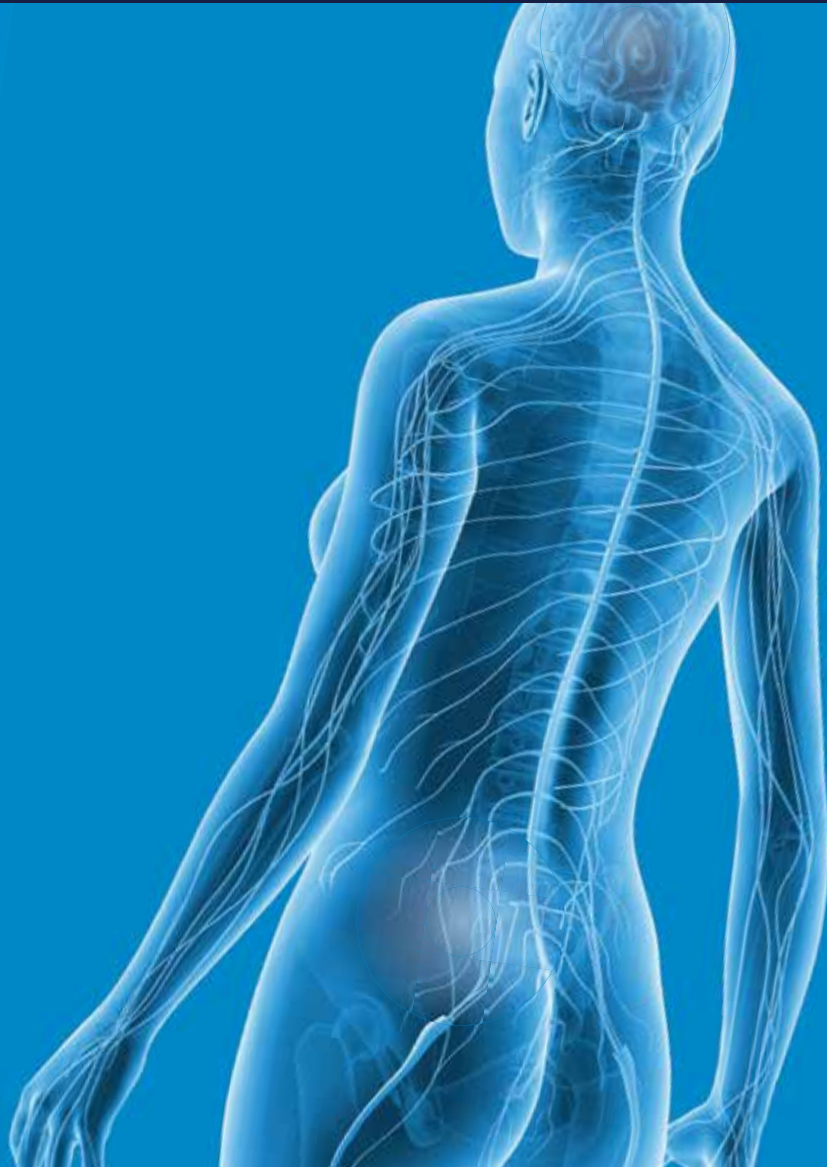


Miross
Lufthansa
City Center



COMPLEXITY SIMPLIFIED

With NIM Eclipse[®]



The platform and **Intraoperative Neuromonitoring Solution** for any type of surgery.

Please visit the Medtronic booth for more information.

**TREATING
1.5 MILLION
PATIENTS
WORLDWIDE.**

**WE EARN
YOUR TRUST
EVERY DAY**



Kyphon Balloon Kyphoplasty
for the treatment of Vertebral
Compression Fractures.

Medtronic
Further, Together

