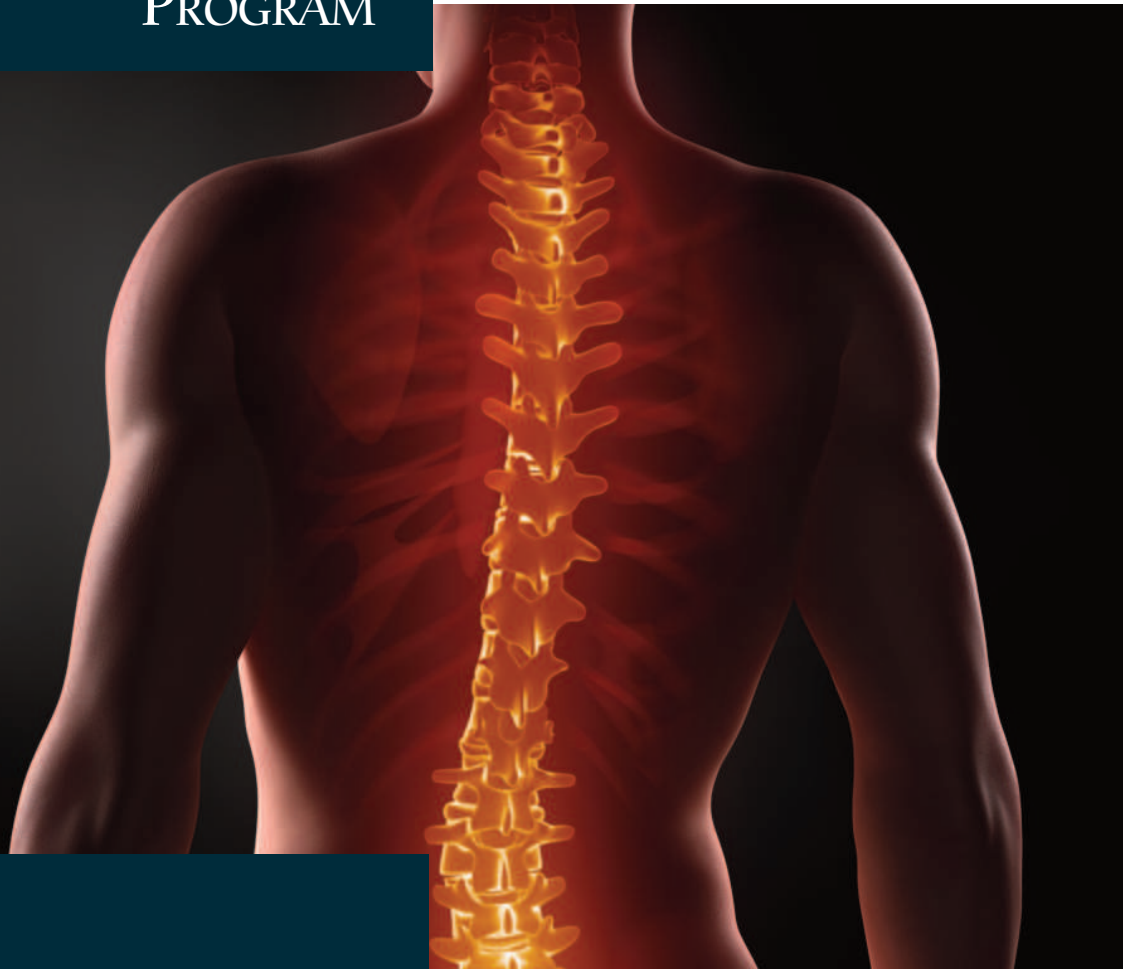


CONTROVERSIES IN SURGERY

PROGRAM



June 12-13, 2015

WESTIN HOTEL
ANNAPOLIS, MARYLAND

The
American
Academy of
Neurological
and Orthopaedic
Surgeons



Letters of Welcome

Governor of Maryland 4
 Mayor of Annapolis 5
 Chair, American Academy of Neurological and Orthopaedic Surgeons 6

Leadership

Board of Directors 7
 2015 Education and Scientific Organizing Committee 7

Continuing Medical Education

Course Sponsor 7
 Overall Course Objectives 7
 Disclosure Policy 7
 Accreditation 7
 Credit Designation 7

Keynote and Featured Lectures

..... 8

Scientific Program

Neurological and Orthopaedic Surgery 10
 Trauma and Acute Care Surgery Part II 10
 The Dr. Andre Crotti Award Recipient’s Lecture 11
 Keynote Lecture Sponsored by AANOS 11
 The Latest Update in Hepato-Pancreatic-Biliary (HPB) Surgery 12
 Neurological and Orthopaedic Surgery 12
 Annual Ethics Forum 14
 Open Forum—Free Paper Presentation 14

Acknowledgements

..... 16

Social Events

..... 17

Scientific Abstracts

..... 18

Moderator and Presenter Index

..... 29

Annapolis Westin, Floor Plans

..... Inside Back Cover

Schedule at a Glance

..... Back Cover



LARRY HOGAN
GOVERNOR

STATE OF MARYLAND
OFFICE OF THE GOVERNOR

June 12, 2015
American Academy of Neurological and Orthopaedic Surgeons
39th Annual Scientific Meeting – Controversies in Surgery

A Message From Governor Larry Hogan

Dear Friends:

I would like to welcome everyone to the 39th Annual Scientific Meeting for the American Academy of Neurological and Orthopaedic Surgeons. I am proud to call our region home to so many exceptional medical facilities, including the Johns Hopkins School of Medicine – the first research university in the U.S. – and Johns Hopkins Hospital – the founding institution of modern American medicine. Maryland has a rich history in medicine and thank you for choosing it as the location for this year's convention.

Founded in 1976, the American Academy of Neurological and Orthopaedic Surgeons serves as a scientific and educational association for orthopedists and neurosurgeons focused on improving the quality of care provided to patients in these two major sub-specialty fields. For nearly 40 years they have set high standards for training and credentialing while providing continuous surgical education through active participation in conferences and seminars such as the one you are attending now. I hope that after participating in this weekend's discussions you will have gained more knowledge about your profession, and built stronger collegial relationships in the process.

Congratulations to Chairman William Matthews and everyone else whose hard work and attendance has made this year's annual convention such a success. Best wishes for a memorable weekend and for continued progress in the years to come.

Sincerely,

A handwritten signature in black ink that reads 'Larry Hogan'.

Larry Hogan
Governor, State of Maryland

STATE HOUSE, ANNAPOLIS, MARYLAND 21401
(410) 974-3901 1-800-811-8336
TTY USERS CALL VIA MD RELAY



Michael Pantelides, Mayor
160 Duke of Gloucester Street
Annapolis, MD 21401-2517

Dear Friends,

I am pleased to welcome you to Annapolis for the 39th Annual Scientific Meeting of the American Academy of Neurological and Orthopedic Surgeons. As you gather to share your surgical knowledge and expertise with other prominent surgeons from across the nation, I applaud your goals that directly impact patient care.

While you will be discussing cutting-edge surgical techniques, I hope you will also find some time during your visit to explore some other healthy options that have been known to be effective in relieving nervous tension and stress.

Just walk out of your hotel to West Street and continue to the top of historic Main Street, where boating shoes and wing tips share the same sidewalks that George Washington and Thomas Jefferson walked along. Enjoy the fresh air coming up from City Dock, as you continue down Main Street popping in and out of our unique shops, restaurants and pubs.

End up at Ego Alley where vessels from around the world anchor for the day as they come on shore to enjoy hearing a United States Naval Academy Band concert and watch the sailboats race back and forth in front of Susan Campbell Park. While sitting at the dock enjoying an old fashioned ice cream cone, your heart will be lighter and your burdens fewer, as a colonial guide dressed in period clothing passes by calling out “Me Lords and Me Ladies.”

While I’m not sure if these options can be used in any discussions regarding surgical techniques, I highly recommend them to you as our esteemed visitors, and sincerely hope you find time to relax and enjoy your stay in Annapolis.



Sincerely,

Michael Pantelides

Michael Pantelides
Mayor



Dear Colleagues,

It is my pleasure to welcome you to the 39th Annual Scientific Meeting of the American Academy of Neurological and Orthopaedic Surgeons being held here at the Westin Hotel in Annapolis on June 12th and 13th. As you join your peers from around the world in this historic location, I hope you will take advantage of this opportunity to acquire more than 20 hours of ACCME accredited category one CME credits.

We have once again combined our meeting with the International College of Surgeons-United States Section (ICSUS). Working closely with ICSUS, we have designed a program specifically for Neurosurgery and Orthopaedic Surgery specialists that will be presented on Friday and Saturday during this conference. There are also several relevant presentations during the sessions on Thursday, June 11th, as well as an Ethics session on the afternoon of Saturday, June 13th after our session concludes. I encourage you to attend.

This year's program includes presentations on controversial cutting-edge Neurosurgical and Orthopaedic Surgery topics by several invited guest speakers and Academy members as well. I am extremely pleased and excited that we welcome our Keynote Speaker, Dr. Sergio Canavero from Italy. His research in the area of spinal fusion and its specific application for the first ever head transplant has sparked the imagination of colleagues and the media from around the world. Be sure to attend this first ever joint session with ICS where surgeons of all specialties will be amazed by Dr. Canavero's lecture.

We will also host The 6th Annual Fund Raiser and Awards Dinner in conjunction with the ICSUS Closing Banquet on Saturday evening featuring an elegant dinner, entertainment and awards.

Specially arranged entertainment by the Eastport Oyster Boys will provide some local flare and create fond memories of the camaraderie of the evening. Don't miss this event, which will benefit the AANOS Scholarship Fund.

On behalf of the members of the Scientific Organizing Committee and the Board of Directors I welcome you to Annapolis and our conference.

Sincerely,

A handwritten signature in black ink that reads "W. Mathews".

William E. Mathews, MD, FICS

Chair, American Academy of Neurological and Orthopaedic Surgeons

Chairman of the Board
William Mathews, MD, FICS
 Lafayette, CA

Manuel Alzugaray, MD, FICS
 Miami, FL

Jeffrey Epstein, MD, FICS
 Babylon, NY

Quirico Torres, MD, FICS
 Abilene, TX

Anca Bereanu, MD
 Yardley, PA

Kazem Fathie, MD, FICS
 Past Chair of the Board
 Las Vegas, NV

Paul Wakim, DO
 Huntington Beach, CA

Gene Bolles, MD, FICS
 Boulder, CO

Robert Mathews, MD, FICS
 Millersville, PA

David Weiss, MD
 Morrisville, PA

W. Craig Clark, MD, FICS
 President
 Greenwood, MS

Mark Perlmutter, MD, FICS
 Mechanicsburg, PA

David Wren Jr, MD, FICS
 Richmond, CA

Maxime Coles, MD, FICS
 Treasurer
 Coffeyville, KS

Alfonso Pino, MD, FICS
 DeLeon, TX

Charles, Xeller, MD, FICS
 Vice President
 Houston, TX

Sudhir Rao, MD
 Big Rapids, MI

Lucia Zamorano, MD, FICS
 Secretary
 Birmingham, MI

Clara Raquel Epstein, MD, FICS
 Boulder, CO

2015 Education and Scientific Organizing Committee

CO-CHAIRS

Maxime J.M. Coles, MD, FICS
 Orthopaedic Surgeon
 Coffeyville, KS

W. Craig Clark, MD, FICS
 Neurosurgeon
 Greenwood, MS

MEMBERS

Jeffrey Epstein, MD, FICS
 Neurosurgeon
 Babylon, NY

Mark Perlmutter MD, FICS
 Orthopaedic Surgeon
 Mechanicsburg, PA

Sudhir Rao, MD
 Orthopaedic Surgeon
 Big Rapids, MI

John Galea, MD
 Neurologist
 Michigan City, IN

Alfonso Pino, MD, FICS
 Orthopaedic Surgeon
 DeLeon, TX

Lucia Zamorano, MD, FICS
 Neurosurgeon
 Birmingham, MI

Course Sponsor

International College of Surgeons - United States Section
 An ACCME Accredited Provider

OVERALL COURSE OBJECTIVES

The Annual Scientific Meeting is designed to offer information regarding the latest surgical advancements and technology to address gaps in knowledge that may exist for practicing surgeons in all surgical specialties, residents in training, and allied health professionals. The desired outcome of this program is increased knowledge, better competency in cutting edge treatment modalities, and enhanced treatment decision making. It is the expressed goal of the course to provide enough material that upon completion of the activity the participant can make educated decisions to incorporate the latest surgical techniques and technologies as well as discern when these procedures are warranted to provide optimum patient care.

Topics presented during the Annual Scientific Meeting have been designed to address and improve the attendee's knowledge and skills in the following competencies; patient care or patient-centered care, medical knowledge, practice-based learning & improvement, quality improvement and professionalism.

Disclosure Policy

It is the policy of both the American Academy of Neurological and Orthopaedic Surgeons and the ICS-US that any individual who is involved in

planning or presenting in a program designated for AMA Physician's Recognition Award Category 1 Credit™ must disclose all relevant financial relationships with a commercial interest prior to being included in the final program. This information is disclosed to the audience prior to the activity. The ICS-US has procedures in place to address a conflict of interest should one arise. Our complete Policy on Commercial Support and Independence is available on FICS Online or by request from Headquarters. Additionally, faculty members are asked to disclose when any discussion of unapproved use of a pharmaceutical or medical device occurs.

Accreditation

The International College of Surgeons-United States Section is accredited by the Accreditation Council for Continuing Medical Education (ACCME) to sponsor Continuing Medical Education for physicians.

Credit Designation

The International College of Surgeons-United States Section designates this live activity for a maximum of 16 AMA PRA Category 1 Credits. Physicians should claim only the credit commensurate with the extent of their participation in the activity.

SERGIO CANAVERO, MD



Dr. Sergio Canavero is Director of the Turin Advanced Neuromodulation Group, a think tank devoted to the advancement of brain stimulation.

He entered neurosurgery with the goal of transcending human limits. In the tradition of Prof. Penfield, he believes the brain only acts as a filter to consciousness which he discusses in his book *IMMORTAL. Why Consciousness is Not in the Brain*.

Over the past 30 years, he focused on making the first head transplant possible. Along the way he worked out the genesis of Central Pain at the age of 27 (for which he has been hailed as a “benefactor of mankind” and “Italian genius” by the US website painonline.org following publication of his Cambridge University Press monograph in 2007), introduced surgical cortical brain stimulation for Parkinson disease, the vegetative state (featured in several international media outlets in December 2008) and stroke recovery. He has over 100 peer-reviewed publications and several books to his credit, including *Head Transplantation And The Quest For Immortality* (Dec 2014).

Recently, he made the news for pushing cortical brain stimulation in the rehabilitation of criminal psychopaths in place of the death penalty.

In the century that will see medical technology impact human life like never before, head-body transplantation will be at the cutting edge. In 1970, US neurosurgeon Dr. Robert White carried out the first cephalosomatic anastomosis (CSA) in monkeys, but could not rejoin the spinal cord. His goal: curing intractable medical disorders.

Now, in an unprecedented turn of events, and fulfilling Robert White’s prophecy, Dr. Canavero brings together many lines of research, some from the past, to recast the problem of spinal cord fusion in new terms.

In June 2015, he will push science forward and prove that a severed spinal cord can be reconnected with another one. The consequences? Not only the cure of hopeless disorders, but the opening of a new frontier: life extension. You will hear from him directly why he will be the first to achieve a full head transplant which will hold the key to the future of mankind. And more...

GARY DIX, MD



Dr. Gary Dix joined Maryland Brain & Spine November 2004. For four years prior to this, Dr. Dix worked in Baltimore, seeing patients at Sinai Hospital, Good Samaritan Spine Center, St. Josephs Medical Center, Maryland General Hospital and Northwest Hospital.

He has extensive experience with complex spine and brain disorders, incorporating the use of the latest minimally invasive procedures, as well as stereotactic radiosurgery to non-invasively treat conditions of the brain and spine. He is also involved in research and teaching and serves as a consultant for several biotechnology companies. Dr. Dix is available in our Annapolis and Bowie locations.

Dr. Dix was born and raised in South Africa where he received his medical degree from the University of Stellenbosch. After completing his internship at Baragwaneth Hospital in Soweto, he immigrated to Canada where he practiced family medicine in northern British Columbia, providing him a unique perspective in helping patients to make decisions about their surgery. In 1993, Dr. Dix entered the neurosurgery residency program at the University of Calgary, Canada and then completed a spine surgery fellowship at Foothills Hospital in Calgary, where he served as staff neurosurgeon for two years. He passed the certifying boards in neurosurgery (2006).

XIAOPING, REN, MD



Dr. Xiaoping Ren received his MD from Harbin Medical University in 1984. He performed his Clinical and Research Hand Fellowship training at the University of Louisville in Kentucky (1996-2000). During this period Dr. Ren created a feasibility large animal CTA model for limb transplantation to allow modulation of the immune reaction and to investigate immunosuppressants. The Nation’s First Hand Transplantation in US was successfully conducted as a direct result of the preclinical swine composite tissue allotrans-

plantation model (CTA). He joined the University of Cincinnati College of Medicine as faculty member in 2001, then appointed Assistant professor and Associate Professor. As well as CTA, another focus of his research program is to understand molecular and neuronal basis of non-ischemic nociceptor-induced cardioprotection. These studies were published in the *Journal of Surgical Research* and in *Circulation*. Dr. Ren has had over 40 publications in peer-reviewed journals. He also serves as a peer reviewer for several journals.

CHAD PATTON, MD, MS



Originally from Kentucky, Dr. Patton completed his undergraduate studies in Neuroscience at Vanderbilt University in Nashville, TN. He subsequently obtained a Master of Science degree in the treatment of spinal cord injury using human stem cells, as well as his Medical Degree, from the University of Louisville School of Medicine. Dr. Patton completed his residency in Orthopaedic Surgery at the University of Vermont. Prior to performing spine surgery in Annapolis, he completed his Spine Surgery fellowship training at the University of Utah School of Medicine, where he worked with both Orthopaedic spine surgeons and neurosurgeons.

Dr. Patton specializes in the operative treatment of spine-related disorders, including degenerative conditions of the

cervical and lumbar spine, disc herniations, spinal stenosis, compression fractures, spinal tumors, as well as adult scoliosis and deformity.

Dr. Patton graduated medical school as a member of the AOA Honor Medical Society and a strong background in research. As a resident, his orthopaedic trauma research was awarded top honors in the New England region, and nationally recognized by the American College of Surgeons. Currently, his interests focus on patient outcomes after spine surgery. Dr. Patton is a member of the American Academy of Orthopaedic Surgeons, AO Spine North America, and the North American Spine Society.

PATRICIA SCRIPKO, MD



Dr. Scripko was born in Baltimore, Maryland. She attended Bucknell University where she studied dance and biology. Scripko then attended medical school at the Cleveland Clinic Lerner College of Medicine of Case Western Reserve University, where she also completed

a Master's in Bioethics. Her interest in Bioethics centered around human enhancement, specifically neurological enhancement, and human life/death. While in medical school, she completed a 1 year research fellowship at the Harvard Stem Cell Institute. She was awarded a Howard Hughes Medical Institute Research Scholarship and a Sarnoff Cardiovascular Research Grant for her stem cell work, as well as a Cleveland Clinic Clinical Research Grant, and several awards for her Bioethics research. She presented her Bioethics work at multiple stem cell conferences, Harvard Business School, Harvard Stem Cell Institute, Cleveland Clinic and Oxford University. Upon graduation, she was given the Alice Paige Leadership Award of Case Western Reserve. After medical school,

she completed her neurology residency at the Massachusetts General Hospital/Brigham and Women's Hospital in Boston. There, she published several papers on brain death and coma based on translational research she began at Massachusetts General Hospital during medical school. She developed a strong interest in headache, and was chosen for the 2014 International Headache Academy at the Mayo Clinic.

Currently, she resides in Monterey, CA, and is a neurologist at Salinas Valley Memorial Hospital. Her clinical interests include headache, pain management, traumatic brain injury (TBI) and acute neurological care. She has started an inpatient headache program at her hospital and serves on their bioethics committee. She also serves as a neurologist for the Laguna Seca race track in Monterey where she is implementing a concussion/TBI protocol. She spends her free time with her husband, golden retriever and children.

DEBRAJ MUKHERJEE, MD



Dr. "Raj" Mukherjee obtained his undergraduate degree from Virginia Commonwealth University, where he was accepted into the select BS/MD program as a Presidential Scholar and where he graduated in 3 years at the top of his class, summa cum laude with university honors as a Biology major. He received his institution's highest undergraduate research award for his work on the role of calcineurin in status epilepticus.

He received his medical degree from Dartmouth Medical School, where he was named a C. Everett Koop Scholar, Rhodes Scholar finalist, Gold Humanism in Medicine Honor Society member, and where he served as a health policy fellow under Surgeon General Richard Carmona. Following medical school, Raj was recruited to Johns Hopkins Bloomberg School of Public Health, where he studied epidemiology, biostatistics, and clinical design as a Sommer Scholar, Albert Schweitzer Fellow, and member of Delta Omega Honor Society. Dr. Mukherjee was also a Halsted sur-

gical intern at Johns Hopkins Hospital, where he received awards for clinical excellence as well as the Resident Golden Apple Teaching Award.

Dr. Mukherjee's clinical research has focused on finding ways to improve brain tumor patient outcomes. He has lead efforts to update a 10-year brain tumor retrospective database at Johns Hopkins, he has mined national databases including the Nationwide Inpatient Sample and Surveillance Epidemiology and End Results database, and he is developing a prospective database to capture quality of life data on patients with low- and high-grade gliomas, pituitary adenomas, and metastatic CNS tumors at multiple institutions across the country. He is also involved in multi-disciplinary work aimed at using pre-operative MRI signal characteristics in conjunction with tumor cell genetic deletions and histological markers with the aim of providing future patients better pre-operative prognostic information while providing providers useful new information for operative planning.

FRIDAY, JUNE 12, 2015

NEUROLOGICAL AND ORTHOPAEDIC SURGERY

9:00-11:00 AM

SENATE A&B

Moderator: W. Craig Clark, MD

A primary goal of the United States Section of the International College of Surgeons is to foster relationships with like-minded organizations to advance the art and science of surgery. For more than 10 years, the College has worked with the American Academy of Neurological and Orthopaedic Surgeons (Academy) to develop scientific programming in the specialties of Neurosurgery and Orthopaedic Surgery. The sessions presented on Friday and Saturday have been developed with the support and assistance of the Academy, its Board of Directors and Scientific Organizing Committee. Presentations include abstract submissions from members of both groups as well as invited presentations by renowned surgeons in these major surgical specialties.

Surgical Management of Back Pain

Chad Patton, MD, MS, Spine Surgery Medical Director, Anne Arundel Medical Center Spine Program, The Orthopaedic and Sports Medicine Center Annapolis, Maryland, Annapolis, MD

Minimally Invasive Instrumented Surgery for Sacroiliac Joint Dysfunction

Gary Dix, MD, Neurosurgeon, Maryland Brain and Spine, Annapolis, MD

Current State of Opioid Guidelines

Charles Xeller, MD, FICS, Orthopaedic Surgeon, League City, TX

Coffee Break - 9:45-10:00 AM

TRAUMA AND ACUTE CARE SURGERY PART II

10:00 AM-Noon

CAPITOL A&B

Moderators: Domingo Alvear, MD & Mayur Narayan, MD

The Multidisciplinary Management of Complex Hepatic Trauma

David Efron, MD, Associate Professor of Surgery, Anesthesiology and Critical Care Medicine, Emergency Medicine Chief, Division of Acute Care Surgery, Baltimore, MD

Acute Care Surgery Model in the World of Specialty Surgery

Adrian Park, MD, Chairman of the Department of Surgery and Chair of the newly created Earl Simulation to Advance Innovation and Learning (SAIL) Center of Anne Arundel Health System (AAHS) in Annapolis, Maryland

Damage Control Surgery

Gene E. Bolles, MD, FICS, Associate Professor of Neurosurgery, University of Colorado Medical Center and Denver Health Medical Center, Denver, CO

Innovative Management for Traumatic Brain Injury: Compartments Communicate

Thomas M. Scalea, MD, Professor of Surgery, University of Maryland School of Medicine, Baltimore, MD

FRIDAY, JUNE 12, 2015

LUNCH AND THE DR. ANDRE CROTTI LECTURE

Noon-1:30 PM

CAPITAL D

Moderator: Uretz Oliphant, MD

There is perhaps no story in medical science over the past 100 years more fascinating than the life of Dr. William Stewart Halsted, generally regarded as the most innovative and influential surgeon the United States has produced. The number and magnitude of Dr. Halsted's contributions to surgery are staggering. This year's Dr. Andre Crotti Award recipient, who is in his own right considered a pioneer in surgery, will remind us all about this important individual from our past.

William Stewart Halsted: Our Surgical Heritage

John Cameron, MD, 2015 Andre Crotti Award Recipient, The Alfred Blalock Distinguished Service Professor, The Johns Hopkins University School of Medicine, Baltimore, MD

KEYNOTE LECTURE SPONSORED BY AANOS

1:30- 3:00 PM

CAPITAL A&B

Moderators: Uretz Oliphant, MD & William Mathews, MD

What is surgery? Pushing the limits. That is why we became surgeons. Testing our limits and the limits of what is achievable. No more than a few decades ago, surgery on the heart was believed to be beyond our grasp, now it is routine. Same goes for the brain. Not to mention transplantation. Surgery is outsmarting nature.

When Robert White carried out his first head transplantation on a monkey, he was drowned in criticisms of all kinds. The past has given us the key to achieve spinal cord fusion and conduct the first human head transplant. By questioning what we used to believe was the correct view of motor and sensory physiology, we can now move on to tap the power of the central nervous system and make it work. This lecture will include details about and provide opportunities for discussion of HEAVEN: the head anastomosis venture project for the first human head transplantation with spinal linkage (GEMINI).

HEAVEN-GEMINI: Head Transplantation—The Future Is Now

Sergio Canavero, MD, Director, Turin Advanced Neuromodulation Group, Turin, Italy

Coffee Break - 3:00-3:15 PM

THE LATEST UPDATES IN HEPATO-PANCREATO-BILIARY (HPB) SURGERY

3:15-5:45 PM

SENATE A&B

Moderators: Reza Saidi, MD & Michael Jacobs, MD

Various HPB related topics will be addressed by experts from Johns Hopkins as well as by members of ICS. Using evidence-based medicine, this session is designed to provide a comprehensive overview of the surgical and medical management of patients with malignancies, neoplasms, and diseases involving the liver, gallbladder, bile ducts and pancreas.

Debate - Controversies of Pancreatectomy

Minimally Invasive Approach: **Matthew Weiss, MD**, Assistant Professor of Surgery, Johns Hopkins Hospital, Baltimore, MD

vs

Open Approach: **Michael J. Jacobs, MD, FICS**, Attending Surgeon Providence Hospital, Southfield, MI

Recent Advances in Liver Transplantation: HCC, Hepatitis C, and Sharing

Andrew Cameron, MD, PhD, Associate Professor of Surgery, The Johns Hopkins University School of Medicine, Baltimore, MD

continued on next page

FRIDAY, JUNE 12, 2015

THE LATEST UPDATES IN HEPATO-PANCREATO-BILIARY (HPB) SURGERY (CONTINUED)
3:15-5:45 PM **SENATE A&B**

Cystic Neoplasms of the Pancreas

Christopher Wolfgang, MD, PhD, Associate Professor of Surgery, Pathology and Oncology, Baltimore, MD

Laparoscopic Pancreas Surgery

Martin Makary, MD, MPH, Professor of Surgery Johns Hopkins Hospital, Baltimore, MD

Controversies and Updates in Management of Patients with Intrahepatic Cholangiocarcinoma

Timothy Pawlik, MD, MPH, PhD, Professor of Surgery and Oncology, Johns Hopkins Hospital, Baltimore, MD

Incidence and Risk Factors of Deep Vein Thrombosis After Liver Transplant

Alagappan Annamalai, MD, FICS, Cedars-Sinai Medical Center, Los Angeles, CA

Liver Transplantation for Malignant Neoplasms

Reza F. Saidi, MD, FICS, FACS, Assistant Professor of Surgery Division of Organ Transplantation Department of Surgery University of Massachusetts Medical School, Providence, RI

SATURDAY, JUNE 13, 2015

NEUROLOGICAL AND ORTHOPAEDIC SURGERY

8:00-10:00 AM

SENATE A&B

Moderators: Sudhir B. Rao, MD & William Mathews, MD

See Page 10 for description

Constrained Fixed-Fulcrum Reverse Shoulder Arthroplasty for the Treatment of Epilepsy-Related Recurrent Shoulder Instability

Tanujan Thangarajah, MB ChB (hons), MRCS, MSc, Research Fellow, The John Scales Centre for Biomedical Engineering, Institute of Orthopaedics and Musculoskeletal Science, Division of Surgery and Interventional Science, University College London, London, UK

Shoulder Arthroplasty in Epileptic Patients

Tanujan Thangarajah, MB ChB (hons), MRCS, MSc, Research Fellow, The John Scales Centre for Biomedical Engineering, Institute of Orthopaedics and Musculoskeletal Science, Division of Surgery and Interventional Science, University College London, London, UK

Early Decompressive Craniectomy in Traumatic Brain Injuries: A Case Series from the Kingdom of Cambodia

Paul Park, MD, PhD, Global Outreach Fellow, Korean American Medical Association, Preah Kossamak Hospital, Phnom Penh, Kingdom of Cambodia, Reno, NV

Surgical Treatment of Humerus Fractures

Sudhir B. Rao, MD, Big Rapids Orthopaedic PC Premier Hand Center Big Rapids, Michigan, Big Rapids, MI

Commodifying Human Traits: The Neuroethical Aspect

Patricia Scripko, MD, Neurologist, Salinas Valley Memorial Hospital, Salinas, CA

Endoscopic Transphenoidal Surgery: A Transition To Neurosurgery-Ent Collaboration Producing Better Outcomes

Bharat Guthikonda, MD, FICS, Associate Professor Director of Skull Base Research Department of Neurosurgery LSU HSC Shreveport

Coffee Break - 9:45-10:00 AM

SATURDAY, JUNE 13, 2015

NEUROLOGICAL AND ORTHOPAEDIC SURGERY (CONTINUED)

10:00 AM-NOON

SENATE A&B

Moderators: Maxime Coles, MD & Bharat Guthikonda, MD

Long-Term Effectiveness of a Non-surgical Treatment for Carpal Tunnel Syndrome

Michael Politis, PhD, Carpal Pain Solutions, Inc., Palm City, FL

Claudication- Neurogenic or Vascular

Gerald Q. Greenfield, Jr., MD, MS, FICS, Clinical Assistant Professor, Orthopaedic Surgery University of Texas Health Sciences Center- San Antonio, San Antonio, TX

Controversies in Neurosurgery: Vertebroplasty vs Kyphoplasty

W. Craig Clark, MD, PhD, FICS, Greenwood Leflore Neurosurgery, Greenwood, MS

Controversies in Neurosurgery: Radiosurgery vs Microsurgery for Benign Tumors in the Adult Posterior Fossa

W. Craig Clark, MD, PhD, FICS, Greenwood Leflore Neurosurgery, Greenwood, MS

Management and Treatment of Sports Concussions

Gene E. Bolles, MD, FICS, Associate Professor of Neurosurgery, University of Colorado Medical Center and Denver Health Medical Center, Denver, CO

Pitfalls in the Treatment of Distal Humerus Fractures

Maxime J.M. Coles, MD, FICS, Orthopaedic Surgeon, Coffeyville Orthopedics, Coffeyville, KS

Surgical Management of Epilepsy

Lucia Zamorano, MD, FICS, Professor of Neurological Surgery, William Beaumont Oakland University School of Medicine, Birmingham, MI

Preclinical Studies of Allogeneic Head and Body Reconstruction

Xiaoping Ren, MD, Professor of Surgery Hand and Microsurgical Center, The Second Affiliated Hospital, Harbin Medical University, Harbin, China

LUNCH

NOON-1:30 PM

CAPITOL D

NEUROLOGICAL AND ORTHOPAEDIC SURGERY (CONTINUED)

1:30-2:15 PM

SENATE A&B

Moderator: Anca Bereneau, MD

Dynamic Cervicomedullary Cord Compression and Alterations in Cerebrospinal Fluid Dynamics in Children with Achondroplasia

Debraj Mukherjee, MD, MPH, MPH, Maxine Dunitz Neurosurgical Institute Department of Neurosurgery Cedars-Sinai Medical Center Los Angeles, CA, Los Angeles, CA

The Latest Clinical Surgical Total Hip Replacement Advancements in Painful Osteoarthritis of the Hip

Robert S. Mathews, MD, PhD, Director of First Team Institute LLC, Millersville, PA

Clinical Depression and ACL Reconstruction: Incidence and Impact on Functional Outcome, a Prospective Cohort Study

Hao-Hua Wu, BA, Third Year Medical Student, Perelman School of Medicine at the University of Pennsylvania, Philadelphia, PA

SATURDAY, JUNE 13, 2015

ANNUAL ETHICS FORUM

2:15-3:30 PM

CAPITAL A&B

Moderator: Frank Bongiorno, MD

Many outside forces seem to corrupt and threaten the relationship between doctors and patients. A doctor's decisions may be influenced by these forces to the detriment of their patients. This session will debate how outside influences are threatening patient care and the relationship between a doctor and their patient. Various scenarios will be presented with ample time for interaction between the audience and panelists.

How Medical Care Is Being Corrupted

Timothy Pawlik, MD, MPH, PhD, Professor of Surgery and Oncology, Johns Hopkins Hospital, Baltimore, MD

OPEN FORUM — FREE PAPER PRESENTATIONS

3:30-5:30 PM

CAPITAL A&B

Moderators: Marco Pelosi, III, MD & Joshua Mammen, MD

This session will include submitted abstract presentations from ICS Fellows, Non-members, Residents and medical students that will address the varied surgical specialties represented within the College. Participants will increase their comprehension of the topics and cases discussed allowing for optimal patient care in a multi-disciplinary setting.

A Team Based Intervention Can Improve Surgical Patient Satisfaction and Readmission Rates in a Teaching Hospital

Sivamainthan Vithianathan, MD, FICS, FACS, Associate Professor of Surgery (Clinical) Alpert Medical School of Brown University Chief, Minimally Invasive and Bariatric Surgery The Miriam and Rhode Island Hospitals, Providence, RI

Profound Hemorrhagic Anemia with No Transfusions

Raymond A. Dieter, MD, FICS, Cardiothoracic Surgeon, Glen Ellyn, IL

Vaginal Surgery Under Local Anesthesia: An Emerging Paradigm

Marco A. Pelosi III, MD, FICS, Director, Pelosi Medical Center, Bayonne, NJ

Update on Light Adjustable Lenses

Phillips Kirk Labor, MD, FICS, Founder, Eye Consultants of Texas, Grapevine, TX

Successful Incorporation of Midlevel Providers in an Academic Surgical Division

Joshua M.V. Mammen, MD, PhD, MBA, FICS, Associate Professor of Surgery and Molecular & Integrative Physiology, University of Kansas, Kansas City, KS

Massive Gastrointestinal Bleeding From Jejunal Diverticulosis: Angiographic Localization and Resection

Jesse Flores, MD, Resident, Texas Tech University Health Sciences Center, Lubbock, TX

Rib Plating of Traumatic Rib Fractures: Patient Selection, Operative Planning and Technique

Milad Mohammadi, MD, Resident, Texas Tech University Health Sciences Center, Lubbock, TX

Non-Surgical Management of Pilonidal Disease - is it Feasible?

Jonathan Cook, MD, General Surgery Resident, PinnacleHealth Hospitals, Harrisburg, PA

Welcome

THE CHAIRMAN OF THE BOARD, OFFICERS AND MEMBERS OF THE AMERICAN ACADEMY OF NEUROLOGIC AND ORTHOPAEDIC SURGEONS WOULD LIKE TO WELCOME THE FOLLOWING NEW MEMBERS WHO HAVE JOINED THE ACADEMY IN THE LAST 12 MONTHS.

Jay Talsonia, MD
Orthopaedic Surgery
Allentown, PA

Mohamed Ahmed, MD
Orthopaedic Surgery
Astoria, NY

Khalid Mehmood, MRCS
Neurosurgery
Ryadh, Saudi Arabia

Tariq Lamki, MD
Neurosurgery
Columbus, OH

Tobias Mattei, MD
Neurosurgery
Williamsville, NY

With Our Thanks

THE FOLLOWING INDIVIDUALS MADE FINANCIAL CONTRIBUTIONS TO ESTABLISH THE KEYNOTE SPEAKER FUND THAT ENABLED THE ACADEMY TO BRING DR. CANAVERO TO ANNAPOLIS

Christopher Barry, MD
Del City, OK

Kazem Fathie, MD
Las Vegas, NV

Corey Ruth, MD
Philadelphia, PA

Anca Bereanu, MD
Yardley, PA

William Mathews, MD
Lafayette, CA

Quirico Torres, MD
Abilene, TX

Gene Bolles, MD
Boulder, CO

Stephen Neely, MD
Lebanon, TN


David Wren Jr., MD
Richmond, CA

Stephen Earle, MD
San Antonio, TX

Mark Perlmutter, MD
Mechanicsburg, PA

Jeffrey Epstein, MD
Babylon, NY

Sudhir Rao, MD
Big Rapids, MI



**THIS SCIENTIFIC MEETING
WOULD NOT BE POSSIBLE WITHOUT THE GENEROUS SUPPORT FROM THE FOLLOWING:**

EXHIBITORS

DePuy Synthes Spine

Globus Medical

SI-BONE, Inc.

Southern Spine, LLC

EXPLORE ANNAPOLIS

Thursday, June 11

10:20-11:20 AM

Senate A&B

This event; geared towards Alliance members, spouses, and family members who are visiting Annapolis during the Annual Meeting will provide attendees with an overview of the history of the city, how Annapolis came to be what it is today and an understanding of the not-to-be-missed highlights of the city during your visit. A local historian will be your guide to the historical importance and highlights of our host city.

Free to all attendees but check with Registration for On-Site Availability.

ALLIANCE BOARD OF DIRECTORS & GENERAL MEMBERSHIP MEETING

Thursday, June 11

11:20-Noon

Senate A&B

Please join us to discuss Alliance plans for the Annual Meeting and beyond. Topics will include future leaders, and current & future social activities for the Alliance. If you have ever wondered what the Alliance is or does, then this meeting shouldn't be missed.

HONORS LUNCHEON

Thursday, June 11

Noon-1:30 PM

Capital D

Please join us as we induct our Section's new Fellows into the College and honor those who have contributed to the success of our meeting and our Section. The winners of the Scholarship competition will also be announced here.

WELCOME RECEPTION

Thursday, June 11

6:00-7:00 PM

Senate B

Our first day's scientific session in Annapolis ends with a cocktail reception. Join us as we kick off the 77th Annual Surgical Update; reconnect with old friends welcome New Fellows and meet members you may not have encountered before.

NAVAL ACADEMY TOUR

Friday June 12

8:45 AM-Noon

Gather at Registration

Friday morning you may choose to depart for a historical tour of the famed United States Naval Academy. Your tour highlights include life at the U.S. Naval Academy past and present. Tour includes Lejeune Hall, Bancroft Hall, Tecumseh Court, Herndon Monument, Main Chapel (when open) and the Crypt of John Paul Jones, Revolutionary War hero.

Everyone 18 and older must have a government-issued photo ID. Photo copies of ID (passports, ID Cards, etc.) cannot be accepted. If you are not a US citizen, please bring your passport.

The tour will last roughly an hour & a half including transportation to and from the Naval Academy. There will be at least one mile of walking over varied surfaces and steps.

Price: \$12 per person. **Check with Registration for On-Site Availability.**

CLOSING DINNER

HOSTED BY

THE AMERICAN ACADEMY OF NEUROLOGICAL AND ORTHOPAEDIC SURGEONS

AND

THE INTERNATIONAL COLLEGE OF SURGEONS - UNITED STATES SECTION

Saturday, June 13

7:00-10:00 PM

Capital D

Join us as we come together for one last event before we bid farewell until next year. Uretz J. Oliphant, MD and William Mathews, MD invite you to attend the combined closing dinner of AANOS and the ICS-US. The buffet style meal will feature complimentary wine at your table, a cash bar, award presentations and live entertainment.

Price: \$100 per person. **Check with Registration for On-Site Availability.**

The following Abstracts are listed in alphabetical order by presenting author.

They have been reproduced as submitted with limited editing.

Incidence And Risk Factors Of Deep Vein Thrombosis After Liver Transplant

Anand Annamalai, MD, FICS

Cedars-Sinai Medical Center, Los Angeles, CA

Purpose: Deep venous thrombosis (DVT) occurs in 0.1% of persons per year affecting 15-40% of general surgical procedures without prophylaxis. Thromboembolic prophylaxis is not commonly used after orthotopic liver transplantation (OLT) due to the risks of bleeding and coagulopathy. Cirrhosis and the association with the coagulation cascade, pre and post-transplant, are not well understood. The purpose of our study was to determine the incidence of DVT and its' risk factors after OLT.

Methods: We retrospectively reviewed OLT performed at our center from 2005 to 2012. We identified patients with Doppler examinations showing DVT post-OLT, platelet count and international normalized ratio (INR) at time of DVT, associated symptoms, DVT prophylaxis, and perioperative risk factors. We determined the incidence of DVT, the odds ratio of each preoperative risk factor, the difference in platelet count and INR between those with and without a DVT, and the weighted risk of each factor in the development of a DVT using logistic regression modeling.

Results: Of 314 patients, the incidence of DVT was 8.6% (27/314). Between those with and without DVT there was no significant difference in age, gender, platelet count, INR, infection, hepatocellular cancer, use of venous bypass, and prior surgery. There was a significant difference in mobility, 67% vs 20% ($p < 0.0001$) and the use of factor VII, 11% vs 2% ($p < 0.05$). The estimated risk for of developing DVT for patients with neither of these factors was 4%; with factor VII the risk rose to 17%; with mobility difficulty the risk rose to 23%; and with both the risk was 62%. In our entire population, there were no cases of pulmonary embolism.

Conclusions: The risk of developing a DVT after OLT is at least 9% even with mechanical DVT prophylaxis. Consideration should be given to using both mechanical and chemical prophylaxis after OLT.

Controversies in Neurosurgery: Vertebroplasty vs Kyphoplasty

W Craig Clark, MD, PhD, FICS

Greenwood Leflore Neurosurgery, Greenwood MS

Purpose: Vertebral Compression Fractures (VCFs) are quite common in the elderly due to a combination of more fragile or brittle osteopenic or osteoporotic bone and an increased number of falls. Due to the overall increase in the aging population, we can expect an ever increasing incidence of VCFs. Maybe of even more significance are complications associated with these events due to the associated pain and secondary lack of mobility. Within the last decade minimally invasive procedures that involve the internal fixation of these fractures with bone cement have been developed. Initially this was the vertebroplasty, and later kyphoplasty. The relative advantages and disadvantages of each procedure or technique is explored, with an emphasis on complication avoidance and maximizing patient safety.

Methods: This study involves the retrospective review of the author's 15 year experience with cementoplasty administered for the treatment of VCF. Parameters examined include patient demographics, LOS, OR time, rates of extravasation or embolization of the bone cement, intra- and perioperative complications, and patient satisfaction

Results: There were in excess of 300 cases available for review and followup. The treatment groups were stratified based on vertebroplasty versus kyphoplasty. Parameters of each group will be presented with nonparametric statistical tests of significance.

Conclusions: Based upon the statistical analysis noted above, subgroup analysis and stratification will attempt to recommend the most efficacious, least costly and safest cementoplasty treatment of VCFs.

Controversies in Neurosurgery: Radiosurgery versus Microsurgery for Benign Tumors in the Adult Posterior Fossa

W Craig Clark, MD, PhD, FICS

Greenwood Leflore Neurosurgery, Greenwood MS

Purpose: The most common benign posterior fossa tumors in adulthood are generally recognized to be meningiomas and nerve sheath tumors. As experience developed the goal of treatment shifted from complete resection to preservation of hearing and facial function. Several large clinical series have now been published and provide the case data for this report. When should the neurosurgeon recommend open microsurgery and when should stereotactic radiosurgery be employed? How effective is radiosurgery in providing growth control of these usually slowly progressive masses? How important is "Gross Total Resection" in the management scheme?

continued on next page

Methods: Several large clinical series of the tumors in question have been reported in the literature. These studies have been combined to provide the case mix for the current report. Variables included were patient demographics, tumor size, any prior surgery in the area, preoperative hearing status and facial function, and progression free intervals during follow-up.

Results: The preliminary results suggest the most predictive variables were tumor size and the presence of any hearing loss or facial weakness. The data are yet to be tested for statistical significance, with that information reported at time of presentation.

Conclusions: The ability to preserve hearing is most often related to tumor size, regardless if the surgeon elects to use radiosurgery or microsurgery. There are finite limits on ideal tumor size to be treated with radiosurgery due to the risks for tumor necrosis, swelling and mass effect in the posterior fossa.

Non-Surgical Management of Pilonidal Disease – is it Feasible?

Jonathan Cook, MD

General Surgery Resident, PinnacleHealth Hospitals, Harrisburg, PA

Purpose: Pilonidal disease is a dermatologic condition affecting the sacrococcygeal region. The condition was first described by Herbert Mayo in 1833. Pilonidal disease commonly manifests as recurrent abscesses and chronic infection of hair follicles in the gluteal cleft. It is a debilitating condition and conventional surgical management can result in considerable morbidity. Despite a variety of surgical approaches and closures, excision of skin in the intergluteal region is associated with high recurrence rates and difficulties in achieving optimal wound healing. Numerous studies have recognized that hair in the natal cleft plays a central role in the etiology of primary pilonidal disease as well as in the development of recurrent disease after surgery. Laser epilation is a safe and effective outpatient method of hair removal. When utilized as part of a strategy to treat pilonidal disease, laser therapy has been shown to be effective in removing hair both in primary and recurrent pilonidal disease. Our study goals:

- * Determine the efficacy of laser therapy as an alternative to surgery in the treatment of pilonidal disease.
- * Evaluate laser hair removal as an adjunct to surgical management of pilonidal disease, especially in the prevention of recurrence.
- * Develop an algorithm for the treatment of pilonidal disease that minimizes time to wound healing, discomfort, and recurrences.

Methods: * Twenty-three patients, ages 11 – 23 were treated over a five year period, according to our treatment algorithm. Incision and drainage was undertaken when necessary, but surgical excision of intergluteal skin was not performed. * Laser therapy consisted of alexandrite (755nm) or NdYag (1064nm), depending on hair type and Fitzpatrick skin type.

Results: * Nine of twenty-three patients (40%) required surgery throughout the course of the study.
* Clinical response (significant reduction in symptoms) was achieved in 100% of those treated. Complete resolution occurred in twenty-one of twenty-three patients (91%).
* Data collection is ongoing

Conclusions: * Laser hair removal provides a safe and effective adjunct to surgical management of pilonidal disease.
* Although not proven to be curative in severe disease, laser therapy alone achieves excellent results in mild and moderate disease.
* Laser treatment is less morbid than conventional surgery with less post operative pain.
* Outcomes are improved when laser therapy is used in conjunction with surgery to prevent hair growth into healing wounds.
* Further study is needed to determine the role of laser hair removal as an alternative to surgical therapy in the prevention of recurrences.

Profound Hemorrhagic Anemia with No Transfusions

Raymond A. Dieter, Jr., MD, FICS

Cardiothoracic Surgeon, Glen Ellyn, IL

The first blood transfusion in DuPage County was in the early 1930's by Dr. C. A. Gutzmer for meningitis with shock and success. No crossmatch was done - only withdraw from the donor and inject the recipient. Since then, blood transfusion has been utilized frequently for treatment of shock, hemorrhage, anemia, and other diseases. More recently, the wisdom of when to transfuse has been questioned due to potential risks.

continued on next page

In general, hemorrhagic shock has been routinely treated with fluids and blood infusion. Initially, guidelines of 9 to 10 gram hemoglobin were felt to be an acceptable indication for transfusion. Later this level was dropped to as low as 7.0 gram hemoglobin in the postoperative period before red cell transfusion. Most non-surgeons transfusing before then. Two patient examples demonstrate that such an arbitrary level does not necessarily bode ill. A 90 year-old female was flipped off a bus onto a Chicago curb into the snow. She bled down to 1.8 gram hemoglobin, due to a large laceration. The second patient, struck by a train, bled down to a hemoglobin of 2.0 grams at age 20. Neither patient was transfused with blood. Both patients received IV fluids and walked out of the hospital with no ill consequences except feeling tired. Both patients hemoglobin rose rapidly while followed as outpatients.

Minimally Invasive Instrumented Fusion for Sacroiliac Joint Dysfunction

Gary Dix, MD

Neurosurgeon, Maryland Brain and Spine, Annapolis, MD

Purpose: Studies indicate that for up to 25% of patients diagnosed with low back pain, their symptoms arise in their sacroiliac joints (SIJ). In those patients with intractable SIJ pain and dysfunction that have failed to respond to conservative treatment, traditional surgical intervention consists of open in-situ arthrodeses with or without instrumentation. Results for this type of operation have consistently been associated with low success rates and high morbidity. A novel minimally invasive technique for fusing the sacroiliac joint appears to significantly improve patients' functional outcomes and quality of life indices.

We present a single-surgeon series of more than 70 patients that have undergone minimally invasive, fluoroscopically-guided placement of multiple triangular, plasma-coated, titanium dowels across the symptomatic sacroiliac joint, following thorough clinical and radiographic work up. Six month and 2 year follow up results confirm excellent short and long term patient satisfaction rates, with more than 20% of patients subsequently electing to have a second operation on the contralateral side. Post operative complication rates have been low.

Minimally invasive instrumented fusion of persistently symptomatic SIJ pain and dysfunction represents a novel approach to managing this problem, with low complication rates and good long term patient outcomes.

Massive Gastrointestinal Bleeding From Jejunal Diverticulosis: Angiographic Localization and Resection

Jesse Flores, MD

Resident, Texas Tech University Health Sciences Center, Lubbock TX

Purpose: The case herein describes massive lower gastrointestinal bleeding secondary to Jejunal Diverticulosis diagnosed and localized with angiography, and subsequently resected.

Methods: Retrospective case review: Jejunal Diverticulosis (JD) is a rare clinical condition, with a reported incidence of 0.3%-4.5% at autopsy. These false diverticula are mucosal evaginations on the mesenteric border of the Jejunum, found more commonly in older males. Major complications include diverticulitis, gastrointestinal bleeding (GIB), intestinal obstruction, and perforation.

Hemorrhage from JD usually occurs as lower GIB, although hematemesis has been described. Hemorrhage may be massive and acute, requiring emergent surgical intervention. Like that of colonic diverticula, Jejunal diverticular hemorrhage results from diverticular erosion through a perforating artery. Diagnosis can be made by computerized tomography (CT) angiography, small bowel contrast study, mesenteric angiogram and technetium-99m red blood cell scan. Bleeding Jejunal Diverticula challenge the physician to rapidly diagnose etiology and location in the hemorrhaging and potentially unstable patient. Treatment of lower GIB secondary to jejunal diverticulosis includes segmental intestinal resection with primary anastomosis.

Results: The patient is a 62 year-old male who presented with abdominal pain, diarrhea, and hematochezia. He underwent an EGD and colonoscopy that showed diverticulosis, but no evidence of bleeding. A tagged RBC scan was also done and was negative. He subsequently had several episodes of bright red blood per rectum and repeat colonoscopy was inconclusive due to blood in the colon.

After an episode of acute bleeding, mesenteric angiogram was performed and no source was identified. Colonoscopy was repeated, with bleeding sigmoid colon diverticuli observed. He was taken to the OR emergently for left hemicolectomy.

Seven days later, he began having bright red blood from the end colostomy. Repeat mesenteric angiography revealed extravasation of contrast in the proximal jejunum. Microcatheter remained in the Jejunal arcade for intraoperative localization.

continued on next page

Intraoperatively, several large Jejunal diverticula containing blood clots were identified in the mesenteric fat. Intraoperative injection of methylene blue localized the bleeding to this area. Segmental small bowel resection with primary anastomosis was performed. Postoperatively, he progressively recovered and was discharged home.

Conclusions: Jejunal diverticulosis is a rare condition that may present with massive gastrointestinal bleeding. JD may demonstrate high mortality rate due to delayed diagnosis and complications. Jejunal diverticulosis should be included in the differential diagnosis of an older patient with massive GIB.

Claudication- Neurogenic or Vascular

Gerald Greenfield, Jr, MD, MS, FICS

Clinical Assistant Professor of Orthopaedic Surgery

University of Texas Health Sciences Center- San Antonio, San Antonio TX

Purpose: The purpose of the report is to define the difference between claudication based on a neurological versus a vascular factors.

Methods: Historical perspective for claudication and its definition will be reviewed along with the anatomical bases for the diagnoses. Testing option for differentiation between the two disorders.

Results: Results will define the difference in the two clinical situations and treatment for neurogenic claudication (ESI), distraction, decompression.

Conclusions: Attendees will have a concrete understanding of the basis for both neurogenic and vascular claudication. Several noninvasive methods to differentiate the two.

Endoscopic Transphenoidal Surgery: A Transition to Neurosurgery-ENT Collaboration Producing Better Outcomes

Bharat Guthikonda, MD, FICS

Associate Professor, Director of Skull Base Research, Department of Neurosurgery, LSU HSC Shreveport, Shreveport LA

Purpose: Endoscopic transphenoidal surgery has become a mainstay in the treatment of pituitary adenomas, craniopharyngiomas, CSF leaks, and other anterior and middle skull base pathologies. Many centers employ a collaborative management team consisting of a skull base neurosurgeon working together with an ENT surgeon with expertise in advanced endoscopy. Other centers may utilize a single service strategy for management of these lesions. After performing a single service management of these lesions for the past few years, we have recently converted to a collaborative team approach for skull base endoscopy. We have appreciated significant improvements in our outcomes, especially as they relate to the rate of conversion to open (microscopic) approach and extent of resection of tumors.

Methods: A review of a prospectively maintained database was performed. We included all endoscopic transphenoidal procedures performed from August 2007 until the present time. We evaluated all endoscopic transphenoidal procedures that were performed by the neurosurgical service alone and separately evaluated those performed by a collaborative neurosurgery / ENT team. Our primary endpoint was the rate of conversion to an open microscopic procedure. Secondary endpoints were extent of resection of the neoplastic lesions, CSF leak recurrences (in the cases performed for CSF rhinorrhea), and intraoperative blood loss. Complications were also assessed and compared between the two subsets of cases.

Results: A total of 75 endoscopic transphenoidal cases were evaluated. 50 were performed by neurosurgery alone and 25 were performed by the combined neurosurgery / ENT team. There was a conversion to open microscopic approach rate of 18% in the cases done by neurosurgery alone and 0% in the combined neurosurgery / ENT cases. There was one failed CSF leak repair requiring a subsequent transcranial repair in both subsets. Extent of resection of pituitary macroadenomas was better and overall blood loss was lower in the cases performed by the combined neurosurgery / ENT team.

Conclusions: Our experience has supported the concept of achieving better outcomes in endoscopic transphenoidal surgery by using a combined neurosurgery / ENT team. We have noted a lower rate of conversion to open microscopic surgery, less blood loss, and improved extent of tumor resection.

Update on Light Adjustable Lenses

Phillips Labor, MD, FICS
Grapevine, TX

For almost 20 years Intraocular lenses have been made available to cataract surgeons as a way to simultaneously correct surgically-induced aphakia and presbyopia. These lenses have been constructed so that they function primarily through accommodative or multifocal modalities. This presentation will show how this same corrective and functional endpoint may be achieved through the use of uniquely designed monofocal lens.

Successful Incorporation of Midlevel Providers in an Academic Surgical Division

Joshua Mammen, MD PhD MBA, FICS

Associate Professor of Surgery and Molecular & Integrative Physiology, University of Kansas, Kansas City, KS

Midlevel Providers serve important roles in the delivery of healthcare in many primary care settings and emergency departments. Surgeons, particularly those who practice in academic settings, have had challenges in identifying opportunities to work most efficiently and with greatest efficacy with midlevel providers. The purpose of this presentation is to describe the effective incorporation of midlevel providers within an academic surgical division. The surgical oncology division at the University of Kansas is composed of five attending physicians and three surgical residents. In addition, two midlevel providers are members of this division for the previous one year. The midlevel providers function as liaisons with patients (returning complex phone calls, communicating results), examine post-operative patients elective and emergently, and initiate evaluations of patients with complex cancer diagnoses. In addition to responsibilities in the outpatient setting one of the midlevel providers also assists in the operating room. Residents on the service value the role of the midlevel provider and appreciate their role on the team. The training of the midlevel providers (both of whom had no surgical experience but extensive primary care experience) had several elements. Both midlevel providers spent extensive time evaluating patients in the clinics of their collaborating attending physician in order to learn the critical elements of the evaluation and treatment of pre-surgical and post-surgical patients. Additionally, they would be present in the operating room often. Finally, they were included in the all patient decisions via email to ensure that they were aware of the thought process involved in decisions. The successful incorporation of midlevel providers can serve as a model for other academic or non-academic divisions.

The Latest Clinical Surgical Total Hip Replacement Advancements in Painful Osteoarthritis of the Hip

Robert Mathews, MD, PhD, FICS

Director of First Team Institute LLC, Millersville, PA

Purpose: In the severely painful osteoarthritic hip joint, the synovium appeared to react to the rigors of joint motion on ambulation. The femoral head debris lost via repetitive microfracture on motion tended to self-perpetuate the inflammatory process and attack mast cells and histiocytes. The inability of the scavenger cells to cope with this degenerative process brought cellular lysosomal enzymic release and cell death in bone which served to self-perpetuate the painful inflammatory process

Methods: We have identified afferent peripheral fibers in the hip joint, tendons, synovium, capsule, periosteum bone, and the scarified tissue near articular cartilage as well as nerves in the bone cortex and cancellous red marrow of human joints.

These nerves supply the capsule, the periosteum and the soft tissue of the hip joint. Nerves appear throughout the bone. The intramedullary, endosteal unmyelinated and myelinated fibers enter the bone through the nutrient foramen with the nutrient artery and travel toward the epiphysis and follow along the trabeculae. The myelinated and unmyelinated fibers of bone were found near the vascular elements. On occasion, a few fibers extended to the endosteal wall of the femoral cortex (Plate I).

Results: The anatomic data in our total hip replacement patients was correlated with the clinically evaluated pain before and after surgery. Each patient seen post-operatively had significant relief of pain. In all, we achieved 95 percent hip pain relief in these patients.

Furthermore, other progress by all of us included: Polyethylene improved, Collarless femoral prosthetics which decrease stress risers, Cement technique, Titanium porous, Length control, Ceramics and Antibiotics in cement

Conclusions: In all, we achieved 95 percent hip pain relief in these patients

Rib Plating Of Traumatic Rib Fractures: Patient Selection, Operative Planning and Technique

Milad Mohammadi, MD

Resident, Texas Tech University Health Sciences Center, Lubbock, TX

Purpose: Herein we present cases of rib fixation for trauma patients with disrupted respiratory mechanics secondary to clinical flail chest. We also describe operative technique with a titanium plate and screw system. This is the first report in the Western literature that describes plating of the 2nd rib.

Methods: This retrospective case review includes operative management conducted at a University Level I Trauma Center for patients who suffered traumatic rib fractures. Operative candidates had radiographic or clinical flail chest, fractures with displaced ribs, chest wall deformity, severe pain, and inability to liberate from mechanical ventilation due to altered mechanics of respiration.

Results: In 2009, over 300,000 patients with rib fractures were seen in U.S. emergency departments. Significant morbidity associated with traumatic rib fractures includes respiratory failure, pneumonia and prolonged hospitalization. Studies have shown improved clinical outcomes following operative stabilization of flail segments.

Open reduction internal fixation of ribs is most beneficial in patients who have clinical flail chest (paradoxical chest motion with respiration), persistent instability of the chest wall with inability to liberate from the ventilator, and non-intubated patients with deteriorating pulmonary function in the setting of flail chest.

Rib fixation is predominantly described in specialty trauma centers and practiced by a minority of trauma, cardiothoracic or orthopedic surgeons. Publications describing operative techniques are rare, and there are no known publications in the Western literature which describe 2nd rib fixation. The cases herein demonstrate successful titanium plate and screw stabilization of disrupted chest wall mechanics secondary to clinical flail chest, including plating of the second rib. Our preferred technique of stabilization using titanium plating and screws is also detailed.

Two patients had 6 and 7 fixation levels respectively. They had successful plating of their 2nd ribs, and both liberated from the ventilator within 24hrs postoperatively. The patients were discharged within 4 days of surgery.

Conclusions: Despite numerous studies detailing improved outcomes in rib fracture patients with surgical stabilization, this operation has not yet become the standard of care. Prospective trials are sorely needed to define which patients will benefit from the procedure, and also to describe the benefits and reduction in morbidities.

Early Decompressive Craniectomy in Traumatic Brain Injuries: A Case Series from the Kingdom of Cambodia

Paul Park, MD, PhD

Global Outreach Fellow, Korean American Medical Association, Preah Kossamak Hospital, Phnom Penh
Kingdom of Cambodia, Reno, NV

Purpose: Decompressive craniectomy (DC) is a controversial treatment option for malignant cerebral edema associated with traumatic brain injury (TBI). A recent multi-center study in the U.S. showed that early DC did not significantly improve mortality rates when compared to medical therapy in patients with TBI related refractory intracranial hypertension. In developing countries, however, where intensive care unit (ICU) support may be minimal and intracranial monitoring technology may be nonexistent, early DC may be preferable to maximize chances for survival.

Methods: A customized database was created for collection of patient information at a government hospital in Phnom Penh, Cambodia. A retrospective analysis was performed on patients who underwent DC for TBI during a 5-month period. The indications, midline shift, outcomes, and complications were analyzed for a series of 12 patients.

Results: All DC patients were male with an average age of 26 years (SD=7; range 19-43 years). Indications for DC included acute subdural hematoma (n=9), epidural hematoma (n=3), brain contusion (n=5), and subarachnoid hemorrhage (n=1). Average GCS prior to DC was 9 (SD=3, range=5-15). The average midline shift (MLS) was 9.4 mm (SD=2.8; range=8.0-16.5 mm), and MLS of 16.5 mm resulted in death even with DC. The mortality rate was 8% (n=1). Five patients (42%) made a good recovery without any significant disability [Glasgow outcome scale (GOS) score of 5]. Average hospital stay was 15 days (SD=7; range 10-32 days). Complications were primarily post-operative and included bone flap infection at site of abdominal storage (n=2) and hygroma (n=2).

Conclusions: Early DC may be preferable over medical therapy when ICU support and intracranial monitoring capabilities may be minimal or nonexistent. Early DC may not increase survival in TBI patients with MLS > 16 mm. DC in developing medical settings, such as the Kingdom of Cambodia, can be performed safely and effectively with minimal risk and favorable outcomes.

Vaginal Surgery under Local Anesthesia: An Emerging Paradigm

Marco Pelosi III, MD, FICS

Director, Pelosi Medical Center, Bayonne, NJ

Purpose: The feasibility of effectively and efficiently performing a variety of commonly performed gynecologic procedures under strict local anesthesia is demonstrated.

Methods: A fifteen-year review of gynecologic procedures done under strict local anesthesia at the Pelosi Medical Center was performed spanning the interval from January 1, 1998, through January 1, 2013. Patient selection criteria, procedure selection criteria, anesthetic protocols, surgical protocols, perioperative protocols, patient report visual pain scores and treatment outcomes were evaluated.

Results: A total of 2,761 gynecologic procedures initiated under strict local anesthesia were identified. All procedures were successfully completed. There were no anesthetic complications. Sixty six patients (2.4%) required supplemental sedation. There were no intraoperative complications. Postoperative complications were limited to 21 urinary tract infections (0.076%).

Conclusions: Gynecologic procedures can be performed effectively under strict local anesthesia with an infrequent need for supplemental sedation with proper patient and procedure selection and adequate protocols.

Long-Term Effectiveness of a Non-surgical Treatment for Carpal Tunnel Syndrome

Michael Politis, PhD

Carpal Pain Solutions, Inc., Palm City, FL

Purpose: Abundant data indicate that most patients who undergo carpal tunnel release surgery could have effectively managed their carpal tunnel syndrome non-surgically. However, long-term efficacy data on alternative nonsurgical therapies are sparse and difficult to ascertain. One alternative therapy is soft tissue manipulation as performed by an automated device called Carpal Rx, which has been in use for several years. Patients report highly effective results but long-term data have not been published.

This study obtained long-term patient satisfaction results to help determine if this device is an effective means for lasting, nonsurgical treatment of carpal tunnel syndrome.

Methods: A total of 66 patients who used the Carpal Rx more than 24 months were contacted by telephone. A 17 question survey was used to assess patient satisfaction based primarily on the Michigan Hand Outcomes Questionnaire (MHQ) for symptoms relief and a standardized Product Satisfaction Questionnaire (PSQ) for overall product/patient satisfaction. Other information obtained included symptoms severity, co-morbidities, age, gender, Carpal Rx use history/schedule, and whether surgery was/is considered/scheduled/performed. Both questionnaires required a response based on a subjective opinion scale of 0-10 (representing least to most symptoms resolution or product satisfaction). Rank-sum nonparametric analyses were used to analyze results.

Results: Of the patients contacted, 52 completed the telephonic survey; 11 declined participation for reasons not related to the product; 3 declined for reasons related to the product. No other information was gathered from non-participants. The mean time from initial use of the Carpal Rx was 27.4 months. In 88% and 12% of patients, overall MHQ results indicated at least a 91.4% and 85.9% symptoms resolution, respectively; and 62% and 88%, respectively, reported needing to use the product on a periodic basis within the past 12 months to maintain or restore symptomatic relief. Mean product satisfaction was 92.2% in overall categories surveyed. In general, both MHQ and PSQ results coincided with respect to symptoms resolution and product satisfaction. There was a slight inverse correlation between symptoms severity and patient satisfaction.

Conclusions: The current research supports prior published short-term data on the use of the Carpal Rx for relieving carpal tunnel syndrome. The high level of symptomatic relief and patient satisfaction suggest that this device is an effective alternative to carpal tunnel release surgery. These data support the use of the Carpal Rx for effective long-term management of carpal tunnel syndrome.

Surgical Treatment of Humerus Fractures

Sudhir Rao, MD

Big Rapids Orthopaedic PC, Premier Hand Center, Big Rapids, Michigan

Fractures of the Humerus can be challenging to treat in any age group. In the pediatric age group fractures usually involve the epiphysis or metaphysis and often require surgery. One must be aware of vascular injury and growth

continued on next page

impairment. In the adult the fracture pattern and treatment methods vary based on the age of the patient, type of fracture and other parameters. There is a wide spectrum of surgical options ranging from percutaneous pinning, internal fixation to arthroplasty. This paper will discuss various clinical situations and treatment options

Preclinical Studies of Allogeneic Head and Body Reconstruction

Xiaoping Ren, MD

Professor of Surgery Hand and Microsurgical Center, The Second Affiliated Hospital, Harbin Medical University, Harbin, China

Purpose: Previously, our work has led to the design and completion of the world's first successful composite tissue allotransplantation (CTA), in preclinical swine models, and initiation of the US first clinical hand allograft procedure and according to the hand and face conversion, achieved a successful clinical representative of the CTA. Joint immunosuppressive regimen and immune rejection taxonomy and other important scientific indicators adopted from these studies have been clinically validated for more than 10 years, and now are internationally adopted. However, there is still no effective way in which to saving the lives of patients with a healthy mind dying of other organ failure in the body. The only surgical treatment strategies, CTA next frontier, allogeneic head and body reconstruction (AHBR) has been subject unable to complete necessary preclinical experiments did not establish an effective biological animal model and thus hinder the clinical translational of the AHBR.

Methods: Our approach, pioneered in mice, involves retaining the donor brainstem and transplanting the head with the remainder of the brain. This allows for retention of breathing and circulatory functions, and this is supported by preliminary data in mice. This is the first successful use of this model to date. To build the AHBR research platform, we plan to further develop AHBR model in mice and establish the model in monkeys in order to evaluate outcomes relevant to translation, including long-term survival and mental function.

Results: Forty Kunming mice and forty C57 wild type underwent the AHBR procedure. After transplantation, 18 mice survived for 3 hours after the ventilator was disconnected. As anticipated, they were capable of breathing spontaneously, because the donor brainstem remained intact. The rate of respiration was 140 ± 15 /minute. During these 3 hours, the mice awakened and displayed cranial nerve function and characteristic responsiveness (blinking, whiskers moving, etc.). After the mice awoke, electroencephalogram (EEG) recordings were made directly from the cortex of the transplanted cephalons. Because blood supply was maintained at an adequate level during surgery by anastomosing the donor and recipient carotid and jugular vessels, the intra- and post-operative EEG and ECG show electrophysiological activity. The systolic blood pressure was maintained above 50 mm/Hg. Although ECG and EEG monitoring shows an unstable curve postoperatively, there was neither significant tachycardia nor bradycardia, and no lethal arrhythmia. The heart rate was 300 ± 20 /minute. Interestingly, the mice did not show postoperative decerebrate rigidity.

Conclusions: This study has developed critical surgical procedures, which allow for the cross-circulation to avoid brain ischemia, retention of donor brainstem, preliminary data for PEG study to promoting CNS function recovery and developing optimization of immune-suppressive treatments to reach AHBR long-term survival. Successful clinical translation of AHBR will become another milestone of human medical history and potentially could save millions of people.

Liver Transplantation for Malignant Neoplasms

Reza F. Saidi, MD, FICS

Assistant Professor of Surgery, Division of Organ Transplantation, Department of Surgery
Alpert Medical School of Brown University, Providence, RI

Purpose: To review the correct data on liver transplantation for hepatic tumors.

Methods: Literature Search/Review

Results: Liver transplantation for malignancies has emerged as proven treatment modality for selected group patients. Currently, around 30% of all liver transplants performed in US are for hepatocellular cancer (HCC). Hepatoblastoma is an excellent indication in pediatric patients with unresectable tumors. Similarly, liver transplantation for HCC in the adult population yields good results for patients whose tumor do not exceed the Milan criteria. It remains to be determined whether patients with more extensive tumors can be reliably selected to benefit from the procedure. Adjunctive procedures like radiofrequency ablation, chemoembolization, or cryotherapy might be indicated to limit tumor progression for patients on waiting lists. Epithelioid hemangioendothelioma is also an appropriate indication for liver transplantation. Metastatic liver disease is not an indication for liver transplantation, with the exception of cases in which the primary is a neuroendocrine tumor, for which liver transplantation can result in long-term survival and even cure in a number of patients. Cholangiocarcinoma might qualify if aggressive neoadjuvant therapies, including chemotherapy and radiotherapy followed by liver transplantation, are carried through. Survival in these selected patients can approach that for other patients with end-stage liver disease.

Conclusions: Liver transplantation is an valuable option in selected patients with liver tumors.

Innovative Management for Traumatic Brain Injury: Compartments Communicate

Thomas Scalea, MD

Professor of Surgery, University of Maryland School of Medicine, Baltimore MD

Purpose: Traditional treatment for intracranial hypertension is all directed at treating the brain. Therapies such as elevating the head of the bed, hyperosmolar therapy and even mild hyperventilation, reduce ICP by directly affecting the brain. Recently, we have described a novel alternative treatment strategy.

Methods: Through a series of case reports and then two full length manuscripts, we have described the use of abdominal wall decompression to treat intracranial hypertension. This therapy was successful, even with modestly elevated intraabdominal pressures. The principles of compartment syndrome are well understood. Pressure rises in a compartment, limiting venous return. Pressure continues to rise until the pressure within the compartment exceeds perfusion pressure, resulting in ischemia.

Results: The cranium, thorax, mediastinum and abdomen sit immediately adjacent to one another. Pressures in the chest or abdomen can be transmitted to the cranium likely via the large veins. In patients without brain injury, this is likely unimportant, but rises in intracranial pressure in patients with brain injury can be very deleterious. We have demonstrated that abdominal wall decompression is an effective way to decrease intracranial pressure. Moreover, patients can develop a constellation of physiologic abnormalities that we have termed Multiple Compartment Syndrome, where pressures in one compartment affect another and then feed back to increase pressure in the original compartment. This downward spiral can be reversed by decompressing either the abdomen or chest.

Conclusions: Decompression in compartments remote from the head can be effective in reducing intracranial hypertension. This represents the first therapy for brain injury not directed at the brain itself. Targeted resuscitation strategies may be very helpful in limiting intracranial hypertension and guiding the need for decompression.

Commodifying Human Traits: the Neuroethical Aspect

Patricia Scripko, MD

Neurologist, Salinas Valley Memorial Hospital, Salinas CA

We are in an age of rapidly advancing neuroscience and technology. With these advances, come ethical questions. This presentation addresses those controversies specific to manipulating or altering the brain for the purpose of medical restoration or enhancement. It explores the argument: that which defines what is human life lies in the brain. Conclusions are drawn using comparisons between how we define human life at different stages based on arguments made in realms concerning abortion, stem cell research, brain death, and human enhancement (cosmetic, physiological, and cognitive). The potential dangers current and theoretical technologies concerning the brain are posed, and a general set of guidelines for the role and responsibilities of physicians practicing in an era of these advancing technologies is suggested.

Constrained Fixed-Fulcrum Reverse Shoulder Arthroplasty For The Treatment Of Epilepsy-Related Recurrent Shoulder Instability

Tanujan Thangarajah, MB ChB (hons), MRCS, MSc

Research Fellow, The John Scales Centre for Biomedical Engineering, Institute of Orthopaedics and Musculoskeletal Science, Division of Surgery and Interventional Science, University College London, The Royal National Orthopaedic Hospital, Stanmore, London UK

Purpose: Epileptic seizures can cause shoulder dislocation and instability. The incidence of dislocation during a seizure is approximately 0.6% but this is probably an underestimation since go undetected. The majority of non-arthroplasty surgical strategies focus on restoration and/or augmentation of the bony glenohumeral joint while also addressing arthritis, which can be a long-term complication. Despite technically satisfactory reconstruction procedures some patients still experience persistent instability and increasing arthritis symptoms.

The Bayley-Walker shoulder (Stanmore Implants Worldwide Ltd, UK) is a constrained fixed-fulcrum reverse anatomy (FF-RSA) prosthesis that was specifically conceived for the treatment of patients with difficult shoulder reconstruction problems. The center of rotation is placed medially and distally to the axis of the normal shoulder, which increases the lever arm of the deltoid, but to a lesser degree than most existing non-linked reversed anatomy prostheses. These features make it a potential treatment option for patients with epilepsy-related recurrent shoulder instability and sufficient glenoid bone stock for secure primary fixation of the glenoid component. There are no reports of this management strategy in the current published literature.

The aim of this study was to report the functional outcome following FF-RSA for epilepsy-related recurrent shoulder instability and establish its role in the management of this challenging condition.

continued on next page

Methods: Between November 1996 and June 2013 five shoulders in five patients underwent FF-RSA for epilepsy-related recurrent shoulder instability. The index dislocation occurred a mean of 13 years (range, 2-38) before surgery. The cohort consisted of four males and one female. Four patients had anterior instability and one had multidirectional instability. FF-RSA was performed after an average of two previous stabilisation procedures (range, 0-5).

Preoperative and postoperative radiographic imaging was performed in all cases. Scapular notching was classified by the size of the defect on the anteroposterior radiograph using the four-part grading system devised by Sirveaux et al. Preoperative and postoperative clinical outcome measures included active forward elevation, active external rotation, the Oxford Shoulder Score (OSS) and the Oxford Shoulder Instability score (OSIS).

Results: The mean follow-up was 3.6 years (range, 2.4 - 6.4 years). There were no further episodes of instability or persistence of apprehension, and no further stabilisation procedures and no revision procedures were performed or anticipated. No cases of scapular notching or loosening of either the humeral or glenoid component were noted. Mean active forward elevation improved from 710 preoperatively (range, 45-1300) to 850 postoperatively (range, 80-900). Mean active external rotation improved from 150 preoperatively (range, 0-800) to 400 (20-700) postoperatively. The mean OSIS improved from 7 preoperatively (range, 1-15) to 27 postoperatively (range, 16-37). The mean OSS improved from 7 preoperatively (range, 4-13) to 26 postoperatively (range, 15-34). An increase was noted in the mean SSV, which improved from 17 (range, 0-50) preoperatively to 54 (range, 30-70) postoperatively.

Conclusions: In our series, FF-RSA eliminated recurrent instability and improved overall functional outcome. An improvement in pain and range of movement (external rotation) was also noted. The procedure should therefore be considered in this highly selected patient population as an alternative to arthrodesis or non-surgical treatment.

Shoulder Arthroplasty In Epileptic Patients Tanujan Thangarajah, MB ChB (hons), MRCS, MSc

The John Scales Centre for Biomedical Engineering, Institute of Orthopaedics and Musculoskeletal Science, Division of Surgery and Interventional Science, University College London, The Royal National Orthopaedic Hospital, Stanmore, London Middlesex, UK

Purpose: Epileptic seizures can cause dislocation of the shoulder joint and recurrent instability. Significant bone loss from the glenoid and humeral head is thought to be responsible for the high recurrence rate and is recognized as being pathognomonic of the condition. Owing to a poor bone stock further reconstruction is challenging. Arthroplasty may therefore represent a suitable treatment option but there have been no reports of this in the published literature. We report our 17-year experience with shoulder arthroplasty in patients with epilepsy-related recurrent shoulder instability to assess the results and rate of revision.

Methods: Between November 1996 and July 2013 179 patients with epilepsy underwent shoulder surgery. Of these, eight shoulders in eight patients underwent arthroplasty for recurrent instability. These included three total shoulder replacements (TSR) and five humeral resurfacing hemiarthroplasty procedures. All patients suffered from grand mal seizures. The cohort consisted of seven males and one female. Six patients had anterior instability and two had posterior instability. Arthroplasty was performed after an average of two previous stabilisation procedures (range, 0-3).

All radiographs were reviewed for the presence of glenohumeral subluxation, periprosthetic lucency and alteration in the position of the components. Radiographs for patients who underwent hemiarthroplasty were also examined for glenoid erosion. Clinical outcome measurements included active forward elevation, active external rotation, active abduction and pain. Pain was graded as 4 which indicated no pain; 3, mild pain; 2, moderate pain; 1, severe pain; and 0, unbearable pain. In addition, all patients were assessed using the subjective shoulder value (SSV).

Results: Mean age of the cohort was 33 years (range, 17-44) and follow-up was for a mean of 3.2 years (range, 1.5 - 5.8 years). Following surgery six patients continued to have grand mal seizures but did not have any further episodes of instability/dislocation. No further stabilisation procedures were performed in the cohort. Six patients were found to have developed degenerative changes at the time of surgery.

Two patients with hemiarthroplasty required further surgery due to painful glenoid erosion. In one, revision to a total shoulder replacement was undertaken and in the other, an isolated glenoid replacement was performed. No revisions were undertaken in the TSR group.

There was a mean increase in pain score of 1.1 points, from a mean of 0.8 (range, 0-1) preoperatively to a mean of 1.9 (range, 0-3) postoperatively. This was accompanied by an increase in the mean SSV, which improved from 33 (range, 10-80) preoperatively to 52 (range, 15-90) postoperatively. Mean active forward elevation improved from 1110 preoperatively (range, 70-1500) to 1160 postoperatively (range, 70-1700). A similar gain was also noted in mean active external rotation, which improved from 310 preoperatively (range, 10-600) to 390 (20-700) postoperatively.

continued on next page

Conclusions: In our series, hemiarthroplasty was associated with a high rate of revision even with a short-term follow-up. However, shoulder arthroplasty did eliminate recurrent instability, reduce pain and improve range of movement. This was accompanied by an increase in the mean SSV. The procedure should therefore be considered in this selected patient population.

Clinical Depression and ACL Reconstruction: Incidence and Impact on Functional Outcome, a Prospective Cohort Study

Hao-Hua Wu, BA

Third Year Medical Student, Perelman School of Medicine at the University of Pennsylvania, Philadelphia, PA

Purpose: Although recent literature has suggested that depression is a potential risk factor for poor functional outcome following orthopaedic procedures, the recognized impact of depression on the outcome of anterior cruciate ligament reconstruction (ACLR) is still controversial. The purpose of this investigation was to quantify the incidence of major depressive disorder (MDD) and correlate depression symptoms with patient-rated knee function in patients undergoing ACL reconstruction (ACLR).

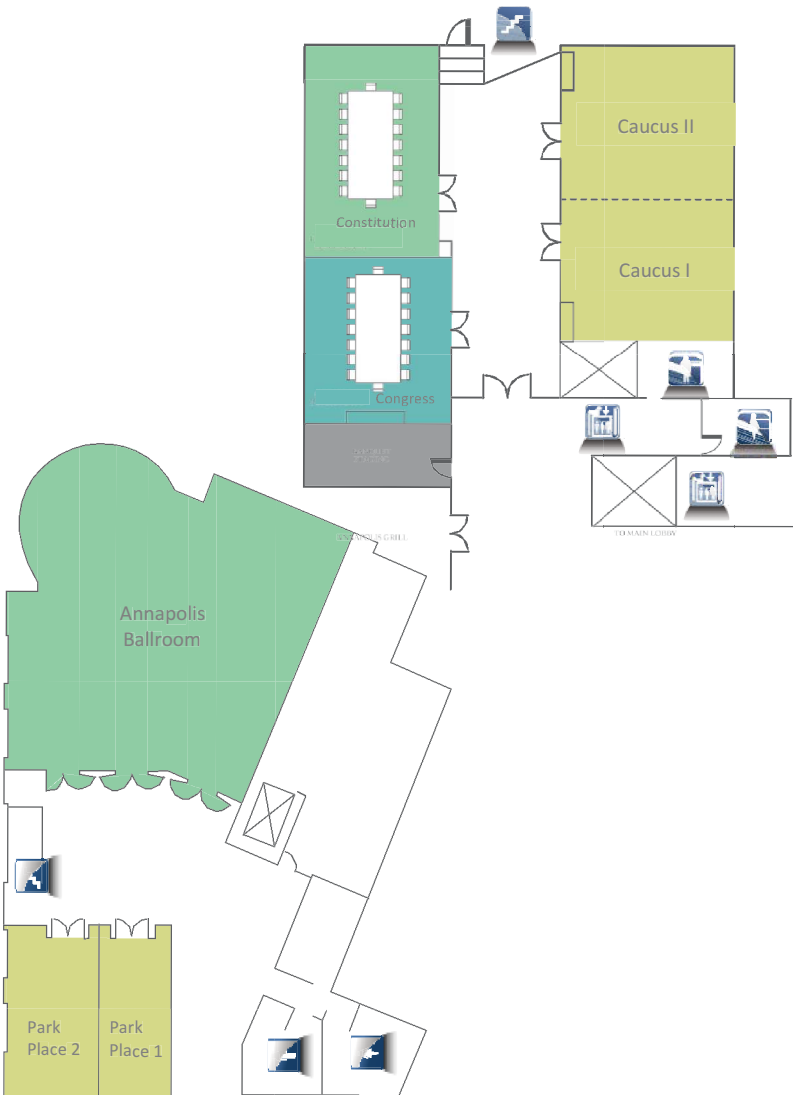
Methods: In this IRB approved, multi-center prospective cohort study, 82 consecutive adult patients undergoing primary ACLR were given a Quick Inventory of Depressive Symptomatology Self-Report (QIDS-SR16) preoperatively and at 6 weeks, 12 weeks, 24 weeks, and one year postoperatively to assess MDD symptoms. International Knee Documentation Committee (IKDC) Subjective Form and Lysholm scores were also obtained at similar time points. Patients with concomitant ligamentous injuries or revision surgery were excluded. A QIDS score of 6 or greater served as a validated threshold for diagnosis of MDD. MDD and non-MDD groups were assigned based on preoperative QIDS scores.

Results: Among the 82 patients enrolled in the study, 37 (44%) scored 6 or greater on the QIDS preoperatively and were categorized in the MDD group. There were no significant differences found between the two groups with respect to demographics, BMI, smoking history, concomitant knee pathology and postoperative complications. The average QIDS score of the MDD group was significantly higher than that of the non-MDD group at all five time points ($p < 0.05$). In addition, MDD patients scored 14.1 points lower on their Lysholm at baseline (50.8 vs. 64.9; $p < 0.001$) and 13.2 points lower on their Lysholm at one year (75.2 vs. 88.4; $p = 0.04$), as well as 13.3 points lower on their IKDC at baseline (43.7 vs. 57.0; $p < 0.001$) and 17.5 points lower on their IKDC at one year (71.8 vs. 89.3; $p = 0.001$) in comparison to the non-MDD group. A moderate inverse correlation between QIDS and Lysholm ($r = -0.51$) and between QIDS and IKDC ($r = -.053$) were also found at each time point.

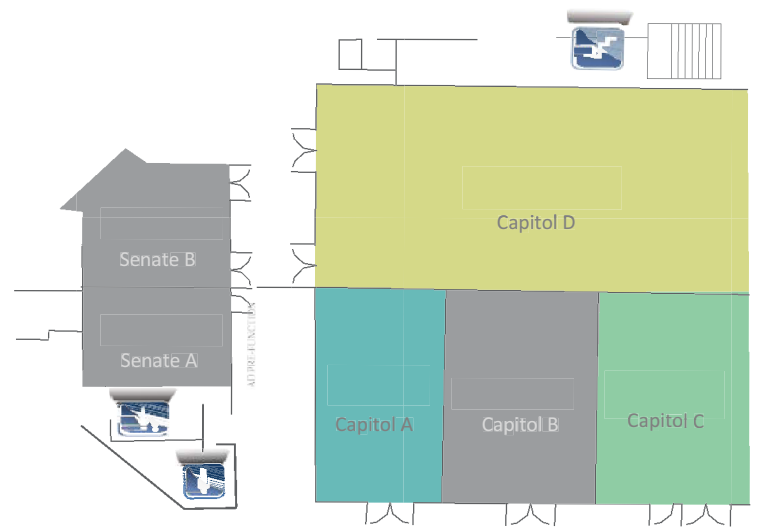
Conclusions: This study suggests the incidence of self-reported MDD among patients undergoing ACLR may be as high as 44% preoperatively, and that these patients have significantly worse clinical self-reported one year postoperatively. Continued poor perception of knee function postoperatively for MDD patients may manifest in greater limitation in daily activity, lengthen time needed to return to competition and adversely impact sport performance. Thus, further studies are warranted to determine whether this subset of MDD patients can benefit from multidisciplinary preoperative intervention and postoperative management to improve ACLR outcomes.

A		N	
Alvear, Domingo T.	10	Narayan, Mayur.....	10
Annamalai, Alagappan.....	12,18		
B		O	
Bereneau, Anca	13	Oliphant, Uretz.....	11
Bolles, Gene E.....	10,13		
Bongiorno, Frank.....	14	P	
C		Park, Adrian.....	10
Cameron, John.....	11	Park, Paul.....	12,23
Cameron, Andrew.....	11	Patton, Chad.....	9,10
Canavero, Sergio.....	8,11	Pawlik, Timothy.....	12,14
Clark, W. Craig	10,13,18	Pelosi III, Marco A.....	14,24
Coles, Maxime J.M.	12,13	Politis, Michael	13,24
Cook, Jonathan.....	14,19		
D		R	
Dieter, Jr., Raymond A.....	14,19	Rao, Sudhir B.	12,24
Dix, Gary.....	8,10,20	Ren, Xiaoping	8,13,25
E			
Efron, David.....	10	S	
F		Saidi, Reza F.....	11,12,25
Flores, Jesse.....	14,20	Scalea, Thomas M.	10,26
G		Scripko, Patricia	9,12,26
Greenfield, Jr., Gerald O.	13,21		
Guthikonda, Bharat.....	12,13,21	T	
J		Thangarajah, Tanujan.....	12,26,27
Jacobs, Michael J.....	11	V	
L		Vithiananthan, Sivamainthan	14
Labor, Phillips Kirk	14,15,22	W	
M		Weiss, Matthew	11
Makary, Martin.....	12	Wolfgang, Christopher.....	12
Mammen, Joshua M.V.	14,15,22	Wu, Hao-Hua.....	13,28
Mathews, Robert S.	13,22	X	
Mathews, William	11,12	Xeller, Charles.....	10
Mohammadi, Milad.....	14,22	Z	
Mukherjee, Debraj	9,13	Zamorano, Lucia.....	13

Floor Plan
Main Level



Westin Annapolis
Lobby



**WEDNESDAY
JUNE 10**

**REGISTRATION
7:30-4:00 PM
Prefunction**

**OFFICER BREAKFAST
7:30-9:00 AM
Prefunction**

**ENDOWMENT FUND,
BOARD OF TRUSTEES
MEETING
8:30-9:00 AM
Capital A&B**

**US SECTION STANDING
COMMITTEE MEETINGS
(AMA, BYLAWS,
BOARD OF TRUSTEES,
ETHICS, PAST PRESI-
DENTS, HONORS &
SCHOLARSHIP)
9:00-10:30 AM
Capital A&B**

**CME COMMITTEE AND
COUNCIL OF SPECIALTY
GROUP CHAIRS
10:30 AM-Noon
Capital A&B**

**OFFICER LUNCHEON
Noon-1:00 PM
Caucus I&II**

**BOARD OF REGENTS
MEETING
1:00-2:00 PM
Senate A&B**

**EXECUTIVE COUNCIL &
HOUSE OF DELEGATES
JOINT MEETING
2:00-4:00 PM
Senate A&B**

**THURSDAY
JUNE 11**

**REGISTRATION
7:00-4:00 PM
Prefunction**

**BREAKFAST
7:30-9:00 AM
CAPITAL D**

**RESEARCH SCHOLAR-
SHIP COMPETITION
8:00-9:45 AM
CAPITAL A&B**

**OPENING CEREMONY
10:00-10:15 AM
CAPITAL A&B**

**SURGICAL RESIDENT
EDUCATION DEBATE &
PANEL DISCUSSION
10:15 AM-NOON
CAPITAL A&B**

**EXPLORE ANNAPOLIS
10:20-11:20 AM
SENATE A&B**

**ALLIANCE BOARD OF
DIRECTORS & MEM-
BERSHIP MEETING
11:20-NOON
SENATE A&B**

**HONORS LUNCHEON
NOON-1:30 PM
CAPITAL D**

**GLOBAL SURGERY
SUMMIT
1:30-3:45 PM
CAPITAL A&B**

**CARDIOTHORACIC &
VASCULAR SURGERY
4:00-6:00 PM
CAPITAL A&B**

**OPENING RECEPTION
6:00-7:00 PM
SENATE A&B**

**FRIDAY
JUNE 12**

**REGISTRATION
7:00-4:00 PM
Prefunction**

**BREAKFAST
7:30-9:00 AM
CAPITAL D**

**TRAUMA AND ACUTE
CARE SURGERY PART I
8:00-9:45 AM
CAPITAL A&B**

**NAVAL ACADEMY
TOUR
8:45 AM-NOON
GATHER AT
REGISTRATION**

**NEUROLOGICAL AND
ORTHOPAEDIC
SURGERY - PART 1
9:00-11:00 AM
SENATE A&B**

**TRAUMA & ACUTE
CARE SURGERY PART II
10:00 AM-NOON
CAPITAL A&B**

**LUNCH &
PRESENTATION OF
THE DR. ANDRE
CROTTI AWARD
NOON-1:30 PM
CAPITAL D**

**KEYNOTE LECTURE
SPONSORED BY
AANOS
1:30- 3:00 PM
CAPITAL A&B**

**THE LATEST UPDATES
IN HEPATO-PANCRE-
ATO-BILIARY (HPB)
SURGERY
3:15-5:45 PM
SENATE A&B**

**AANOS BOARD
MEETING
4:00-5:30 PM
Caucus I&II**

**SATURDAY
JUNE 13**

**REGISTRATION
7:00-4:00 PM
Prefunction**

**BREAKFAST
7:30-9:00 AM
CAPITAL D**

**BARIATRIC AND
GENERAL SURGERY
8:00-9:45 AM
CAPITAL A&B**

**NEUROLOGICAL AND
ORTHOPAEDIC
SURGERY - PART 2
8:00-2:15 PM
SENATE A&B**

**LUNCHEON
NOON-1:30 PM
CAPITAL D**

**COLORECTAL SURGERY
SYMPOSIUM
10:00-NOON
CAPITAL A&B**

**ARNO ROSCHER
ENDOWED LECTURE
1:30-2:15 PM
CAPITAL A&B**

**ANNUAL ETHICS
FORUM
2:15-3:30 PM
CAPITAL A&B**

**OPEN FORUM - FREE
PAPER PRESENTATIONS
3:30-5:30 PM
CAPITAL A&B**

**CLOSING DINNER
7:00-10:00 PM
CAPITAL D**