

CORONARY ARTERY BYPASS GRAFTING (CABG) (Part 1)

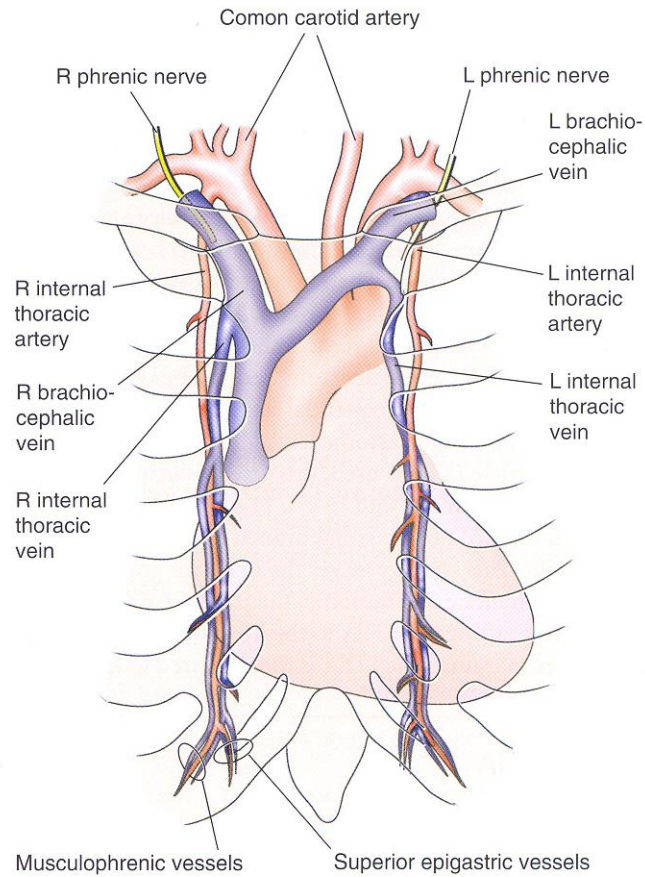
**Mark Shikhman, MD, Ph.D., CSA
Andrea Scott, CST**

I have constructed this lecture based on publications by leading cardiothoracic American surgeons: Timothy J. Gardner, MD; Brian F. Buxton, MD; Patrick G. Magee, MD.

History. Coronary Artery Bypass Grafting (CABG) began in the late 1960s along two parallel paths that included bypassing coronary artery obstructions using either the **Internal Mammary artery (IMA)** as the bypass conduit or reversed **saphenous vein graft (SVG)** from the leg. Each approach had early proponents, but the use of saphenous vein graft became the dominant approach by the majority of cardiac surgeons in 1970s. This preference was based on ease use of larger and technically less demanding saphenous vein graft, as well as the grater versatility of the vein graft. Saphenous veins could be used to graft any coronary artery site. By the mid- 1980s, with CABG being done increasingly often throughout the world and with 10- to 15-year follow-up experience available, two extremely important observations were made. Many of the earliest patients to receive bypass grafts were returning 5-10 or 12 years after operation with progression of atherosclerosis in their native coronary arteries and, even more alarming, had severe obstructive atherosclerosis in the vein grafts that were used in the original procedure. A second unexpected observation was that in patients who had IMA bypass grafts performed previously, graft atherosclerosis and graft occlusion were rarely encountered. These surprising finding led to changes in the approach in CABG procedure in the mid- to late 1980s, which has resulted in the current standard approach to coronary artery bypass surgery. The majority of patients who undergo CABG surgery today receive a **left IMA (LIMA) graft to the left anterior descending coronary artery (LAD)**. Other additional bypasses are constructed using reversed saphenous vein grafts with proximal aortic anastomoses.

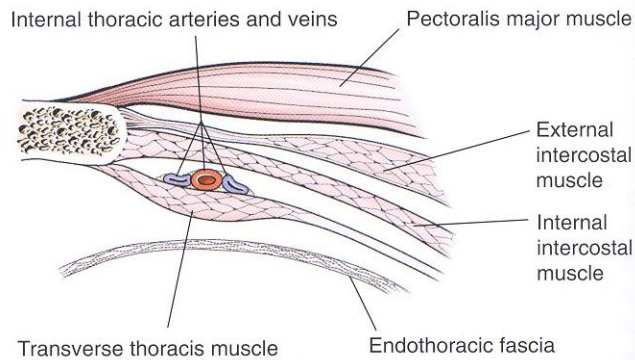
Preoperative assessment. All patients with considerations of CABG will have a coronary angiogram performed, which will give information about coronary arterial branches are completely or partially occluded and not visualizes. Another important component of preoperative assessment is the availability of suitable conduits. But before we will analyze importance of such assessment let's list and discuss variety of arterial and vinous conduits.

Arterial Conduits. The most usable arterial conduit in coronary grafting procedure is **Left Internal Thoracic (Mammary) Artery (LIMA)**. It was originated by work of Dr. Vineberg in 1946. The ITA arise from subclavian artery just above and behind the sternal end of the clavicle (Pic.1)



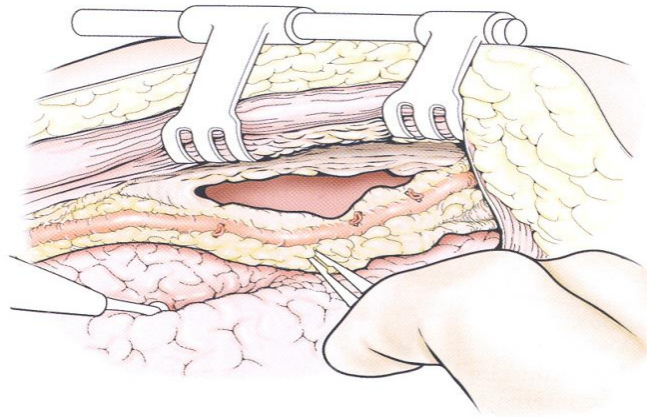
Pic.1

The artery descends vertically 1cm lateral to the sternal border, behind the first six costal cartilages. Pic.2 shows the ITA (IMA) position regarding pectoralis muscle, sternum, and pleura with endothoracic fascia.

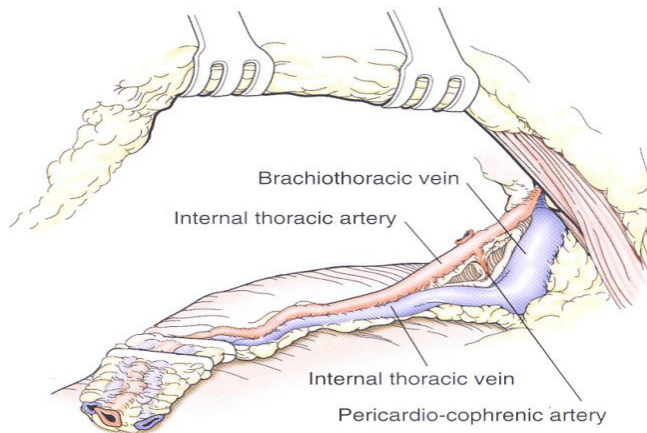


Pic.2

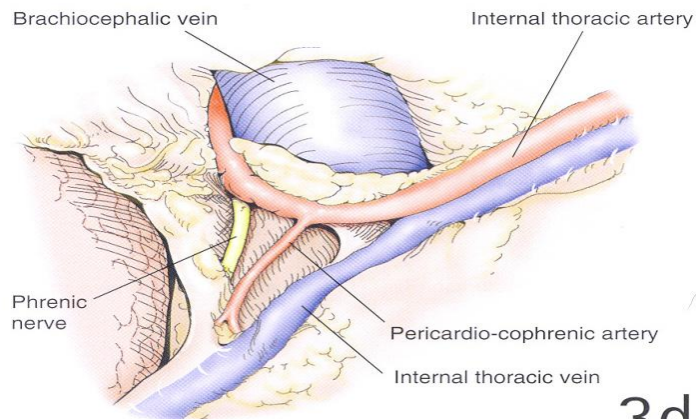
The next three pictures (pic3b, 3c, 3d) demonstrate stages of artery harvesting. Surgeons prefer to harvest artery with a pedicle which means together with surrounding tissues that provide protection for the artery.



3b

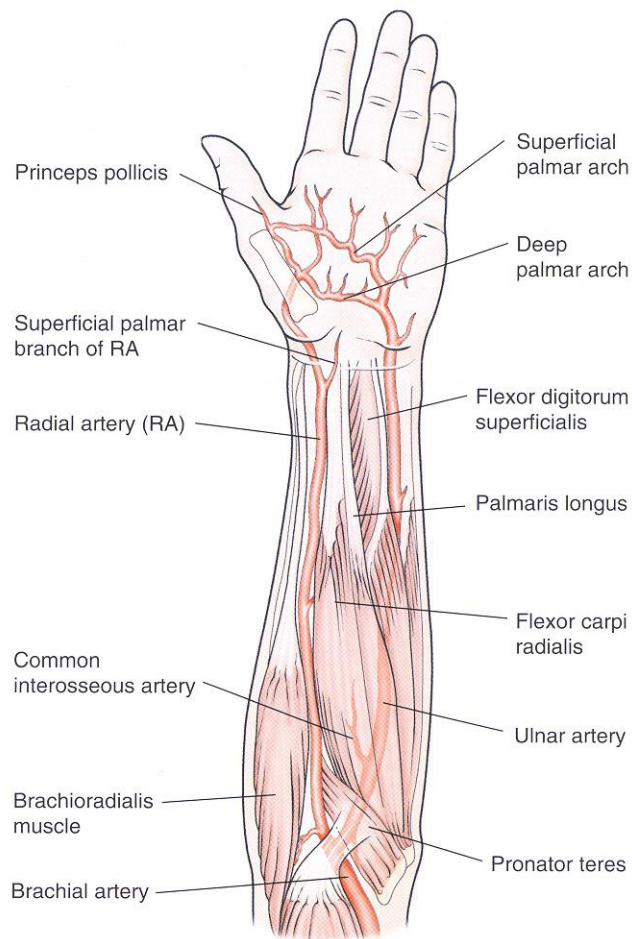


3c



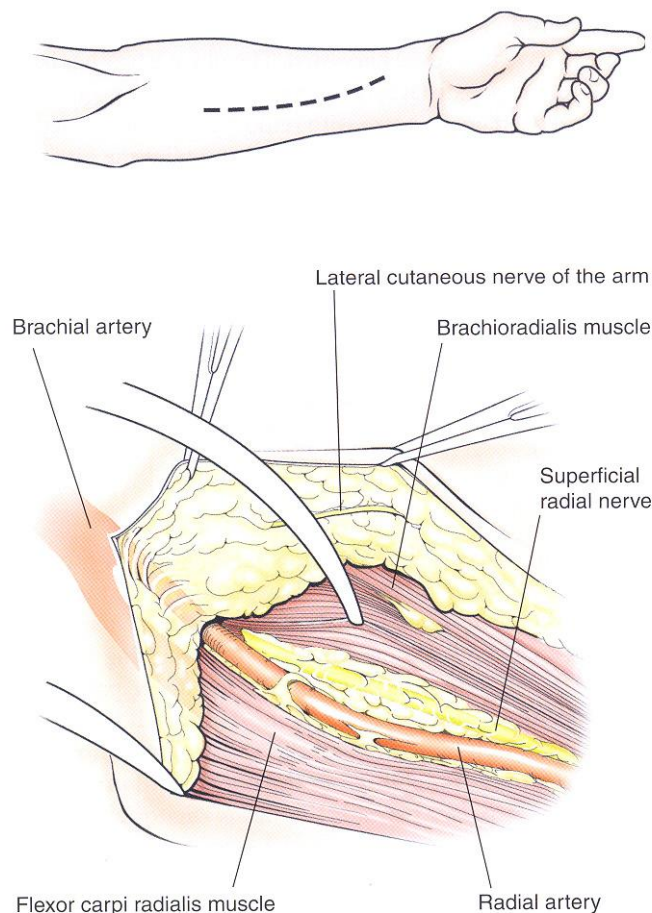
3d

The second artery that can be used as arterial conduit for coronary graft is **Radial Artery (RA)**. The RA arises from the bifurcation of the brachial artery in the cubital fossa and terminates by forming the deep palmar arch in the hand. The main concern using RA is blood supply to the wrist and hand but in recent anatomical study was found that superficial palmar arch of the ulnar artery provides the blood supply to all fingers I 67% of hands. Additionally to it in 87.5% of hands there is intense communication between deep palmar branches of the radial and ulnar arteries (pic.4).



Pic.4

Pictures below demonstrate location of incision and expose of the Radial artery.

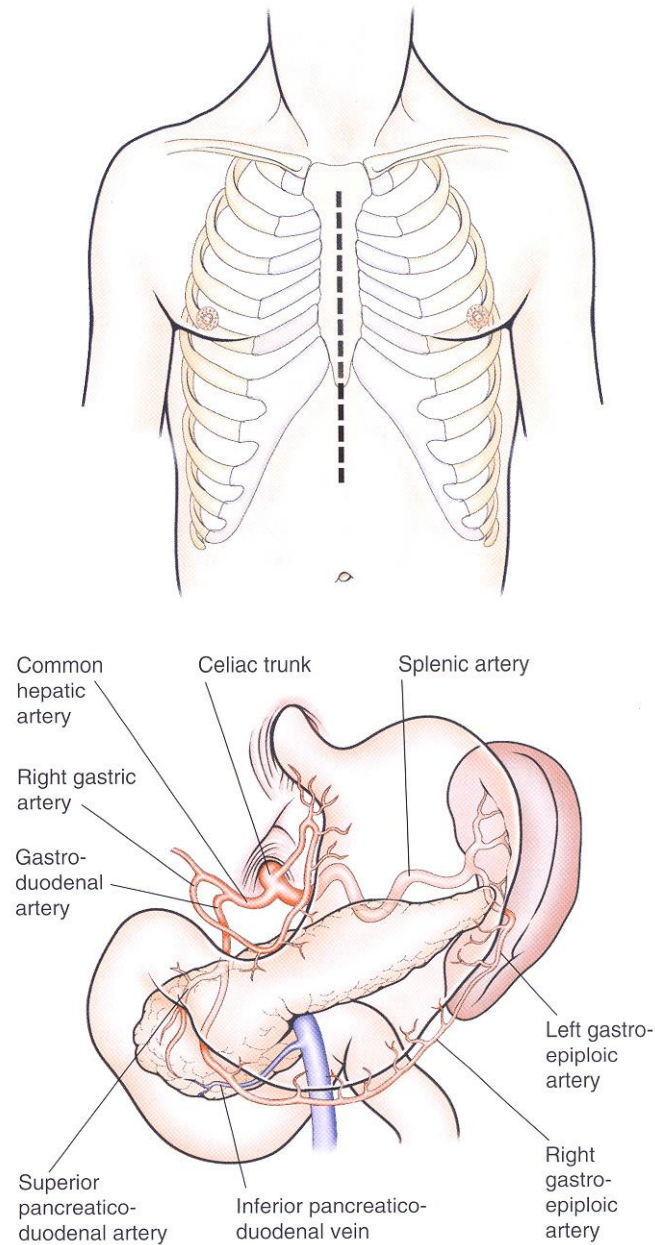


Pic.5

Occasionally, when surgeons do not have other choice they use **Ulnar Artery** as arterial conduit.

The **Gastroepiploic artery** is sometimes used as an arterial graft when the IMA cannot reach the posterior surface of the heart or when other conduits are not available. As you remember, there are two Gastroepiploic arteries: left and right. Both arteries are active participants in stomach vascularisation, but because of wide system of anastomosis between them and existence of other major gastric arteries, using the bigger – right Gastroepiploic artery as conduit does not

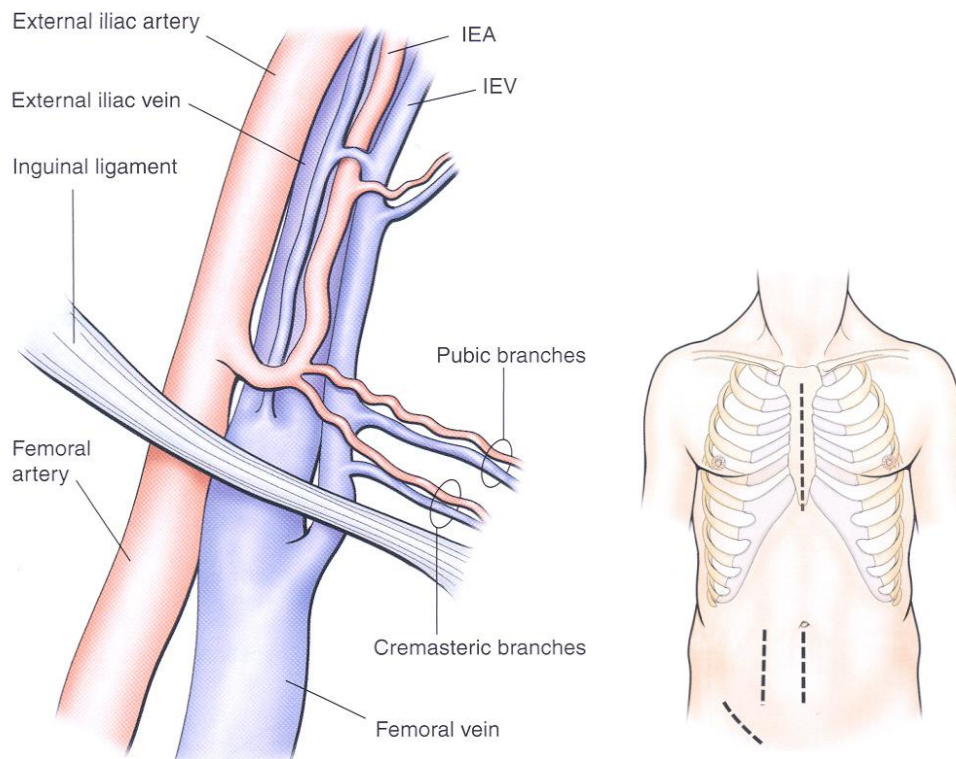
compromise stomach blood supply. Anatomy of Gastroepiploic arteries is presented on the picture 6.



Pic.6

It is not necessary to perform additional incision for harvesting this type of conduit; the median sternotomy incision is extended inferiorly for a further 5cm for performing laparotomy and Right Gastroepiploic artery harvesting. The last artery that can be used as arterial conduit in the coronary bypass surgery is **Inferior Epigastric Artery**. In many patients, when it is used alone, the length

of this artery is not sufficient for an independent graft. It is used as a composite graft with the LIMA as extension graft. You are familiar with this artery regarding anatomy of inguinal triangle. The inferior epigastric artery arises from the external iliac artery and gives branches to the spermatic cord, pubis, abdominal muscles, and skin (pic.7). Unfortunately this artery is positioned far away from even extended sternotomy incision and its harvesting requires additional either low midline, or paramedian, or oblique inguinal approach.



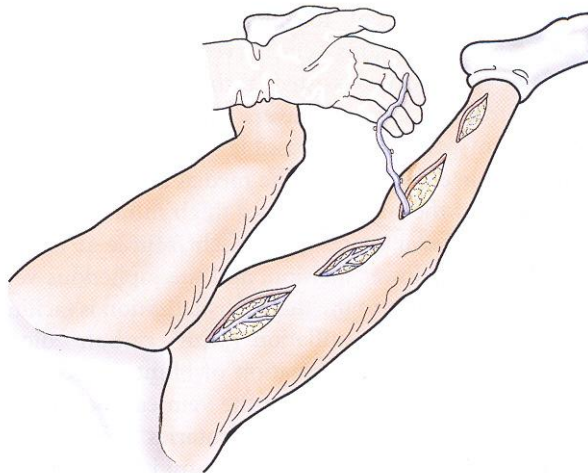
Pic.7

Saphenous Vein Graft. Despite of the progressive atherosclerosis that has been founded in the vein graft, it is one of the major conduits for coronary arteries bypass surgery. The Greater Saphenous Vein (GSV) of the lower extremity is the best choice of this type of graft based on:

- There are two independent types of low extremity vein system and removal of superficial one (GSV) does not jeopardize the vinous flow from the leg
- Position, diameter and length of the GSV are in constant pattern which simplifies its harvest

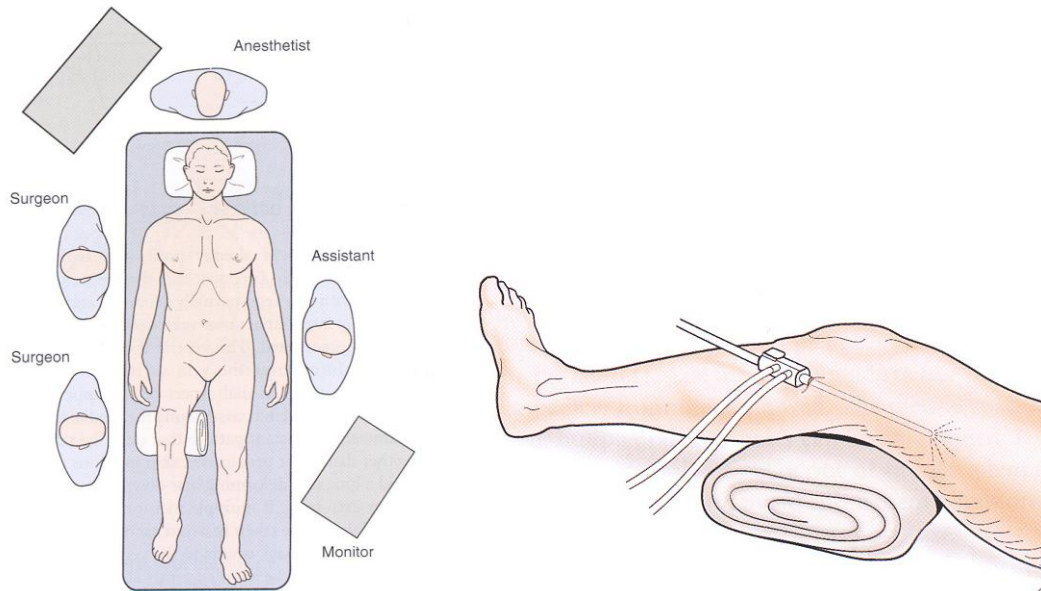
GSV is harvested in two different ways:

- **Directly** through multiple incisions and tunneling over the vein along the medial thigh and leg (Pic.8).



Pic.8

- **Endoscopic** vein harvest (Pic.9). In many patients it is possible to make two small incisions, one above the knee, and the second upper thigh for this type of harvest. Patient, leg and surgical team positions are presented on pictures below.



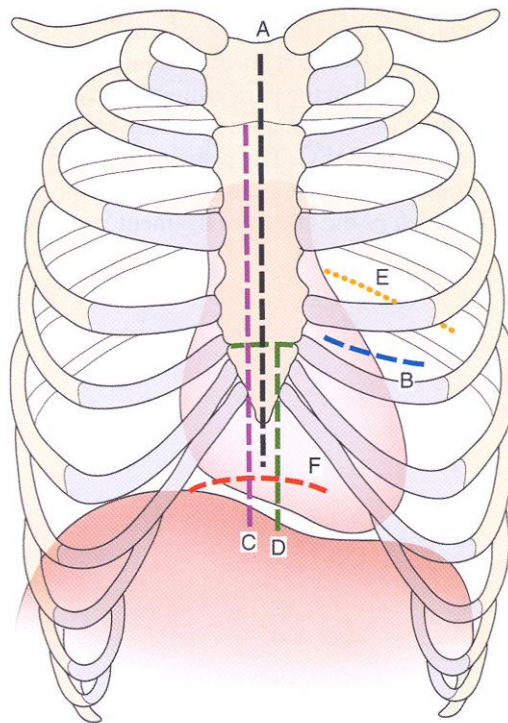
Pic.9

CORONARY ARTERY BYPASS GRAFTING (CABG) (Part 1)

Mark Shikhman, MD, Ph.D., CSA
Andrea Scott, CST

Incision

The next picture (Pic.10) shows few different types of surgical accesses that commonly used in cardiothoracic surgery



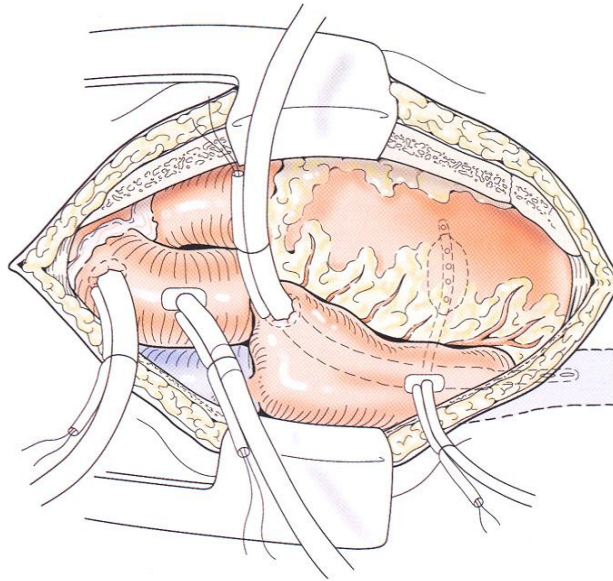
Pic.10

- A – Sternotomy**
- B – Anterior Thoracotomy**
- C – Sternotomy with Subxiphoid Laparotomy**
- D – Distal Sternotomy**
- E – Posterior Thoracotomy**
- F – Transverse Curved Laparotomy**

In majority of the cases Sternotomy is the approach of the choice since entire sternum must be divided for the traditional multi-vessel CABG operation.

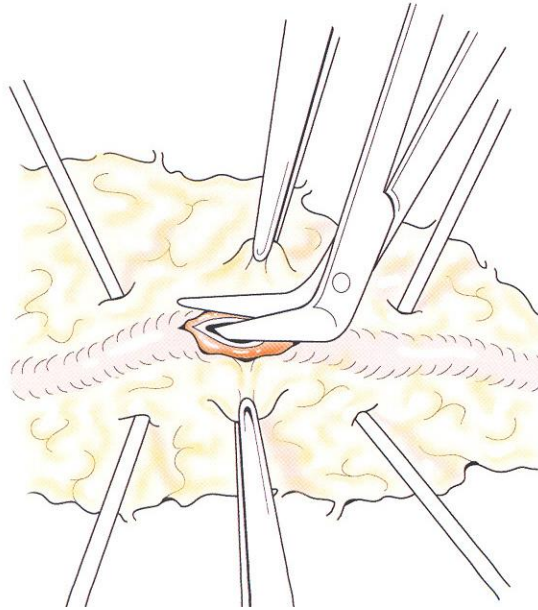
Cardiopulmonary bypass

Cardiopulmonary bypass (Pic.11) has to be established by arterial cannulation onto aortic arch and venous cannulation through the right atrial appendage into the inferior vena cava.



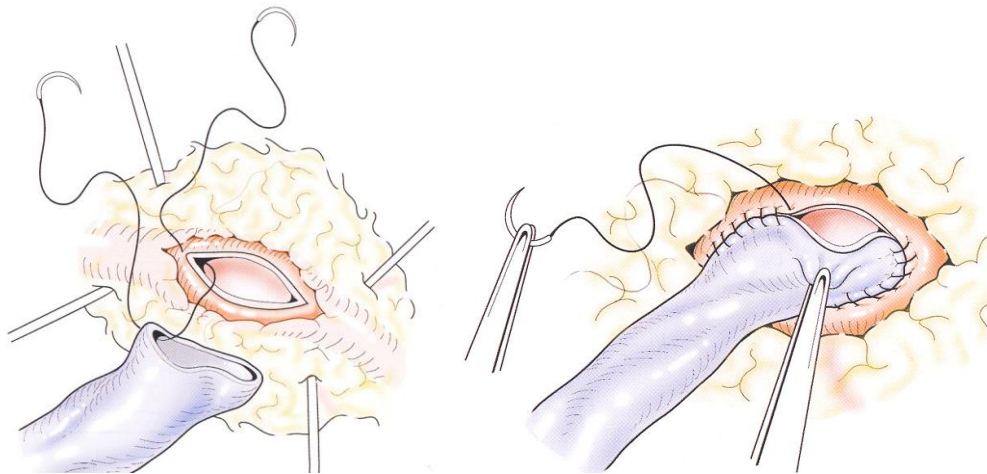
Pic.11

In the conventional CABG procedures construction of the **Distal Venous Anastomoses** should be performed first to avoid possible traction on the mammary artery graft. Coronary artery is stabilized, the epicardium overlying the artery is incised, and arteriotomy is performed for a distance of 6-8 mm (Pic.12).



Pic.12

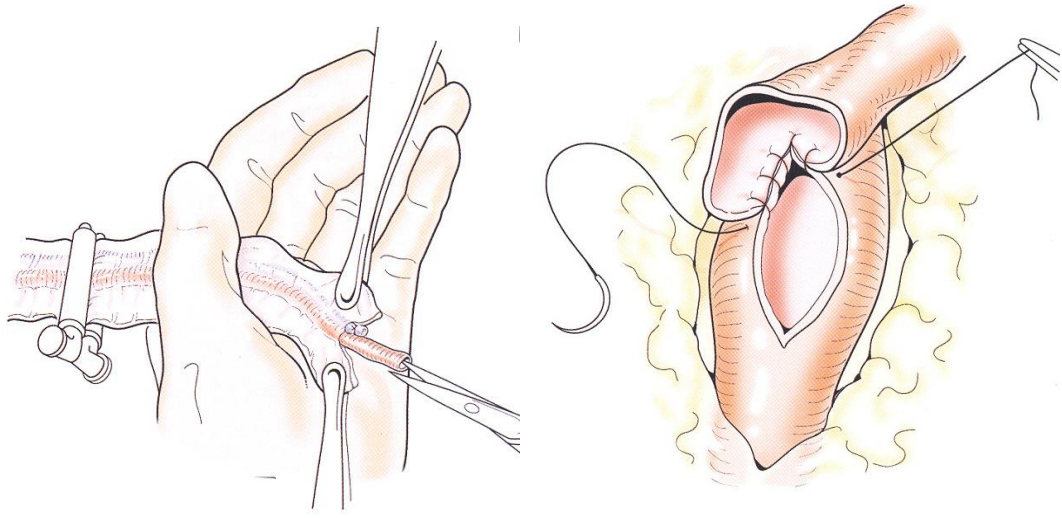
The **reversed** saphenous vein is slightly beveled and anastomosed to the coronary artery with a single **7/0 polypropylene suture** (Pic.13).



Pic.13

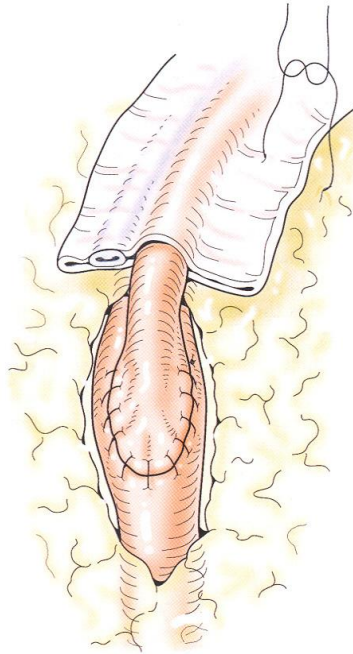
Next, the **Internal Mammary Artery (IMA) is anastomosed to the Left Anterior Descending Coronary Artery (LAD)**. Once an adequate pedicle length is determined, the LAD is incised and the IMA incised on an angle at an appropriate distal site. A 7/0 or 8/0 polypropylene suture is used to construct this

type of anastomosis of approximately 3-4 mm in length with the continuous stitch (Pic.14).



Pic.14

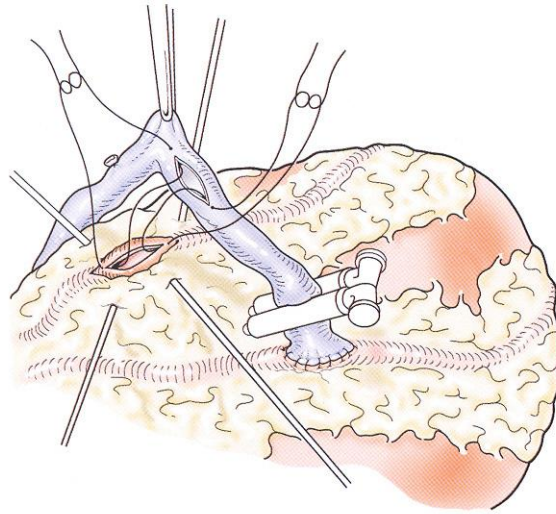
Final view of the anastomosis is presented below (Pic.15)



Pict.15

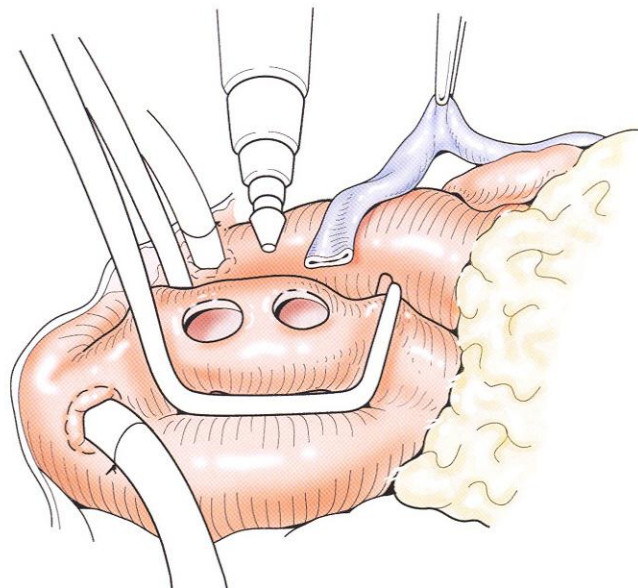
Now surgeon can go back and complete proximal vein graft anastomosis with aorta. But in instances in which available vein for grafting is limited or when there is concern about multiple anastomoses on aorta, surgeon can construct two

or more distal anastomoses with a single vein graft. It will be called **Sequential Distal Vein Graft Anastomoses** (Pic.16).

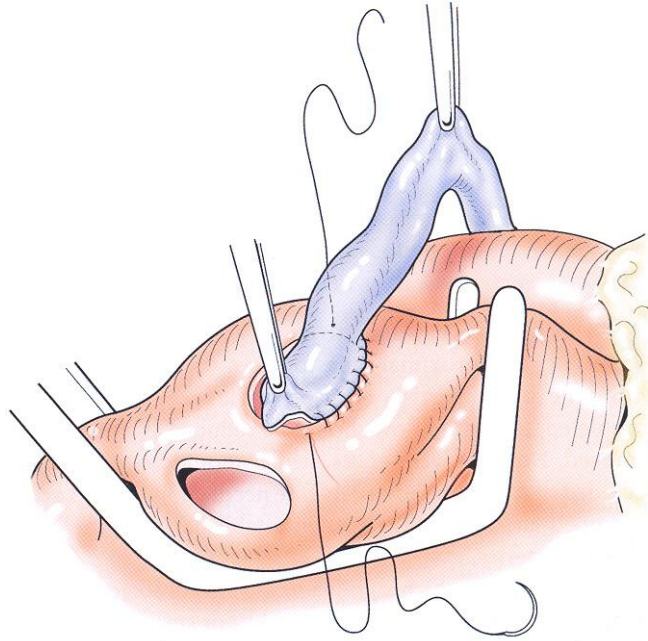


Pic.16

The final stage of the grafting procedure is construction of the **Proximal Vein Graft Anastomoses**. The **Aorta Wall Punch** is used to create openings in aorta for anastomoses (Pic.17) and distal segment of the vein graft is anastomosed with aorta (Pic.18).

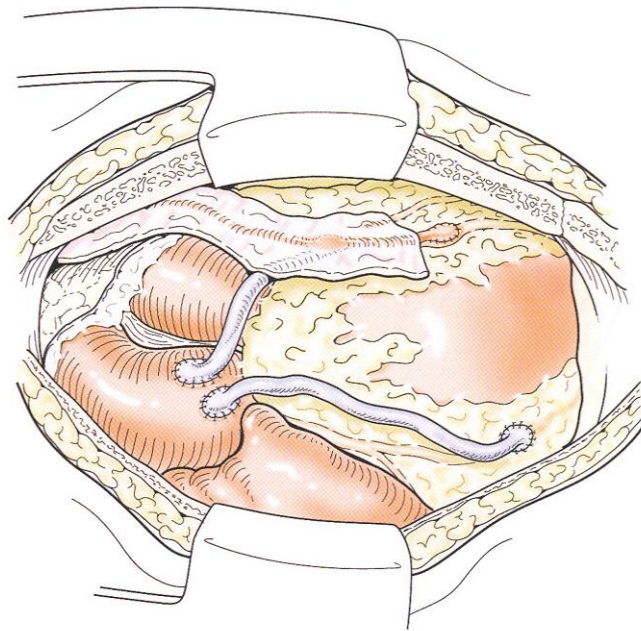


Pic.17



Pic.18

The final view of the completed CABG procedure is presented below (Pic.19).



Pic.19
