

CT IMAGING OF THE PARANASAL SINUSES – BASIC ANATOMY AND IMAGE INTERPRETATION

Benjamin Y. Huang, MD, MPH
University of North Carolina

OVERVIEW

- Indications for imaging chronic sinusitis
- Scan technique
- Basic anatomy of the paranasal sinuses
- Anatomic variants which predispose to sinusitis and surgical complications

WHY DO WE CARE ABOUT THE PARANASAL SINUSES?

- Rhinosinusitis affects 14-16% of adults
- Accounts for 11.6 million outpt office visits annually
- Estimated direct costs of sinusitis \$5.8 billion
- 5th most common diagnosis leading to antibiotic prescriptions
- Over 200,000 FESS procedures performed annually

INDICATIONS FOR CT

****THE DIAGNOSIS OF SINUSITIS IS MADE CLINICALLY!!!**

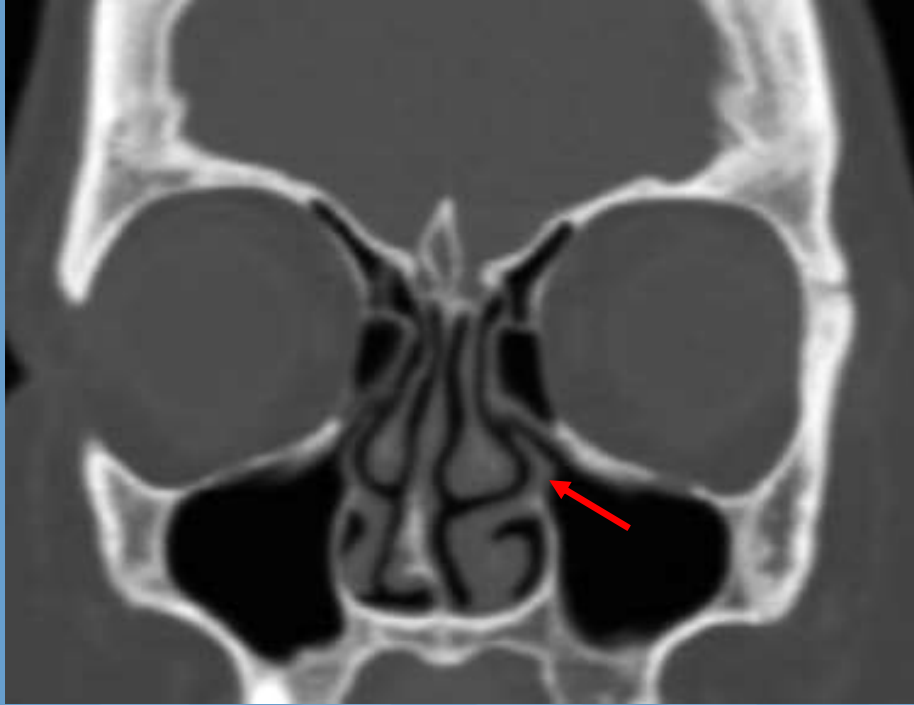
- Sinusitis refractory to maximal medical therapy
- Surgical planning and operative guidance
- Evaluation of operative failure or complications
- Suspected complications of sinusitis (invasive fungal dz, mucocele, orbital cellulitis/abscess, intracranial spread)

SCAN TECHNIQUE

- Standard coronal CT is INADEQUATE to understand 3D sinus anatomy, particularly in the frontal recess
- Axial thin section (<1mm) helical CT
- Axial, coronal, and sagittal reconstruction (3 mm thick or less)
- Bone and soft tissue windows
- Patients should only be scanned after a trial of maximal medical therapy (3-6 wks)

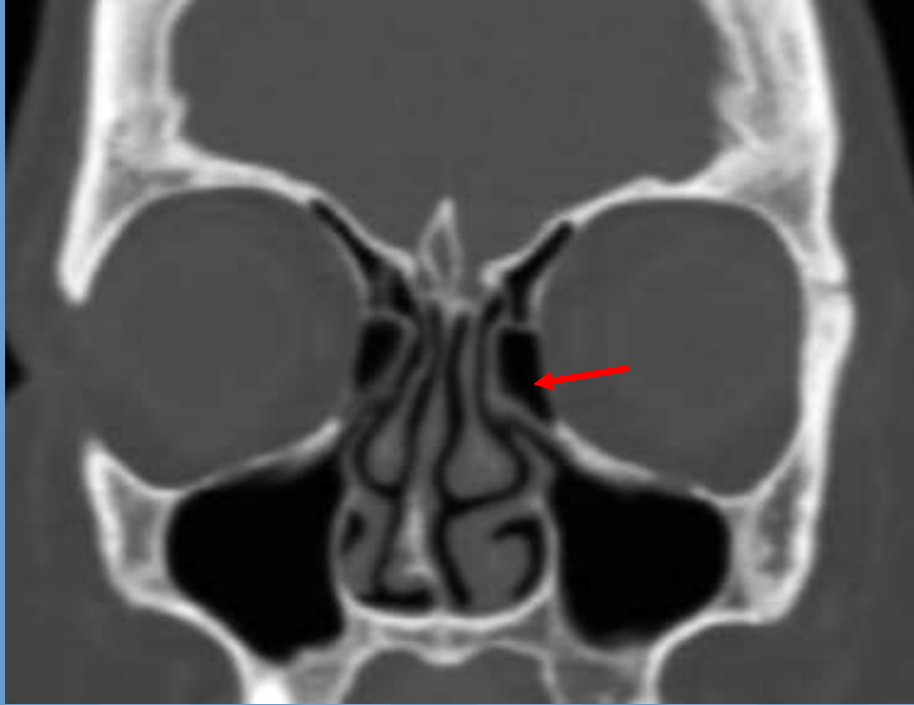
ANATOMIC “TIGHT SPOTS”

- Areas which are predisposed to obstruction
 - 1) Ostiomeatal complex
 - 2) Frontal recess
 - 3) Sphenoethmoidal recess



Name the structure indicated by the arrow.

- A) Middle turbinate
- B) Ethmoid bulla
- C) Uncinate process
- D) Ethmoidal infundibulum



Name the structure indicated by the arrow.

A) Middle turbinate

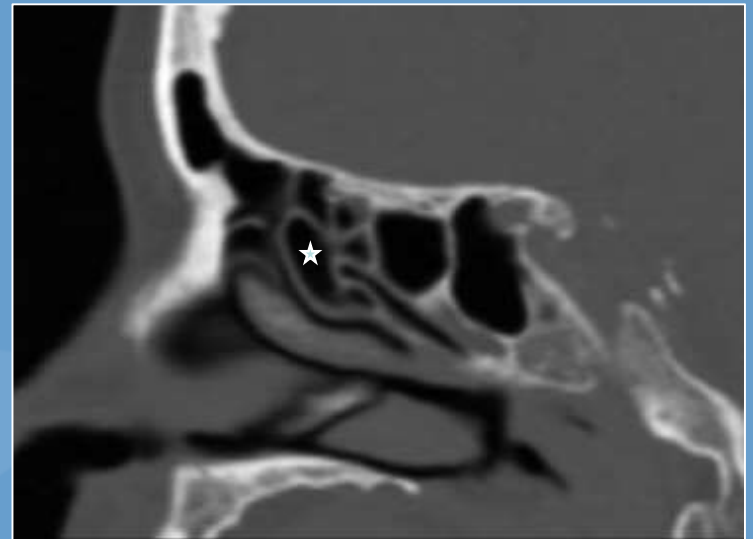
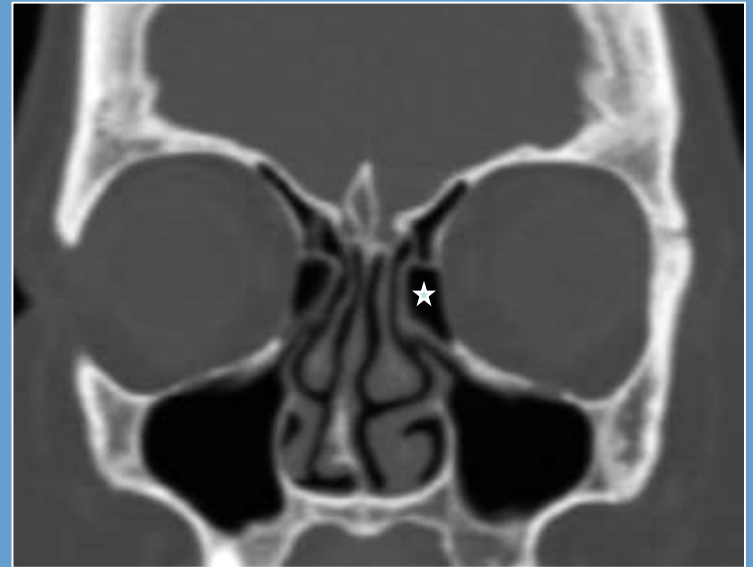
B) Ethmoid bulla

C) Agger nasi

D) Ethmoidal infundibulum

ETHMOID BULLA

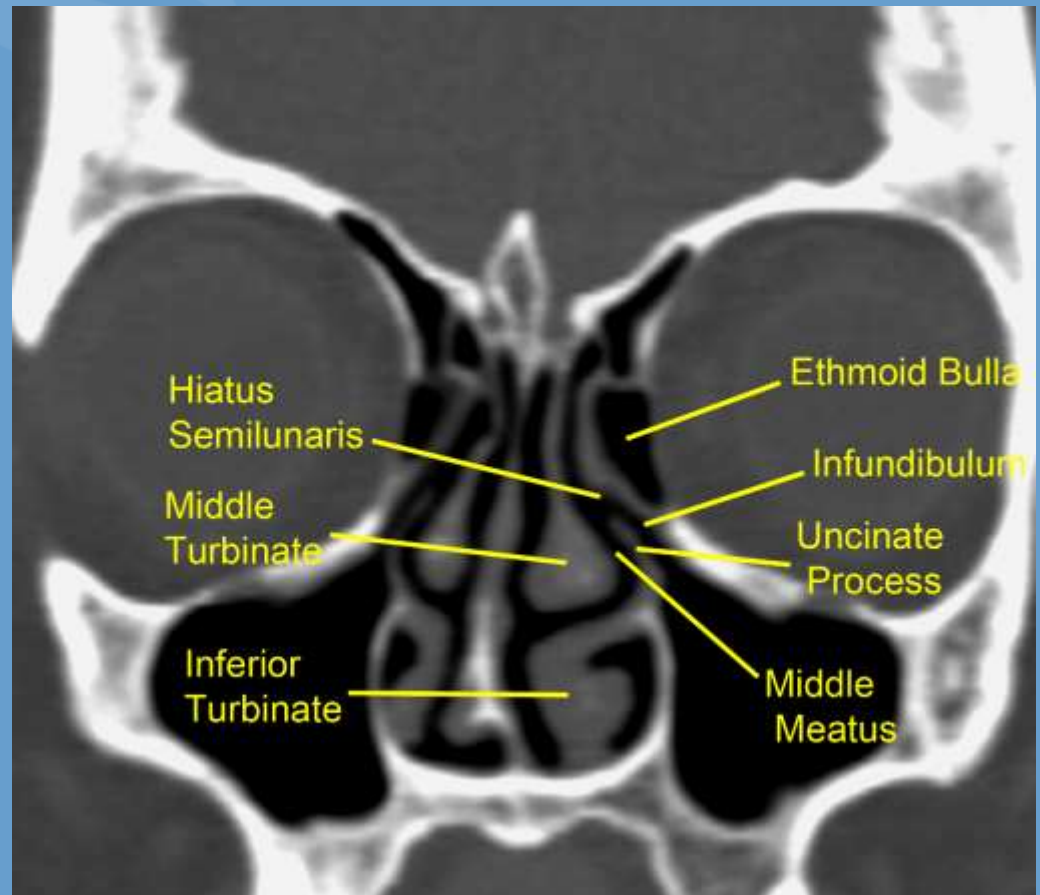
- Bulge on the lateral nasal cavity wall above the hiatus semilunaris
- Forms the roof the of ethmoidal infundibulum
- Usually a single large ethmoid air cell



OSTIOMEATAL COMPLEX

Common channel draining the maxillary, anterior ethmoid & frontal sinuses:

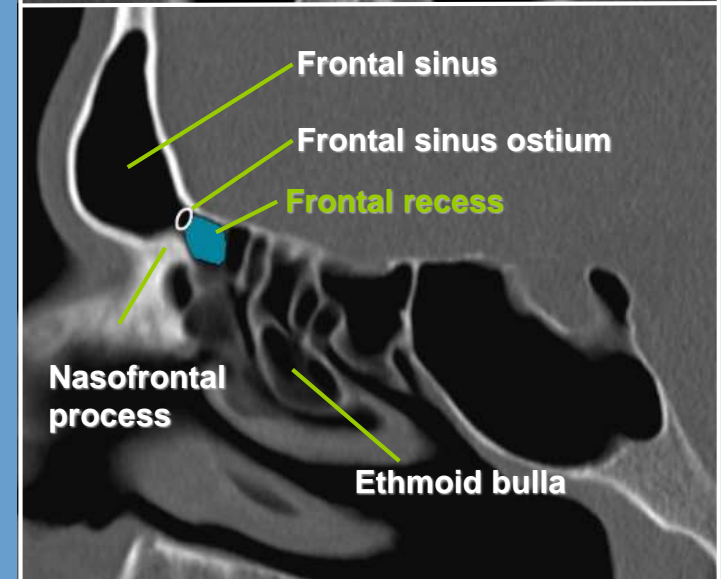
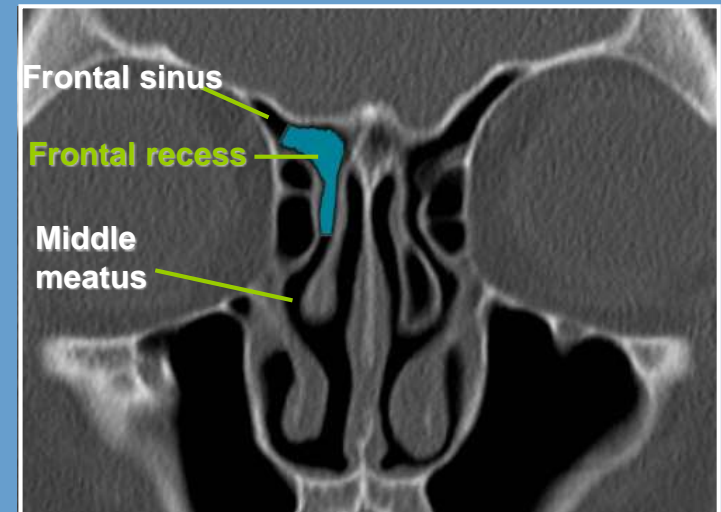
- Maxillary sinus ostium
- Ethmoid infundibulum
- Uncinate process
- Ethmoid bulla
- Hiatus semilunaris
- Middle turbinate



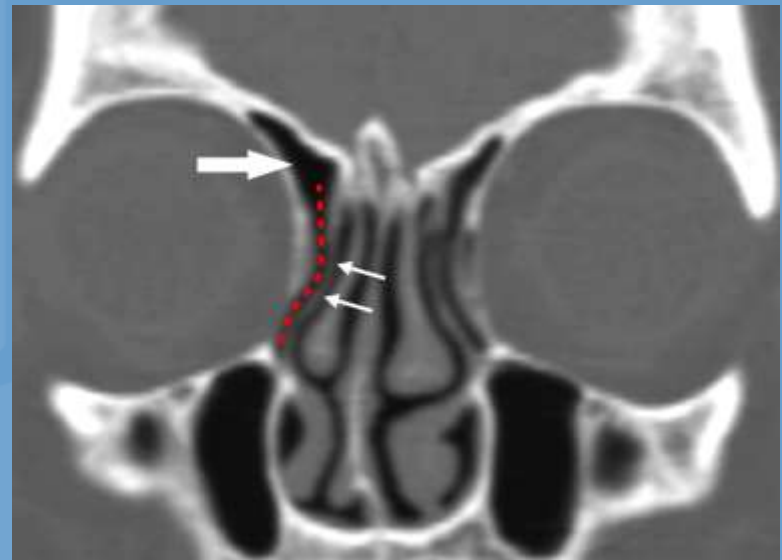
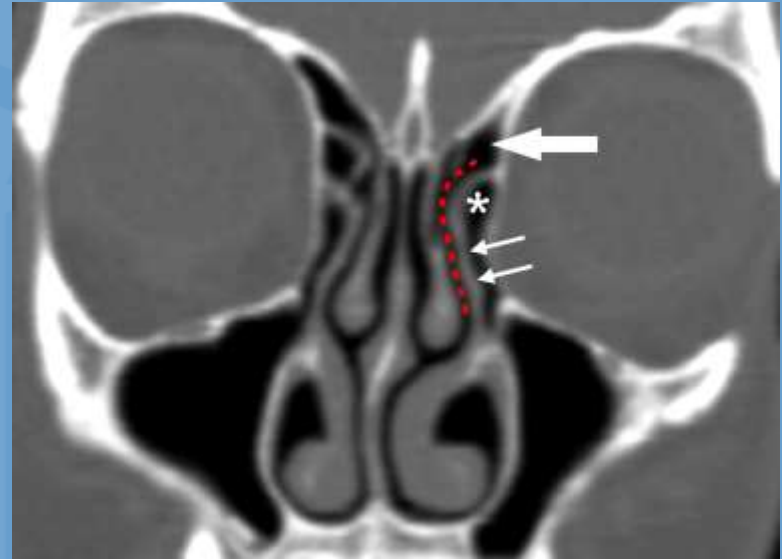
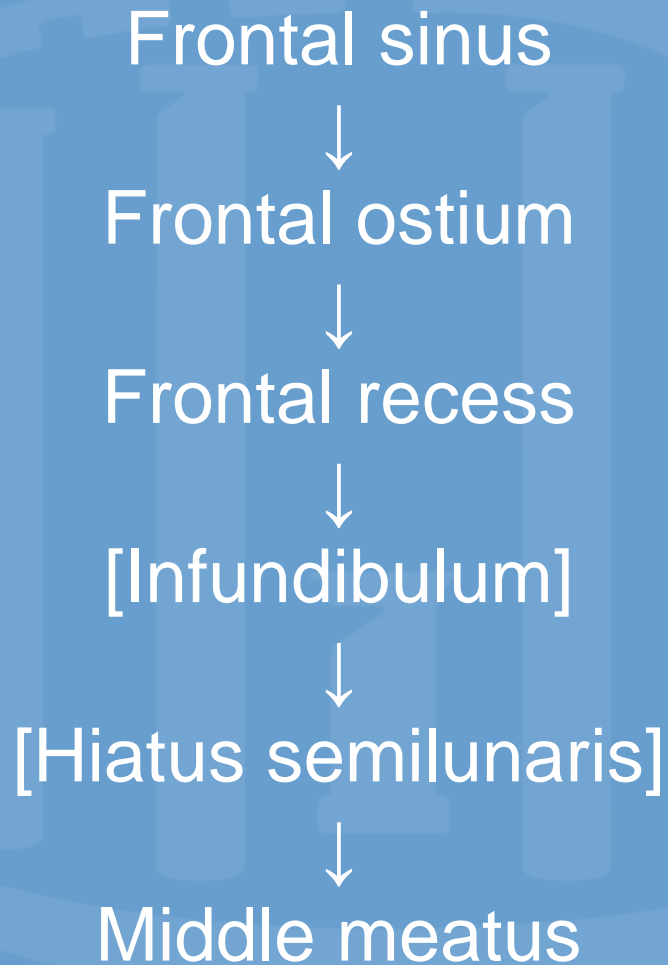
FRONTAL RECESS

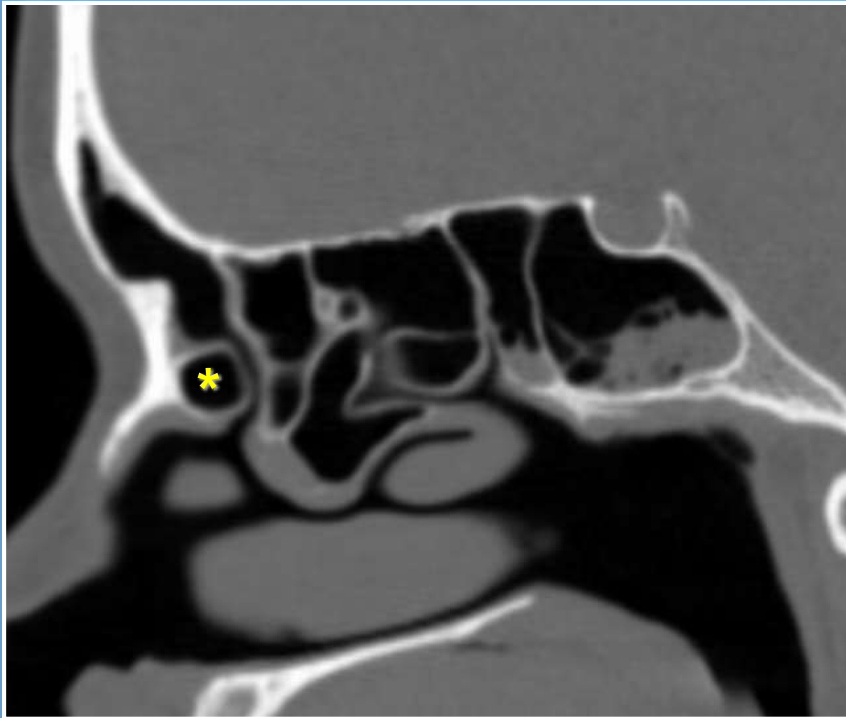
Structures involved in drainage pathway for the frontal sinus

- Frontal sinus ostium
- Nasofrontal process
- Frontal recess
- Agger nasi
- Frontal recess cells
- Uncinate process
- Middle meatus
- Lamina papyracea



FRONTAL SINUS DRAINAGE





Name the structure indicated by the asterisk.

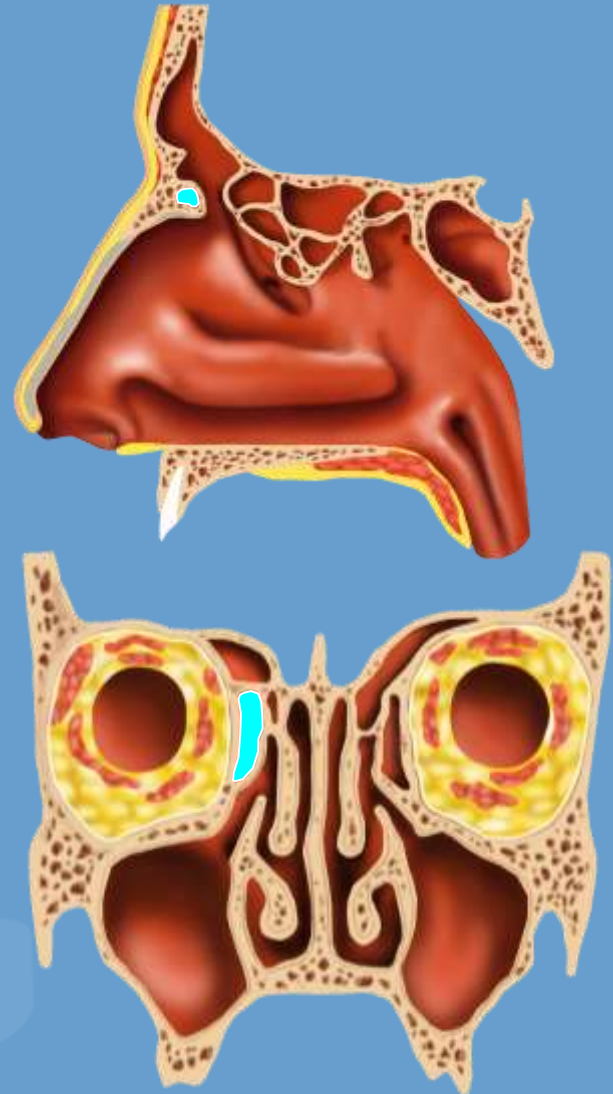
- A) Ethmoid bulla
- B) Agger nasi
- C) Type I frontal cell
- D) Type IV frontal cell

FRONTAL RECESS CELLS

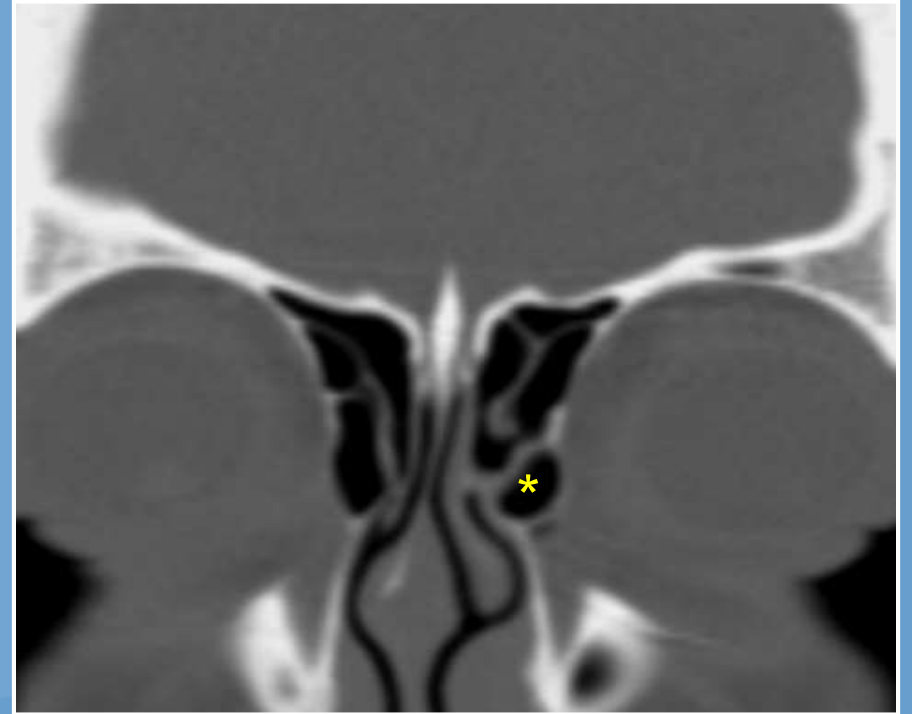
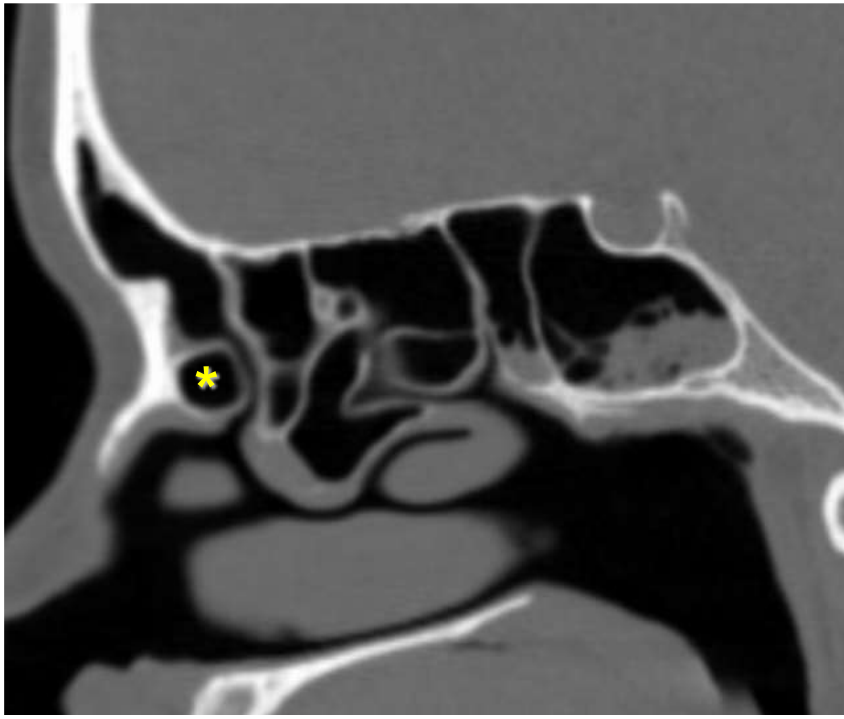
- Agger nasi cell (ANC)
- Frontal cell (FC)
- Supraorbital ethmoid cell (SOC)
- Frontal bullar cell (FBC)
- Suprabullar cell (SBC)
- Interfrontal sinus septal cell (ISSC)

AGGER NASI CELL

- “Anterior-most ethmoid cell”
- Found in nearly all patients normally
- Pneumatized intranasal portion of the frontal process of the maxilla
- Forms the anterior boundary of the FR
- Best seen on coronal and sagittal images



AGGER NASI CELL

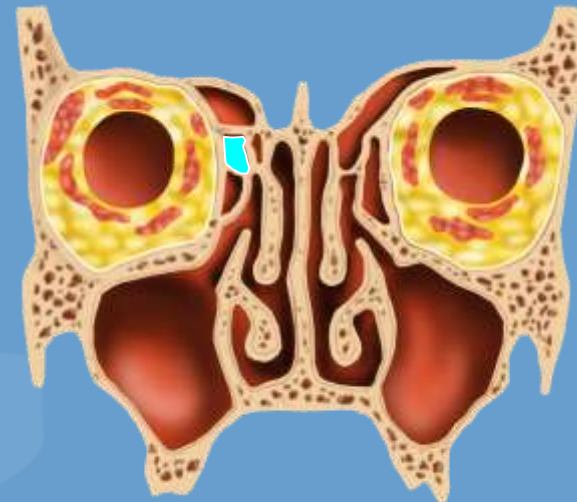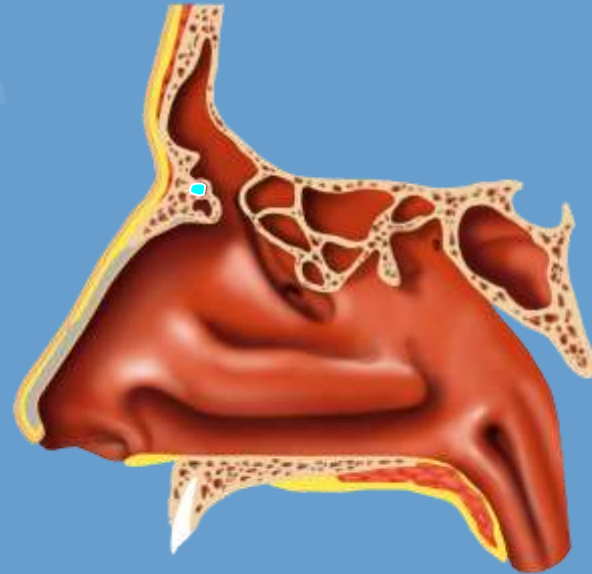


FRONTAL CELLS

- 4 types of frontal cells (I-IV)
- Found in 20%-41% of sinus specimens
- Can obstruct outflow at the FR or ostium
- Frontal cells are well seen on ***coronal and sagittal*** images

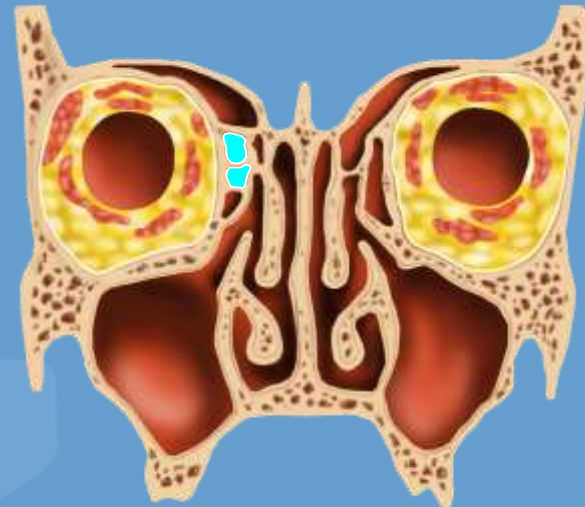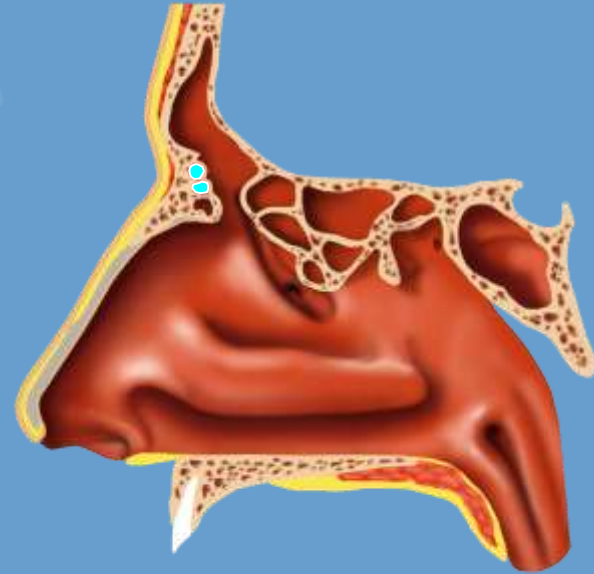
TYPE I FRONTAL CELL

- Most common of the frontal cells, seen in 14%-37% of frontal recess sides
- **Single** anterior ethmoid cell above the agger nasi cell
- Posterior wall makes up the anterior FR



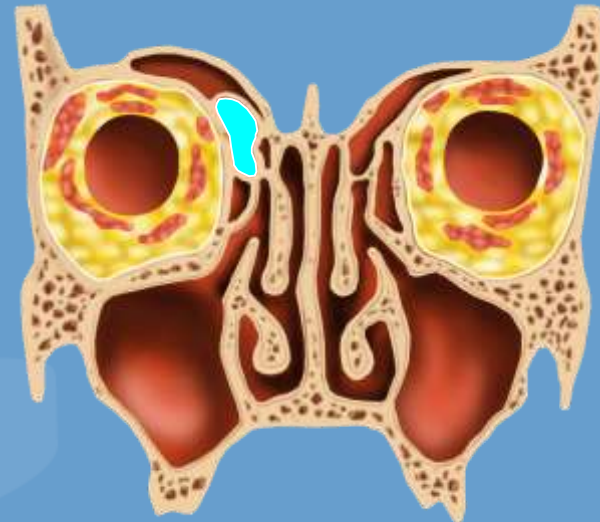
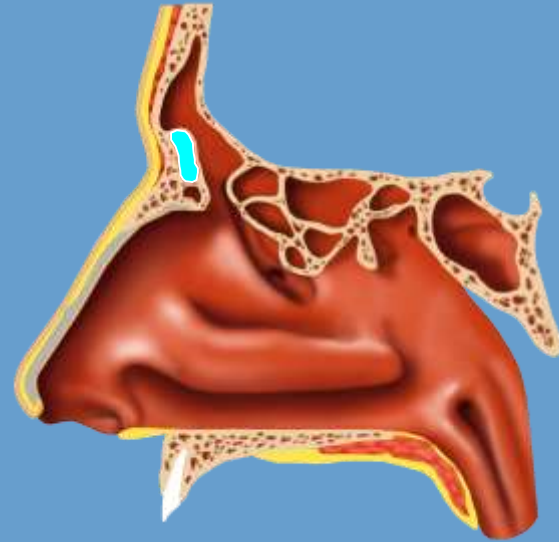
TYPE II FRONTAL CELLS

- Tier of **2 or more** anterior ethmoid cells above the agger nasi cell
- Posterior wall makes up the anterior frontal recess



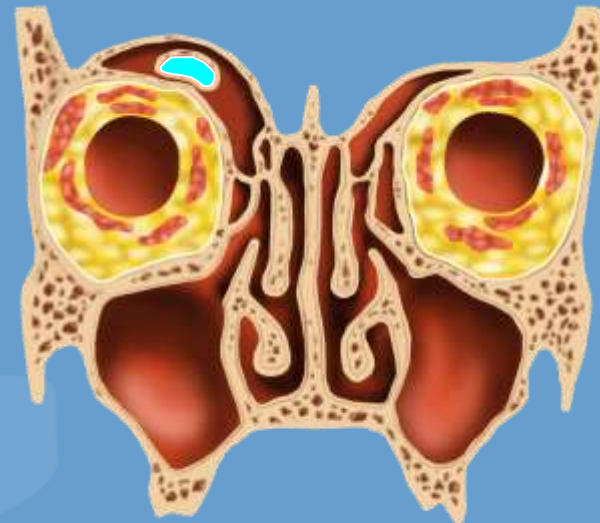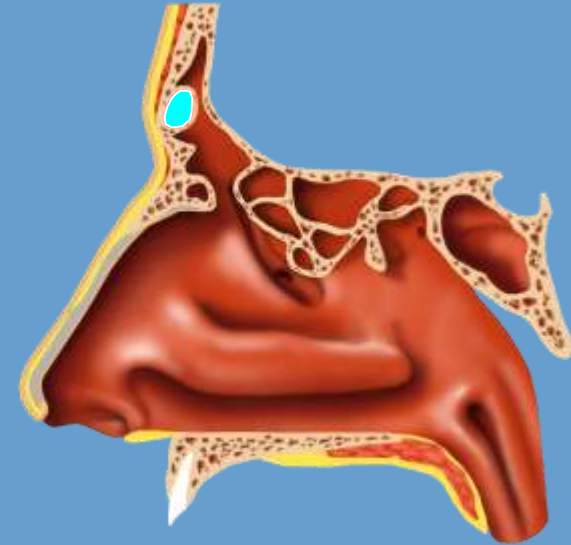
TYPE III FRONTAL CELL

- Single large anterior ethmoid cell, above the agger nasi, extends from frontal recess into the true frontal sinus
- Posterior wall makes up the anterior frontal recess wall

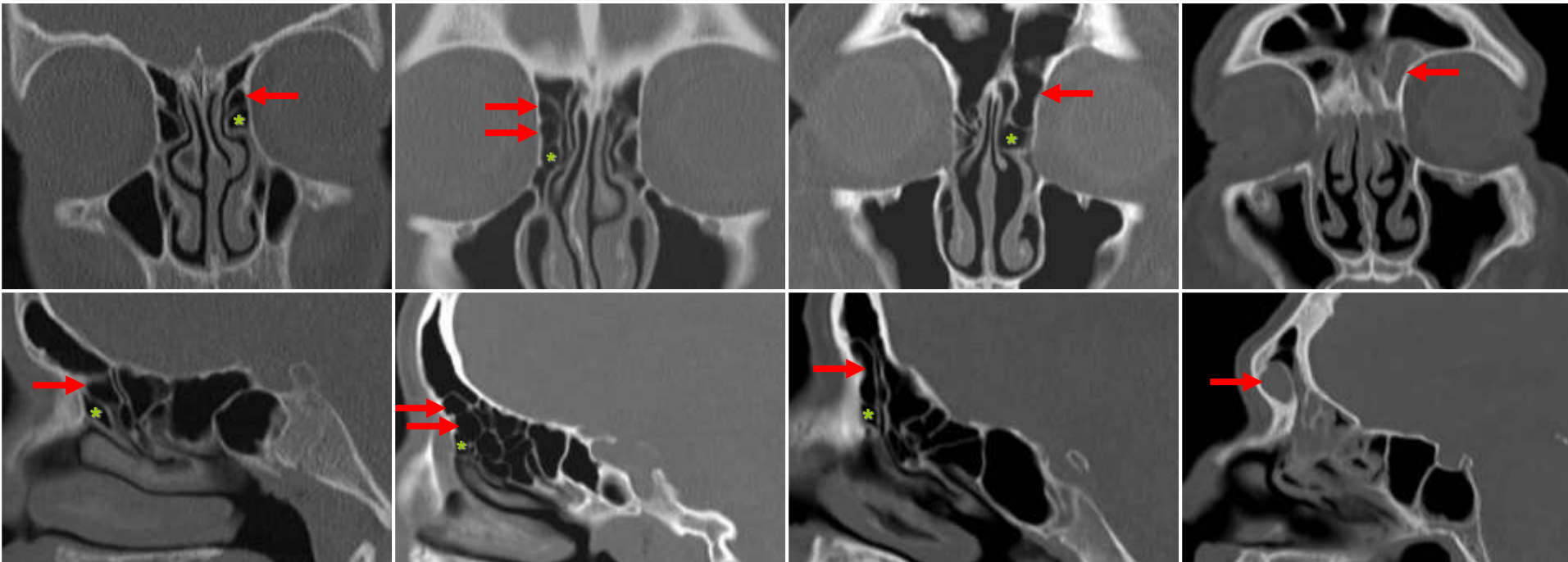


TYPE IV FRONTAL CELL

- Isolated anterior cell completely within the frontal sinus, above the agger nasi cell
- “Sinus within a sinus”
- Should not extend to posterior frontal sinus table
- Rarest form of frontal cell seen



FRONTAL CELLS



Type 1

Type 2

Type 3

Type 4

Arrow = frontal cell(s)
Asterisk = agger nasi cell

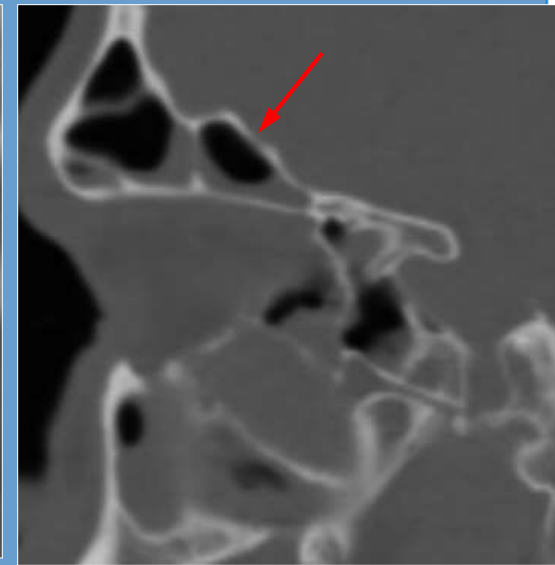
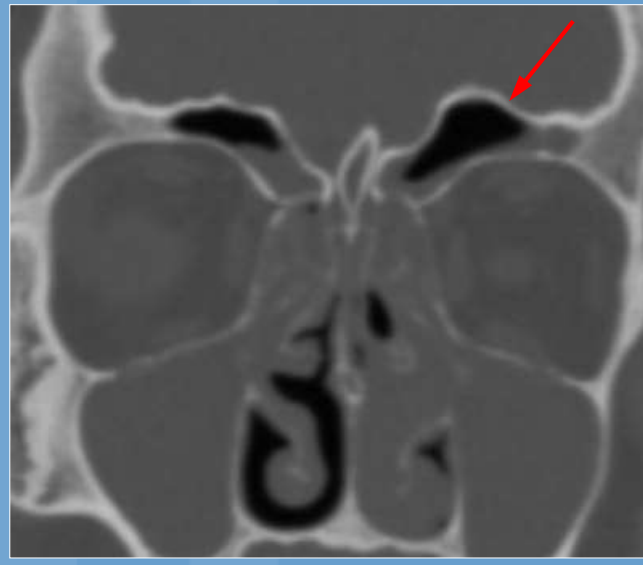
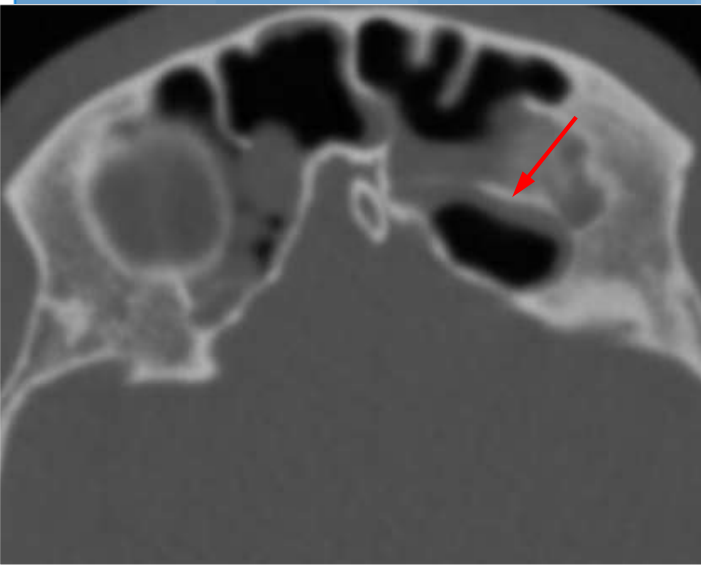
FRONTAL RECESS CELLS

- Agger nasi cell (ANC)
- Frontal cell (FC)
- Supraorbital ethmoid cell (SOC)
- Frontal bullar cell (FBC)
- Suprabullar cell (SBC)
- Interfrontal sinus septal cell (ISSC)

SUPRAORBITAL ETHMOID CELL

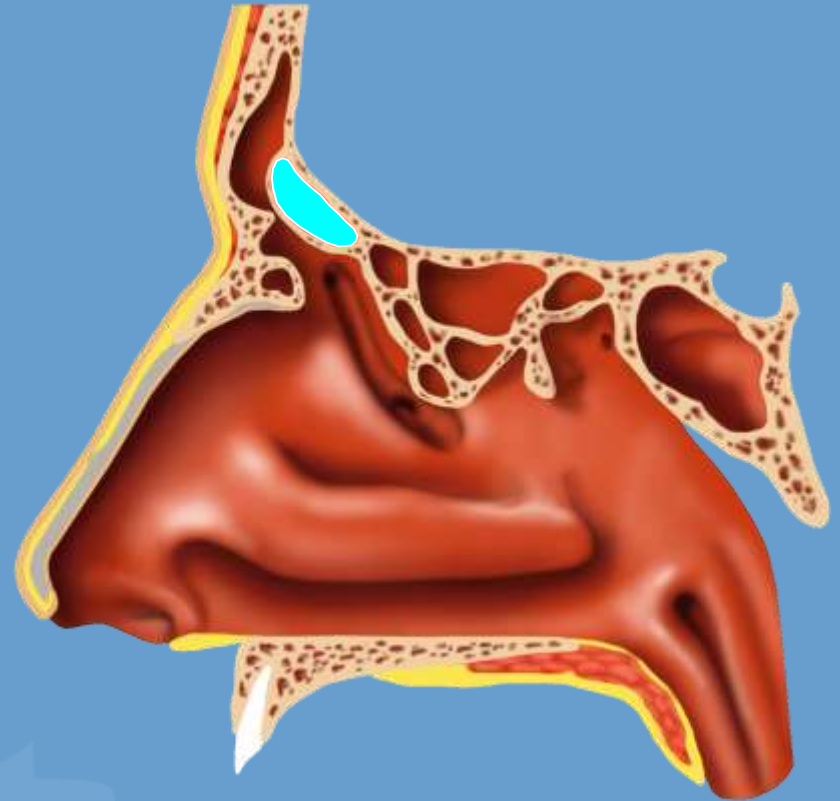
- Ethmoid cell extending over the orbit from the frontal recess
- Opens into the lateral aspect of frontal recess (posterior to true frontal sinus ostium)
- Single or multiple
- Mimics a septated frontal sinus
- Seen best on *axial and coronal* images

SUPRAORBITAL ETHMOID CELL



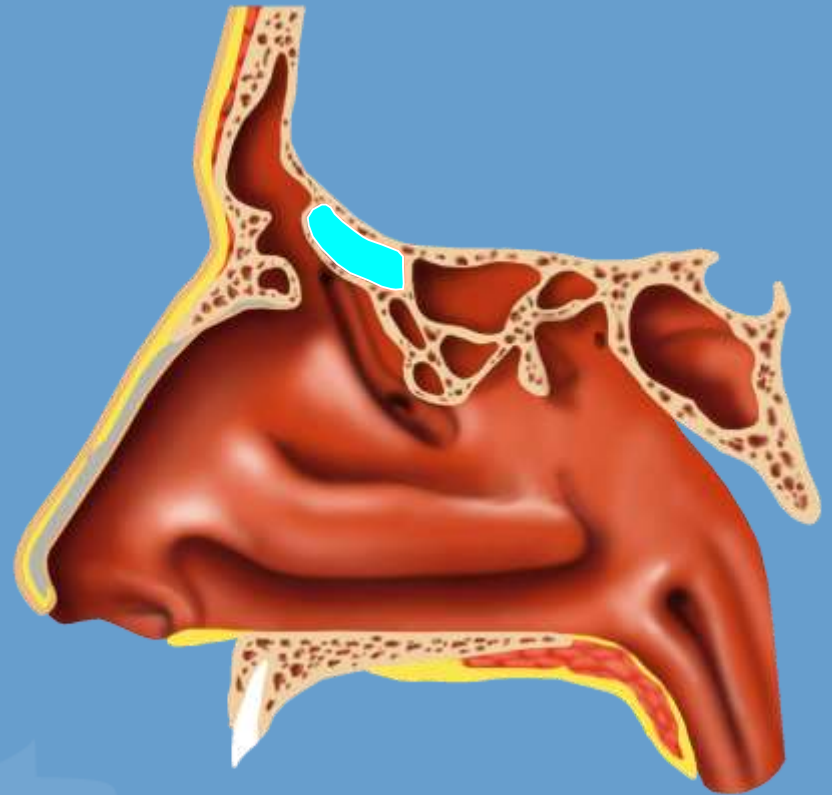
FRONTAL BULLAR CELL

- Posteriorly positioned cell above the ethmoid bulla
- Anterior border extends into frontal sinus
- **Posterior** wall is anterior cranial fossa skull base
- Seen best on *sagittal* images

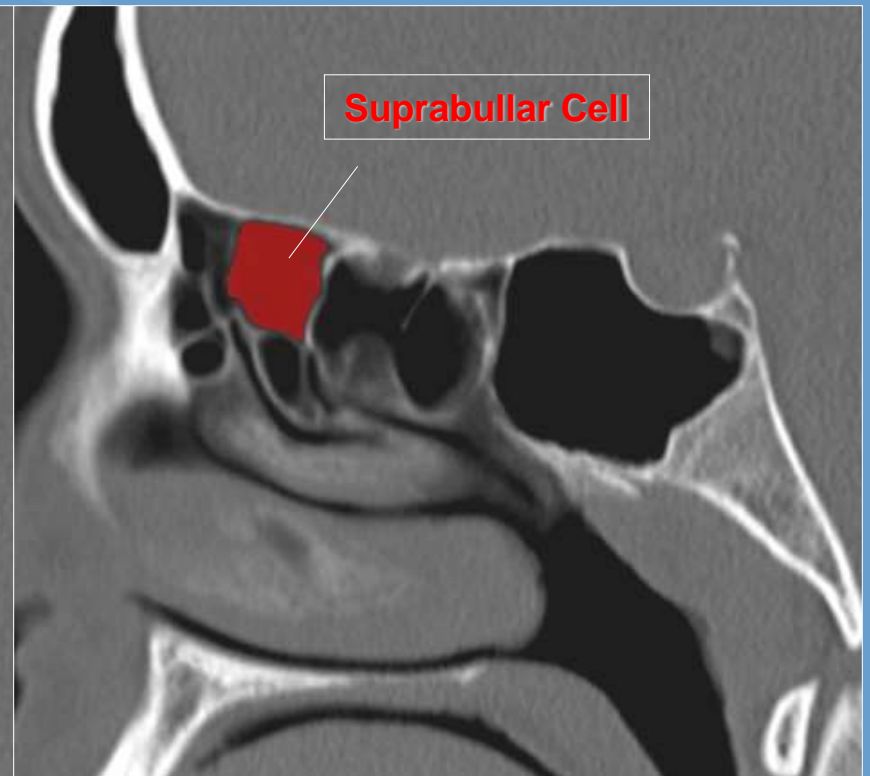
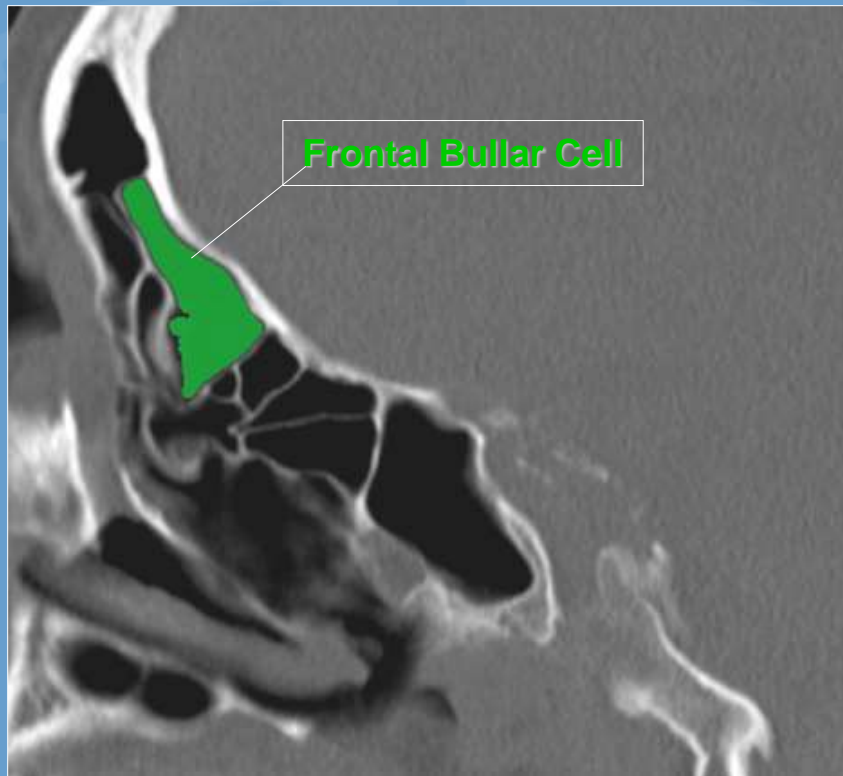

SUPRABULLAR CELL

- Posteriorly positioned cell above the ethmoid bulla
- Anterior border *does not* extend into the frontal sinus
- **Superior** wall is anterior cranial fossa skull base
- Seen best on ***sagittal*** images



FRONTAL BULLAR AND SUPRABULLAR CELLS

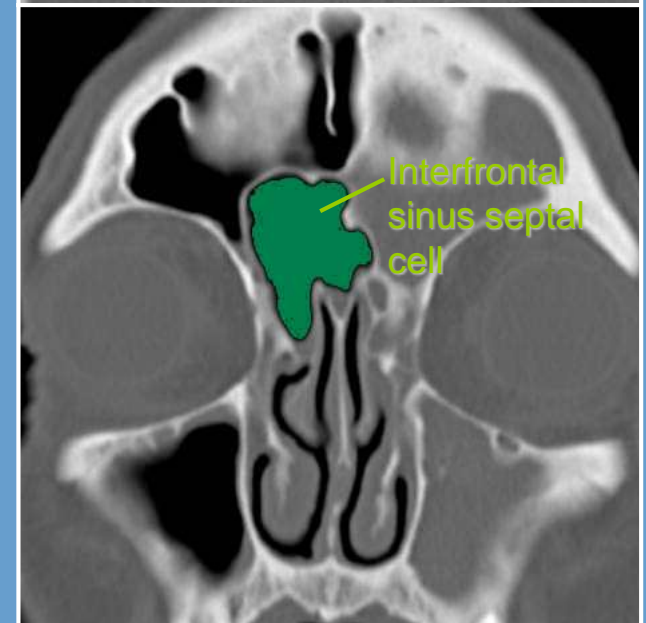
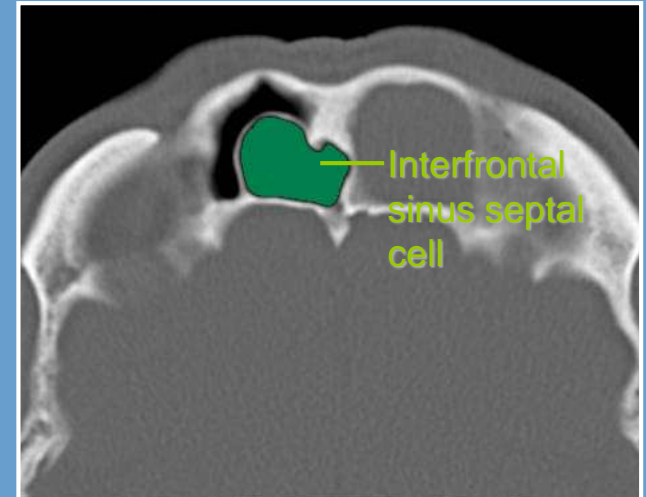


FRONTAL RECESS CELLS

- Agger nasi cell (ANC)
- Frontal cell (FC)
- Supraorbital ethmoid cell (SOC)
- Frontal bullar cell (FBC)
- Suprabullar cell (SBC)
- Interfrontal sinus septal cell (ISSC)

INTERFRONTAL SINUS SEPTAL CELL

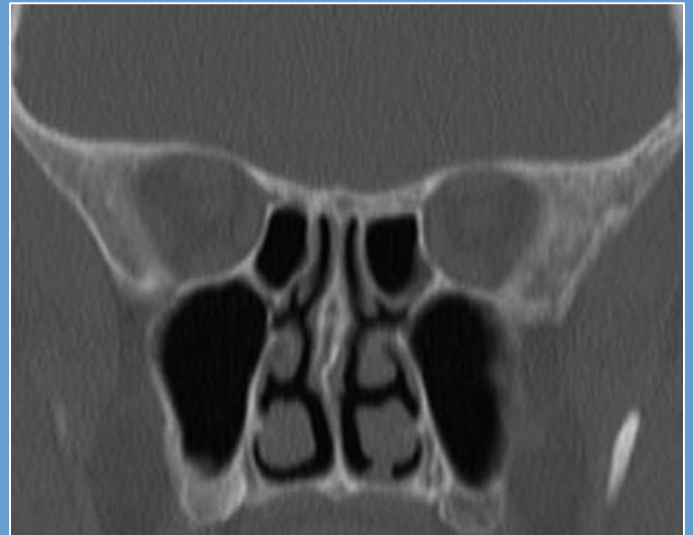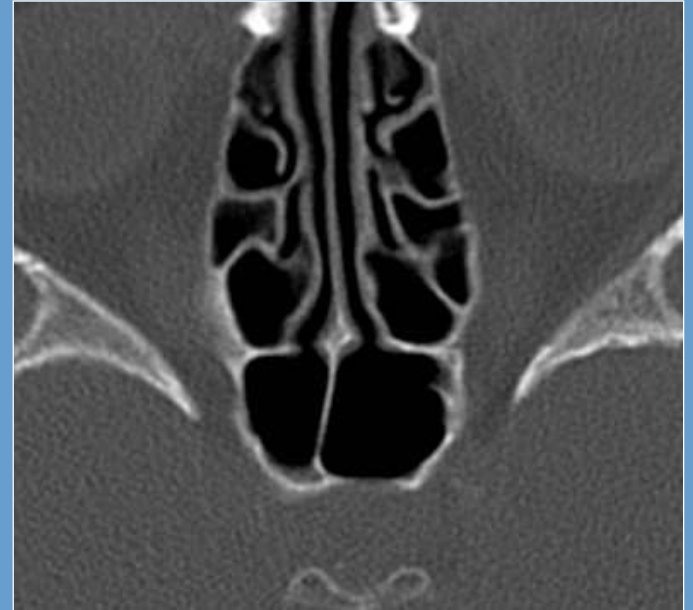
- Pneumatization of the frontal sinus septum
- May pneumatize the crista galli
- Drains into frontal recess
- Best characterized on *axial and coronal* images



ANATOMIC “TIGHT SPOTS”

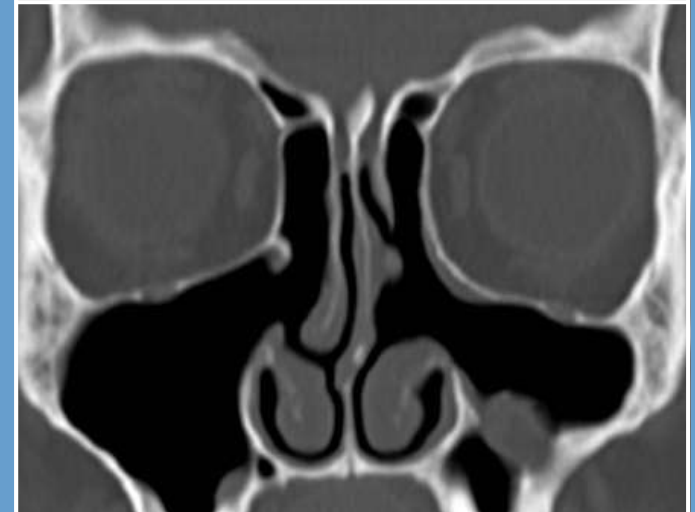
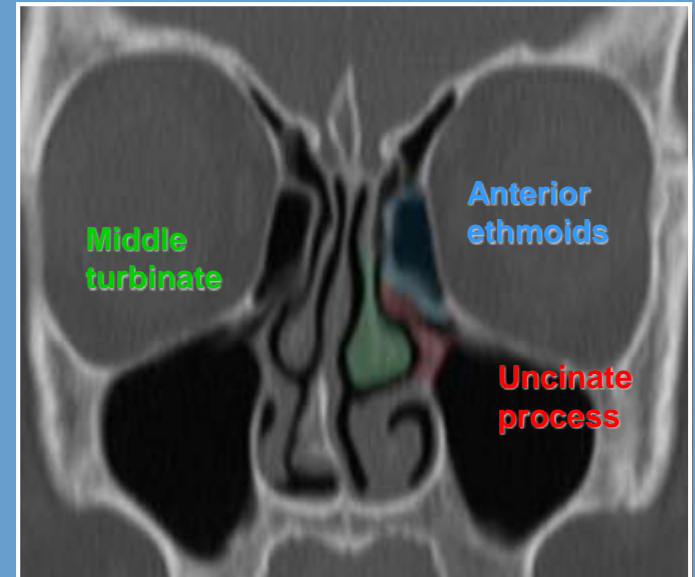
SPHENOETHMOIDAL RECESS

- Drains sphenoid (via sphenoid ostium) and posterior ethmoids
- Empties into superior meatus
 - Superior & middle turbinates



PRIMARY FESS

- Commonly performed procedures for initial treatment include:
 - Uncinectomy/Maxillary (middle meatal) antrostomy (**red**)
 - Anterior ethmoidectomy (**blue**)
 - Partial middle turbinectomy (**green**)
- Refractory or more complicated disease in the FR may require a Draf type drill out



FESS

PREOPERATIVE EVALUATION

- Surgical planning is initiated only after maximal medical treatment has failed or in patients with chronic or recurrent episodes of sinusitis
- Preoperative evaluation includes
 - Diagnostic nasal endoscopy
 - Multiplanar sinus CT
 - performed after maximal medical treatment

PREOPERATIVE CT IMAGING IN CHRONIC SINUSITIS

- To assess the extent and severity of disease
- To identify anatomic causes of sinus outflow obstruction
- To search for potential surgical pitfalls
- To elucidate sinus anatomy
- Intraoperative guidance

LUND-MACKAY CT SCORING SYSTEM

Table 1 - Lund-McKay staging system.

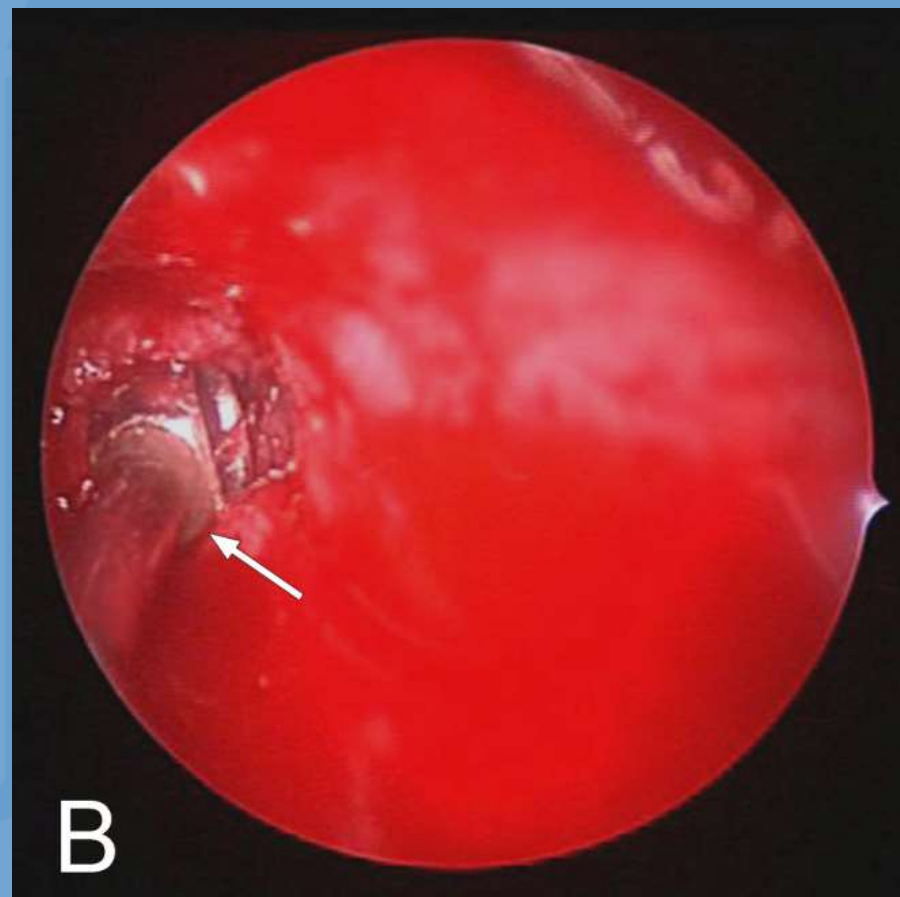
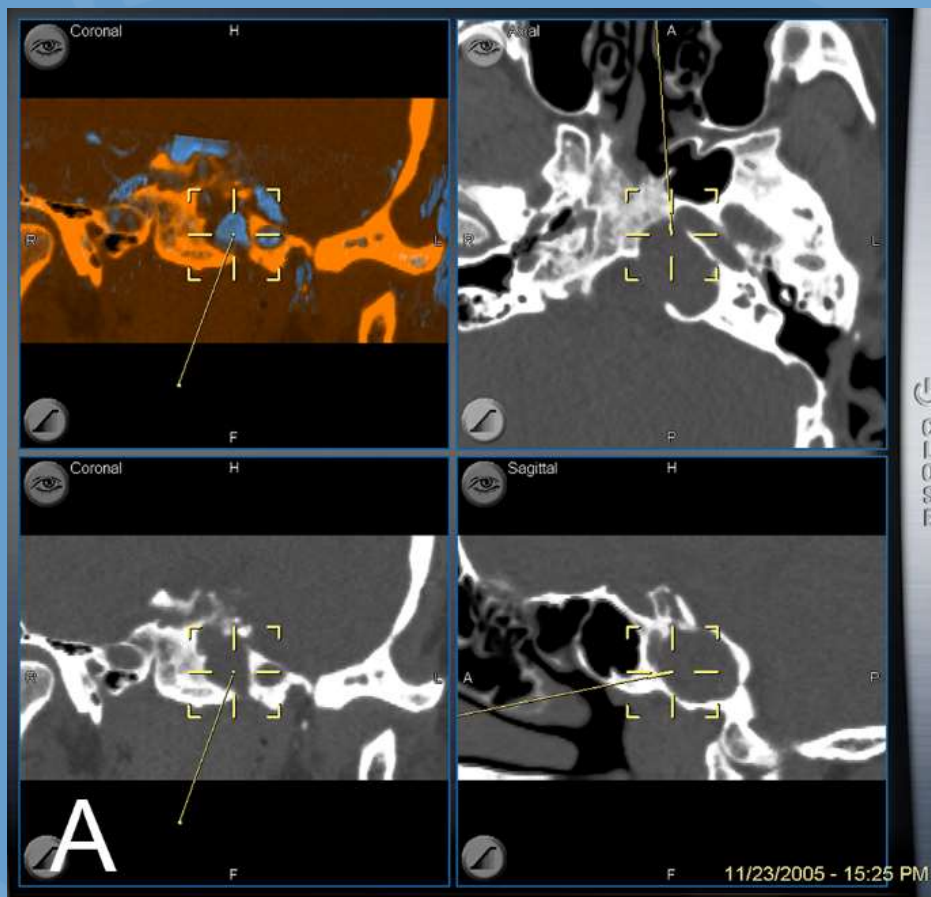
Paranasal sinuses	Right	Left
Maxillary	0, 1, 2	
Anterior Ethmoid	0, 1, 2	
Posterior Ethmoid	0, 1, 2	
Sphenoid	0, 1, 2	
Frontal	0, 1, 2	
Ostiomeatal complex	0* or 2*	
Total points to each side		

0 = no abnormalities; 1 = partial opacification; 2 = total opacification

0* = not occluded and 2* = occluded

Score range: 0-24

IGS SYSTEMS

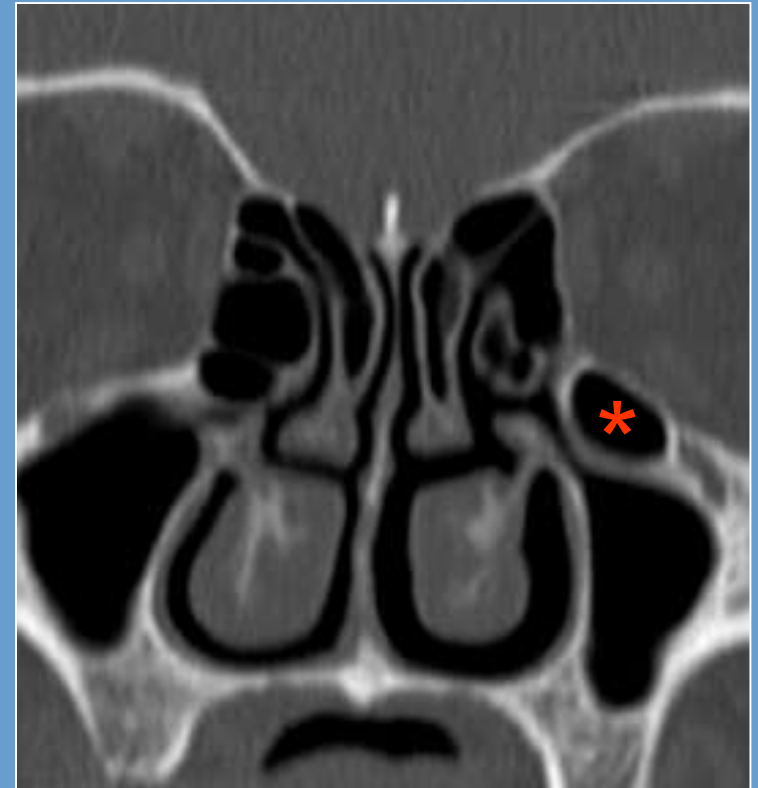


ANATOMIC VARIANTS

- Haller cell
- Concha bullosa
- Paradoxical middle turbinate
- Lateralized middle turbinate
- Atelectatic uncinata
- Pneumatized uncinata
- Nasal septum deviation

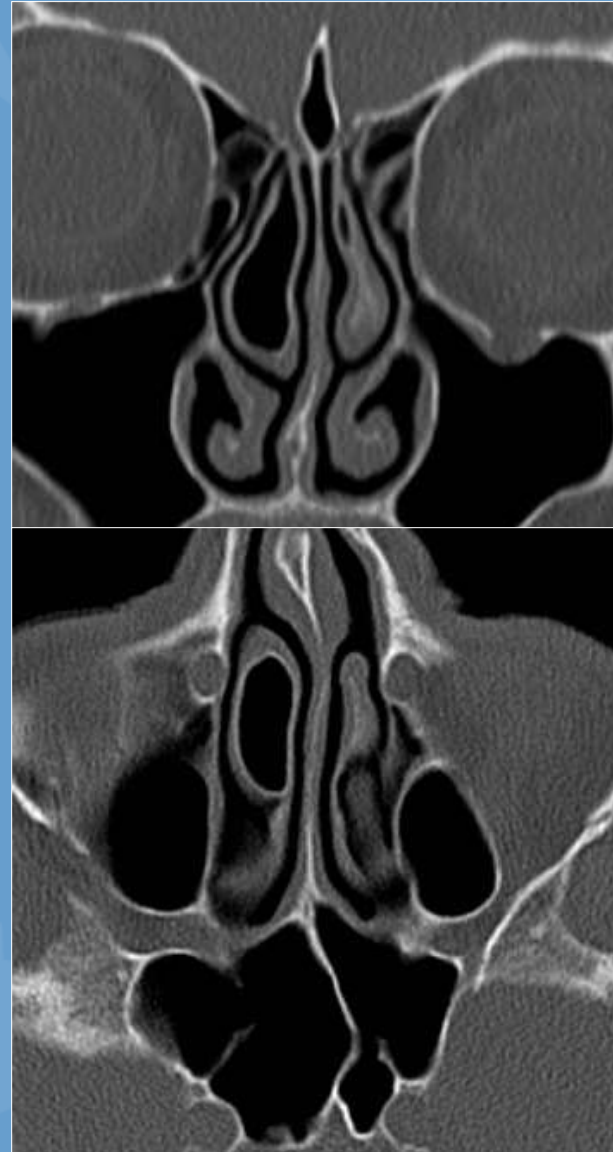
HALLER CELL

- AKA infraorbital ethmoid cell
- Incidence ~20%
- Air cell extending along the medial floor of the orbit
- Can become infected
- Can narrow infundibulum or maxillary sinus ostium
- May lead to inadvertent entry into the orbit



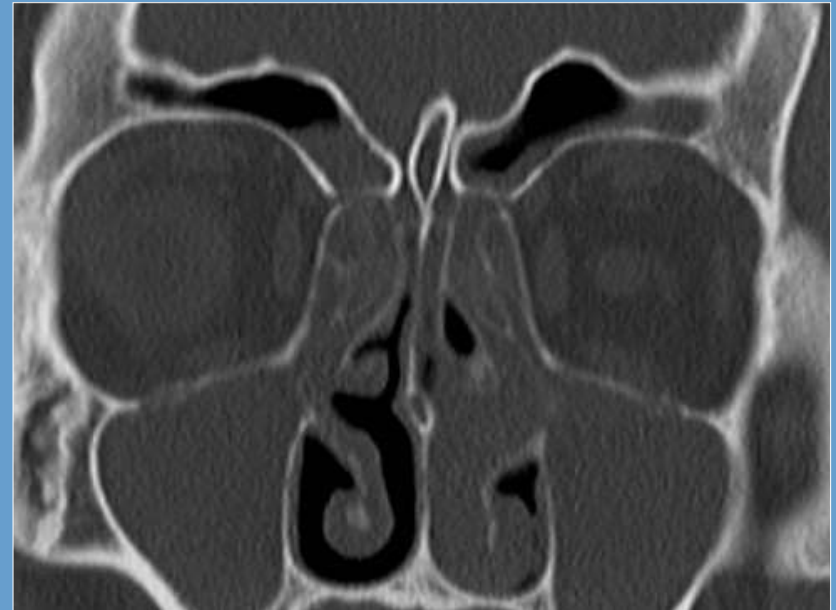CONCHA BULLOSA

- Pneumatized turbinate (usually MT)
- Incidence ~35%
- May obstruct middle meatus when large
 - Can interfere with FESS
- Can also become infected

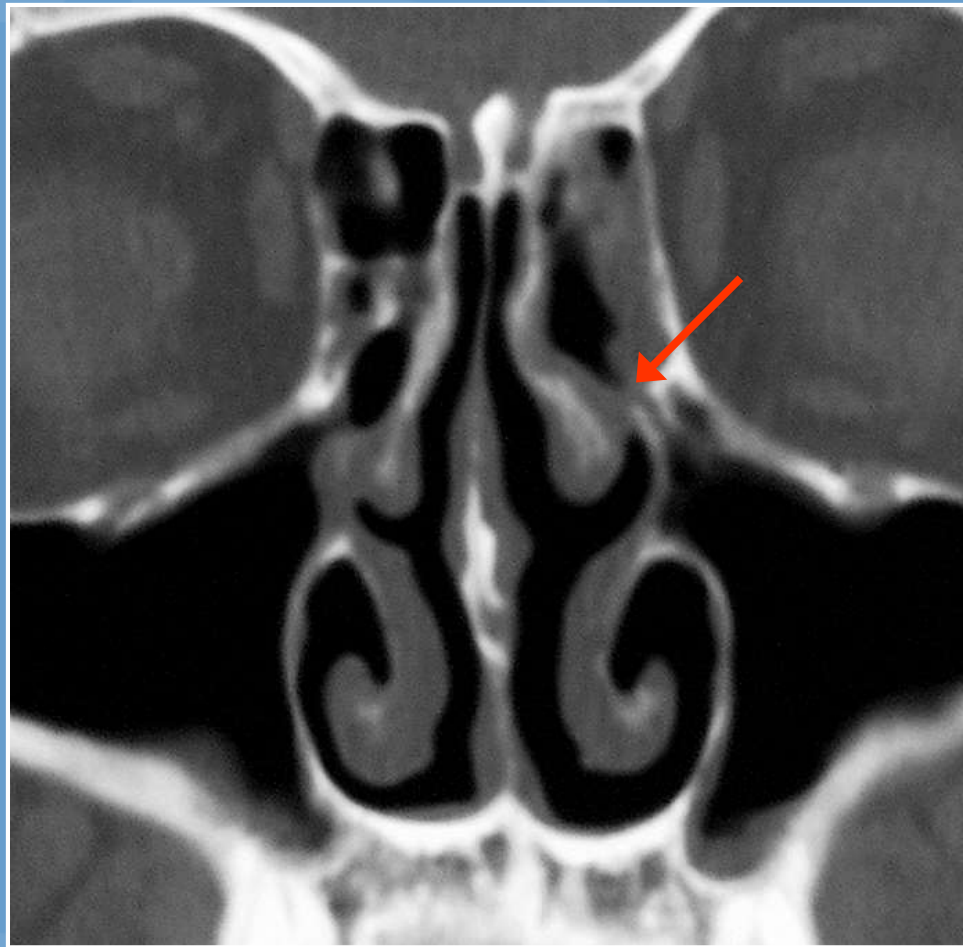


PARADOXICAL MIDDLE TURBINATE

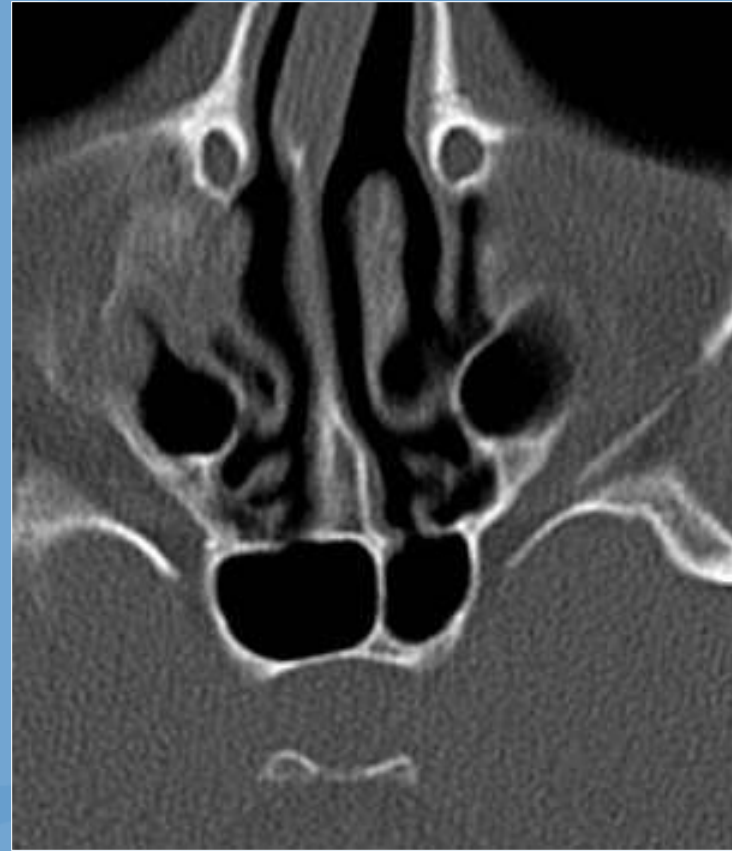
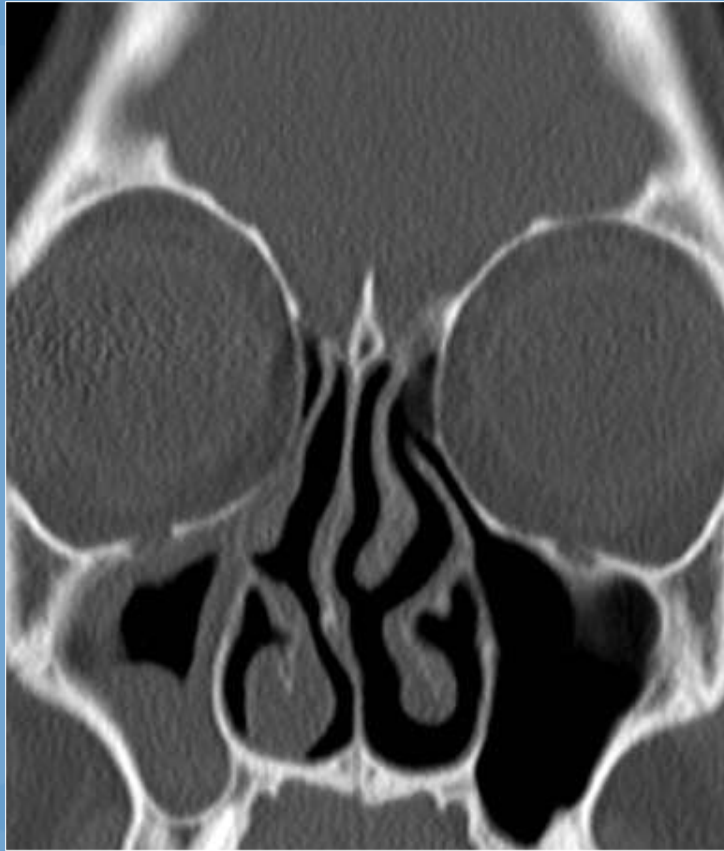- Normal MT convexity directed medially
- Controversy exists as to whether paradoxical MT increases likelihood of sinusitis

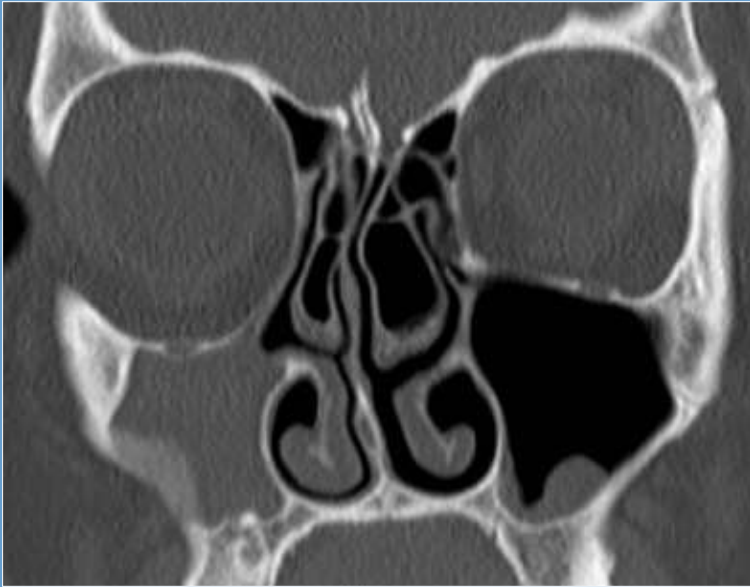


LATERALIZED MT



LATERALIZED MT AND ATELECTATIC UNCINATE





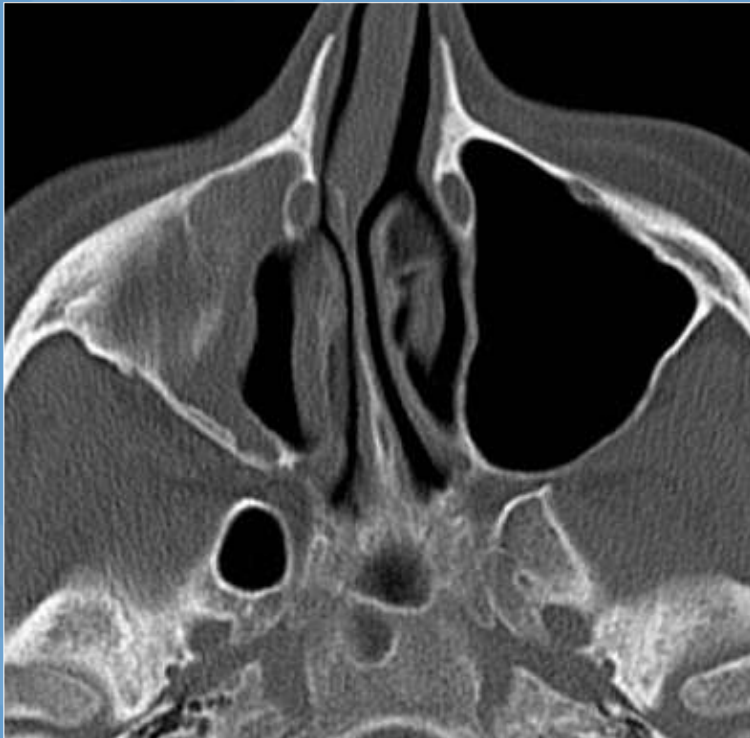
What is the diagnosis?

A) Maxillary sinus mucocoele

B) Antrochoanal polyp

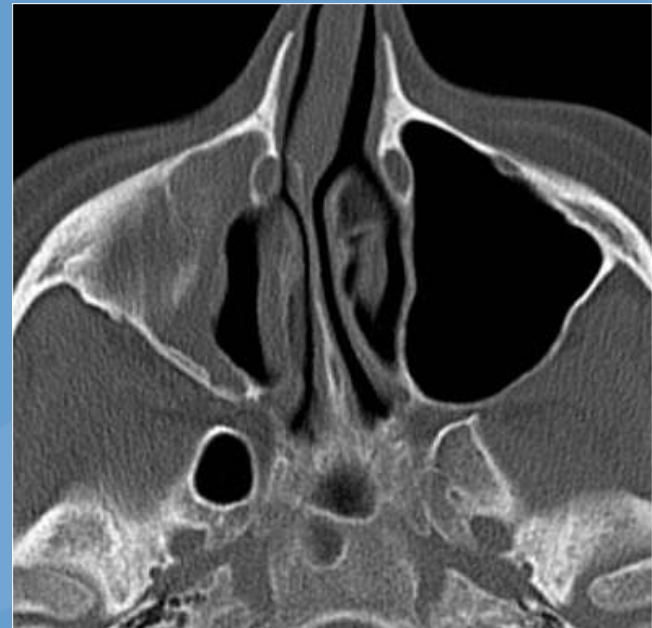
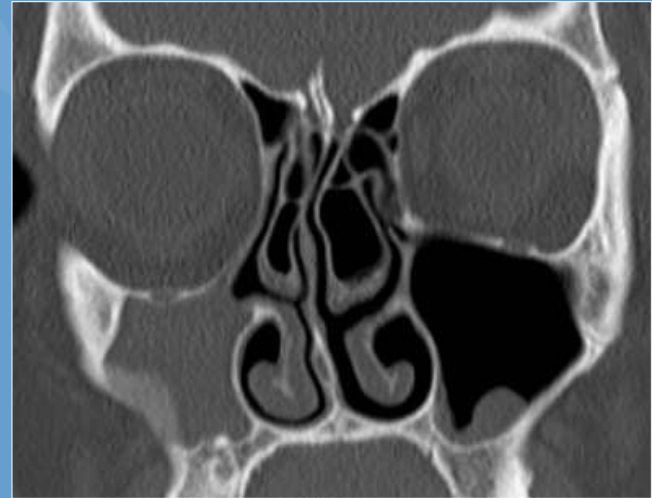
C) Silent sinus syndrome

D) Orbital blowout fracture

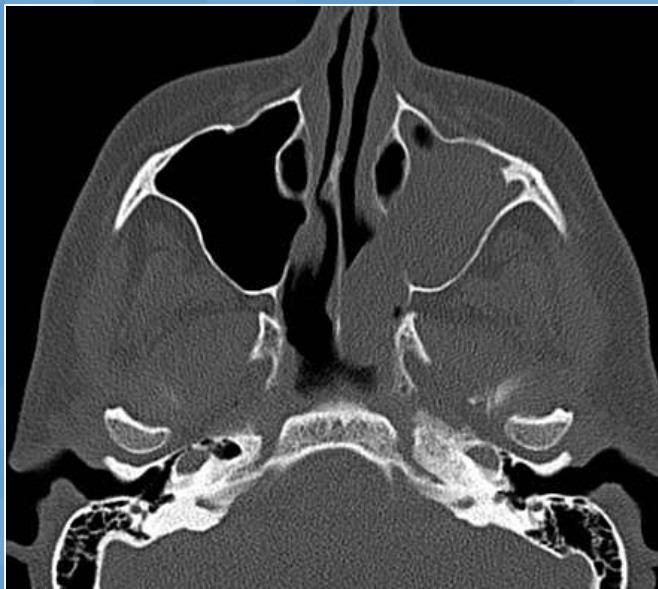
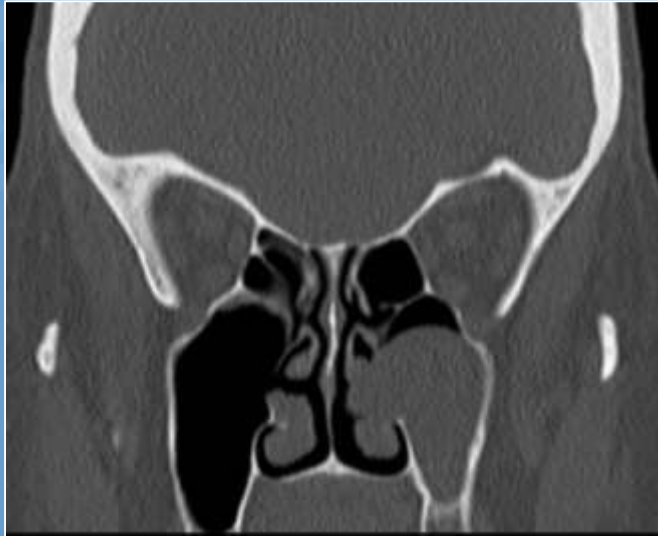
SILENT SINUS SYNDROME

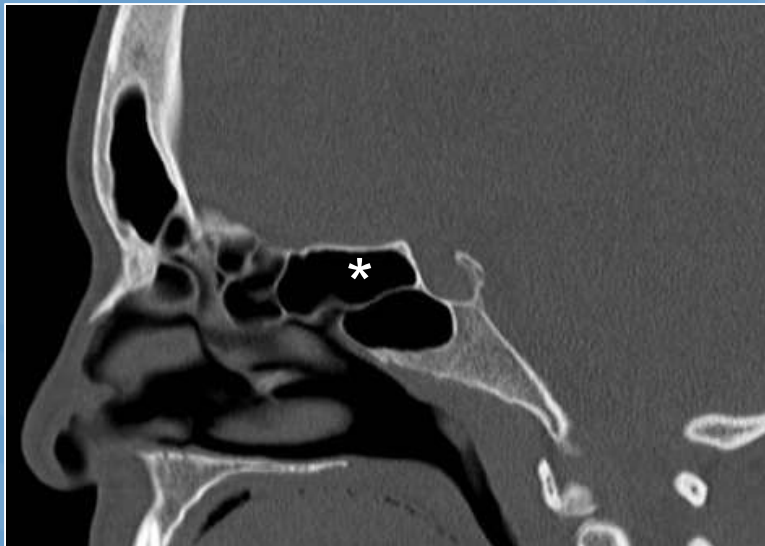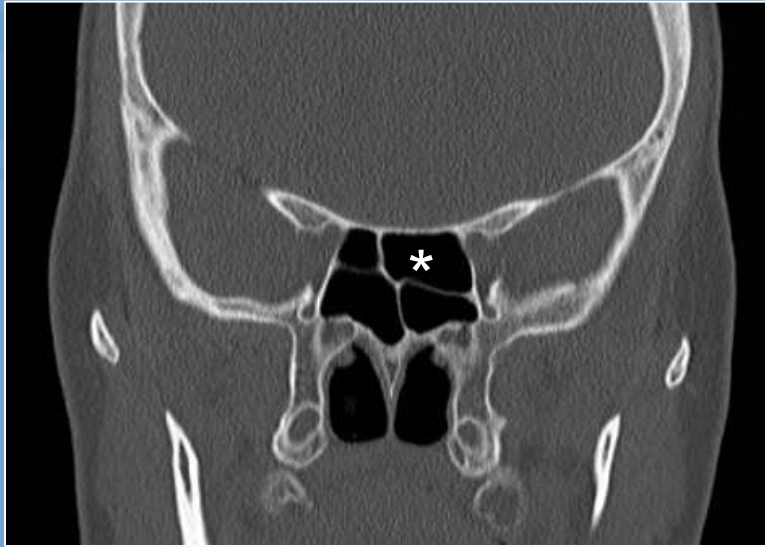- “Imploding antrum”
- Chronic maxillary outflow tract obstruction
- Negative pressure causes shrinking of maxillary sinus
- UP is atelectatic
- Causes painless enophthalmos



ANTROCHOANAL POLYP



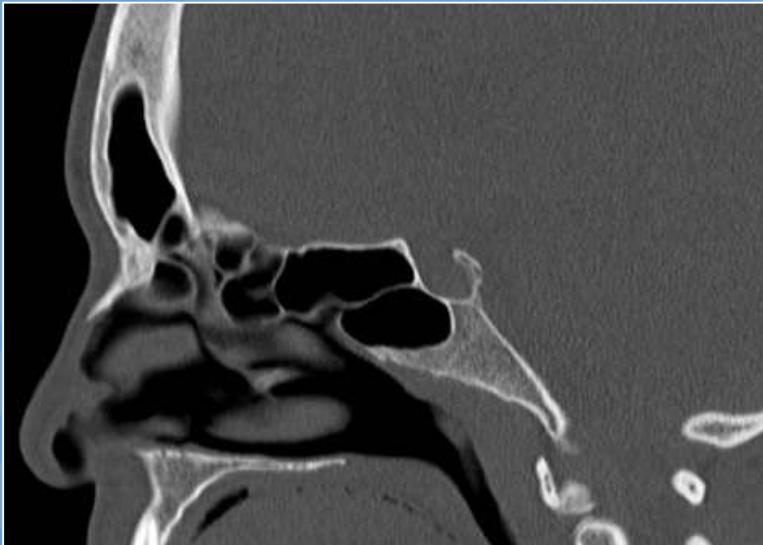
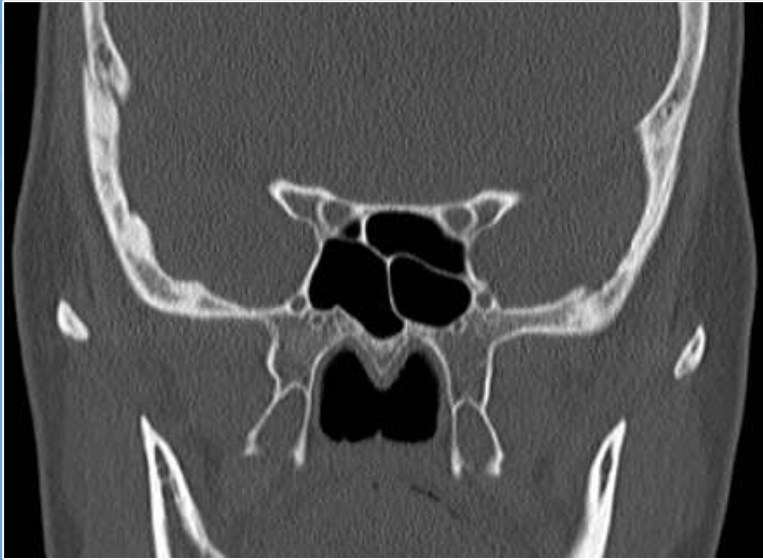- Solitary polyp arising in maxillary sinus and passing through maxillary ostium or accessory ostium
- Extends into nasal cavity and nasopharynx
- Mucin density
- Widens maxillary ostium



Name the structure indicated by the asterisk:

- A) Sphenoid sinus
- B) Onodi cell
- C) Ethmoid bulla
- D) Suprabullar cell

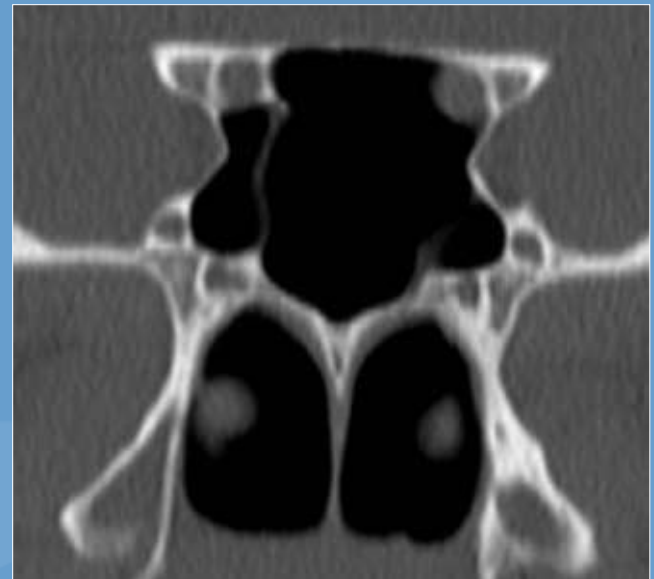
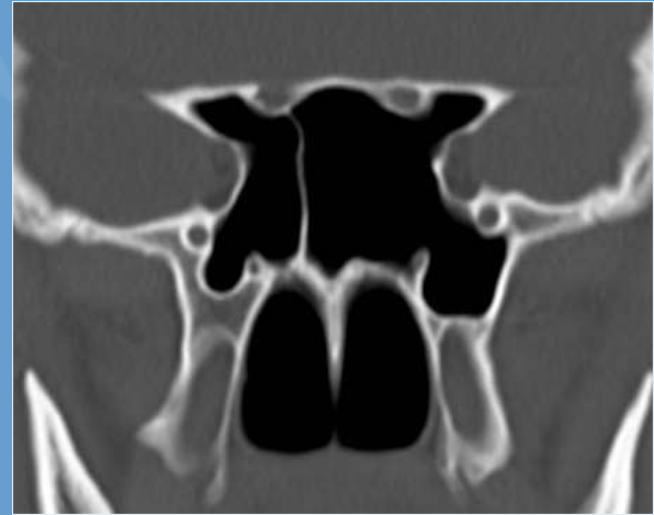ONODI CELL



- AKA sphenoethmoidal air cell
- Ethmoidal cell lying superior or posterior to the sphenoid sinus
- Incidence ~10%
- May be located close to the ON or ICA
 - Potential for injury to either during FESS

SPHENOID REGION VARIANTS

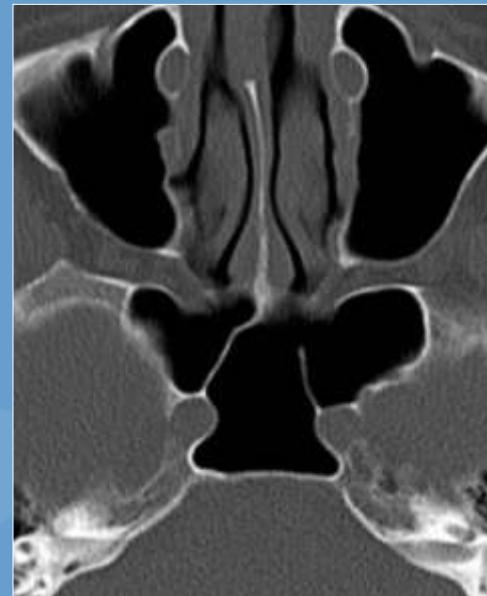
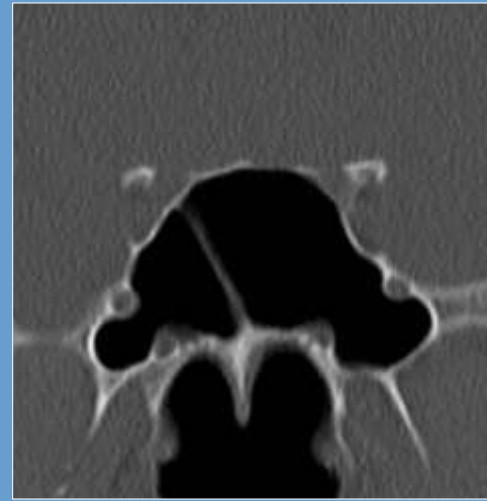
- Onodi cell
- Large lateral recess
- Anterior clinoid pneumatization
- Dehiscent nerves or ICA
- Septal insertion on the ICA or ON canal



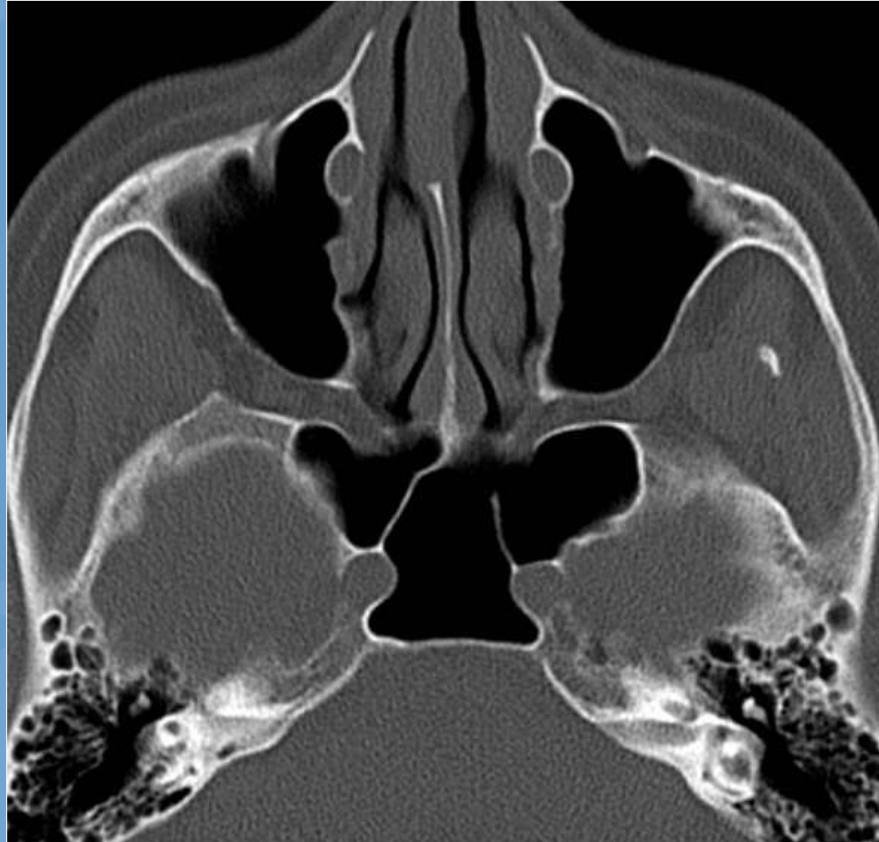MEDIALIZED CAROTID ARTERIES

SPHENOETHMOIDAL RECESS

- Superior turbinate
- Posterior ethmoids
- Sphenoid ostium
- Optic nerve
- Foramen rotundum
- Vidian canal
- Carotid canal

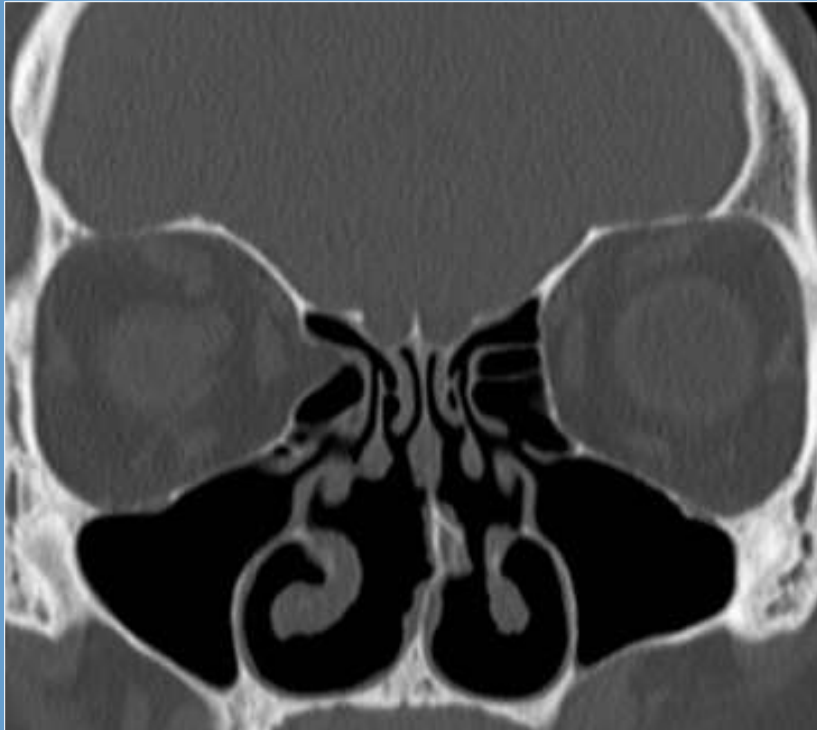


OTHER FINDINGS PREDISPOSING TO SURGICAL COMPLICATIONS

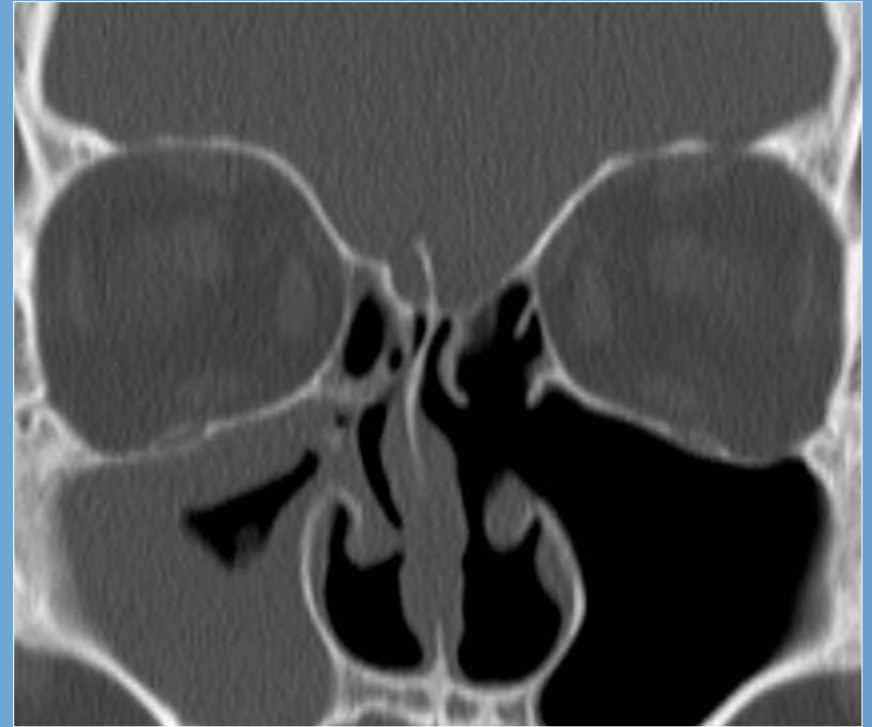


Medialized carotid arteries & septal insertion on the carotid canal

OTHER FINDINGS PREDISPOSING TO SURGICAL COMPLICATIONS

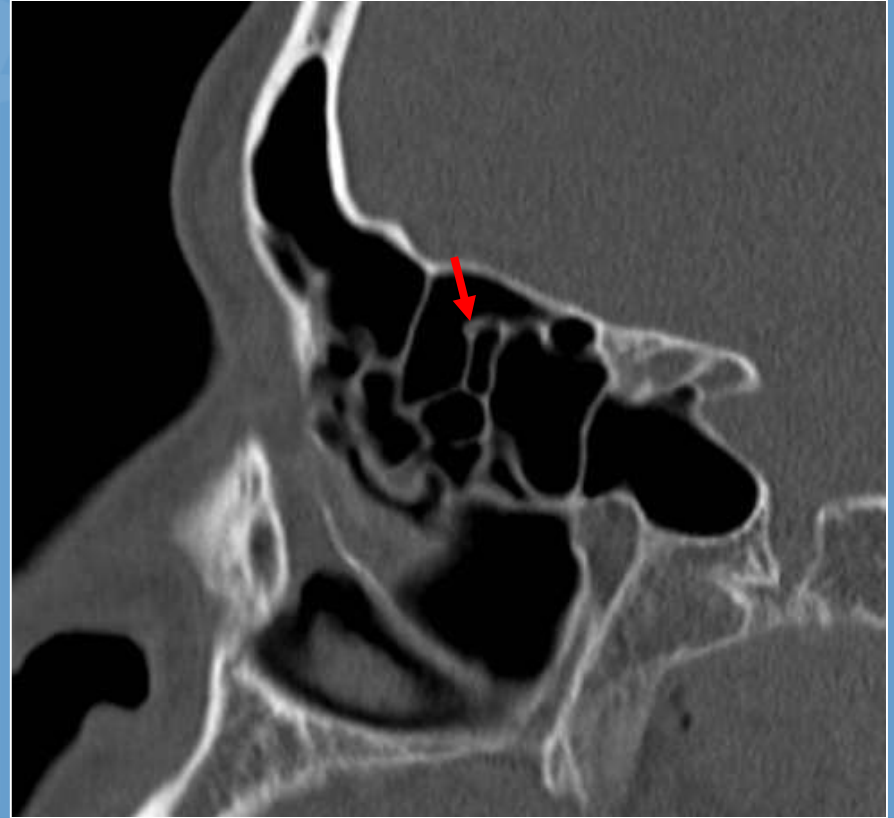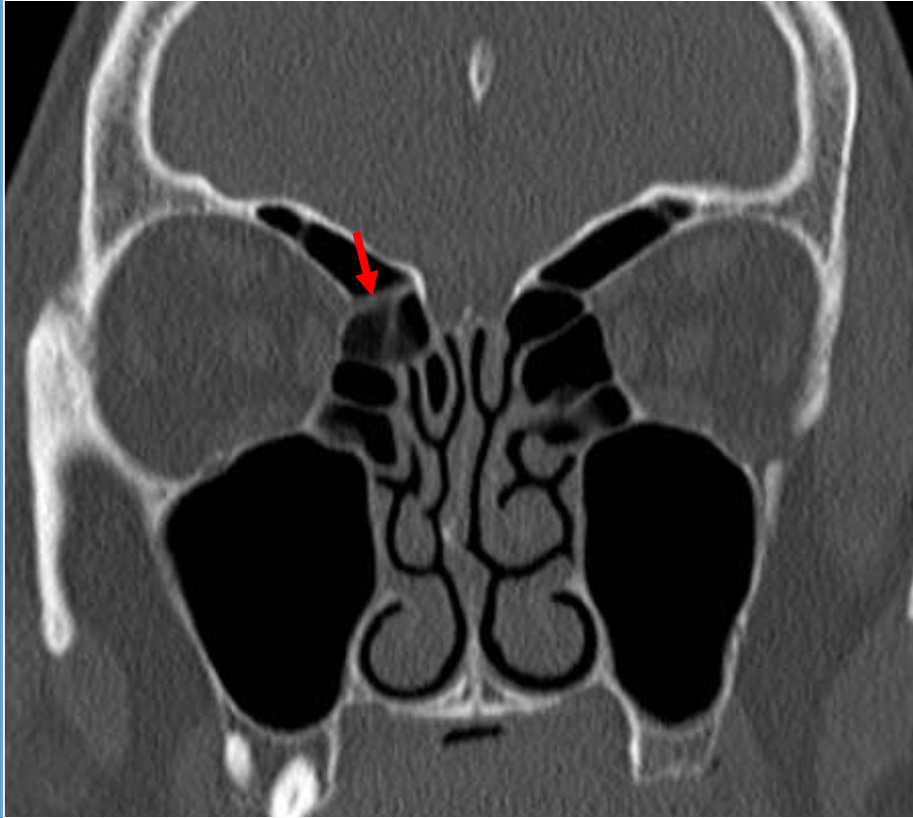


Lamina papyracea dehiscence



Asymmetry in ethmoid roof height

OTHER FINDINGS PREDISPOSING TO SURGICAL COMPLICATIONS



Low lying anterior ethmoidal artery canal

CONCLUSION

- Normal drainage pathways
 - OMC – Maxillary & anterior ethmoids
 - Frontal recess – Frontal sinus
 - Sphenoethmoidal recess – Sphenoid & posterior ethmoids
- Anatomic factors that may alter sinus drainage or affect surgical procedure
- Potential surgical pitfalls

CONCLUSION

What to include in your reports:

- Prior surgeries
- Status of individual sinuses and their drainage pathways
- Potential causes of obstruction including variant anatomy
- Bony changes (osteoneogenesis, dehiscence)
- Anatomic factors which might influence surgery
- Complications and other findings