



Fig.99.1, 99.2 & 99.3: *Columba livia* (rock dove, from which the domestic pigeon, then known as carrier pigeon, were obtained by progressive selection).

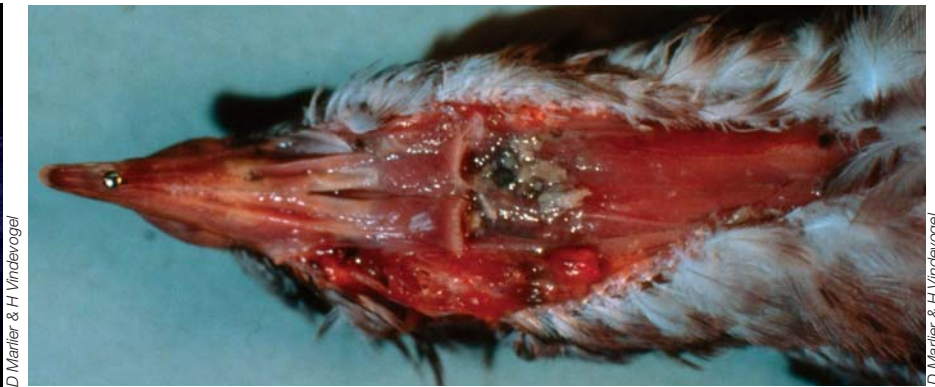

Fig.99.4: Herpetic coryza: grayish yellow wattles.

Fig.99.5: Herpetic coryza: closure of the cleft palate, back of the palate congested; diphtheroid pharyngitis.

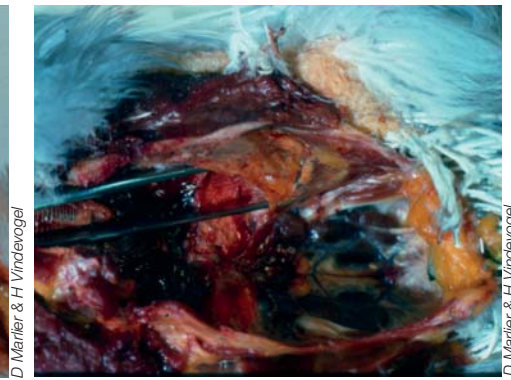
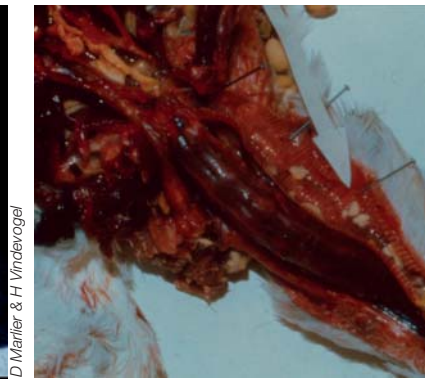


Fig.99.6: Sinusitis in chronic respiratory disease: herpesvirus and *Staphylococcus* infection.

Fig.99.7 & 99.8: Chronic respiratory disease: herpesvirus and *Escherichia coli* infection. Obstruction of the trachea by a caseous plug (left) and chronic airsacculitis (right).

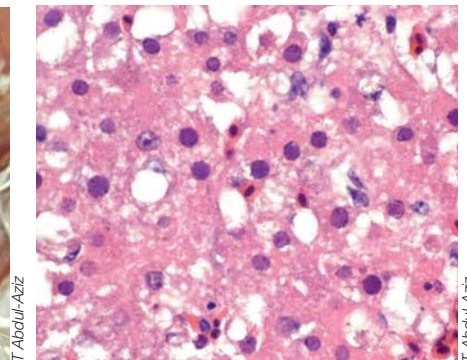
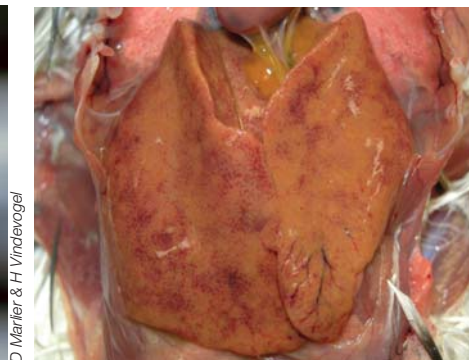

Fig.99.9: Chronic respiratory disease (owl's head). Herpesvirus and *Pasteurella septica* infections.

Fig.99.10 & 99.11: Herpetic hepatitis (three-week-old pigeon). Macroscopic and microscopic lesions.

Section VI

99. DISEASES OF PIGEON

INTRODUCTION

The homing pigeon or domestic pigeon (*Columba livia*) belongs, as well as nearly 300 other species, to the *Columbidae* family. In Europe, this family is represented by five distinct species: two species of doves: *Streptopelia turtur*, *S. decaocto*, and three species of pigeons: *Columba palumbus*, *Columba oenas* and *Columba livia* (rock dove, from which the domestic pigeon and subsequently the carrier pigeon were obtained by progressive selection). The latter is a full-fledged athlete receiving veterinary care as if it were a priced racehorse. Indeed, some can fetch top dollars on the market.

As for all species, diseases of pigeons may be of biological (viral, bacterial, parasitical and fungal) and non-biological (mechanical, physical, chemical, nutritional, genetic, *etc.*) origins. In this chapter, only recent data on «new» clinical entities (infections caused by herpesviruses, adenoviruses, circovirus, and *Streptococcus gallolyticus*), and on current problems associated with the emergence of resistance to conventional treatments for trichomoniasis and respiratory diseases will be presented in details.

VIRAL DISEASES

Herpesvirus infection (coryza)

The *Columbid herpesvirus 1* (CoHV-1), or pigeon herpesvirus, is part of the subfamily *Alphaherpesvirinae*, genus *Mardivirus* (close to the herpesvirus of Marek's disease). This virus was first associated with the clinical syndrome «conjunctivitis, nasopharyngitis» or coryza. This condition is the leading cause of counter performances in carrier pigeons and of stunting in meat pigeons. In Europe, pigeons are the natural hosts of this infection with a prevalence of over 50 percent. In fact, the CoHV-1 is present in 60% of dovecotes where respiratory diseases are observed and it can be isolated in 82% of pigeons suffering from acute coryza. Transmission occurs especially during the force-feeding of squabs after hatching (they are protected by maternal antibodies but will become latent carriers) or by contact (between pigeons or with other susceptible birds). Following recovery, affected pigeons become latent carriers and may shed the virus again, thus maintaining the infection.

Clinical expressions of herpesvirosis in pigeons may be acute (frequent sneezing, conjunctivitis, obstruction of the nostrils, wattles normally white turning yellow-gray) or chronic (sinusitis and intense dyspnea associated with severe secondary bacterial infections). Hence, coryza may have two clinical presentations: wet and dry coryza. The latter is more difficult to detect. The clinical signs observed with wet coryza are sneezing, scratching of nostrils and greyish or yellowish wattles and conjunctivitis. The oral, pharyngeal and laryngeal mucosae are congested and can be dotted with small whitish necrotic foci which can expand and ulcerate. Nasal discharge is abundant and forms crusts that may obstruct the nostrils. In the beak, the nasal discharge dries out because of the airflow and forms yellowish false membranes that do not adhere to the mucosa. With dry coryza, pigeons do not have nasal discharge, but only frequent yawning associated with poor athletic performances. Wattles remain white. The nose has an increased sensitivity when pinched with fingers, resulting in sneezing. The throat is glairy and the mucosae are inflamed. The tear duct is often blocked. In many cases, secondary bacterial complications with *Staphylococcus intermedius* (72%), *Pasteurella multocida* (17%), *Escherichia coli* (9%) and *Streptococcus* β hemolytic (2%) develop and can cause sinusitis and, in some cases, chronic respiratory diseases.

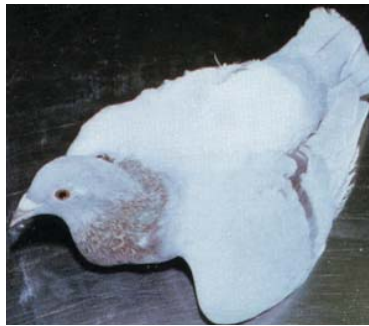Gross lesions are characterized by necrotic damage to the upper respiratory tract and liver. Eosinophilic intranuclear inclusion bodies are observed in the epithelium of affected organs; in the liver, pancreas and brain in cases of generalized infection. The acute form must be differentiated from Newcastle disease (pneumotropic and lentogenic strain) and the chronic form from the diphtheroid form of fowlpox. It is possible to immunize pigeons with a herpesvirus vaccine either attenuated or inactivated with adjuvant to prevent the onset of clinical disease or viral shedding in infected birds in order to limit viral dissemination. However, vaccination will not prevent birds from becoming carriers of the pathogen.

In owls or hawks, CoHV-1 infection does not cause specific clinical signs but a histological examination shows characteristic lesions of hepatosplenitis with necrosis associated with eosinophilic



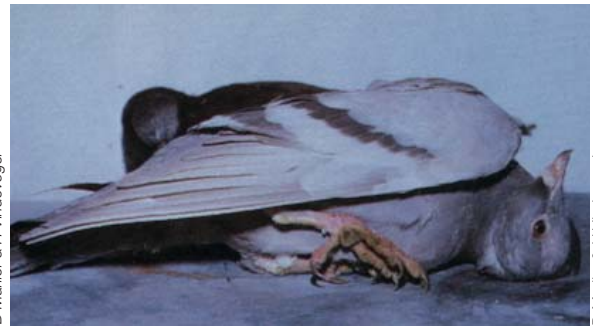D Marlier & H Vindvogel

Fig.99.12: Paramyxovirus (PMV1). Torticollis.



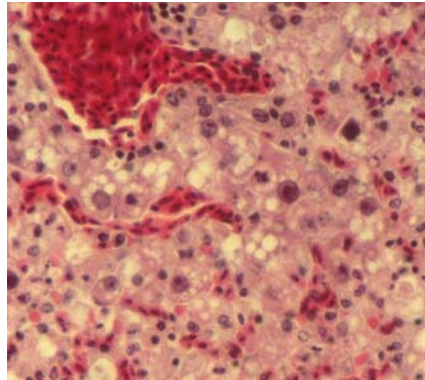
D Marlier & H Vindvogel

Fig.99.13: Paramyxovirus (PMV1). Paralysis of the wings.



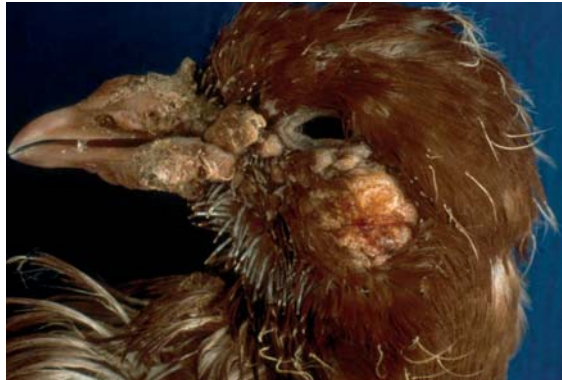D Marlier & H Vindvogel

Fig.99.14: Paramyxovirus (PMV1). Balance disorder.



LDA 22

Fig.99.15: Adenovirus type II (Pigeon). Hepatic necrosis, intranuclear basophilic inclusion bodies (HES × 400).



LDA 22

Fig.99.16 & 99.17: Pigeon pox (cutaneous form). Crusts on the eyelids and beak.

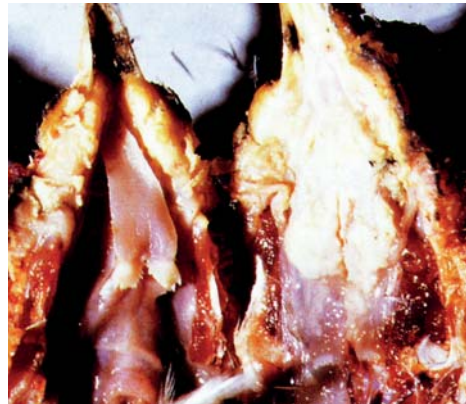

LDA 22



Dnev - Ceva Santé animale

Fig.99.18: Pigeon pox (cutaneous form).



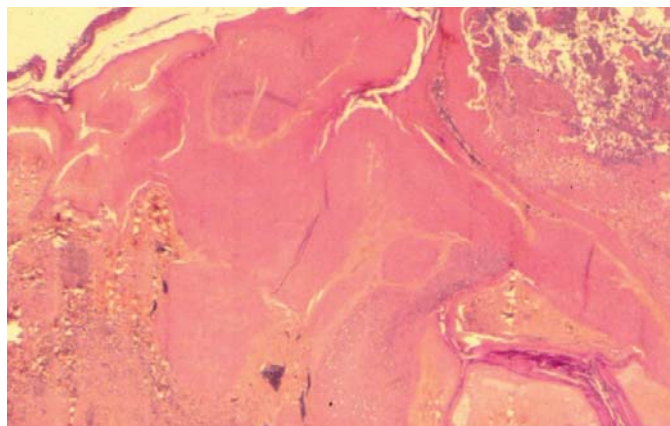
D Marlier & H Vindvogel

Fig.99.19: Diphtheroid form of pigeon pox. Yellowish membranes in the oral cavity.



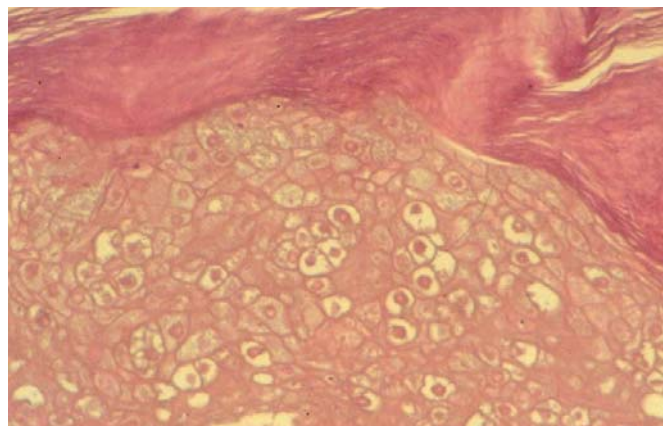
D Marlier & H Vindvogel

Fig.99.20: Sequelae of pigeon pox after a fracture of the lower mandible of the beak.



LDA 22

Fig.99.21: Pigeon pox (skin). Hyperplasia and necrosis of the skin epithelium (HES × 25).



LDA 22

Fig.99.22: Pigeon pox (skin). Ballooning cells and intracytoplasmic inclusion bodies (HES × 400).

intranuclear inclusion bodies. The susceptibility of raptors to this herpesvirus of pigeons justifies not including pigeons in their diet when they are kept in captivity.

The usual therapeutic approach is to assess whether there might be parasitic or bacterial complications, and to adjust the therapy accordingly. No CoHV-1 specific vaccine is currently available. Currently in the field, treatments are often applied in such a way as to contribute to the development of resistant bacterial strains, which may result in significant therapeutic failures. Antibiotic and anti-parasitic treatments should be reserved for sick pigeons only and their judicious application should be according to regulations.

Paramyxovirosis

Paramyxoviruses are classified into several types, with type 1 (PMV1) being the virus of Newcastle disease (ND). Between 1971 and 1973, a ND epidemic due to a velogenic PMV1 virus devastated the European poultry industry. The virus was identified in pigeons with respiratory, digestive and nervous signs. Then in 1980, lentogenic strains of PMV1 were isolated from pigeons presenting only respiratory signs associated with poor athletic performances. Later, viscerotropic and neurotropic mesogenic strains caused more severe clinical problems (tremors, torticollis, paralysis, balance and vision problems). Morbidity ranged from 30 to 70% while the mortality rate remained low (less than 10%). Vaccination is the only way to control the disease. Live attenuated vaccines should not be used in pigeons because they do not effectively protect (only a low level of local immunity develops) which requires the use of inactivated vaccines, preferably in an aqueous adjuvant.

Highly pathogenic avian influenza virus (HPAI)

Pigeons are also susceptible to the orthomyxoviruses of HPAI. When infected, they have nervous, respiratory and/or digestive problems.

Adenovirus

The family *Adenoviridae* includes the genera *Mastadenovirus* and *Aviadenovirus*, the latter including three serogroups. Pigeons are susceptible to certain chicken adenoviruses (serogroup I) (isolation is possible in cell culture) and to a specific pigeon adenovirus that has not been characterized to date because it is not yet possible to grow this virus in culture. Adenovirus infections of pigeons

are known since 1976 but gained significant importance since 1993-1994. In pigeons, adenovirus infections are responsible for two different clinical conditions known as adenovirus type I (classical adenovirus) and type II (necrotic hepatitis). These types refer only to clinical signs and gross lesions and not to antigenic types.

Clinically, adenovirus type 1 affects almost exclusively birds that are less than one year old (mainly 3-5 months). Very liquid diarrhea with vomit, severe weight loss and overall very poor body condition are observed. The infection spreads rapidly in the pigeon house and after a few days, all the young pigeons are affected. In general, the mortality rate is low, with recovery taking place within one to two weeks. However, athletic performances remain below normal for several weeks. In most cases, this form of adenovirus is complicated by bacterial infections, particularly *Escherichia coli*. In this case, the diarrhea becomes putrid. The duration of the disease increases and some pigeons die (sometimes up to 40%). The adenoviruses type 1 should be suspected on the basis of the occurrence of diarrhea and vomiting in almost all the squabs mainly between March and July. The differential diagnosis must include paramyxovirosis, salmonellosis, trichomoniasis and hexamitiasis. At necropsy, there is an acute hemorrhagic to fibrinous duodeno-jejunitis and often an intense diffuse hepatitis. Confirmation of the diagnosis is done by histopathological examination with the observation of intranuclear inclusion bodies in hepatocytes and enterocytes.

In adenovirus type II, pigeons of all ages (from 6 days to 6 years) can be affected. Generally there are only few clinical signs: the pigeon curls up into a ball and die within 24 to 48 hours; very rarely, vomiting or liquid yellowish droppings are present. New cases are observed sporadically over a period of six weeks to two months. In the pigeon house, the overall mortality ranges from 30% to 70%. The most common observation is that, in the same pigeon house, some pigeons die suddenly while others are in perfect health. The differential diagnosis of adenovirus type II must include salmonellosis, streptococcosis and poisoning. At necropsy, the main lesion is an intense necrotic hepatitis. Confirmation of the diagnosis is made by histopathological examination of the liver showing extensive areas of necrosis with the presence of eosinophilic intranuclear inclusion bodies. Using transmission electron microscopy, paracrystalline arrays of icosahedral viral particles are observed in the nucleus of hepatocytes and enterocytes.

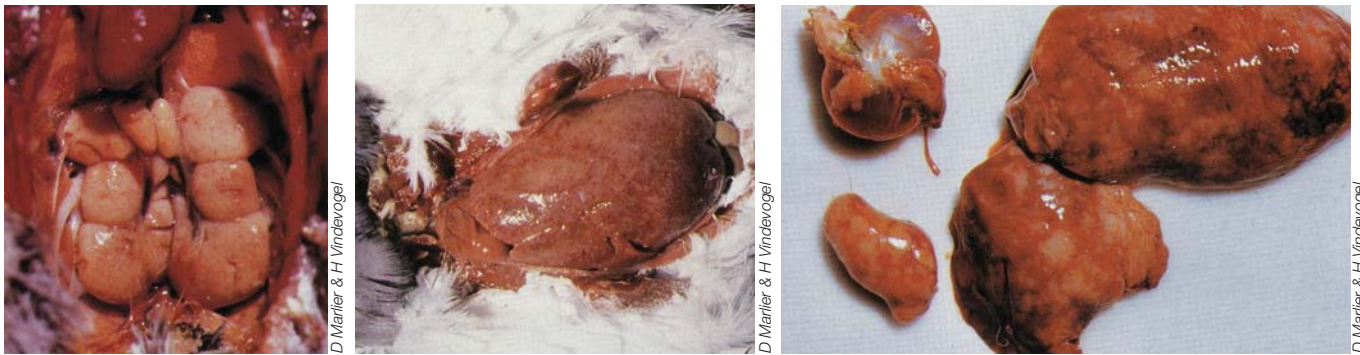


Fig.99.23, 99.24 & 99.25: Leucosis: renal tumors (left), diffuse hepatic lymphomatosis (middle), lymphomatosis of the liver and the spleen (right).

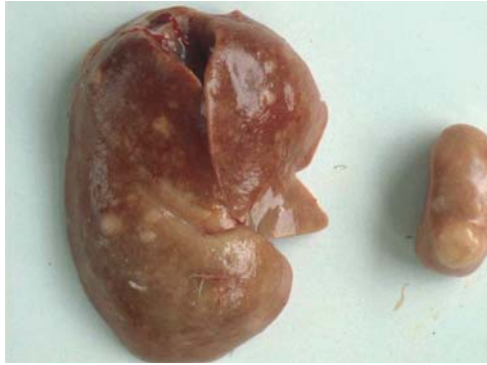


Fig.99.26: Renal neoplasia.

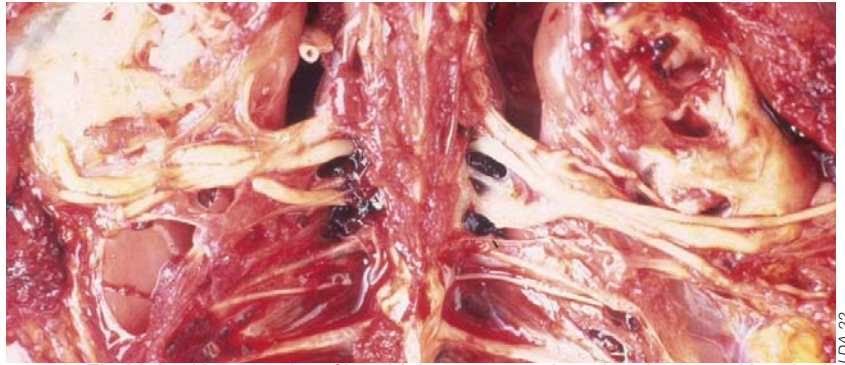

Fig.99.27: Hypertrophy of brachial nerves may be related to a nutritional origin (riboflavin deficiency?), pigeon being refractory to Marek's disease.

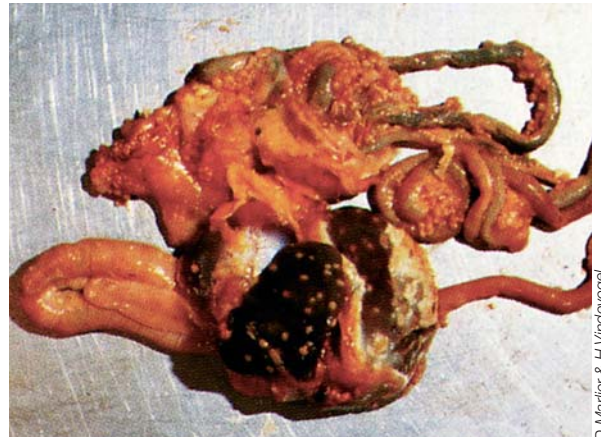
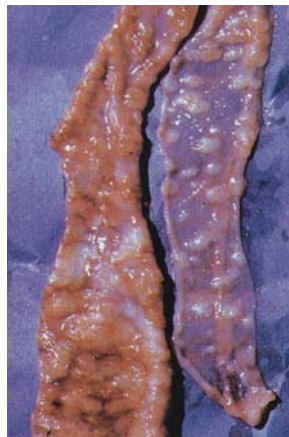
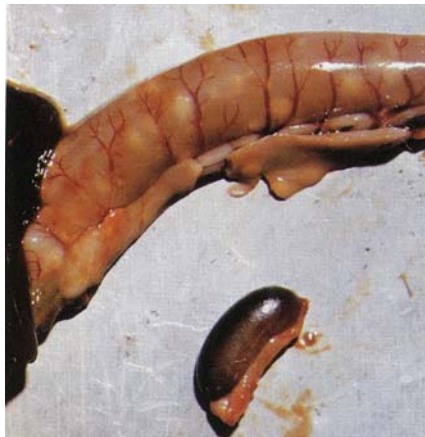Fig.99.28, 99.29 & 99.30: Salmonellosis (*Salmonella Typhimurium*). Enlarged spleen, transversal ulcers visible by transparency in the duodenal loop, abscesses in the pancreas (left). Intestinal mucosal dotted with many transversal ulcers (middle). Multiple foci in the liver (right).

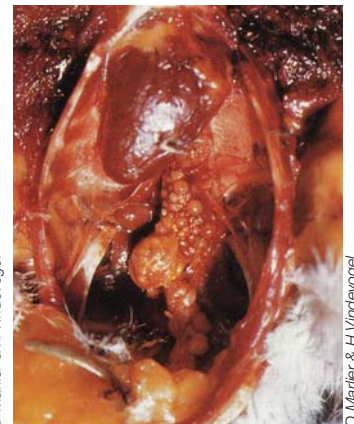
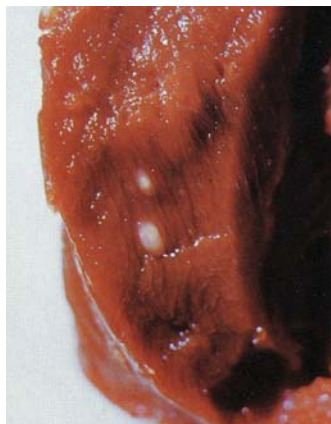

Fig.99.31, 99.32 & 99.33: Salmonellosis (*Salmonella Typhimurium*). Abscesses in the pectoral muscle (left). Humero radio-ulnar arthritis (middle). Oophoritis: caseous pedunculated follicles (right).

Section VI

There is no specific treatment for adenovirus; the use of vaccines against EDS76 in chickens does not help, since the adenovirus associated with this disease belongs to group III.

Circovirus

The presence of viral particles morphologically similar to circoviruses has been described in 1993 in the United States. This virus infects squabs before the normal involution of the bursa of Fabricius, which is between the ages of five to six months; but viral particles have been found in the bursa as early as four weeks and as late as one year of age. The transmission of the infection is primarily horizontal via droppings but vertical transmission cannot be excluded. The bursa of Fabricius may be the portal of entry into the host for the virus. The virus is highly immunosuppressive and has a tropism for primary and secondary lymphoid organs. The clinical expression of the disease is highly variable, from asymptomatic to 100% mortality depending on secondary infections. Often vaccine failures are observed in particular when vaccinating against PMV1 infections. Generally, morbidity is significant, but mortality is limited, although squabs are in very poor general condition. Unlike the circovirus of parrots (Psittacine Beak and Feather Disease), feather and beak lesions are very rare. Diagnosis is made at necropsy, with the bursa appearing enlarged or atrophied depending on the stage of the disease. Diagnostic confirmation is obtained by observing basophilic intracytoplasmic inclusion bodies in the bursa of Fabricius or by the observation of paracrystalline arrays of non-enveloped virions by transmission electron microscopy. There is no specific treatment or vaccine.

Poxvirus

The pigeon poxvirus is transmitted primarily by contact. Pigeon pox is frequently encountered in squabs, either as a cutaneous epithelioma or in its diphtheroid form. Control is achieved by vaccination (live attenuated pigeon pox virus).

Leukosis

Neoplasias of viral origin observed in pigeons involve mainly the liver, kidneys and spleen.

BACTERIAL DISEASES

There are a considerable number of bacteria that enter the body of a weakened or stressed pigeon without having any recognized etiological role. The main bacterial diseases encountered in pigeons

include chlamydiosis, salmonellosis (paratyphosis), colibacillosis, pasteurellosis, pseudotuberculosis, tuberculosis, staphylococcosis and erysipelas. The clinical expressions of these diseases are presented in other chapters. Typically, the origin of septicemia in pigeons is usually attributed to *Salmonella* Typhimurium variety Copenhagen, more rarely, *Pasteurella multocida* or *Erysipelothrix rhusiopathiae*. An identical pathogenic role is now recognized for *Streptococcus gallolyticus*.

Streptococcus gallolyticus

Streptococcus gallolyticus (previously known as *Streptococcus bovis*) is one of the few pathogenic non- β hemolytic streptococci. There are five serotypes, five biotypes and two sub-biotypes; serotypes 1 to 5 representing 25, 48, 13, 3 and 10% of the strains isolated in Belgium, respectively. The pathogenicity varies according to the serotype, serotypes 1 and 2 being by far the most pathogenic. *Streptococcus gallolyticus* is an opportunistic pathogen. This bacterium is present in the intestinal microflora of 40% of healthy pigeons and can be detected in droppings collected in 80% of pigeon houses. At necropsy, infection with *S. gallolyticus* is found in about 10% of pigeons dying of septicemia. This infection affects pigeons of all ages. Carriers do not usually develop the disease. In an affected pigeon house, *S. gallolyticus* causes sudden deaths in adult birds as well as in young pigeons in the nests. Greenish mucoid droppings are observed. Some pigeons are lamed, while others are no longer able to fly. On palpation, it is possible to detect an indurated area in one of the superficial pectoral muscles. At necropsy, septicemic lesions with the congestion of various organs are observed. An area of focal necrosis, within one or two superficial pectoral muscles, and a serous or serofibrinous liquid around the tendon of the deep pectoral muscle or of the shoulder articulation are sometimes present and would be pathognomonic. The clinical diagnosis is very difficult and must be differentiated from *Salmonella* infection. Diagnostic confirmation is obtained on the basis of gross lesions seen at necropsy and after performing additional tests: culture of cardiac blood or hepatic parenchyma on Slanetz and Bartley agar. No vaccine is available, and even autovaccines have very limited effectiveness. Treatment consists in the administration of antibiotics, the best results being obtained with ampicillin, doxycycline, erythromycin and amoxicillin. Most strains are resistant to tetracyclines and sulfamides/trimethoprim. Relapses are frequent after the end of treatment in a pigeon house.

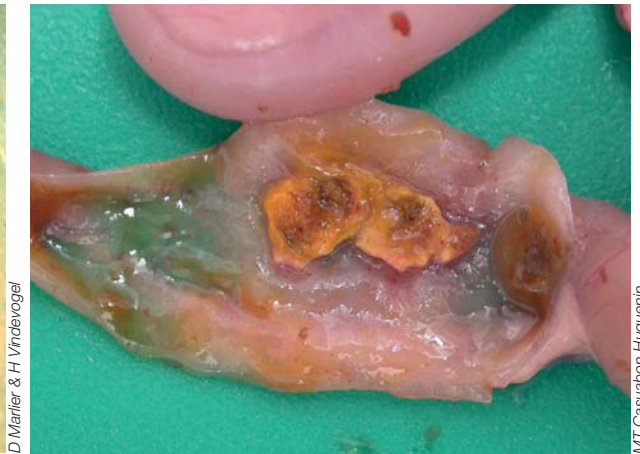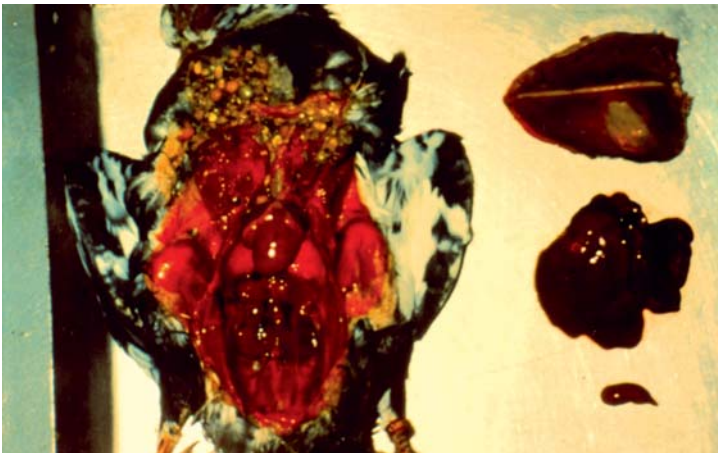


Fig.99.34: Septicemia (*S. gallolyticus*): generalized congested appearance of the cadaver, hepatomegaly and splenomegaly; area of focal necrosis in the right superficial pectoral muscle.

Fig.99.35: *Staphylococcus aureus*. Ulcerative enteritis (Pigeon).

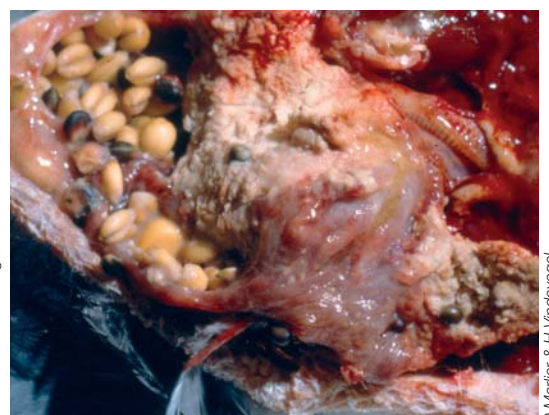
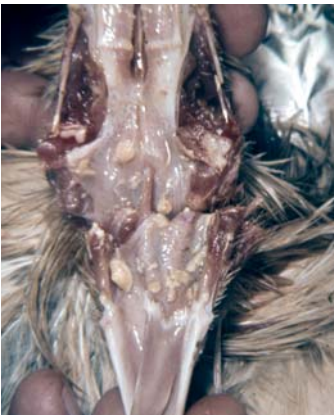
Fig.99.36: Trichomoniasis: abscess in the oral cavity.

Fig.99.37 & 99.38: Trichomoniasis: abscess in the crop.

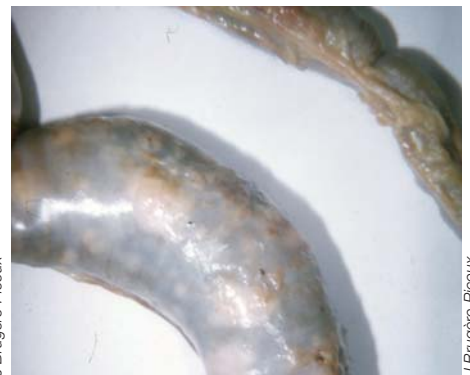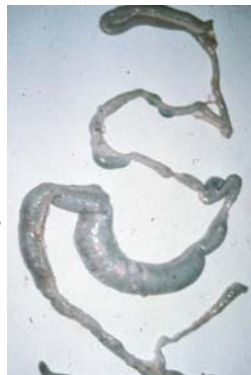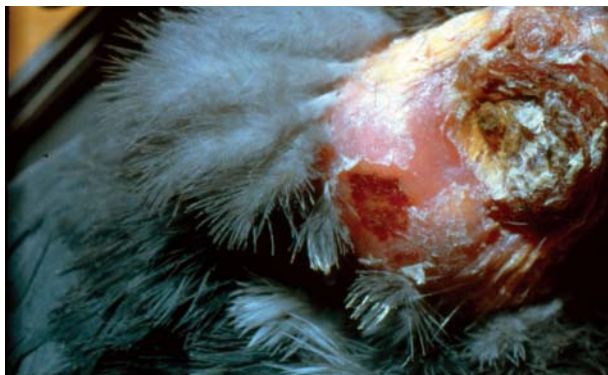


Fig.99.39: Trichomoniasis: abscess of the umbilicus.

Fig.99.40 & 99.41: Trichomoniasis has invaded the entire gastrointestinal tract.

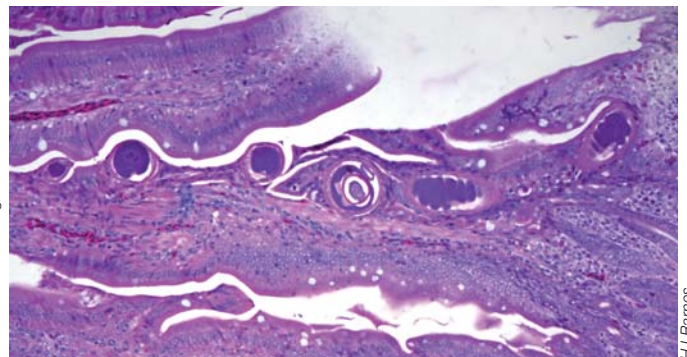
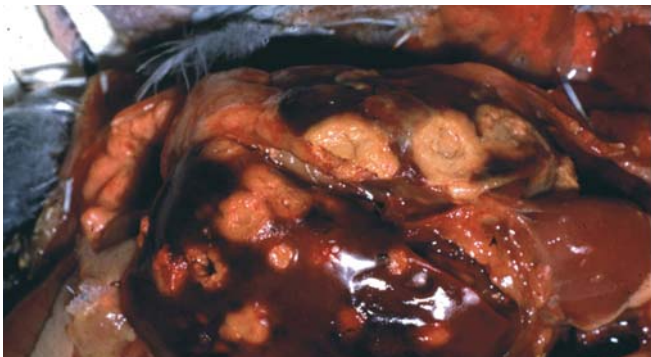


Fig.99.42: Trichomoniasis: multiple caseous abscesses in the liver.

Fig.99.43: Presence of *Capillaria* in the intestine (x 45).

PARASITIC DISEASES

Like any other poultry, pigeons can be affected by internal parasites (coccidiosis, trichomoniasis, hexamitiasis, nematodes, cestodes, trematodes) or external parasites (mites, insects) and also fungal diseases (candidiasis, aspergillosis). Although some of these parasites are specific to pigeons, only trichomoniasis, which is very common in pigeons, is presented here.

Trichomoniasis

Trichomoniasis is a parasitic disease caused by a flagellate protozoan (*Trichomonas gallinae*) that reproduces by longitudinal binary fission. Eighty percent of birds are asymptomatic carriers. This infection spreads by direct and indirect contacts; *T. gallinae* surviving several hours in water troughs. Clinical signs in adults are a sore throat, poor flight performance, and more rarely watery diarrhea. In squabs, one can also observe «oral canker» with yellow necrotic lesions of the upper digestive tract (mouth, crop and esophagus). Sometimes there is a systemic spread with involvement of the viscera including the liver with dyspnea, the birds being in very poor general condition. Infections with *T. gallinae* are one of the factors responsible for the recurrence of Pigeon herpesvirus 1 (CoHV-1) episodes in carriers of this virus.

Classically, the treatment of these infections is by oral administration of imidazole derivatives such as carnidazole or ronidazole. Usually, preventive treatments are administered during brooding and curative treatment is reserved for sick birds during periods of competition. Unfortunately in recent years, fanciers have become accustomed to apply inadequate treatments (duration of treatment too short, excessive use, doses too low) and this has

led to the selection of resistant strains and a significant increase in treatment failure. A recent survey showed that the pathogenicity of *T. gallinae* strains is highly variable. *In vitro*, only 23% of strains were highly pathogenic, 35% were moderately pathogenic and 42% had low pathogenicity. Forty-five percent of the strains studied were close to the threshold of resistance, the number of resistant strains being higher when the strains were obtained from houses in which birds had received the most treatments. In 1975, almost all strains were sensitive to treatment with ronidazole at a level of 50 mg/liter of water. Today, the recommended treatment is 100 to 150 mg/liter for a minimum period of five to seven days. Therefore, treatment with the recommended dosage and duration of application should be reserved for heavily infected pigeons (systematic verification by swabbing the mucosa of the crop) showing clinical signs.

REFERENCES

- Duchatel JP *et al.*, Première mise en évidence en Belgique de particules ressemblant a des circovirus chez le pigeon voyageur. *Ann Méd Vét*, 1998,142: 425-428.
- Duchatel JP & Vindevogel H. Miscellaneous herpesvirus infections. In *Diseases of poultry* (ed Y.M. Saif), Blackwell Publ., Ames 2008, pp. 404-409.
- Vereecken M *et al.* Adenovirus infections in pigeons: a review. *Avian Pathol*, 1998,27: 333-338.
- Vindevogel H *et al.* Le pigeon voyageur, seconde édition. Edition du Point Vétérinaire. 1994.
- Vindevogel H *et al.* Fréquence de l'ornithose-psittacose et de l'infection herpétique chez le pigeon voyageur et les psittacidés en Belgique. *Rev Méd Liège*, 1981,36:693-696.
- Woods LW & Latimer KS. Circovirus infection on nonsittacine birds. *J. Avian Med Surg*, 2000,14: 154-163.