

---

**U.S. ARMY MEDICAL DEPARTMENT CENTER AND SCHOOL  
FORT SAM HOUSTON, TEXAS 78234-6100**

---



# **DENTAL RADIOGRAPHY**

**SUBCOURSE MD0512**

**EDITION 100**

## **DEVELOPMENT**

This subcourse is approved for resident and correspondence course instruction. It reflects the current thought of the Academy of Health Sciences and conforms to printed Department of the Army doctrine as closely as currently possible. Development and progress render such doctrine continuously subject to change.

## **ADMINISTRATION**

For comments or questions regarding enrollment, student records, or shipments, contact the Nonresident Instruction Section at DSN 471-5877, commercial (210) 221-5877, toll-free 1-800-344-2380; fax: 210-221-4012 or DSN 471-4012, e-mail [accp@amedd.army.mil](mailto:accp@amedd.army.mil), or write to:

COMMANDER  
AMEDDC&S  
ATTN MCCS HSN  
2105 11TH STREET SUITE 4192  
FORT SAM HOUSTON TX 78234-5064

Approved students whose enrollments remain in good standing may apply to the Nonresident Instruction Section for subsequent courses by telephone, letter, or e-mail.

Be sure your social security number is on all correspondence sent to the Academy of Health Sciences.

## **CLARIFICATION OF TRAINING LITERATURE TERMINOLOGY**

When used in this publication, words such as "he," "him," "his," and "men" are intended to include both the masculine and feminine genders, unless specifically stated otherwise or when obvious in context.

## **USE OF PROPRIETARY NAMES**

The initial letters of the names of some products are capitalized in this subcourse. Such names are proprietary names, that is, brandnames or trademarks. Proprietary names have been used in this subcourse only to make it a more effective learning aid. The use of any name, proprietary or otherwise, should not be interpreted as an endorsement, deprecation, or criticism of a product. Nor should such use be considered to interpret the validity of proprietary rights in a name, whether it is registered or not.

# TABLE OF CONTENTS

<u>Lesson</u>	<u>Paragraphs</u>
INTRODUCTION	
1 HISTORY, HAZARDS, AND PROTECTION	
Section I.Introduction .....	1-1--1-5
Section II.Production of X-rays.....	1-6--1-7
Section III.Radiation Hazards and Protection.....	1-8--1-11
Exercises	
2 RADIATION BIOLOGY .....	2-1--2-7
Exercises	
3 PRODUCTION OF DENTAL RADIOGRAPHS	
Section I.Introduction .....	3-1--3-4
Section II.Radiographic Processing Facilities and Materials.....	3-5--3-8
Section III.Faulty Radiographs .....	3-9--3-20
Section IV.Mounting and Filing/Disposing of Radiographs.....	3-21--3-23
Section V.Anatomic Radiographic Landmarks .....	3-24--3-28
Exercises	
4 RADIOGRAPHIC EXPOSURE TECHNIQUES	
Section I.Introduction .....	4-1--4-5
Section II.Bisecting (Short-Cone) Periapical Exposure Techniques.....	4-6--4-17
Section III.Paralleling (Long-Cone) Periapical Exposure Techniques.....	4-18--4-27
Section IV.Interproximal (Bite-Wing) Exposure Techniques.....	4-28--4-30
Section V.Occlusal Exposure Techniques .....	4-31--4-37
Section VI.The Panoramic Radiograph .....	4-38--4-42
Exercises	

**CORRESPONDENCE COURSE OF THE  
U.S. ARMY MEDICAL DEPARTMENT CENTER AND SCHOOL**

**SUBCOURSE MD0512**

**DENTAL RADIOGRAPHY**

**INTRODUCTION**

This subcourse is designed to acquaint you with fundamental concepts of dental radiography. It seeks to familiarize you with the techniques of positioning the patient, the tubehead, and film as well as exposing and processing dental radiographs. A knowledge of radiography is essential to understanding the dangers inherent in the use of X-rays. Radiographs are used in helping the dental or medical officer to make diagnoses. There are examples in this subcourse of commonly produced radiographs. Utmost care must be taken to follow the rules for exposing and processing X-ray films to ensure that diagnostic quality radiographs are produced.

**Subcourse Components:**

This subcourse consists of four lessons. The lessons are as follows:

Lesson 1, History, Hazards, and Protection.

Lesson 2, Radiation Biology.

Lesson 3, Production of Dental Radiographs.

Lesson 4, Radiographic Exposure Techniques

**Credit Awarded:**

To receive credit hours, you must be officially enrolled and complete an examination furnished by the Nonresident Instruction **Section** at Fort Sam Houston, Texas. Upon successful completion of the examination for this subcourse, you will be awarded 12 credit hours.

You can enroll by going to the web site <http://atrrs.army.mil> and enrolling under "Self Development" (School Code 555).

A listing of correspondence courses and subcourses available through the Nonresident Instruction Section is found in Chapter 4 of DA Pamphlet 350-59, Army Correspondence Course Program Catalog. The DA PAM is available at the following website: <http://www.usapa.army.mil/pdffiles/p350-59.pdf>.

## **LESSON ASSIGNMENT**

### **LESSON 1**

History, Hazards, and Protection.

### **LESSON ASSIGNMENT**

Paragraphs 1-1 through 1-11.

### **LESSON OBJECTIVES**

After completing this lesson you should be able to:

- 1-1. Identify how x-rays were discovered.
- 1-2. Define selected terms related to radiology, radiation hazards, and radiation protection.
- 1-3. Describe the parts of a dental x-ray unit and the three-step process required to produce x-rays.
- 1-4. List the protective measures used against the hazards of excessive exposure to radiation.

### **SUGGESTION**

After studying the assignment, complete the exercises at the end of this lesson. These exercises will help you to achieve the lesson objectives.

## LESSON 1

### HISTORY, HAZARDS, AND PROTECTION

#### Section I. INTRODUCTION

##### 1-1. GENERAL

Radiography is a highly technical field, indispensable to the modern dental practice, but presenting many potential hazards. The dental radiographic specialist must be thoroughly familiar with the procedures necessary to produce radiographs of diagnostic quality. He must also have a thorough knowledge of the hazards associated with the use of radiation and how to protect himself and the patient against those hazards. This lesson deals with the production, characteristics, and effects of radiation and how it may be used safely in dentistry.

##### 1-2. DISCOVERY OF X-RAYS

In 1895, Wilhelm Konrad Roentgen was searching for invisible light by experimenting with a Crookes vacuum discharge tube. This is a glass tube in which the vacuum is nearly complete, having a negative electrode (cathode) and a positive electrode (anode). Many investigators believed that invisible light rays were emitted from the negative electrode when a high voltage current was sent through the tube. With the room darkened and the tube covered with black paper, Roentgen passed a high voltage current through the Crookes tube and was surprised to observe that a fluorescent screen lying on a table at some distance was glowing brightly. He then noted that a shadow was produced when an object was placed between the tube and the screen. Further experimentation revealed that the rays that caused the fluorescent screen to glow also acted upon the emulsion on photographic plates in the same manner as light. Thus it was shown that the rays produced would pass through some substances through which light would not pass. Since Roentgen was unable to determine the exact nature of the rays produced, he referred to them as x-rays (x being commonly used to denote an unknown factor). In later years scientists have referred to them as Roentgen rays.

##### 1-3. RADIOLOGICAL TERMINOLOGY

a. **Radiograph.** An exposed and processed film (roentgenograph, roentgenogram). Also known as an x-ray negative.

b. **Roentgenology.** The study and use of x-rays (radiology).

c. **Roentgen Ray.** Electromagnetic radiation of pure energy and extremely short wavelength (X-ray), sometimes referred to as x-ray photons.

d. **X-ray Photon.** Electromagnetic rays produced by the x-ray machine. (The x-ray photon will be dealt with in greater detail in Lesson 4 of this text.)

#### 1-4. SOURCES OF RADIATION

a. **General.** There are two sources of radiation (natural background radiation and man-made) both of which are harmful to man.

b. **Natural Background Radiation.** There are three sources of natural background radiation: cosmic, earth, and internal. Although natural background radiation may be harmful, man has lived in this environment without significant injurious effects since his appearance on earth.

c. **Man-Made Radiation.** Man-made radiation has many sources. Some of them are from medical and dental radiographs, occupational exposure, fallout from weapons testing, television sets, and certain radioactive watch dials, clocks, and meters. Man-made radiation, used improperly, can be significantly more harmful to man than natural background.

#### 1-5. TYPES OF RADIATION

a. **Particulate.** Particulate or corpuscular radiation comes from radioactive decay or disintegration of radioactive materials. Alpha and beta particles are examples of this type radiation.

b. **Electromagnetic.** Electromagnetic radiation covers a very wide spectrum ranging from electrical power to visible light to x and gamma rays. The portion of the electromagnetic spectrum most important to us in this particular study is the x-ray portion.

### Section II. PRODUCTION OF X-RAYS

#### 1-6. PARTS AND COMPONENTS OF THE DENTAL X-RAY MACHINE

a. **General.** The standard structural parts of the dental x-ray machine include a control panel (usually mounted behind a protective shield); a tube head, which houses the dental x-ray tube; and a flexible extension arm from which the tube head is suspended (see figure 1-1).

b. **The Control Panel.** The components of the control panel are switches, dials, gauges, and lights. Basically, each control panel has the same function, the arrangement and location of these components will differ, depending upon the make, model, and year of construction of the dental x-ray unit. An operator's manual is issued with each unit. The operator should study it until he is familiar with its operational capability.

c. **The Extension Arm.** The tube head is attached to the metal extension arm by means of a yoke that can revolve 360 degrees horizontally where it is connected. The construction of the yoke also provides vertical movement as well.

d. **The Tube Head.** Inside the metal tube housing is the x-ray tube. The diagram in figure 1-2 represents a dental x-ray tube head and a dental x-ray tube. This tube emits radiation in the form of photons (photons will be discussed in Lesson 2) or x-rays. X-ray photons expose the film. In addition to exposing the film, it also exposes the patient to radiation. Unless certain protective measures are taken, the x-ray technician may also be exposed.

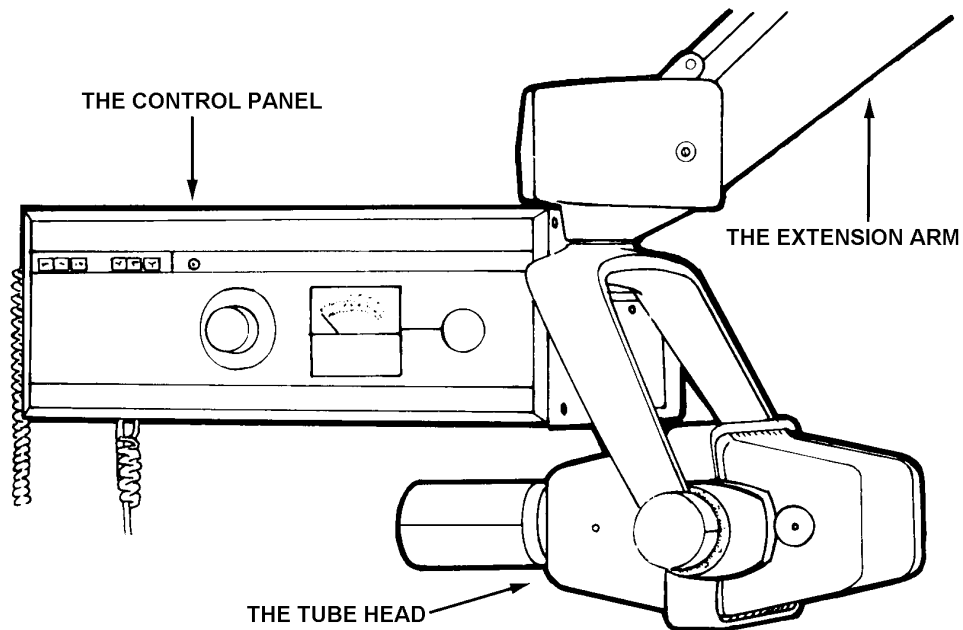


Figure 1-1. A representation of a control panel, x-ray tube head, and extension arm.

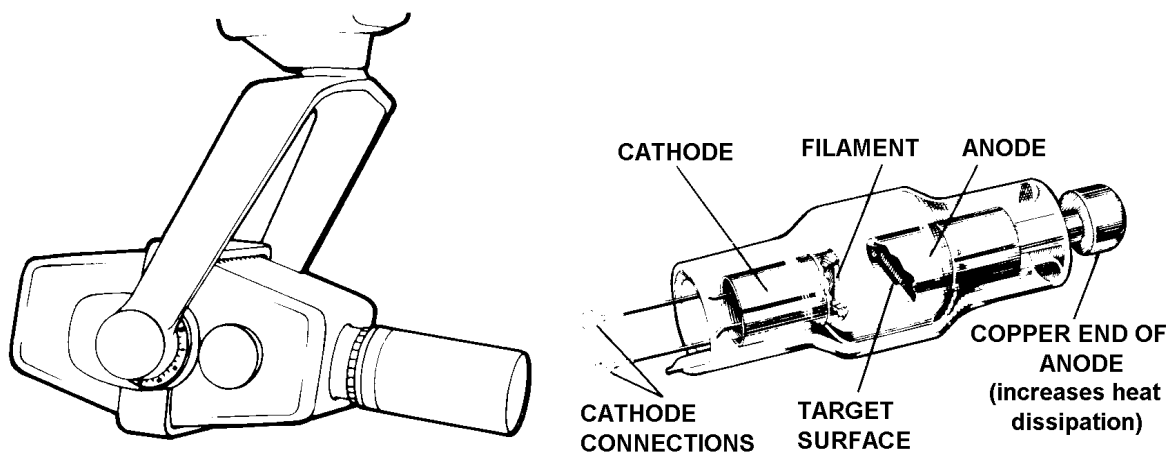


Figure 1-2. Dental x-ray tube head and dental x-ray tube.



## 1-7. THREE STEP PROCESS OF X-RAY PRODUCTION

a. **The First Step.** The first step in x-ray production is to turn on the machine. (If there is doubt on the part of the x-ray technician concerning the operation of the unit, reference should be made to the operator's manual.) When the unit is turned on, the filament of the cathode is heated by electrical current, causing it to emit electrons (see figure 1-3).

b. **The Second Step.** For the second step of this three-step process, high voltage is passed across the x-ray tube. When this is done, the electrons or electron cloud from the filament are drawn across the opening toward the anode. The anode is made of tungsten and is sometimes called the tungsten target. Figure 1-4 depicts the electrons speeding toward the anode (tungsten target).

c. **The Third Step.** The third and final step in this three-step process is the collision of electrons with the anode (tungsten target). This rapid deceleration of electrons produces x-rays, also referred to as photons. Figure 1-5 represents electrons striking the anode (tungsten target) and producing x-ray photons.

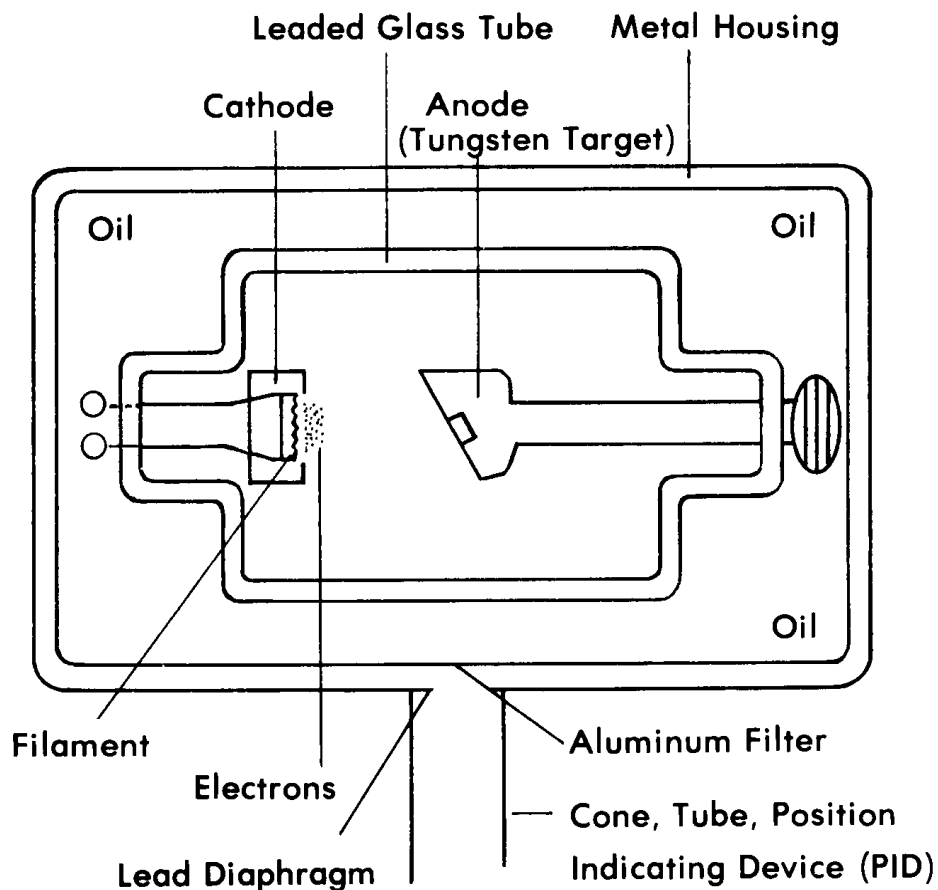


Figure 1-3. Tube head with the filament of the cathode emitting electrons.

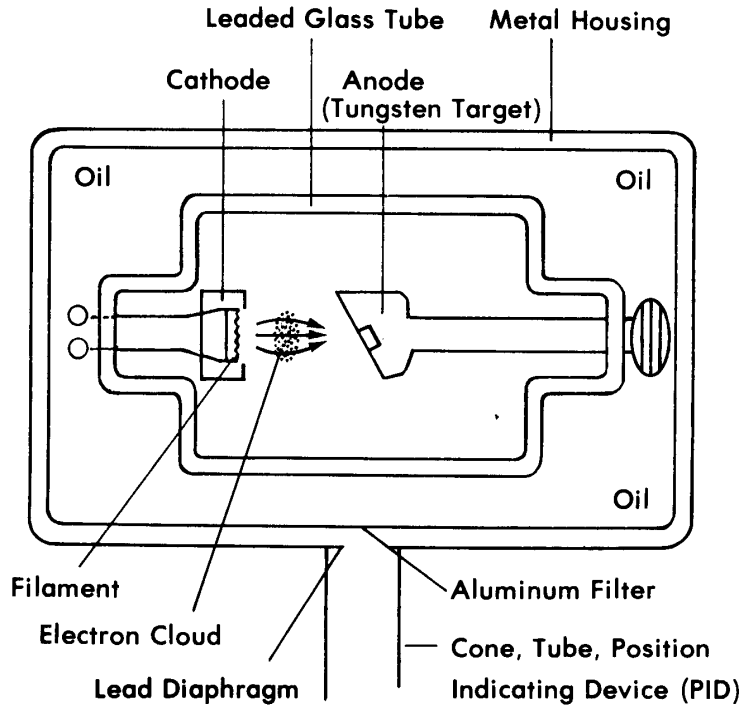


Figure 1-4. Electrons speeding toward the anode (tungsten target).

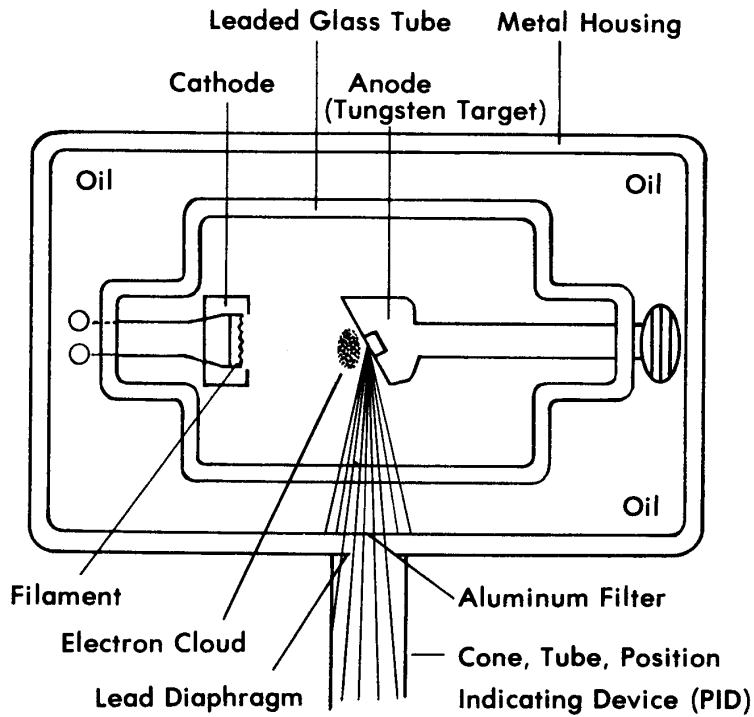


Figure 1-5. Electrons striking the anode (tungsten target) producing x-ray photons.

### Section III. RADIATION HAZARDS AND PROTECTION

#### 1-8. RADIATION HAZARDS

The dental x-ray technician should never receive primary radiation from a dental x-ray unit if safety precautions are observed. However, scattered and/or secondary radiation is more difficult to avoid and is a serious danger to the technician. This type of radiation is produced by a scattering of the primary x-ray beam. The x-ray photons and photo-electrons in the beam undergo a change of direction after interaction with atoms and molecules as they pass through a substance. (Photo-electrons will be discussed in Lesson 2.) Figure 1-6 depicts scattered/secondary radiation. Scattered/secondary radiation from a patient is depicted in figure 1-7.

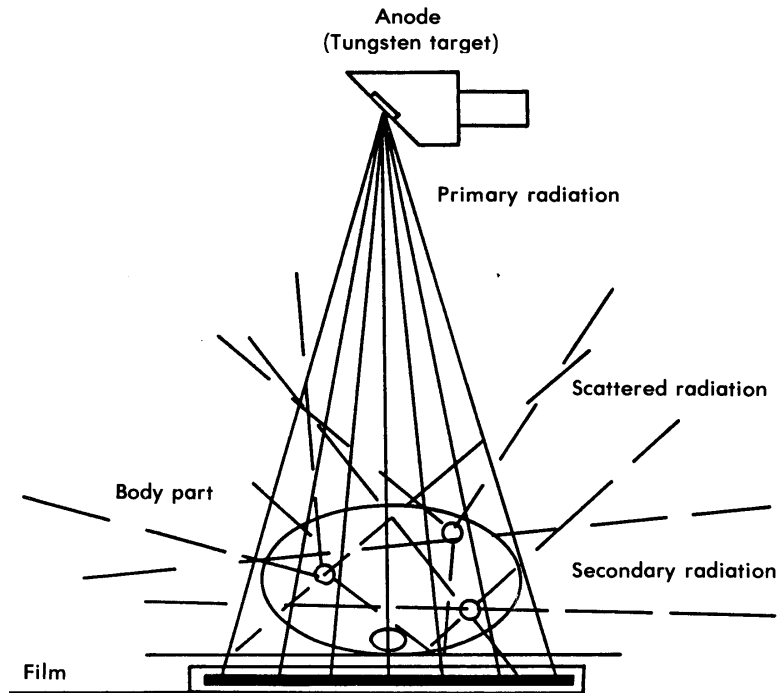


Figure 1-6. Diagram of scattered/secondary radiation.




Figure 1-7. Scattered/secondary radiation from a patient.

## 1-9. RADIATION PROTECTION

a. **General.** Filtration and collimation of the x-ray beam are very important safety measures. The filter and collimator (diaphragm) block the majority of the unwanted x-ray photons. As you progress through the next few paragraphs of this text, you will understand their importance. The following diagram will identify the location of these two devices (see figure 1-8).

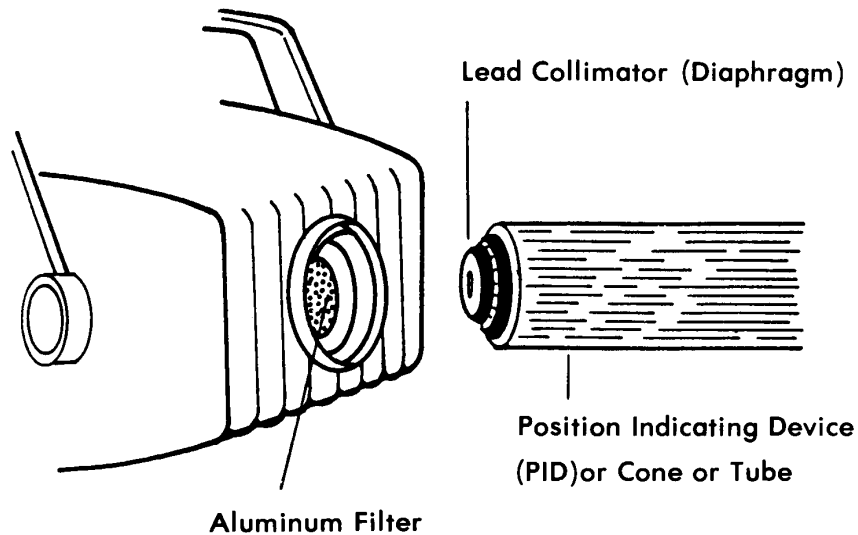


Figure 1-8. Tube head assembly: filter, collimator (diaphragm), PID or cone or tube.

b. **Filter.** The aluminum filter or disk is placed in the path of the x-ray beam. It is located at the base of the cone or position indicating device (PID) just inside the metal housing. Figure 1-8 shows the location of the PID. The filter completely covers the opening where the x-ray beam emerges from the x-ray tube. The reason for the aluminum filter is to absorb the low energy, long wavelength x-rays (photons) and allow the high energy, short wavelength x-rays (photons) to pass through the filter. Filters on dental x-ray machines with over 70 kVp have a minimum thickness of 2.5 mm of aluminum. Those machines below 70 kVp have a safety standard minimum of 1.5 mm aluminum.

**NOTE:** The terms cone, PID, or tube are used interchangeably throughout this text. See figure 1-8.

c. **Collimator.** The lead diaphragm is collocated with the aluminum filter. It restricts the x-ray beam to the desired size. The diaphragm or collimator is constructed of 1/16-inch lead. Without this collimator, x-ray photons would cover a wide area of the patient's head. With the lead diaphragm or collimator in place, only the area necessary for exposure receives the primary beam. This is depicted in figure 1-7. The diagram in figure 1-8 represents an x-ray tube, cone, or PID removed to show the location of the lead diaphragm or collimator and the aluminum filter.

## 1-10. PROTECTIVE MEASURES AND STANDARDS

a. **General.** Every possible safety precaution must be utilized when exposing radiographs. Collimation and filtration are only two of the several measures used to protect the patient and the technician from ionizing radiation. If all safety rules are strictly adhered to, the technician should receive no radiation and the patient exposure will be minimal. Even with the numerous safety precautions, accidental exposure is still possible.

### b. Technician Protection and Standards.

(1) Radiation monitoring. AR 40-14 prescribes monitoring practices for Army personnel. It requires all primary x-ray technicians to wear a dosimeter or film badge. The dosimeter monitors or measures radiation received by the technician. The results are recorded on DD Form 1141. This form is kept permanently and made a part of the individual's health record.

(2) Radiation standards. For the technician operating a dental x-ray machine, the level of radiation must not ever exceed an accumulated whole body dose, in rems, of five times the number of years beyond age 18 and a maximum of three rems in any 3-month period.

**NOTE:** The term rem refers to "roentgen equivalent in man," a unit measuring the biological effect of radiation energy. For x-rays, 1 rem is equal to 1 rad, or "radiation absorbed dose" (rad).

(3) Protective booth and shields. Standards for dental x-ray booths or rooms require a shielding thickness of 1/16-inch lead or equivalent. The timer switch used to activate the machine for exposures is permanently affixed to the outside wall. The timer switch is mounted outside the protective shielding to prevent the operator from standing inside the booth during exposures. The shield is so designed that the radiation must scatter at least twice before reaching the x-ray technician. Lead glass on the booth or shield provides a continuous view of the patient during the exposure. Consequently, any holding of the film or tube head by the x-ray technician is strictly prohibited.

c. **Patient Protection.** It is the responsibility of the x-ray technician to use all available protective measures to reduce exposure to the patient. Only those radiographs requested by the dental officer will be taken. Be sure that a good quality x-ray is produced each time a request is made. Wrong exposures, improper exposures, and faulty processing techniques must be avoided. These mistakes result in retakes and unnecessary patient exposure. Also, the lead apron must be used for every exposure. These safety devices significantly reduce patient exposure.

## 1-11. X-RAY BEAM QUANTITY AND QUALITY

The quality of the x-ray beam is controlled by the voltage, while the milliamperes control the quantity. An increase in the voltage and milliamperes reduces exposure time for the patient.

a. **X-ray Beam Quality.** The quality of the x-ray beam is controlled by the amount of voltage. Voltage provides contrast to the film. The desired contrast appears as various shades of gray, black and white in the x-ray negative (radiograph). Increased voltage provides less contrast (or more shades of gray). However, the beam has more penetrating power. Decreased voltage, on the other hand, provides more contrast (fewer shades of gray and more black and white shades). However, there is less penetrating power in the low voltage exposure. The technique most commonly used to expose periapical and bite-wing X-rays is a 90 kilovolt peak and 15 milliamperes.

b. **X-ray Beam Quantity.** The x-ray beam quantity is controlled by the milliamperes. The more x-rays (photons) in the x-ray beam, the more dense (dark) the x-ray negative (radiograph) becomes. By increasing the milliamperes, we increase the number of available electrons at the cathode filament. When electrical current (voltage) is applied to the x-ray tube, the electrons cross the gap. When they impact on the anode (tungsten target), a greater number of x-rays (photons) are also produced. The more x-rays that are available to penetrate an object, the more dense (dark) is the x-ray negative (radiograph).

[Continue with Exercises](#)

## EXERCISES, LESSON 1

**INSTRUCTIONS:** Answer the following exercises by marking the lettered response that best answers the question or best completes the incomplete statement or by writing the answer in the space provided.

After you have completed all the exercises, turn to "Solutions to Exercises" at the end of the lesson and check your answers.

1. \_\_\_\_\_ discovered the x-ray in 1895.

2. What name is associated with the vacuum discharge tube?

\_\_\_\_\_

3. Roentgen was unable to determine the exact nature of the rays produced so he referred to them as x-rays with x being commonly used to:

\_\_\_\_\_

4. An electromagnetic radiation of pure energy and extremely short wavelength (x-ray), sometimes referred to as x-ray photons, is known as:

\_\_\_\_\_

5. What are the two sources of radiation?

\_\_\_\_\_

\_\_\_\_\_

6. List at least four examples of man-made radiation.

\_\_\_\_\_

\_\_\_\_\_

\_\_\_\_\_

\_\_\_\_\_

7. The three sources of natural background radiation are:

---

---

---

8. List the standard structural parts of the dental x-ray machine as identified.

a. Usually mounted behind a protective shield: \_\_\_\_\_

b. Houses the dental x-ray tube: \_\_\_\_\_

c. The tube head is suspended from this object: \_\_\_\_\_

9. Scattered/secondary radiation is dangerous to the \_\_\_\_\_.

10. \_\_\_\_\_ are those x-rays (photons) and photo-electrons that have undergone a change in direction after interaction with atoms and molecules.

11. What is used to absorb the low energy, long wavelength x-rays (photons) and allow the high energy, short wavelength x-rays (photons) to pass through the filter?

---

12. How is it possible to expose only the area necessary for exposure when taking x-rays?

---

---



13. What is used to monitor or measure radiation received by the technician?

---

14. The dosimeter results are recorded on:

---

15. What is the maximum dose of radiation a worker may receive in any 3-month period?

---

---

---

16. Standards for dental x-ray booths or rooms require an equivalent shielding

thickness of \_\_\_\_\_ .

17. An increase in the voltage and milliamperes reduces \_\_\_\_\_ for the patient.

18. How does a technician get a greater quantity of x-rays (photons) in the x-ray beam?

---

19. List the processes required for obtaining the desired film contrast (quality of x-ray beam).

More shades of gray:

---

Fewer shades of gray, more black and white shades:

---

**Check Your Answers on Next Page**

## SOLUTIONS TO EXERCISES, LESSON 1

1. Wilhelm Konrad Roentgen (para 1-2)
2. Crookes (para 1-2)
3. denote an unknown factor (para 1-2)
4. roentgen ray (para 1-3c)
5. natural background  
man-made radiation (para 1-4a)
6. Any four:  
medical and dental radiographs  
occupational exposure  
fallout from weapons testing  
television sets  
certain watch dials, clocks and meters (para 1-4c)
7. cosmic  
earth  
internal (para 1-4b)
8. a. control panel  
b. tube head  
c. flexible extension arm (para 1-6)
9. technician and patient (para 1-8)
10. Scattered/secondary radiation (para 1-8)
11. aluminum filter or disk (para 1-9b)
12. The collimator restricts the x-ray beam to the desired size. (para 1-9c)
13. dosimeter (para 1-10b(1))
14. DD Form 1141 (para 1-10b(1))
15. An accumulated whole body dose, in rems, of five times the number of years beyond age 18 and a maximum of 3 rems in any 3-month period is permitted. (para 1-10b(2))

16. 1/16 inch lead (para 1-10b(3))
17. exposure time (para 1-11)
18. The technician increases the milliamperes. (This action increases the number of electrons at the cathode filament. When more electrons strike the anode (tungsten target), a greater number of x-rays (photons) are produced.) (para 1-11b)
19. Increased voltage provides less contrast  
(more shades of gray)

Decreased voltage provides more contrast  
(fewer shades of gray, more black and white shades) (para 1-11a)

**End of Lesson 1**

## **LESSON ASSIGNMENT**

### **LESSON 2**

Radiation Biology.

### **LESSON ASSIGNMENT**

Paragraphs 2-1 through 2-7.

### **LESSON OBJECTIVES**

After completing this lesson, you should be able to:

- 2-1. Define selected terms relating to radiation biology.
- 2-2. Identify the components of the atom.
- 2-3. Describe the effect of x-ray photons upon atoms and molecules.
- 2-4. List the harmful effects of overexposure to radiation.

### **SUGGESTION**

After studying the assignment, complete the exercises at the end of this lesson. These exercises will help you to achieve the lesson objectives.

## LESSON 2

### RADIATION BIOLOGY

#### 2-1. GENERAL

A very basic understanding of radiation biology is necessary for the dental x-ray specialist. In the next few paragraphs, a review of some basic concepts will be discussed along with diagrams representing atomic and molecular configurations. This lesson discusses the interaction and factors influencing cells, tissue, and matter when exposed to ionizing radiation.

#### 2-2. TERMS RELATING TO RADIATION BIOLOGY

a. **Ionization.** The gain or loss of electrons from an electrically neutral atomic or molecular configuration caused by radiation. There are other ways whereby electrons may be gained or lost, but we are most concerned with changes brought about by radiation.

b. **Element.** A simple substance that cannot be broken down by chemical means. An example of an element is oxygen.

c. **Atom.** The smallest unit of an element that still retains the properties of that element.

d. **Compound.** A complex substance formed by a chemical union of two or more elements. An example of a compound is water or H<sub>2</sub>O.

e. **Molecule.** The smallest unit of a compound.

#### 2-3. COMPONENTS OF THE ATOM

The atom is comprised of protons, neutrons, and electrons. The nucleus of an atom contains protons, which have a positive charge. The nucleus also contains neutrons, which are neutral. Electrons, which are negatively charged, revolve or orbit about the nucleus. Generally, protons and electrons in an atom are equal in number. Figure 2-1 represents an atom with one proton, one neutron, and one orbiting electron.

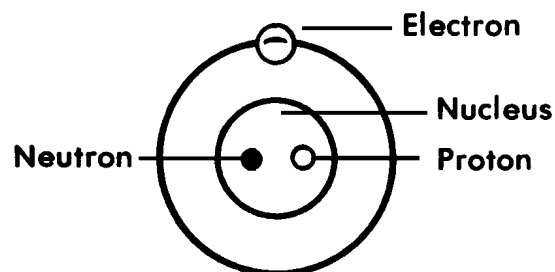


Figure 2-1. Components of the atom.

## 2-4. ORBITING ELECTRONS

The electrons revolve or orbit around the nucleus. They are arranged in shells or orbits much like the planets revolve around the sun (see figure 2-2). The first shell (K shell) can hold one or two electrons but no more. The second shell, or L shell, may contain up to 8 electrons and the third, or M shell, may contain as many as 18 electrons. Some atoms have numerous electrons. To determine the maximum number of electrons in any given shell, the calculations in Table 2-1 can be used. However, no outer shell actually contains more than eight electrons (see figure 2-3).

**NOTE:** The electrons are shown orbiting the nucleus like planets orbiting a sun for ease of explanation. The actual workings of the atom are a bit more complicated.

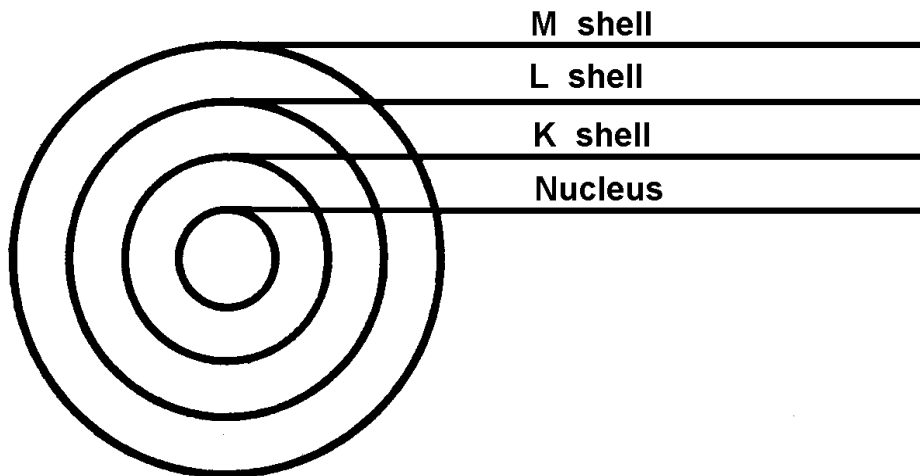


Figure 2-2. Diagram of K, L, and M shells.

$2 \times 1^2$	=	2 (K shell)
$2 \times 2^2$	=	8 (L shell)
$2 \times 3^2$	=	18 (M shell)

Table 2-1. Determining the maximum number of electrons in any given shell.

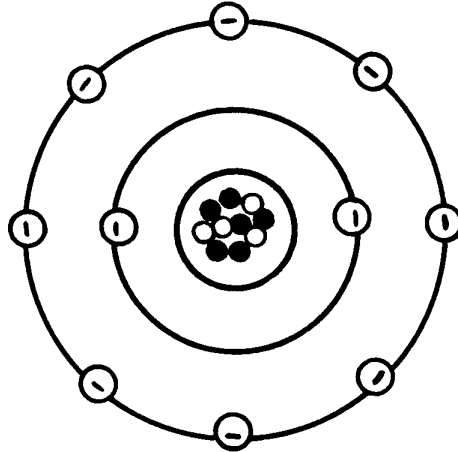


Figure 2-3. Orbiting electrons: 10 electrons.

## 2-5. ATOMS AND MOLECULES

a. **Atoms.** Some atoms are inert or neutral atoms. They have outer shells that are completely filled with electrons. It is extremely difficult for them to combine with other atoms to form molecules. Other atoms are referred to as bonding atoms. They have less than eight electrons in their outer shell (less than two in the K shell) and combine readily with atoms of other bonding atoms. See figure 2-4.

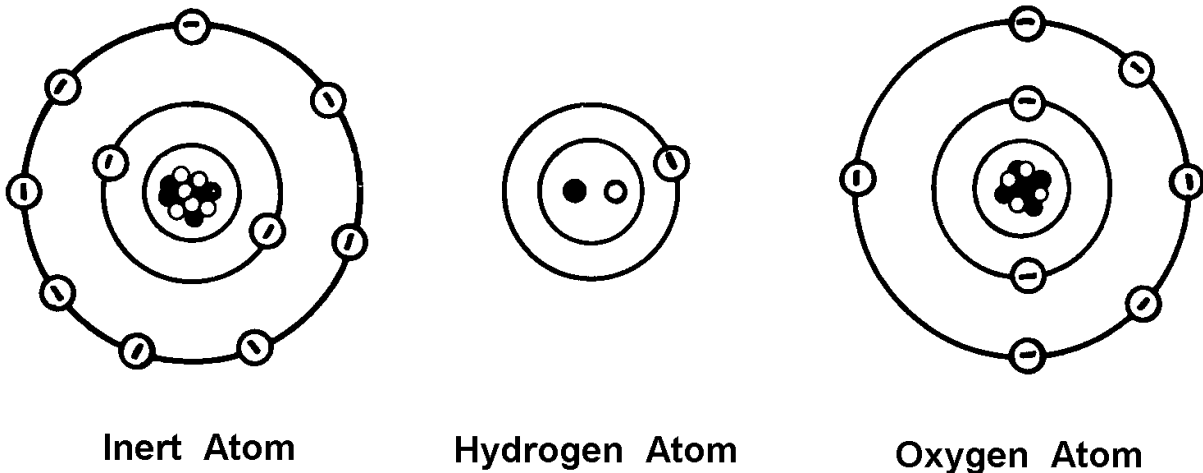


Figure 2-4. Inert atoms and bonding atoms.

b. **Molecules.** Molecules are formed by the combination of two or more atoms. A very common molecular formation is water, resulting from the combination of bonding atoms. Both have outer shells containing less than eight electrons. Two hydrogen atoms combine (or bond) with one oxygen atom to form water or  $H_2O$ . See figure 2-5.

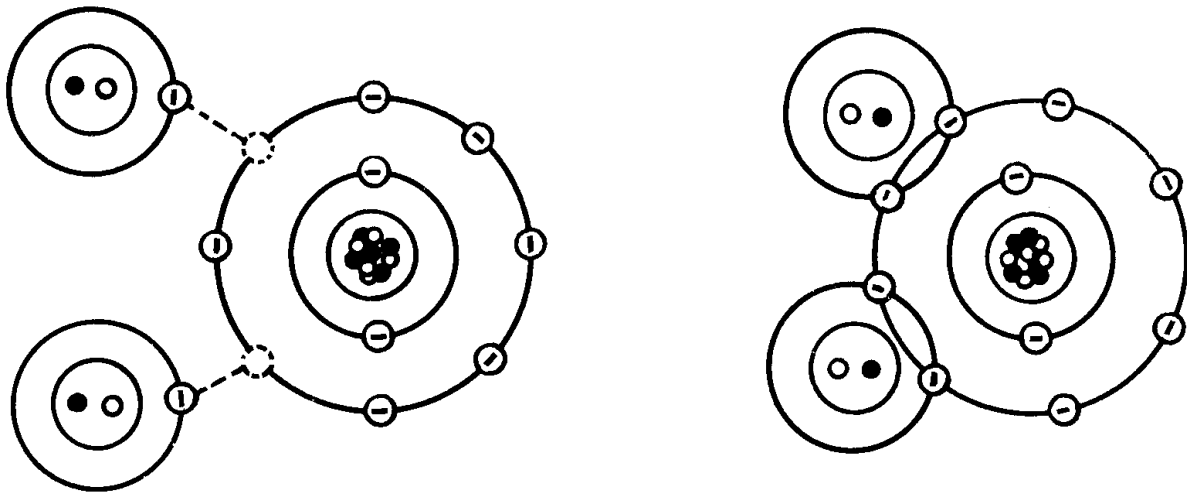


Figure 2-5. Bonding of one oxygen and two hydrogen atoms (water).

## 2-6. X-RAY PHOTON

A brief definition of an x-ray photon was previously stated. However, a more comprehensive definition is necessary for the next series of photon actions. X-ray photons are electromagnetic rays produced in the x-ray tube head when electrons from the cathode filament strike the anode target. They are bundles of pure energy. The photons transfer their energy to the substance through which they pass whether it be air, an x-ray film, or the living tissue of the patient or the specialist. They cannot be seen or felt.

### a. Photon Action Upon Atoms.

(1) Photon collision with the nucleus of an atom. The photon may strike the nucleus of an atom. If this occurs, the atom will be destroyed and the photon will release or expend its energy. See figure 2-6.

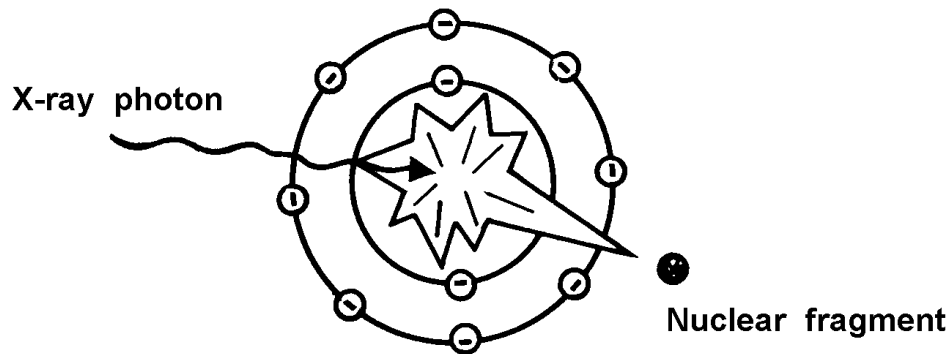


Figure 2-6. X-ray photon strikes the nucleus of an atom.



(2) A direct photon hit upon an electron by a photon. The photon may strike an electron with a direct hit. This action will result in the release of the photon's energy, transferring its energy to the electron. The electron will be dislodged from its shell. When an electron is dislodged in this manner, it is called a photo-electron. The dislodged or departing electron (now a photo-electron) will have energy to ionize or strike other electrons (figure 2-7). This is a form of scattered/secondary radiation, as noted earlier in the text.

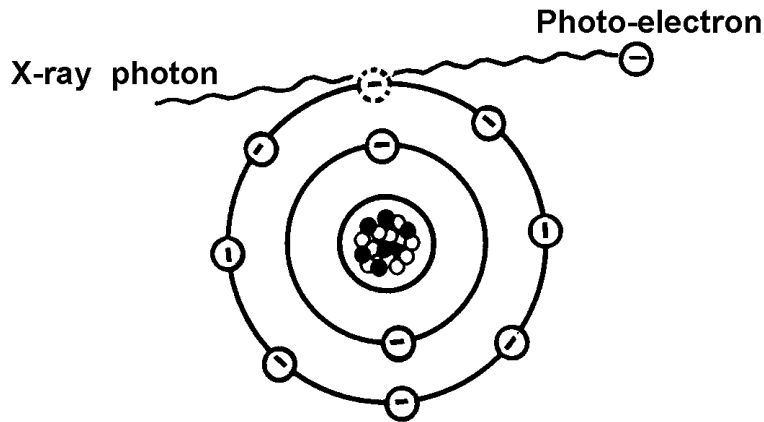


Figure 2-7. Direct hit upon an electron by a photon.

(3) An indirect photon hit upon an electron. The photon may strike one of the orbiting electrons with a glancing blow, dislodging the electron from its shell. By striking a glancing blow, the photon will still possess energy and go on to strike other electrons. The dislodged electron becomes a photon-electron and will have energy itself. It, too, may strike and dislodge other electrons (figure 2-8). This is also a form of scattered/secondary radiation.

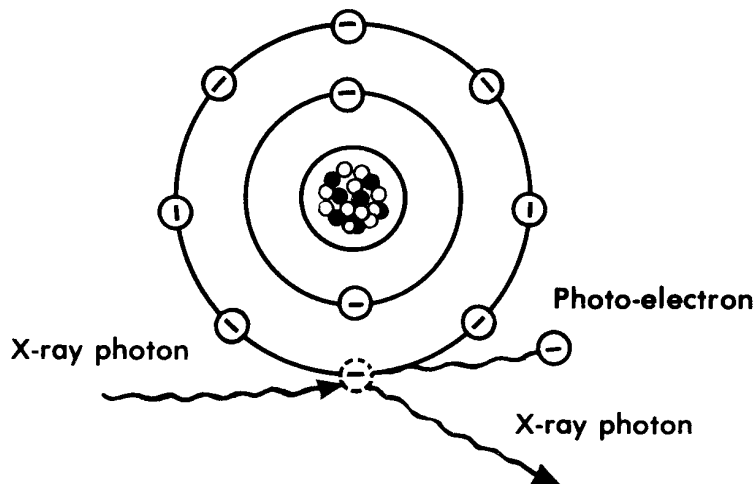


Figure 2-8. Indirect photon hit upon an electron.

## b. Photon Action Upon Living Cells.

(1) Living cells are composed of atoms and molecules. If the structure of the atoms and molecules is changed, this may adversely affect the cell. When cells are exposed to ionizing radiation, the structure of some of the atoms and molecules within the cell are changed.

(2) These are some of the effects that ionizing radiation has upon the cell.

(a) Cell death. The x-ray photon may strike a molecule in a sensitive area of a living cell and cause cell death.

(b) Toxic substances. The body is composed of a high percentage of water ( $H_2O$ ). The ionization (gain or loss of positive and/or negative charge) of atoms and molecules results in the breaking of the hydrogen-oxygen bond. When this occurs, there is a reforming of hydrogen and oxygen elements and hydrogen-oxygen compounds. One compound resulting from this restructuring of the atoms and molecules is hydrogen peroxide ( $H_2O_2$ ). Hydrogen peroxide is highly toxic to cells. If large amounts of toxic substances (hydrogen-oxygen compounds) are formed, cell death will result.

(c) Mutated cell formation. The chromosomes, which are the blueprint for the formation of new cells, are changed by excessive radiation exposure, resulting in mutated cells. The new mutated cells do not function properly. When a cell is changed in this manner, the life cycle or span of the cell is changed.

## 2-7. HARMFUL EFFECTS OF OVEREXPOSURE TO RADIATION

### a. Somatic Effects.

(1) Erythema. This is the reddening of the skin much like that of a sunburn; however, radiation exposure affects deeper tissue.

(2) Radiodermatitis. This refers to dry, flaky skin that doesn't heal easily. Ulcerations may become malignant.

(3) Cataracts. An overexposure to the eye could result in cataracts (a clouding of the lens or of its surrounding transparent membrane); however, this effect will appear long after the original exposure.

(4) Cancer. The cause of most natural occurring cancers is unknown. With increased exposure to radiation there is an increase in the incidence of cancer.

(5) Alopecia (epilation). This is hair loss.

**b. Genetic Effects.**

(1) Female. The ovaries are especially sensitive to radiation to the female fetus before birth and through childhood. The ovaries decline in sensitivity when the female reaches 20 to 30 years of age. After this time, there is increased sensitivity with increasing age.

(2) Male. Many investigators have recorded normal births from fathers whose testicles had received a radiation dose between 50 and 300 rad. Nevertheless, procreation at any time following such irradiation is ill advised.

(3) An unborn child. Radiation exposure is dangerous to any unborn child. However, the period of greatest danger is between 18 and 45 days of gestation. The results of excessive exposure could result in reduced growth, skeletal malformation, vision problems, and reduced head size which is associated with mental retardation.

**Continue with Exercises**

## EXERCISES, LESSON 2

**INSTRUCTIONS:** Answer the following exercises by marking the lettered response that best answers the question or best completes the incomplete statement or by writing the answer in the space provided.

After you have completed all the exercises, turn to "Solutions to Exercises" at the end of the lesson and check your answers.

1. Define the term "element" as used in radiation biology.

---

---

2. The nucleus of an atom contains protons, which have a \_\_\_\_\_ charge.

3. Electrons, which are \_\_\_\_\_ charged, revolve around the nucleus.

4. How are molecules formed?

---

5. Electromagnetic rays that are produced in the x-ray tube head when electrons from the cathode filament strike the anode target are called:

---

6. The photons transfer their energy to the substance through which they pass

whether it be \_\_\_\_\_, \_\_\_\_\_, or \_\_\_\_\_

of the patient or the specialist.

7. What happens if a photon strikes the nucleus of an atom?

---

---

8. When an electron is dislodged from its orbit due to a direct hit by a photon, what is the departing electron then called?

---

9. At what stage of pregnancy does radiation pose the greatest danger to an unborn child?

---

**SPECIAL INSTRUCTIONS FOR EXERCISES 10 THROUGH 16.** One item from **Column A** is closely related to or associated with an item in **Column B**. Select the correct associated term in **Column B** and write the letter in the blank space at the left of the number in **Column A**.

COLUMN A	COLUMN B
___10. A complex substance formed by a chemical union or two or more elements.	a. protons, neutrons, electrons
___11. The smallest unit of an element that still retains the properties of that element.	b. two
___12. The smallest unit of a compound.	c. compound
___13. This would normally be found in an atom.	d. hydrogen peroxide
___14. The maximum number of electrons that can be held in the K shell.	e. molecule
___15. Harmful somatic effects of overexposure to radiation.	f. erythema, cataract, cancer
___16. One toxic hydrogen-oxygen compound.	g. atom
	h. three
	i. erythema, cataract, canker sores

**Check Your Answers on Next Page**

## SOLUTIONS TO EXERCISES, LESSON 2

1. A simple substance that cannot be broken down by chemical means (i.e., oxygen). (para 2-2b)
2. positive (para 2-3)
3. negatively (para 2-3)
4. Bonding atoms combine with each other to form molecules. (para 2-5b)
5. x-ray photons (para 2-6)
6. air, an x-ray film, or living tissue (para 2-6)
7. The atom will be destroyed and the photon will release or expend its energy. (para 2-6a)
8. photo-electron (para 2-6a(2))
9. 18 to 45 days of gestation (para 2-7b(3))
10. c (para 2-2d)
11. g (para 2-2c)
12. e (para 2-2e)
13. a (para 2-3)
14. b (para 2-4)
15. f (para 2-7a)
16. d (para 2-6b(2)(b))

**End of Lesson 2**

## LESSON ASSIGNMENT

### LESSON 3

Production of Dental Radiographs.

### LESSON ASSIGNMENT

Paragraphs 3-1 through 3-28.

### LESSON OBJECTIVES

After completing this lesson, you should be able to:

- 3-1. Define selected terms related to radiographic film.
- 3-2. List in sequence the steps for exposing, processing, and viewing dental radiographs.
- 3-3. Describe the facilities, materials, and methods used in processing quality x-rays.
- 3-4. List the reasons for nondiagnostic quality (faulty) radiographs.
- 3-5. Identify procedures for mounting dental radiographs.
- 3-6. Identify radiolucent landmarks on maxillary radiographs.
- 3-7. Identify radiolucent landmarks on mandibular radiographs.
- 3-8. Identify radiopaque landmarks on maxillary radiographs.
- 3-9. Identify radiopaque landmarks on mandibular radiographs.

### SUGGESTION

After studying the assignment, complete the exercises at the end of this lesson. These exercises will help you to achieve the lesson objectives.

## LESSON 3

### PRODUCTION OF DENTAL RADIOGRAPHS

#### Section I. INTRODUCTION

##### 3-1. GENERAL

A diagnostic radiograph is vitally important for most procedures in dentistry. A high level of skill and training is required of the dental specialist. The production of suitable diagnostic radiographs requires knowledge of the anatomical (refer to Subcourse MD0501) characteristics of the oral cavity and the relationship between individual teeth. It also requires knowledge of types of dental film, appropriate exposure and processing techniques, and use of darkroom equipment.

##### 3-2. GENERAL EXPOSURE FACTORS

Each type of dental film requires a specific exposure time and technique to obtain satisfactory radiographs. The exposure depends upon the type of emulsion, the density of the tissues to be radiographed, the target-film distance, and the characteristics of the exposing rays. X-ray units are designed to provide exacting control of voltage, amperage, and exposure time. Satisfactory results are best achieved by carefully following the film manufacturers' instructions.

##### 3-3. DENTAL RADIOGRAPHIC FILM

Dental radiographic film is supplied in various sizes and degrees of sensitivity, each designed for a specific purpose. Film should be stored in a cool, dry place free from chemical contamination. High temperatures, moisture, and certain chemicals will cause deterioration of the film's emulsion. Dispensers made of radiopaque metal are commonly used to provide a limited stock of periapical films. Lead-lined boxes are available for storage and protection of film used in the dental clinic (see figure 3-1). An expiration date is stamped on each film package by the manufacturer. Film should not be overstocked, but maintained in quantities that will be used before the expiration date.

###### a. Film Construction.

(1) An x-ray film has two parts, the cellulose acetate base and the emulsion covering it. The base is made of cellulose and is a transparent plastic that is clear or with a slightly bluish tint. The emulsion is a thin coating of a special gelatin with minute particles of a silver compound. When x-rays penetrate through soft tissue, such as the cheek or the gingiva, they also penetrate the emulsion easily, which causes the silver compound to stick to the cellulose base during processing. Therefore, the film is darker (this is known as radiolucence). When x-rays are directed to hard tissue (which is



dense), such as bone, tooth enamel, and metal restorations, fewer x-rays reach the film. So, more of the silver compound is removed by processing. This results in lighter shades on the film (which is known as radiopaque).

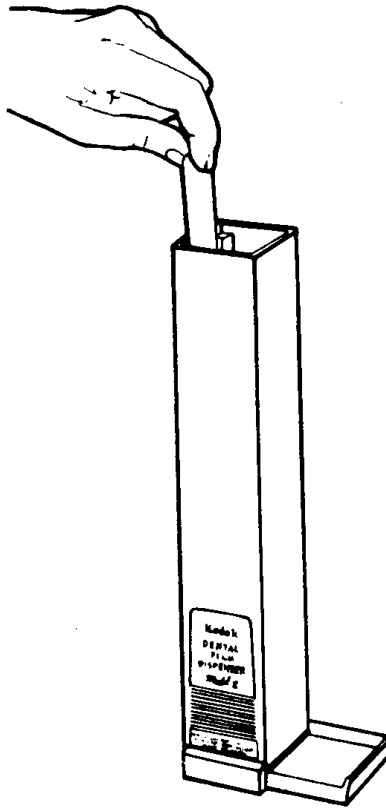


Figure 3-1. Dental film dispenser.

(2) All dental x-ray films (intraoral films) have an embossed dot (a raised spot) to identify right and left. This raised dot is on the side of the film facing the x-ray tube. The purpose of the embossed dot is to assist in mounting radiographs in correct anatomical order.

#### **b. Types of Film.**

(1) Intraoral film. Periapical, bite-wing, and occlusal are three types of intraoral film used to reveal different dental structures.

(a) Periapical film is used primarily for radiographic examination of teeth and adjacent tissues to include the periapical region. The standard periapical film (Type 2) used in the Army is 1 1/4 by 1 5/8 inches, which is large enough to include a view of about three teeth. A small size periapical film (Type O) is also a standard item of issue for use in radiography of children's teeth and measures 7/8 by 1 3/8 inches.

(b) Bite-wing film is used to obtain a radiograph of the coronal two-thirds of opposing maxillary and mandibular teeth and their adjacent tissues on a single film. The film packets are provided with tabs that extend from the center of the film. When a radiograph is being made, the patient is instructed to bite down on the tab. The tab holds the film firmly in position with the lower half lying lingual to the mandibular teeth and the upper half held lingual to the maxillary teeth. Type 3 is the standard type of bite-wing film used in the Army. It measures 1 1/16 by 2 1/8 inches. When the type 3 bite-wing film is unavailable or if the dental officer requests it, the type 2 periapical film may be used to take bite-wing x-rays. However, these films would require the use of paper adapters. Type O periapical film may be used as a bite-wing film for children. These, also, would require the use of paper adapters.

(c) Occlusal film is a highly sensitive double-emulsion film supplied in packets similar to periapical film but in a size convenient for obtaining a view of the entire upper or lower arch or portions thereof. It measures 2 1/4 by 3 inches. Some packets contain two films. The first film is developed at normal time to give a detailed image of hard structures. The second film is developed in one half the normal time to reveal soft tissue images.

(2) Extraoral film. Extraoral film is used for radiographs of the jaws, facial bones, the temporomandibular joints, and other relatively large areas. This film has no embossed dot to identify right and left.

(a) Intensifying screens are used with extraoral film to intensify the effects of the exposing rays and lessen the exposure time.

(b) A cassette is constructed of rigid metal, plastic, or cardboard. It often contains intensifying screens that magnify the x-ray beam, thus reducing exposure time. The film must be transferred to the cassette from its paper covering in the protection of the dark room.

(3) Panoramic film. Panoramic film, a type of extraoral film, is used in panoramic radiography. This film shows the entire dentition and surrounding bone structure.

### **3-4. BASIC PROCEDURES**

Radiographs are never taken unless requested or authorized by a dental officer. When a patient reports to the dental radiographic service, the desired radiographs are determined, appropriate information is recorded in the logbook (depending upon local policy), and certain basic procedures are performed.

#### **a. Exposing Procedure.**

(1) Seat the patient and adjust the headrest to establish the proper position of his head.

- (2) Drape the patient with the lead apron and attach the cervical collar.
- (3) Position the film packet.
- (4) Align the x-ray tube.
- (5) Select the proper exposure factor.
- (6) Make the exposure.
- (7) Place the film in a film safe until ready to process.

b. **Processing Procedure.** The processing procedure is performed in total darkness or with a special "safe" light.

- (1) Prepare the darkroom.
- (2) Stir the developing solution and note its temperature.
- (3) Open the film packet and attach it to the film hanger.
- (4) Set the timer in accordance with the graph as shown in figure 3-6 and place the film in the developing solution.
- (5) Rinse the film in clear water.
- (6) Set the timer again and place the film in the fixing solution.

**NOTE:** If a wet reading is desired, the film(s) may be removed from the fixing solution after it clears or after about two minutes. They are washed and taken to the dental officer for viewing. After the wet reading, the film(s) must be returned to the fixing bath for complete fixation.

- (7) Wash the film.
- (8) Dry the film.

**NOTE:** See paragraph 3-7 for additional information concerning the use of the automatic processor.

c. **Viewing Procedure.**

- (1) Mount in a suitable frame.
- (2) Label the mount for proper identification.

## Section II. RADIOGRAPHIC PROCESSING FACILITIES AND MATERIALS

### 3-5. GENERAL

Precise methods in the processing of x-ray films are as important in attaining good results, as is the use of precise exposure technique. Regardless of the method (automatic or manual) used by the dental specialist, if proper processing procedures are followed, quality radiographs will result.

### 3-6. DARKROOM

a. **Construction.** Since x-ray films are more sensitive to light than most photographic films, it is important to have a good darkroom. The room need not be large, but it must be constructed so that no light can enter through cracks or crevices. An entrance built in the form of a maze to keep out light is better than a door. If the darkroom has a door, it should have an inside lock so that no one can accidentally enter while films are being processed. The walls of the darkroom and the maze should be painted black to absorb light. The ceiling may be painted white so that enough illumination will be reflected when the correct type of safelight is used. The room should be supplied with both hot and cold water. The water pipes should lead to a mixing valve so the temperature of the flow can be regulated. Adequate ventilation must be provided. This can be done by forcibly changing the air with a ventilator fan.

b. **Cleanliness.** Because of the extreme sensitivity of x-ray films, rigid cleanliness must be observed when processing films. Clean all equipment and only use for its intended purpose. The dental specialist must not spill chemicals. If chemicals are spilled, wipe up immediately and wash the area with clear water. Spilled chemicals that are not wiped up will evaporate and leave a precipitated concentrate that contaminates films. Wash the thermometers and film holders thoroughly before transferring them to either the developing or fixing solutions. Film hangers require particular attention after films have been removed from them. If a hanger is not washed properly, the fixing solution dries on it. Then, when new films are placed on the hanger and immersed in the developing solution, the dried fixing solution runs down onto the films and causes streaked or spotted radiographs. It also contaminates the developing solution.

c. **Thermometer.** Since films must be processed at an exact and predetermined temperature, a thermometer is needed to register the temperature of the solutions.

d. **Timer.** Because of the direct relationship between temperature and time in processing, the dental specialist must know the exact time and any given film is to be left in each solution. A good watch may be used for this purpose, but it is much better to use an interval timer. The interval timer is a small clock giving the time in minutes and fractions of minutes. When set for the exact time required for development, it sounds an alarm at the expiration of that time.

e. **Film Holders.** There are three types of film holders. The frame type is used for extraoral films and the clip and hinge types are used for intraoral films (see figure 3-2).

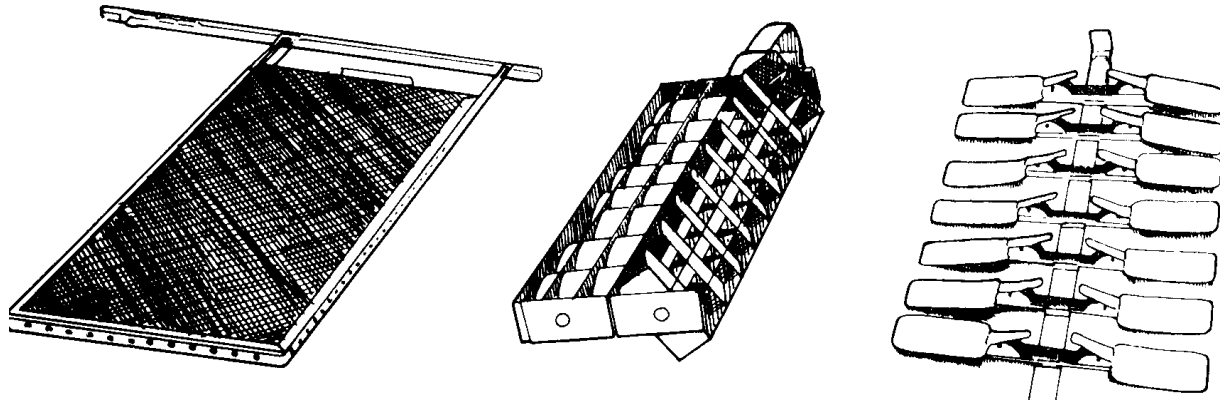


Figure 3-2. Film holders for processing intraoral and extraoral films.

f. **Illumination.** A photographically safe light must be used to illuminate the darkroom. The standard for a safelight is that it must be possible to permit underdeveloped film to be exposed to the light at a distance of 4 feet for 1 minute without the least evidence of fogging.

g. **Sink.** A sink is useful in the darkroom for mixing solutions, washing hands, and disposing of used chemicals. Remember that the fixing solution is not disposed of like other chemicals. It is retained for silver recovery.

h. **Solutions.** There are two types of processing solutions. One is used for the automatic processor and another for the manual processor. They are not designed to work interchangeably. Before changing the processing solutions, check the manufacturers' instructions to be sure that you have the proper chemicals for the processor you are using. Also, follow manufacturers instruction when preparing them. Some will require several chemicals mixed with water while others may be used directly from the container.

### 3-7. AUTOMATIC PROCESSOR

The automatic processor (see figure 3-3) is used by most dental treatment facilities. Following exposure, the film is unwrapped in the darkroom and immediately loaded into the automatic processor. The unit consists of rollers and compartments filled with chemical solutions through which the film advances. At the end of the processing cycle, the film is released. The cycle duration varies from 4 to 6 minutes.

a. **Preventive Maintenance.** Preventive maintenance is the key for keeping this machine operational. The operator must adhere to the daily, weekly, and monthly maintenance schedule as prescribed by the manufacturer.

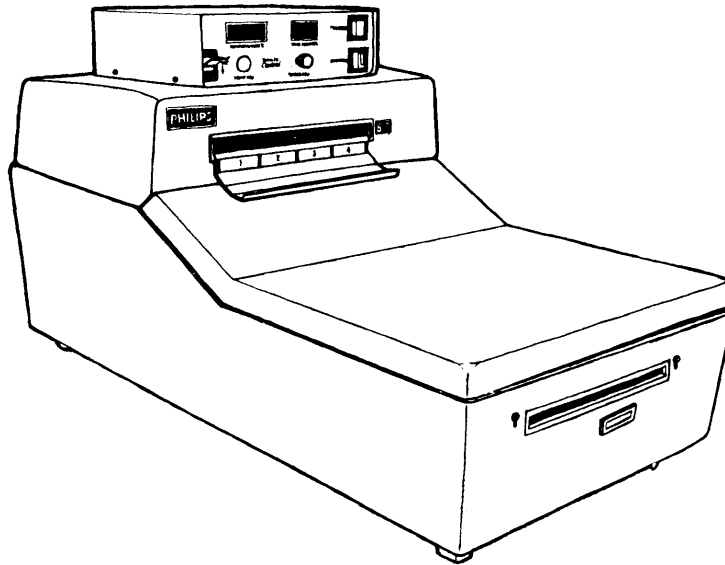


Figure 3-3. Automatic processor.

b. **Operation.** There are several automatic processors on the market today. Each machine has a slightly different design as well as maintenance and operational requirements. Therefore, you must consult the operator's manual; otherwise a very expensive piece of equipment may be damaged.

### 3-8. MANUAL PROCESSING

The manual processor uses the standard time-temperature method and small containers of the different processing solutions. The dental specialist should be familiar with the manual processor in case the automatic processor is not available. The manual processor will allow the dental specialist to continue providing support to the dental officer without interrupting patient treatment.

**NOTE:** Manual processing is the primary method whereby film will be processed when field equipment is used.

a. **Processing Tank.** The processing tank most commonly used in dental clinics has three compartments (see figure 3-4). The compartment to the left contains the developing solution, water is in the center compartment, and the fixing solution is on the right. In addition to the three compartments, a source of hot and cold water, a drain, an overflow valve, and a cover are needed. The water is adjusted to the proper temperature and is allowed to circulate in the middle compartment and pass from the tank by the overflow valve. This action provides temperature controls to the developing and fixing solution.

b. **Processing Procedures.** In order to produce a radiographic image, the processing procedure for the film is sequenced as follows: developing, rinsing, fixing, washing, and drying. The quality and diagnostic value of radiographs depend upon proper processing procedures.

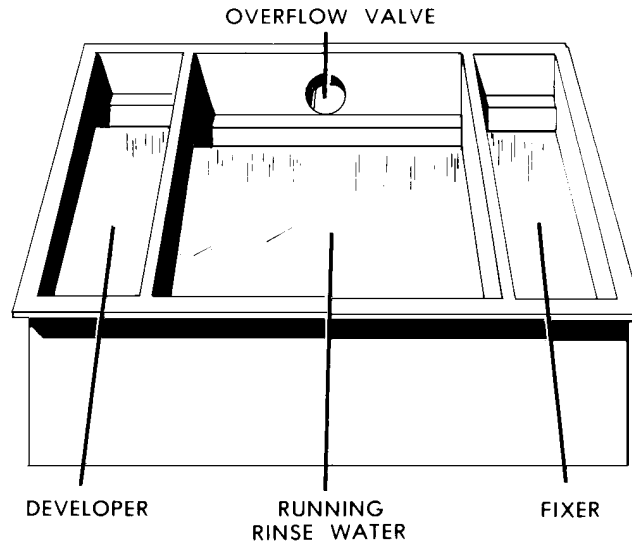


Figure 3-4. Tank for processing dental film.

c. **Developing.** All equipment should have a definite place in the darkroom to facilitate handling when the user is working by the safelight only. Steps used when developing film are as follows:

(1) Wash gloved hands, so that hands are clean and dry. This is to prevent the appearance of finger marks on the developed film.

(2) Remove the lightproof wrapper from the film.

**NOTE:** Dispose of contaminated wrappers in accordance with (IAW) local standing operating procedures.

(3) Place the film on the film holder. The film should be held lightly by its edges to avoid the appearance of smudges or fingerprints on the developed film. They may appear even when the hands are clean.

(4) Set the interval timer (clock) for the prescribed developing time. Timer should start when the film is placed in the developing solution (developer).

**NOTE:** The recommended temperature for the developing solution is 68° F (20° C). At this temperature, most films should be left in the developer exactly 4 1/2 minutes. Without adequate equipment, 68° F (20° C) cannot always be obtained. In that case, the time factor should be adjusted according to the chart in figure 3-5. Temperatures above 70° F (21°C) and below 60°F (15°C) should be avoided if possible.

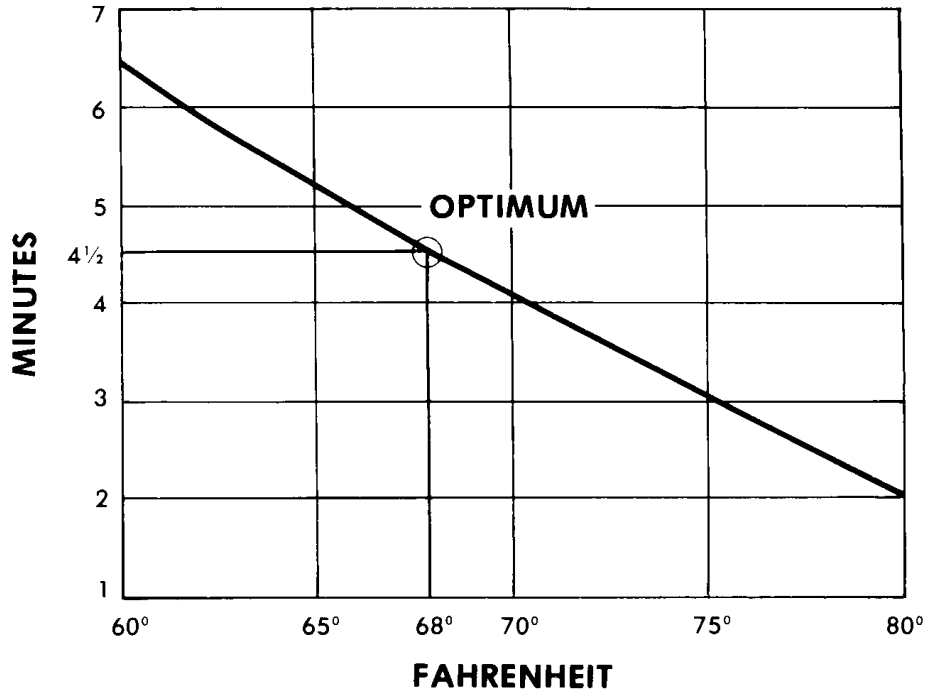


Figure 3-5. Time-temperature ratio for processing film.

(5) Immerse the film in the developing solution (figure 3-6), moving the film holder up and down several times to break up air bubbles that may have formed on the surface of the film.

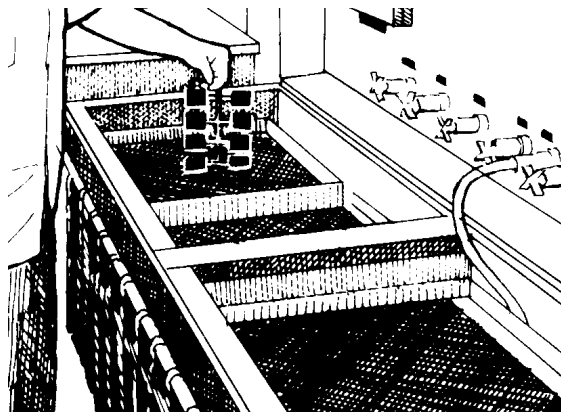


Figure 3-6. Developing x-ray film.

**NOTE:** If bubbles are allowed to remain, they prevent the developer from acting on the area of film contained in each bubble. Also, care should be taken to ensure that the film does not touch another film or touch the sides of the tank. Such contact affects the emulsion and prevents the developer from acting upon it properly.



(6) Remove the film at the expiration of the developing time. Hold the film rack in a tilted position for a few seconds to allow excess solution to drain into the developing section of the tank.

(7) Rinse the film in clear water.

d. **Rinsing.** The film should remain in the rinse water at least 20 seconds to remove the developing solution. Be sure to tilt the film rack to allow excess water to drain back in. (You do not want to dilute the fixing solution.) After removing the film from the rinse water (figure 3-7) and draining, place it in the fixing solution (fixer).

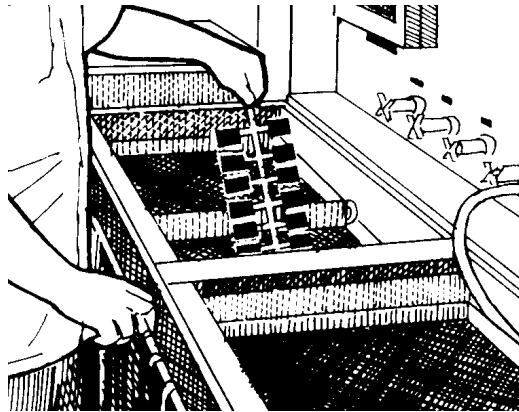


Figure 3-7. Rinsing x-ray film.

e. **Fixing.** During the first stage of fixation, unexposed silver crystals are removed from the film, thereby clearing the film and making the image translucent. The hanger should be moved up and down several times (figure 3-8) to make sure the fixer contacts all surfaces. An average safe time for the film to remain in a fresh fixing solution is 10 minutes. This provides time for the emulsion to harden properly after the film has cleared. The film may be examined briefly after 1 minute in the fixer, but it must be returned to the solution to complete the hardening process. For wet readings, a minimum of 2 minutes of fixation is required. After readings, the film must be returned to the fixing solution to complete the process.

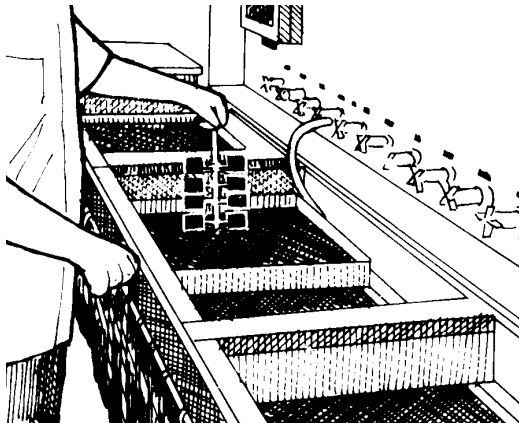


Figure 3-8. Fixing x-ray film.

f. **Washing.** Upon the completion of fixation, the film should be immersed in fresh, cool, circulating water for at least 20 minutes to ensure complete removal of the fixing solution (figure 3-9). If not washed properly, the radiograph will turn yellow and fade with time if any of the fixing chemical remains on its surface.

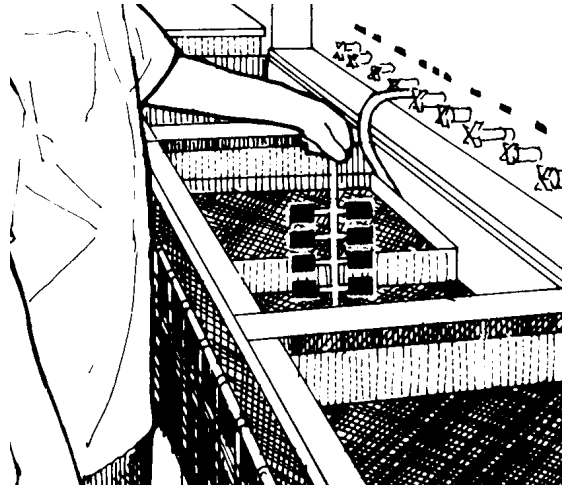


Figure 3-9. Washing x-ray film.

g. **Drying.** Wet films must be handled carefully so that the emulsion is not touched or marred. After washing, the hanger should be hung carefully upon the drying rack. A pan under the rack serves to catch water dripping from films. Drying is done by leaving the film suspended in the air until it is completely dry. Drying may be speeded up by directing a current of air from a small electric fan over the film's surface or by using an x-ray film drier (see figure 3-10).

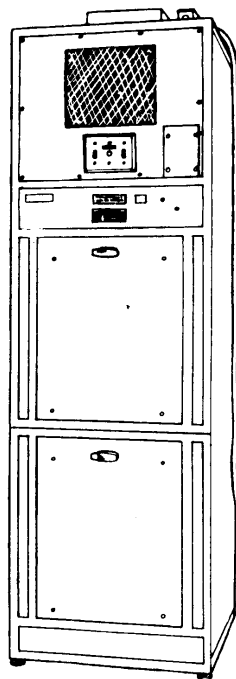


Figure 3-10. X-ray drier.

## Section III. FAULTY RADIOGRAPHS

### 3-9. GENERAL

Errors in improperly exposing or processing dental films can produce undesirable dental radiographs of nondiagnostic quality. These are known as faulty radiographs. The dental x-ray specialist should be familiar with the common causes of faulty radiographs and how to prevent them.

### 3-10. UNDEREXPOSED IMAGE

An underexposed image (see figure 3-11), an image that is too light, may be caused by:

- a. Insufficient radiation exposure.
- b. Insufficient development time.
- c. Use of an overused developing solution.
- d. Use of a developing solution that is too cold.

### 3-11. OVEREXPOSED IMAGE

An overexposed image (see figure 3-12), an image that is too dark, may be caused by:

- a. Too much radiation exposure.
- b. Too much development time.
- c. Use of developing solution that is too warm.

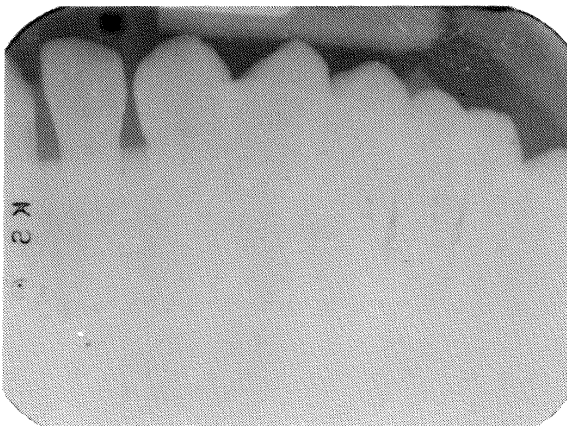


Figure 3-11. Underexposed image.

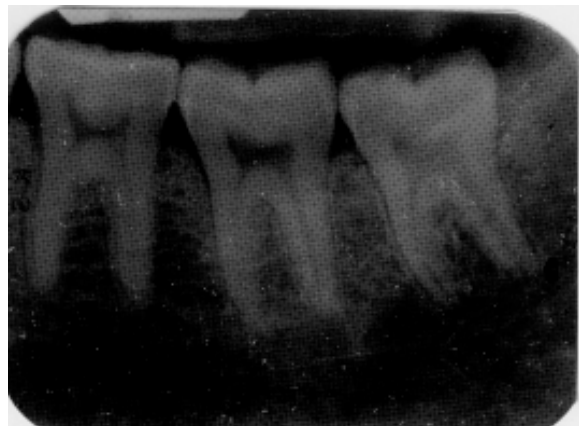

Figure 3-12. Overexposed image.

### 3-12. BLURRED IMAGE

A blurred image (see figure 3-13) is easily recognized by the appearance of more than one image of the object, or objects, on the film. It may be caused by movement of the patient, film, or tube during exposure.

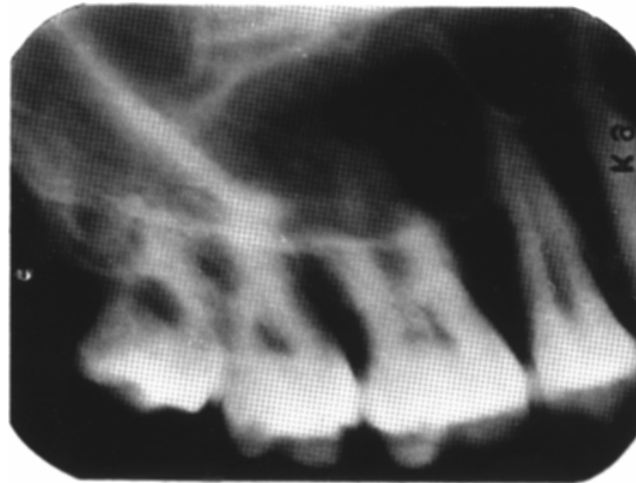

Figure 3-13. Blurred image.

### 3-13. PARTIAL IMAGE

A partial image (see figure 3-14) may be caused by failure to immerse the film completely in the developing solution, contact of the film with another film during developing, or improper alignment of the central ray.

### 3-14. DISTORTED IMAGE

A distorted image (see figure 3-15) may be caused by improper angulation of the central ray due to bending of the film packet.

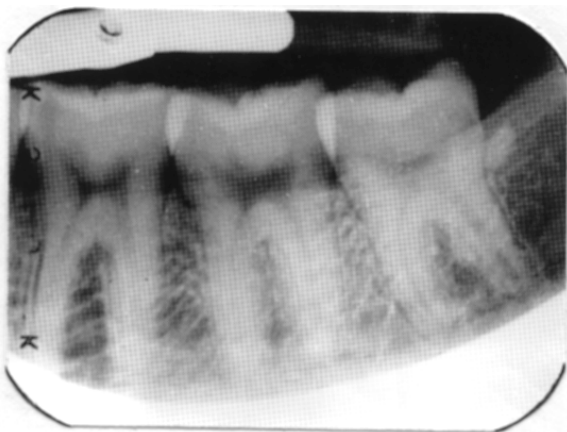

Figure 3-14. Partial image.

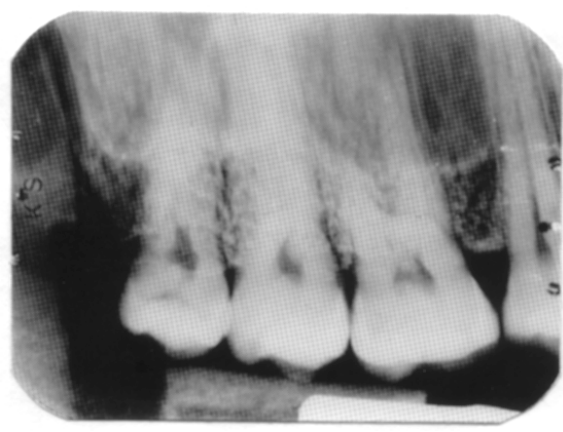

Figure 3-15. Distorted image.

### 3-15. FOGGED FILM

Fogged film (see figure 3-16) may be caused by:

- a. Exposure of film to light during storage.
- b. Leaving film unprotected (that is, outside the lead-lined box or in the x-ray room during operation of the x-ray machine).
- c. Use of film that has been exposed to heat or chemical fumes.
- d. Use of improperly mixed or contaminated developer.
- e. Defective safelight.

### 3-16. STAINED OR STREAKED FILM

Stained or streaked film (see figure 3-17) may be caused by dirty solutions, dirty film holders or hangers, incomplete washing, or solutions left on the workbench.

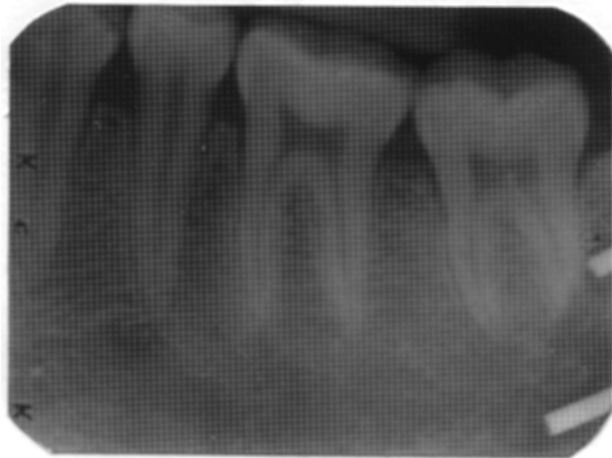

Figure 3-16. Fogged film.

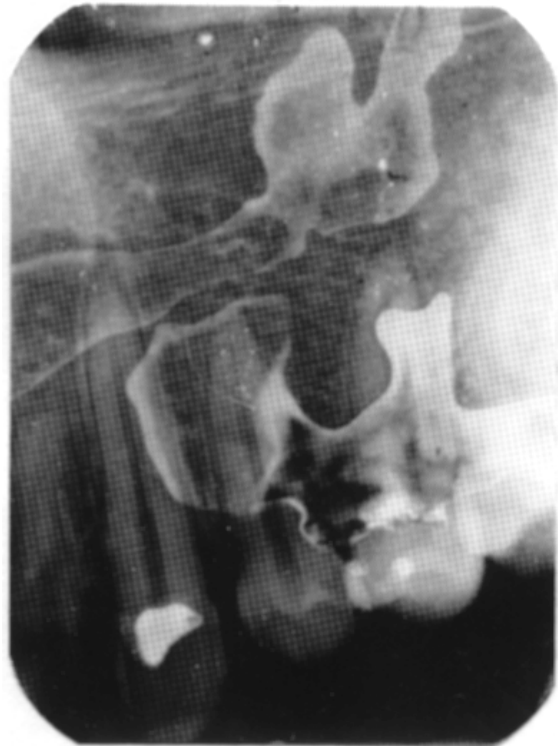

Figure 3-17. Stained or streaked film.

### 3-17. BLEACHED IMAGE

A bleached image (see figure 3-18) is caused by leaving the film in a freshly-mixed fixing solution too long or at a temperature that is too warm.

### 3-18. LEAD-FOIL IMAGE

A lead-foil image (see figure 3-19) occurs when the embossing pattern from the lead foil backing appears on the radiograph. The embossing pattern consists of raised diamonds across both ends of the film. This happens when the film is put in backwards.

### 3-19. NO IMAGE

No image may result if no current was passing through the tube at the time of exposure or if the film was placed in the fixing solution before it was placed in the developing solution.




Figure 3-18. Bleached image.

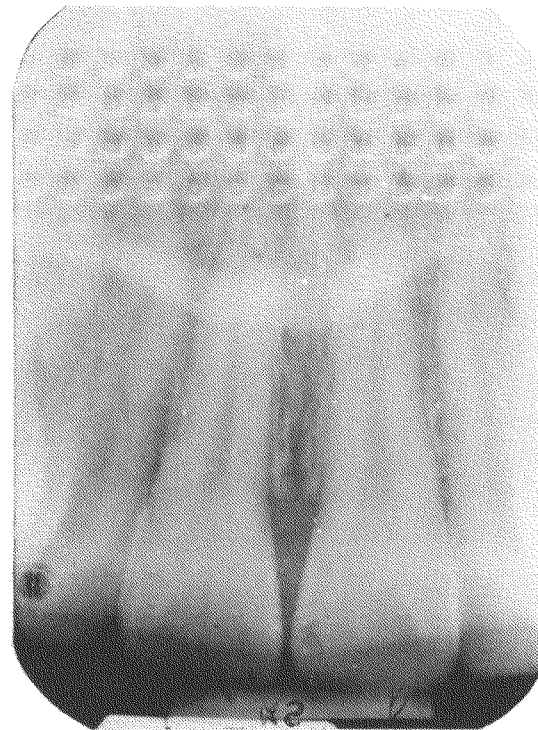


Figure 3-19. Lead-foil image.

### 3-20. RETICULATION

A reticulated film appears as a network of wrinkles or corrugations on the emulsion of the x-ray film. When reticulation occurs, the finished film has a netlike or puckered appearance resulting from swelling of the film's gelatin. Swelling is caused by sudden changes in temperature during processing, as in the transfer from a cool fixing bath to warm wash water or from a warm rinse water to a cool fixing bath.

## Section IV. MOUNTING AND FILING/DISPOSING OF RADIOGRAPHS

### 3-21. GENERAL

Cardboard or plastic mounts for 16-film, full-mouth radiographs and bite-wing mounts are available as standard items of dental supply. Sections of these, or small paper envelopes, are used for protecting and identifying individual periapical or bite-wing radiographs. The film mounts are designed so that the film may be arranged in the same order as the teeth in the mouth. Thus, mounting not only protects and labels the radiographs, but also facilitates viewing and studying of the film, particularly in full-mouth examinations. See figure 3-20.

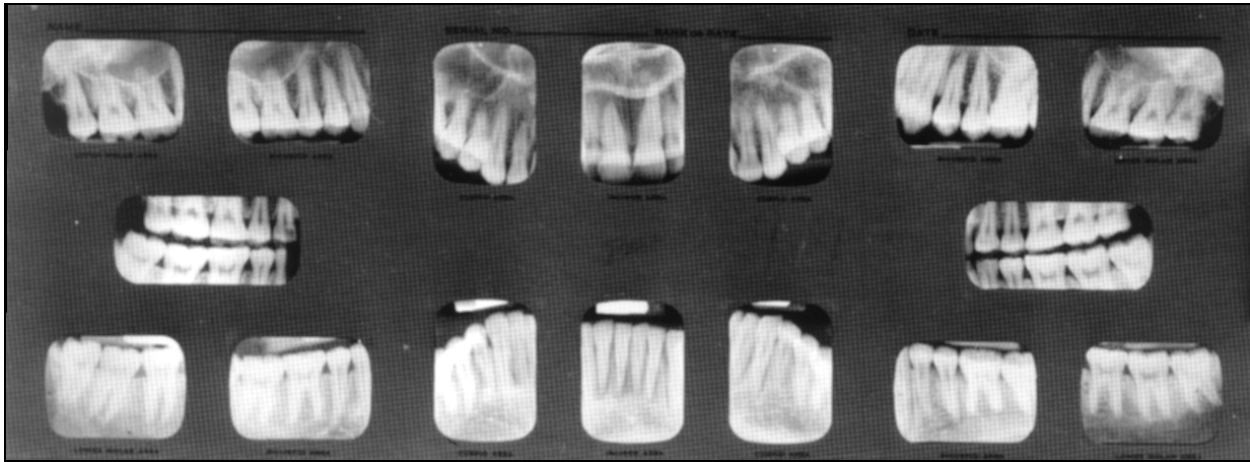


Figure 3-20. Full-mouth radiographic mount.

### 3-22. MOUNTING

In mounting radiographs, care must be taken to avoid marks from damp or perspiring fingers. Hands and fingers should be clean and dry. The film should be handled only on the edge. Under adequate illumination, the radiographs are removed one at a time from the hanger and placed carefully into the appropriate opening in the film mount. Radiographs are mounted so that the raised part of the embossed dot faces the dental specialist. In this way the radiographs are viewed from the facial aspect in correct anatomical order.

a. Maxillary and mandibular radiographs may be identified by the anatomy of the teeth and surrounding structures. (See paragraphs 3-24 through 3-28 for anatomic landmarks.) Radiographs are mounted with apices of maxillary teeth directed upward and apices of mandibular teeth directed downward.

b. The mesial aspect of a radiograph may also be determined by the anatomic features of tissues included on the film. If the mesial is to the right (when viewed from the facial side), it is a film taken on the patient's right side. If the mesial is to the left (when viewed from the facial side), it is a film taken of the patient's left side.

### 3-23. FILING AND DISPOSING

Dental radiograph holders or containers should be identified with the patient's name, rank, and other pertinent information, such as date and teeth, or area, included in the films. See Subcourse MD0510, General Duties of the Dental Specialist. Guidance for filing, transferring, and disposing of records is contained in AR 340-18 and other army regulations.

a. **The Dental Health Record.** Dental radiographs needed for future treatment or follow-up observation of a patient are kept in the dental health record.

b. **Disposition of Radiographs.** Some radiographs may be kept for extended periods if the dental officer deems necessary. These radiographs may serve as history with regard to future treatment of the patient.

## Section V. ANATOMIC RADIOGRAPHIC LANDMARKS

### 3-24. GENERAL

A number of anatomic landmarks are visible in dental radiographs. Knowledge of the location and normal appearances of these landmarks is important in identification and orientation of radiographs. This knowledge is valuable to the dental officer in determining whether the area is normal or abnormal. The landmarks that appear as dark areas on the film are radiolucent. The areas that appear as light areas on the film are radiopaque. Anatomic characteristics and the relationship between individual teeth are anatomic landmarks with which all dental specialists should be familiar.

### 3-25. RADIOLUCENT LANDMARKS ON MAXILLARY RADIOGRAPHS

a. **Maxillary Sinus.** The maxillary sinus (see figure 3-21) is a very prominent radiolucent structure. It sometimes appears as overlapping lobes or a single radiolucent area with a radiopaque border. The maxillary sinus is partially seen in all periapical radiographs of the bicuspid-molar area. It occupies a large part of the body of the maxilla, varying greatly in dimension, but normally extending into the alveolar process adjacent to the apices of the posterior teeth.

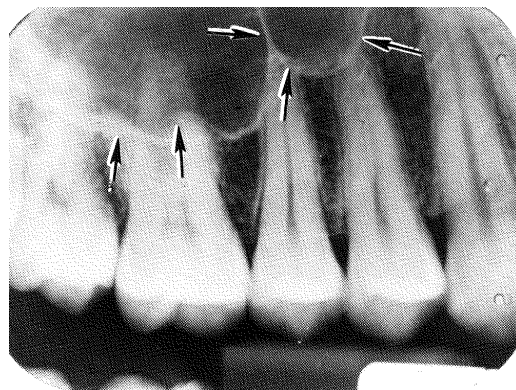


Figure 3-21. Maxillary sinus.



b. **Incisive Foramen.** The incisive foramen (see figure 3-22) is seen as a dark area located between and extending above the central incisors. In radiographs exposed from the region of the cuspid or lateral incisor, the incisive foramen may appear as a radiolucency at the apex of one of the incisors.

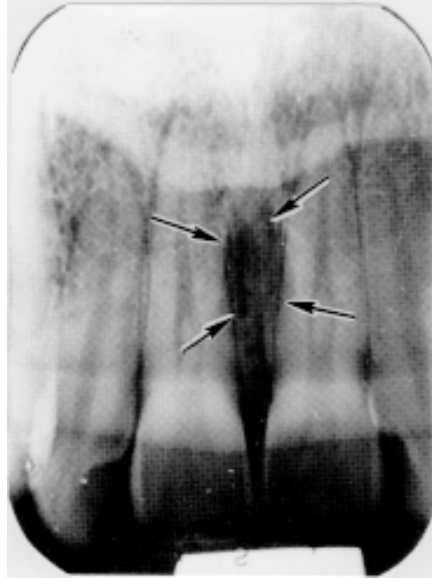


Figure 3-22. Incisive foramen.

c. **Median Palatal Suture.** The median suture of the palate (see figure 3-23) may appear as a radiolucent line extending posteriorly from the alveolar border in the sagittal plane of the maxilla, on an anterior periapical film, or occlusal film.

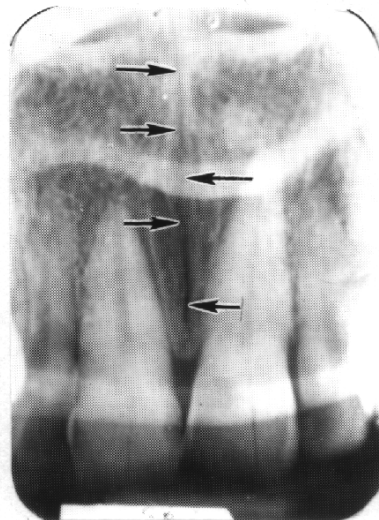


Figure 3-23. Median palatal suture.

d. **Nasal Fossae.** In a radiograph of the maxillary central incisors, the images of the paired fossae appear as somewhat elliptical radiolucent areas of various sizes separated by a radiopaque band representing the nasal septum (see figure 3-24).

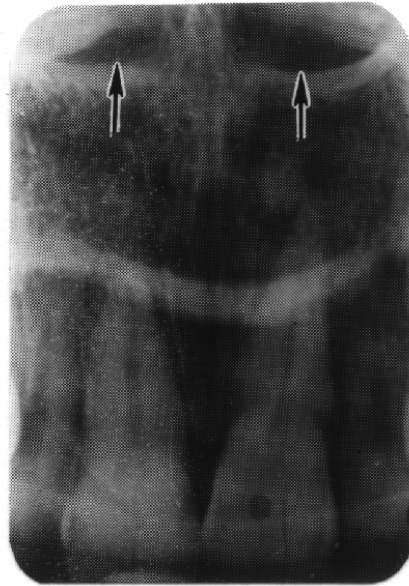


Figure 3-24. Nasal fossae.

### 3-26. RADIOPAQUE LANDMARKS ON MAXILLARY RADIOGRAPHS

a. **Maxillary Tuberosity.** The maxillary tuberosity (see figure 3-25) is the convex distal inferior border of the maxilla, curving upward from the alveolar process and distal of the third molar. An extension of the maxillary sinus is occasionally seen within the maxillary tuberosity.

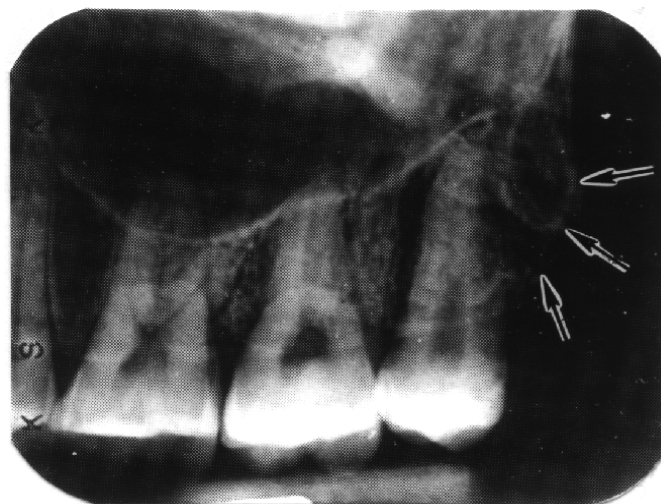


Figure 3-25. Maxillary tuberosity.

b. **Coronoid Process of the Mandible.** The coronoid process of the mandible (see figure 3-26) sometimes appears on maxillary molar films as a triangular opaque area located in the region of or distal to the maxillary tuberosity.

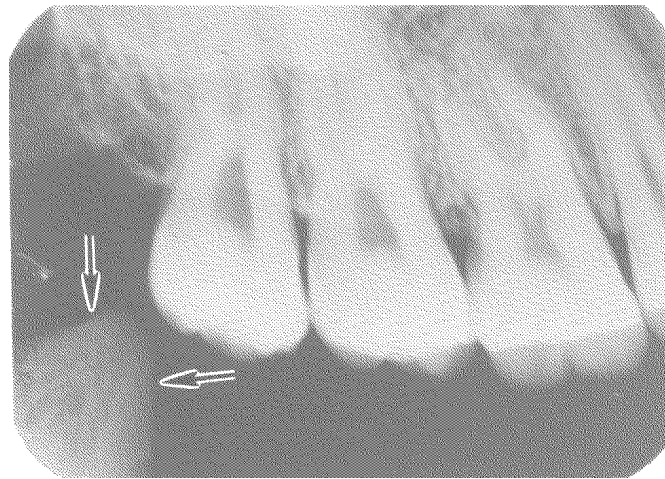


Figure 3-26. Coronoid process of the mandible.

c. **Zygomatic Process (Malar Bone).** The zygomatic arch (see figure 3-27) commonly appears as a well-defined radiopaque area that may be superimposed over the molar roots. Additional radiographs are sometimes made at adjusted angulation to provide a better view of the molar root area.

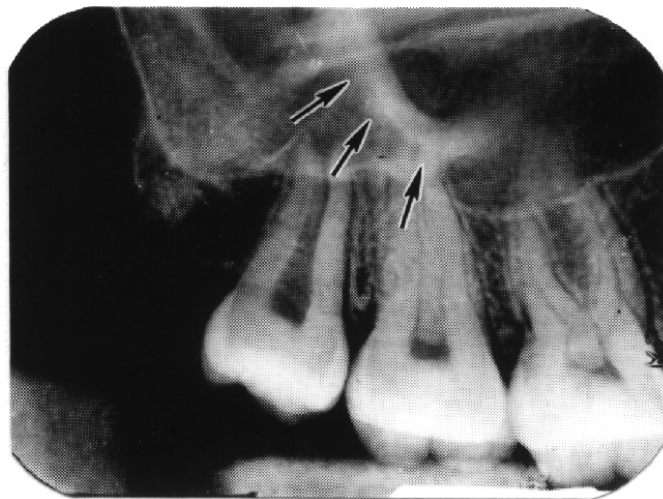


Figure 3-27. Zygomatic process (malar bone).

d. **Nasal Septum.** The nasal septum is usually seen as a white ridge extending above and between the central incisors.

### 3-27. RADIOLUCENT LANDMARKS ON MANDIBULAR RADIOGRAPHS

a. **Mandibular Foramen.** The mandibular foramen is seen on extraoral mandibular films as a dark area near the middle of the mandibular ramus.

b. **Mandibular Canal.** The mandibular canal (see figure 3-28) appears as a dark band with radiopaque borders running downward and forward from the mandibular foramen in the ramus to the region of the bicuspid teeth in the body of the mandible. It may be seen below the roots of the posterior teeth.

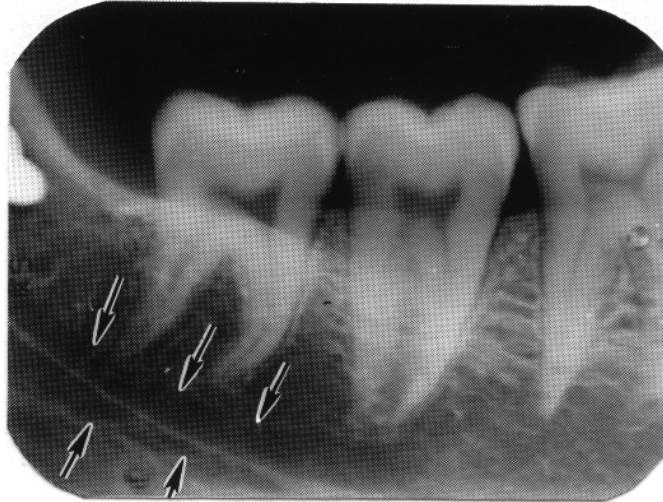


Figure 3-28. Mandibular canal.

c. **Mental Foramen.** The mental foramen (see figure 3-29) is seen as a dark area below and between the bicuspids. Since it is not contiguous with either bicuspid, its relationship to these teeth appears different on radiographs made at different angulations.

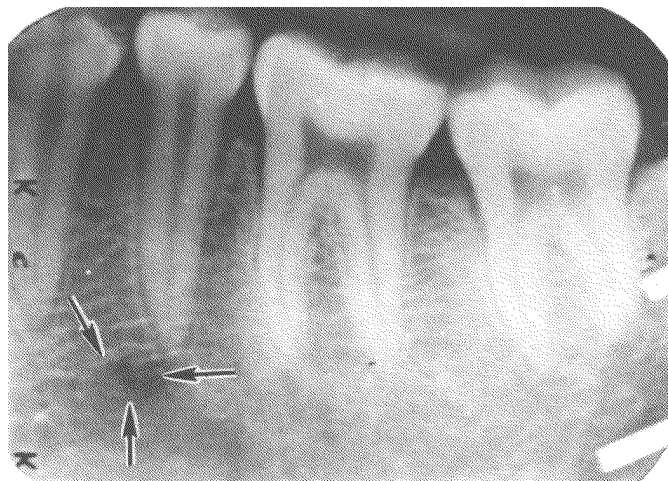


Figure 3-29. Mental foramen.

### 3-28. RADIOPAQUE LANDMARKS ON MANDIBULAR RADIOGRAPHS

a. **Border of the Mandible.** The border of the mandible is seen as a heavy white line (see figure 3-30). A similar line does not appear on maxillary radiographs.

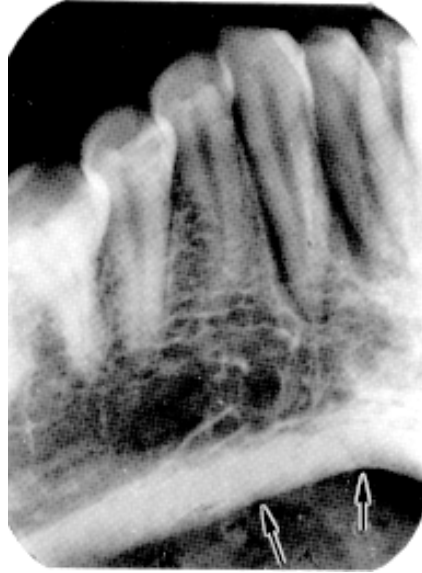

Figure 3-30. Border of the mandible.

b. **External Oblique Ridge.** The external oblique ridge is a white line of variable density extending into the molar region as a continuation of the anterior border of the ramus of the mandible (see figure 3-31).

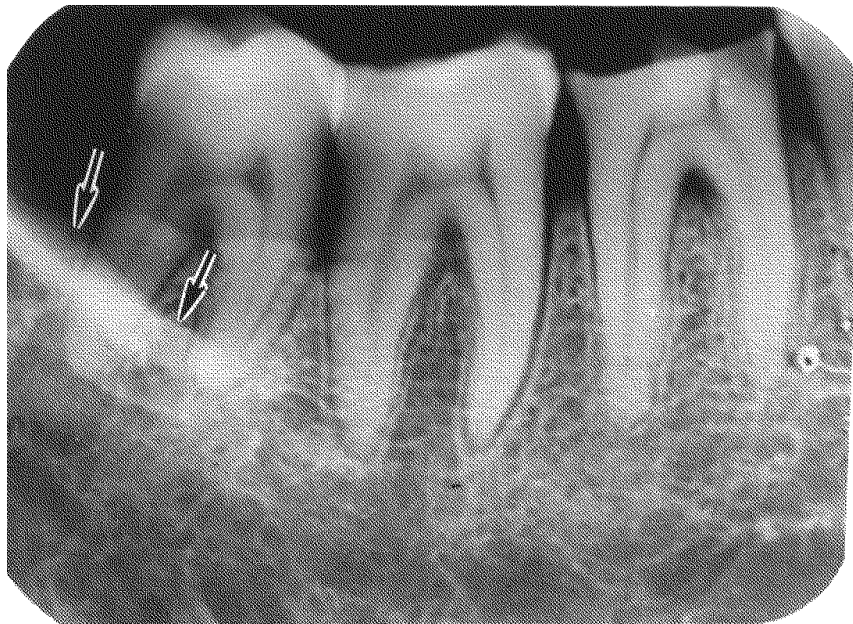


Figure 3-31. External oblique ridge.

c. **Genial Tubercles.** Genial tubercles are seen as round white areas, having dark centers, located below and between the central incisors (see figure 3-32).

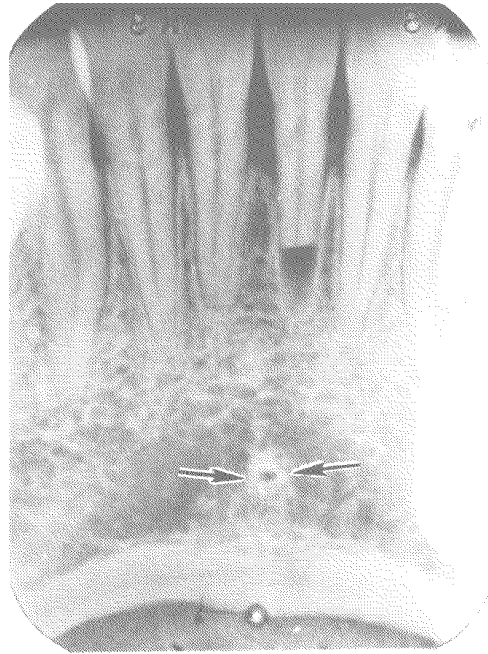


Figure 3-32. Genial tubercles.

d. **Mental Process (Mental VRidge).** The mental ridge may appear as a dense white ridge of varying density extending from the anterior midline to the bicuspid region, usually located below the anterior teeth, but occasionally superimposed over the apices.

e. **Mylohyoid Ridge (Internal Oblique Ridge).** The mylohyoid ridge appears as a white line of varying width and indensity, extending from close to the lower border of the symphysis of the mandible, upward and distally, to end beyond the third molar. It reaches its greatest prominence in the molar region. It is generally not a prominent feature.

**Continue with Exercises**

### EXERCISES, LESSON 3

**INSTRUCTIONS:** Answer the following exercises by marking the lettered response that best answers the question or best completes the incomplete statement or by writing the answer in the space provided.

After you have completed all the exercises, turn to "Solutions to Exercises" at the end of the lesson and check your answers.

1. List four exposure factors that are essential for obtaining satisfactory radiographs.

---

---

---

---

2. Where should film be stored?

---

---

3. What is the emulsion on dental radiographic film?

---

4. How can you identify dental x-ray films (intraoral films) for mounting purposes?

---

5. What size periapical film is used for radiography of children's teeth?

---

6. Why are intensifying screens used with extraoral film?

---

7. The cassette is constructed of rigid metal, plastic, or cardboard and often contains intensifying screens that:

---

8. The panoramic film shows:

---

9. The compartments of the dental processing tank are sectioned to contain the:

---

10. What is the cycle duration time for an automatic processor to process the film?

---

11. List the necessary conditions and equipment needed in a darkroom.

---

---

---

---

12. A thermometer is used in the darkroom to:

---

13. List the sequence to follow when processing film.

---

---



14. What three factors may produce a processed film that is overexposed?

---

---

---

15. A blurred image may be caused by:

---

16. Failure to immerse the film completely in the developing solution, contact of the film with another film during developing, and improper alignment of the central ray are factors which cause a/an:

---

17. List five factors that can cause fogged film.

---

---

---

---

---

18. List the radiolucent landmarks seen on maxillary radiographs.

---

---

---

---

19. List the radiopaque landmarks seen on maxillary radiographs.

---

---

---

20. List the radiolucent landmarks seen on mandibular radiographs.

---

---

---

21. List the radiopaque landmarks seen on mandibular radiographs.

---

---

---

---

---

**FOR EXERCISES 22 THROUGH 32.** Read each statement carefully. Complete the statement with one of the terms or set of terms listed below:

**fixation  
reticulation  
processing**

**darkroom  
ten minutes  
twenty minutes**

**mounts  
viewing  
lead-foil image**

**distorted image  
stained or  
streaked film**

22. For the \_\_\_\_\_ procedure, the radiograph is mounted in a suitable frame and labeled for proper identification.
23. Precise methods in the \_\_\_\_\_ of the x-ray films are as important in attaining good results as is the use of precise exposure technique.
24. Since x-ray films are more sensitive to light than most photographic films, it is important to have a good \_\_\_\_\_ for processing the film.
25. During the first state of \_\_\_\_\_, unexposed silver crystals are removed from the film, thereby clearing the film and making the image translucent.
26. An average time for the film to remain in a fresh fixing solution is \_\_\_\_\_.
27. Upon completion of fixation, the film should be immersed in fresh, cool, circulating water at least \_\_\_\_\_ minutes to ensure complete removal of the fixing solution.
28. A \_\_\_\_\_ may be caused by improper angulation of the central ray due to bending of the film packet.
29. \_\_\_\_\_ may be caused by dirty solutions, dirty film holders or hangers, or incomplete washing.
30. When a film is positioned backwards, the embossing pattern from the backing appears on the radiograph, producing a \_\_\_\_\_.
31. When \_\_\_\_\_ occurs, the finished film has a netlike or puckered appearance resulting from swelling of the film's gelatin.
32. Film \_\_\_\_\_ are designed so that the film may be arranged in the same order as the teeth in the mouth.

**Check Your Answers on Next Page**

## SOLUTIONS TO EXERCISES, LESSON 3

1. type of emulsion  
density of the tissues to be radiographed  
target-film distance  
characteristics of the exposing rays (para 3-2)
2. Film should be stored in a cool, dry place free from chemical contamination because high temperatures, moisture, and certain chemicals will cause deterioration of the film's emulsion. (para 3-3)
3. The emulsion of the film is a thin coating of a special gelatin with minute particles of a silver compound. (para 3-3a(1))
4. An embossed dot (a raised spot) to identify right and left. This assists mounting radiographs in correct anatomical order. (para 3-3a(2))
5. A small size periapical film (Type O) measuring  $7/8 \times 1 \frac{3}{8}$  inches. (para 3-3b(1)(a))
6. To intensify the effects of the exposing rays and lessen the exposure time. (para 3-3b(2)(a))
7. Magnify the x-ray beam, thus reducing exposure time. (para 3-3b(2)(b))
8. The entire dentition and surrounding bone structure. (para 3-3b(3))
9. Developing solution, water, and fixing solution. (para 3-8a)
10. Four to six minutes. (para 3-7)
11. cleanliness  
thermometer  
timer  
film holders  
processing solutions  
sink  
illumination  
specific construction (para 3-6a-h)
12. To register the temperature of the solutions. (para 3-6c)

13. develop  
rinse  
fix  
wash  
dry (para 3-8b)
14. Too much radiation exposure.  
Too much development time.  
Use of a developing solution that is too warm. (para 3-11)
15. Movement of the patient, film, or tube during exposure. (para 3-12)
16. partial image. (para 3-13)
17. Exposure of film to light during storage.  
Leaving film unprotected in the x-ray room during operation of the x-ray machine.  
Use of film that has been exposed to heat or chemical fumes.  
Use of improperly mixed or contaminated developer.  
Defective safelight. (para 3-15)
18. maxillary sinus  
incisive foramen  
median palatal suture  
nasal fossae (para 3-25a-d)
19. maxillary tuberosity  
coronoid process of the mandible  
zygomatic process and nasal septum (para 3-26a-d)
20. mandibular foramen  
mandibular canal  
mental foramen (para 3-27a-c)
21. border of the mandible  
external oblique ridge  
genial tubercles  
mental process  
mylohyoid ridge (para 3-28a-e)
22. viewing (para 3-4c)
23. processing (para 3-5)
24. darkroom (para 3-6a)

25. fixation (para 3-8e)
26. ten minutes (para 3-8e)
27. twenty minutes (para 3-8f)
28. distorted image (para 3-14)
29. stained or streaked film (para 3-16)
30. lead-foil image (para 3-18)
31. reticulation (para 3-20)
32. mounts (para 3-21)

**End of Lesson 3**

## LESSON ASSIGNMENT

### LESSON 4

Radiographic Exposure Techniques

### LESSON ASSIGNMENT

Paragraphs 4-1 through 4-42.

### LESSON OBJECTIVES

After completing this lesson, you should be able to:

- 4-1. List the types of intraoral radiographic film.
- 4-2. Identify standard patient head positioning techniques.
- 4-3. Identify steps of procedure for placement of film packets in a patients mouth.
- 4-4. Identify the bisecting angle (short-cone) periapical exposure techniques.
- 4-5. Identify the paralleling (long-cone) periapical exposure techniques.
- 4-6. Identify the interproximal (bite-wing) exposure techniques.
- 4-7. Identify the occlusal exposure techniques.
- 4-8. Identify the panoramic exposure technique.

### SUGGESTION

After studying the assignment, complete the exercises at the end of this lesson. These exercises will help you to achieve the lesson objectives.

## LESSON 4

### RADIOGRAPHIC EXPOSURE TECHNIQUES

#### Section I. INTRODUCTION

##### 4-1. GENERAL

Diagnostic and treatment procedures cannot be performed satisfactorily without a variety of radiographic exposure techniques. The dental specialist should be able to properly position the patient, the tube head, and the x-ray film for intraoral or panoramic film exposures. He must also be able to read and to follow manufacturer's instructions accurately.

##### 4-2. INTRAORAL RADIOGRAPHY

Most dental radiographs are made on intraoral film. An intraoral radiograph is made with the film held in the mouth during exposure. Intraoral radiographs taken in closer relation to the object give more detail than is possible with extraoral radiographs, which are taken from outside the mouth, and have less superimposition of shadows.

##### 4-3. TYPES OF INTRAORAL RADIOGRAPHIC FILM AND THEIR PURPOSES

a. **Periapical.** The periapical film provides information concerning the entire tooth and adjacent tissues.

b. **Bite-wing (Interproximal).** The bite-wing film aids in the detection and determination of depth of caries or other defects of the coronal two-thirds (the crown portion) of opposing teeth and the surrounding alveolar crest.

c. **Occlusal.** The occlusal film provides a means of examining larger areas of the jaws and does so from a different angle than is possible with other intraoral methods. It is valuable in locating and diagnosing fractures, salivary duct stones, and impacted teeth. Occlusal radiographs are used much less than periapical and interproximal radiographs.

##### 4-4. PLACEMENT OF FILM PACKETS

Several factors must be considered in the placement and stabilization of intraoral film packets to achieve satisfactory results.

a. Ensure that the film is positioned correctly.

b. Center the film lingual to the tooth/teeth (except the bicuspid) being radiographed.



c. Avoid movement of the film during exposure.

d. In placing the film packet in the mouth, avoid contact between the film and oral tissues until the film is in approximately the desired position. Many patients tend to gag when film is moved along in contact with oral tissues. Patience and gentleness will help to reduce gagging. Allowing anesthetic lozenges to dissolve on the tongue before film is placed in the mouth is sometimes helpful. Instructing the patient to breathe deeply through the nose also aids in controlling the gag reflex.

#### 4-5. PERIAPICAL RADIOGRAPHIC TECHNIQUES

Periapical radiography is designed to give diagnostic images of the apical portions of teeth and their adjacent tissues. A full mouth intraoral examination consists of 14 periapical radiographs with two bite-wing films and provides an image of all teeth and related structures. Single periapical radiographs are often made of individual teeth or groups of teeth to obtain information for treatment or diagnosis of localized diseases or abnormalities. The bisecting (short-cone) and paralleling (long-cone) techniques are two of the most commonly used techniques. Both techniques have advantages and disadvantages. The dental officer's preference determines which technique will be used.

#### Section II. BISECTING (SHORT-CONE) PERIAPICAL EXPOSURE TECHNIQUES

#### 4-6. GENERAL

A short cone is used to take x-rays with bisecting angle exposure techniques. The target-film distance is 8 inches. The resulting image x-ray is somewhat larger using the short cone rather than using a long cone (see figure 4-1). The bisecting plane is halfway between the plane of the dental film and the longitudinal axis of the tooth. The average angle of projection is the angle between the occlusal plane and the angle of the central ray. The angle of the central ray is in relation to the bisecting plane.

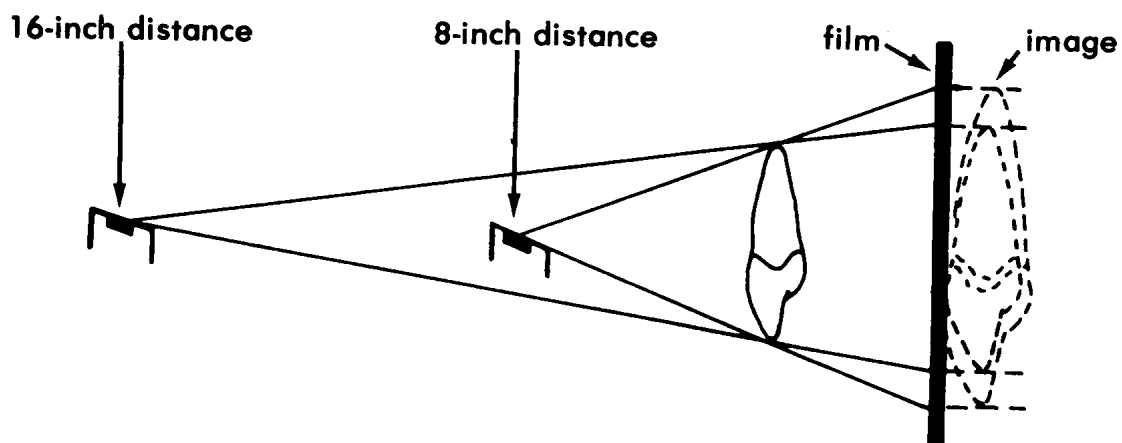


Figure 4-1. Comparison of 8-inch and 16-inch target-film distances.

## 4-7. POSITIONING THE PATIENT

Standard radiographic procedures include precise positioning of the patient's head as one step in placing film. The tissues to be radiographed and the x-ray beam must be in proper relationship to produce an accurate radiographic image. This is particularly important when using the bisecting angle technique. In adjusting the backrest and headrest, it is important to make the patient as comfortable as possible to minimize movement during exposure. As in photography, movement during exposure will result in a blurred image. Blurring may be greatly reduced through the use of ultra-speed film.

a. **Head Positioning in Radiography of the Maxilla Using the Bisecting Technique.** In radiography of the maxilla, the head should be positioned so that the occlusal surfaces of the maxillary teeth are in a horizontal plane (see figure 4-2). This is done by adjusting the headrest so that the median plane (sagittal plane) is vertical and a line from the ala of the nose to the tragus of the ear is horizontal.

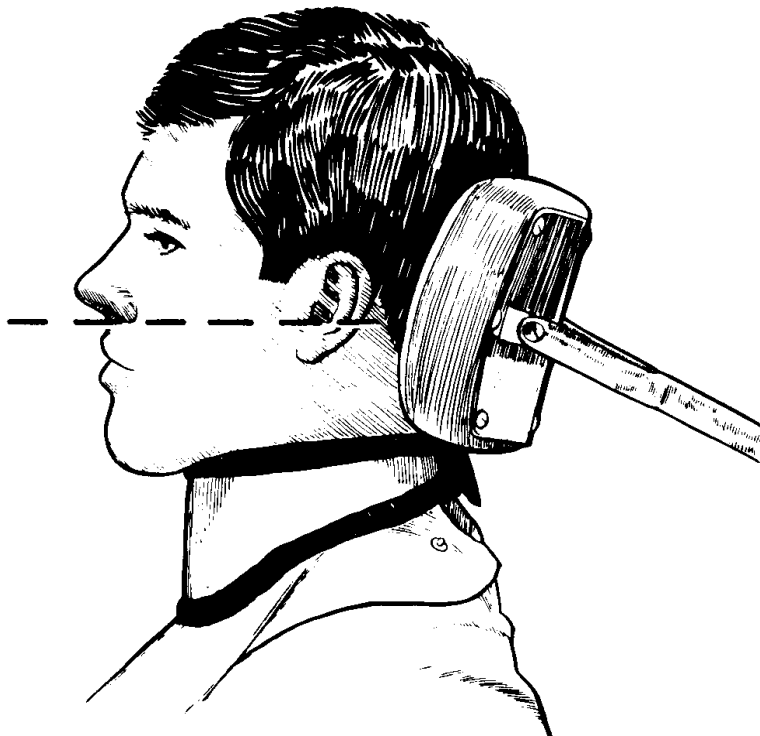


Figure 4-2. Head position for making maxillary periapical radiographs.

b. **Head Positioning in Radiography of the Mandible Using the Bisecting Technique.** In periapical radiography of the mandible, the head should be positioned so that the occlusal surfaces of the mandibular teeth will be horizontal when the mouth is opened to the position in which the radiographs are to be made (see figure 4-3). This is done by adjusting the headrest so the median plane is vertical and a line from the corner of the mouth to the tragus of the ear is horizontal.

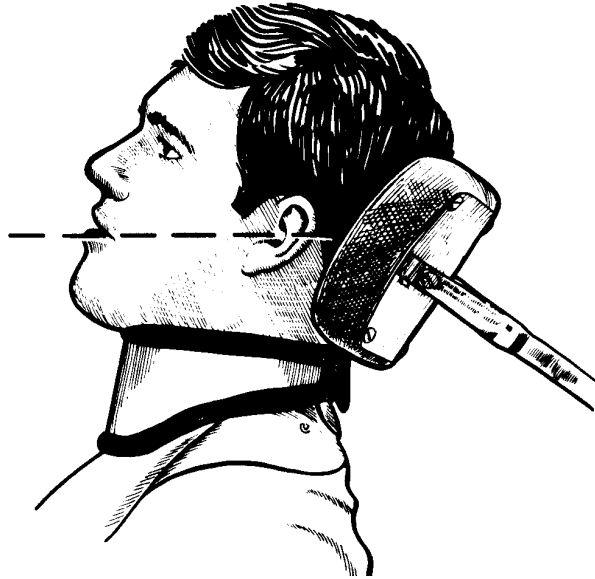


Figure 4-3. Head position for making mandibular periapical radiographs.

c. **Angulation.** When the cone is adjusted to project the central beam upward, it will be set at a negative (-) degree angulation. When it is adjusted to project the central beam downward, it will be set at a positive (+) angulation.

#### 4-8. CENTRAL RAY ANGULATION

The angle of the x-ray beam, the average angle of projection of the central ray, is essential for successful use of the bisecting exposure techniques. Both vertical and horizontal angulations must be considered.

a. Vertical angulation is the up-and-down movement of the tube head or x-ray beam. The correct vertical angulation exists when the central ray is directed perpendicular to the bisector of the angle formed by the long axis of the tooth and the plane of the film (see figure 4-4). When this angulation is correct, the vertical dimension of the tooth will be as realistic as possible. Incorrect vertical angulation may cause two problems--foreshortening or elongation.

(1) Foreshortening exists if the vertical angulation is larger than necessary. The image of the teeth appears smaller than normal (see figure 4-5).

(2) Elongation exists if the vertical angulation is less than is necessary. The image of the teeth appears larger than normal (see figure 4-6).

b. Horizontal angulation is the side-to-side movement of the tube head or x-ray beam. Correct horizontal angulation for successful radiographs exists when the central ray is perpendicular to the facial surfaces of the teeth and parallel to the mesial and distal surfaces (see figure 4-7). If the horizontal angulation is incorrect, overlapping will occur on the radiograph. Overlapping results when the proximal surfaces of adjacent

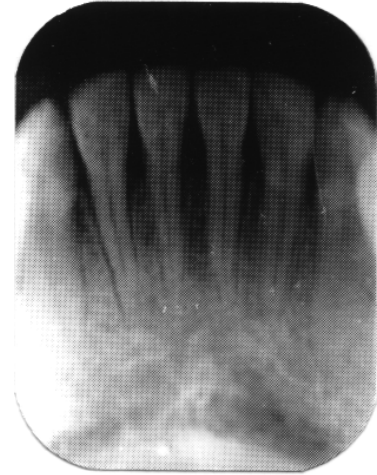
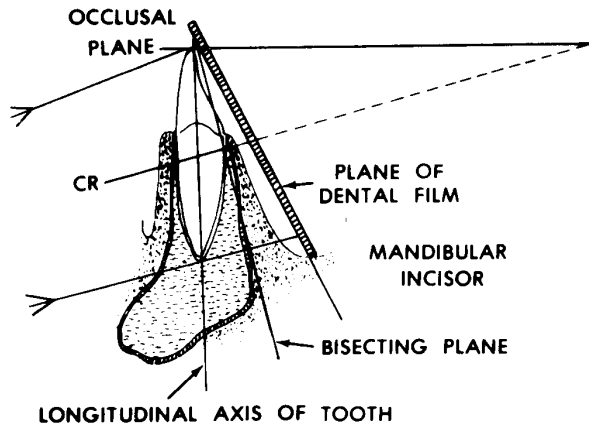


Figure 4-4. Correct projection of central ray.

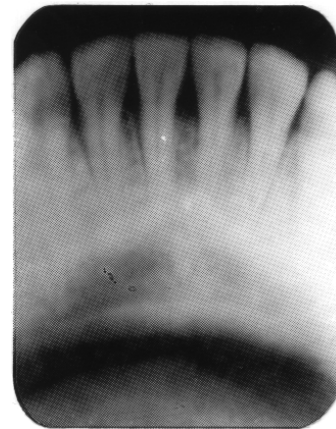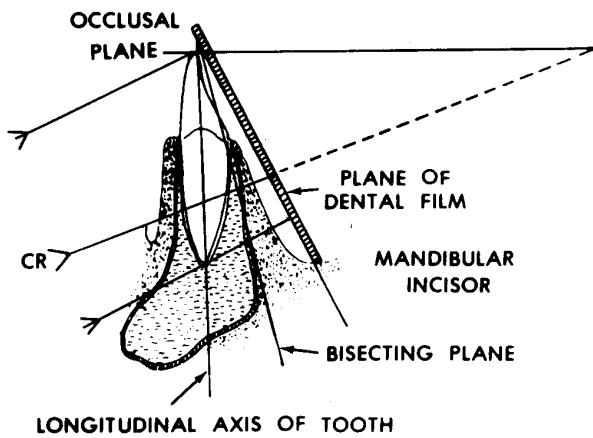


Figure 4-5. Foreshortened image caused by projection of central ray from an angle that is too great.

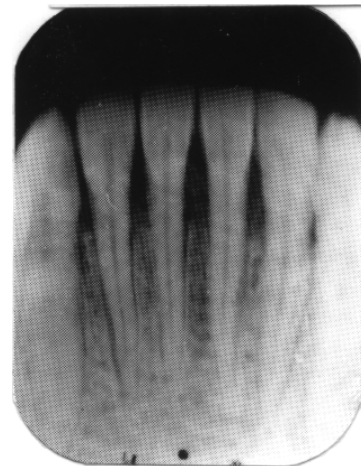
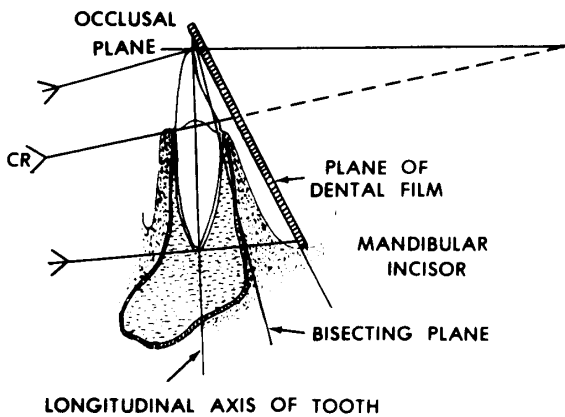


Figure 4-6. Elongated image caused by projection of central ray from an angle that is too small.

teeth are superimposed over one another (see figure 4-8). When this occurs, there will be a light area where the two teeth are overlapped or superimposed. The resultant light area is the inability of the x-ray beam to penetrate the two dense surfaces. Correct horizontal and vertical angulation of the x-ray beam is necessary to obtain radiographs of diagnostic quality.

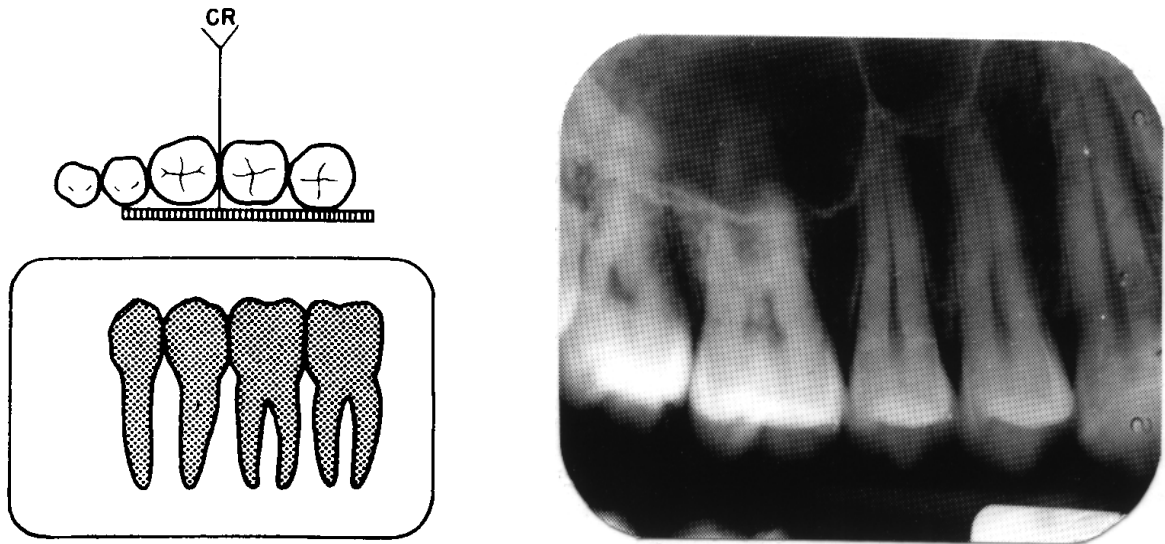


Figure 4-7. Correct image resulting from proper horizontal projection of the central ray.

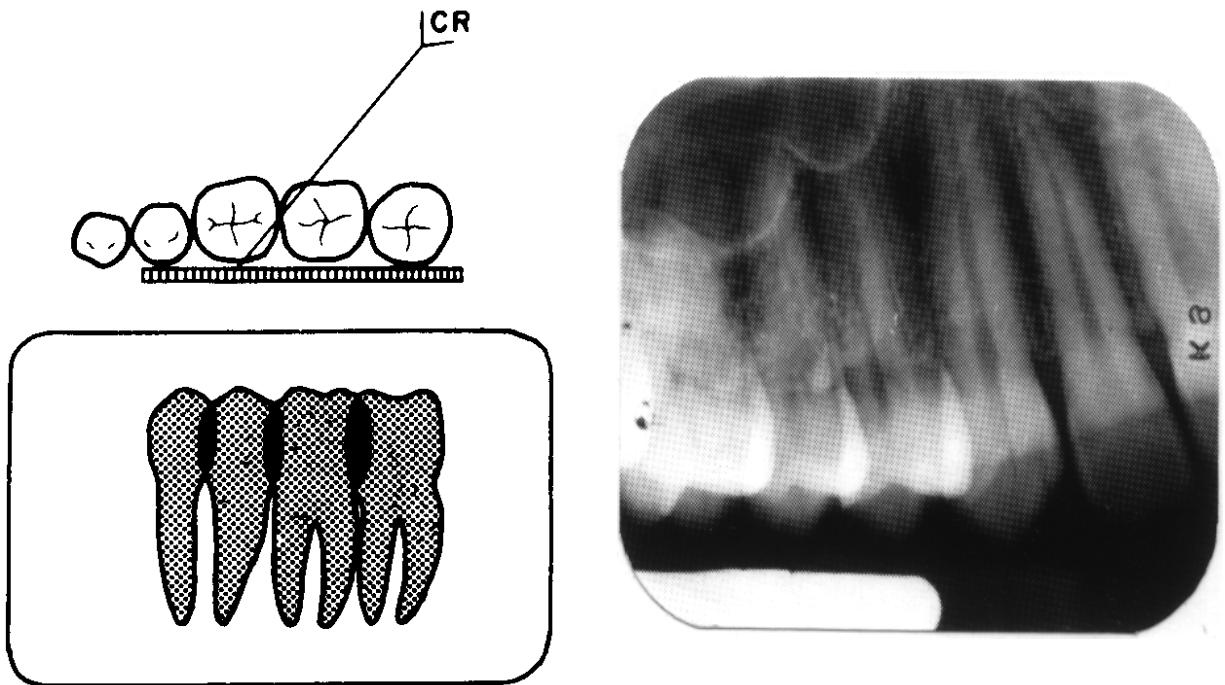


Figure 4-8. Overlapping images caused by incorrect horizontal projection of the central ray.

#### 4-9. OVERVIEW OF THE BISECTING ANGLE EXPOSURE TECHNIQUES

a. The bisecting method of periapical radiography is used to varying degrees in Army dental clinics. The dental specialist should be familiar with its techniques. The following paragraphs describe techniques using this method to produce a 14-exposure set of radiographs of an adult dentition. Discussion of the techniques for exposure of each area of the mouth will include illustrations and descriptions of film placement, film holding, direction of the central ray, and average angulation. Slight contouring of a corner may facilitate film placement in restricted areas of the mouth, such as those of the maxillary incisors or the maxillary third molar, and make it more comfortable. To shape the film, press it over the rounded contour of a finger to pre-adapt it to the position in the mouth. Use only slight contouring to prevent distortion of the image. (A flat image produces the best image.) Paragraph 4-7 covers proper head positioning and other instructions for intraoral radiography.

b. Various film holding devices may be used to secure the film in place when using the bisecting technique: the Rinn EEZEE-GRIP Film Holder, a hemostat, a plastic or Styrofoam film holder (with 105° angle) (see figure 4-9). When such film holding devices are not available, the finger or thumb may be used.

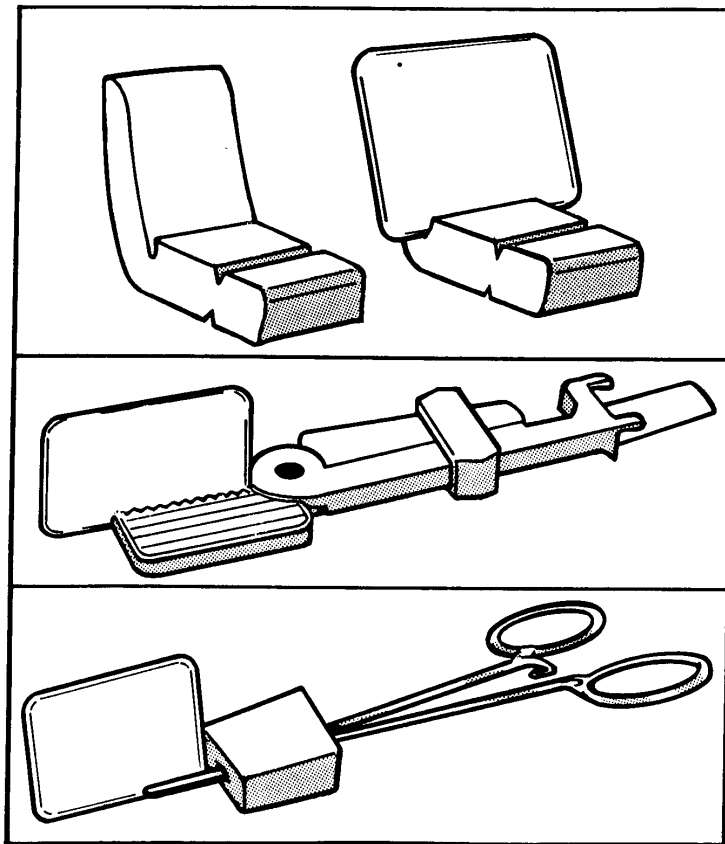


Figure 4-9. Film holding devices for the bisecting technique.

#### 4-10. MAXILLARY MOLARS

Adjust the head as described for radiographs of maxillary teeth (refer to paragraph 4-7a). Place the film packet in the mouth so that its long axis is horizontal, the anterior border of the film is lingual to the mesial border of the second bicuspid, and the lower border of the film is parallel to and slightly below (approximately 1/4 inch) the occlusal surfaces of the molars. The upper corner of the packet may be contoured slightly but the film packet should not be bent. Adjust the tube to an average angulation of  $+20^\circ$ . Direct the central ray straight through the interproximal spaces in the area of the second molar and perpendicular to the bisecting plane (see figure 4-10). Follow the manufacturer's instructions for all exposure times.

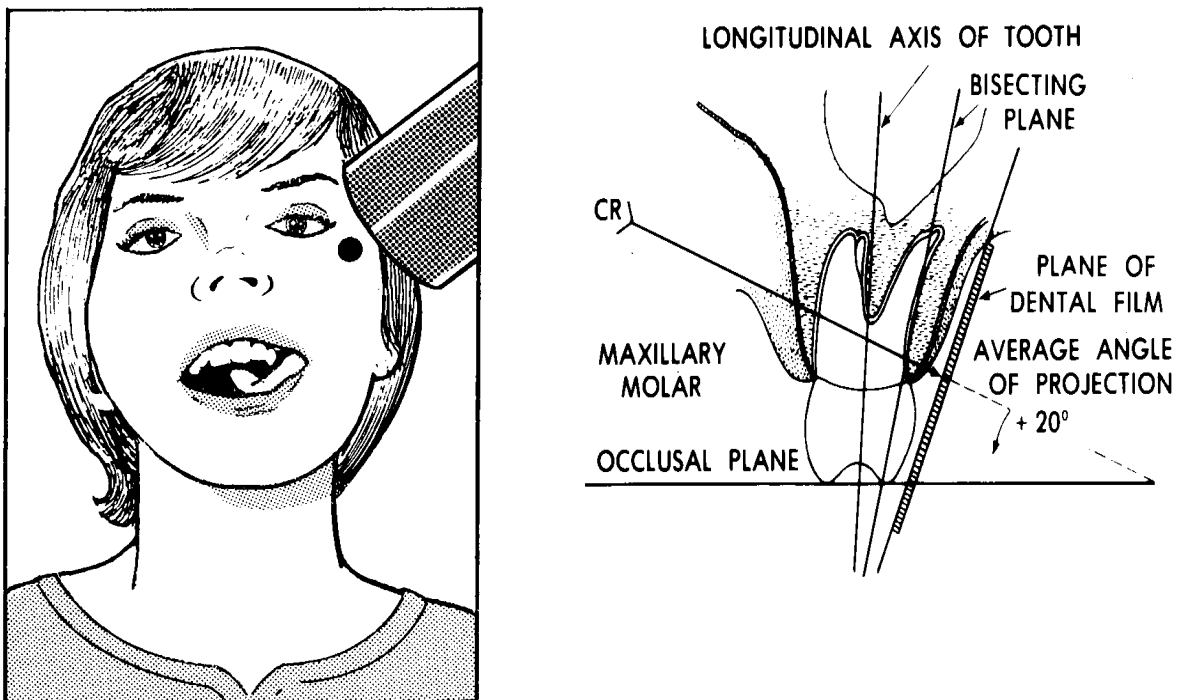


Figure 4-10. Maxillary molar area.

#### 4-11. MAXILLARY BICUSPIDS

Adjust the head as described for radiographs of maxillary teeth. Place the film packet in the mouth so that its long axis is horizontal and its anterior border is lingual to the mesial surface of the cuspid. Have its lower border paralleled to, and slightly below, the occlusal surfaces of the teeth (approximately 1/4-inch). Adjust the cone to an average angulation of  $+30^\circ$ . Direct the central ray straight through the interproximal spaces of the first and second bicuspids at the center of the film and perpendicular to the bisecting plane (see figure 4-11). Follow the manufacturer's instructions for all exposure times.

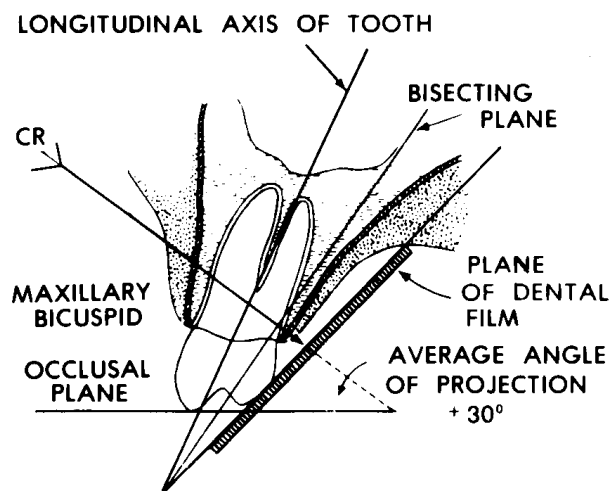


Figure 4-11. Maxillary bicuspid area.

#### 4-12. MAXILLARY CUSPIDS

Adjust the head as described for radiographs of maxillary teeth. Place the film packet in the mouth so that its long axis is vertical and its lower border is parallel to and slightly below (approximately 1/8 inch) the incisal edges of the lateral incisor and cuspid teeth. The anterior border of the film should lie lingual to the central incisor of the same side. The upper anterior corner of the film may be contoured slightly to fit the curvature of the maxillary arch. Adjust the cone to an average angulation of  $+45^\circ$ . Direct the central ray straight at the cuspid at the level of the root and perpendicular to the bisecting plane (see figure 4-12). Follow the manufacturer's instructions for exposure times.

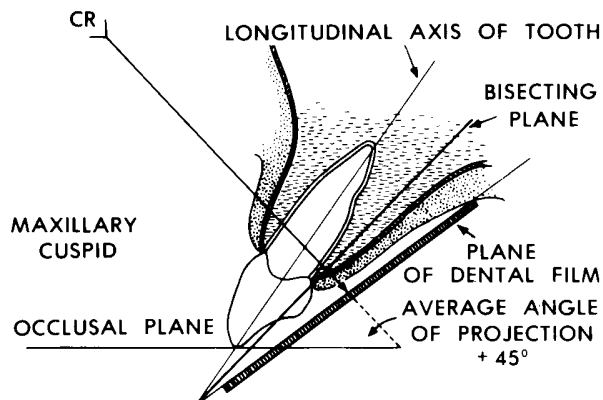



Figure 4-12. Maxillary cuspid area.



#### 4-13. MAXILLARY INCISORS

Adjust the head as described for radiography of maxillary teeth. Gently contour both long borders of the film slightly in the direction of the curvature of the palate. Place the film packet in the mouth so that its long borders are vertical and its center is in line with the median plane of the upper arch. Have the lower border of the packet slightly below (approximately 1/8 inch) and parallel to the incisal edges. Adjust the tube to an average angulation of  $+40^\circ$ . Direct the central ray to pass through the tip of the nose in line with the median plane and perpendicular to the bisecting plane (see figure 4-13). Follow the manufacturer's instruction for exposure times.

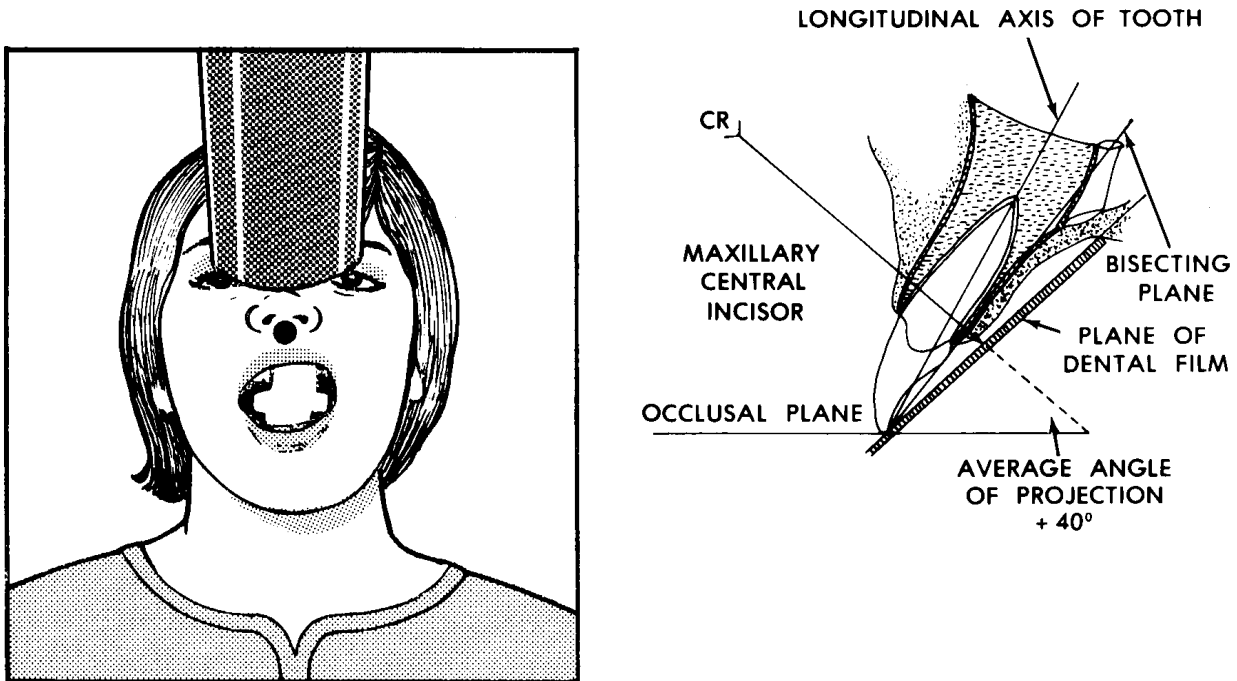


Figure 4-13. Maxillary incisor area.

#### 4-14. MANDIBULAR MOLARS

Adjust the head as described for radiographs of mandibular teeth (paragraph 4-7b). Place the packet in the mouth with the long axis horizontal and the upper border of the film parallel to, and slightly above (approximately 1/4 inch) the occlusal surfaces of the molar teeth. Relieve the lower anterior border by contouring. Place the packet alongside the tongue and far enough distally to include the entire third molar area. Impacted or malposed mandibular teeth may require special positioning of the film packet. Adjust the tube to an average angulation of  $-5^\circ$ . Direct the central ray straight through the interproximal spaces at the center of the film and perpendicular to the bisecting plane (see figure 4-14). Follow the manufacturer's instructions for exposure times.

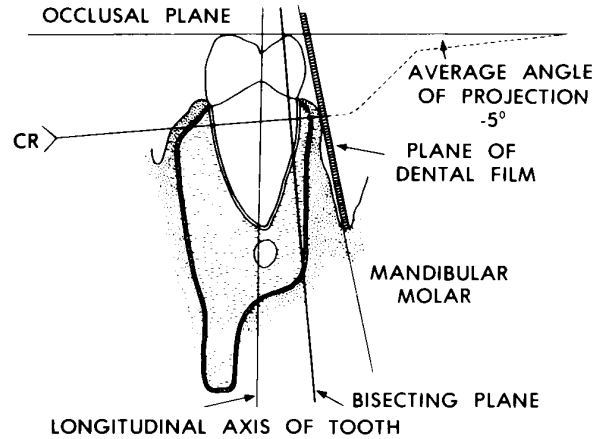


Figure 4-14. Mandibular molar area.

#### 4-15. MANDIBULAR BICUSPIDS

Adjust the head as described for radiographs of mandibular teeth. Place the film packet in the mouth with its long axis horizontal and its upper border parallel to and slightly above (approximately 1/4 inch) the occlusal surfaces of the teeth. Locate the anterior border of the film lingual to the mesial surface of the cuspid. The lower anterior border of the film should be contoured slightly to fit the curvature of the mandibular arch. Adjust the tube to an average angulation of  $-10^{\circ}$ . Direct the central ray straight through the interproximal spaces at the center of the film and perpendicular to the bisecting plane (see figure 4-15). Follow the manufacturer's instructions for exposure times.

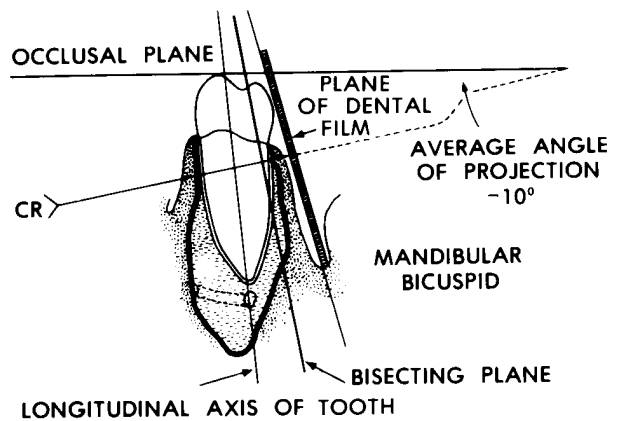


Figure 4-15. Mandibular bicuspid area.

#### 4-16. MANDIBULAR CUSPIDS

Adjust the head as described for radiographs of mandibular teeth. Place the film packet in the mouth with its long axis vertical and its upper border parallel to and slightly above (approximately 1/8 inch) the incisal edges of the lateral incisor and cuspid teeth. The film's anterior border should be located lingual to the distal surface of the opposite central incisor. Adjust the tube to an average angulation of  $-20^\circ$ . Direct the central ray straight through the bisecting plane (see figure 4-16). Follow the manufacturer's instructions for exposure times.

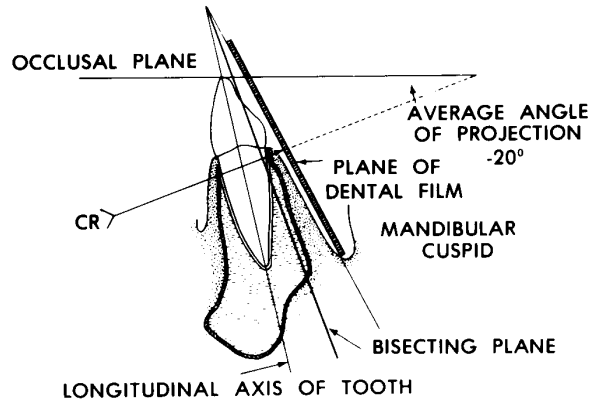


Figure 4-16. Mandibular cuspid area.

#### 4-17. MANDIBULAR INCISORS

Adjust the head as described for radiographs of mandibular teeth. Place the film packet in the mouth with the long axis vertical. Both the long borders of the packet should be placed under the tongue with the center of the film opposite the midline of the arch and the upper border parallel to and slightly above (approximately 1/8 inch) the incisal edges of the incisor teeth. Adjust the tube to an average angulation of  $-15^\circ$ . Direct the central ray straight through the interproximal spaces at the center of the film and perpendicular to the bisecting plane (see figure 4-17). Follow the manufacturer's instructions for exposure times.

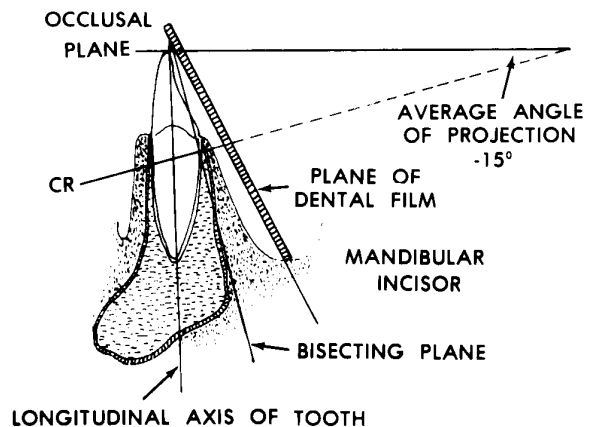



Figure 4-17. Mandibular incisor area.

### Section III. PARALLELING (LONG-CONE) PERIAPICAL EXPOSURE TECHNIQUES

#### 4-18. GENERAL

A long cone is used to take x-rays with paralleling exposure techniques. Periapical film is held parallel to the long axis of the tooth using film-holding instruments. The central ray is directed to pass at a perpendicular angle to both the tooth and the film. Since the slope and curvature of the dental arches and the alveolar processes will not permit the film to be held close to the teeth and still be parallel to their long axes, the film must be held away from the teeth. This method provides a target-film distance of approximately 16 inches, in contrast to 8 inches for the bisecting technique (see figure 4-1). The increase in the target-film distance is related to the size of the image produced. If the film is held away from the tooth and the target-film distance kept at 8 inches, enlargement of the image would be unavoidable. Enlargement is minimized, however, by increasing the target-film distance to 16 inches, thus using the parallel rays. An extension cone is used (see figure 4-18) to increase the target-film distance.

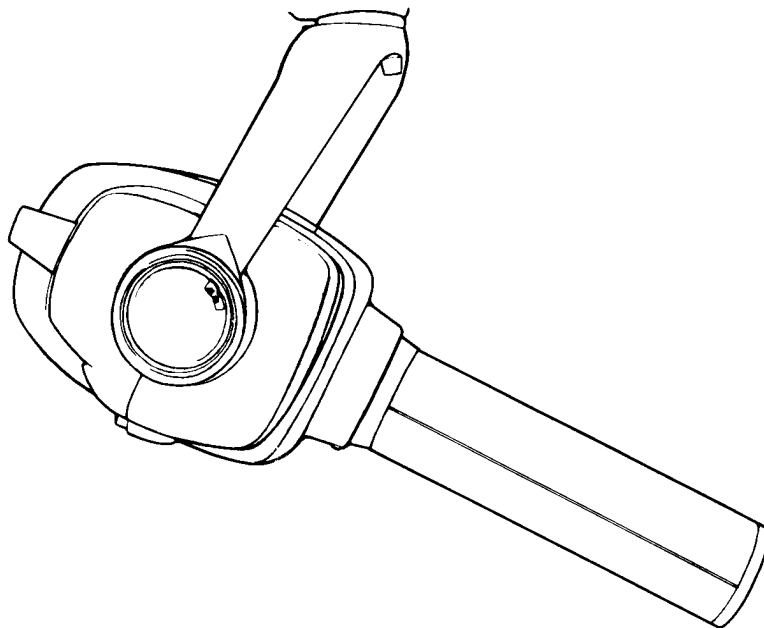


Figure 4-18. Long cone on x-ray unit.

#### 4-19. ASSEMBLY OF FILM-HOLDING INSTRUMENTS

The instruments used to hold the film parallel to the teeth are plastic bite-blocks, indicator rods, and plastic locator rings.

a. **Anterior Instrument.** The anterior instrument (see figure 4-19) is assembled and used as follows.

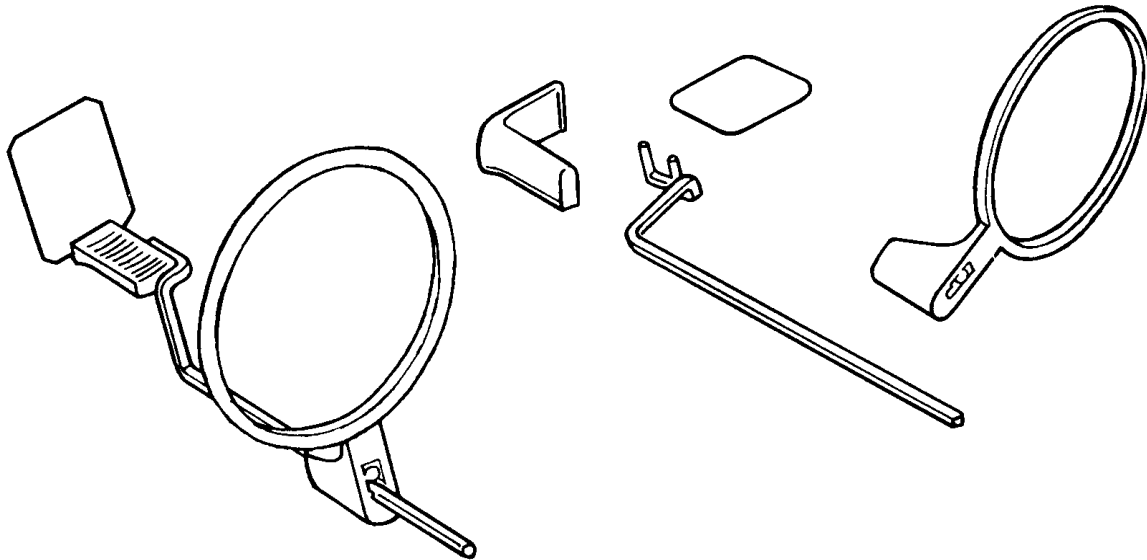


Figure 4-19. Anterior instrument assemblage.

(1) The shielded or printed side of the film packet is placed against the backing support of the bite-block.

(2) It is inserted vertically into the slot by using a downward motion and, at the same time, placing slight pressure against the backing support to open the slot.

(3) There is an embossed dot on the corner of the periapical film. This embossed dot is always placed in a downward position when placing the film into the slot on the plastic bite-block.

(4) The offset position of the indicator rod is held away from the biting surface of the block. The pins are inserted in the proper holes.

(5) The plastic locator ring is fitted onto the indicator rod opposite the film packet.

(6) The assembly is then positioned in the mouth.

b. **Posterior Instrument.** The posterior instrument (see figure 4-20) is assembled and used as follows:

(1) The shielded, printed or broken side of the film packet is placed against the backing support of the bite-block.

(2) It is inserted horizontally into the slot by using a downward motion and, at the same time, placing slight pressure against the backing support to open the slot.

(3) The embossed dot on the corner of the film is also placed in a downward position when placed in the plastic bite-block.

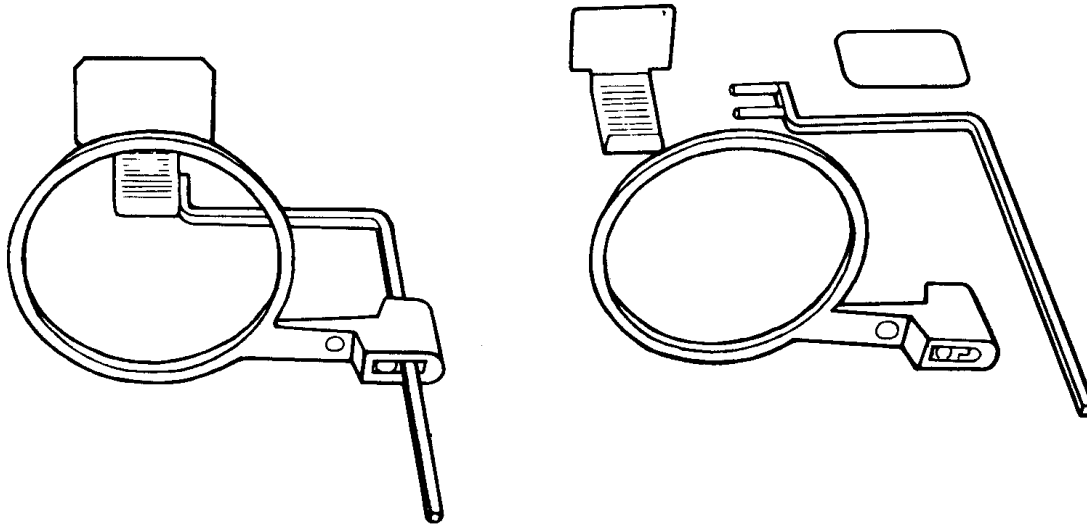


Figure 4-20. Posterior instrument assemblage.

(4) The right angle portion of the indicator rod is held anterior to the bite-block and away from the film.

(5) The pins are inserted into the proper holes. (The three holes allow a choice for the desired lingual positioning of the film.)

(6) The plastic locator ring is fitted onto the indicator rod opposite the film packet.

(7) The assembly is then positioned in the mouth.

#### 4-20. MAXILLARY MOLARS

Position the posterior instrument assembly in the patient's mouth, with the plastic bite-block centered on the second molar (see figure 4-21). Be sure that the anterior edge of the film is adjacent to the distal of the second bicuspid. Parallel the film with the long axis of the molars. Place a cotton roll between the underside of the teeth and the block and have the patient close his teeth in order to maintain the film position. Move the locator ring along the indicator rod to approximately the skin surface and align the x-ray unit extension tube with the rod and the ring on horizontal and vertical planes.

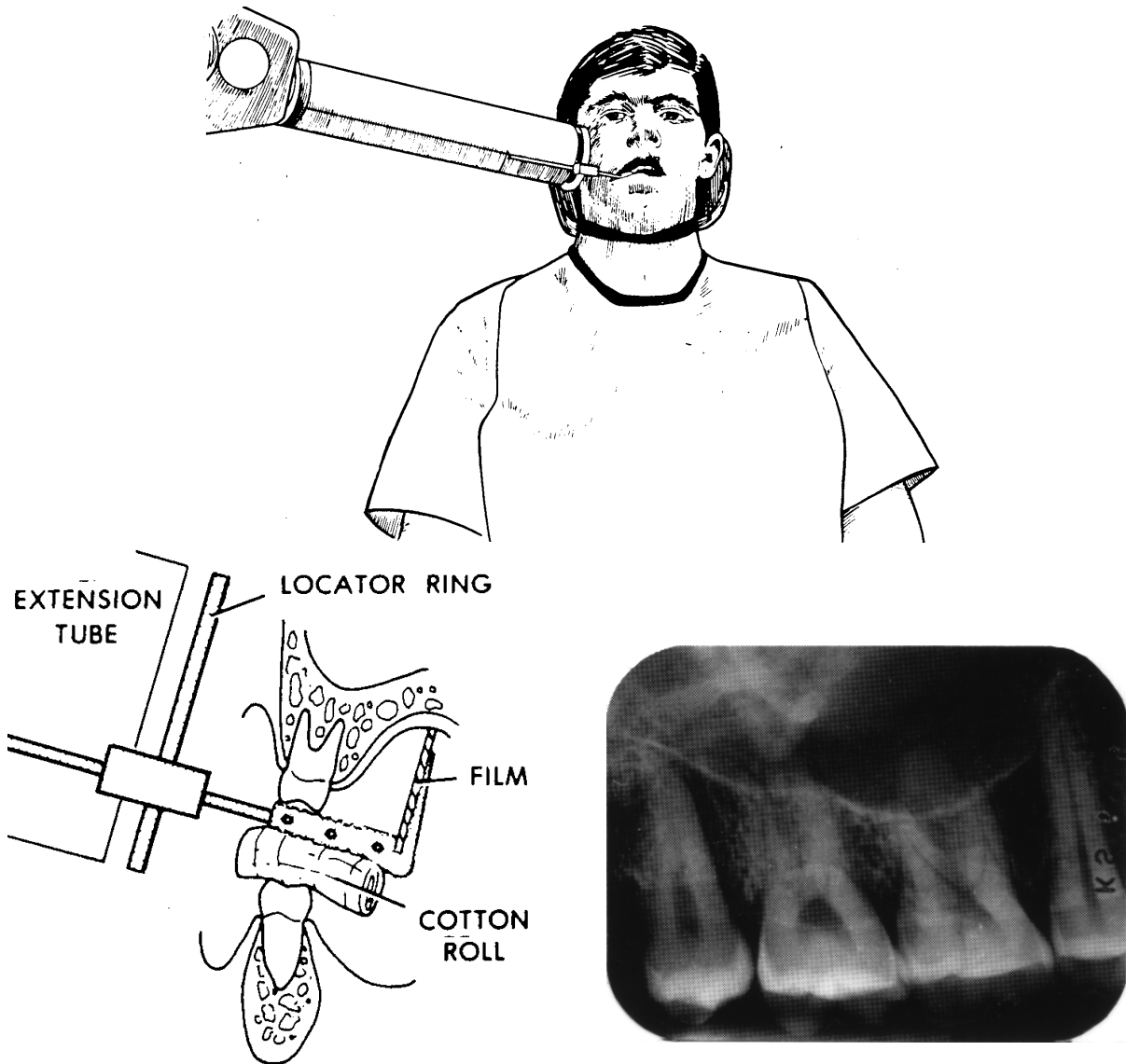


Figure 4-21. Maxillary molar area.

#### 4-21. MAXILLARY BICUSPIDS

Position the posterior instrument assembly in the patient's mouth with the bicuspid centered on the film parallel to the long axis of the teeth (see figure 4-22). Some patients have small mouths. Therefore, the bicuspid may not be centered on the film. The first priority is to parallel the film to the two bicuspid both vertically and possibly touching the anterior hard palate. Gently contour the anterior superior corner of the film to aid positioning. With the bite-block held on the occlusal surfaces of the maxillary bicuspid, insert a cotton roll between the underside of the block and the mandibular teeth. Have the patient close his teeth holding the film in place. Slide the locator ring along the indicator rod to approximate the skin surface and align the x-ray unit extension tube with the rod and the ring on the horizontal and vertical planes.

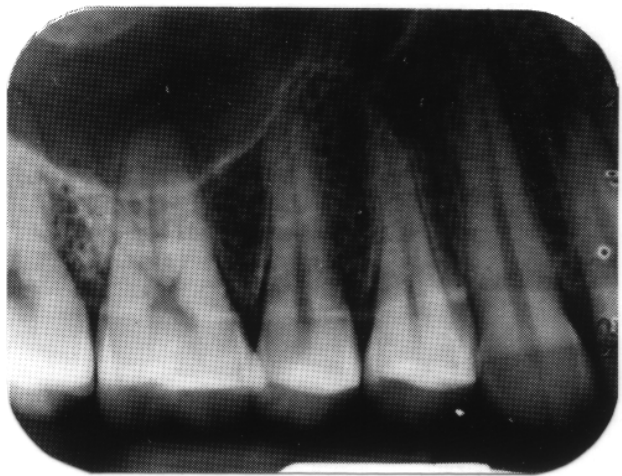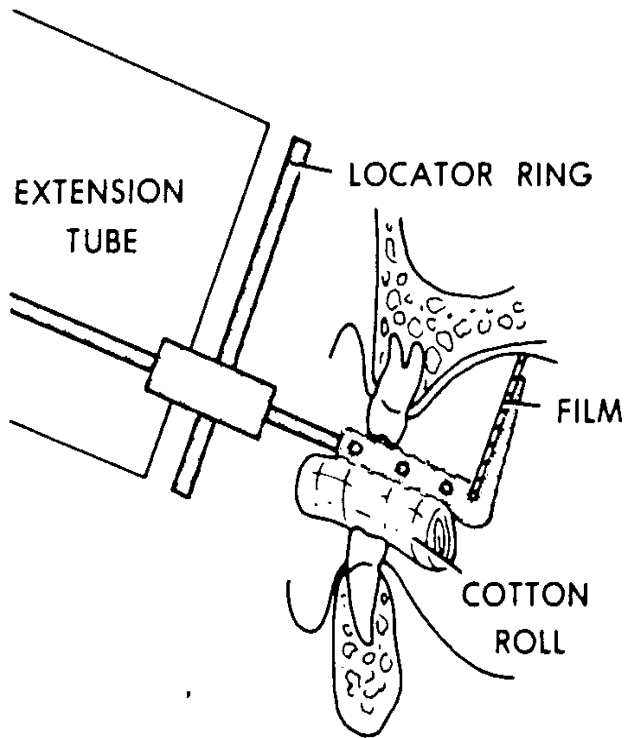
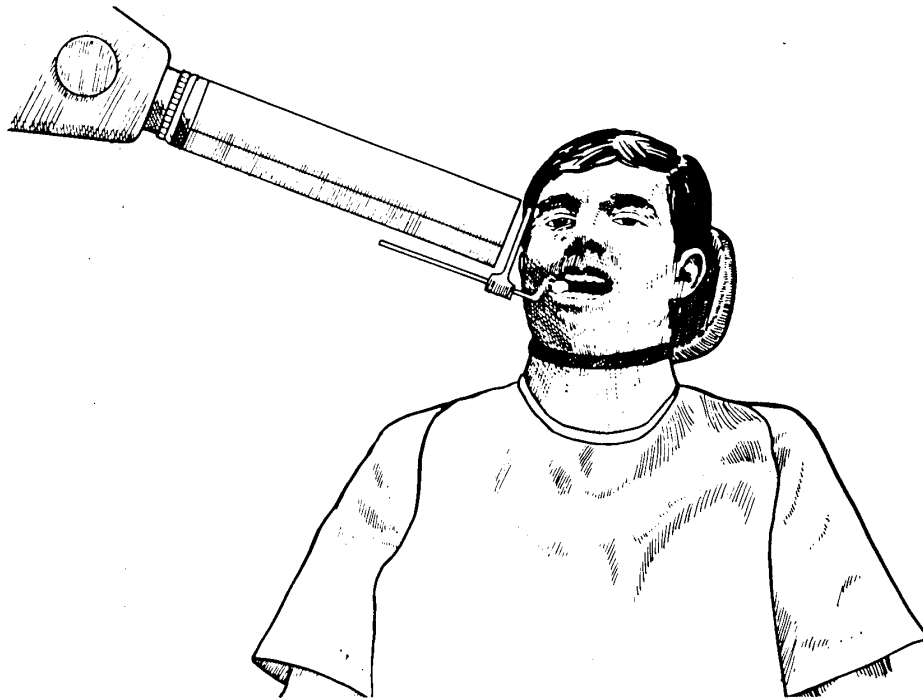


Figure 4-22. Maxillary bicuspid area.



## 4-22. MAXILLARY CUSPIDS

Using the anterior instrument assembly, position the cuspid tooth on the film parallel to the long axis of the tooth and center it (see figure 4-23). Gently contour the anterior corner of the film to maintain position. With the block resting on the maxillary cuspid, insert a cotton roll between the block and the mandibular teeth. Have the patient close his teeth holding the film in place. Slide the locator ring along the indicator rod bringing it close to the skin surface and align the x-ray unit extension tube with the rod and the ring on the vertical and horizontal planes.

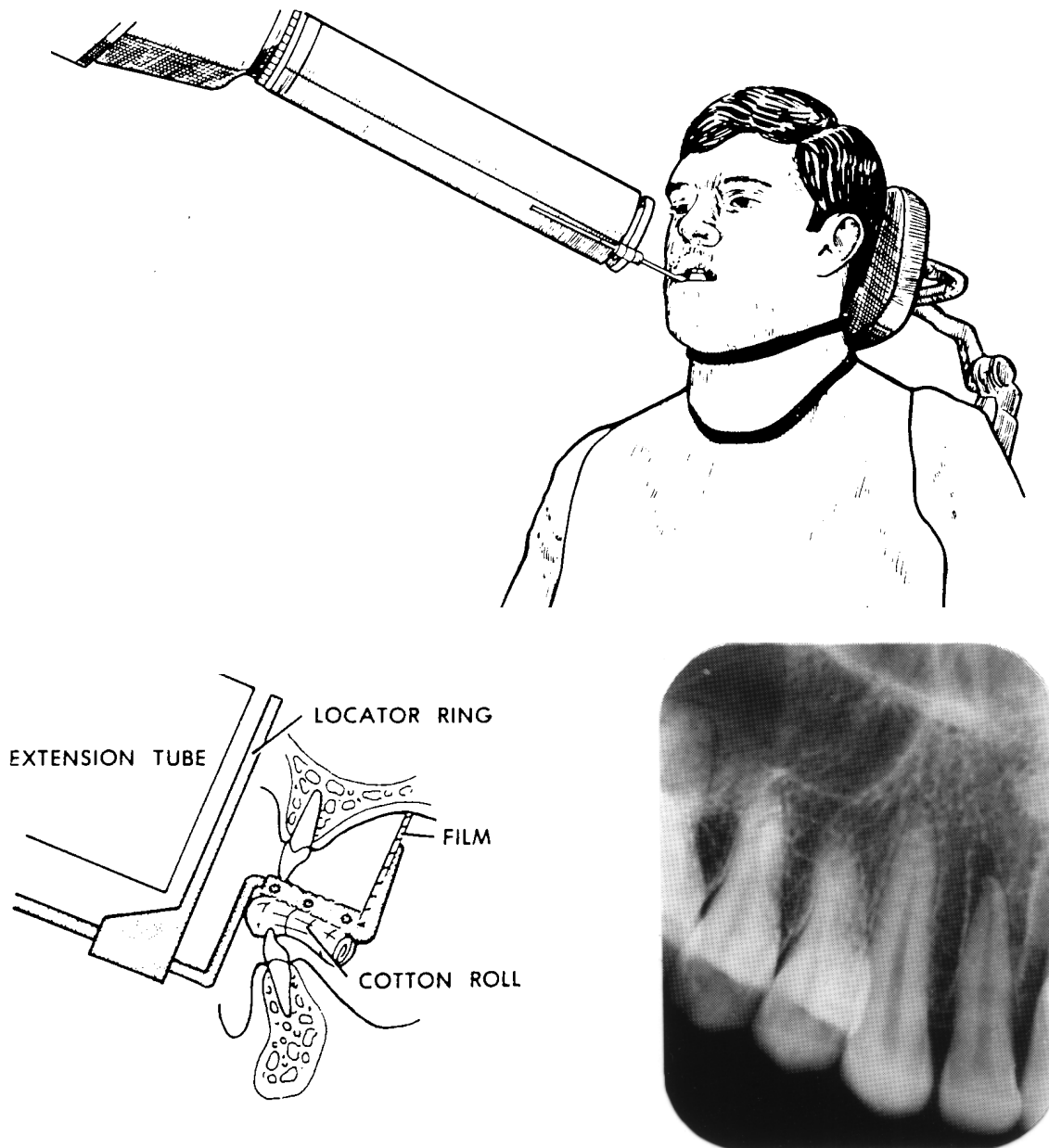


Figure 4-23. Maxillary cuspid area.

#### 4-23. MAXILLARY INCISORS

Using the anterior instrument assembly, center the film parallel to the long axis of the incisors, ensuring that it is lined up with the midline (see figure 4-24). Use the full length of the block to position the film distally to the region of the first molar. With the block resting on the incisal edges of the teeth to be x-rayed, insert a cotton roll between the mandibular incisors and the block. Have the patient close his teeth holding the film in place. Slide the locator ring along the indicator rod bringing it close to the skin surface and align the x-ray unit extension tube with the rod and the ring on the vertical and horizontal planes.

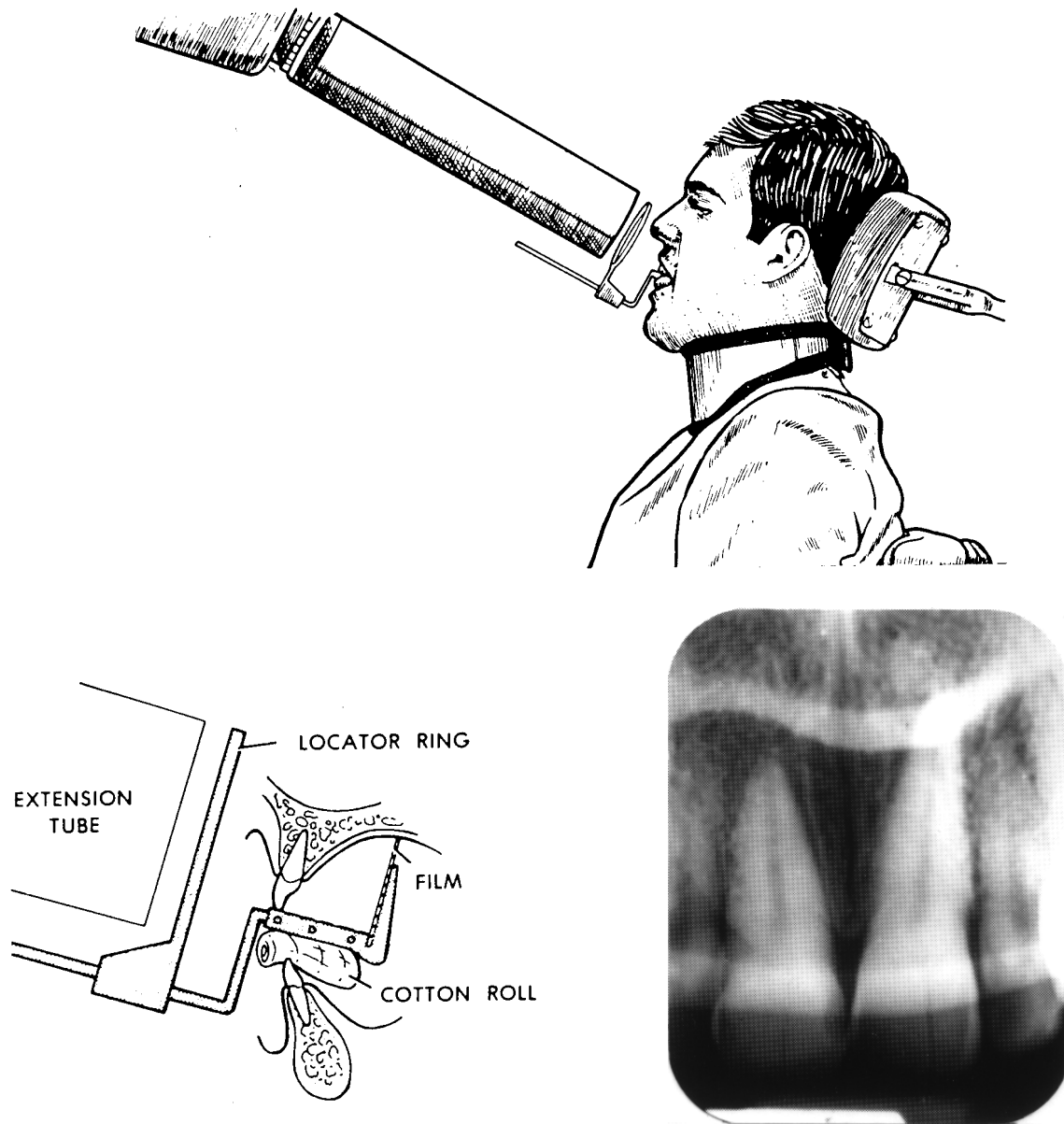


Figure 4-24. Maxillary incisor area.

#### 4-24. MANDIBULAR MOLARS

Position the posterior instrument assembly with the plastic bite-block centered on the second molar (see figure 4-25). Assure that the anterior edge of the film is adjacent to the distal end of the second bicuspid. Ensure that the film is parallel with the long axis of the molar teeth. Place a cotton roll between the block and the opposing maxillary teeth and have the patient close his teeth holding the film in place. Slide the locator ring along the indicator rod bringing it close to the skin surface and align the x-ray unit extension tube with both the rod and the ring on the horizontal and vertical planes.

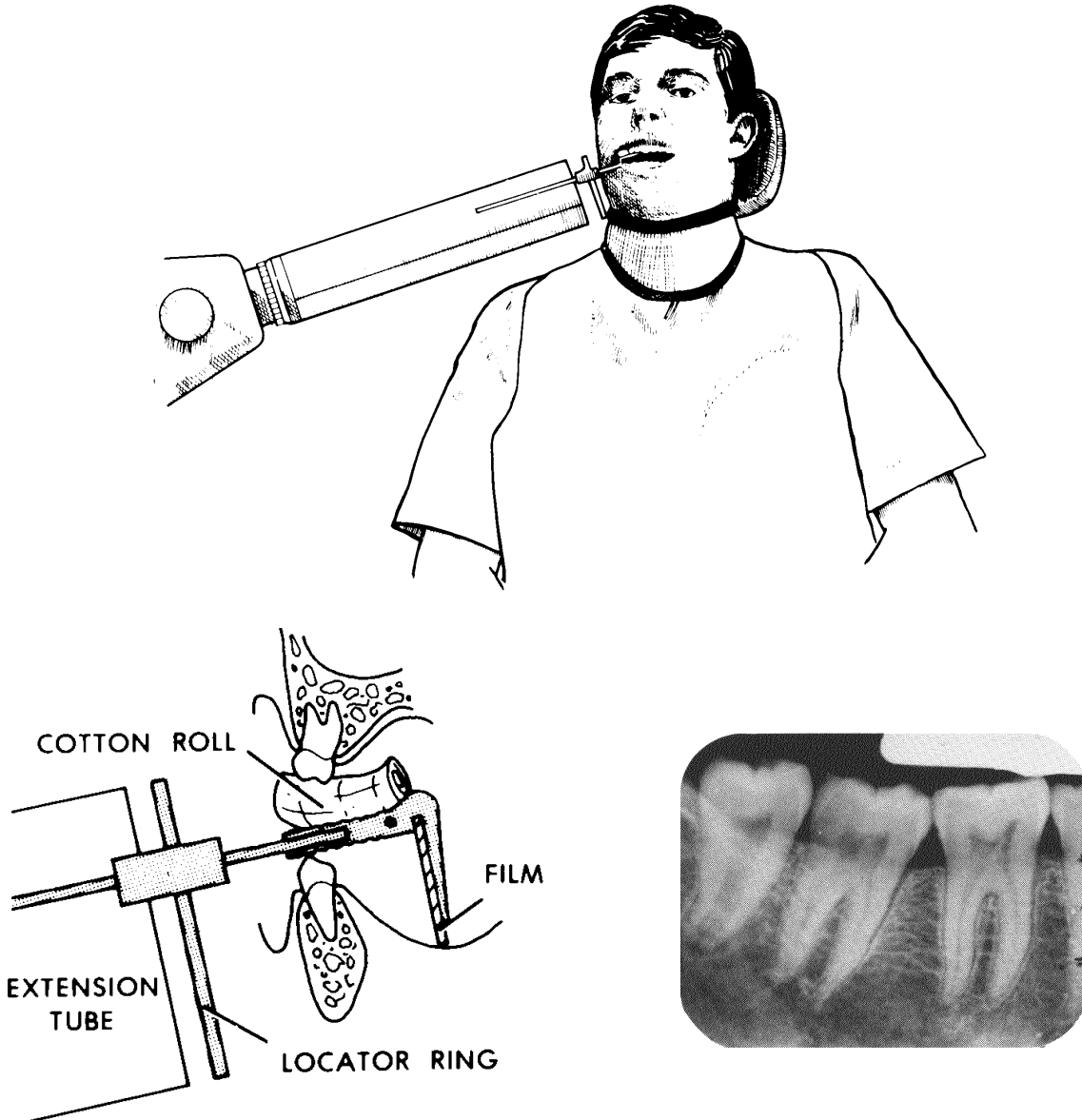


Figure 4-25. Mandibular molar area.

#### 4-25. MANDIBULAR BICUSPIDS

Position the instrument assembly in the patients mouth with the bicuspid centered on the film assuring that the film is parallel both vertically and horizontally. Centering the bicuspid may not be possible in patients with small mouths. Therefore, position the film in the center of the mouth as far forward as possible, touching the curvature of the lower arch (see figure 4-26). Parallel film placement is the key; it prevents dimensional distortion and overlapping. With the plastic bite-block held in place by the occlusal surfaces of the mandibular bicuspid, insert a cotton roll between the block and the maxillary teeth. Have the patient close his teeth holding the film in place. Slide the locator ring along the indicator rod bringing it close to the skin surface and align the x-ray unit extension tube with both the rod and the ring on the horizontal and vertical planes.

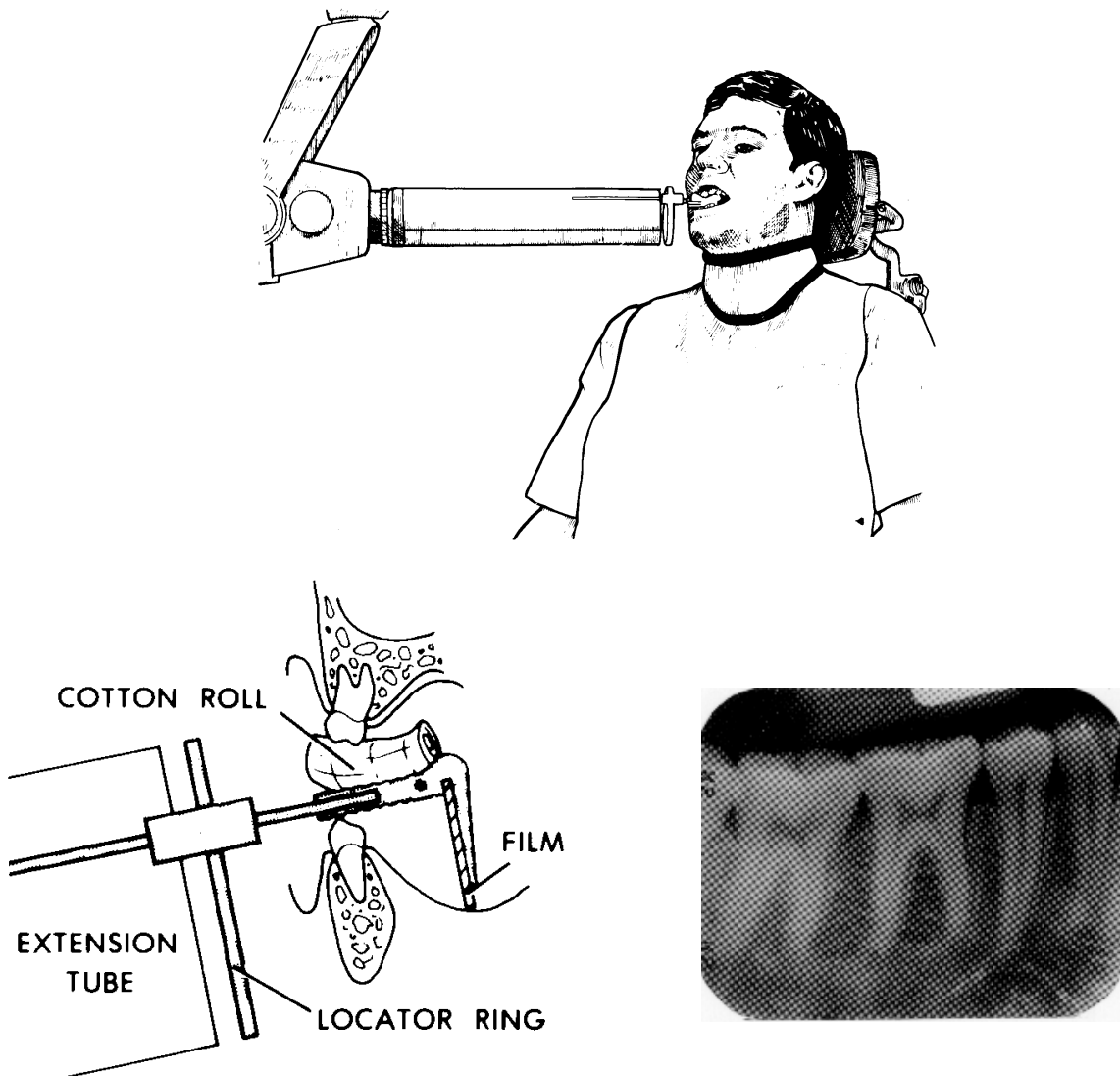


Figure 4-26. Mandibular bicuspid area.

#### 4-26. MANDIBULAR CUSPIDS

Using the anterior instrument assembly, center the cuspid on the film, parallel with the long axis of the tooth (see figure 4-27). With the bite-block resting on the mandibular cuspid, insert a cotton roll between the block and the maxillary teeth. Have the patient close his teeth, holding the film in place. Slide the locator ring along the indicator rod bringing it close to the skin surface and align the x-ray unit extension tube with the rod and the ring on the vertical and horizontal planes.

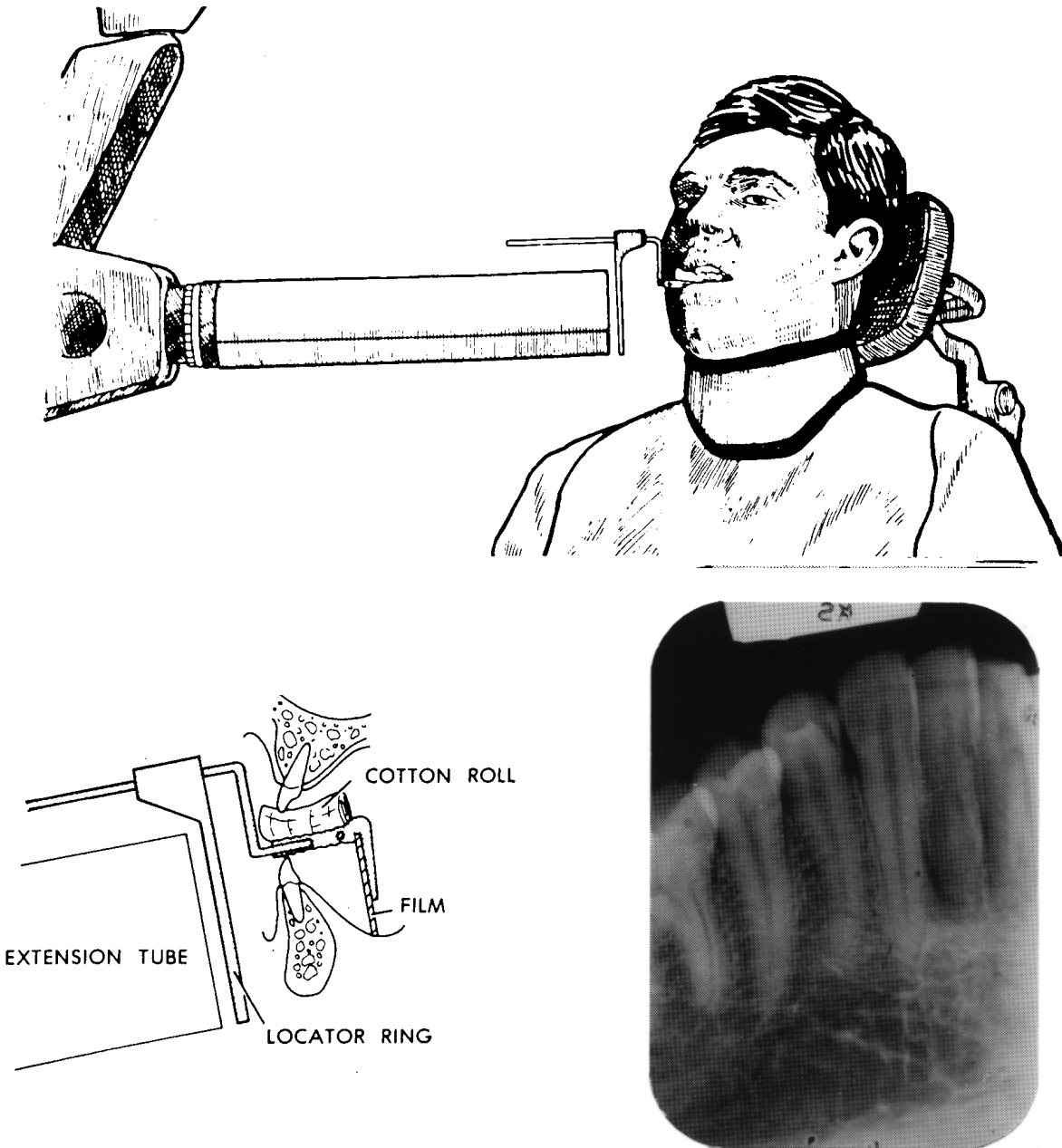


Figure 4-27. Mandibular cuspid area.

## 4-27. MANDIBULAR INCISORS

Using the anterior instrument assembly, center the film parallel to the long axis of the incisor teeth (see figure 4-28). Ensure that the film is situated along the midline of the teeth. The positioning can be accomplished by lingual placement of the film to the area of the second bicuspids. With the bite-block resting on the incisal edges of the maxillary incisor teeth. Have the patient close his teeth holding the film in place. Slide the locator ring along the indicator rod bringing it close to the skin surface and align the x-ray unit extension tube with the rod and the ring on the vertical and horizontal planes.

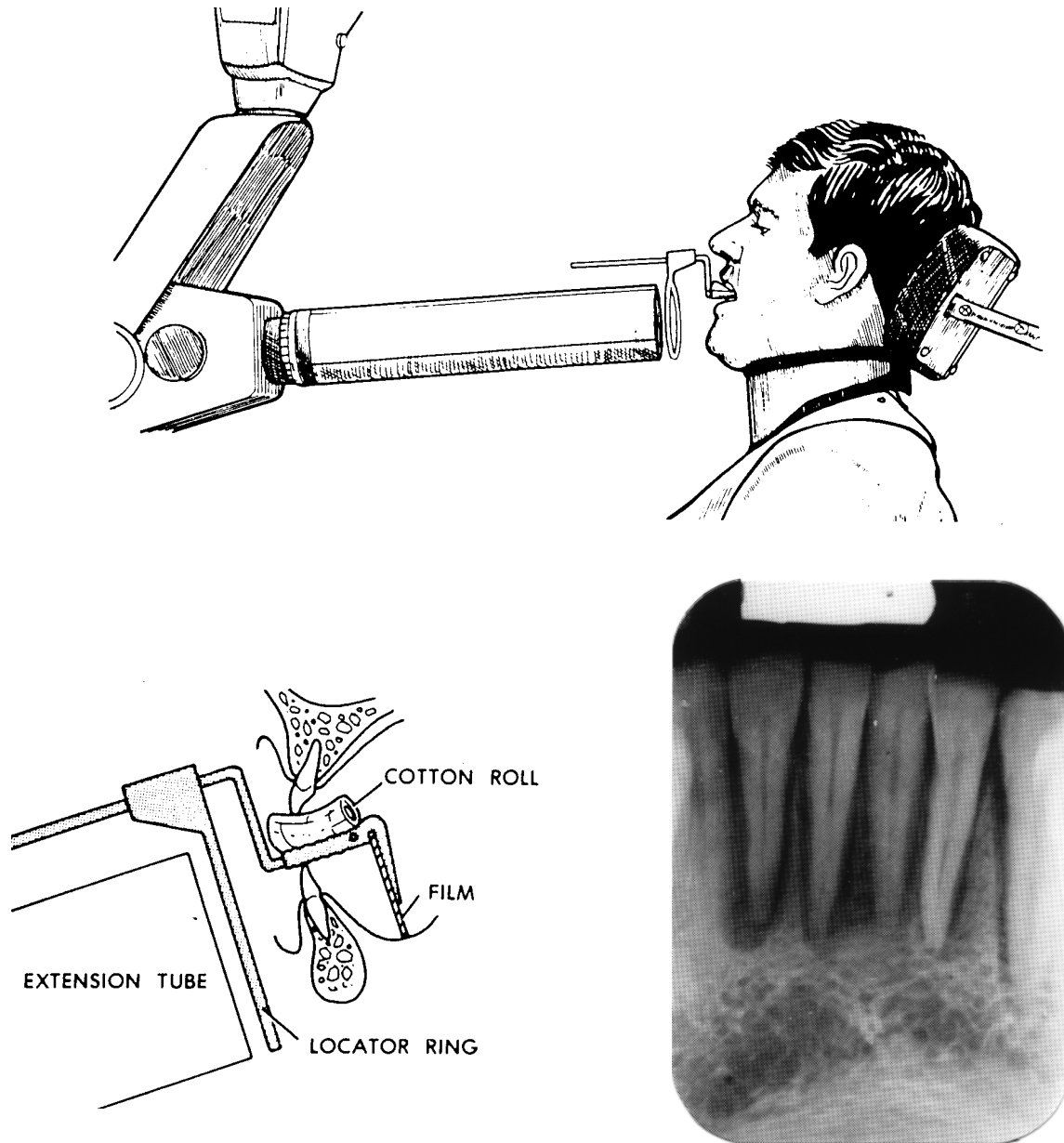


Figure 4-28. Mandibular incisor area.

## Section IV. BITE-WING (INTERPROXIMAL) EXPOSURE TECHNIQUES

### 4-28. GENERAL

Bite-wing film has many uses. The main use is to detect decay between teeth (including depth of caries) by obtaining an image of the crowns of the teeth without the distortion that often occurs in a periapical examination. This is made possible by using a low vertical angle of projection with the film packet held in a nearly vertical position. No attempt is made to include the apices of the teeth. Bite-wing film is also used to detect calculus and to examine the alveolar crest, margins of restorations, and the pulp chamber. Both the maxillary and mandibular teeth of an area are shown on one film.

### 4-29. MOLARS AND BICUSPIDS (POSTERIOR TEETH)

For radiographs of posterior teeth, adjust the head so that the occlusal surfaces of the maxillary teeth lie in a horizontal plane. Place a film packet in the mouth so that the resulting radiograph will include the desired teeth. The lower part of the film will lie between the tongue and the mandibular ridge; the upper part will lie against the roof of the mouth. Have the patient slowly close his teeth on the tab. Adjust tube to an average angulation of  $+8^\circ$ . Direct the central ray to pass straight through the interproximal spaces to the center of the film at the level of the occlusal plane (see figure 4-29). Follow the manufacturer's instructions for exposure times.

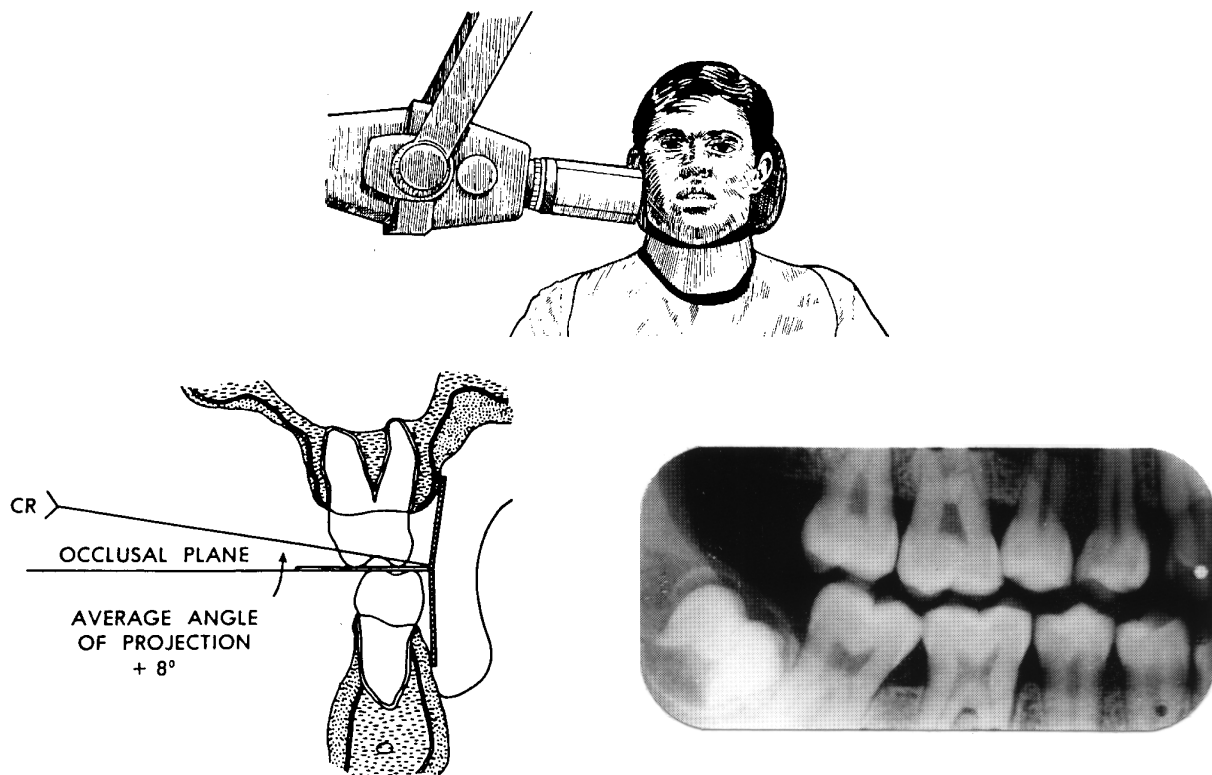


Figure 4-29. Posterior bite-wing technique.

#### **4-30. CENTRAL AND LATERAL INCISORS AND CUSPIDS (ANTERIOR TEETH)**

Periapical film with an adapter is used for bite-wing radiographs of anterior teeth. Head positioning for anterior bite-wing exposures is the same as for the posterior teeth. Refer to paragraph 4-29. However, a bite-wing radiograph of anterior teeth is seldom requested by a dentist.

a. **Central Area.** Place the film packet in the mouth with the center of the film in line with the median plane. The lower part should be placed between the tongue and mandibular ridge. The upper part is then allowed to lie against the roof of the mouth. Have the patient bite tightly end-to-end against the tab. Adjust the tube to an angulation of +8°. Direct the central ray through the interproximal spaces between the central incisors at the level of the incisal plane. Follow the manufacturer's instructions for exposure time.

b. **Lateral and Cuspid Area.** Place the packet as specified for the central incisor region. Instruct the patient to bite very gently against the tab to hold it in position. Shift the tab distally until its mesial surface of the film is located at the midline of the arch between the central incisors. Then instruct the patient to bite firmly end-to-end against the tab. Adjust the tube to an angulation of +8°. Direct the central ray straight through the lateral incisor at the level of the incisal plane. Follow the manufacturer's instructions for exposure time.

### **Section V. OCCLUSAL EXPOSURE TECHNIQUES**

#### **4-31. GENERAL**

At times, more extensive radiographic views of oral tissues are desired than are obtainable with periapical or bite-wing film. These views are made by using occlusal film (refer to paragraph 4-3c). The occlusal film will always be exposed through the unbroken side. Periapical film is used at times to obtain occlusal views in children and views of small areas in adults. Follow the manufacturer's instructions for exposure times.

a. **Maxillary Head Positioning.** In all maxillary occlusal techniques, the patient's head is first adjusted so that the median plane (sagittal plane) of the face is in a vertical position and the occlusal surfaces of the maxillary teeth are in a horizontal plane (parallel to the floor). The x-ray is taken through the facial bones. The film is held in place by the patient's teeth, closed gently but firmly against the film packet.

b. **Mandibular Head Positioning.** In the mandibular full and posterior occlusal techniques, the patient is tilted back so that the x-ray is taken through the body of the mandible. In the anterior occlusal technique, the x-ray is taken through the chin. The patient holds the film in place by closing his teeth gently but firmly against the film.



#### 4-32. MAXILLARY FULL OCCLUSAL

Position the film packet carefully in the mouth with its short axis in line with the median plane and the film placed far enough distally to include all the teeth. Adjust the tube so that the point of the cone is at the hairline of the forehead, in the median line, and directed downward and perpendicular to the plane of the packet (see figure 4-30).

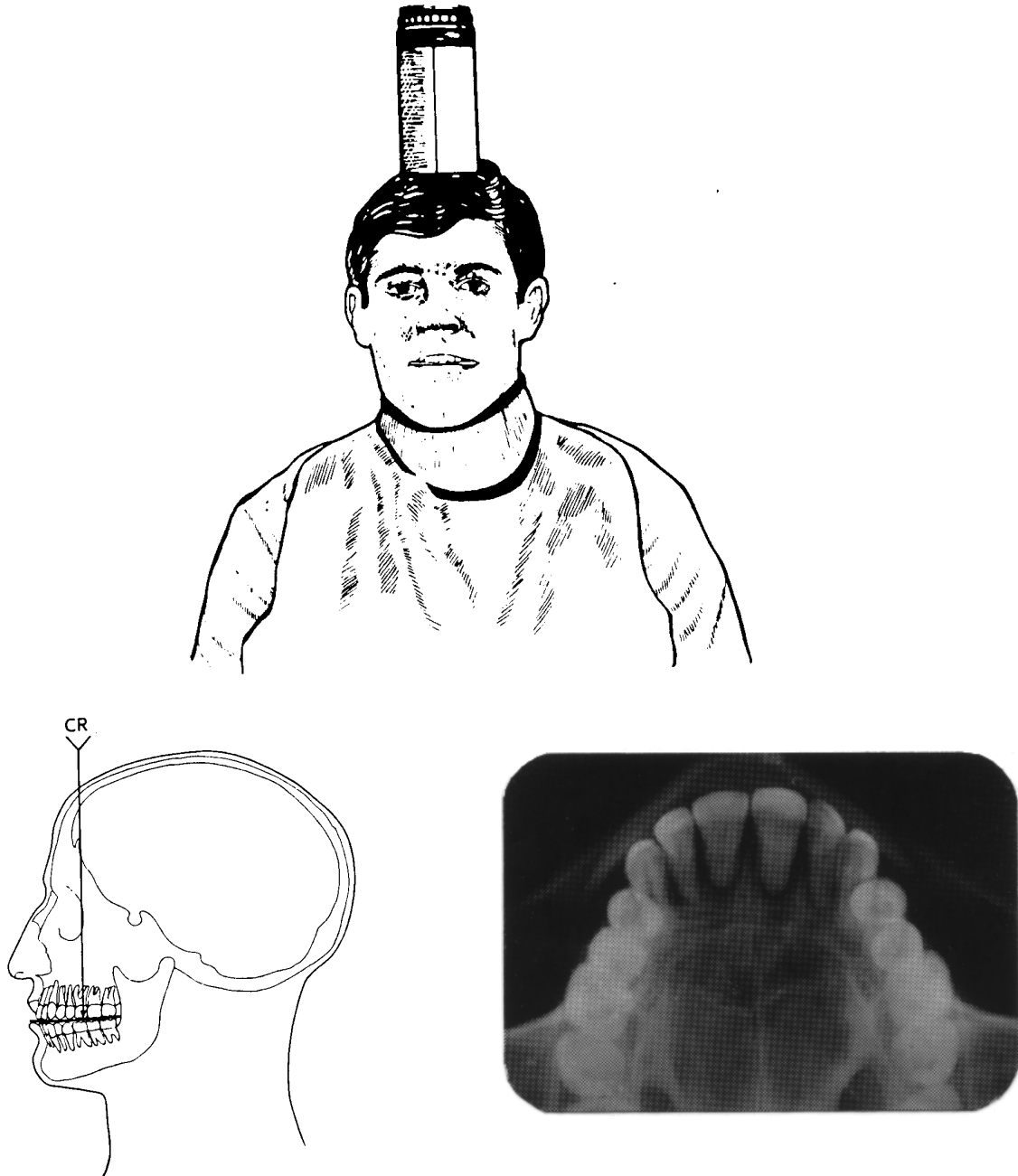


Figure 4-30. Maxillary full occlusal view technique.

### 4-33. MAXILLARY ANTERIOR OCCLUSAL

Place the film packet in the mouth with its short axis in line with the median plane. Adjust the tube so that the central ray is directed along the median line and at an angulation of  $+65^\circ$  to pass through the bridge of the nose to the film packet (see figure 4-31).

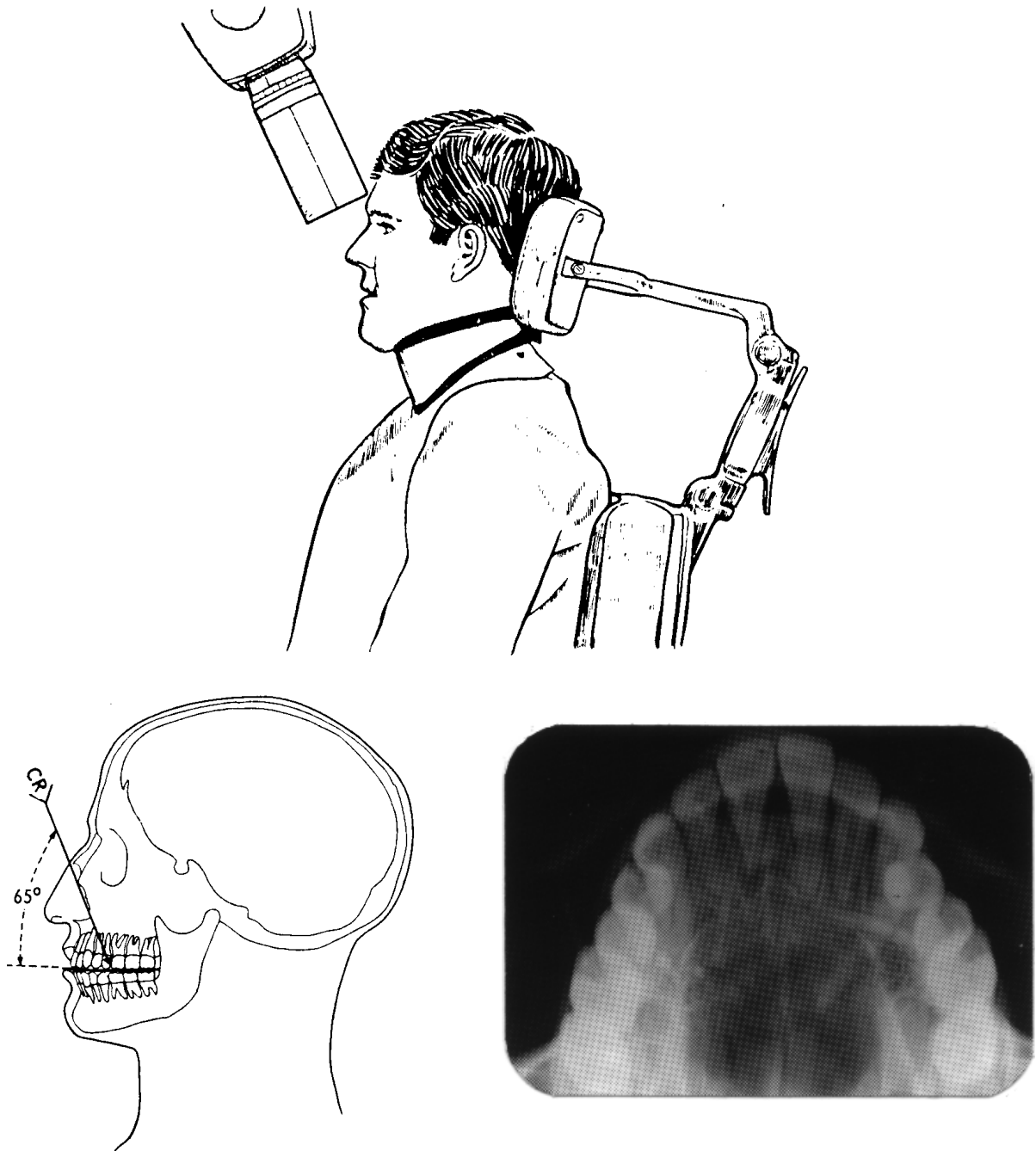


Figure 4-31. Maxillary anterior occlusal view technique.

#### 4-34. MAXILLARY POSTERIOR OCCLUSAL

Place the film packet in the mouth on the side to be radiographed with its long axis parallel to the median plane. Adjust the tube to a vertical angulation of  $+60^\circ$ . Direct the central ray to pass through the ala of the nose and apical region of the cuspid and first bicuspid to the plane of the film packet (see figure 4-32).

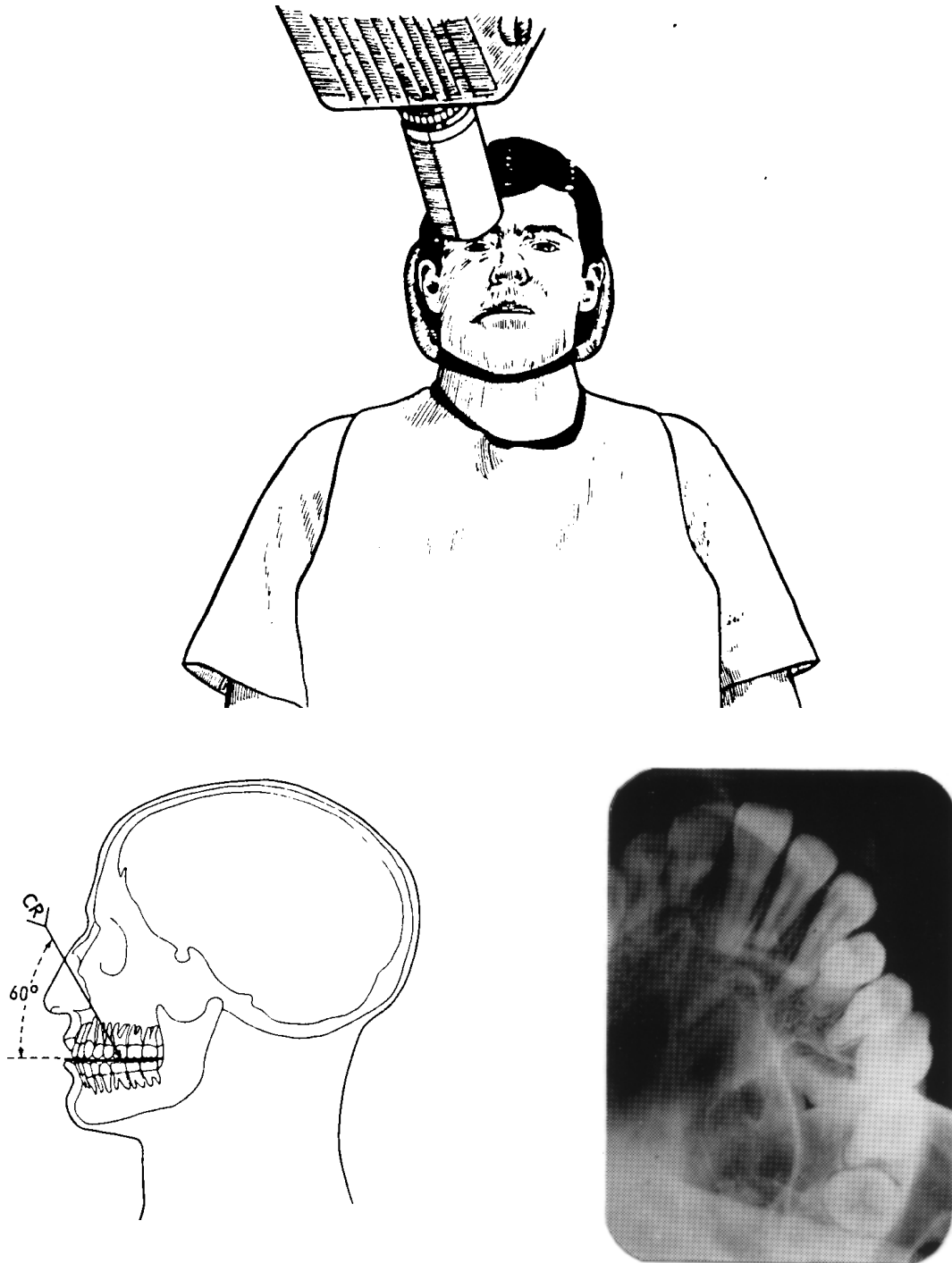


Figure 4-32. Maxillary posterior occlusal view technique.

#### 4-35. MANDIBULAR FULL OCCLUSAL

Tilt the head back so that the occlusal plane of the mandibular teeth is at right angles to the horizontal plane with the median plane (sagittal plane) of the face in a vertical position. Place the film packet in the mouth with its short axis in line with the median plane and its posterior border in contact with the mandibular rami. Adjust the tube to direct the central ray along the median plane so as to be perpendicular to the film packet. The ray should pass through the floor of the mouth and the body of the mandible to the center of the film (see figure 4-33).

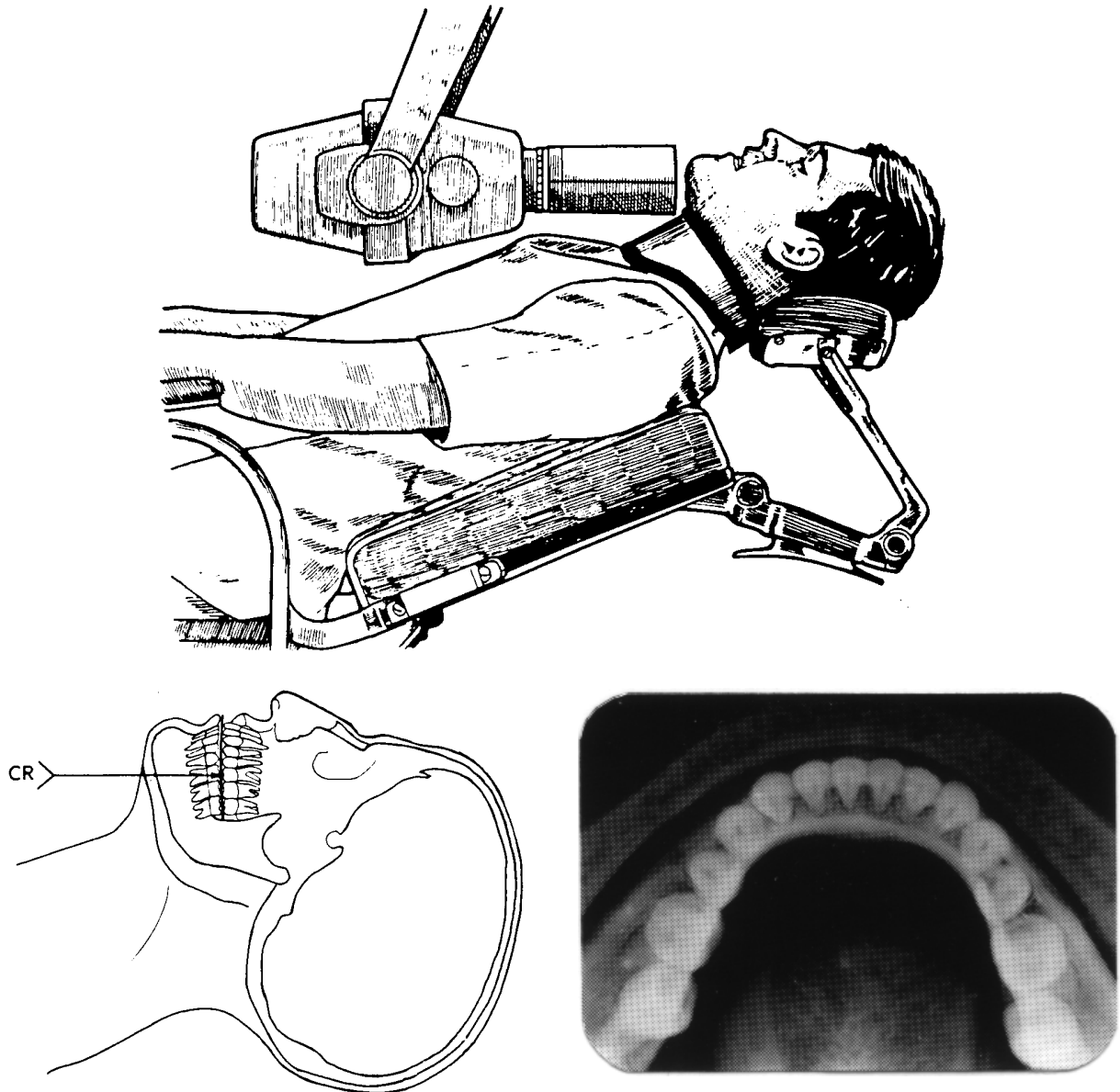


Figure 4-33. Mandibular full occlusal view technique.

#### 4-36. MANDIBULAR ANTERIOR OCCLUSAL

Tilt the head backward so that the occlusal plane of the mandibular teeth is at a  $+55^\circ$  angle to the horizontal and median plane. Position the film in the mouth with its short axis in line with the median plane. Adjust the tube to direct the central rays through the point of the chin at a  $+55^\circ$  angle to the plane of the packet (see figure 4-34).

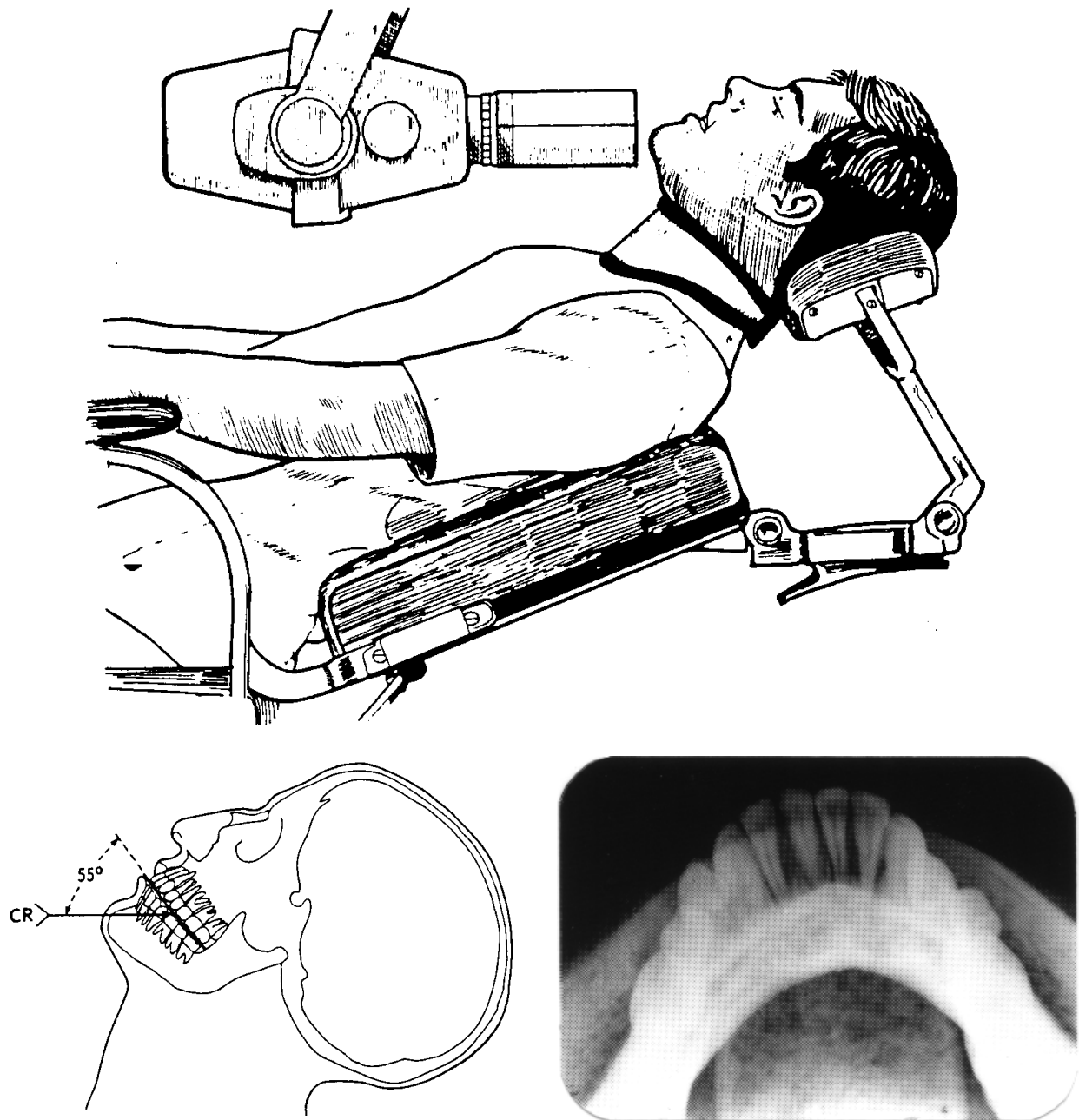


Figure 4-34. Mandibular anterior occlusal view technique.

#### 4-37. MANDIBULAR POSTERIOR OCCLUSAL

Position the head so that the occlusal plane of the mandibular teeth is perpendicular to the horizontal plane and the median plane of the face is vertical. Place the film packet in the mouth so that it is centered over the teeth on the side to be radiographed. Adjust the tube so that the central ray will pass from below the mandible and through the second molar at a perpendicular angle to the plane of the film packet (see figure 4-35).

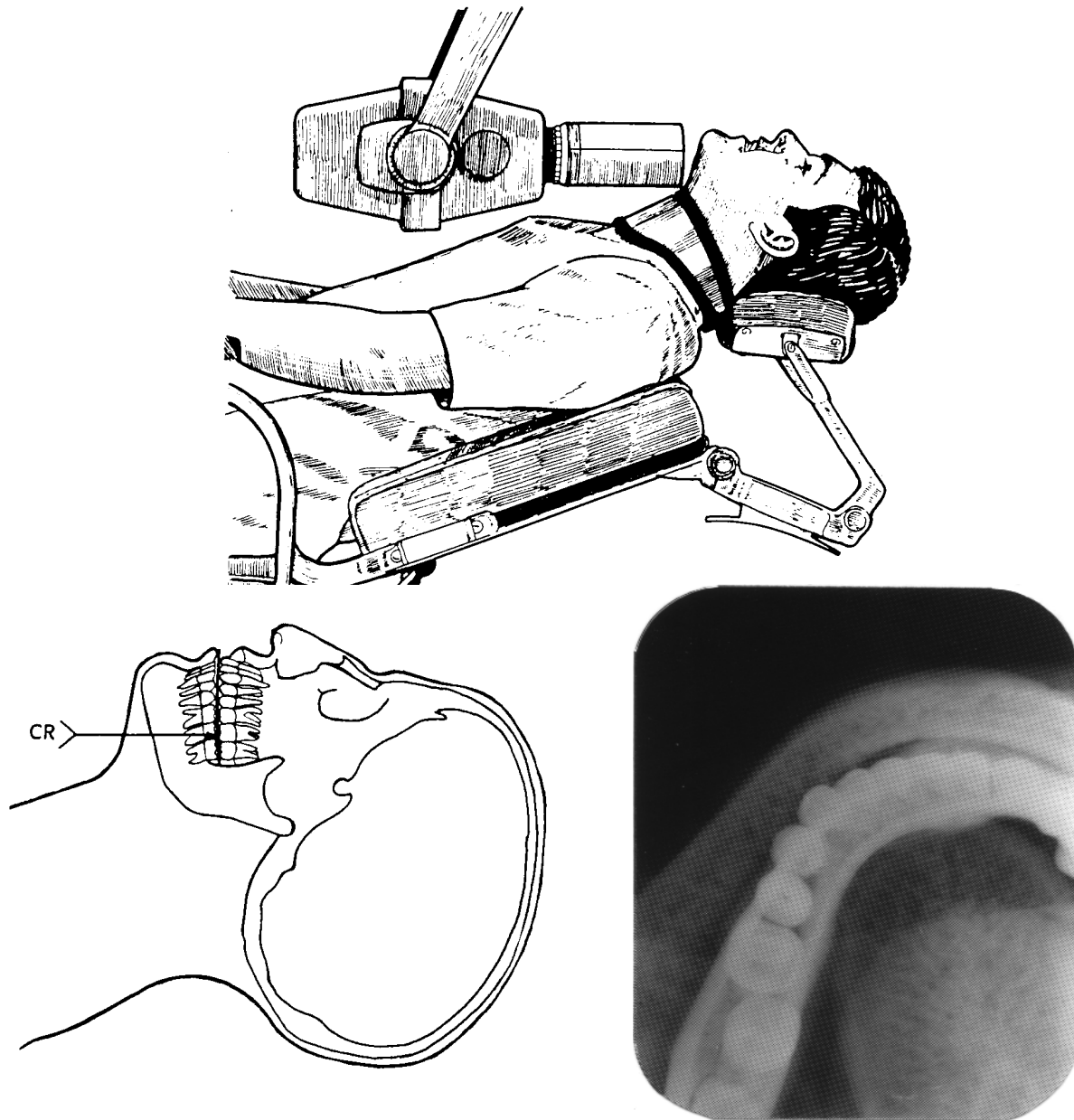


Figure 4-35. Mandibular posterior occlusal view technique.

## **Section VI. THE PANORAMIC RADIOGRAPH**

### **4-38. GENERAL**

The panoramic technique is used to show a continuous view of the lower half of the face. This includes the teeth, jaws and some soft tissue anatomy. This radiograph is mandatory for all military personnel and is used for initial dental processing of the soldiers. It may also be used should post mortem identification become necessary.

### **4-39. ADVANTAGES OF THE PANORAMIC RADIOGRAPH**

The principal advantages of the panoramic radiograph are the large area of coverage, the bilateral view of anatomy, low patient radiation dose, and it can be used on handicapped patients, children, and on those who are unable to open their mouths.

### **4-40. DISADVANTAGES OF THE PANORAMIC RADIOGRAPH**

Unfortunately, this radiograph has several disadvantages. The definition of the x-ray is not as sharp as a periapical or a bitewing x-ray. Therefore, small caries, periapical disease along with other diseases, and abnormalities that would show up on intraoral x-rays would not be identified on a panoramic view. Other problems would include magnification, distortion, and natural overlapping of some of the teeth.

### **4-41. USES OF THE PANORAMIC RADIOGRAPH**

The uses of the panoramic radiograph are numerous in the diagnosis of disease and abnormalities. A number of uses are as follows: a complete survey can be made of the teeth and related structures, some tumors and cysts can be examined and evaluated, the location and position of impacted teeth may be determined, fractures of the lower face may be located, and growth patterns of the jaws can be studied and evaluated. These uses make the panoramic radiograph a valuable tool.

### **4-42. THE PANORAMIC UNIT**

There are various types and models of the panoramic unit on the market today. The operation of each machine will vary. Therefore, manufacturer's instruction should be read and carefully followed. For a new machine, a technical representative should be summoned to demonstrate its use and operation.

**Continue with Exercises**

## EXERCISES, LESSON 4

**INSTRUCTIONS:** Answer the following exercises by marking the lettered response that best answers the question or best completes the incomplete statement or by writing the answer in the space provided.

After you have completed all the exercises, turn to "Solutions to Exercises" at the end of the lesson and check your answers.

1. Most dental radiographs are made on \_\_\_\_\_ film, which is made with the film held in the mouth during exposure.

2. The types of intraoral radiographic film are:

---

---

---

3. The occlusal examination is valuable in:

---

---

---

4. When preparing for a mandibular exposure using the bisecting technique, the head position should be such that the occlusal surfaces of the mandibular teeth will be \_\_\_\_\_ when the mouth is opened.

5. Two of the most commonly-used techniques in periapical radiography are:

---

---



6. \_\_\_\_\_ is the up-and-down movement of the tube head or x-ray beam when using the bisecting periapical technique.
7. \_\_\_\_\_ exists if the vertical angulation is larger than necessary. The image of the teeth appears smaller than normal.
8. \_\_\_\_\_ exists if the vertical angulation is less than is necessary. The image of the teeth appears larger than normal.
9. \_\_\_\_\_ is the side-to-side movement of the tube head or x-ray beams when using the bisecting periapical technique.
10. Correct horizontal angulation for successful radiographs exists when the central ray is \_\_\_\_\_ to the facial surfaces of the teeth and \_\_\_\_\_ to the mesial and distal surfaces.
11. In the \_\_\_\_\_ (long-cone) technique, the film is held parallel to the long axis of the tooth. The central ray is directed to pass at a \_\_\_\_\_ angle to both the tooth and the film.
12. The paralleling (long-cone) periapical technique provides a target-film distance of approximately \_\_\_\_\_ inches, in contrast to 8 inches for the bisecting technique.
13. The instruments used to hold the film parallel to the teeth are:  
\_\_\_\_\_  
\_\_\_\_\_  
\_\_\_\_\_

14. The interproximal or bite-wing film is used to obtain an image of the \_\_\_\_\_ of the teeth, without the distortion that often occurs in a periapical examination.
15. At times, more extensive radiographic views of oral tissues are desired than are obtainable with periapical or bite-wing film. These views are made by using \_\_\_\_\_ film.
16. In all maxillary occlusal techniques, the patient's head is first adjusted so that the median plane (sagittal plane) of the face is in a \_\_\_\_\_ position and the occlusal surfaces of the maxillary teeth are in a \_\_\_\_\_ plane.
17. Describe the head positioning and direction of the x-rays for the mandibular occlusal techniques.
- 
- 

**Check Your Answers on Next Page**

## **SOLUTIONS TO EXERCISES, LESSON 4**

1. intraoral (para 4-2)
2. periapical  
interproximal (bite-wing)  
occlusal (para 4-3)
3. locating and diagnosing fractures  
salivary duct stones  
impacted teeth (para 4-3c)
4. horizontal (para 4-7b)
5. bisecting (short-cone)  
paralleling (long cone) techniques (para 4-5)
6. vertical angulation (para 4-8a)
7. foreshortening (para 4-8a(1))
8. elongation (para 4-8a(2))
9. horizontal angulation (para 4-8(b))
10. perpendicular, parallel (para 4-8(b))
11. paralleling  
perpendicular (para 4-18)
12. 16 (para 4-18)
13. plastic bite-blocks  
indicator rods  
plastic locator rings (para 4-19)
14. crown portions (paras 4-28; 4-29)
15. occlusal (para 4-31)
16. vertical, horizontal (para 4-31a)
17. Patient is tilted back.  
The x-ray is taken through the chin or the body of the mandible. (para 4-31b)

**End of Lesson 4**