



A R T I C L E S

Proper positioning for the pelvis and proximal femur

The lowdown on lumbar spine positioning

Radiographic positioning techniques for the cervical spine

Boning up on humerus, clavicle, and AC joint positioning

Getting the most from shoulder positioning

The bends and flexures of forearm and elbow x-ray positioning

The twists and turns of hand and wrist x-ray positioning

Digit imaging requires diligent positioning

Patient positioning techniques for a lower gastrointestinal series

Patient positioning tips for a premium UGI series

Positioning techniques for quality esophagrams

Dorsal & lateral decubitus patient positioning for abdominal x-ray exams

AP abdominal projection x-ray positioning techniques

Tips and techniques for decubitus and oblique chest x-rays

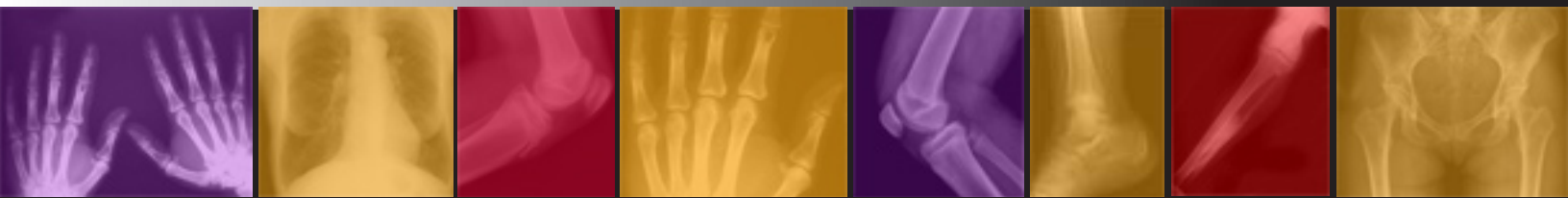Mastering AP and lateral positioning for chest x-ray

Good positioning is key to PA chest x-ray exams

DIGITAL



X-RAY



Introduction

Dear AuntMinnie Member,

I'm pleased to present this compendium of positioning techniques for the most commonly performed radiographic exams, based on a series of articles I authored for AuntMinnie.com between 2001 and 2003.

The articles feature a clear, easy-to-follow organization, with positioning and projection information in an easy-to-read, bulleted format, and corresponding positioning photos, radiographic images, and anatomical drawings.

We hope having these articles available in a single, easily downloadable PDF format will enhance your understanding of anatomy and positioning.

Dr. Naveed Ahmad
Orlando, FL
March 2008

*Copyright © 2008 AuntMinnie.com,
1350 N. Kolb Road, Suite 215, Tucson, AZ 85715*



Proper positioning for the pelvis and proximal femur

Proper positioning for the pelvis and proximal femur

By Dr. Naveed Ahmad

August 8, 2003

This article is the 16th in our series of white papers on radiologic patient positioning techniques for x-ray examinations. If you'd like to comment on or contribute to this series, please e-mail editorial@auntminnie.com.

The standard radiographic projections used to evaluate injury to the pelvic girdle and proximal femur include the anteroposterior (AP) pelvis (bilateral hips) and AP unilateral hip. AP oblique pelvis (the "frog leg") projections are commonly performed on non-trauma patients to evaluate congenital hip dislocation. The AP view is frequently not sufficient to provide adequate evaluation of the entire sacral bone, the sacroiliac (SI) joints, and the acetabulum. Special radiographic projections are performed to evaluate the SI joints, sacral bones, and acetabulum.

AP pelvis (bilateral hips) projection

The standard radiographic view for the pelvis is obtained in an AP position with the patient supine. Most traumatic conditions involving the sacral wings, the iliac bones, ischium, the pubis, and the femoral head and neck can sufficiently be evaluated on the AP projection of the pelvis and hip. This view also demonstrates an important anatomical relationship in the longitudinal axes of the femoral neck and shaft. Normally, the angle formed by these axes ranges from 125°-135°. Varus and valgus configuration of a femoral neck fracture is said to occur if there is decrease or increase, respectively, in this angle.

Technical factors

- Image receptor (IR): 14 x 17 inch (35 x 43 cm) crosswise
- 75- 85 kVp range
- mAs 12 (at 80 kVp)
- Moving or stationary grid
- Surface-to-image distance (SID) of 40 inches (100 cm)

Positioning for the AP pelvis (bilateral hips) projection

1. The patient is positioned supine on the radiographic table, with arms placed at the side or across the upper chest. Placing a support under the head and knee helps to relieve the strain on the patient while in the supine position.
2. The midsagittal plane of the body should be centered to the midline of the grid device. There should be no rotation of the pelvis. The distance from tabletop to each anterior superior iliac spine (ASIS) should be equal.



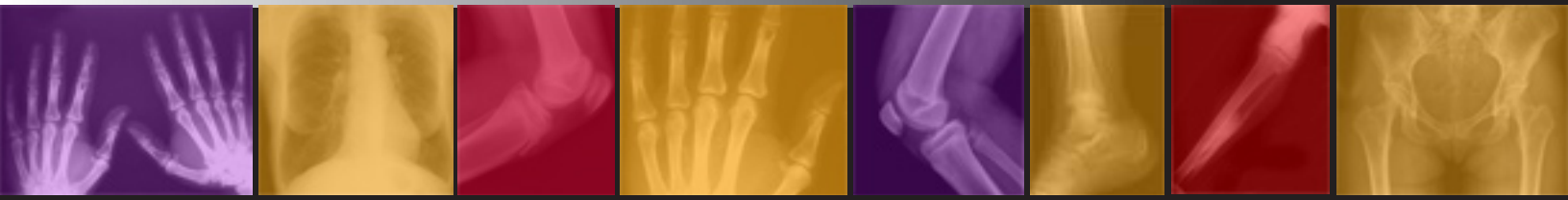Continued

3. The feet are placed in approximately 15°-20° of internal (medial) rotation. This is done to overcome the normal anteversion of the femoral necks and to place their longitudinal axes parallel to the film. The heels should be 8-10 inches (20-24 cm) apart.
4. For correct centering of the pelvis (bilateral hips), palpate for the iliac crest and adjust the position of the cassette so that the upper border of the cassette is 1-1 ½ inches (2.5-3.8 cm) above the iliac crest. The center of the cassette should be midway between the ASIS and the pubic symphysis.
5. For a pelvis with bilateral hips projection, carefully palpate the superior portion of the iliac crest and direct the central ray (CR) midway between the level of the ASIS and the symphysis pubis.
6. Shield gonads on all male patients. Ovarian shielding on females, however, is generally not possible without obscuring essential pelvic anatomy (unless interest is in area of hips only).
7. Ask the patient to suspend their breathing on expiration.

Evaluation criteria for AP pelvis (bilateral hips)

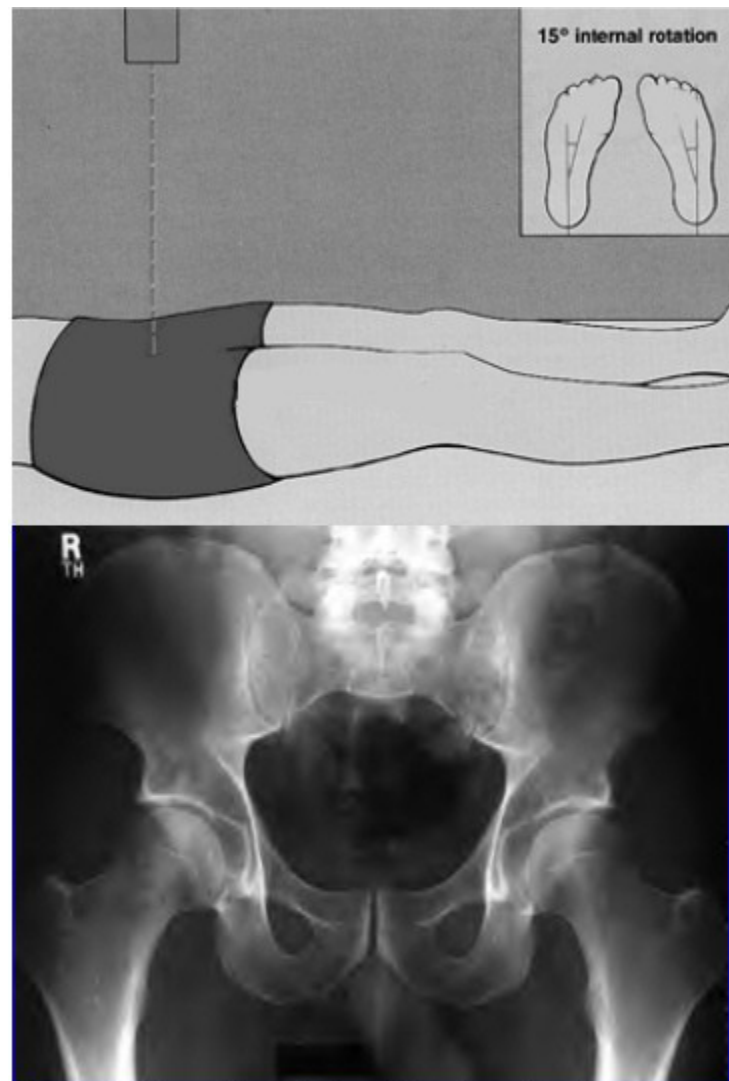
- The entire pelvis along with proximal femoral neck including pelvic girdle, L5, sacrum, and coccyx should be seen.
- The lesser trochanters usually are not visible at all, or if they are, should appear equal in size and shape on the medial border of the femora. The greater trochanters should be visible in profile.
- No rotation is evidenced by symmetric appearance of the two obturator foramina, as well as a symmetric iliac alae and ischial spines. A closed or narrowed obturator foramen indicates rotation in that direction.
- Correct collimation and centering is evidenced by demonstration of both ilia equidistant to the edge of the radiograph, both greater trochanters equidistant to the edge of the radiograph, and the lower vertebral column centered to the middle of the radiograph.
- Optimal exposure should clearly demonstrate L5, sacral area, and margins of the femoral heads and acetabula without overexposing the ischium and the pubic bones.
- No motion is evidenced by sharp orbicular markings of the proximal femora and the pelvic structures.

(see Fig. 1, next pg.)



Continued

(Fig. 1)



For an AP view of the pelvis and hip, the patient is supine with the feet in slight (15°-20°) internal rotation, which compensates for the normal anteversion of the femoral neck, elongating its image. Correct collimation and centering is evidenced by demonstration of both ilia equidistant to the edge of the radiograph, both greater trochanters equidistant to the edge of the radiograph, and the lower vertebral column centered to the middle of the radiograph. Image courtesy of Dr. Naveed Ahmad.



Continued

AP unilateral hip projection

An AP unilateral hip study is usually a postoperative or a follow-up exam to demonstrate the acetabulum, femoral head and neck, and the greater trochanters, as well as the condition and placement of any existing orthopedic appliance. Technical factors and patient positioning are the same as for an AP pelvis (bilateral hips) exam.

The CR is placed perpendicular to the femoral neck in question, approximately 2 ½ inches (6.4 cm) distal on a line drawn perpendicular to the mid point of a line between the ASIS and the pubic symphysis. In other words, the CR is directed 1-2 inches (2.5-5 cm) distal to mid femoral neck.

The femoral neck can be located about 1-2 inches (3-5 cm) medial and 3-4 inches (8-10 cm) distal to the ASIS. The collimated field should demonstrate the femoral head and neck, trochanters, the proximal third of the femur shaft, regions of the ilium, and the pubic bones adjoining the pubic symphysis.

The greater trochanter and femoral head and neck should be in full profile without foreshortening. The lesser trochanter should not project beyond the medial border of the femur. Optimal exposure should ensure visualization of the femoral head through the acetabulum.

AP oblique pelvis projection x-ray positioning techniques

This projection is also called the bilateral "frog leg" position. It is useful for demonstration of a non-trauma hip or developmental dysplasia of the hip, also known as congenital hip dislocation (CHD). It shows an AP oblique projection of the femoral heads, necks, and the trochanteric areas projected onto one radiograph for comparative purposes.

Technical factors

- IR: 14 x 17 inch (35 x 43 cm) crosswise
- 75-85 kVp range
- mAs of 12 (at 80 kVp)
- Moving or stationary grid
- SID of 40 inches (100 cm)

Positioning for the AP oblique pelvis projection

1. The patient is positioned supine on the radiographic table, arms placed at the side or across the upper chest. Placing a support under the head helps relieve the strain on the patient while in the supine position.



Continued

2. The midsagittal plane of the body should be centered to the midline of the grid device. There should be no rotation of the pelvis. The distance from tabletop to each ASIS should be equal.
3. For a bilateral projection, both hips and knees are flexed approximately 90° . Have the patient draw the feet up as much as possible. After correctly centering the cassette 1 inch (2.5 cm) superior to the pubic symphysis, abduct both thighs approximately 45° from the vertical plane to place the long axis of femoral necks parallel with the plane of the cassette. Ensure that both thighs are abducted the same amount and that pelvis is not rotated (equal distance of both ASIS to the tabletop). Have the patient turn their feet to brace the soles against one another for support.
4. For unilateral frog leg projection center the ASIS of the affected side to the midline of the grid. Ask the patient to flex the hip and knee of the affected side, then abduct the thigh laterally, approximately 45° . Have the patient draw the foot up to the opposite knee as much as possible so that the sole of the foot is against the opposite knee. The pelvis may rotate slightly in a unilateral projection.
5. Carefully palpate the superior portion of iliac crest and direct the CR to a point 3 inches (7.5 cm) below the level of the ASIS (1 inch or 2.5 cm above symphysis pubis). For the unilateral position, direct the CR to the femoral neck.
6. Shield gonads on all male patients. Ovarian shielding on females, however, is generally not possible without obscuring essential pelvis anatomy (unless interest is in area of hips only).

(see Fig. 2, next pg.)

Evaluation criteria

Femoral heads and necks, acetabulum, and trochanteric areas should be visible on a single radiograph.

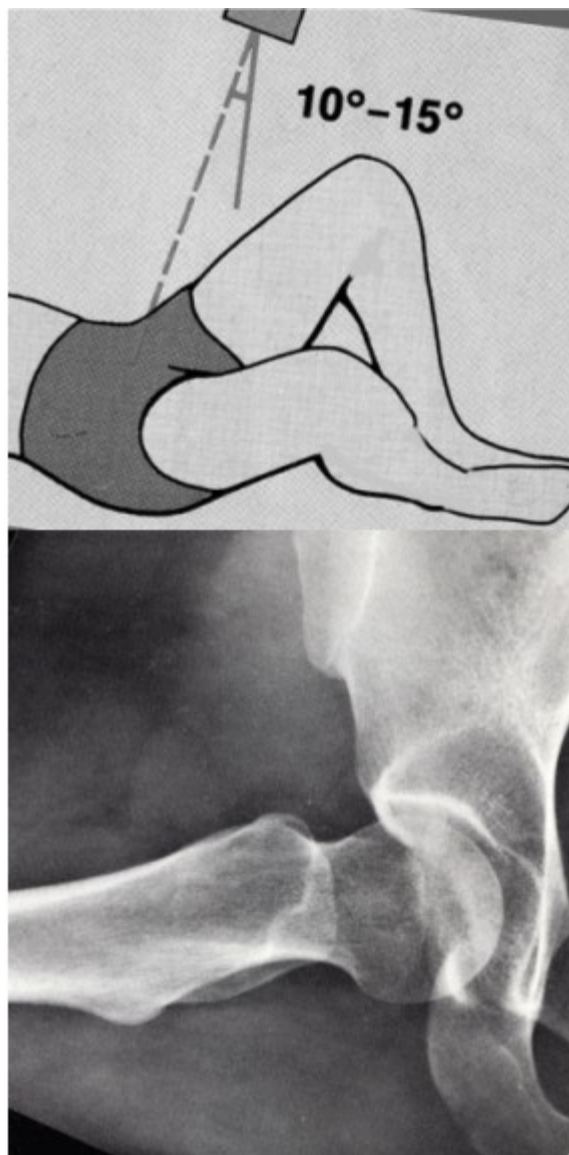
No rotation is evidenced by symmetric appearance of the two obturator foramina and pelvic bones. The lesser trochanters should appear equal in size as projected on the medial margins of the femora. The greater trochanters are superimposed over the femoral necks.

The femoral heads and necks and trochanters should appear symmetric if both thighs are abducted equally.



Continued

(Fig. 2)



For the bilateral frog leg view of the proximal femur and hip, the patient is supine with the knees flexed, the soles of the feet together, and the thighs abducted. For simultaneous imaging of both hips, the CR is directed vertically or with 10°-15° cephalad angulation to a point slightly above the pubis symphysis. For a selective examination of one hip, it is directed toward the affected hip joint. The film in the projection demonstrates the lateral aspect of the femoral head and trochanters. Image courtesy of Dr. Naveed Ahmad.



Continued

Special projections of pelvis and proximal femur

Other special radiographic projections to evaluate injury to the pelvic girdle include the AP axial outlet projection, AP axial inlet projection, oblique projections for acetabulum, groin projections (axiolateral), and posterior oblique projections for SI joints. These are usually requested in trauma patients after a routine AP projection shows some pathology, or in postsurgical patients who need follow-up evaluation.

AP axial pelvic outlet and AP axial pelvic inlet projections

The AP axial outlet projection shows an elongated projection of the pubic and ischial rami. This projection provides an excellent view of the bilateral pubes and ischia to assess pelvic bones for fractures and displacements. The AP axial inlet projection provides assessment of the pelvic ring.

The technical factors and patient positioning for these projections are the same as for an AP pelvis projection. The main difference lies in the CR angulations.

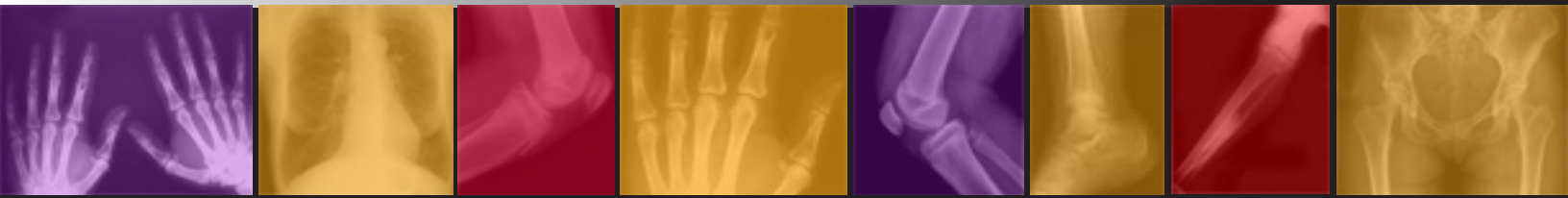For an AP axial outlet projection, the CR is angulated cephalad 20°-35° for males and 30°-45° for females and is centered to a point 2 inches (5 cm) distal to the superior border of the pubic symphysis. For an AP axial inlet projection, the CR is angulated caudad 40° and is centered to a midline point at the level of both ASIS.

Oblique projections of the acetabulum

Oblique projections, known as Judet's views, are necessary to evaluate the acetabulum. The anterior (internal) oblique projection helps delineate the anterior column and the posterior rim of the acetabulum. The posterior (external) oblique projection delineates the posterior column and the anterior acetabular rim.

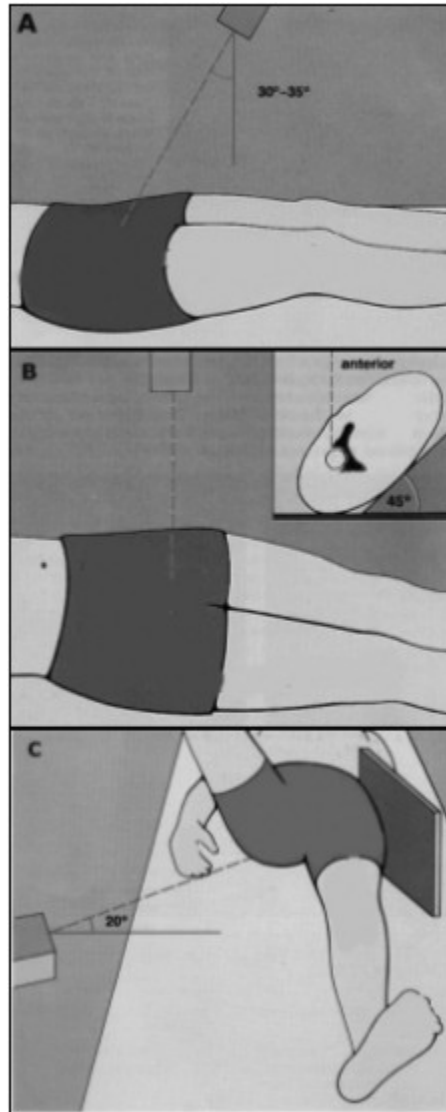
For a posteroanterior (PA) oblique projection the patient lies in a semi-prone position on the affected side. The unaffected side is elevated so that the anterior surface of the body forms a 38° angle from the table. The CR is directed 12° cephalic to the side being examined, approximately 2 inches (5 cm) lateral to the midsagittal plane at the inferior level of coccyx, permitting the CR to be directed through the acetabulum.

(see Fig. 3, next pg.)



Continued

(Fig. 3)



A: For the angled AP (Ferguson) view of the pelvis, the patient is in the same position as for the standard AP projection. The radiographic tube, however, is angled at about 30°-35° cephalad, and the CR is directed toward the midportion of the pelvis.

B: For the posterior oblique view of the pelvis, the patient is supine and anteriorly rotated; the unaffected hip is elevated 45°. The CR is directed through the affected hip.

C: For the groin lateral view of the hip, the patient is supine with the affected extremity extended and the opposite leg elevated and abducted. The cassette is placed against the affected hip on the lateral aspect, and the CR is directed horizontally toward the groin with about 20° cephalad angulation. Images courtesy of Dr. Naveed Ahmad.

Axiolateral projection of the hip and proximal femur (groin projection)

The groin projection is particularly useful in evaluating anterior and posterior displacement of fracture fragments in proximal femoral fractures, as well as the degree of rotation of the femoral head. This projection provides a true lateral image of the proximal femur and also demonstrates an important anatomic feature, the angle of the anteversion of the femoral neck, which normally ranges from 25°-30°.

It may be done on a stretcher or at bedside if the patient cannot be moved. The unaffected leg is elevated and flexed so that the unaffected thigh is outside the collimation field. The IR is placed in a crease above the iliac crest so that it is parallel to the femoral neck and perpendicular to the CR. If the limb can be safely moved,



Continued

internally rotate the foot about 15° by grasping the heel to overcome the anteversion of the femoral neck. The CR is directed to the femoral neck and to IR.

Oblique projection for the SI joints

Various methods have been used to examine the sacroiliac joints; however, none is ideal as the normal undulating articular surfaces make evaluation of these joints extremely difficult. An angled AP radiograph can be taken with the tube angulated 30° - 35° in a cephalad direction.

This projection is known as a Ferguson view. It not only shows the SI joints to a better advantage but also helps in more effectively evaluating injury to the sacral bone, the pubis, and the ischial rami. Some radiologists prefer a PA radiograph with 25° - 30° of caudal angulation of the tube to evaluate the SI joints. In either case, both sacroiliac joints are exposed on a single film, facilitating a comparative evaluation.



The lowdown on lumbar spine positioning

The lowdown on lumbar spine positioning

By Dr. Naveed Ahmad

June 19, 2003

This article is the 15th in our series of white papers on radiologic patient positioning techniques for x-ray examinations. If you'd like to comment on or contribute to this series, please e-mail editorial@auntminnie.com.

The standard radiographic examination for evaluating the lumbar spine includes the anteroposterior, lateral, and oblique projections, supplemented by coned-down lateral films of the lumbosacral junction (L5-S1). The anteroposterior (AP) view is usually sufficient for evaluating traumatic conditions involving vertebral bodies and transverse processes, and the intervertebral disk spaces are also well demonstrated, except for the lowest (L5-S1). The spinous processes and articular facets however are not well demonstrated on this projection.

On the lateral projection of the lumbar spine, the vertebral bodies are seen in profile and the superior and inferior end plates are well demonstrated. Fractures of spinous processes are adequately evaluated on this projection, as are abnormalities involving the intervertebral disc spaces, including L5-S1.

Oblique views are particularly effective in demonstrating the facet joints (articular facets). Examination of motion in the lumbar spine may provide useful information. To accomplish this, lateral radiographs may be obtained during flexion and extension, and frontal radiographs may be obtained during lateral bending of the spine.

AP (or PA) projection of the lumbar-lumbosacral spine

The frontal radiograph of the lumbar spine can be obtained in the posteroanterior (PA) or AP projection with the patient erect or recumbent. Although the AP projection is more commonly used, there are some advantages to the PA projection.

Because the patient is in a prone position in the PA projection, the natural lumbar curvature is placed in such a way that the intervertebral disk spaces are parallel to the diverging beam of radiation, thus allowing better visualization of the intervertebral disc spaces. Moreover, the PA projection is more comfortable for patients who have back pain.

An additional advantage is lower radiation dose for females (25%-30% less for a PA projection compared with AP projection). A disadvantage of the PA projection for a patient with a large abdomen is the increased object to image distance (OID) of the lumbar vertebra, which results in radiographic distortion.



Continued

Technical factors

- Image receptor (IR): 14 x 17 inch (35 x 43 cm) for the lumbosacral spine, 11 x 14 inch (30 x 35 cm) for the lumbar spine only
- 75- 80 kVp range, some department protocols require use of a higher kVp (85-92) with reduction of mAs
- mAs 15 (at 80 kVp)
- Moving or stationary grid
- Surface to image distance (SID) of 48 inches (122 cm) is recommended to reduce distortion

Positioning for the AP projection of the lumbar-lumbosacral spine

1. The patient is positioned supine on the radiographic table, with the hips and knees flexed and the head on a pillow so that their back is in firm contact with the table. Flexion of the knees and hips straightens the spine, reduces the lumbar curvature (lordosis), and brings their back closer to the table and their vertebral column more parallel to the IR. This better delineates the vertebral bodies and opens intervertebral disk spaces.
2. If the patient is having excruciating back pain and is unable to assume a recumbent position, an AP or PA projection can be performed in an upright position. The upright position is also useful for demonstrating the natural weight-bearing status of the spine.
3. Place the patient's hands on the upper chest. Center the midsagittal plane of the patient's body to the midline of the grid/table, with the shoulders and hips lying in the same horizontal plane.
4. Central Ray (CR): Carefully palpate the superior portion of iliac crest (this corresponds to the L4-L5 intervertebral disc space) and direct the CR at this level, perpendicular to the cassette. Centering the CR to the iliac crest level will demonstrate both the lumbar spine and sacrum if a 14 x 17 inch (35 x 43 cm) cassette is used. If only a lumbar examination is intended, use an 11 x 14 inch (30 x 35 cm) cassette and direct the CR 1-½ inches (3.8 cm) above the iliac crests (L3).
5. Place a contact shield over the gonads without obscuring the area of interest.
6. Ask the patient to suspend their breathing on expiration.
7. Some radiologists prefer that the AP projection be performed with the collimator open to the cassette size, especially in trauma patients. This provides additional information about the abdomen, such as air or bowel gas patterns.

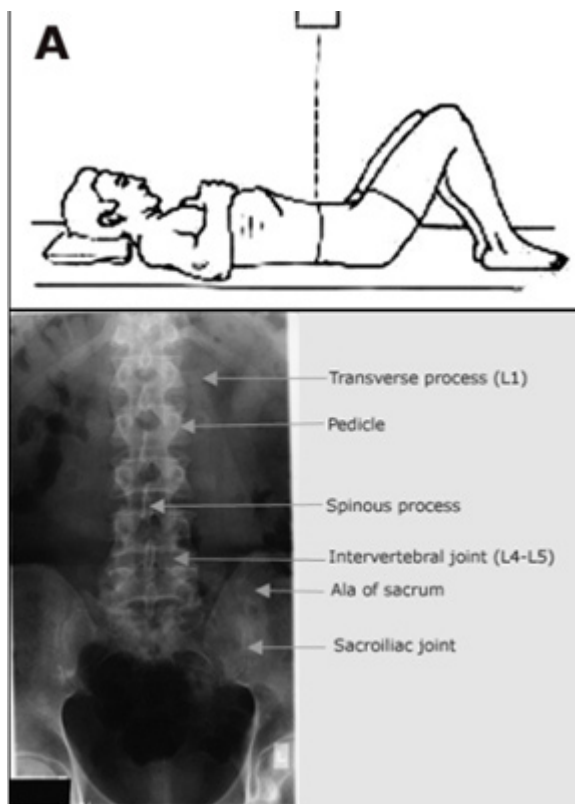


Continued

Evaluation criteria

- Lumbar vertebral bodies, disk spaces, spinous and transverse processes, lateral margin of psoas muscle, SI joints, and the sacrum should be clearly demonstrated. For a lumbosacral spine examination, T11 to the distal sacrum should be included; for a lumbar examination, T12 to S1 should be included.
- There should be no rotation of the vertebral column. Rotation can be evidenced on a radiograph by looking at following areas:
 - Spinous processes in the midline of the vertebral bodies.
 - Right and left transverse processes equal in length.
 - Symmetric vertebrae.
 - Sacroiliac joints demonstrate equal distance from the spine.
- Optimal exposure should clearly demonstrate soft tissues as well as margins of psoas muscle and bony vertebrae.

(Fig.1)



For an AP projection of the lumbar spine, the patient is supine on the table, with their hips and knees flexed to eliminate the normal physiologic lumbar lordosis. The CR is directed vertically to the center of the abdomen at the level of the iliac crests. The radiograph in this projection demonstrates the vertebral bodies and the intervertebral disk spaces. The spinous processes are seen enface, appearing as teardrops, and the pedicles, also visualized enface, project as oval densities on either side of the bodies. Image courtesy of Dr. Naveed Ahmad.

**Continued**

Lateral projection of the lumbar-lumbosacral spine

Technical factors

- IR: 14 x 17 inch (35 x 43 cm) for the lumbosacral spine, 11 x 14 inch (30 x 35 cm) for the lumbar spine only
- 85-90 kVp range for the lumbosacral spine (the lateral position requires a higher kVp than a spine position because of increased part thickness)
- mAs 50
- Moving or stationary grid
- Minimum SID of 40 inches (100 cm)

Positioning for lateral projection of the lumbar-lumbosacral spine

1. The patient is positioned either recumbent or upright on the radiographic table with a pillow for the head (use the same body position as for PA or AP projection).
2. Ask the patient to turn onto the affected side so that the mid-coronal plane of the body is aligned to the midline of the grid, then place a radiolucent support under the waist and adjust it so that the long axis of the spine is horizontal (parallel to the table).
3. To better maintain a true lateral position, flex the patient's hips and knees to a comfortable position. Their knees should be exactly superimposed to prevent rotation. Place a support (a small sandbag) between their knees to ensure no movement.
4. If the patient has a lateral curvature (scoliosis) of the spine, they should be placed in whichever lateral position places the convexity of the spine down. This helps open the intervertebral spaces.
5. If the lateral projection is performed in the upright position, ensure that the patient stands straight with weight equally distributed on the feet and hands above the head (having the patient grasp an IV stand with both hands at shoulder height helps to achieve immobilization).
6. Place a contact shield over the gonads without obscuring the area of interest.
7. Ask the patient to suspend their breathing on expiration.
8. CR: Direct the CR perpendicular to the long axis of the spine. When using a 14 x 17 inch (35 x 43 cm) cassette for a lumbosacral spine examination, center it at the level of the iliac crest (L4-L5). When using an 11 x 14 inch (30 x 35 cm) cassette for a lumbar spine examination, center it 1-1/2 inches (3.8 cm) above the iliac crest.



Continued

Sometimes the long axis of the spine cannot be adjusted horizontal (parallel to the table), due to the patient's body habitus (this is especially true for women with a wide pelvis). In those cases a 5°-10° caudad angulation of the CR is desired.

9. Close collimation is necessary for lateral spine radiographs. The vertebral column should be centered to the collimated field.
10. A coned-down lateral projection of the lumbosacral junction also is included as part of a routine lumbosacral spine radiographic examination to better delineate spondylothesis (forward movement of one vertebrae in relation to another) involving L5-S1. An 8 x 10 inch (18 x 24 cm) cassette is used. Use the same body position as for a lateral lumbar spine study with a radiolucent support under the lower thorax so the long axis of the spine is horizontal. The CR is centered on a coronal plane 2 inches (5 cm) posterior to the anterior superior iliac spine (ASIS) and 1 ½ inches (3.8 cm) inferior to the iliac crest. The ASIS is easily palpated in all patients when they are lying on their side.

Evaluation criteria

- Lumbar vertebral bodies, intervertebral foramina, disk spaces, spinous and transverse processes, SI joints, and sacrum should be clearly demonstrated. For a lumbosacral spine examination T11 to the distal sacrum should be included; for a lumbar examination T12 to S1 should be included.
- There should be no rotation of the vertebral column. Rotation can be evidenced on a radiograph by looking at following areas:
- Nearly superimposed iliac crests when the x-ray beam is not angled.
- Superimposed posterior margins of each vertebral body.
- Open intervertebral disc spaces.
- The vertebrae should be aligned down in the middle of the radiograph.
- The L5-S1 lumbosacral junction lateral projection should demonstrate the lower one or two lumbar vertebrae and the upper sacrum with lumbosacral joint in the center of the radiograph.
- Optimal exposure should demonstrate clearly soft tissues as well as joint spaces and bony vertebrae.

Oblique projection of the lumbar-lumbosacral spine

As in the cervical spine, an oblique projection of the lumbar spine can be obtained from either the patient's anterior or posterior aspect, although the PA oblique projection



Continued

is preferable. Oblique radiographs allow evaluation of the posterior elements of the lumbar spine (lamina, pedicle, the facet joints, and intervertebral foramina) although some regard the oblique projections as unnecessary.

The L5 intervertebral foramina (right and left) are not usually well visualized on the lateral projection because of their oblique direction. Consequently, oblique projections are used for these foramina. When oblique projections are indicated, they are generally performed after the AP projection and in the same body position (recumbent or upright). For comparison, radiographs are generally obtained from both sides (right and left oblique).

Technical factors

- IR: 14 x 17 inch (35 x 43 cm) or 11 x 14 inch (30 x 35 cm), lengthwise
- 75- 80 kVp range, some department protocols require use of a higher kVp (85-90) with reduction of mAs
- mAs 15 (at 85 kVp)
- Moving or stationary grid
- Minimum SID of 40 inches (100 cm)

Positioning for oblique projections of the lumbar-lumbosacral spine

1. Have the patient in a semi-supine (right posterior oblique and left posterior oblique) or semi-prone (right anterior oblique and left anterior oblique) position by elevating their shoulder, hip, and knee so that the patient turns from the supine position toward their side, approximately 30°-45°. A support may be placed under the elevated shoulder, hip, and knee. This helps to bring the facet joints closest to the cassette.
2. A 45°oblique from the plane of the table visualizes the facet (zygopophyseal joints) at L1-L4, whereas a 30° oblique from the plane of the table visualizes L5-S1 to a better advantage.
3. The long axis of the spine should be horizontal (parallel to the table) and in the midline of the grid.
4. CR: Direct the CR perpendicular to the midpoint of the cassette, entering 2 inches (5 cm) medial to the ASIS and 1 ½ inches (3.8 cm) above the iliac crest.



Continued

Evaluation criteria

- The oblique projections of the lumbosacral spine should demonstrate the articular process and facet joints of the side closest to the cassette. They should be open and uniformly visible through the vertebral bodies.
- Adequate rotation of the spine is evidenced by the position of the pedicles. If the pedicle is anterior on the vertebral body, the patient is not rotated enough, if the pedicle is posterior on the vertebral body, the patient is rotated too much.
- Both sides should be examined for comparison.
- When the patient has been properly positioned in a 30°-45° oblique position, the articular process and facet joints have the appearance of "Scottie dogs."



Radiographic positioning techniques for the cervical spine

Radiographic positioning techniques for the cervical spine

By Dr. Naveed Ahmad

March 26, 2003

This article is the 14th in our series of white papers on radiologic patient positioning techniques for x-ray examinations. If you'd like to comment on or contribute to this series, please e-mail editorial@auntminnie.com.

The most common routine cervical projections are the anteroposterior (AP), AP open mouth, and lateral. Oblique projections of the cervical spine are not routinely obtained, although they may be called for to help visualize obscure fractures of the neural arch and abnormalities of the neural foramina and apophyseal joints.

Structurally, the first and second cervical vertebrae possess anatomic features distinct from those of the remaining five cervical vertebrae. The first cervical vertebra, C-1 or atlas, is a bony ring consisting of anterior and posterior arches connected by two lateral masses. The atlas has no body; its main weight-bearing structures are the lateral masses, also called articular pillars. The second vertebra, C-2 or axis, is a more complex structure whose distinguishing feature is the odontoid process, also known as the "dens" (tooth), projecting cephalad from the anterior surface of the body.

The vertebrae C-3 to C-7 exhibit identical anatomic features and are more uniform in appearance, consisting of a vertebral body and a posterior neural arch, including the right and left pedicles and laminae, which together with the posterior aspect of the body enclose the spinal canal. Extending caudad and cephalad from the junction of the pedicle and lamina on each side are superior and inferior articular processes, which form the apophyseal joints between the successive vertebrae. Extending laterally from the pedicle on each side is a transverse process, and in the posterior portion, a spinous process extends from the junction of the laminae in the midline.

Lateral projection of the cervical spine

Radiographic examination of a patient with cervical spine trauma may be difficult and is usually limited to one or two projections. Frequently the patient is unconscious, there are associated injuries, and unnecessary movement risks damage to the cervical cord. The single most valuable projection in these instances is the lateral view, which may be obtained in the standard fashion or with the patient supine, depending on their condition.

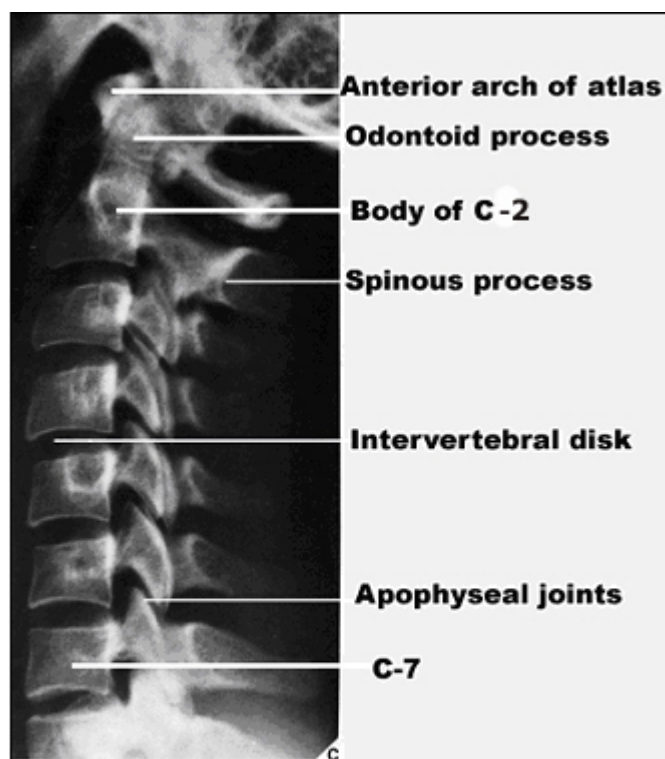
This projection suffices to demonstrate most traumatic conditions of the cervical spine, including injuries involving the anterior and posterior arches of C-1; the odontoid process, which is seen in profile; and the anterior atlantal-dens interval. The bodies and



Continued

spinous processes of C-2 to C-7 are fully visualized, and the intervertebral disk spaces and prevertebral soft tissues can be adequately evaluated.

(Fig. 1)



Lateral view of cervical spine. The film in this projection clearly shows the vertebral bodies, apophyseal joints, spinous processes, and intervertebral disc spaces. It is mandatory to demonstrate the C-7 vertebrae. Image courtesy of Dr. Naveed Ahmad.

The lateral view can also be obtained in flexion and extension of the neck, which is particularly effective in demonstrating suspected instability at C-1 to C-2 by allowing evaluation of the atlanto-odontoid distance. It is of the utmost importance on the lateral projection of the cervical spine that the C-7 vertebra be visualized, as this is the most commonly overlooked site of injury.

Technical factors

- Image receptor (IR): 8 x 10 inch (18 x 24 cm)
- 70-80 kVp range, mAs 28
- Use of grid is optional
- Minimum SID of 60 inches-72 inches (150-180 cm)



Continued

Positioning for a lateral projection of the cervical spine

1. For non-trauma cases, position the patient in a lateral position, either seated or standing, with the patient's shoulder against a vertical cassette holder.
2. Center the mid-coronal plane (the plane that passes through the mastoid tips) to the midline of the cassette.
3. Adjust the shoulders to lie in the same horizontal plane and be sure the patient's body is in a true lateral position with the long axis of the cervical vertebrae parallel to the plane of the cassette.
4. Ask the patient to elevate the chin slightly (to prevent superimposition of the upper cervical spine by the mandible).
5. As a final step before exposure, ask the patient to relax and drop the shoulders down and forward as far as possible. Be careful to ensure that the patient does not elevate the shoulders.
6. If the clinician's request asks for a lateral projection with flexion and extension then perform the following procedures. For a flexion projection, ask the patient to depress the chin until it touches the chest -- or as far as the patient can tolerate. For an extension view, ask the patient to raise the chin with the head tilted back as far as possible.
7. When radiographing a trauma patient, do not remove cervical collar and do not manipulate the head or neck. With the patient in the supine position on a stretcher or radiographic table, support the cassette vertically against their shoulder, or place the stretcher next to a vertical grid device.
8. The central ray (CR) should be perpendicular to the cassette and will be directed horizontally to C-4 (level of upper margin of thyroid cartilage).

Evaluation criteria

- C-1 through C-7 cervical vertebral bodies, intervertebral disc spaces, articular pillars, spinous processes, and apophyseal joints should be demonstrated.
- The junction of C-1 to T-1 should be seen; otherwise additional views such as the swimmer's view should be obtained.
- The rami of the mandible should not superimpose C-1 to C-2.
- No rotation can be evidenced by superimposition of both rami of mandible, both side apophyseal joints, and posterior borders of the vertebral bodies.



Continued

- For extension view, spinous processes should be in close proximity.
- For flexion view, spinous processes should be well separated.
- Optimal exposure should clearly demonstrate soft tissues as well as margins of air column and bony vertebrae.

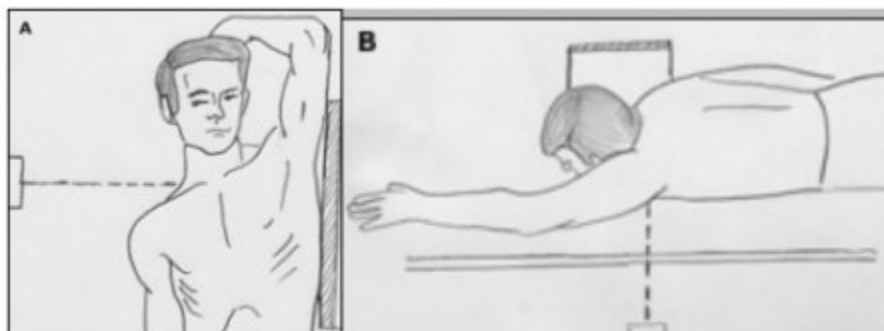
Cervicothoracic (swimmer's view) lateral projection of cervical spine

Special projections may occasionally be required for sufficient evaluation of the structures of the cervical spine. The swimmer's view may be employed for better demonstration of C-7, T-1, and T-2 vertebrae, which on the standard lateral projection are obscured by the overlapping clavicle and soft tissues of the shoulder girdle.

Technical factors

- IR: 10 x 12 inch (24 x 30 cm)
- 80-85 kVp range, mAs 120
- Minimum SID of 60 inches-72 inches (150-180 cm)

(Fig. 2)



A: For a swimmer's view projection, the arm adjacent to the vertical grid is elevated and flexed, resting the forearm on the head for support, while the other arm is depressed and moved slightly anterior to place the vertebral head anterior to the vertebrae. The CR is centered to T1 and directed perpendicular to the shoulder.

B: A swimmer's view projection can also be taken with the patient placed prone on the table with the left hand abducted 180° and the right hand to the side, as if swimming. The cassette is placed against the right side of the neck. Image courtesy of Dr. Naveed Ahmad.



Continued

Positioning for swimmer's view lateral projection of the cervical spine

1. Position the patient in a lateral position (sitting or standing) against a vertical grid device (this view can be performed in the recumbent position if the patient's condition requires it).
2. Align midcoronal plane of the body to the midline of the grid.
3. Ask the patient to elevate the arm adjacent to the vertical grid and flex it, resting the forearm on their head for support, while the other arm is depressed and moved slightly anterior, which will place the vertebral head anterior to the vertebrae.
4. Adjust the thorax and head to a true lateral position.
5. Suspend the patient's breathing in full expiration when making the exposure.
6. The CR is centered to T-1 and directed perpendicular to the shoulder if the shoulder is well depressed. If the shoulder is not well depressed, a caudal angle of 5° is necessary to separate the two shoulders.
7. The swimmer's view projection can also be taken with the patient placed prone on the table with the left hand abducted 180° and their right arm by their side, as if swimming. The cassette is placed against the right side of the neck, as for the standard cross-table lateral view.

Evaluation criteria

- Intervertebral spaces and vertebral outline from approximately C-5 to T-4 should be clearly demonstrated through shoulder structures.
- The shoulders should be separated from one another.

AP axial projection of the cervical spine

On the AP view of the cervical spine the bodies of the C-3 to C-7 vertebrae (in young patients the C-1 and C-2 vertebrae may be visible) are well demonstrated, as are the uncovertebral (Luschka) joints, and the intervertebral disk spaces. The spinous processes are seen almost on end, casting oval shadows that resemble teardrops.

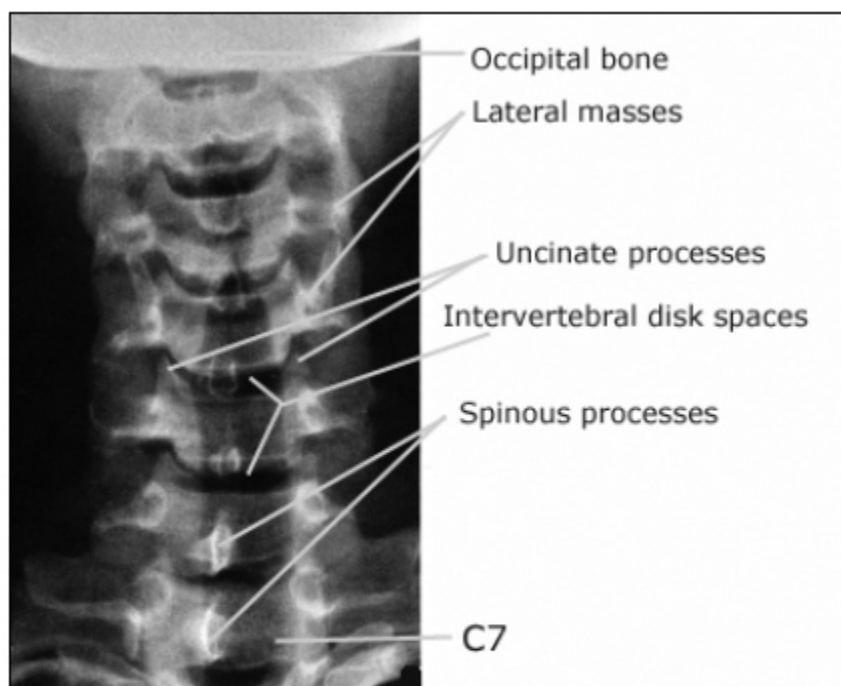


Continued

Technical factors

- IR: 8 x 10 inch (18 x 24 cm)
- 70-80 kVp range, mAs 12
- Minimum SID of 40 inches (100 cm)

(Fig. 3)



An AP axial cervical spine radiograph. Note that this projection demonstrates the C-3 through C-7 vertebral bodies and the intervertebral spaces. The spinous processes are seen superimposed on the bodies resembling teardrops. The C-1 and C-2 vertebrae are not adequately seen. Image courtesy of Dr. Naveed Ahmad.

Positioning for an AP projection of the cervical spine

1. The patient is placed in the supine or upright position with their back against the cassette holder; the shoulders should lie in the same horizontal plane to prevent rotation.
2. Align the midsagittal plane of the patient's body to the midline of the table or IR.
3. The chin of the patient should be extended enough so that a line from the upper



Continued

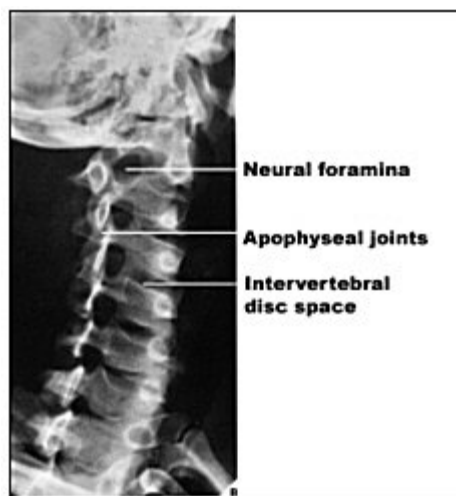
occlusal plane (chewing surface of teeth) to the base of the skull (mastoid tips) is perpendicular to the table or IR. This will prevent superimposition of the mandible and mid-cervical vertebrae.

4. Center the cassette at the level of C-4.
5. Ensure no rotation of the head by adjusting the head so that the mid-sagittal plane is in straight alignment and perpendicular to the cassette.
6. The CR is directed through C-4 at an angle of 15°-20° cephalad. The CR should enter at the level of the lower margin of the thyroid cartilage to pass through C-4.

Evaluation criteria

- C-3 to T-2 or T-3 vertebral bodies should be shown and the space between the pedicles and intervertebral disk spaces should also be clearly seen.
- No rotation: Spinous processes and sternoclavicular joints (if visible) should be equidistant from the spinal column lateral borders. The mandible and base of the skull will be superimposed over the first two cervical vertebrae.
- Intervertebral disk spaces should be open, indicating correct CR angle.

(Fig. 4)



Oblique view of the cervical spine. This view is effective primarily for demonstrating neural foramina. Image courtesy of Dr. Naveed Ahmad.



Continued

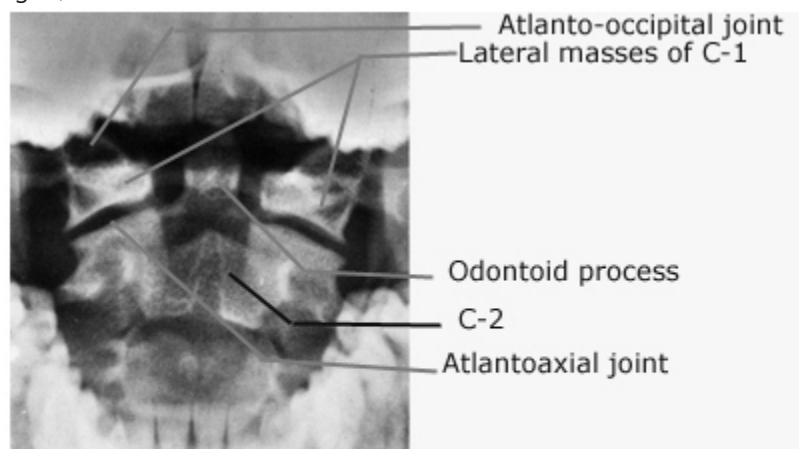
AP "open-mouth" projection of the cervical spine

This variant of the AP projection, also known as the "open-mouth" view, may be obtained as part of the standard cervical spine examination. This view provides effective visualization of the structures of the first two cervical vertebrae. The body of C-2 is clearly imaged, as are the atlantoaxial joints, the odontoid process, and the lateral spaces between the odontoid process and the articular pillars of C-1.

Technical factors

- IR: 8 x 10 inch (18 x 24 cm)
- 70-80 kVp range, mAs 15
- Minimum SID of 40 inches (100 cm)

(Fig. 5)



Open-mouth radiograph of the cervical spine. On this radiograph the odontoid process, the body of C-2, and lateral masses of the atlas are well demonstrated. The atlantoaxial joints are seen to best advantage. Image courtesy of Dr. Naveed Ahmad.

Positioning for open-mouth projection of the cervical spine

1. The patient is placed in the supine or upright position with their back against the cassette holder. Be sure that their shoulders lie in the same horizontal plane to prevent rotation. Center the midsagittal plane of the body to the midline of the grid and place the patient's arms along the sides of their body.
2. Align the patient's head so that the midsagittal plane is perpendicular to the plane of the table and center the cassette at the level of the axis.
3. Ask the patient to open his or her mouth as wide as possible, and then adjust the



Continued

head so that a line from the lower margin of the upper incisors to the base of the skull (tip of the mastoid process) is perpendicular to the cassette.

4. Ensure that the mouth remains wide open during exposure. During the exposure, the patient should softly phonate an "ah" to affix the tongue to the floor of the mouth so that its shadow is projected over C-1 and C-2.
5. The CR is directed through the center of the open mouth, and is perpendicular to the center of the cassette.

Evaluation criteria

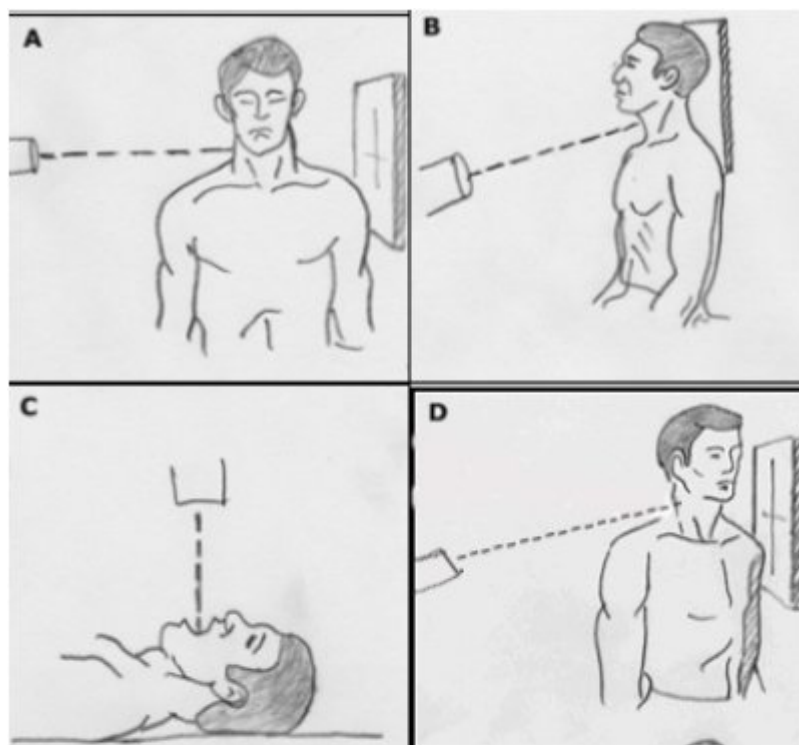
- The dens (odontoid process) and vertebral body of C-2, the lateral masses of C-1, and apophyseal joints between C-1 and C-2 should be clearly demonstrated through the open mouth.
- Neither the teeth nor the skull base should superimpose the dens. If the teeth are superimposed on the upper dens, reposition by slight hyperextension of the skull and angle the CR slightly cephalic. If the base of the skull is superimposed on the upper dens, reposition by slight hyperflexion of the neck or angle the CR slightly caudal.
- Rotation can imitate pathology by causing unequal spaces between the lateral masses and dens. No rotation is evidenced by equal distances from the lateral masses to the condyles of the mandible, and by center alignment of the spinous process of C-2.
- Optimal exposure should demonstrate both bone and soft-tissue density.

(see Fig. 6, next pg.)



Continued

(Fig. 6)



A: For the erect lateral view of the cervical spine, the patient is standing or sitting, with head straight in neutral position. The CR is directed horizontal to the center of C-4 vertebra (at the level of the chin).

B: For the AP view of the cervical spine, the patient is either erect or recumbent. The beam is directed toward the C-4 vertebra (at the Adam's apple) at an angle of 15°-20° cephalad.

C: For the open-mouth view, the patient is positioned in the same manner as for the supine AP projection; the head is straight, in the neutral position. With the patient's mouth open as wide as possible; the CR is directed perpendicular to the midpoint of the open mouth.

D: For the oblique view of the cervical spine, the patient may be erect or recumbent. The patient is rotated 45° to the left, to demonstrate the left-side neural foramina. The CR is directed to the C-4 vertebra with 15°-20° cephalad angulation. Image courtesy of Dr. Naveed Ahmad.



Boning up on humerus, clavicle, and AC joint positioning

Boning up on humerus, clavicle, and AC joint positioning

By Dr. Naveed Ahmad

February 18, 2003

This article is the 13th in our series of white papers on radiologic patient positioning techniques for x-ray examinations. If you'd like to comment on or contribute to this series, please e-mail editorial@auntminnie.com.

For the humerus, anteroposterior (AP) and lateral radiographs constitute the basic examination. Both views should include the elbow and joints of the shoulder, with the elbow manifesting a true lateral configuration in the lateral projection.

Technical factors

- Image receptor (IR): lengthwise (large enough to include the entire humerus) 14 x 17 inch (35 x 43 cm).
- Moving or stationary grid (non-grid detail screen for smaller patients).
- kVp: 70 ± 5 kVp with screen; 65-70 kVp with grid on larger patients.
- mAs: 6.
- SID: minimum of 40 inches (101 cm).

Positioning for an AP projection of the humerus

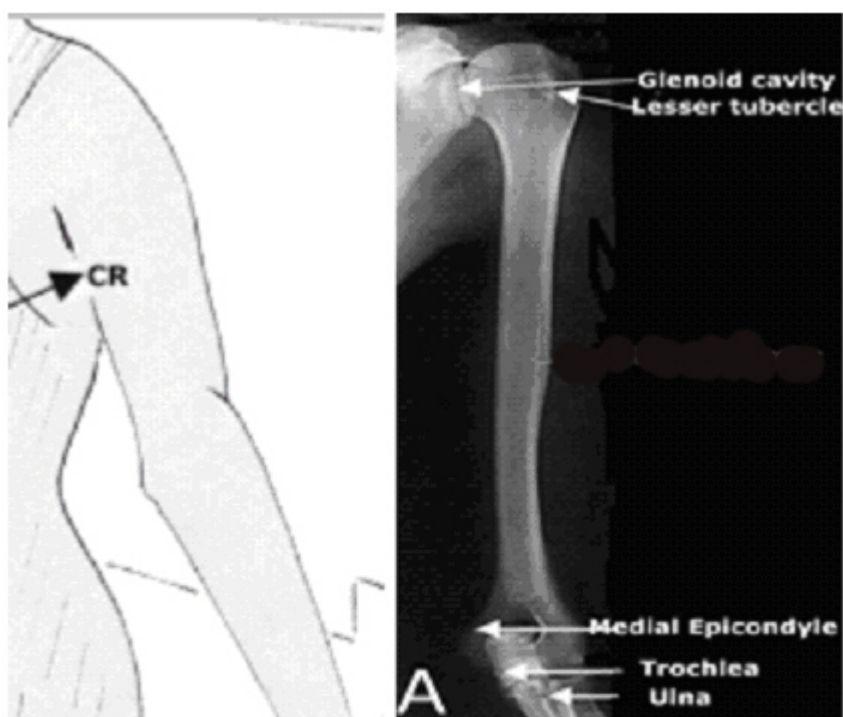
1. Place the patient in an upright-seated or standing position facing the x-ray tube. However, if the patient's condition doesn't allow upright positioning, an AP projection can be performed in the supine position.
2. Adjust the height of the cassette to place its upper margin about 1½ inches (3.8 cm) above the head of the humerus.
3. Abduct the arm slightly, and supinate the hand so that epicondyles of the elbow are equidistant from IR.
4. A coronal plane passing through the epicondyles should be parallel with the cassette plane for the AP or posteroanterior (PA) projection.
5. Respiration: suspend.
6. Central ray (CR): perpendicular to the midportion of the humerus and the center of the cassette.

(see Fig. 1, next pg.)



Continued

(Fig. 1)



Upright positioning for AP humerus; the CR is directed perpendicular to the midportion of the humerus. The adjacent radiograph is in AP projection. Greater tubercle are seen in profile laterally while the medial and lateral epicondyles are both visualized in profile. Image courtesy of Dr. Naveed Ahmad.

Evaluation criteria for AP projection of humerus

- AP projection of the entire humerus, including the shoulder and elbow joints.
- Long axis of the humerus should be aligned to the long axis of the IR.
- A true AP projection is evidenced at the proximal humerus by the following:
 - The greater tubercle is seen in profile laterally.
 - The humeral head is partially seen in profile medially, with minimal superimposition of the glenoid cavity.
 - The distal humerus should show both lateral and medial epicondyles visualized in profile.
- CR and center of the collimation field should be to the approximate midpoint of the humerus.
- Optimal density and contrast with no motion and sharp cortical margins. Bony trabecular markings should be demonstrated at both the proximal and the distal portions of the humerus.

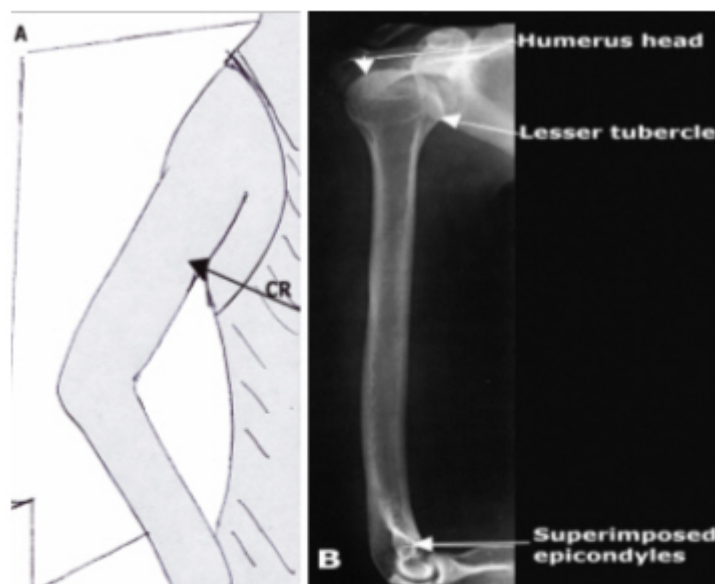


Continued

Positioning for a lateral projection of the humerus

1. Place the patient in a seated-upright or standing position facing the x-ray tube. However, if the patient's condition doesn't allow upright positioning, a lateral projection can be performed in the supine position.
2. Place the top margin of the cassette approximately 1½ inches (3.8 cm) above the level of the head of the humerus.
3. Unless contraindicated by possible fracture, internally rotate the arm, flex the elbow approximately 90°, and place the patient's hand on their hip. A coronal plane passing through the epicondyles should be perpendicular with the cassette plane.
4. Respiration: suspend.
5. CR: perpendicular to the midportion of the humerus and the center of the cassette.

(Fig. 2)



Upright position for lateral humerus. The patient's hand is placed on the hip, and the CR is directed perpendicular to the midportion of the humerus. The adjacent lateral projection shows lesser tuberosity in profile medially and superimposed epicondyles. Image courtesy of Dr. Naveed Ahmad.



Continued

Evaluation criteria for lateral projection of humerus

- A lateral projection of the entire humerus, including elbow and shoulder joints, should be visible.
- A true lateral projection is evidenced by the following:
 - Epicondyles are directly superimposed.
 - Lesser tubercle is shown in profile medially, partially superimposed by lower portion of glenoid cavity.
- CR and center of collimation field should be to the approximate midpoint of the humerus.
- Optimal density and contrast with no motion and sharp bony trabecular markings of entire humerus should be seen.

Radiographic positioning for the clavicle

The radiographic evaluation of the clavicle requires AP and AP axial projections.

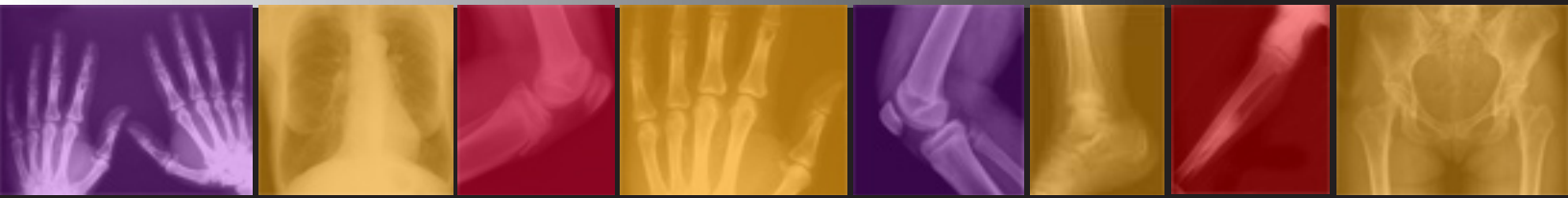
Technical factors

- IR: 25 x 30 cm (10 x 12 inch) crosswise.
- Automatic exposure control (AEC) is not recommended.
- Digital IR requires very close collimation.
- kVp: 70 ± 5 kVp range.
- mAs :8.
- SID: minimum of 40 inches (101 cm).

Positioning for an AP projection of the clavicle

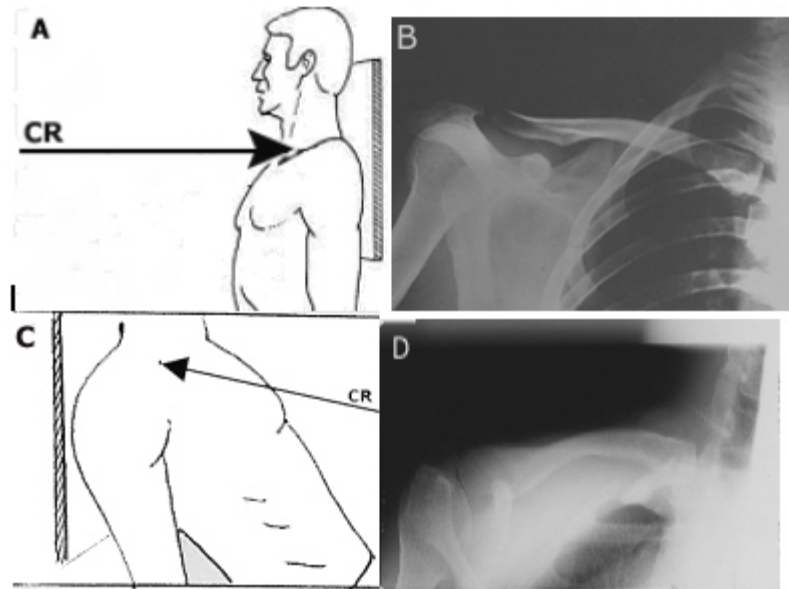
1. Place the patient in the supine or upright position.
2. Adjust the body to center the clavicle to the midline of the table or vertical grid device.
3. Place the patient's arms along the sides of their body, and adjust their shoulders to lie in the same horizontal plane.
4. Center the clavicle to the cassette.
5. Respiration: suspend at the end of exhalation to obtain a more uniform-density image.
6. CR: perpendicular to the mid-clavicle.

(see Fig. 3, next pg.)



Continued

(Fig. 3)



A: AP clavicle: The CR is perpendicular to the midshaft of the clavicle.

B: AP radiograph of clavicle. The lateral half of the clavicle is above the scapula, with the medial half superimposing the thorax.

C: AP axial clavicle, lordotic position. The CR is angled 15° cephalad to midclavicle.

D: AP axial radiograph of the clavicle. Most of the clavicle is projected above the ribs and scapula with the medial end overlapping the first rib.

Image courtesy of Dr. Naveed Ahmad.

Positioning for an AP axial projection of the clavicle

1. Stand or seat the patient 1 foot (30 cm) in front of the vertical cassette device, with the patient facing the x-ray tube. Alternatively, if the patient is unable to stand and assume the lordotic position, place the patient supine on the table.
2. If the patient is in the standing lordotic position, have the patient lean backward in a position of extreme lordosis, and rest the neck and shoulder against the vertical grid device. The neck will be in extreme flexion.
3. Center the clavicle to the center of the cassette.
4. Respiration: suspend at the end of full inspiration to further elevate and angle the clavicle.
5. CR: 15°-30° cephalad to mid-clavicle. Thinner patients will require more angulation to project the clavicle off the scapula and ribs. For the standing lordotic position, 0°-15° is recommended. For the supine position, 15°-30° is recommended.



Continued

Evaluation criteria for the clavicle

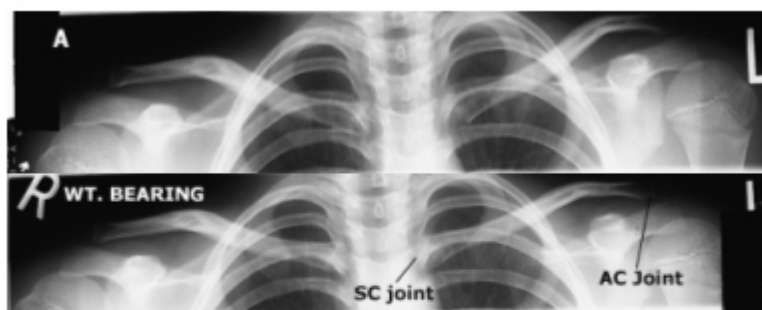
- On a true AP projection, the lateral half of the clavicle should be seen above the scapula, with the medial half superimposing the thorax.
- On an AP axial projection, most of the clavicle should be projected above the scapula and ribs. Only the medial portion of the clavicle will be superimposed by the first and second ribs.
- On an AP axial projection, the entire clavicle should be clearly demonstrated in a horizontal placement along with the acromioclavicular (AC) joint and the sternoclavicular (SC) joint.

Radiographic positioning for the AC joint

The AC joint is a small synovial joint between the lateral end of the clavicle and the medial aspect of the acromion of the scapula. It permits both gliding and rotary (elevation, depression, protraction, and retraction) movements. Although the AC joint is visualized in routine views of the shoulder, it may be superimposed on other osseous structures.

Radiographs obtained in the frontal projection with a cephalad tilt of the incident beam of approximately 15° are superior in delineating abnormalities of this articulation. Stress radiographs are frequently necessary to diagnose AC joint subluxation and dislocation. These are obtained by having the patient hold a 2.3-7 kg (5-15 pound) mass (weight) in the hand or tying this weight to the wrist. If possible, it is beneficial to view both AC joints on a single film. This allows comparison of the two joints, permitting the radiologist to observe the distance between the coracoid process and clavicle on both sides.

(Fig. 4)



AP AC joints, with and without weight-bearing, with both AC joints on a single film. This technique enables comparison of the two joints, permitting the radiologist to observe the distance between the coracoid process and clavicle on both sides. Image courtesy of Dr. Naveed Ahmad.



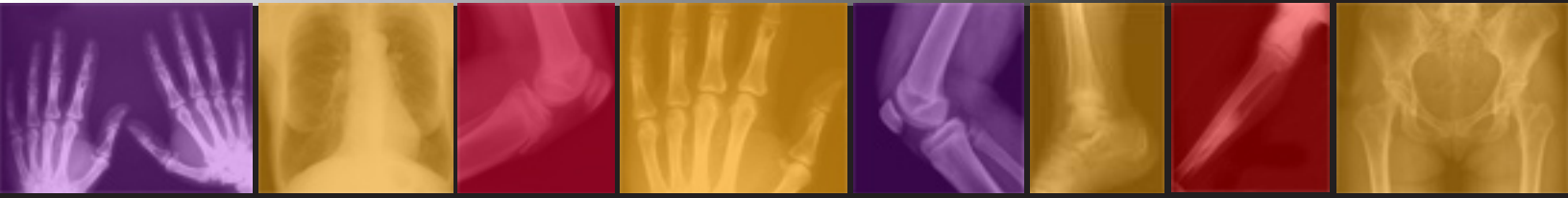Continued

Technical factors

- IR: 7 x 17 inch (18 x 43 cm) or two 8 x 10 inch (20 x 25 cm), as needed to fit the patient.
- "With weight" and "without weight" markers.
- No grid.
- AEC is not recommended.
- kVp: 65 ± 5 kVp with screen; 65-70kVp (with grid) on larger patients.
- mAs: 20.
- SID: 72 inches (183 cm). A longer SID reduces magnification, which enables both joints to be included on one image. It also reduces the distortion of the joint space resulting from CR divergence.

Positioning for an AP projection of the AC joint

1. Place the patient in the upright position either seated or standing -- because dislocation of the AC joint tends to reduce itself in the recumbent position -- before a vertical grid device, and adjust the height of the cassette so that the midpoint lies at the same level as the AC joints.
2. Center the midline of the body to the midline of the grid.
3. Ensure that the weight of the body is equally distributed on the feet to avoid rotation.
4. With the patient's arms hanging by their side, adjust their shoulders to lie in the same horizontal plane. It is important that the arms hang unsupported.
5. Make two exposures: one in which the patient is standing upright without weights attached, and a second in which the patient has equal weights (5-8 pound, 2.3-3.6 kg) affixed to each wrist.
6. After the first exposure, slowly affix the weights to the patient's wrist using a band or strap.
7. Instruct the patient not to favor (tense) the injured shoulder.
8. Avoid having the patient hold the weights as this makes the shoulder muscles contract, thus reducing the possibility of demonstrating a small AC separation.
9. Respiration: suspend.

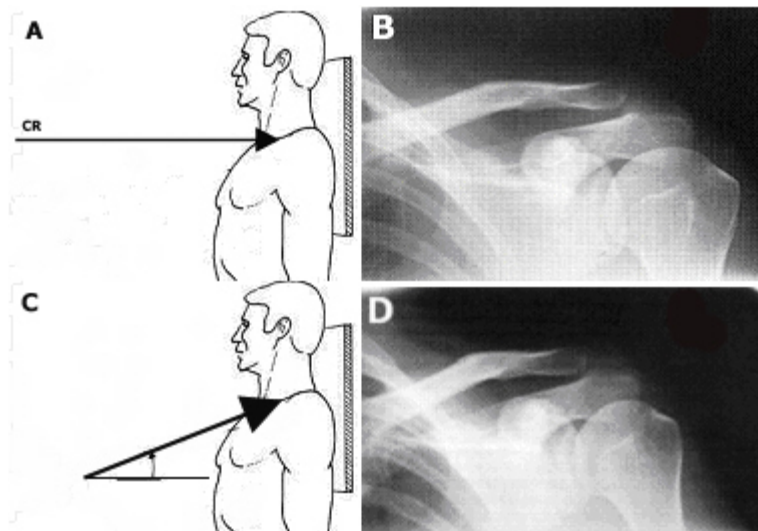


Continued

10. CR:

- In the Pearson method (AP projection) the CR is perpendicular to the midpoint between the AC joints for a single projection, and is directed at each respective AC joint when two separate exposures are needed for each shoulder in broad-shouldered patients.
- In the Alexander method (AP axial projection), which is superior in delineating abnormalities of AC joint, the CR is directed to the coracoid process at a cephalic angle of 15°. This angulation projects the AC joint above the acromion.

(Fig. 5)



A: Bilateral AP AC joints: The CR is directed to a middle point between AC joints.

B: AP projection of AC joint with the CR directed to the left AC joint.

C: AP axial AC joint (Alexander method). The CR is directed to the coracoid process at a cephalic angle of 15°.

D: AP axial projection showing AC joint projecting above the acromion.

Image courtesy of Dr. Naveed Ahmad.



Continued

Evaluation criteria for an AC joint radiograph

- Both AC joints, as well as the entire clavicles and SC joints, should be entirely included on one or two single radiographs.
- Both AC joints on the same horizontal plane; rotation should be evidenced by symmetric appearance of the SC joints on each side of the vertebral column.
- CR and center of the collimation field should be at the midpoint between the AC joints.
- Optimal density and contrast should clearly demonstrate the AC joints and soft tissue without excessive density. Bony margins and trabecular marking will appear sharp, indicating no motion.
- Right and left markers, as well as markers indicating with and without weights, should be visible without superimposing essential anatomy.
- In an AC joint radiograph taken using the Alexander method, the AC joint and clavicle should be projected above the acromion.



Getting the most from shoulder positioning

Getting the most from shoulder positioning

By Dr. Naveed Ahmad

December 24, 2002

This is the 12th in our series of white papers on radiologic patient positioning techniques for x-ray examinations. If you'd like to comment on or contribute to this series, please e-mail editorial@auntminnie.com.

Radiographic positioning of the shoulder (glenohumeral joint)

Radiographic examination of the shoulder area includes evaluation of the shoulder girdle (clavicle and scapula) and the joints of the shoulder girdle (glenohumeral, acromioclavicular, and sternoclavicular). In a non-trauma patient, the radiographic examination of the glenohumeral joint includes rotational views of the proximal humerus. The AP (internal and external rotation) projections satisfactorily demonstrate pathology such as degenerative joint disease (DJD) and calcifications.

In a trauma patient, the shoulder area can be sufficiently evaluated on the AP projection, either with the arm in the neutral position, or with the arm internally or externally rotated. The one limitation of these views is that the humeral head is seen overlapping the glenoid, thereby obscuring the glenohumeral joint space.

An additional radiograph at approximately right angles to the frontal radiographs is mandatory to determine the relative positions of the humeral head and glenoid. This can be accomplished via an AP oblique, scapular Y (PA oblique position), axillary, or transthoracic projection.

Technical factors

- Image receptor (IR): 8 x 10 inch (18 x 24 cm).
- 60 to 70 kVp range, mAs 6.
- Minimum SID of 40 inches (100 cm).

Positioning for an AP projection of the shoulder joint

1. Have the patient upright or in the supine position. The upright position should be used in shoulder-trauma patients whenever possible to avoid movement and pressure.
2. Center the shoulder joint to the midline of the grid.
3. Adjust the position of the cassette so that its center is 1 inch (2.5 cm) inferior to the coracoid process. The coracoid process is about 2 cm inferior to the lateral portion of the palpable clavicle.



Continued

4. Position the arm in the external, internal, or neutral rotation.
5. If necessary to overcome the curve of the back and the resultant obliquity of the shoulder structures, slightly rotate the patient enough to place the body of the scapula parallel with the plane of the cassette.
6. Suspend respiration during the exposure.
7. The central ray (CR) should be perpendicular to a point 1 inch (2.5 cm) inferior to the coracoid process.

External rotation

The external rotation represents the true AP projection of the humerus. Supinating the hand will position the humerus in the external rotation and places the epicondyles of the humerus parallel to the IR. With the external rotation view, the greater tubercle is positioned in profile laterally and the lesser tubercle is located anteriorly. Ask the patient to extend the arm. Abduct and slightly rotate the arm and elbow externally until the palm of the hand is forward (supinate hand) and the epicondyles of the distal humerus are parallel to the plane of the cassette.

(see Fig. 1)

The hand position and its affect on the proximal humerus.

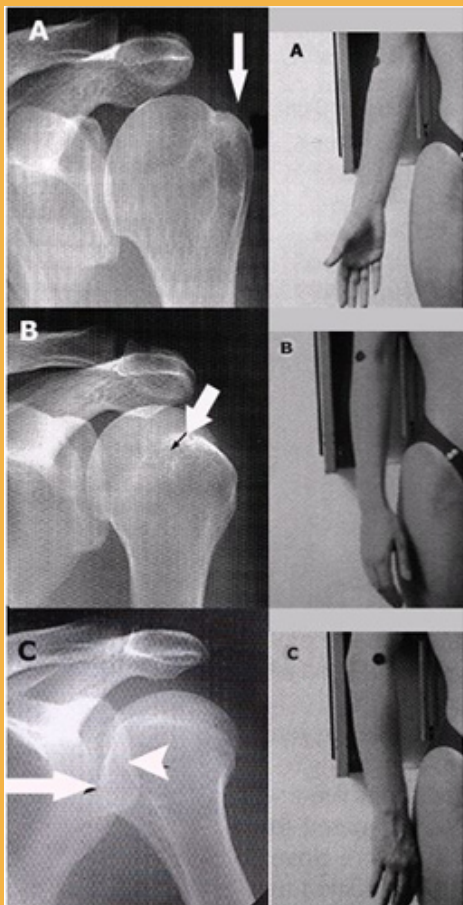
A: Supinating the hand will position the humerus in external rotation. The AP shoulder radiograph in external rotation shows the greater tubercle (arrow) positioned in profile laterally.

B: The palm of the hand placed against the hip will position the humerus in neutral rotation. The AP radiograph in neutral position places the greater tubercle anteriorly (arrow)

C: The posterior aspect of the hand placed against the hip will position the humerus in internal rotation. The AP radiograph with internal rotation shows the greater tubercle (arrowhead) and lesser tubercle (arrow) in profile.

Image courtesy of Dr. Naveed Ahmad.

(Fig. 1)



Reprinted from *Merrill's Atlas of Radiographic Positions and Radiologic Procedures*, 9th edition, Ballinger and Frank, page 161 (table 5-2), copyright 1999 Mosby, with permission from Elsevier Science.



Continued

Internal rotation

The AP projection of the shoulder taken in internal rotation position shows a lateral position of the humerus. The lesser tubercle is seen medially in profile, whereas the greater tubercle is seen rotated anteriorly.

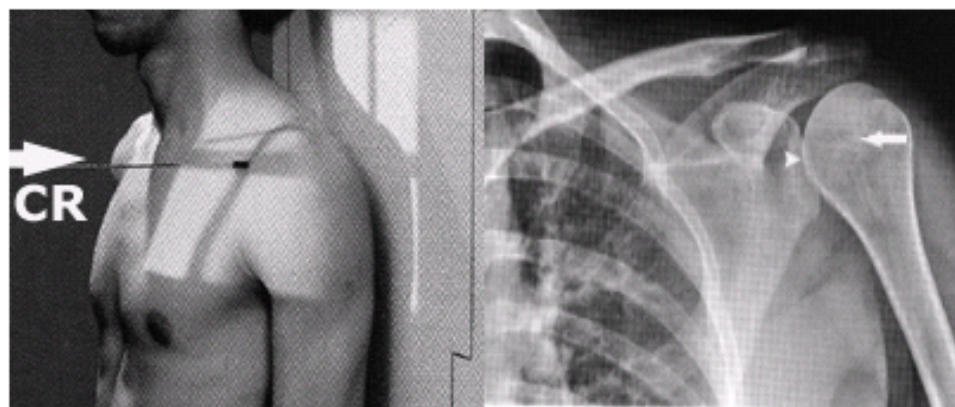
In order to position the shoulder in internal rotation, the posterior aspect of the hand is placed against the hip. This can be done by abducting the extending arm slightly, then internally rotating the arm (pronate hand) until the epicondyles of the distal humerus are perpendicular to the plane of the cassette.

Neutral rotation

The neutral rotation AP projection of the shoulder is taken on a trauma patient when rotation views cannot be accomplished.

In order to position the shoulder in neutral position, ask the patient to rest the palm of the hand against their hip. This arm position rolls the humerus into a neutral position, placing the epicondyles at an angle of about 45° to the plane of the cassette.

(Fig. 2)



AP radiograph in neutral projection.

The CR is directed 1 inch (2.5 cm) inferior to the coracoid process. The humeral head is seen overlapping the glenoid fossa (arrowhead). The greater tubercle is seen anteriorly (arrow). Image courtesy of Dr. Naveed Ahmad.

Reprinted from *Merrill's Atlas of Radiographic Positions and Radiologic Procedures*, 9th edition, Ballinger and Frank, page 163 (figure 5-14), copyright 1999 Mosby, with permission from Elsevier Science.



Continued

Evaluation criteria for an AP projection

- The AP projection of the shoulder should clearly demonstrate the proximal humerus, the lateral two-thirds of the clavicle, and the upper scapula -- including the relationship of the humeral head to the glenoid cavity.
- Optimum density and contrast with no rotation is evidenced by clear, sharp bony trabecular markings with soft-tissue detail visible for possible calcium deposits.
- The full external rotation view is evidenced by the greater tubercle visualized in full profile on the lateral aspect of the proximal humerus. Lesser tubercle is superimposed over humeral head.
- Full internal rotation view is evidenced by the lesser tubercle visualized in full profile on the medial aspect of the humeral head. An outline of the greater tubercle should be visualized superimposed over the humeral head.
- With natural rotation, both the greater and lesser tubercles will be mostly superimposed by the humeral head.

Positioning for an AP oblique projection of the shoulder joint

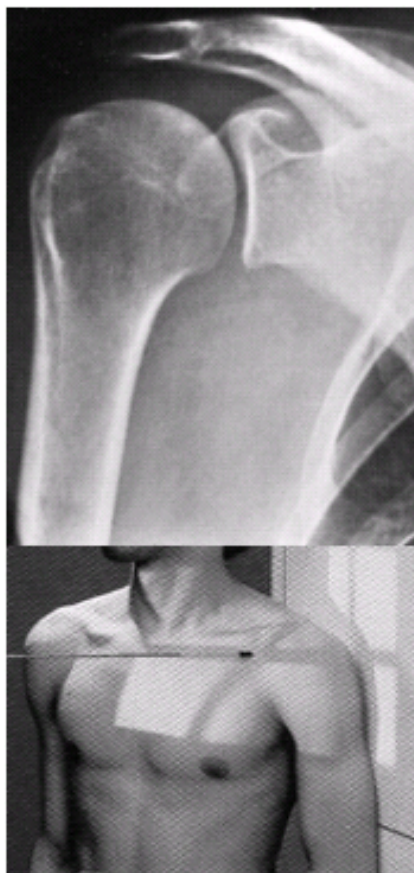The AP projections of the shoulder joint have the limitation of not being able to demonstrate the glenohumeral joint space. The humeral head is seen overlapping the glenoid in the AP projections, thereby obscuring the glenohumeral joint space. Eliminating this overlap can be accomplished by obtaining an AP oblique projection. This special view is known as a Grashey projection.

1. Have the patient in a supine or upright position. The upright position is more comfortable for the patient and facilitates accurate adjustment of the shoulder.
2. Center the cassette to the glenohumeral joint.
3. Rotate the body approximately 35°- 45° toward the affected side.
4. Abduct the arm slightly in internal rotation and place the palm of the hand on the abdomen, if possible.
5. Adjust the degree of rotation to place the scapula parallel with the plane of the cassette. This allows the head of the humerus to be in contact with the cassette.
6. If the patient is in the supine position, the body may need to be rotated more than 45° to place the scapula parallel to the cassette.
7. If the radiograph is done with the patient in the supine position, place supports under the elevated shoulder and hip to maintain position.
8. The CR should be perpendicular to the glenoid cavity at a point 2 inches (5 cm) inferior to the superolateral border of the shoulder.



Continued

(Fig. 3)



Upright AP oblique projection of shoulder joint.

The patient is rotated about 40° toward the side of the suspected injury and the CR is directed perpendicular to a point 2-inches (5 cm) medial and 2-inches (5 cm) inferior to the superolateral border of the shoulder. The film in this projection shows the glenoid in true profile. Note the glenohumeral joint space is now clearly visible. Image courtesy of Dr. Naveed Ahmad.

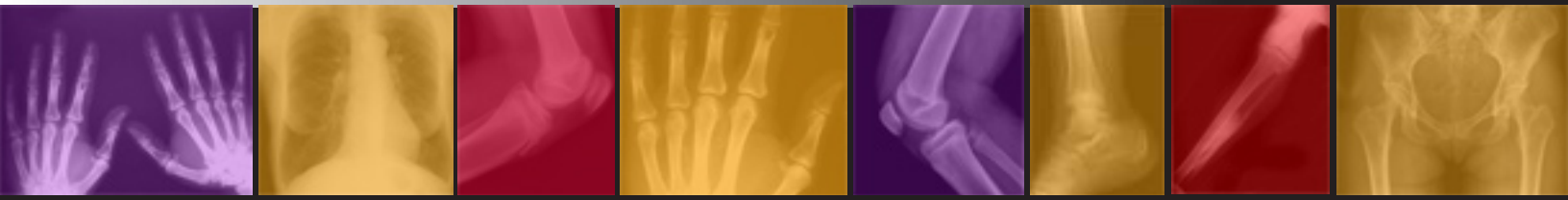
Reprinted from *Merrill's Atlas of Radiographic Positions and Radiologic Procedures*, 9th edition, Ballinger and Frank, page 164 (figure 5-15), copyright 1999 Mosby, with permission from Elsevier Science.

Evaluation criteria

- The glenoid cavity should be seen in profile without superimposition of the humeral head.
- The glenohumeral joint space should be open.
- The anterior and posterior rims of the glenoid cavity are superimposed.

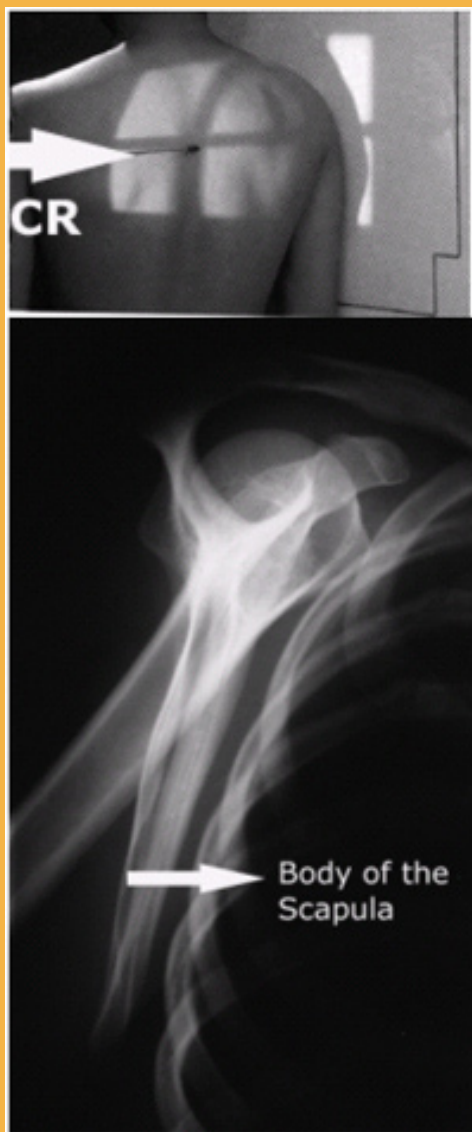
Positioning for the scapular Y projection of the shoulder joint

This projection obtains its name as a result of the appearance of the scapula. The body of the scapula forms the vertical component of the Y, while the acromion and coracoid processes form the upper limbs of the letter.



Continued

(Fig. 4)



This projection is useful in the evaluation of suspected shoulder dislocations. In a normal shoulder, this projection shows the humeral head directly superimposed over the junction of the Y. In anterior dislocations, the humeral head is beneath the coracoid process; in posterior dislocations, it is projected beneath the acromion process.

1. Position the patient in an erect or recumbent position; the upright position is preferred.
2. Position the anterior surface of the shoulder being examined against the upright table.
3. Rotate the patient into an anterior oblique position, as for a lateral scapula, with the patient facing the cassette. An average patient would form an angle of 45°-60° to the cassette.
4. Palpate the scapular borders to determine the correct rotation for a true lateral position of the scapula.
5. Position the center of the cassette at the level of the glenohumeral joint.
6. If the patient is severely injured, modify the anterior oblique by placing the patient in the posterior oblique position.
7. The CR should be perpendicular to the glenohumeral joint.

(see Fig. 4)

Scapular Y lateral projection with the CR perpendicular to the cassette directed to the glenohumeral joint 2 inches (5 cm) below the top of the shoulder. The radiograph shows the true lateral view of the scapula. Image courtesy of Dr. Naveed Ahmad.



Continued

Evaluation criteria

- The scapula should be clearly demonstrated in the lateral profile.
- The thin body of the scapula should be seen on end without rib superimposition.
- The acromion and coracoid processes should appear as nearly symmetric upper limbs of the Y.
- The humeral head should appear superimposed over the base of the Y if the humerus is not dislocated.

Positioning for the transthoracic lateral projection of the shoulder joint

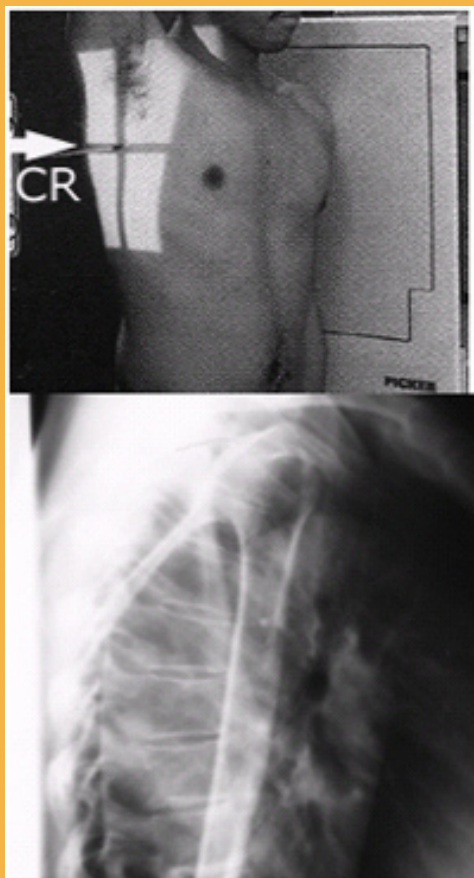Suspected trauma to the proximal humerus may require a transthoracic lateral view for sufficient evaluation. This projection provides a true lateral view of the proximal humerus. If the arm cannot be rotated or abducted, this view is particularly valuable in determining the degree of displacement or angulation of the bony fragments.

1. Have the patient raise the uninjured arm and place their hand over the top of their head, elevating the shoulder as much as possible. Elevating the uninjured shoulder drops the injured side, separating the shoulders to prevent superimposition.
2. Center the cassette to the surgical neck area of the effected humerus. Ensure that the thorax is in a true lateral position.
3. Ask the patient to hold their breath at full inspiration. This improves the contrast and decreases the exposure. However, if the patient can cooperate, a breathing technique is preferred in order to blur the overlying ribs. The patient is asked to practice slow, deep breathing while preventing any voluntary motion.
4. The CR should be perpendicular to the cassette, entering midcoronal plane at the level of the surgical neck. However, if the patient cannot elevate the unaffected shoulder, angle the CR 10°-15° cephalad.

(see Fig. 5)

For the transthoracic lateral projection of the proximal huerus, the patient is upright with the injured arm against the radiographic table. The opposite arm is abducted so that the forearm rests on the head. The CR is directed below the axilla, slightly above the level of the nipple. The film in this projection demonstrates the true lateral view of the proximal humerus. Image courtesy of Dr. Naveed Ahmad.

(Fig. 5)





Continued

Evaluation criteria

- The lateral view of the humerus and glenohumeral joint should be visualized through the thorax without the superimposition of the opposite shoulder.
- The outline of the shaft of the proximal humerus should be clearly visualized anterior to the thoracic vertebrae. There should be no arm motion during exposure.
- The overlying ribs and lung marking should appear blurred because of breathing technique.
- The relationship of the humeral head and glenoid cavity should be demonstrated.

Positioning for an axillary projection of the shoulder joint

A superiorinferior view of the shoulder, known as the axillary projection, is helpful for determining the exact relationship of the humeral head and the glenoid fossa, and for detecting anterior and posterior dislocation. This view can be difficult to obtain, however, especially if the patient is unable to abduct the arm, in which case a variant of the axillary projection, known as the West Point axillary view, may be similarly effective.

1. As mentioned above, before undertaking this position, verify the patient's ability to abduct the arm to a nearly right angle to the long axis of the body.
2. Seat the patient at the end of the table on a stool or chair.
3. Place the cassette near the end of the table and extend the patient's shoulder under the examination well and over the cassette.
4. Center the shoulder to the midline of the cassette by having the patient lean over the cassette.
5. Flex the patient's elbow 90° and place their hand in the prone position.
6. The CR should be angled 5°-15° through the shoulder joint and toward the elbow.

Evaluation criteria

- The coracoid process is seen projecting above the clavicle.
- The lesser tubercle is clearly demonstrated in profile.
- The acromioclavicular joint is seen through the humeral head.
- There is an open glenohumeral joint (this is not open in patients with limited flexibility)

To obtain a West Point axillary view, the patient lies prone on the radiographic table with a pillow placed under the affected shoulder to raise it about 3 inches (8 cm). The film cassette is positioned against the superior aspect of the shoulder. The CR is angled toward the axilla at 25° to the patient's midline, and at 25° to the table's surface.



The bends and flexures of forearm and elbow x-ray positioning

The bends and flexures of forearm and elbow x-ray positioning

By Dr. Naveed Ahmad

November 21, 2002

This article is the 11th in our series of white papers on radiologic patient positioning techniques for x-ray examinations. If you'd like to comment on or contribute to this series, please e-mail editorial@auntminnie.com.

Radiographic positioning of the forearm

Radiographic examination of the forearm is performed using anteroposterior (AP) and lateral projections. Both projections of the forearm demonstrate the elbow joint, the radius and the ulna, and the proximal row of slightly distorted carpal bones.

Technical factors

- Image receptor (IR): Lengthwise 11 x 14 inch (30 x 35 cm) divided; 7 x 17 inch (18 x 43 cm) single; 14 x 17 inch (35 x 43 cm) divided.
- Detail screen, tabletop.
- In a lateral projection, place the elbow at the cathode end of the x-ray beam to make best use of the anode-heel effect.
- 60 to 65 kVp range, mAs 6.
- Minimum SID of 100 cm.

Positioning for an AP projection of the forearm

1. Seat the patient close to the radiographic table and low enough to place the entire limb in the same horizontal plane.
2. Supinate the hand, extend the elbow, and center the unmasked half of the cassette to the forearm. Ensure that both the wrist and elbow joints are included.
3. The long axis of the forearm should be aligned to the long axis of the IR
4. Ask the patient to lean laterally until the forearm is in a true supinated position, and adjust the humeral epicondyles so they are equidistant from the cassette.
5. Ensure that the hand is supinated. Pronation of the hand crosses the radius over the ulna at its proximal third and rotates the humerus medially, resulting in an oblique projection of the forearm.
6. The central ray (CR) should be perpendicular to the midpoint of the forearm.

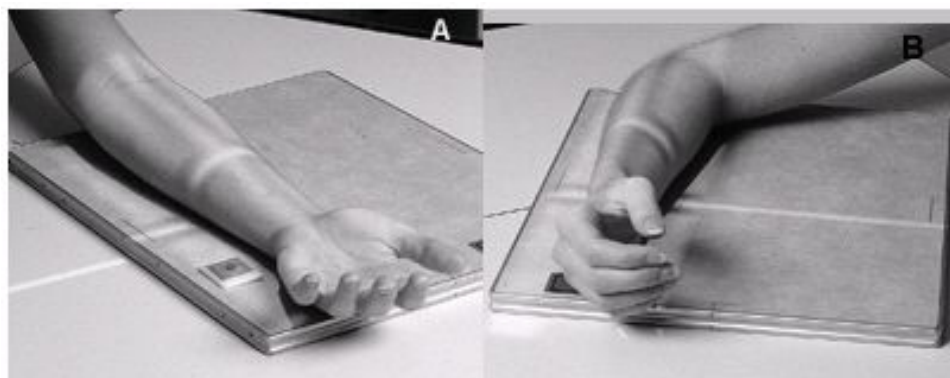


Continued

Evaluation criteria

- The entire radius and ulna should be visible, with pertinent soft tissues, such as fat pads and stripes of the wrist and elbow joints.
- The wrist (along with the proximal carpal row) and distal humerus should be clearly demonstrated.
- No rotation as evidenced by humeral epicondyles visualized in profile with slight superimposition of the radial head, neck, and tuberosity over the proximal ulna.
- No elongation or foreshortening of the humeral epicondyles.
- Partially open elbow joint if the shoulder was placed in the same plane as the forearm.
- Similar radiographic densities of the proximal and distal forearm.

(Fig. 1)



Frame A: AP forearm (including both joints)

Frame B: Lateral forearm (including both joints)

Image courtesy of Dr. Naveed Ahmad

Positioning for a lateral projection of the forearm

1. Seat the patient close to the radiographic table and low enough so that the humerus, shoulder joint, and elbow lie in the same plane.
2. Flex the elbow 90°, and center the forearm over the unmasked half of the cassette and parallel with the long axis of the forearm.
3. Make sure that the entire joint of interest is included.
4. Adjust the limb in a true lateral position; the thumb side of the hand must be up.
5. The CR is perpendicular to the midpoint of the forearm.

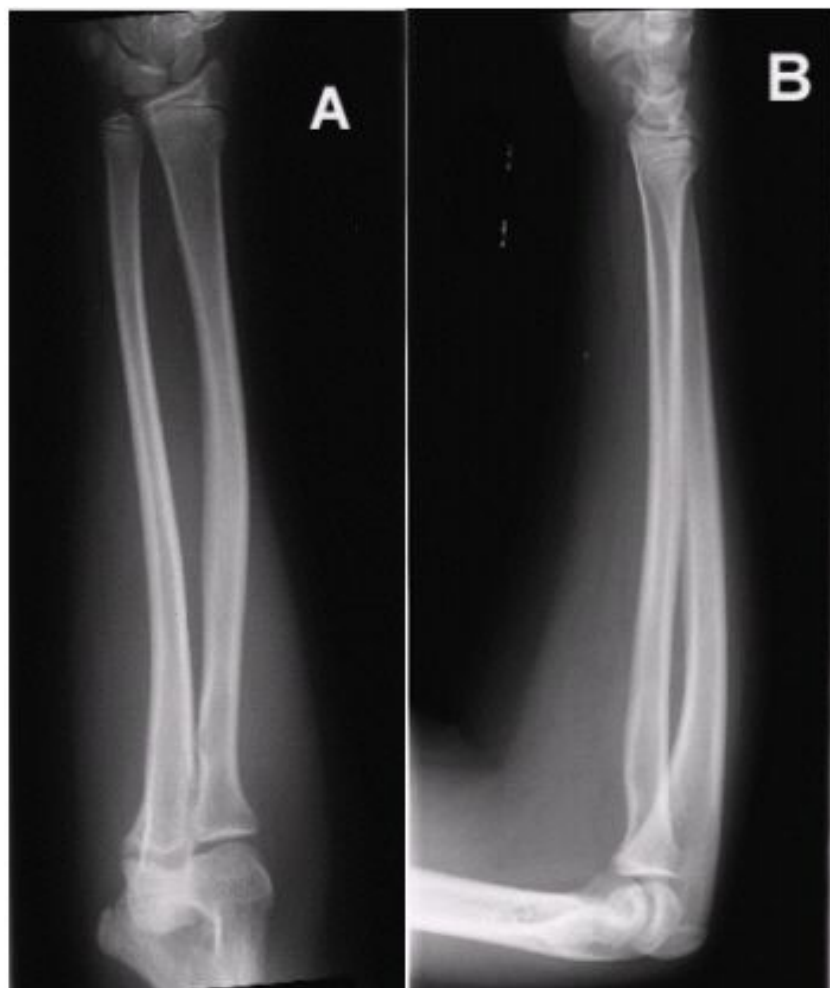

Continued

Evaluation criteria

1. Lateral projection of the entire radius and ulna along with wrist and distal humerus should be clearly demonstrated.
2. No rotation as evidenced by:
 - Superimposition of the radius and ulna at their distal end.
 - Superimposition by the radial head over the coronoid process.
 - Radial tuberosity facing anteriorly.
 - Superimposed humeral epicondyles.
1. Elbow should be flexed 90°.
2. Pertinent soft tissues, such as fat pads and stripes of the wrist and elbow joints, and bony trabeculations should be visible.

(Fig. 2)



Frame A: AP forearm

Frame B: Lateral forearm

Image courtesy of Dr. Naveed Ahmad



Continued

Radiographic positioning of the elbow

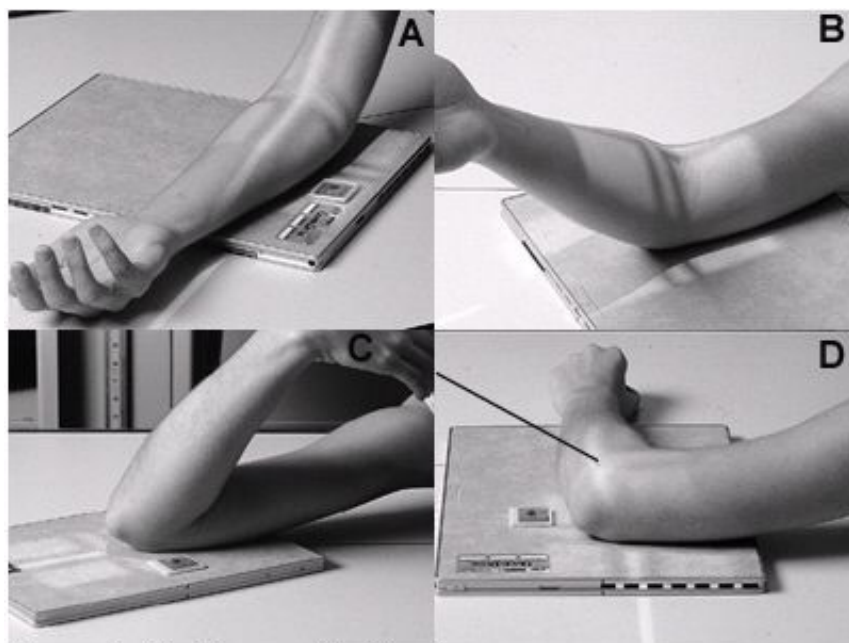
Routine radiographic examination of elbow is performed using the AP, AP oblique, and lateral projections. AP oblique projections include medial (internal) rotation and lateral (external) rotation views.

The lateral projection (lateromedial view) is obtained by flexing the elbow 90°. Diagnosis of certain important joint pathological processes (such as possible visualization of the posterior fat pad) depends on 90° flexion of the elbow joint. By doing this, the olecranon process can be seen in profile, and the elbow fat pads are the least compressed. Also, by allowing a partial or complete extension, the olecranon process elevates the posterior elbow fat pad and simulates joint pathology.

Technical factors

- IR: Lengthwise 11 x 14 inch (30 x 35 cm) divided; 7 x 17 inch (18 x 43 cm) single; 14 x 17 inch (35 x 43 cm) divided.
- Detail screen, tabletop.
- 60 to 65 kVp range, mAs 6.
- Minimum SID of 100 cm.

(Fig. 3)



Frame A: AP elbow partially flexed

Frame B: AP elbow partially flexed

Frame C: AP distal humerus: acute flexion of elbow for demonstrating olecranon process, CR perpendicular to humerus

Frame D: Lateral elbow for demonstrating radial head (with hand pronated), CR directed at a 45° angle toward shoulder, centered to radial head

Image courtesy of Dr. Naveed Ahmad



Continued

Positioning for an AP projection

1. Seat the patient near the radiographic table and low enough to place the shoulder joint, humerus, and elbow joint in the same plane.
2. Extend the elbow, supinate the hand.
3. When the elbow cannot be fully extended, obtain two AP projections -- one with forearm parallel to IR and one with humerus parallel to IR.
4. Center the cassette to the elbow joint.
5. Adjust the cassette to make it parallel with the long axis of the arm.
6. Ask the patient to lean laterally until the humeral epicondyles and anterior surface of the elbow are parallel with the plane of the cassette.
7. Supinate the hand to prevent rotation of the bones of the forearm.
8. The CR should be perpendicular to the elbow joint.

Evaluation criteria

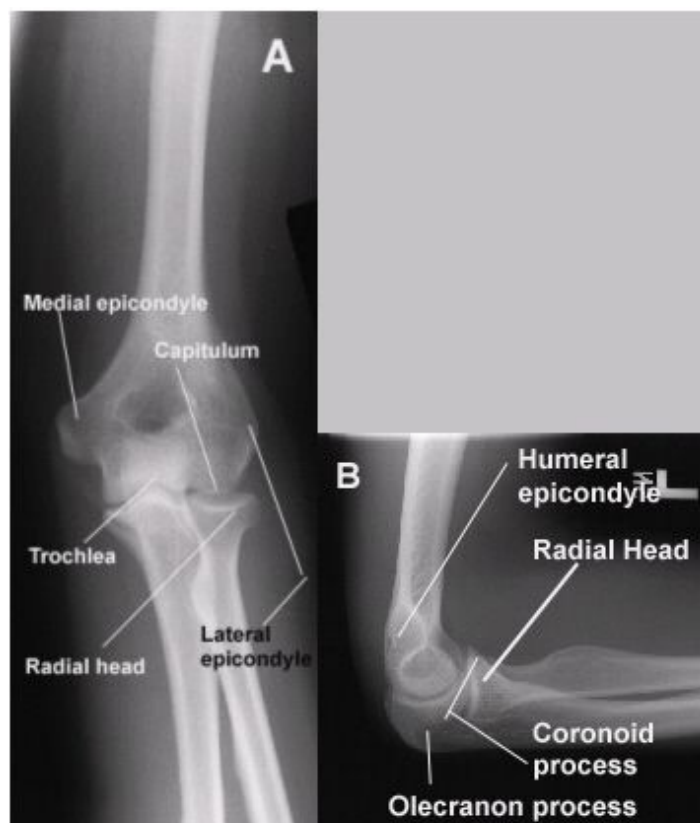- Distal humerus, elbow joint space, proximal radius, and ulna should be clearly demonstrated.
- No rotation is evidenced by appearance of bilateral epicondyles seen in profile; radial head, neck, and tuberosity slightly superimposed over the proximal ulna.
- Elbow joint appears open with fully extended arm.
- Soft tissue and bony trabeculation should be visible.

(see Fig. 4, next pg.)



Continued

(Fig. 4)



Frame A: AP elbow

Frame B: Lateral elbow

Image courtesy of Dr. Naveed Ahmad

Positioning for a lateral projection

1. Seat the patient at the end of the radiographic table low enough to place the humerus and elbow joint in the same plane with elbow flexed 90°.
2. Align long axis of the forearm to the long axis of the cassette.
3. Place the humerus and forearm in contact with the table.
4. Center the cassette to the elbow joint.
5. Adjust the cassette diagonally to include most of the arm and forearm.
6. Rotate the hand and wrist in to a true lateral position, thumb side up, and ensure that the humeral epicondyles are perpendicular to the plane of the cassette.
7. The CR should be perpendicular to the elbow joint, regardless of its location on the cassette.

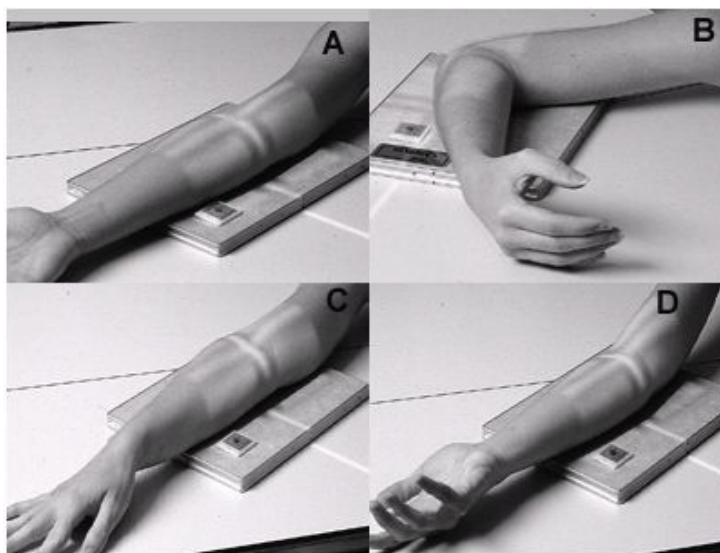


Continued

Evaluation criteria

- Distal humerus, proximal forearm should be clearly demonstrated.
- Open elbow joint centered to the central ray.
- Elbow flexed 90°.
- Superimposed humeral epicondyles.
- Radial tuberosity facing anteriorly.
- Radial head partially superimposing the coronoid process.
- Olecranon process seen in profile.
- A true lateral projection is indicated by three concentric arcs of the trochlear sulcus, double ridges of the capitulum and trochlea, and the trochlear notch of the ulna.
- Bony trabeculation and any elevated fat pads in the soft tissue at the anterior and posterior distal humerus and the anterior proximal forearm should be visible.

(Fig. 5)



Frame A: AP elbow

Frame B: Lateral elbow

Frame C: AP oblique elbow: medial (internal) rotation

Frame D: AP oblique elbow: lateral (external) rotation

Image courtesy of Dr. Naveed Ahmad



Continued

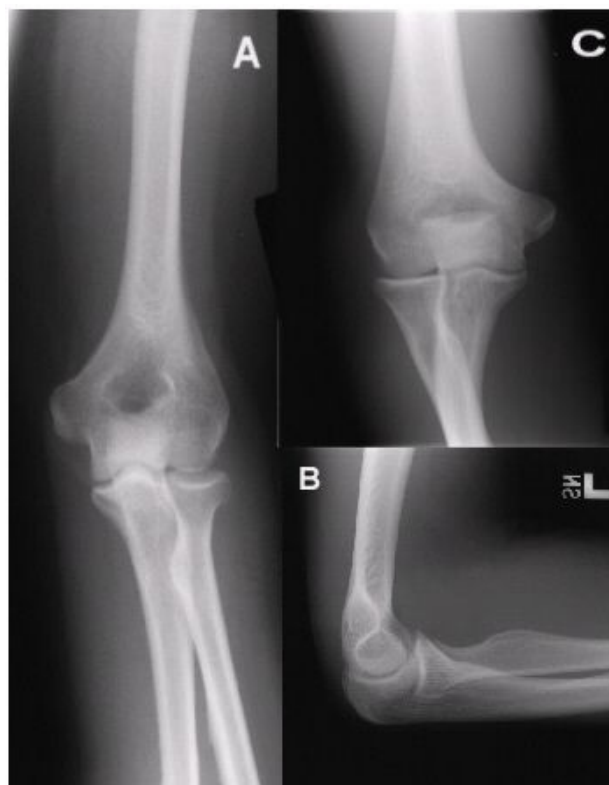Positioning for an AP oblique projection medial (internal) rotation

1. Seat the patient at the end of the radiographic table with the arm extended and in contact with the table.
2. Extend the limb in position for an AP projection, and center the midpoint of the cassette to the elbow joint.
3. Medially (internally) rotate or pronate (palm-down) the hand.
4. Adjust the elbow to place its anterior surface at an angle of 45° (palpating epicondyles to determine a 45° rotation). This degree of obliquity usually clears the coronoid process of the radial head.
5. The CR should be perpendicular to the elbow joint.

Evaluation criteria

- Coronoid process in profile should be clearly demonstrated.
- Elongated medial humeral epicondyle.
- Ulna superimposed by the radial head and neck.
- Olecranon process within the olecranon fossa.
- Soft tissue and bony trabeculation visible.

(Fig. 6)



Frame A: AP elbow

Frame B: Lateral elbow

Frame C: AP oblique view (medial rotation) - Image courtesy of Dr. Naveed Ahmad.



Continued

Positioning for an AP oblique projection lateral (external) rotation

1. After seating the patient at the end of table, extend the patient's arms into position for an AP projection.
2. Center the midpoint of the cassette to the elbow joint.
3. Rotate the hand laterally (externally) to place the posterior surface of the elbow at a 45° angle.
4. When proper lateral rotation is achieved, the patient's first and second digits should touch the table.
5. The CR should be perpendicular to the elbow joint.

Evaluation criteria

- An oblique view of the distal humerus and proximal radius and ulna should be demonstrated.
- Correct 45° lateral oblique should project the radial head, neck, and tuberosity, free of superimposition by ulna.
- Open elbow joint should be clearly demonstrated.
- Soft tissue and bony trabeculation should be visible.



The twists and turns of hand and wrist x-ray positioning

The twists and turns of hand and wrist x-ray positioning

By Dr. Naveed Ahmad

October 15, 2002

This is the tenth in our series of white papers on radiologic patient positioning techniques for x-ray examinations. If you'd like to comment on or contribute to this series, please e-mail editorial@auntminnie.com.

Radiographic positioning of the hand

Radiographic examination of the hand is performed using posteroanterior (PA), oblique, and lateral projections. The PA projection is the best conventional view for demonstrating malalignment, joint-space narrowing, and soft-tissue abnormalities in early rheumatoid arthritis, while the anteroposterior (AP) oblique projection ("ball-catcher" position) is commonly used to look for early evidence of rheumatoid arthritis at the second through fifth proximal phalanges and metatarsophalangeal (MP) joints. Both hands are generally exposed, with the contralateral image used for bony structure comparison.

Technical factors

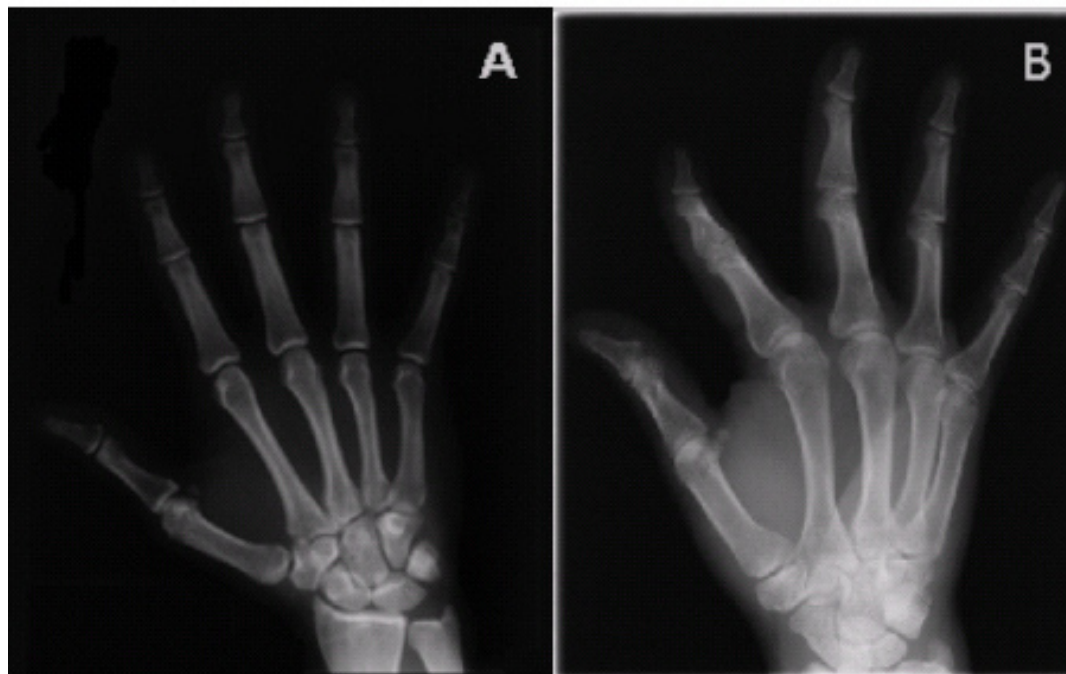
- Image receptor (IR), 10 x 12 inch (24 x 30 cm) crosswise for two or more images on one cassette.
- Digital screen, use lead masking.
- Detail screen, tabletop.
- 50-60 kVp range, mAs 3-4.
- Minimum SID of 100 cm.

(see Fig. 1, next pg.)



Continued

(Fig. 1)



*A) PA radiograph of hand (digits parallel).
B) Oblique hand (digits not parallel) joint spaces not open.
Images courtesy of Dr. Naveed Ahmad.*

Positioning for PA projection

1. Seat the patient at the end of the radiographic table and adjust the patient's height so that their forearm is resting on the table.
2. Rest the patient's forearm on the table and place the hand with the palmar surface down on the cassette.
3. Center the cassette to the metacarpophalangeal (MCP) joints, and adjust the long axis of the cassette parallel with the long axis of the hand and forearm.
4. Spread the fingers slightly.
5. Ask the patient to relax the hand to avoid motion. To prevent involuntary movement, use adhesive tape or positioning sponges. A sandbag may be placed over the distal forearm.
6. Central ray (CR): Perpendicular to the third MCP joint



Continued

Evaluation criteria

- The entire hand, wrist, and about 2.5 cm of the distal forearm should be visible.
- MCP and interphalangeal joints should appear open, indicating correct CR location and that hand was fully pronated. The long axis of the hand and wrist should be aligned to the long axis of the IR.
- No rotation of hand as evidenced by the following: the symmetric appearance of both sides or the concavities of the shafts of metacarpals and the phalanges of digits 2 through 5; and the amount of soft tissue on each side of phalanges 2 through 5 appears equal. The digits should be separated slightly with soft tissues and should not be overlapping.

Positioning for PA oblique projection

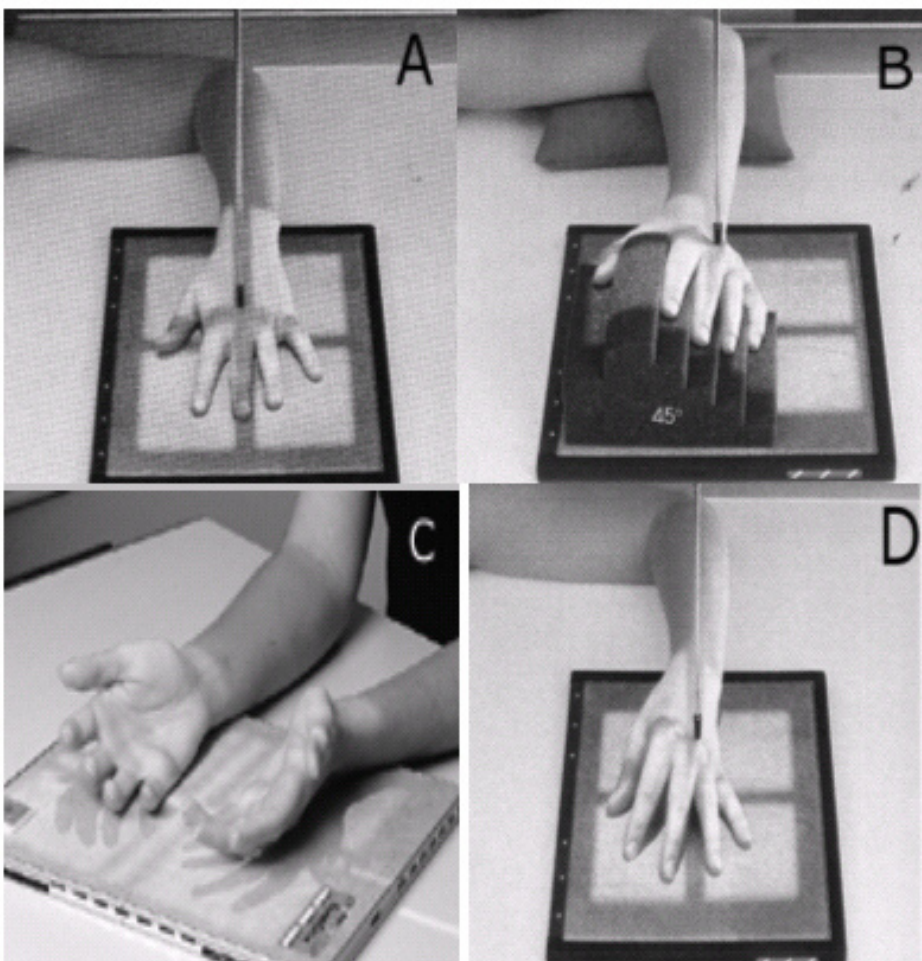
1. Rest the patient's forearm on the table with the hand pronated and the palm resting on the cassette.
2. Adjust the obliquity of the hand so that the MCP joints form an angle of approximately 45° with the cassette plane.
3. Use a 45° foam wedge to support the fingers in the extended position to demonstrate the interphalangeal joints.
4. When examining the metacarpals, obtain a PA oblique projection of the hand by rotating the patient's hand laterally (externally) from the pronated position until the fingertips touch the cassette.
5. Elevate the index finger and thumb on a suitable radiolucent material if it is not possible to obtain the correct position with all fingertips resting on the cassette. Elevation will open the joint spaces and reduce the degree of foreshortening of the phalanges.
6. Center the cassette to the MCP joints and adjust the midline to be parallel with the long axis of the hand and forearm.
7. CR: Perpendicular to the third MCP joint.

(see Fig. 2, next pg.)



Continued

(Fig. 2)



- A) PA hand.
 B) PA oblique hand for demonstration of joint spaces.
 C) AP oblique hand (ball-catcher's position).
 D) PA oblique hand for demonstration of metacarpals.
 Images courtesy of Dr. Naveed Ahmad.

Evaluation criteria

- Entire hand, wrist, and about 2.5 cm of the distal forearm should be visible in oblique view.
- MCP and interphalangeal joints should be open without foreshortening of midphalanges or distal phalanges, indicating fingers are parallel to IR.
- Long axis of hand and wrist should be aligned with IR.



Continued

- A 45° oblique is evidenced by the following: Midshafts of third, fourth, and fifth metacarpals should not overlap; some overlap of the distal heads of third, fourth, and fifth metacarpals but no overlap of distal second and third metacarpals should occur; excessive overlap of metacarpals indicates overrotation, and too much separation indicates underrotation.

Positioning for lateral projection

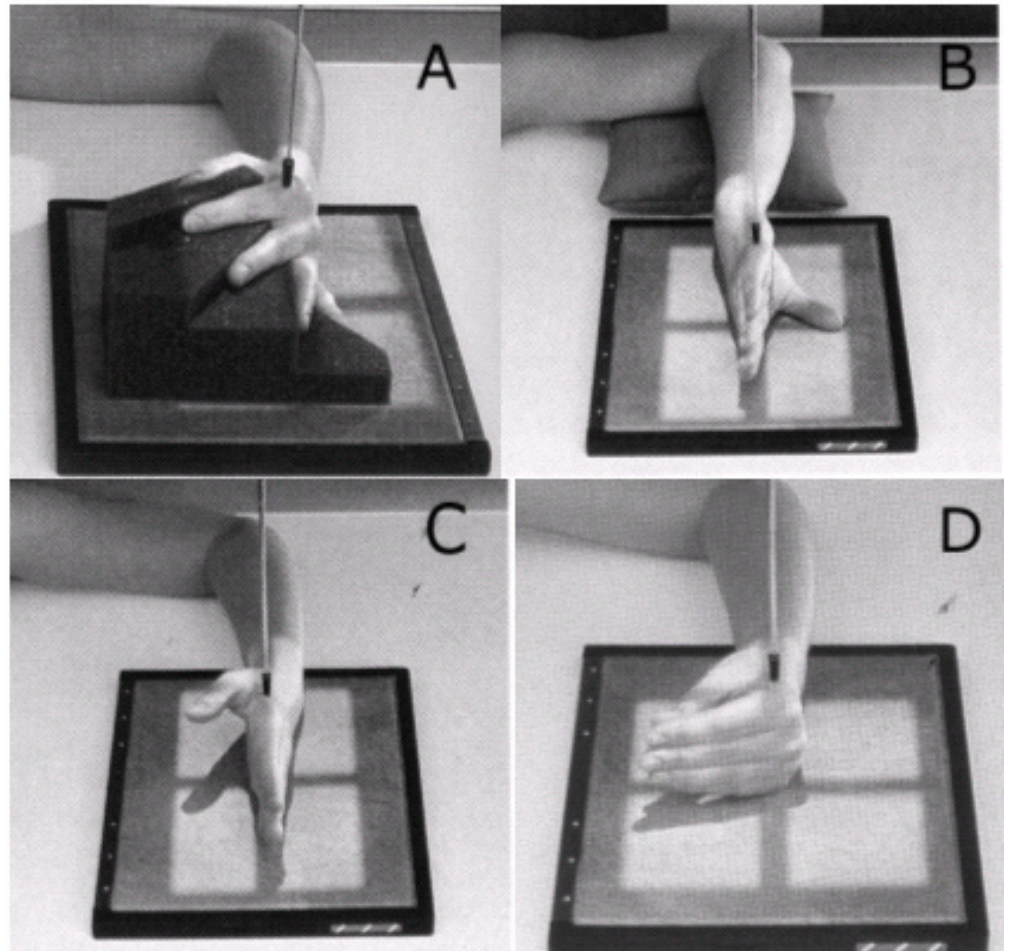
1. Seat the patient at the end of the radiographic table with the forearm in contact with the table and the hand in the lateral position with the ulnar aspect down.
2. Alternatively, place the radial side of the wrist against the cassette. However, this position is more difficult for the patient to assume.
3. If the elbow is elevated, support it with sandbags.
4. Extend the patient's digits and adjust the first digit at a right angle to the palm.
5. Place the palmar surface perpendicular to the cassette.
6. Center the cassette to the MCP joints, and adjust the midline to be parallel with the long axis of the hand and forearm. If the hand is resting on the ulnar surface, immobilization of the thumb may be necessary.
7. The two extended-digit positions result in superimposition of the phalanges. A modification of the lateral hand is the fan-lateral position, which eliminates superimposition of all but the proximal phalanges. For the fan-lateral position, place the digits on a sponge wedge. Abduct the thumb and place it on a radiolucent sponge for support.
8. CR: Perpendicular to the second-digit MCP joint.

(see Fig. 3, next pg.)



Continued

(Fig. 3)



A) Fan lateral hand.

B) Lateral hand with radial surface to cassette -- mediolateral.

C) Lateral hand with ulnar surface to cassette -- lateromedial.

D) Lateral hand in flexion.

Images courtesy of Dr. Naveed Ahmad.



Continued

Evaluation criteria

- Entire hand, wrist, and about 2.5 cm of the distal forearm should be visible.
- Fingers should appear equally separated, with phalanges in the lateral position and joint spaces open, indicating fingers were parallel to IR.
- Thumb should appear in a slightly oblique position completely free of superimposition, with joint spaces open.
- Long axis of hand and wrist should be aligned to the long axis of the IR.
- Hand and wrist should be in a true-lateral position evidenced by the following: Distal radius and ulna superimposed; metacarpals are superimposed.

Positioning for AP oblique projection (ball-catcher position)

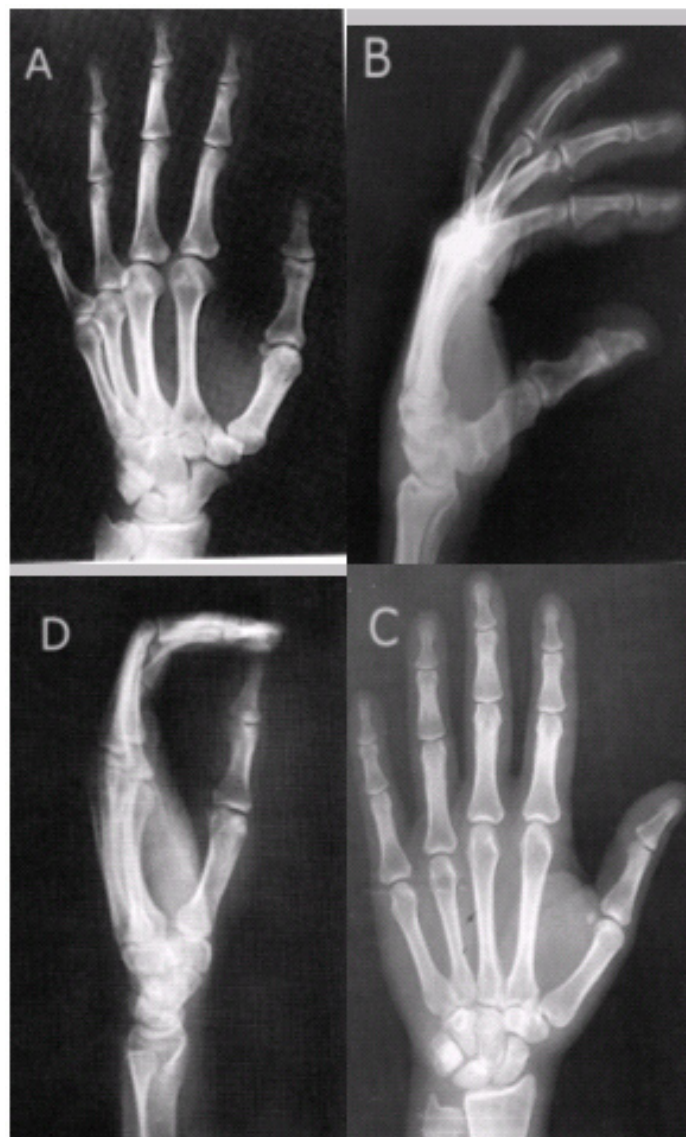1. Seat the patient at the end of the radiographic table. Have the patient place the palms of both hands together.
2. Center the MCP joints on the medial aspect of both hands to the cassette. Both hands should be in the lateral position.
3. Place two 45° radiolucent sponges against the posterior aspect of each of the patient's hands to a half-supinate position until the dorsal surface of each hand rests against each 45° sponge support.
4. Extend the patient's fingers, and abduct the thumbs slightly to avoid superimposition over the fingers.
5. CR: Perpendicular to the point midway between both hands at the level of the MCP joints for either of the two patient positions.

(see Fig. 4, next pg.)



Continued

(Fig. 4)



A) PA oblique hand with digits on sponge to demonstrate open joints.

B) Fan lateral hand.

Evaluation criteria

- Entire hand, wrist, and about 2.5 cm of the distal forearm should be visible.
- Fingers should appear equally separated, with phalanges in the lateral position and joint spaces open, indicating fingers were parallel to the IR.
- Thumb should appear in a slightly oblique position completely free of superimposition, with joint spaces open.
- Long axis of hand and wrist should be aligned to the long axis of the IR.



Continued

- Hand and wrist should be in a true-lateral position, evidenced by the following: Distal radius and ulna superimposed; metacarpals should be superimposed.

Radiographic positioning of the wrist

The routine radiographic examination of the wrist uses the frontal and lateral projections. The PA radiograph is best obtained with the arm abducted 90° from the trunk and the forearm flexed at 90° to the arm. For the evaluation of arthritis, oblique projections also are necessary. These latter projections should include radiographs exposed with the wrist in both a semipronated oblique and a semisupinated oblique position.

Technical factors

- IR: 10 x 12 inch (24 x 30 cm) crosswise for two or more images on one cassette.
- Digital screen, use lead masking.
- Detail screen, tabletop.
- 50-60 kVp range, mAs 4-5.
- Minimum SID of 100 cm.

Positioning for PA wrist projection

1. Have the patient rest their forearm on the table, and center the wrist to the cassette area.
2. Seat the patient low enough to place the axilla in contact with the table, or elevate the limb to shoulder level on a suitable support.
3. Adjust the hand and forearm to lie parallel with the long axis of the cassette.
4. Slightly arch the hand at the MCP joints by flexing the digits to place the wrist in close contact with the cassette.
5. CR: Perpendicular to the midcarpal area

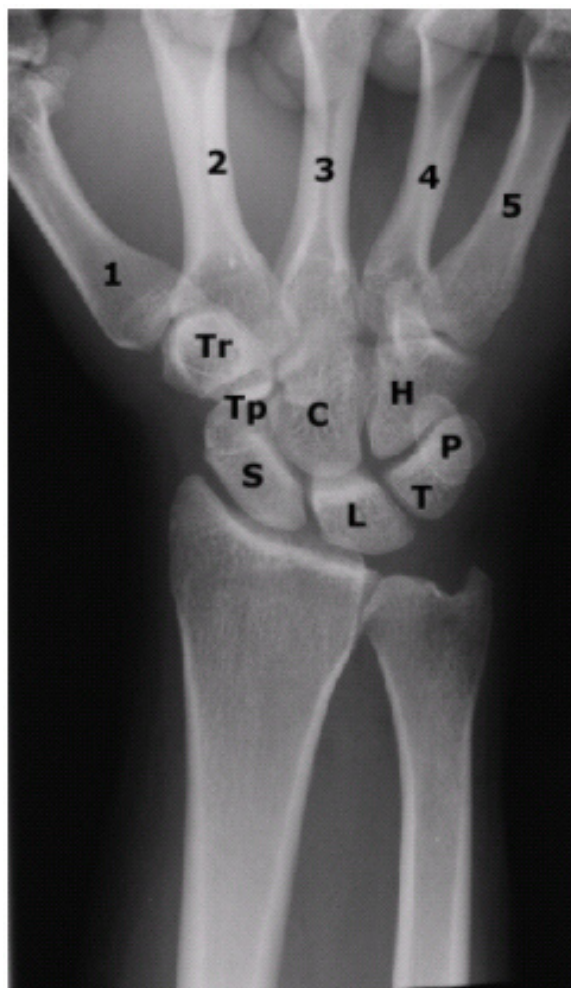Positioning for AP wrist projection

1. Seat the patient at the end of the radiographic table.
2. Have the patient rest the forearm on the table, with the arm and hand supinated.
3. Place the cassette under the wrist, and center it to the carpals.
4. Elevate the digits on a suitable support to place the wrist in close contact with the cassette.
5. Have the patient lean laterally to prevent rotation of the wrist.
6. CR: Perpendicular to the midcarpal area.



Continued

(Fig. 5)



*PA wrist (S, Scaphoid; L, Lunate;
T, Triquetrum; P, Pisiform; H, Hamate;
Tr, Trapezium; Tp, Trapezoid).
Image courtesy of Dr. Naveed Ahmad.*

Evaluation criteria for AP and PA wrist

- The carpal interspaces are better demonstrated in the AP image than the PA interspaces; they are more closely parallel with the divergence of the x-ray beam.
- Long axis of the hand, wrist, and forearm is aligned with IR.
- True PA is evidenced by the following: Equal concavity shapes are on each side of the shafts of the proximal metacarpals; near equal distances exist among the proximal metacarpals; separation of the distal radius and ulna is present, except for possible minimal superimposition at the distal radioulnar joint.
- Soft tissue and bony trabeculation should be visible.

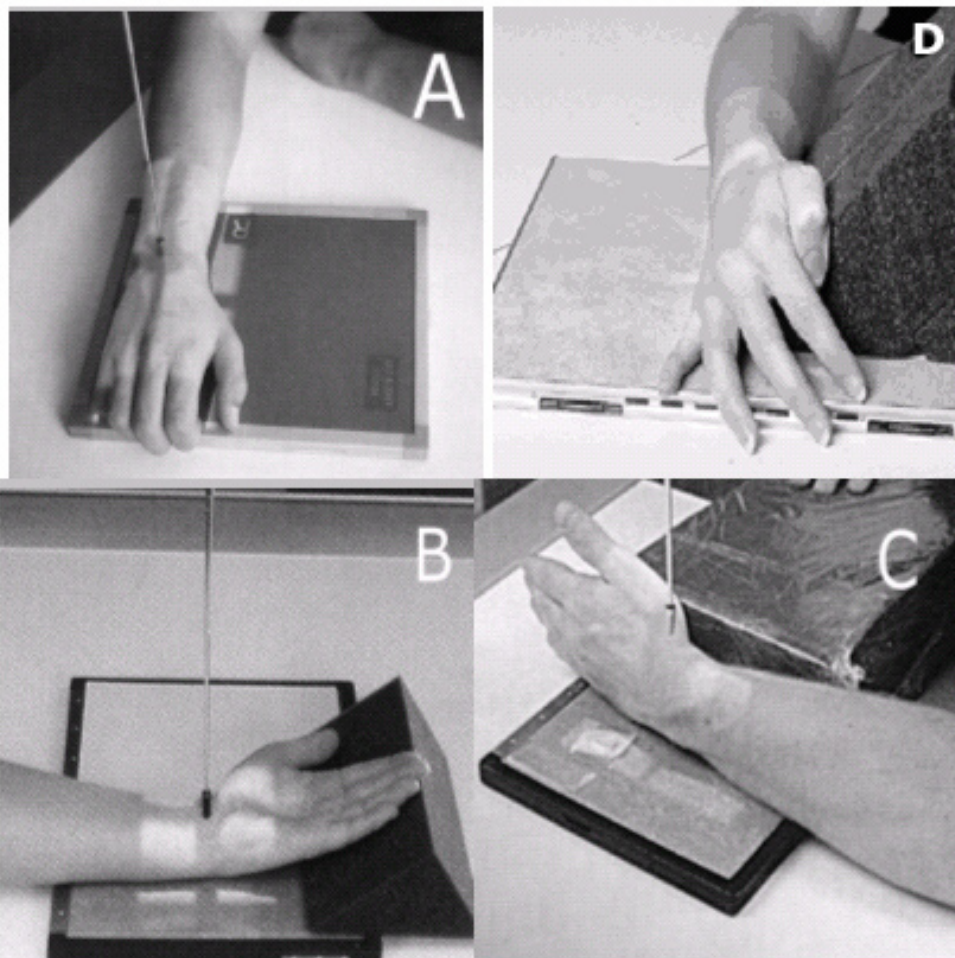


Continued

Positioning for PA oblique projection of wrist

1. Seat the patient at the end of the radiographic table, placing the axilla in contact with the table.
2. Rest the palmar surface of the wrist on the cassette.
3. Adjust the cassette so that its center point is under the scaphoid when the wrist is rotated from the pronated position.
4. From the pronated position, rotate the wrist laterally (externally) until it forms an angle of approximately 45° with the plane of the cassette.
5. To ensure duplication in follow-up examinations, place a 45° foam wedge under the elevated side of the wrist.
6. Extend the wrist slightly, and if the digits do not touch the table, support them in place.
7. When the scaphoid is under examination, adjust the wrist in ulnar deviation. Place a sandbag across the forearm.
8. CR: Perpendicular to the midcarpal area, it enters just distal to the radius.

(Fig. 6)



- A) PA wrist
 B) AP wrist
 C) PA oblique wrist (lateral rotation)
 D) Lateral wrist
 Image courtesy of Dr. Naveed Ahmad

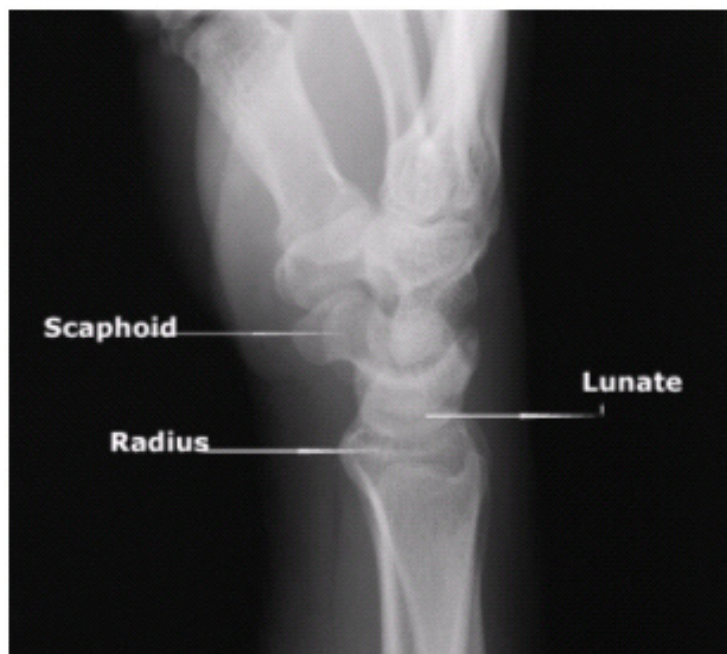

Continued

Evaluation criteria

- Distal radius, ulna, carpals, and at least the midmetacarpal area should be visible.
- The trapezium and scaphoid should be well visualized, with only slight superimposition of other carpals on their medial aspects.
- Long axis of the hand, wrist, and forearm should be aligned with the IR.
- 45° oblique of the wrist should be evident by ulnar head being partially superimposed by distal radius.
- The proximal third, fourth, and fifth metacarpals should appear mostly superimposed.
- Soft tissue and bony trabeculation should be visible.

(Fig. 7)

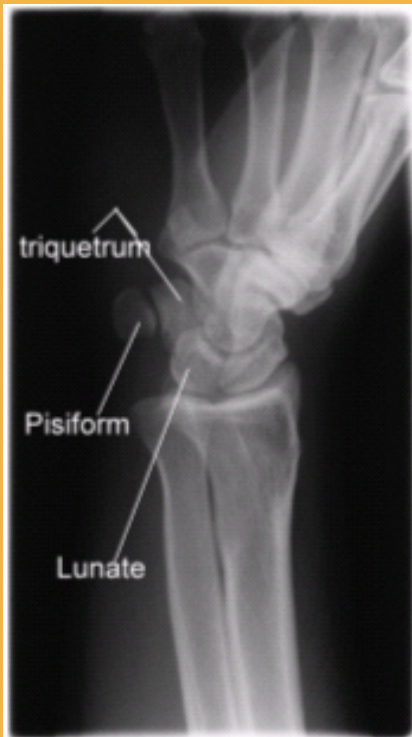

*Lateral wrist with ulnar surface to cassette.
Image courtesy of Dr. Naveed Ahmad.*



Continued

(Fig. 8)



The AP oblique wrist position separates the pisiform from the adjacent carpal bones. It also provides a more-distinct radiograph of the triquetrum and hamate.

Image courtesy of Dr. Naveed Ahmad.

Positioning for lateral projection

1. Seat the patient at the end of the radiographic table.
2. Have the patient rest the arm and forearm on the table to ensure that the wrist is in a lateral position.
3. Have the patient flex the elbow 90° to rotate the ulna to the lateral position.
4. Center the cassette to the carpals, and adjust the forearm and hand so that the wrist is in a true-lateral position.
5. CR: Perpendicular to the wrist joint.

Evaluation criteria

- Distal radius and ulna, carpals, and at least the midmetacarpal area should be visible.
- Long axis of the hand, wrist, and forearm should be aligned with long axis of IR.
- True-lateral position is evidenced by the following: Ulnar head should be superimposed over distal radius; proximal second through fifth metacarpals all should appear aligned and superimposed.
- Soft tissue and bony trabeculation should be visible.

(see Fig. 8)

Positioning for AP oblique wrist projection (medial rotation).

1. Place the cassette under the wrist and center it at the dorsal surface of the wrist.
2. Rotate the wrist medially (intimally) until it forms a semisupinated position of approximately 45° to the cassette.
3. CR: Perpendicular to the midcarpal area, it enters the anterior surface of the wrist midway between its medial and lateral borders.

Evaluation criteria

- Carpals on medial side of wrist.
- Triquetrum, hamate, and pisiform free of superimposition and in profile.
- Distal radius and ulna, carpals, and proximal half of metacarpals.
- Soft tissue and bony trabeculation should be visible.



Continued

Positioning for PA projection wrist with ulnar deviation (flexion)

1. Position the wrist on the cassette for a PA projection.
2. With one hand cupped over the joint to hold it in position, move the elbow away from the patient's body and then turn the hand outward until the wrist is in extreme ulnar deviation.

Positioning for PA projection wrist with radial deviation (flexion)

1. Position the wrist on the cassette for a PA projection.
2. Cup one hand over the wrist joint to hold it in position. Then move the hand medially until the wrist is in extreme radial deviation.
3. CR: Perpendicular to the midcarpal area.
4. Radial deviation opens the interspaces between the carpals on the medial side of the wrist.

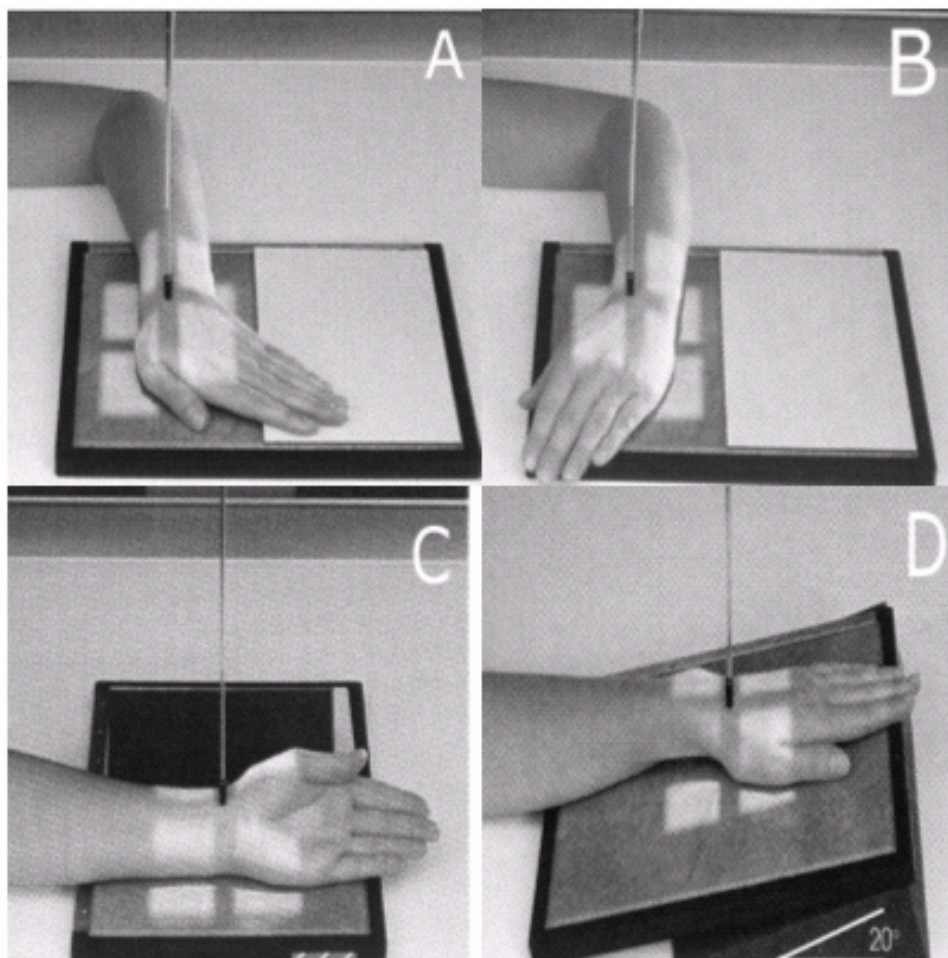
Evaluation criteria

- Carpals and their articulations should be on the medial side of the wrist.
- No rotation of wrist is evidenced by appearance of the distal radius and ulna.
- Extreme radial deviation should be clearly demonstrated, as revealed by the angle formed between longitudinal axes of forearm compared to the longitudinal axes of the metacarpals.
- Soft tissue and bony trabeculation should be visible.



Continued

(Fig. 8)



- A) PA wrist in ulnar deviation.
 B) PA wrist in radial deviation.
 C) PA oblique wrist (medial rotation).
 D) PA axial wrist for scaphoid (Stecher method)

Image courtesy of Dr. Naveed Ahmad.

Positioning for scaphoid carpal bone (PA wrist axial projection)

1. Place one end of the cassette on a support and adjust it so that the finger end is elevated 20° (this angulation of the wrist places the scaphoid at right angles to the CR so that it is projected without self-superimposition).
2. Adjust the wrist on the cassette for a PA projection, and center the wrist to the cassette.
3. CR: Perpendicular to the table and directed to enter the scaphoid.

Evaluation criteria

- Scaphoid should be clearly visible.
- No rotation of carpals, metacarpals, radius, or ulna.
- Distal radius and ulna, carpals, and proximal half of the metacarpals should be demonstrated.
- Soft tissue and bony trabeculation should be visible.



Digit imaging requires diligent positioning

Digit imaging requires diligent positioning

By Dr. Naveed Ahmad

September 17, 2002

This article is the ninth in our series of white papers on radiologic patient positioning techniques for x-ray examinations. If you'd like to comment on or contribute to this series, please e-mail editorial@auntminnie.com.

One of the earliest x-ray images ever produced by Wilhelm Conrad Roentgen was of his wife Bertha's hand. Since that November day in 1895, the technological options for hand imaging have evolved to include most of the major radiographic modalities.

However, the x-ray of the hand is still the frontline tool used for diagnostic purposes. Obtaining a quality radiographic image requires a combination of proper technique and attention to patient positioning.

General procedures for upper-limb positioning

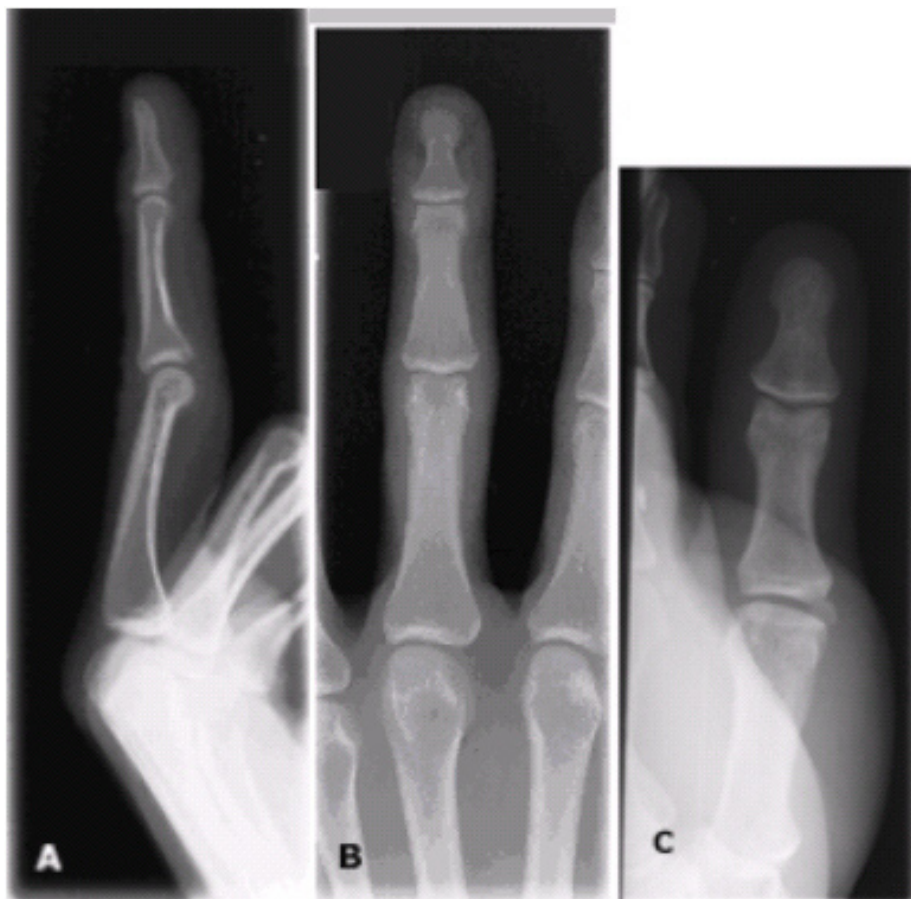- Remove rings, watches, and other radiopaque objects.
- Seat the patient at the side or end of the table and place the cassette at a location and angle that allows the patient to be in the most comfortable position.
- Direct the central ray (CR) at a right angle to the midpoint of the cassette.
- When performing a bilateral examination of hands or wrists, separately radiograph each side.
- Shield the patient's gonads from scattered radiation.
- Use close collimation. This technique is recommended for all upper-limb radiographs.
- When placing multiple exposures on one cassette, the side of the unexposed cassette should always be covered with lead.
- Use right or left markers and any other vital identification markers when appropriate.

(see Fig. 1, next pg.)



Continued

(Fig. 1)



Common views for hand x-rays: A -- lateral third digit; B -- PA third digit; C -- AP first digit. Images courtesy of Dr. Naveed Ahmad.

First digit (thumb)

Positioning of the thumb is unique because its axis differs from that of the other digits. Basic views of the thumb include anteroposterior (AP), posteroanterior (PA), oblique, and lateral. Stress views of the first metacarpophalangeal (MCP) articulation may be required for evaluation of injuries of the ligaments of this joint.

Technical factors

1. Image receptor (IR): 8 x 10 inch (18 x 24 cm) crosswise for two or more images on one cassette.
2. Digital IR (use lead masking).
3. Detail screen, table top.
4. 50-60 kVp range, cm 3, mAs 3, Sk 10, ML 10.
5. Position: Seat the patient at the end of the radiographic table with their arm internally rotated.



Continued

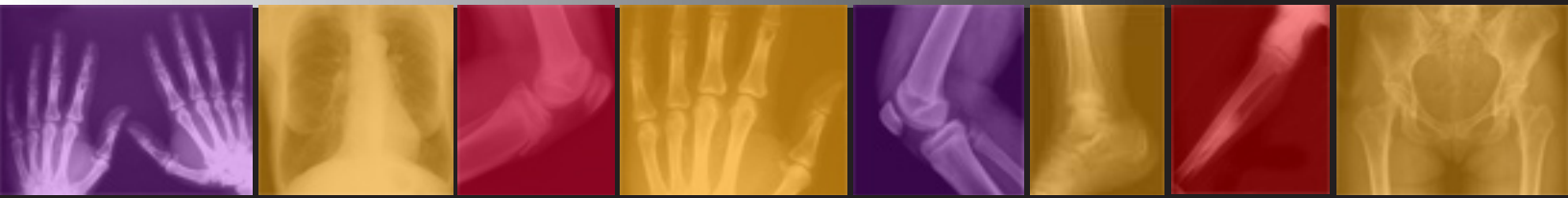
Positioning technique for an AP projection

- Put the patient's hand in a position of extreme internal rotation with the least amount of strain on the arm.
- Have the patient hold the extended digits back with tape or the opposite hand. Rest the thumb on the cassette. If the elbow is elevated, place a support under it and have the patient rest their opposite forearm against the table for support.
- Center the long axis of the thumb parallel with the long axis of the cassette. Adjust the position of the hand to ensure a true AP projection of the thumb.
- Place the fifth metacarpal back far enough to avoid superimposition.

Positioning technique for a lateral projection

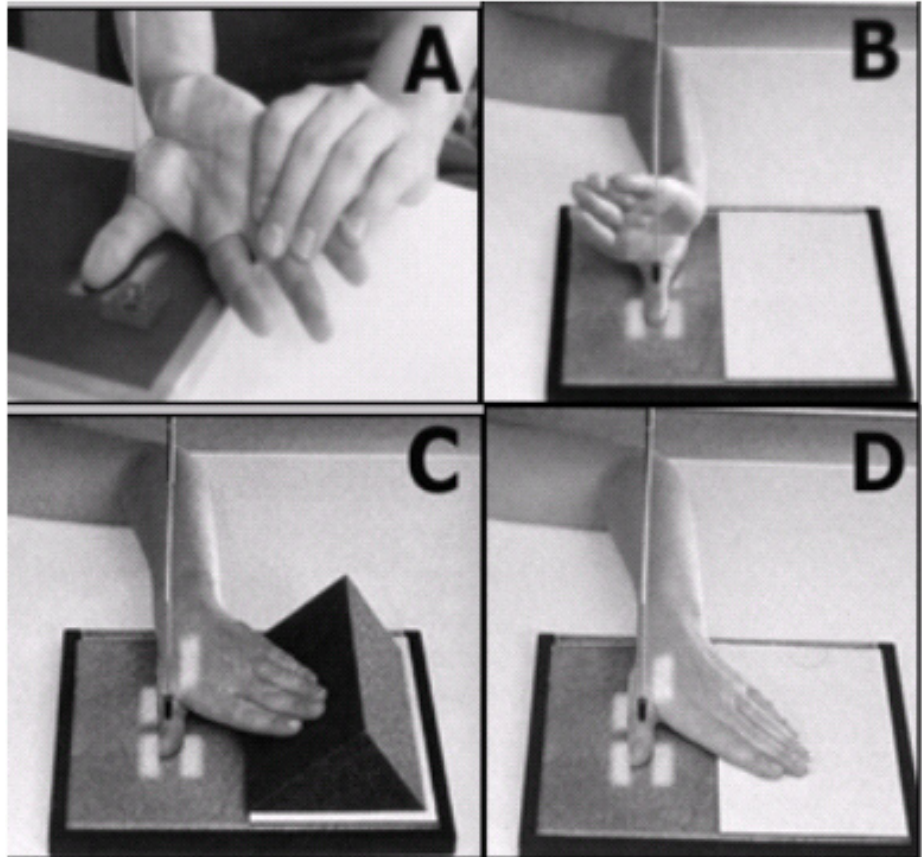
- Place the hand in its natural arched position with the palmar surface down and fingers flexed or resting on a sponge.
- Place the midline of the cassette parallel with the long axis of the digit. Center the cassette to the MCP joint.
- Adjust the arching of the hand until a true lateral position of the thumb is obtained.

(see Fig. 2, next pg.)



Continued

(Fig. 2)



Routine positioning for first digit: A -- first carpometacarpal (CMC) joint AP projection; B -- AP projection thumb; C -- lateral projection thumb; D -- lateral oblique projection thumb. Image courtesy of Dr. Naveed Ahmad.



Continued

Positioning technique for a PA oblique projection

- With the thumb abducted, place the palmar surface of the hand in contact with the cassette. Ulnar deviate the hand slightly. This relatively normal placement positions the thumb in the oblique position.
- Align the longitudinal axis of the thumb with the long axis of the cassette. Center the cassette to the MCP joint.

Positioning technique for the first MCP joint

- Extend the limb straight out on the radiographic table and rotate the arm internally; this places the posterior aspect of the thumb on the cassette with the thumbnail down.
- Place the thumb in the center of the cassette.
- Hyperextend the hand so that the soft tissue over the ulnar aspect does not obscure the first CMC joint. This ensures that the thumb is not oblique.

Central ray

- The CR should be perpendicular to the MCP joint for the AP, lateral, and oblique projections. Collimate to include entire first digit.
- For the first carpometacarpal (CMC) joint AP projection, the CR should be perpendicular, entering at the first CMC joint. However, CR angulation of 10° -15° proximally along the long axis of the thumb and entering the first CMC or MCP joint helps to project the soft tissue of the hand away from the first CMC joint, and open the joint space.

Evaluation criteria

1. The area from the distal tip of the thumb to the trapezium should be clearly demonstrated.
2. There should be no rotation, and concavity of the phalangeal and metacarpal shafts should be demonstrated with equal amounts of soft tissue on both sides of the phalanges.
3. In the first CMC joint radiograph:
4. The first CMC joint should be free of superimposition of the hand or other bony elements.
5. The first metacarpal and trapezium should be clearly demonstrated.
6. There should be open interphalangeal and MCP joint spaces.
7. The soft tissue and bony trabeculation should be clearly present.



Continued

Digits (second through fifth)

Adequate radiographic evaluation of the fingers requires PA and lateral projections. The particular position employed for obtaining a lateral radiograph of one of the four ulnar (medial) digits will depend on the specific digit being examined. Placing the hand on a step wedge permits separation of individual fingers in the lateral projection, allowing all digits to be examined on a single radiograph.

PA projection -- technical factors

1. IR: 8 x 10 inch (18 x 24 cm) crosswise for two or more projections on one cassette.
2. Digital screen, use lead masking.
3. Detail screen, table top.
4. 50- 60 kVp range, mAs 2, cm 2, Sk 6, ML 6.

Patient position

Seat the patient at the end of the radiographic table.

Positioning technique

When imaging individual digits (except the first), take the following steps:

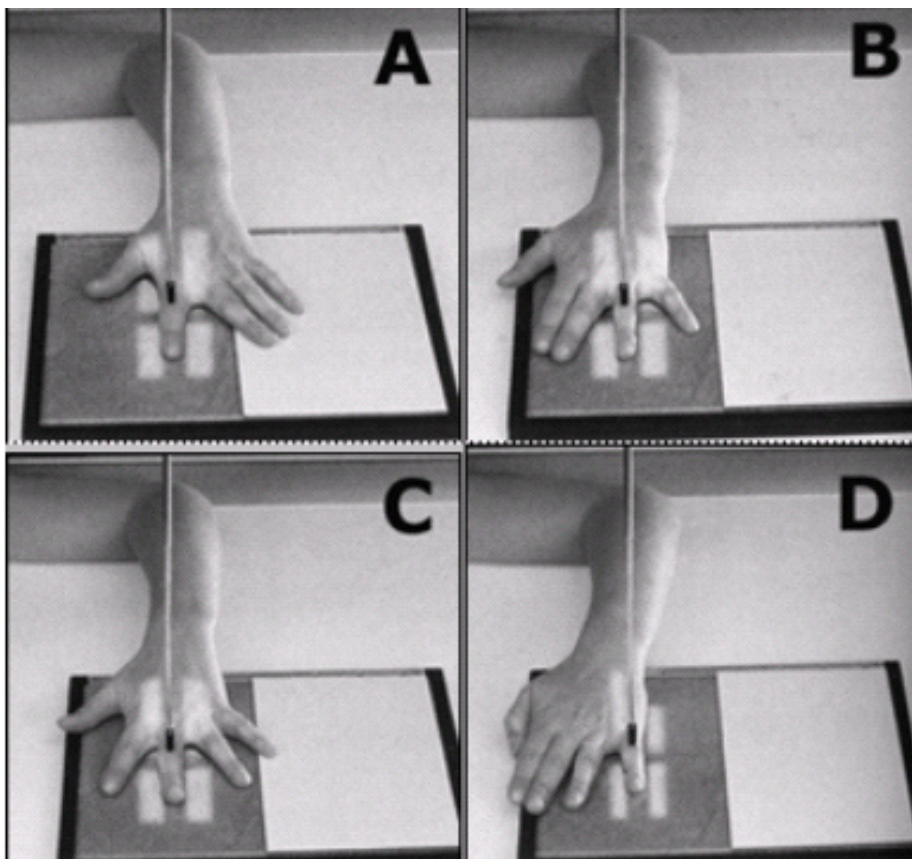
- Place the extended digit with the palmar surface down on the unmasked portion of the cassette.
- Separate the digits slightly, and center the digit under examination to the midline portion of the cassette. Center the proximal interphalangeal (PIP) joint to the cassette.
- For computed radiography the digit must be placed in the central area of the cassette for all finger projections.

(see Fig. 3, next pg.)



Continued

(Fig. 3)



PA positioning for second through fifth digits: A -- second digit; B -- third digit; C -- fourth digit; D -- fifth digit. Image courtesy of Dr. Naveed Ahmad.



Continued

Central ray

The CR should be perpendicular to the PIP joint of the affected digit. Collimate to the digit under examination.

Evaluation criteria

1. To ensure no rotation of the digit concavity of the phalangeal shafts, an equal amount of soft tissue on both sides of the phalanges should be clearly demonstrated.
2. The entire digit, from fingertip to distal portion of the adjoining metacarpal, should be clearly demonstrated.
3. There should be no soft-tissue overlap from adjacent digits.
4. The interphalangeal and MCP joint should be open without overlap of bones.

Lateral projection -- technical factors

1. IR: 8 x 10 inch (18 x 24 cm) crosswise for two or more images on one cassette.
2. Digital screen, use lead masking.
3. Detail screen, table top.
4. 50-60 kVp range, mAs 2, cm 2, Sk 6, ML 6.

Patient positioning

Seat the patient at the end of the radiographic table

Positioning technique

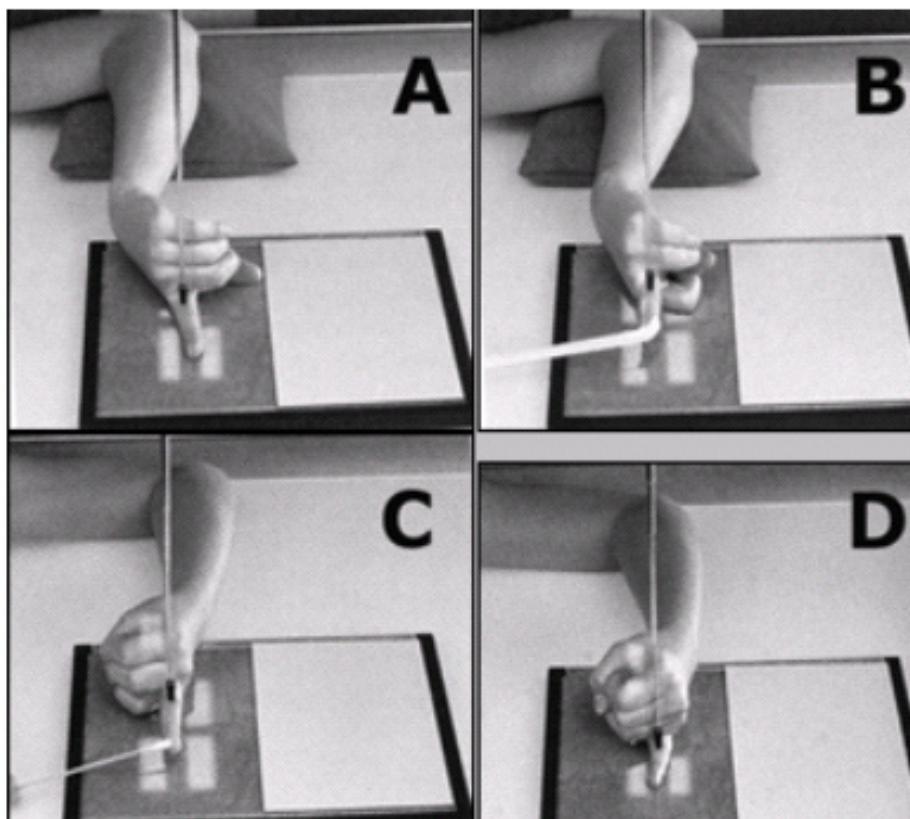
- Because lateral digit positions are difficult to hold, demonstrate the position with your own finger to the patient.
- Ask the patient to extend the digit to be examined. Close the rest of the digits into a fist, and hold them in complete flexion with the thumb.
- Have the patient's hand rest on the radial surface, for the second or third digits, or on the ulnar surface for the fourth and fifth digits.
- If the elbow is elevated, place a support under it and have the patient rest their opposite forearm against the table for support.
- Place the cassette so that the midline of its unmasked portion is parallel with the long axis of the digit. Center the cassette to the PIP joint.
- When imaging the second and fifth digits, rest them directly on the cassette. Use a radiolucent sponge if needed to support the digits.



Continued

- When imaging the third and fourth digits, elevate them and place their long axes parallel with the plane of the cassette. Use a radiolucent sponge if needed to support the digits.
- Place a strip of adhesive tape, as needed, to immobilize the extended digit against the palmar surface.
- Obtain a true lateral position of the digit by adjusting the anterior or posterior rotation of the hand.

(Fig. 4)



Lateral positioning for second through fifth digits: A -- second digit; B -- third digit; C -- fourth digit; D -- fifth digit. Image courtesy of D Naveed Ahmad.



Continued

Central ray

The central ray should be perpendicular to the PIP joint of the affected digit. Collimate to the digit being examined.

Evaluation criteria

1. The entire digit should be clearly demonstrated in a true lateral position with no rotation.
2. The fingernail should be in profile and the anterior surfaces of the phalanges should be concave.
3. There should be no obstruction of the proximal phalanx or MCP joint by adjacent digits.
4. The interphalangeal and MCP joint should be open.



Patient positioning techniques for a lower gastrointestinal series

Patient positioning techniques for a lower gastrointestinal series

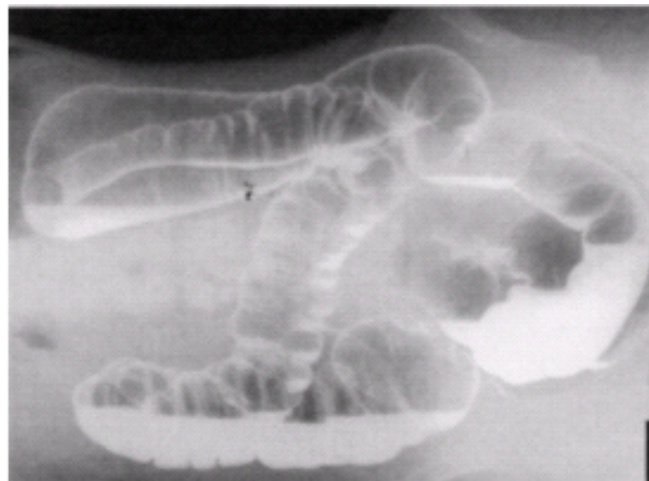
By Dr. Naveed Ahmad

June 27, 2002

With this article we continue our series of white papers on radiologic patient positioning techniques for x-ray examinations. The monthly series explores each of the major modalities. If you'd like to comment on an article or contribute an installment, please e-mail editorial@auntminnie.com.

The contrast study of the large bowel, also called the lower gastrointestinal (LGI) series, is commonly performed using a barium enema. It is a valuable diagnostic tool that helps detect abnormalities in the large intestine. The barium enema, along with colonoscopy, remains standard in the diagnosis of colon cancer, ulcerative colitis, and other inflammatory diseases of the colon. There are two basic radiological methods of examining the large intestine by means of contrast enemas: a single-contrast method and a double-contrast method.

(Fig. 1)



Double-contrast AP large intestine, right lateral decubitus position. Image courtesy of Dr. Naveed Ahmad.

Barium sulfate is the most common type of contrast media used for a barium enema. It is important to choose a barium suspension of appropriate density and viscosity for barium enema. If the viscosity of the barium suspension is too high, the examination will be prolonged, the filling of cecum and right colon will be difficult, and the drainage of barium will be inadequate. A standard mixture used for single-contrast barium enemas ranges between 15%-25% weight-to-volume (500 cc of barium sulfate is mixed into 1,500 cc tepid water to produce a 12%-20% solution).

A double-contrast barium enema uses a thicker barium with a weight-to-volume (w/v) concentration between 75%-95% or higher. Some patients require glucagon during the



Continued

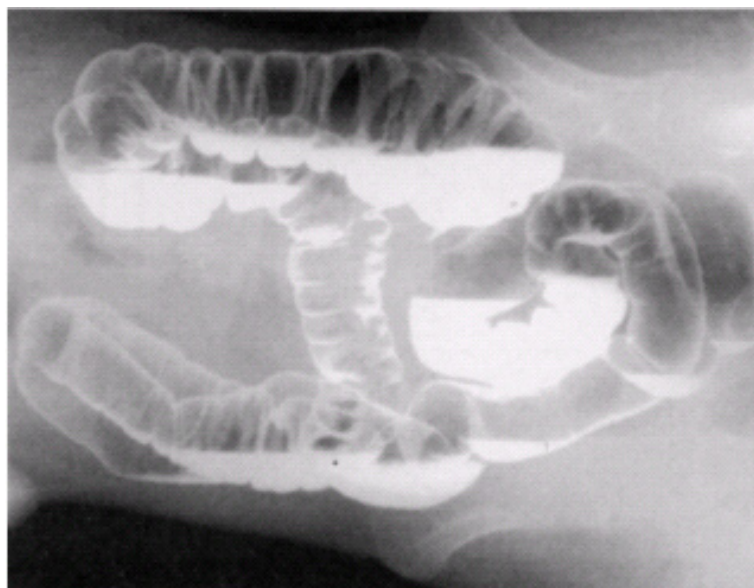
examination. Glucagon is a hypotonic drug used to achieve relaxation of colon. Colonic relaxation diminishes patient discomfort, accelerates the examination, and decreases incontinence.

Choice of contrast medium and indications for examination

The choice between the single- and double-contrast barium enema is the prerogative of the radiologist, and is an educated decision based on the condition of the individual patient and the clinical problem to be solved.

The single-contrast barium enema is preferable for the very young, the very old, the seriously ill, or the very disabled patient. Such patients are usually unable to stand on their own or to turn 360° when lying down. The method is often used for suspected obstruction, fistulization, and evaluation of the distal colon after colostomy.

(Fig. 2)



Double-contrast AP large intestine, left lateral decubitus position. Image courtesy of Dr. Naveed Ahmad.

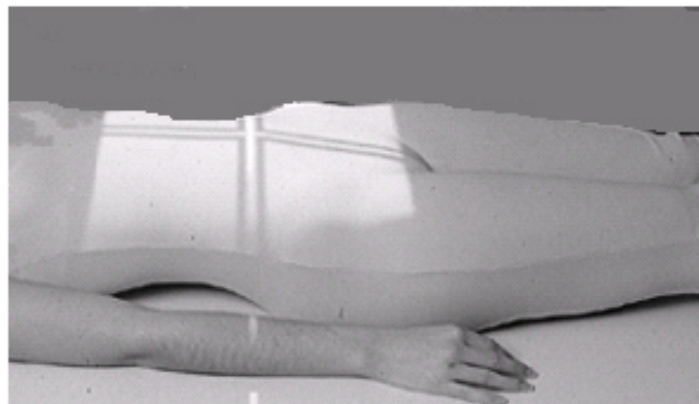The double-contrast barium enema is preferable in patients with a family or personal history of colon neoplasia, in patients suspected or known to have inflammatory bowel disease, and in the search for the etiology of anemia, weight loss, or hematochezia.

The use of biphasic examinations (a double-contrast examination followed immediately after evacuation by low-density barium or a limited double-contrast evaluation of a difficult segment identified in single contrast) should be considered when a given examination is incomplete or equivocal.



Continued

(Fig. 3)



- The goal is to view the entire colon, including the splenic flexure and rectum.
- Place the patient in the supine position.
- Center the midsagittal plane to the grid and adjust the center of the cassette at the level of the iliac crest.
- The central ray is directed perpendicular to the cassette to enter the midline of the body at the level of the iliac crest.
- The vertebral column is centered so that the ascending and descending colon are completely included.
- Respiration is suspended.

Water-soluble contrast medium should be used for patients with suspected perforation and for patients with suspected anastomotic leak.

Contraindications

Contraindications to the use of any barium enema include:

1. Suspected perforation of the colon or pneumoperitoneum (an iodinated water-soluble contrast material should be used instead of barium).
2. Generalized peritonitis.
3. Gas in the bowel wall.
4. Toxic megacolon.
5. Biopsy of the colon after rigid sigmoidoscopy. A biopsy through the flexible fiberoptic endoscope for a superficial mucosal biopsy is not a contraindication. A barium enema can be performed on the same day as an endoscopy, providing a deep biopsy has not been made.



Continued

6. Recent polypectomy by colonoscopy.
7. Acute diverticulitis or other acute inflammatory bowel disease. In these patients, barium enemas should be delayed until medical management has had time to quiet the inflammation.
8. A suspected abscess or fistula (an iodinated water-soluble contrast material should be used instead of barium).

(Fig. 4)



- The goal is to include the rectosigmoid area with less superimposition than the AP projection by angulating the central ray.
- Place the patient in the supine position.
- Center the midsagittal plane to the grid (14 x 17-inch, or 36 x 40-cm IR).
- Adjust the center of the cassette 2 inches (5 cm) above the level of the iliac crest.
- The central ray is directed 30°-40° cephalad to enter the midline of the body 2 inches (5 cm) below the level of the iliac crest.
- Respiration is suspended.

AP axial large intestine. Image courtesy of Dr. Naveed Ahmad.

Patient preparation


- The day before the exam, the patient consumes a liquid nutritional supplement without fiber for breakfast, lunch, and dinner. This provides calories without residue.
- At 2 p.m. on the day before the exam, the patient drinks 12 oz (35.5 cl) of magnesium citrate, then drinks 8 oz (20 cl) of water every hour until 6 p.m., when four 5-mg bisacodyl laxative tablets are taken.



Continued

- The patient then drinks 8 oz (20 cl) water at 7 p.m., 8 p.m., and 9 p.m. on the day before the exam.
- A 10-mg bisacodyl suppository is unwrapped and inserted into the rectum between 6-7 a.m. on the morning of the exam.

(Fig. 5)



- The goal is to view the "up" (medial) side of the ascending colon and the lateral side of the descending colon when the colon is inflated with air.
- Place the patient on the right side with the abdomen in contact with the vertical grid device.
- With the patient lying on an elevated radiolucent support, center the mid-sagittal plane to the grid.
- Adjust the center of the cassette at the level of the iliac crest.
- The central ray is directed horizontal and perpendicular to the cassette to enter the midline of the body at the level of the iliac crest.
- Respiration is suspended.

AP large intestine, right lateral decubitus position. Image courtesy of Dr. Naveed Ahmad.

Reprinted from *Merrill's Atlas of Radiographic Positions and Radiologic Procedures*, 9th edition, Ballinger and Frank, page 149 (figure 17-116), copyright 1999 Mosby, with permission from Elsevier Science.



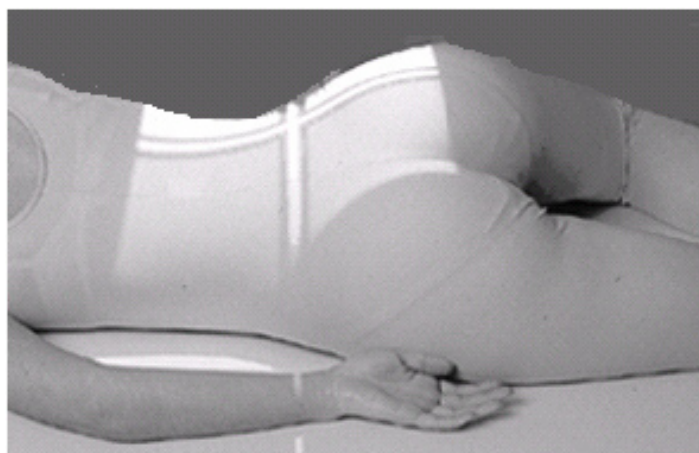
Continued

Supplies

1. Glucagon.
2. 1-cc syringe (for glucagon).
3. 18-gauge needle (for drawing glucagon), 25-gauge needle (for injecting glucagon).
4. Tourniquet.
5. Alcohol swab.
6. Small bandage.
7. Barium sulfate 500-600 cc (105% w/v for double-contrast barium enema).
8. Barium sulfate 500-600 cc (85%-100% w/v for single-contrast barium enema).
9. Barium enema bag with wide tubing (to allow flow of dense barium).
10. Double-contrast enema tip with retention cuff.
11. Cuff innator (for enema tip retention cuff).
12. Lubrication jelly.
13. Pneumatic bulb (to inflate colon) for double-contrast study.

A scout film is taken of the anteroposterior (AP) abdomen. If sufficient retained stool is visualized on the scout film, consider rescheduling the patient for the following day and repeating the bowel preparation or performing a cleansing enema. Residual stool can obscure small colonic lesions.

(Fig. 6)



- The goal is to view the left colic flexure less superimposed or open as compared to the PA projection.
- Place the patient in the prone position.
- With the patient's left arm by the side of the body and the right hand by the head, roll the patient onto the left hip to obtain a 35° - 45° rotation from the table.



Continued


- Center the patient's body to the midline of the grid.
- The central ray is directed perpendicular to the cassette entering 1-2 inches (2.5-5cm) laterla to the midline of the body at the level of the iliac crest.
- Respiration is suspended.

*AP oblique large intestine, LAO position.
Image courtesy of Dr. Naveed Ahmad.*

Radiation

- Fluoroscopy: 750 mrad/min.
- Spot films: 70 mrad per spot film.
- kVp: single contrast -- 110 kVp, double contrast -- 90 kVp.

(Fig. 7)



Sims position for rectal tube insertion. Image courtesy of Dr. Naveed Ahmad.

Rectal tube insertion procedure

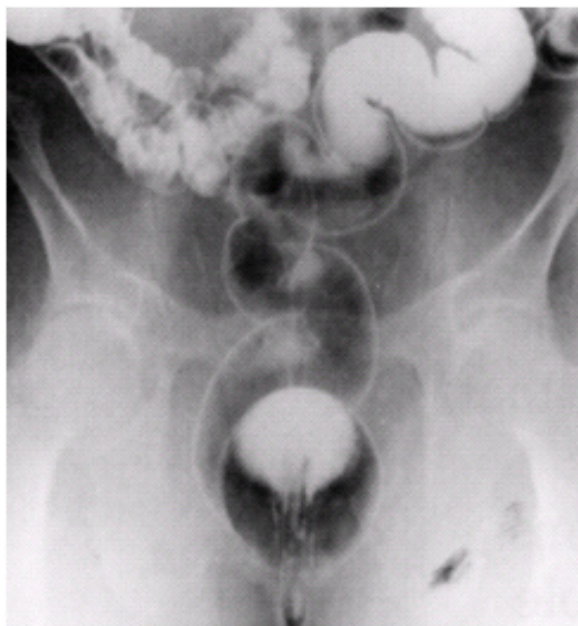
1. Describe the tip insertion procedure to the patient.
2. The patient is asked to roll onto the left side and lean forward. The right leg is flexed at the knee and hip and is placed in front of the left leg. The left knee is comfortably flexed. This is called the Sims position. The goal is to relax the abdominal muscles and decrease pressure within the abdomen.
3. Before insertion, the barium-sulfate solution should be well mixed. Allow barium to flow through the tubing and from tip to remove any air in the system.
4. After wearing gloves, coat the enema tip well with water-soluble lubricant.



Continued

5. Advise the patient to relax and take deep breaths. On expiration, insert the rectal tube gently into the anal orifice and direct the tube anteriorly 1-1 ½ inches (2.5-3.8 cm). The total insertion should not exceed 1 ½ inches (3 to 4 cm). Do not force the enema tip.
6. After the rectal tube is inserted, tape it in place to prevent slipping. Do not inflate the retention balloon unless directed by the radiologist.
7. Ensure that enema bag is no more than 24 inches (60 cm) above the table.
8. Ensure tubing stopcock is in the closed position and no barium flows into the patient.
9. Notify the radiologist as soon as everything is ready for the examination.
10. Radiologist inflates the rectal balloon if necessary, observing with fluoroscopy to ensure placement proximal to the internal sphincter.

(Fig. 8)



*Double-contrast PA axial (40° angulation).
Image courtesy of Dr. Naveed Ahmad.*

Patient positioning, imaging techniques for routine single-contrast barium enema


The basic principle for performing an accurate single-contrast barium enema is radiography of the colon so that all segments of the colon are clearly seen without overlapping loops. It is also necessary that each segment of colon be seen at



Continued

fluoroscopy and on at least two films so that any suspected lesion can be verified. This is accomplished by a combination of fluoroscopy and compression spot films of the entire colon, as well as bucky films of the entire colon. Compression spot filming is employed to thin out the barium column so that a small lesion, such as a polyp, can be easily seen. However, the rectum and the pelvic loops of the sigmoid colon are not amenable to compression. A through examination incorporates the following procedures and film sequences.

(Fig. 9)



- The goal is to view the "up" (lateral) side of the ascending colon and the medial side of the descending colon when the colon is inflated with air.
- Place the patient on the left side with the abdomen in contact with the vertical grid device.
- With the patient lying on an elevated radiolucent support, center the mid-sagittal plane to the grid.
- Adjust the center of the cassette at the level of the iliac crest.
- The central ray is directed horizontal and perpendicular to the cassette to enter the midline of the body at the level of the iliac crest.
- Respiration is suspended.

*PA large intestine left lateral decubitus position.
Image courtesy of Dr. Naveed Ahmad.*

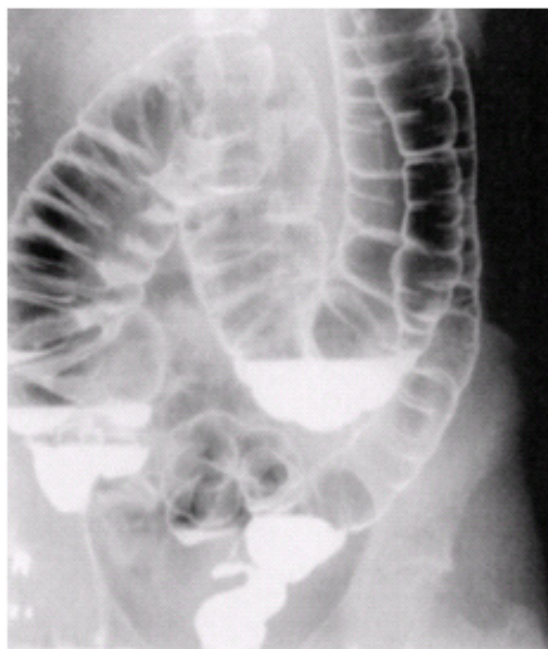


Continued

Spot films

1. Rectum. Use a 10 x 12-inch (25 x 30-cm) image receptor (IR). After insertion of the rectal tube with the patient in Sims position tilt the table head up (20° - 30°), release the control clip until the enema flow fully distends the rectum, then image the rectum in both the AP and left lateral projections. Continued filling risks barium flooding the entire colon and terminal ilium, and can obscure the rectosigmoid colon.
2. Sigmoid colon. Use a 10 x 12-inch (25 x 30-cm) IR. After imaging the rectum, run more barium and image the sigmoid in the left posterior oblique (LPO) and right posterior oblique (RPO) projections.
3. Flexures. Use a 10 x 12-inch (25 x 30-cm) IR. With the table in the horizontal position, release the control clip and run more barium to opacify both flexures, oblique the patient to open, and image splenic flexure in RPO projection and hepatic flexure in LPO projection.
4. Cecum. Use a 10 x 12-inch (25 x 30-cm) IR. Keeping the patient in the AP position, deliver more barium until the cecum is filled, and image with and without compression in AP projection. The ileocecal valve must be seen to ensure complete filling of the colon.
5. Entire colon. Palpate the entire colon with a lead glove to look for masses under fluoroscopy and obtain spot films if needed.

(Fig. 10)



Double-contrast PA large intestine. The splenic flexure is cut off due to hyperesthetic body habitus of the patient; two cassettes are needed to view the entire colon. Image courtesy of Dr. Naveed Ahmad.



Continued

Overhead films

All overhead films must be taken at 110 kVp; suggested films which should be obtained are the following:

1. A posteroanterior (PA) axial projection should include the rectosigmoid area (14 x 17-inch, or 36 x 40-cm IR). The PA projection with the patient in prone projection is preferred over an AP in supine as it results in a more uniform radiographic density of the entire abdomen. The entire colon, including the rectum, should be clearly seen.
2. A PA oblique projection in the left anterior oblique (LAO) position (14 x 17-inch, or 36 x 40-cm IR) should include both flexures.
3. A PA oblique projection in the right anterior oblique (RAO) position (14 x 17-inch, or 36 x 40 cm-IR) should include both flexures.
4. A post-evacuation film. After the radiologist reviews the overhead films, send the patient to the restroom to evacuate as much barium as possible, and obtain an AP abdomen (14 x 17-inch, or 36 x 40-cm IR) post-evacuation film on a horizontal table using 90 kVp.

(Fig. 11)



- The goal is to view the right colic flexure less superimposed or open as compared to the PA projection.
- Place the patient in the prone position.
- With the patient's right arm by the side of the body and the left hand by the head, roll the patient onto the right hip to obtain a 35°- 45° rotation from the table.
- Center the patient's body to the midline of the grid.
- The central ray is directed perpendicular to the cassette entering 1-2 inches (2.5-5 cm) lateral to the midline of the body at the level of the iliac crest.
- Respiration is suspended.

PA oblique large intestine, RAO position. Image courtesy of Dr. Naveed Ahmad.



Continued

Patient positioning, imaging techniques for routine double-contrast barium enema

- After insertion of the rectal tube with the patient in the Sims position, tilt the table head down (-30°) and position the patient in the prone position. Release the control clip and fill the colon with barium (105% w/v). Out of 500 cc only 350 cc usually runs into the colon; the remainder of the barium will remain trapped in the tubing.
- Clamp the tubing and elevate the table to the horizontal position. Place the patient in the LPO position and begin slowly inflating the colon with air, using a pneumatic bulb while changing positions to left lateral, LAO, PA, RAO, and right lateral. Slowly administer four or five puffs in each position. When the barium is well in the right colon, stop inflating and position the patient prone.
- Elevate the table to about 80° while the patient is in the PA position. Unclamp the tubing and lower the enema bag to help drain the excess barium.
- Spot films.
 - Rectosigmoid colon. After draining the excess barium, turn the table to the horizontal position. Inflate the colon with more air to distend the rectosigmoid colon, then take spot films of:
 - Rectum. PA and left lateral.
 - Sigmoid. LPO and right lateral.
 - Flexures. Elevate the table to the upright (vertical) position and obtain spot film of the splenic flexure (RPO) and the hepatic flexure (LPO).
 - Cecum. Decline the table to the horizontal position and obtain AP and LPO views of the cecum. If barium is retained in the cecum, use a lead glove to disperse the barium and turn the patient in LPO or RPO positions.
- Overhead films. All overhead films must be taken at 110 kVp; additional air should be insufflated before taking decubitus projections (approximately 5-7 pumps before each decubitus). No post-evacuation film is needed. All overhead films are obtained with the table horizontal. Suggested films that should be obtained are:
 - PA to include rectum (14 x 17-inch, or 36 x 40-cm IR).
 - 15° RAO with 35° tube angle caudad for sigmoid (14 x 17-inch, or 36 x 40-cm IR); three overhead films and five on a gurney against an upright bucky.
 - Left lateral decubitus (14 x 17-inch, or 36 x 40-cm IR).
 - Right lateral decubitus (14 x 17-inch, or 36 x 40-cm IR).



Continued

- Cross-table lateral rectum with patient prone and tip removed.
- Upright abdomen (14 x 17-inch, or 36 x 40-cm IR).
- The films must be evaluated by a radiologist before the patient leaves the department in case additional radiographs are needed to evaluate suspicious areas. If a lesion is suspected in the distal rectum, removal of the enema tip and additional radiographs will be necessary.



Patient positioning tips for a premium UGI series

Patient positioning tips for a premium UGI series

By Dr. Naveed Ahmad

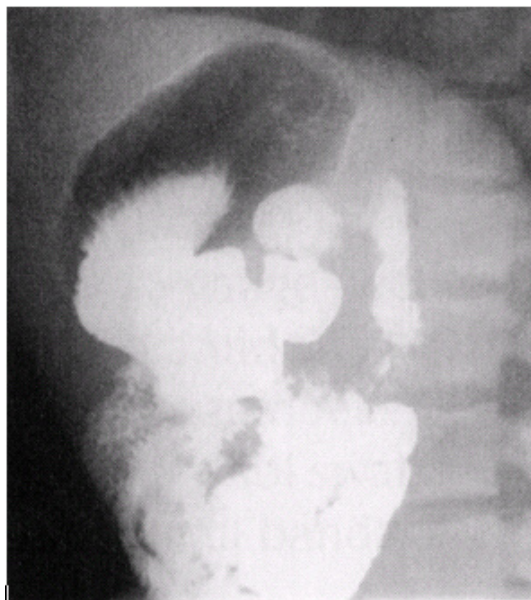
April 17, 2002

This article is one in a series of white papers on patient positioning techniques. Appearing monthly on AuntMinnie.com, the articles will explore each of the major modalities. If you'd like to comment on or contribute to this series, please e-mail editorial@auntminnie.com.

The upper gastrointestinal (UGI) procedure includes radiographic and fluoroscopic evaluation of the esophagus, stomach, and duodenum while the patient is drinking a barium solution. Barium is completely inert, not absorbed, and not allergenic. The liquid barium has a chalky taste, although the taste can be masked somewhat by added flavors such as strawberry or chocolate. Spot films are obtained in various projections during the dynamic portion of the study. Subsequent to this, routine overhead films are obtained. Three approaches are commonly used.

1. Single-contrast gastrointestinal (GI) series.
2. Double-contrast GI series.
3. Biphasic upper GI examination (both single- and double-contrast incorporated together).

(Fig. 1)



Single-contrast UGI overhead image of right lateral stomach with patient in right lateral position. Image courtesy of Dr. Naveed Ahmad.

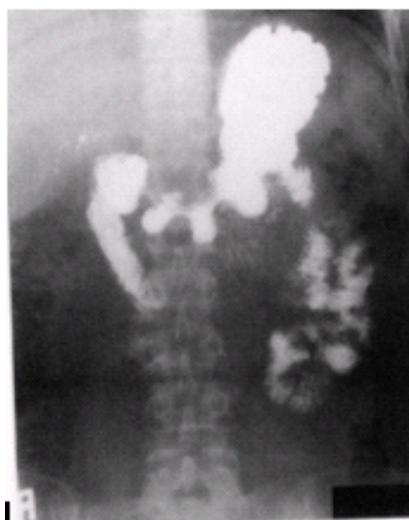

Continued

Single-contrast upper gastrointestinal series

In a single-contrast UGI examination, the outline of the barium-filled viscous provides the most apparent information, enabling any lesions causing contour defects such as large tumors and ulcers to be easily seen. However, small lesions such as small ulcers and polyps require fluoroscopically guided compression. Compression is critically important in the detection of these small lesions. The single-contrast UGI series uses a medium-density barium suspension that permits a combination of meaningful compression filming. Kilovoltage for most single-contrast studies should be in the range of 90-110 kVp to allow adequate penetration.

(Fig. 2)



Single-contrast UGI overhead PA film. Note that the stomach is imaged at the superior aspect of the film so as to visualize as much of the small bowel as possible. Image courtesy of Dr. Naveed Ahmad.

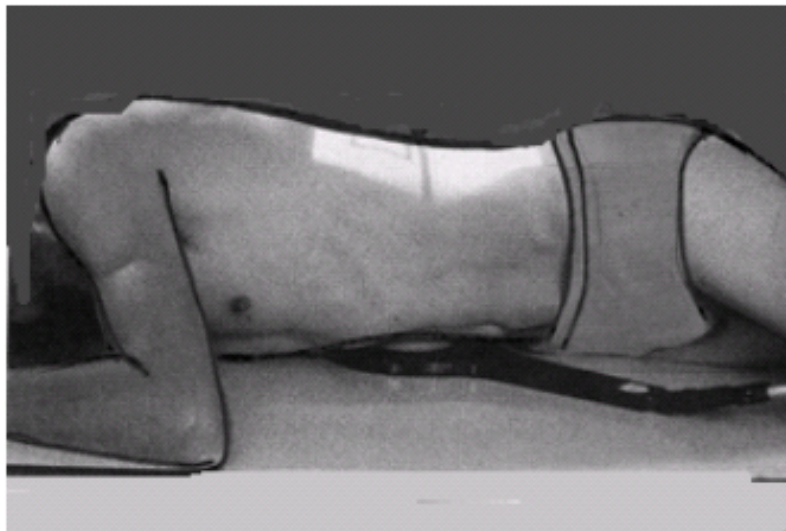
After the fluoroscopy and spot film are complete, the technologist obtains bucky films of the patient's stomach and duodenum using an overhead tube. The following views constitute a suitable set of bucky films:

1. Prone film of the stomach and duodenum.
2. Right anterior oblique (RAO) film of the stomach and duodenum.
3. Right lateral film of the stomach and duodenum.
4. Supine film of the stomach and duodenum.



Continued

(Fig. 3)



- ❖ Position the patient in the prone and slightly RAO position.
- ❖ Place an inflatable paddle in the area of interest and, under fluoroscopy, adjust the patient so that the center of the duodenal bulb is in the center of the paddle.
- ❖ CR perpendicular to the IR.
- ❖ Pylorus and duodenal bulb should not superimpose.

Right anterior oblique position for gastrointestinal imaging. Image courtesy of Dr. Naveed Ahmad.

Indications

- To precede a small bowel series.
- Inability to tolerate biphasic UGI series (nausea, vomiting, decreased mobility).
- Assessment of gastric peristalsis or for gastric outlet obstruction.
- Suspected hiatal hernia.
- Evaluation of masses, varices, strictures, fistulas, or aberrant anatomy.
- Post pyloroplasty.

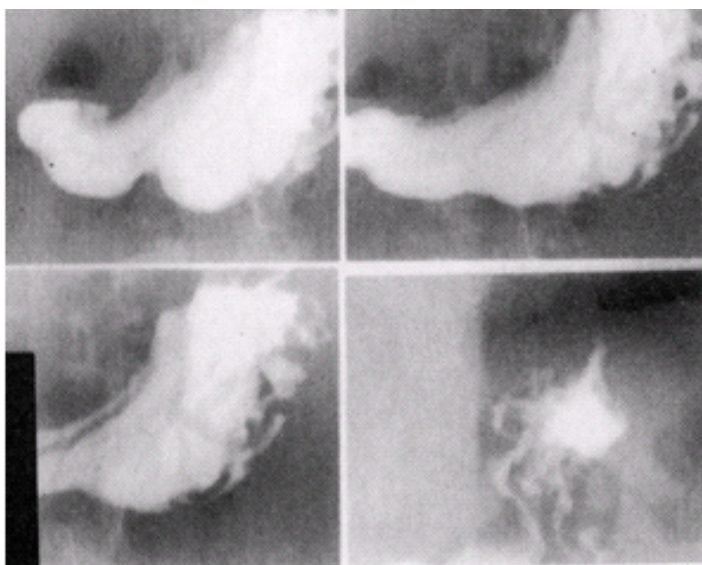


Continued

Contraindications

If perforation is suspected, water-soluble contrast is used by convention.

(Fig. 4)



Stomach images in which the upper two images are obtained with compression. The bottom two images are superior body and fundus, which, being under the ribs, cannot be compressed. Image courtesy of Dr. Naveed Ahmad.

Patient preparation

The patient should be NPO (nothing by mouth) after midnight or for 6 hours prior to the exam.

Supplies

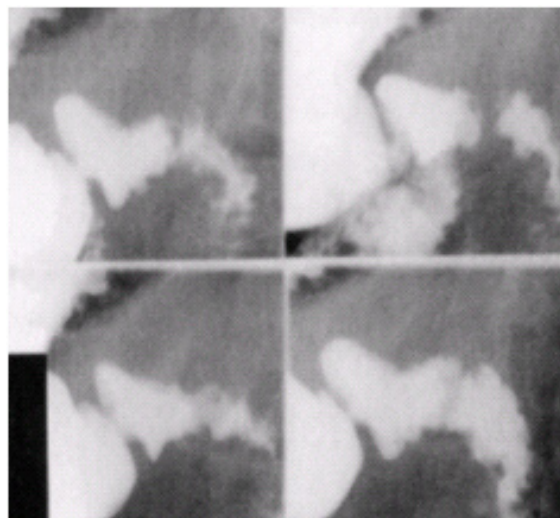
1. 2 oz (59 ml), then 4-6 oz (118-177 ml) of regular barium (60% weight/volume)
2. Barium cup
3. Large-caliber flexible straw
4. Scout film: not obtained routinely.

(see Fig. 5, next pg.)



Continued

(Fig. 5)



Images of the duodenal bulb in four slightly different views (10 x 12 image receptor, 4 on 1). Image courtesy of Dr. Naveed Ahmad.

Patient positioning and imaging techniques

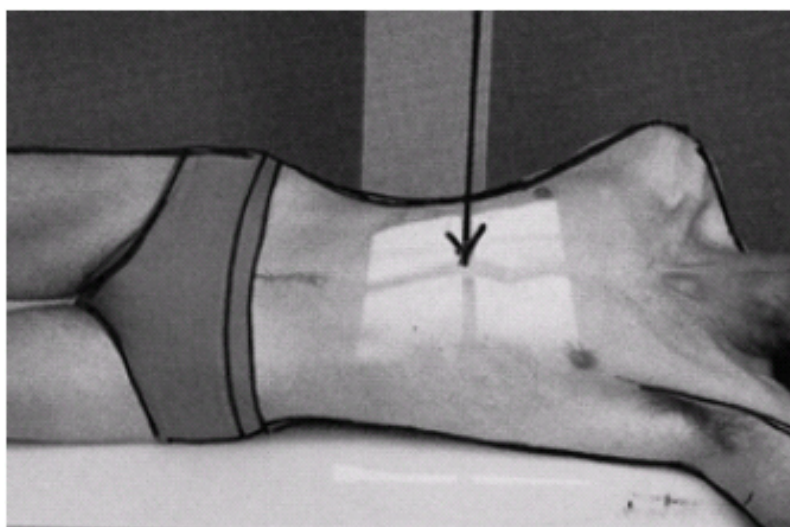
1. With table vertical and patient in the left posterior oblique (LPO) position, have the patient drink 2 oz regular barium (60% w/v) and quickly scan the esophagus from the pharynx to the lower esophageal sphincter.
2. Keep the tabletop vertical and patient LPO, and image the stomach with compression to reveal the gastric folds. If the folds are difficult to see, decline the table to 45° and compress again. The superior body and fundus are under the ribs and cannot be compressed. Bring the table to the horizontal position to image the fundus.
3. With the table head down -20°, obtain a single contrast esophagram by having the patient drink 4-6 oz regular barium (60% w/v) to fill and distend the esophagus, and obtain images of the proximal esophagus, midesophagus, and the distal esophagus with patient in RAO position.
4. With the tabletop horizontal and patient in right lateral position, image the duodenal bulb. Visualize the barium-filled duodenal bulb and obtain at least four slightly different views. If the bulb is not well seen, have the patient inhale deeply and stop breathing briefly to improve visualization of the bulb. Alternatively, the patient can be placed prone and the duodenal bulb can be compressed from underneath by using a balloon compression paddle.



Continued

5. With the table horizontal, image both the stomach and duodenal bulb in the right lateral or RAO position. Alternatively, the technologist can obtain this image as an overhead film.
6. Obtain an overhead PA film. The stomach should be positioned at the superior aspect of the film, so as to visualize as much of the proximal small bowel as possible.

(Fig. 6)



- ❖ Position the patient in the supine position.
- ❖ Place the right arm along the side of the body and abduct the left arm.
- ❖ Turn the patient toward the left (30-60°) resting on the left posterior body surface.
- ❖ Flex the right knee.
- ❖ Immobilize by placing a sponge against back of the patient.
- ❖ Center CR and IR to duodenal bulb at level of L1-L2.

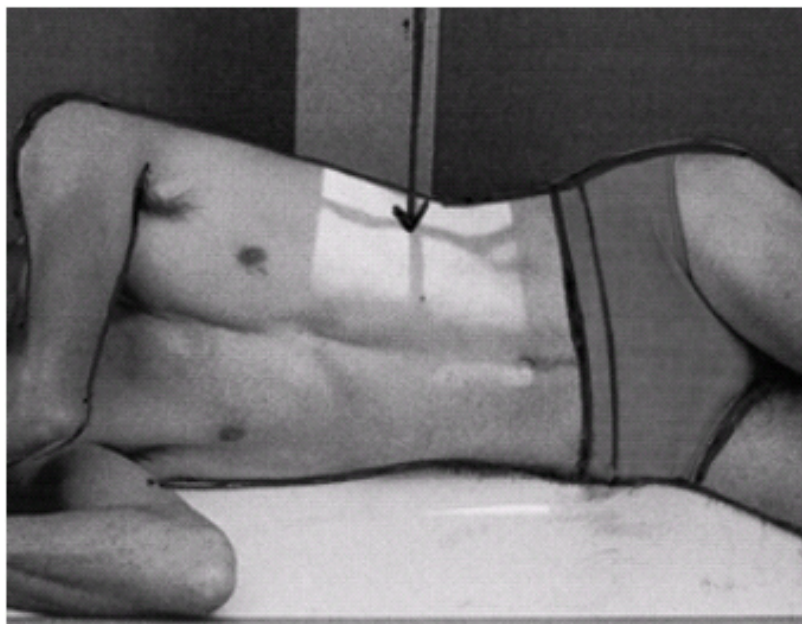
Left posterior oblique position for stomach and duodenum imaging. Image courtesy of Dr. Naveed Ahmad.

Reprinted from *Merrill's Atlas of Radiographic Positions and Radiologic Procedures*, 9th edition, Ballinger and Frank, page 112 (figure 17-42), copyright 1999 Mosby, with permission from Elsevier Science.



Continued

(Fig. 7)



- ❖ Position the patient in the right lateral position.
- ❖ Place the arms up by the patient's head and flex their knees.
- ❖ Center CR and IR to duodenal bulb at level of L1 and 1-1.5 inches (2.5-3.8 cm) anterior to mid-coronal plane.
- ❖ Minimum SID is 40 inches (100 cm).
- ❖ Adjust the body in a true lateral position.

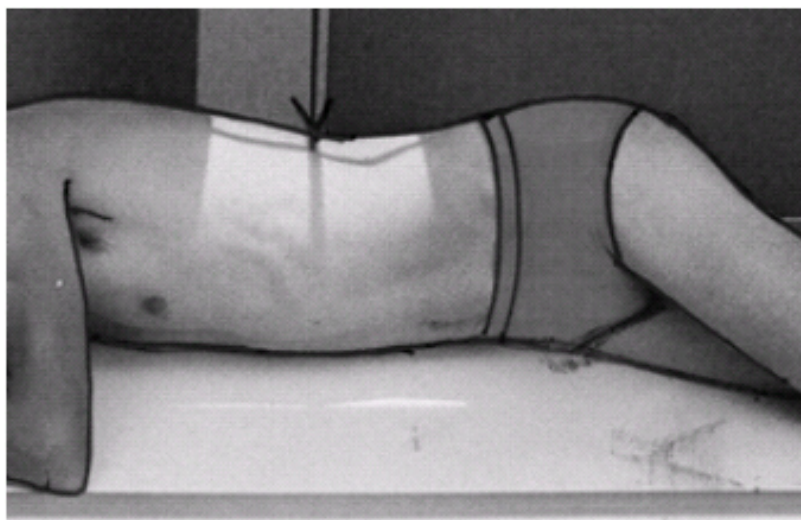
Right lateral position for stomach and duodenum imaging. Image courtesy of Dr. Naveed Ahmad.

Reprinted from *Merrill's Atlas of Radiographic Positions and Radiologic Procedures*, 9th edition, Ballinger and Frank, page 114 (figure 17-44), copyright 1999 Mosby, with permission from Elsevier Science.



Continued

(Fig. 8)



- ❖ Place the patient in the supine position.
- ❖ Rest the patient's head on their right cheek.
- ❖ Turn the patient toward the left (40-70°) so the right side of their body is against the table.
- ❖ Place the right arm along the side of the body and flex the knees.
- ❖ CR is perpendicular and midway between the vertebral column at the level of L1-L2.

*Right anterior oblique position for stomach and duodenum imaging.
Image courtesy of Dr. Naveed Ahmad.*

Single-contrast upper gastrointestinal series with small bowel follow-through

Indications

- Evaluation of small bowel obstruction
- Malabsorption, diarrhea
- Systemic diseases such as progressive systemic sclerosis (scleroderma), celiac disease, hypoproteinemia
- Gastrointestinal bleeding, anemia of unknown origin



Continued

Contraindications

If perforation is suspected, water-soluble contrast is used by convention.

Patient preparation

NPO after midnight or 6 hours prior to exam.

Supplies

1. 2 oz (59 ml), then 4-6 oz (118-177 ml) of regular barium (60% w/v) for single-contrast UGI series
2. 8-10 oz (237-296 ml) of regular barium (60% w/v) for small bowel series
3. Barium cup
4. Large-caliber flexible straw
5. Tourniquet
6. Alcohol swab
7. Small bandage
8. Scout film: AP abdomen
9. Tabletop: horizontal

Patient positioning and imaging techniques

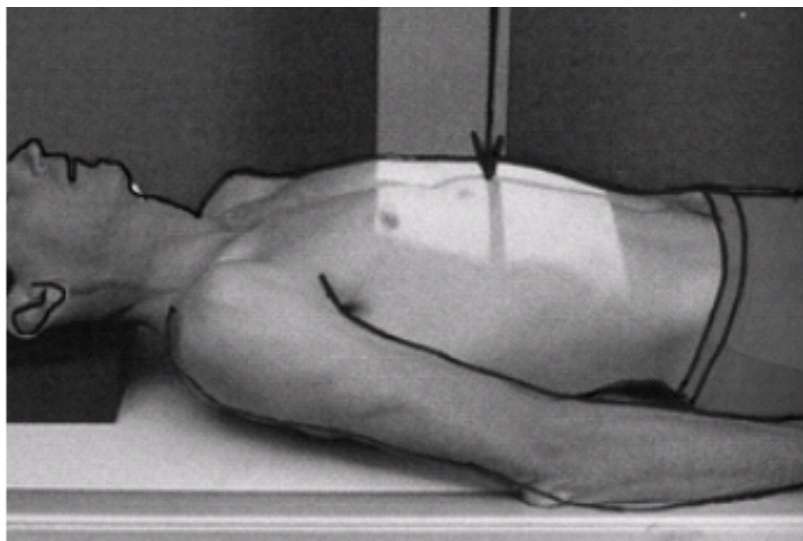
1. Perform a routine single-contrast UGI series.
2. Have the patient drink 8-10 oz of additional regular barium. With the tabletop horizontal, obtain overhead posteroanterior (PA) abdominal films at 20-minute intervals until barium reaches the cecum or ascending colon. It may be necessary to have the patient drink additional barium periodically to keep the stomach and proximal small bowel opacified.
3. When the jejunum and ileum are well visualized, keep the tabletop horizontal, and obtain one or two anteroposterior (AP) spot films of jejunum and ileum using a compression device to separate the loops.



Continued

- After barium is visualized in the cecum or ascending colon on the overhead films, obtain 2 or 3 compression views of the ileocecal valve and the terminal ileum. The ileocecal valve and the terminal ileum can be seen best in most patients by turning them slightly LPO and compressing.

(Fig. 9)



- ❖ Position the patient in the supine position.
- ❖ Place the both arms along the side of the body.
- ❖ Align midsagittal plane to midline of table.
- ❖ Turn the patient toward the left, resting on the left posterior body surface.
- ❖ CR is centered perpendicular to IR at level of L1-L2.
- ❖ Ensure that body is not rotated.

Anteroposterior position for stomach and duodenum imaging. Image courtesy of Dr. Naveed Ahmad.

Double-contrast GI series

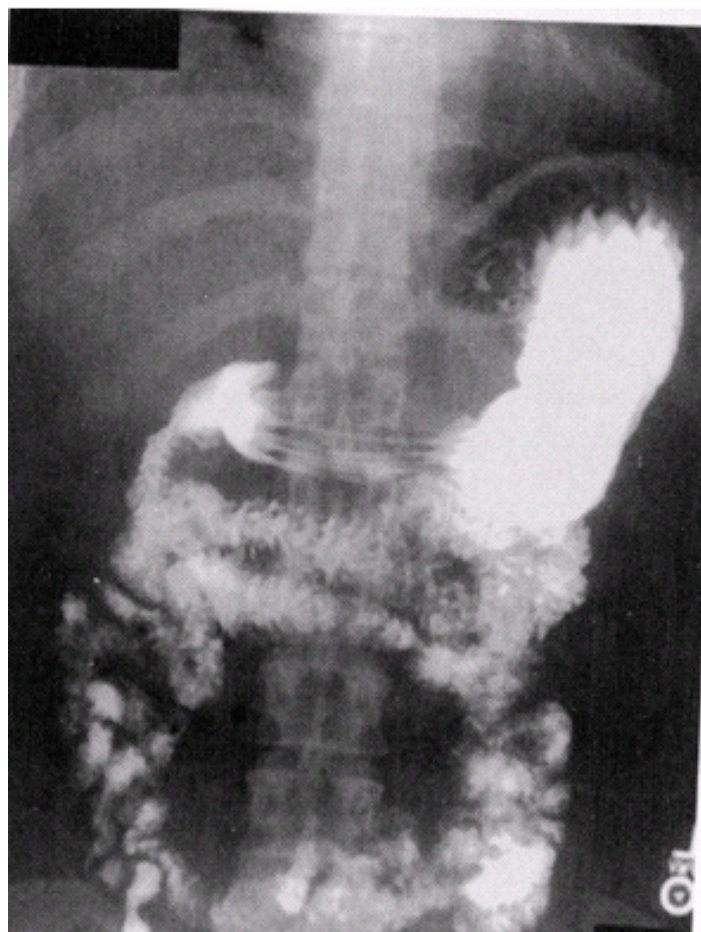
The double-contrast examination is a general study of the upper gastrointestinal tract from the pharynx to the duodeno-jejunal flexure that employs coating the mucosa uniformly with barium. A relatively small quantity of high-density barium (200-250% w/v) is used to demonstrate fine mucosal detail, and distension and double contrast are achieved by means of a gas-producing agent.

(see Fig. 10, next pg.)



Continued

(Fig. 10)



Double-contrast UGI, overhead PA film. The overhead view must include two or more loops of jejunum. Image courtesy of Dr. Naveed Ahmad.

Biphasic upper gastrointestinal series

The biphasic examination is a commonly used modification of the double-contrast technique whereby an additional quantity of dilute barium is given toward the end of an examination and further films are obtained of the compressible parts of stomach and duodenum. The goal of the biphasic examination is to have both mucosal delineation in the double-contrast phase and full column distension in the single-contrast phase. The advantage of this method is that it images some lesions better than by double contrast alone.

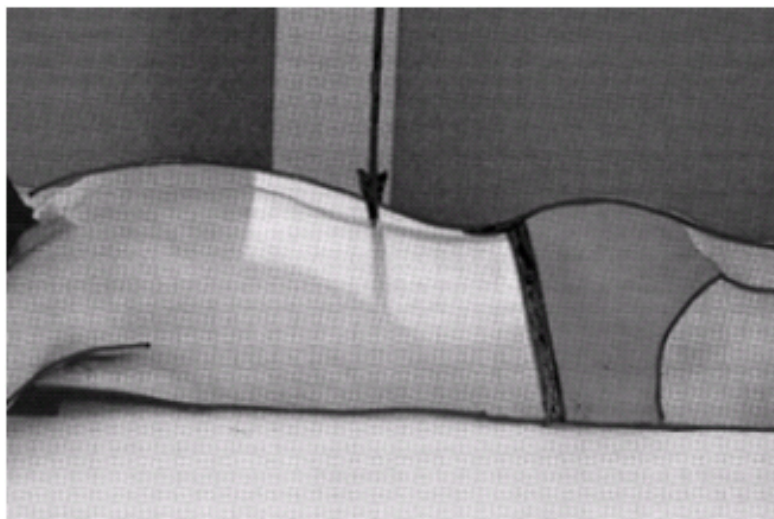
After the radiologist completes the fluoroscopic and spot filming portion of the examination the technologist usually obtains two overhead radiographs. Both of these are obtained at 120 kVp.



Continued

1. RAO of the stomach and duodenum
2. PA prone projection of the stomach, duodenum, and proximal jejunum

(Fig. 11)



- ❖ Position the patient in a recumbent position
- ❖ Upright position can also be used
- ❖ Align midsagittal plane to midline of table
- ❖ Ensure that body is not rotated
- ❖ CR is centered to duodenal bulb at the level of L1 (lower lateral margin of ribs)
- ❖ Minimum SID is 40 inches (100 cm)

Indications

Mucosal disease (early erosions, ulcerations, polyps, cancer)

Contraindications

- Suspected perforation
- A biphasic exam should not precede a small bowel series so as not to fill the small bowel with dense barium.

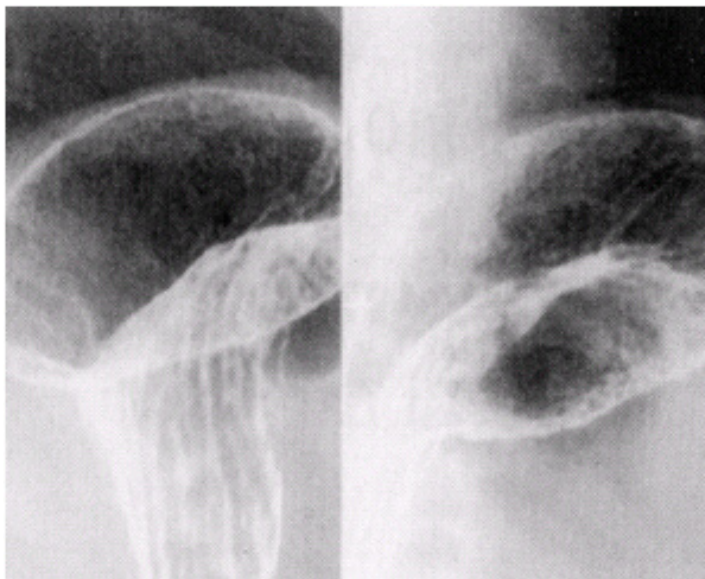
Patient preparation

NPO after midnight or 6 hours prior to exam.



Continued

(Fig. 12)



Double-contrast image of gastric fundus in right lateral position. Image courtesy of Dr. Naveed Ahmad.

Supplies

1. 0.2 mg glucagon
2. 1 cc syringe (for glucagon)
3. 18-gauge needle (for drawing glucagon)
4. 25-gauge needle (for injecting glucagon)
5. Tourniquet
6. Alcohol swab
7. Small bandage
8. 2 oz (59 ml), then 4-6 oz (118-177 ml) regular barium (60% w/v) Barium cup
9. Large-caliber flexible straw
10. 3/4 ampule effervescent granules (such as Baros)
11. 10 cc water
12. 2 medicine cups (for effervescent granules and water)

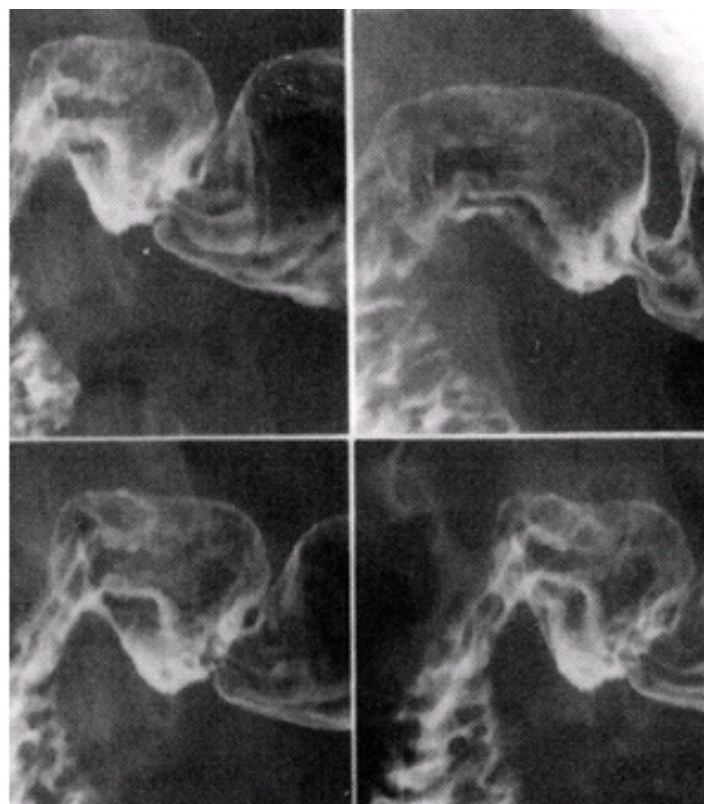


Continued

13. 4-6 oz (118-177 ml) dense barium (200-250% w/v)

14. Scout film: not obtained routinely.

(Fig. 13)



Double-contrast images of duodenal bulb in left lateral position in various obliques (10 x 12 image receptor, 4 on 1). Image courtesy of Dr. Naveed Ahmad.

Patient positioning and imaging technique

1. Administer 0.2 mg glucagon (intravenously if possible). Glucagon causes temporary paralysis of the gut, which reduces spasm and motion artifacts.
2. With the tabletop head up 20-30°, perform a routine single-contrast UGI. Do not wait for the duodenal bulb to fill with barium, as the effect of glucagon rapidly diminishes.
3. With the tabletop vertical, obtain a double-contrast esophagram. Pour the effervescent granules and 10 cc of water into the patient's mouth. With tabletop horizontal, have the patient swallow and then quickly drink 4 oz of dense barium.



Continued

Caution the patient not to burp. As the patient is drinking, observe the esophagus for a "silver-satin" appearance, and obtain images of the proximal esophagus, midesophagus, and the distal esophagus in the LPO position.

4. After obtaining the double-contrast esophagram, decline the table to horizontal, roll the patient to the prone position, and rock the hips from side to side 8-10 times to optimize mucosal coating. Pull the patient from prone to the LPO position to film the antrum, then the AP position to film the antrum and body. Take several slightly different views of these areas.
5. Keep the table horizontal, move the patient to the right lateral position, and film the fundus.
6. Keep the patient in the right lateral position until the duodenal bulb fills with dense barium, and then turn the patient to the left lateral position. When gas fills the bulb, take images in various obliques.
7. With the table horizontal, turn the patient to the right lateral position and image the stomach, which should be centered on the film. Alternatively, the technologist can obtain this image as an overhead film.
8. Obtain an overhead film that includes the stomach, duodenum, and two or more loops of the jejunum. The exam is not complete until at least two loops of the jejunum are visualized.



Positioning techniques for quality esophagrams

Positioning techniques for quality esophagrams

By Dr. Naveed Ahmad

March 20, 2002

This article continues our series of white papers on radiologic patient positioning techniques for x-ray examinations. Appearing each month on AuntMinnie.com, the series will explore each of the major modalities. If you'd like to comment on or contribute to this series, please e-mail editorial@auntminnie.com.

The esophagus may be examined by performing a single-contrast study in which only barium or another radiopaque contrast agent is used to fill the esophageal lumen. A double-contrast procedure also may be used. For this study, barium and carbon dioxide crystals (which liberate carbon dioxide) are the two contrast agents. No preliminary preparation of the patient is necessary.

Single-contrast esophagram

A single-contrast esophagram may be ordered for the following indications:

- Dysphagia (difficulty swallowing)
- Odynophagia (painful swallowing)
- Globus (sensation of a lump in the throat)
- Retrosternal discomfort
- Evaluation of masses, vascular rings/slings, strictures, or aberrant anatomy
- Evaluation of esophageal motility

If an esophageal perforation is suspected, water-soluble contrast is used by convention.

(see Fig. 1)

Supplies and technical factors

1. 4-6 oz (100-200 ml) regular barium (60% weight/volume)
2. Barium cup
3. Flexible large-caliber straw
4. ± 2 oz (± 59 ml) regular barium (60% w/v) diluted with 2 oz (59 ml) water

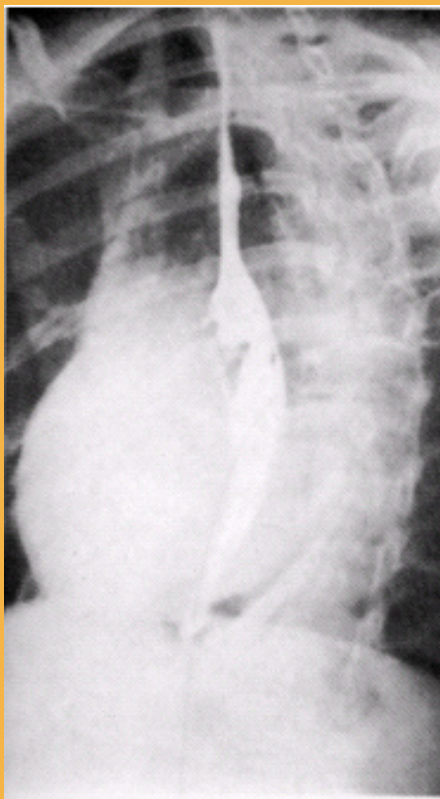
Scout film: not routinely obtained

Image receptor (IR) or cassette: 14 x 14 inches (35 x 35 cm); for a 3-on-1 or spot-film image

kVp: 110

Table-top position: the table is declined to -20° to allow for a full esophageal distention

(Fig. 1)

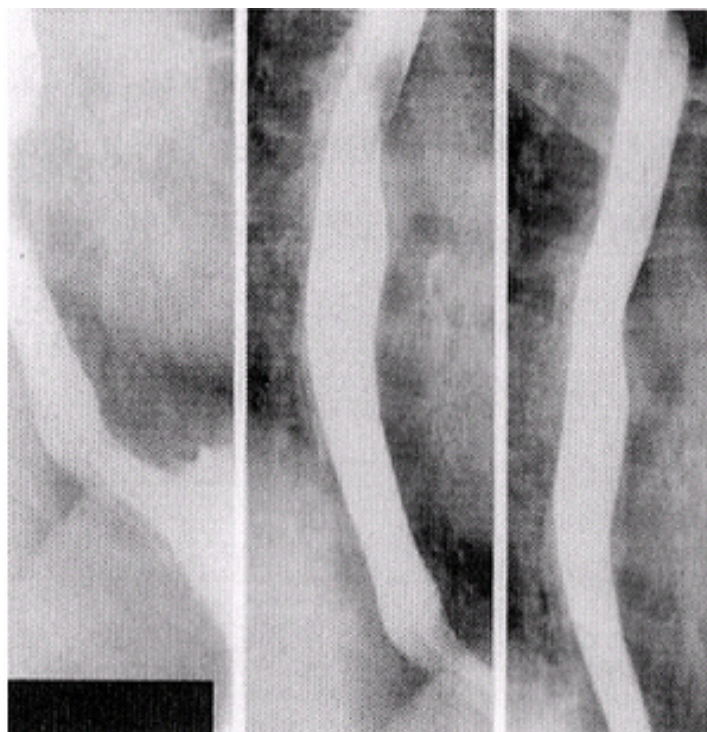


Left anterior oblique projection, single-contrast esophagram. Image courtesy of Dr. Naveed Ahmad.



Continued

(Fig. 2)



Single-contrast study of esophagus in RAO position with table top in head-down -20° position. Image courtesy of Dr. Naveed Ahmad.

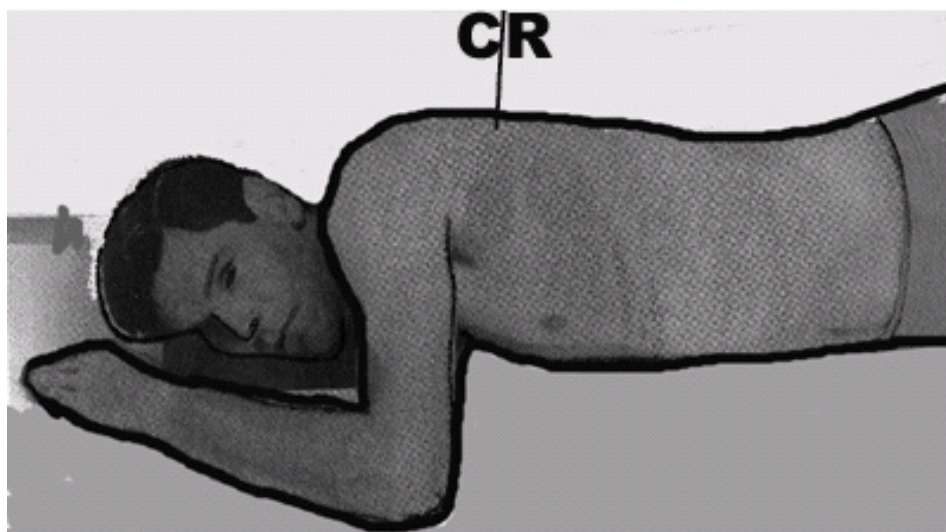
Patient positioning for a single-contrast esophagram

- Place the patient in the right anterior oblique (RAO) position to offset the esophagus from the spine. The patient's right arm is placed alongside the body, with the left knee flexed.
- The technologist should place the cup of barium in the patient's left hand, with the straw between the patient's teeth.
- The patient's neck is turned to the left, and the head is placed flat on a pillow. Patients who are unable to tolerate this position may be imaged in the left posterior oblique (LPO) position.
- Position the fluoroscope so that the apex of the left lung appears at the top of the monitor.
- The technologist will ask the patient to continuously drink the barium. This fills and distends the esophagus while the technologist obtains images of the proximal esophagus, midesophagus, and the distal esophagus, including an open lower esophageal sphincter (magnified if possible).



Continued

(Fig. 3)



PA oblique esophagus, RAO position (the midsagittal position forms an angle of 35° -45° from the grid device). Image courtesy of Dr. Naveed Ahmad.

Double-contrast esophagram

The performance of the double-contrast esophageal examination is similar to that of a single-contrast examination. For a double-contrast examination, free-flowing, high-density barium must be used. A gas-producing substance, usually carbon dioxide crystals, can be added to the barium mixture or taken by mouth immediately before the barium suspension is ingested. Spot radiographs are taken during the examination, and delayed images may be obtained on request.

A double-contrast esophagram may be ordered for indications of early mucosal disease such as erosions, polyps, tumors, inflammation, or infection. It is contraindicated for the following conditions:

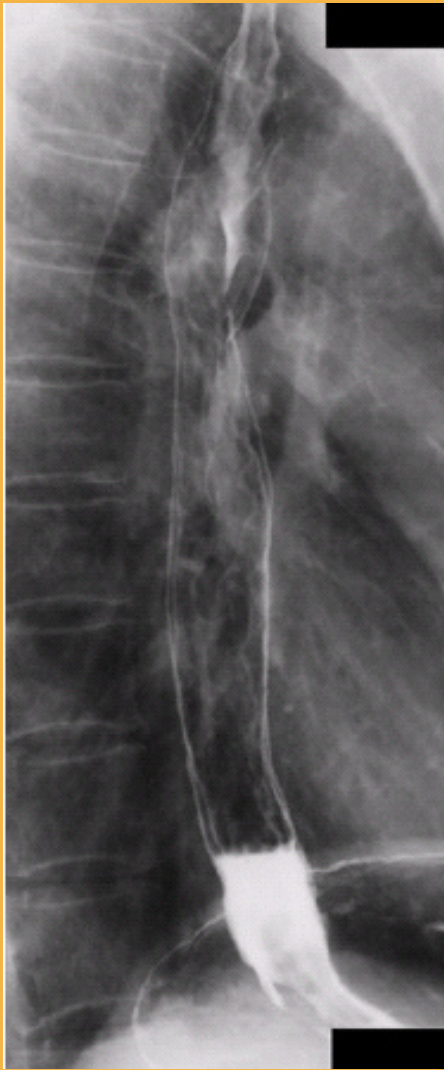
- Suspected esophageal perforation
- Suspected aspiration
- Suspected tracheoesophageal fistula
- Esophageal strictures, or rings
- Evaluation of esophageal motility

(see Fig. 4, next pg.)



Continued

(Fig. 4)



PA oblique distal esophagus, RAO position, double-contrast spot image. Image courtesy of Dr. Naveed Ahmad.

Supplies and technical factors

1. 2 medicine cups (for effervescent granules and water)
2. 3/4 ampule effervescent granules
3. 10 cc water
4. 4-6 oz (100-200 ml) dense barium (200-250% w/v)
5. Barium cup

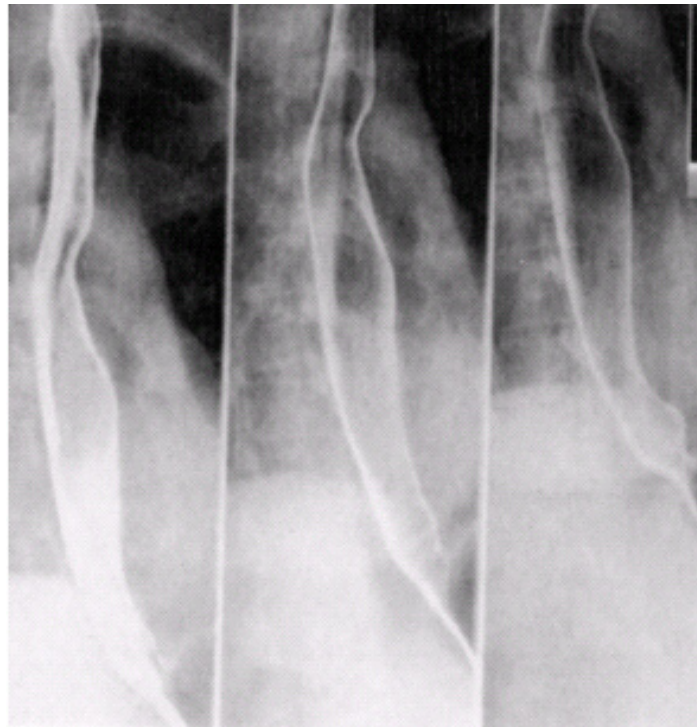
Scout film: not obtained routinely

IR or cassette: 14 x 14 inches (35 x 35 cm) for a 3-on-1 or spot-film image

kVp: 90

Table-top position: vertical

(Fig. 5)



Double-contrast study of esophagus with patient in LPO position with table top in vertical position. Image courtesy of Dr. Naveed Ahmad.



Continued

Patient positioning for a double-contrast esophagram

- Have the patient stand on a footboard in the LPO position to offset the esophagus from the spine.
- Place the cup of dense barium in the patient's left hand.
- Have the patient take a small sip of the dense barium to become acclimated to its consistency. If the patient appears unable to tolerate the dense barium, obtain a single-contrast esophagram.
- Instruct the patient on the swallowing sequence. This is essential for obtaining a satisfactory exam.

Swallowing sequence and technique

1. The patient's head is tilted back to extend the neck.
2. Center the fluoroscope over the upper third of the esophagus to localize the esophagus, then lower the tower and administer the effervescent granules and water. The technologist pours the granules into the back of the patient's mouth, then adds the water and tells the patient to immediately swallow. (Overdistension is prevented by using only 3/4 ampule of the effervescent granules.)
3. The patient drinks the barium with moderate rapidity and with constant encouragement by the technologist.
4. Caution the patient not to burp.
5. Image the entire esophagus as the patient is drinking, observe the esophagus for a "silver-satin" appearance -- indicating the best possible coating -- and obtain images of the proximal esophagus, midesophagus, and the distal esophagus.

Post-fluoroscopy projections

The three basic post-fluoroscopy projections for the esophagram are the anteroposterior (AP) or posteroanterior (PA) projection; AP or PA oblique in the RPO or LPO position; and the lateral projection from the right or left position.

Patient positioning for post-fluoroscopy projections

- Position the patient as for chest radiographs (AP, PA, oblique, and lateral).
- The right anterior oblique (RAO) position is usually used in preference to the left anterior oblique (LAO) position. An RAO position of 35° -40° gives a wider space for an image of the esophagus between the vertebrae and the heart. The LPO position may also be recommended.



Continued

- The patient is placed in the recumbent position for esophageal studies unless specified otherwise. This helps to obtain a more complete contrast filling of the esophagus (especially filling of the proximal part) by having the barium column flow against gravity. Moreover, the recumbent position is also used to demonstrate variceal distensions of the esophageal veins.

(see Fig. 6)

Barium administration and respiration

Thick barium: Two or three spoonfuls of thick barium should be ingested and the exposure made immediately after the last bolus is swallowed. (The patient generally does not breathe immediately after a swallow.)

Thin barium: For complete filling of the esophagus with thin barium, the patient may need to drink through a straw to achieve continuous swallowing. The exposure is made after three or four swallows without suspending respiration, and using as short an exposure time as possible.

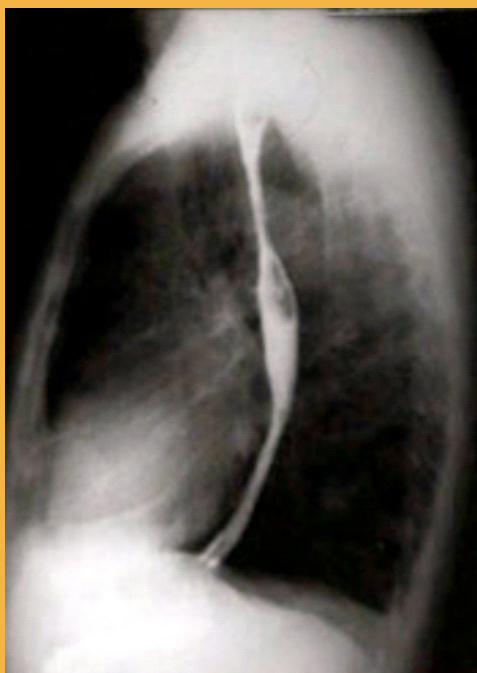For the demonstration of esophageal varices, instruct the patient to fully expirate and then to swallow the barium bolus -- avoid inspiration until the exposure has been made.

Technical factors

- IR or cassette: 14 x 17 inches (35 x 43 cm)
- Grid: yes (moving or stationary)
- kVp: 100 -110 (higher kVp is needed for penetration of barium)
- mAs: 3
- cm :15
- Sk: 65
- ML: 24

(see Fig. 7, next pg.)

(Fig. 6)

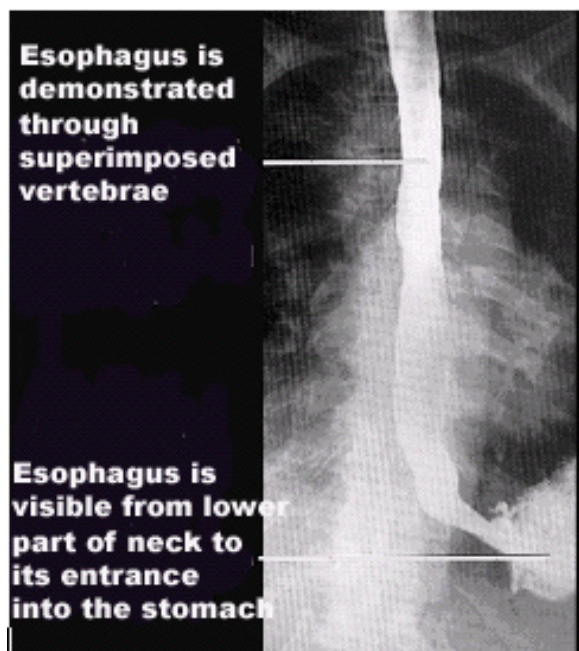


Lateral esophagus, single-contrast study. Image courtesy of Dr. Naveed Ahmad.



Continued

(Fig. 7)



A PA esophagus single-contrast study showing a good esophagram. Image courtesy of Dr. Naveed Ahmad.

Evaluation criteria for a good esophagram

1. The esophagus should be clearly demonstrated from the lower part of the neck to its entrance into the stomach.
2. Technical factors should be adequate for penetration of the barium.
3. On an AP or PA projection, the esophagus should be clearly demonstrated through the superimposed thoracic vertebrae.
4. No rotation of the patient should be seen on an AP or PA projection.
5. On a lateral projection the esophagus is demonstrated between the vertebrae. The heart and ribs posterior to the vertebrae are superimposed to show that the patient was not rotated.
6. On an oblique projection the esophagus is demonstrated between the vertebrae and the heart.
7. The patient's arm should not interfere with visualization of the proximal esophagus.



Dorsal and lateral decubitus patient positioning for abdominal x-ray exams

Dorsal and lateral decubitus patient positioning for abdominal x-ray exams

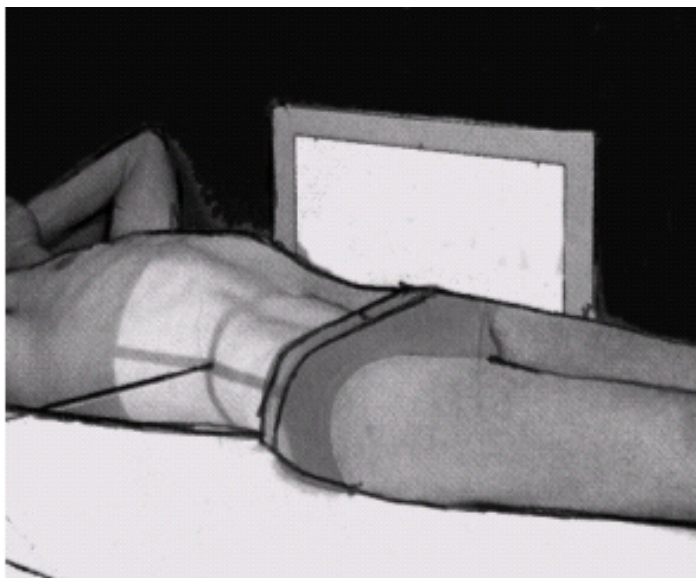
By Dr. Naveed Ahmad

February 28, 2002

This article continues our series of white papers on radiologic patient positioning techniques for x-ray examinations. Appearing each month on AuntMinnie.com, the series will explore each of the major modalities. If you'd like to comment on or contribute to this series, please e-mail editorial@auntminnie.com.

The dorsal decubitus (right or left) position is a good alternative to obtaining a lateral decubitus or erect abdominal x-ray image when a patient cannot stand or lie on their side. It can provide information regarding pneumoperitoneum and air fluid levels in cases of suspected acute abdominal trauma. The examination can be performed at the patient's location, such as the ICU, with a mobile x-ray unit. This view can also help to evaluate an incisional hernia or the diameter of a calcified aortic aneurysm.

(Fig. 1)



Lateral abdomen, left dorsal decubitus position (cross table projection). Image courtesy of Dr. Naveed Ahmad.

Reprinted from *Merrill's Atlas of Radiographic Positions and Radiologic Procedures*, 9th edition, Ballinger and Frank, page 50 (figure 16-19), copyright 1999 Mosby, with permission from Elsevier Science.



Continued

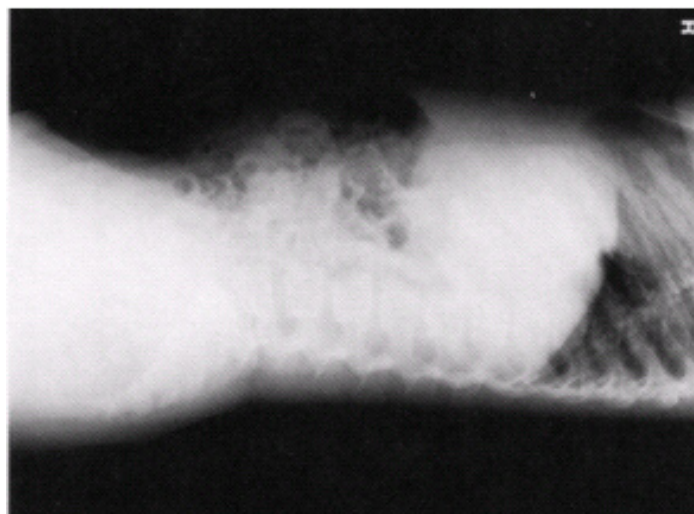
Position of the patient

Place the patient in the supine position on a radiolucent pad with the right or left side against the grid device. Elevate their arms and place them along side their head or across the upper chest. Placing a support under the knee helps to relieve strain when a patient is in the supine position.

Position of abdomen

1. The most commonly used abdominal landmark is the iliac crest, which corresponds to the level of the mid-abdomen and is at the L4-L5 vertebral inter-space level. The iliac crest is at the upper-most position of the curved border of the ilium.
2. Position the patient so that a point approximately 2 inches (5 cm) above the level of iliac crests is centered on the cassette.
3. Ensure that no rotation from the supine position occurs.
4. Maximal relaxation of the abdominal musculature is important in reducing film artifact caused by motion. Relaxation of the abdominal musculature is facilitated by supporting and slightly flexing the patient's knees.
5. The exposure is made at the end of expiration and should begin 1-2 seconds after respiration is suspended. Ask the patient to take a deep breath, let all their breath out, and hold the position while not inhaling. This moves the diaphragm to a superior position that results in better visualization of the abdominal viscera.

(Fig. 2)



A dorsal decubitus (cross table view) projection -- right lateral position. Image courtesy of Dr. Naveed Ahmad.



Continued

Film holder placement

Adjust the height of the vertical grid so the long axis of the cassette is centered to the mid-coronal plane. A 14 x 17 inch (35 x 43 cm) film or image receptor (IR) should be positioned crosswise.

Central ray

The central ray (CR) should be horizontal and perpendicular to the center of the cassette and directed to the mid-coronal plane, 2 inches (5 cm) above the level of the iliac crests.

Collimation

Collimation is adjusted to center mid-coronal plane of the patient to the IR margins, making sure that upper and lower soft tissue borders the abdomen are included. Close collimation is important because of the increased scatter from a high kVp and the need for soft tissue visibility.

Imaging technique

- Film or IR size: 14 x 17 inches (35 x 43-cm) crosswise
- Moving or stationary grid
- 70-80 kVp range
- mAs 60
- Sk 1040
- SID minimum of 40 inches (100 cm)
- cm 30

Evaluation criteria for a good dorsal decubitus projection

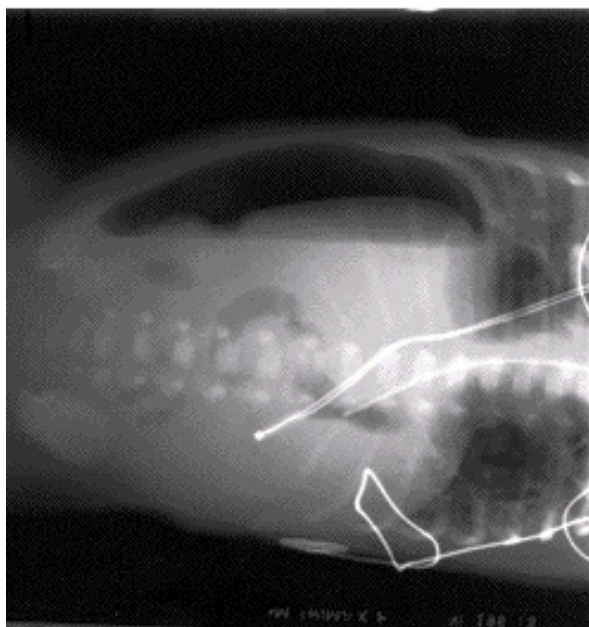
1. Proper collimation and CR -- the image should include the area from the upper border of the pubic symphysis to the diaphragm so that the entire abdomen is demonstrated.
2. Proper exposure -- soft tissue detail in the anterior abdomen and in the prevertebral region of the lower lumbar vertebra should be visible.
3. No motion -- the diaphragm should appear sharp.
4. No rotation -- the posterior ribs and the posterior borders of the iliac wings should be superimposed.



Continued

5. Proper collimation and CR -- the image should include the area from the upper border of the pubic symphysis to the diaphragm.
6. Appropriate markers should be placed indicating the position.

(Fig. 3)



Lateral decubitus radiograph taken with the patient's left side down. There is air on both sides of the bowel and air layering to the top.

Left lateral decubitus AP abdominal exam

The left lateral decubitus position is usually performed on patients who are too ill to stand and are lying on a transportation cart. Special care must be exercised to ensure that patient does not fall off the cart. Lock all the wheels securely in position. Remove any opaque objects in the clothing or gown that can cause artifacts in the area to be x-rayed. Use gonadal shielding on males; the upper edge of the shield should not be above the pubic symphysis. In female patients, an ovarian shield can obscure pelvic anatomy, so one should not be used unless the physician requests it.

Position of the patient

- Place the patient in the left lateral recumbent position on a radiolucent pad. The patient's back should be against the grid device.
- Before films are obtained, the patient should be in the left side down position for at least 10 minutes. This position allows air/fluid to rise out of the lesser sac

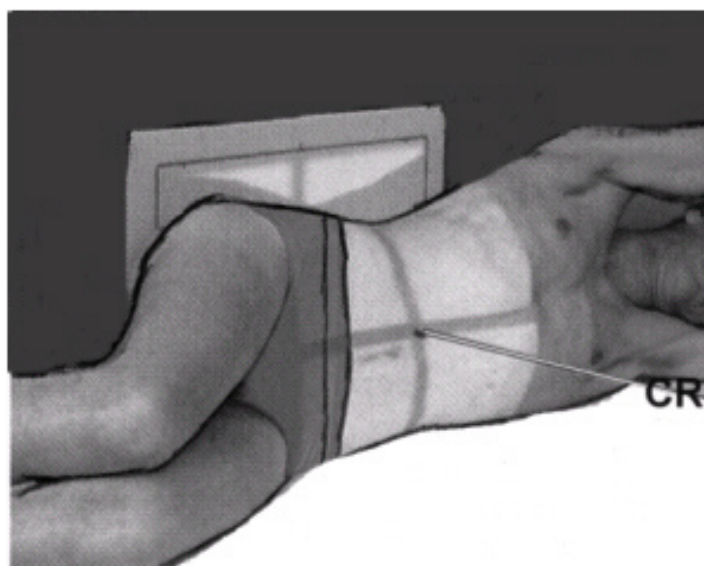


Continued

of the peritoneal cavity (where it may be located) and accumulate beneath the iliac crest or over the right margin of the liver.

- The knees are slightly flexed and superimposed to provide stabilization.
- The arms are elevated and placed along side of the patient's head. The scapulae should lie in the same vertical plane.

(Fig. 4)



*AP abdomen left lateral decubitus position.
Image courtesy of Dr. Naveed Ahmad.*

Reprinted from *Merrill's Atlas of Radiographic Positions and Radiologic Procedures*, 9th edition, Ballinger and Frank, page 44 (figure 16-11), copyright 1999 Mosby, with permission from Elsevier Science.

Position of abdomen

1. Adjust the patient to ensure that a true lateral position is obtained with no rotation of pelvis or shoulders.
2. The most commonly used abdominal landmark is the iliac crest, which corresponds to the level of the mid-abdomen and is at the L4-L5 vertebral inter-space level.
3. The cassette or IR is centered to the iliac crest and the lower abdomen is generally included on the lower margin of the cassette. In some cases, a slightly higher centering point may be needed to ensure that the diaphragm is included in the image.



Continued

4. The exposure is made at the end of expiration and should begin 1-2 seconds after respiration is suspended. Ask the patient to take a deep breath, let it all their breath out, and to hold their position while not inhaling. This moves the diaphragm to a superior position that results in better visualization of the abdominal viscera.

Film holder placement

The long axis of the film should be parallel with the long axis of the body and film is centered to the CR. A 14 x 17 inch (35 x 43 cm) film or IR should be positioned lengthwise, with its lower edge at the symphysis pubis. Crosswise cassette placement is appropriate if the patient is very large. The proximal margin of the cassette should be approximately at the level of the axilla.

Central ray

The CR is directed to the midpoint of the mid-sagittal plane at the level of the iliac crest, in some patients a slightly higher CR, 2 inches (5 cm) above the iliac crest may be needed to include the diaphragms. The CR is directed perpendicular to the film.

Collimation

Collimation is adjusted to center mid-sagittal plane of the patient to the IR margins, making sure that upper side of the abdomen is clearly included.

Imaging technique

- Film or IR size: 14 x 17 inches (35 x 43 cm) lengthwise
- Moving or stationary grid
- 70-80 kVp range
- mAs 30
- Sk 396
- cm 21

Evaluation criteria for a good left lateral decubitus projection

1. Proper alignment -- the vertebral column should be in the midline position. The ribs, pelvis, and hips should be equidistant to the edge of the radiograph.
2. Proper exposure -- slightly less overall density than the supine abdomen projection. Exposure should be sufficient to visualize spine, ribs, and soft tissues.
3. No motion -- the diaphragm should appear sharp bilaterally.
4. No rotation -- spinous processes in the center of the vertebral column and symmetric ilial wings.



Continued

5. Proper collimation and CR -- The image should include the area from the upper border of the pubic symphysis to the diaphragm and upper side of the abdomen should be clearly included.
6. Appropriate markers should be placed indicating the position.

Supplemental projections of the abdomen

When a patient with an acute abdominal trauma is evaluated, the following radiographic projections may be ordered.

1. AP supine radiograph and a horizontal beam radiograph: It is critical that a minimum of these two radiographs be obtained for the demonstration of both free intraperitoneal air (pneumoperitoneum) and air fluid levels. Failure to obtain these projections will result in substantial errors in diagnosis. The upright film centered at the diaphragm is the "best" horizontal beam film in that it will show the smallest amount of free intraperitoneal air.
2. Lateral decubitus position and cross table lateral films: If the patient is unable to stand, a film of the patient in the lateral decubitus position should be obtained with a horizontal beam. This method results in less penetration of the abdominal viscera but good visualization of small amounts of extra alimentary gas. Alternatively, this information can be obtained on a film of the abdomen taken with the patient in the dorsal decubitus position. This position is usually adequate in providing the required image and should be used in patients where an upright position film is impractical.
3. Posteroanterior chest films: In a patient with abdominal pain, a PA chest film with the patient in the upright position is useful for two reasons: it facilitates the detection of small amounts of free intraperitoneal air, and it may demonstrate unsuspected thoracic disease that is causing abdominal pain. PA views are more sensitive for detecting pneumoperitoneum than abdominal films taken with the patient in an erect position. This difference in sensitivity occurs because the x-ray beam is centered at the iliac crest on abdominal films, so that it penetrates air beneath the diaphragm obliquely rather than tangentially. In addition, the exposure technique that is required to penetrate the abdomen obscures small collections of free intraperitoneal air.
4. Perforation series: This term is sometimes used to indicate views of the abdomen including upright, supine, lateral decubitus, and chest PA upright films. The objective of this series is to increase the sensitivity for detection of free intraperitoneal air in case of visceral perforation.
5. Depending on the clinical setting, additional projections such as prone, oblique, lateral, or coned views may be obtained for better localization of lesions, calcifications, or herniations.



AP abdominal projection x-ray positioning techniques

AP abdominal projection x-ray positioning techniques

By Dr. Naveed Ahmad

January 16, 2002

This article continues our series of white papers on radiologic patient positioning techniques. Appearing each month on AuntMinnie.com, the series explores each of the major modalities. If you'd like to comment on or contribute to this series, please e-mail editorial@auntminnie.com.

The anteroposterior (AP) radiograph taken with the patient in a supine position is the basis of the majority of plain-film examinations of the abdomen. The abdominal film obtained with the patient in an erect position is ordered routinely, but rarely adds significant diagnostic information. However, an upright-position film may be helpful in patients with suspected bowel obstruction, as well as to assess the air-fluid levels in the distended bowel.

This information can also be obtained on a film of the abdomen taken with the patient in the lateral decubitus position. An AP supine projection is often called a flat plate or KUB (because it includes the kidneys, ureter, and bladder).

The following are the main reasons abdominal films are requested:

- Bowel obstruction -- abnormal gas pattern.
- Free intraperitoneal air (pneumoperitoneum).
- Free intraperitoneal fluid (ascites).
- Abnormal size or contour of organs.
- Abnormal masses.
- Calculi or other abnormal intra-abdominal calcifications.
- Radiopaque foreign bodies.
- As a preliminary radiograph before performing a gastrointestinal series with contrast, an intravenous pyelogram (IVP), or other radiological procedures.
- To assess the positions of intra-abdominal tubes and catheters.

Preliminary bowel preparation

Preliminary bowel preparation in nonacute patients is administered with a combination of laxatives, enemas, and controlled diet. Preparation is important if the patient will be undergoing contrast examination of the gastrointestinal tract or an IVP.

In all other cases, the decision regarding whether or not a patient undergoes preliminary bowel preparation is determined by the requesting physician. Bowel preparation should not be administered to patients suspected of having bowel



Continued

obstruction, visceral perforations, or abdominal trauma, or to an acutely ill patient.

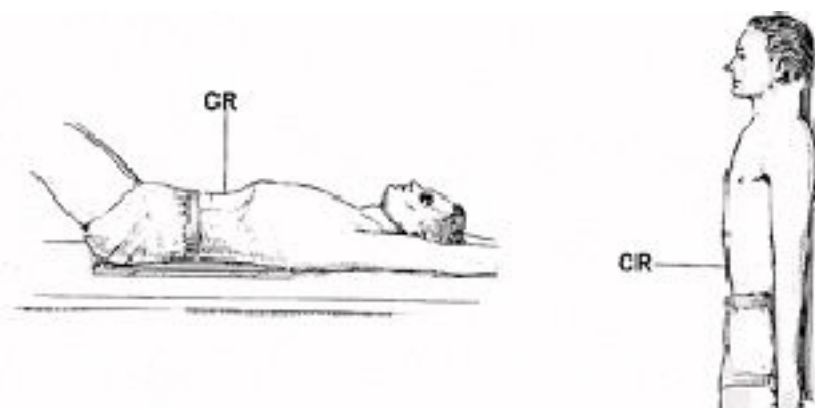
Patient preparation

Ask the patient to remove all clothing and put on a hospital gown. If the patient cannot do so, remove any opaque objects in the clothing that can cause artifacts in the area to be x-rayed. Use gonadal shielding on males; the upper edge of the shield should not be above the pubic symphysis. In female patients, an ovarian shield can obscure pelvic anatomy, so one should not be used unless the physician requests it.

Position of the patient

- If a supine-position radiograph is ordered, placing a support under the knee helps to relieve the strain on the patient while they are in the supine position.
- For upright-position radiograph, the patient's back should be against the grid device, legs slightly spread, with body weight distributed equally on both feet.
- In both positions, the midsagittal plane of the body should be centered to the midline of the grid device.
- There should be no rotation of the shoulder and pelvis.
- Place the patient's arms at the sides and away from the body.

(Fig. 1)



Standard AP supine and upright abdominal patient position. Image courtesy of Dr. Naveed Ahmad.

Position of abdomen

1. The most commonly used abdominal landmark is the iliac crest, which corresponds to the level of the mid-abdomen and is at the L4-L5 vertebral inter-space level. The iliac crest is at the uppermost position of the curved border of the ilium.



Continued

2. For the supine position, the cassette or image receptor (IR) is centered to the iliac crest and the lower abdomen is generally included on the lower margin of the cassette.
3. For the upright position, the cassette is centered 2 inches (5 cm) above the level of the iliac crest, or high enough to include the diaphragm.
4. Maximal relaxation of the abdominal musculature is important in reducing film artifact caused by motion. Relaxation of the abdominal musculature is facilitated by supporting and slightly flexing the patient's knees.
5. Two radiographs may be needed if the patient is very tall.
6. The exposure is made during expiration and should begin 1-2 seconds after respiration is suspended. Ask the patient to take a deep breath, exhale completely, and then hold the position while not inhaling. This moves the diaphragm to a superior position that results in better visualization of the abdominal viscera.

Film holder placement

A 14 x 17-inch (35 x 43-cm) film or IR should be positioned lengthwise, with its lower edge at the symphysis pubis. Crosswise cassette placement is appropriate if the patient is very large.

Central ray

- For a supine-position radiograph, the central ray (CR) should be perpendicular to the cassette at the level of iliac crests.
- For an upright-position film, the CR should be horizontal and 2 inches (5 cm) above the level of the iliac crests and should include the diaphragm.

Collimation

For abdominal radiographs of small patients, some side collimation of the side borders is possible -- if it does not cut off abdominal anatomy. For adults, collimation on the top and bottom should be adjusted to the margins of the film holder, allowing for divergence of the x-ray beam.

Imaging technique

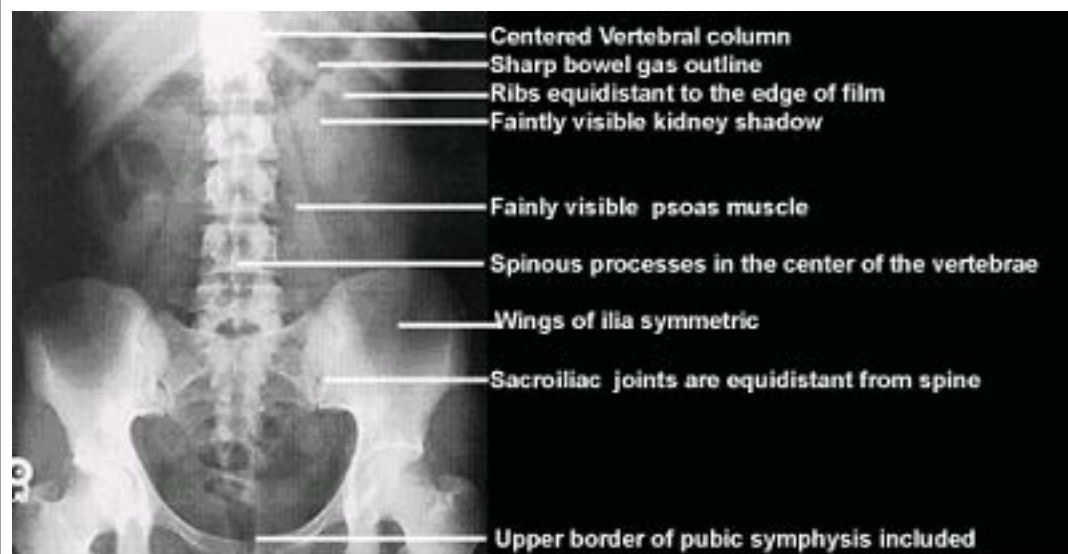
- Film or IR size: 14 x 17 inches (35 x 43 cm) lengthwise
- Moving or stationary grid
- 70-80 kVp range
- mAs 30



Continued

- Sk 396
- cm 21

(Fig. 2)



*AP abdominal image showing important evaluation criteria.
Image courtesy of Dr. Naveed Ahmad.*

Evaluation criteria for a good AP projection

1. The image should include the area from the upper border of the pubic symphysis to the diaphragm.
2. Proper alignment -- the vertebral column should be in the midline position. Ribs, pelvis, and hips should be equidistant to the edge of the radiograph.
3. No rotation -- spinous processes in the center of the vertebral column and symmetric ilial wings.
4. No motion -- ribs and gas bubble margins should appear sharp. The diaphragm should appear sharp in an upright film.
5. Soft tissues visualization -- correctly exposed abdominal radiographs on an average-size patient should faintly visualize the lower liver margin, kidneys, the lateral borders of psoas muscles, and transverse processes of lumbar vertebrae.
6. Appropriate markers should be placed indicating either upright or supine position.



Tips and techniques for decubitus and oblique chest x-rays

Tips and techniques for decubitus and oblique chest x-rays

By Dr. Naveed Ahmad

December 21, 2001

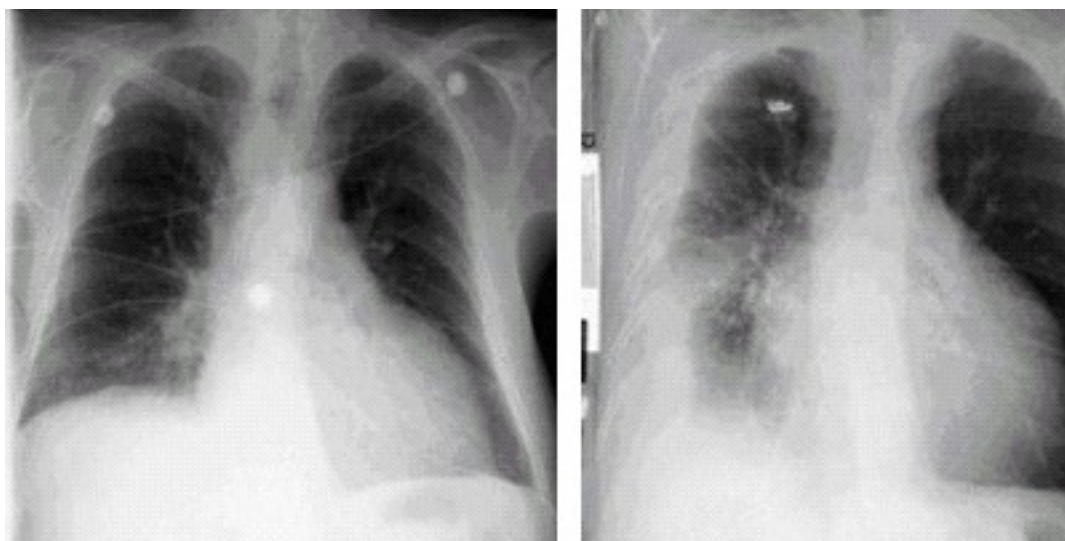
This article continues our series of white papers on radiologic patient positioning techniques. Appearing each month on AuntMinnie.com, the series explores each of the major modalities. If you'd like to comment on or contribute to this series, please e-mail editorial@auntminnie.com.

Chest x-ray lateral decubitus positioning techniques

Decubitus means lying down; thus, this projection is made with the patient lying on their side and the x-ray beam horizontal (parallel) to the floor. The primary goal of performing the lateral decubitus projection is to demonstrate fluid in the pleural cavity (a pleural effusion), which is otherwise not clearly visible on a supine or upright chest radiograph.

Lateral decubitus films are helpful for determining if effusion is free flowing, and are also used to determine whether there is enough fluid to sample by thoracentesis. A lateral decubitus projection can also be helpful in showing small amounts of air in the pleural cavity (a pneumothorax) as well as air fluid levels in other cases.

(Fig. 1)



A case of subpulmonic effusion (pleural effusions located between the lung and the diaphragm). Subpulmonic effusions are suspected by hemidiaphragm elevation. In this case a lateral decubitus x-ray with the patient lying on the side of the effusion is helpful not only to ensure the presence of effusion but also to quantify the volume. Image courtesy of Dr. Naveed Ahmad.



Continued

Patient preparation

Ask the patient to remove all clothing from the waist up, put on a hospital gown, remove any jewelry (necklace, earrings), and, if necessary, tie hair up on top of the head.

Patient position considerations

- Instruct the patient to lie on the affected side if the x-ray is being taken to determine pleural effusion -- or on the unaffected side if it is being taken to look for a pneumothorax. The side to be imaged must be determined by the requesting physician. The projection is called a right lateral decubitus if the patient is lying on the right side and a left lateral decubitus if the patient is lying on the left side.
- A lateral decubitus projection can be obtained in anteroposterior (AP) or posteroanterior (PA) view; however, the AP view is more commonly used.
- Be sure to maintain the patient in position for at least five minutes before making the exposure so that fluid in the pleural cavity can settle and air, if present, can rise.
- Place the appropriate markers to indicate which side is up (decubitus marker or arrow) on the film cassette.

Position of chest

1. Instruct the patient to extend the neck, chin, and head to avoid their superimposition on the lung fields.
2. The patient's arms should be extended sufficiently above the head to prevent their superimposition on the upper chest field.
3. Adjust the thorax in true lateral position and make sure that the patient is not leaning forward, backward, or sideways against the grid. For an AP view, the back of the patient's chest should be placed firmly against the image receptor (IR). Ensure that there will be no rotation in the image by viewing the patient from the tube position. (Placing a radiolucent board under the patient can help reduce the possibility of rotation in the image.)
4. Place a lead shield between the x-ray tube and the patient's pelvis for gonadal protection.
5. When the exposure is ready to be made, ask the patient to take two deep breaths. The exposure is made at the end of the second full inspiration to ensure maximum expansion of the lungs.



Continued

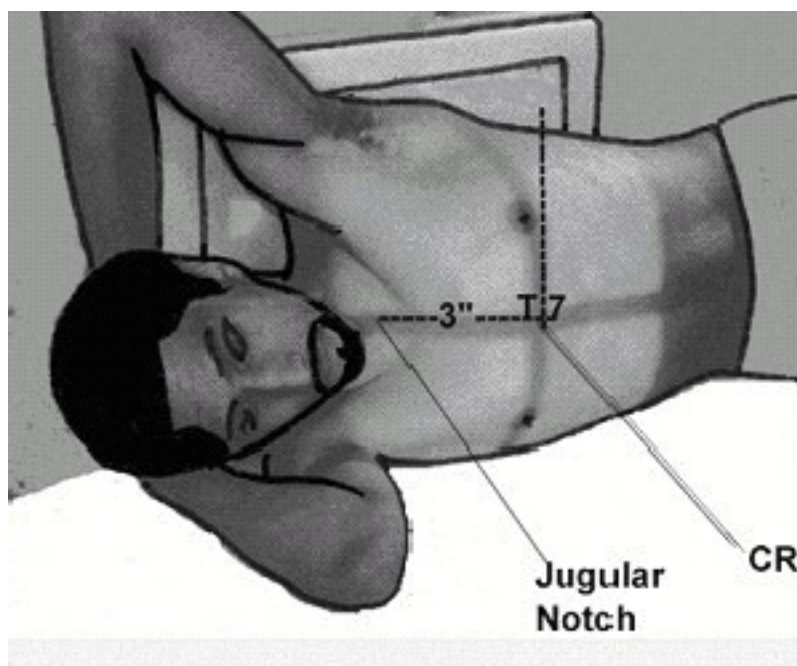
Film holder placement

For lateral decubitus chest radiographs, place a 14 x 17-inch (35 x 43-cm) film holder or IR behind the patient, either crosswise or lengthwise depending on their build. Adjust the IR so that it extends approximately 1 ½ - 2 inches (4-5 cm) beyond their shoulders. The source to image distance (SID) should be at a minimum of 72 inches (180 cm).

Central ray

The central ray (CR) is set horizontal and perpendicular to the center of the cassette. Using a horizontal beam is very important; otherwise air fluid levels or a pneumothorax (the primary goal of performing this projection) can be missed.

(Fig. 2)



*AP projection lateral decubitus position.
Image courtesy of Dr. Naveed Ahmad.*

Reprinted from *Merrill's Atlas of Radiographic Positions and Radiologic Procedures*, 9th edition, Ballinger and Frank, page 548 (figure 10-68), copyright 1999 Mosby, with permission from Elsevier Science.



Continued

For an AP projection lateral decubitus exposure, the jugular notch is used as a landmark. The CR should be directed 3-4 inches (8-10 cm) below the jugular notch that corresponds to the center of the lung fields at the T7 level (mid-thorax). For a PA projection lateral decubitus position, the CR should be directed 7-8 inches (18-20 cm) below the vertebra prominans at the level of the inferior angle of the patient's scapula.

Collimation

On each side of the posterior chest, the illuminated field margins should correspond to the outer skin margins of the patient. The upper border of the illuminated field should be above the patient's shoulders. This will result in a lower collimation border of 1-2 inches (3-5 cm) below the costophrenic angle, if the central ray was correctly centered. The collimation should be adequate to allow for some margin of error in both CR placement and lung expansion during deep inspiration.

Imaging technique

- Film size: 14 x 17 inches (35 x 43 cm)
- Exposure: 125 kVp
- mAs: 3
- cm: 21
- ML: 7
- Sk: 22

Evaluation criteria for a good lateral decubitus position (AP or PA projection)

1. The entire lung field from apices to the costophrenic angles should be clearly demonstrated.
2. No rotation -- the sternal ends of the clavicle should be at the same distance from the center line of the spine.
3. Arms should not superimpose upper lungs.
4. If the primary goal of the lateral decubitus projection is to demonstrate fluid in the pleural cavity (pleural effusion), the suspected side should be down and the affected side should be demonstrated in its entirety. Do not cut off that side of the chest in the image.
5. If the primary goal of the lateral decubitus projection is to demonstrate air in the pleural cavity (pneumothorax) the suspected side should be up and the affected side should be demonstrated in its entirety.



Continued

6. Appropriate markers to indicate which side is up (decubitus marker or arrow) should be placed on the film cassette.
7. Sharp radiographic outline -- the outline of the diaphragm and lung markings -- should be sharp. This can be accomplished by ensuring no motion or breathing is taking place at the time of exposure.
8. The vertebrae and ribs should be faintly visible through the heart shadow.

Chest x-ray oblique positioning techniques

Oblique projections are not ordered as frequently as a few years ago, because CT is more commonly employed whenever pathology is not clearly visualized on a standard chest x-ray.

However, oblique-view chest x-rays may be helpful and are requested for the following reasons:

- For separating a pulmonary or mediastinal mass or opacity from structures that overlie it on the PA and lateral views.
- For studying lesions that are visible in the PA view but not in the lateral view.
- For determining the site of origin of an intrathoracic lesion.
- Right anterior oblique (RAO) and left anterior oblique (LAO) positions are routinely used to study the esophagus in barium examinations.
- As an aid for the differential diagnosis of cardiac and great vessel enlargement.

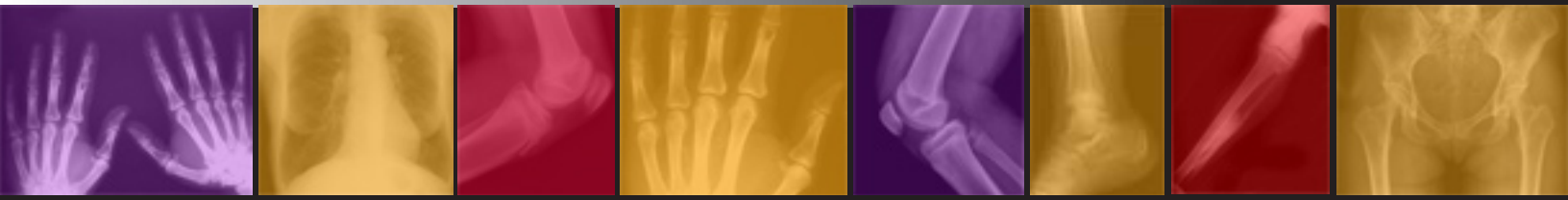
Patient preparation

Ask the patient to remove all clothing from the waist up, put on a hospital gown, remove any jewelry (necklace, earrings), and, if necessary, tie hair up on top of the head.

Patient position

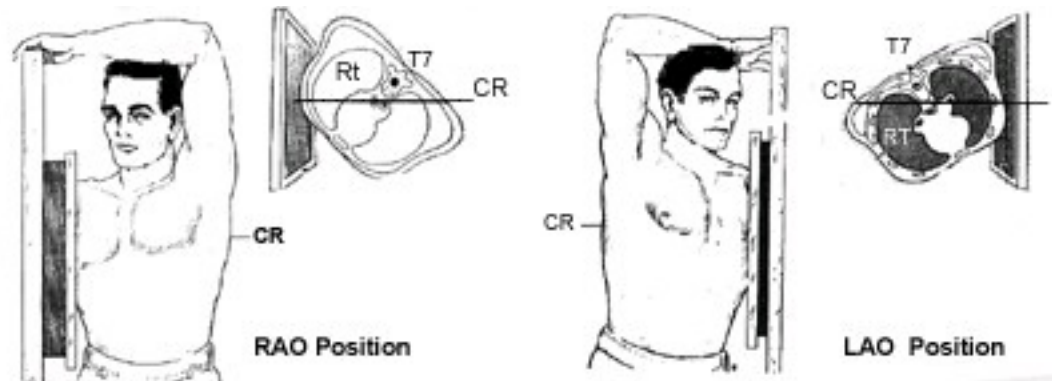
Anterior (PA) oblique projections are obtained with patient upright with respective side of the chest rotated 45 degrees against the IR. The patient's arm that is closest to the cassette should be flexed, with the hand resting on the hip. The patient's opposite arm should be raised as high as possible. The patient should be looking straight ahead, with the chin raised. Posterior oblique positions are only used when the patient is too ill to be turned to a prone position.

(see Fig. 3, next pg.)



Continued

(Fig. 3)



Anterior (PA) oblique projections -- the side of interest is the side furthest from the cassette. Image courtesy of Dr. Naveed Ahmad.

Chest position

Oblique positions are named according to the chest part closest to the cassette. For anterior (PA) oblique projections the side of interest is the side furthest from the cassette.

- RAO view -- This is obtained with the right front of the patient against the cassette. The patient is turned approximately 45 degrees toward the right side, placing the patient's right shoulder in contact with the grid device and left hand on their hip. This position demonstrates the maximum area of the left lung field.
- LAO view -- This is obtained with the left front of the patient against the cassette. The patient is turned approximately 45 degrees toward the left side, placing the patient's left shoulder in contact with the grid device and right hand on their hip. This position demonstrates the maximum area of the right lung field.
- Left posterior oblique (LPO) view -- This is obtained with the right back of the patient against the cassette. The patient is rotated 45 degrees with left posterior shoulder against the IR. It is comparable to an RAO view in demonstrating the maximum area of the left lung field.
- Right posterior oblique (RPO) view -- This is obtained with the left front of the patient against the cassette. The patient is rotated 45 degrees with right posterior shoulder against the IR. This position is comparable to an LAO view demonstrating the maximum area of the right lung field.

Place a lead shield between the x-ray tube and the patient's pelvis for gonadal protection. When the exposure is ready to be made, ask the patient to take two deep breaths. The exposure is made at the end of the second full inspiration to ensure maximum expansion of the lungs.



Continued

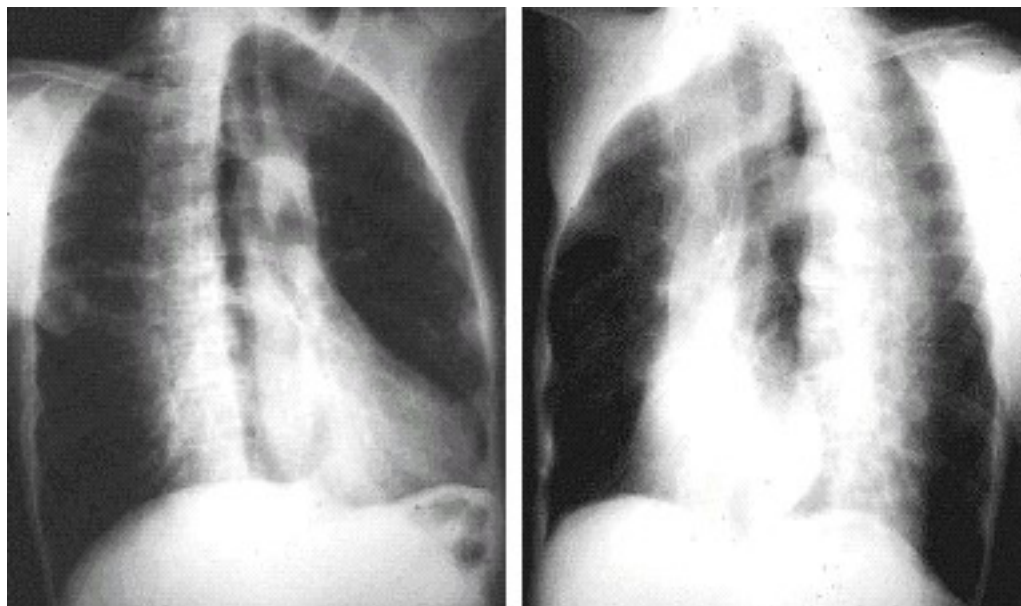
Central ray

The CR should be perpendicular to the center of the cassette at the level of T7.

Film holder placement

The cassette or IR should be 14 x 17 inches (35 x 43 cm) lengthwise. The SID should be at a minimum of 72 inches (180 cm).

(Fig. 4)



A right anterior oblique (right image) and left anterior oblique (left image) view demonstrate maximum area of the lung field. Image courtesy of Dr. Naveed Ahmad.

Evaluation criteria for a good oblique chest projection

- Both lungs, from the apices to the costophrenic angles, should be included.
- The maximum area of the right lung field should be demonstrated on an LAO and RPO view.
- The maximum area of the left lung field should be demonstrated on an RAO and LPO view.
- The distance from the outer margin of the ribs to the vertebral column on the side furthest from the IR should be approximately two times the distance of the side closest to the IR. This is to evaluate 45-degree rotation.
- The diaphragm and heart borders should be sharp with no motion.
- On an AP oblique projection, the heart and great vessels appear magnified.



Mastering AP and lateral positioning for chest x-ray

Mastering AP and lateral positioning for chest x-ray

By Dr. Naveed Ahmad

November 20, 2001

This article continues our series of white papers on radiologic patient positioning techniques that appear each month on AuntMinnie.com. The series will explore each of the major modalities. If you'd like to comment on or contribute to this series, please e-mail editorial@auntminnie.com.

Chest x-ray AP positioning techniques

Anteroposterior (AP) chest radiographs can be made in the intensive care unit, the operating suite, or the patient's room using mobile equipment. They are often known as a portable film when performed with a mobile unit. They are generally of lesser quality than a posteroanterior (PA) radiograph or recumbent films made in the radiology department. Hence, it is preferable to obtain a film in the radiology department unless the patient cannot be moved without hazard.

Patient preparation

Ask the patient to remove clothes from the waist up, put on a hospital gown, remove any jewelry (necklace, earrings), and, if necessary, tie hair up on top of the head.

Patient position considerations

Instruct the patient to lie supine or upright, with the back against the grid. If the patient's condition allows, raise the head end of the cart, as the semi-erect position will improve the anatomical details.

Positioning is difficult in a hospital bed, thus the patient's true position is often unknown, which causes difficulty in assessing pulmonary vascularity or the presence of pleural fluid. If a portable film must be done, an upright portable film is preferable to a supine film. The patient's position and the distance from the x-ray tube to the film should be recorded on the film cassette.

Position of chest

1. The midsagittal plane of the chest should be in the center of the cassette.
2. If the patient's condition allows, ask the patient to relax the shoulders and place hands on hips (to move the scapula away from the lung fields).
3. Place a lead shield between the x-ray tube and the patient's pelvis for gonadal protection.



Continued

- If the patient cooperates, instruct him or her to take a deep breath and then hold it to fully aerate the lungs. The patient should then take a second deep breath. (This allows for a deeper inspiration, as more air is inhaled during the second breath.) The exposure is made at the end of the second full inspiration to ensure maximum expansion of the lungs.

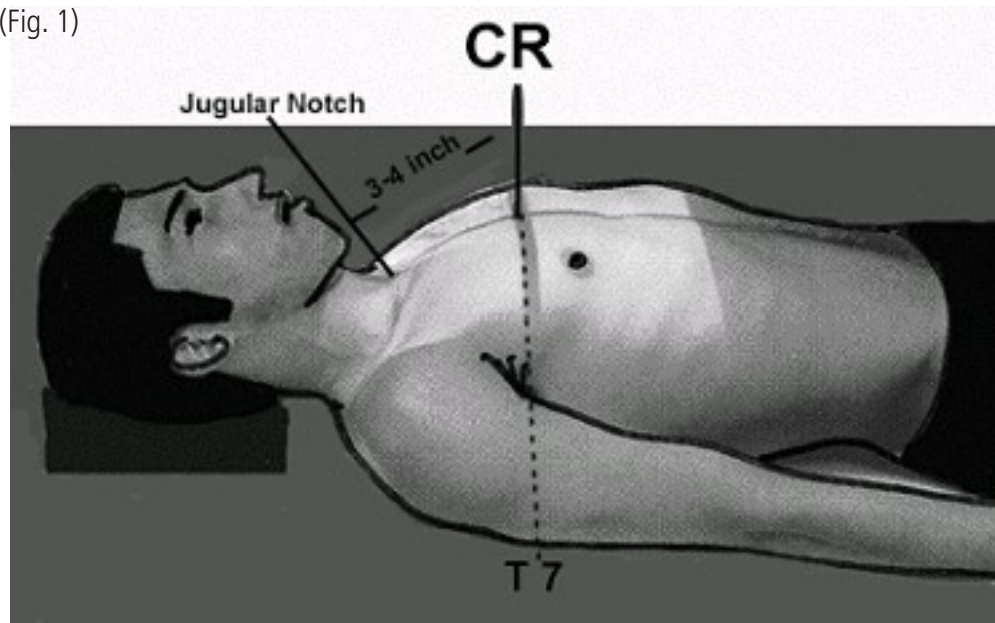
Film holder placement

For AP chest radiographs, the recommendation is to place the cassette film holder or image receptor (IR) crosswise, not lengthwise, using a 14 x 17-inch (35 x 43-cm) IR. Place the IR behind or underneath the patient. The lengthwise use of the IR can cut off the side borders of the lung fields. The cassette should be adjusted so that the upper border is approximately 1 1/2 to 2 inches (3.8-5 cm) above the shoulders.

Central ray

The central ray (CR) is set perpendicular to the long axis of the sternum and the center of the cassette. The jugular notch is the recommended landmark for the location of the CR for AP chest radiographs. The notch is used for locating the center of the lung fields at the T7 level (mid-thorax).

(Fig. 1)



For an AP chest radiograph, the landmark used for positioning the central ray (CR) is at T7 (mid-thorax). The level of T7 is 3-4 inches (8-10 cm) below the jugular notch. Image courtesy of Dr. Naveed Ahmad.

Reprinted from *Merrill's Atlas of Radiographic Positions and Radiologic Procedures*, 9th edition, Ballinger and Frank, page 58 (figure 10-52), copyright 1999 Mosby, with permission from Elsevier Science.



Continued

The T7 level on an average adult is 3-4 inches (8-10 cm) below the jugular notch. For older or thinly built patients it is 3 inches (8 cm) below the jugular notch, and for patients with athletic physiques it can be as much as 5 inches. This distance can be estimated by using your hand. The average-size hand, with fingers together, is approximately 3 inches. In patients with kyphosis, a slight cephalad angulation may be needed.

Collimation

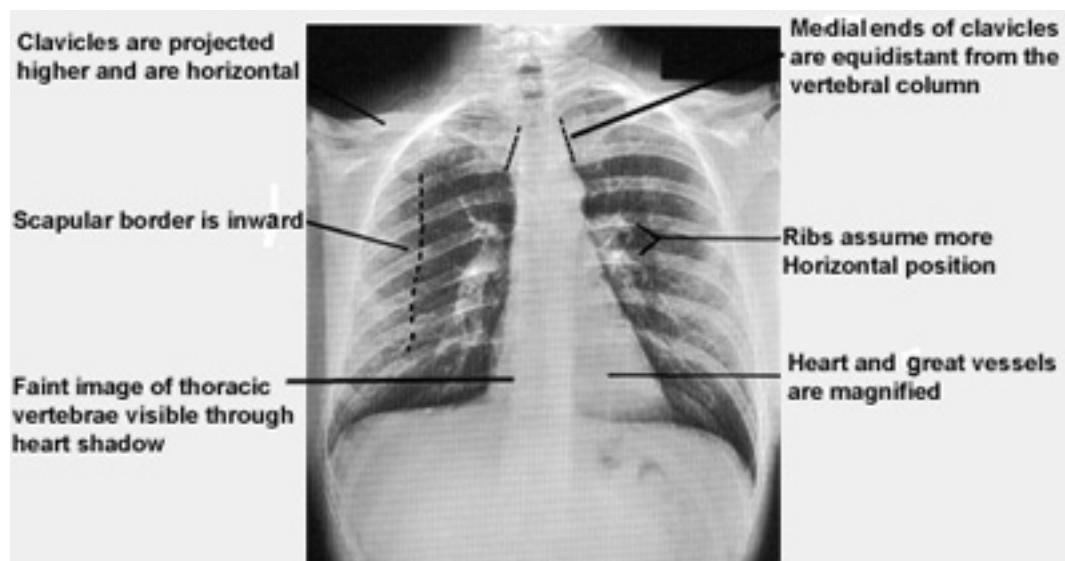
The upper border of the illuminated field should be above the shoulders and on each side. It should correspond to the outer skin margins.

Imaging technique

- Film size: 14 x 17 (35 x 43 cm) crosswise
- Exposure: 110-125 kVp range
- mAs: 1.7
- cm: 22
- ML : 2

Evaluation criteria for a good AP projection

(Fig. 2)





Continued

1. The entire lung fields from apices to the costophrenic angles should be clearly demonstrated.
2. No rotation -- the sternal ends of the clavicle should be at the same distance from the center line of the spine. However, in portable radiographs it is sometimes not achievable due to the condition of the patient.
3. The trachea should be visible in the midline.
4. The scapulae are usually projected in the lung fields.
5. Full inspiration is usually not achievable in ill patients; generally, only eight or nine ribs are visualized above the diaphragm.
6. Three posterior ribs should be seen above clavicles if the CR angle is correct.
7. Clavicles are projected higher and the ribs assume a more horizontal position.
8. The heart and great vessels appear magnified.
9. A faint image of the ribs and thoracic vertebrae should be visible through the heart shadow.
10. The outline of the heart and diaphragm should be sharp.

Chest x-ray lateral projection positioning techniques

A lateral chest projection is part of standard x-ray examination of the chest. Although the PA view is the mainstay of diagnosis, it provides a clear view of only about 80% of the lungs; the retrosternal and retrocardiac spaces as well as the posterior sulci are obscured by overlying anatomy. The lateral view clearly displays these areas and is especially useful in detecting lower-lobe lung disease, pleural effusions, and anterior mediastinal masses.

Patient Preparation

Ask the patient to remove clothes from the waist up, put on a hospital gown, remove any jewelry (necklace, earrings), and, if necessary, tie hair up on top of the head.

Patient position

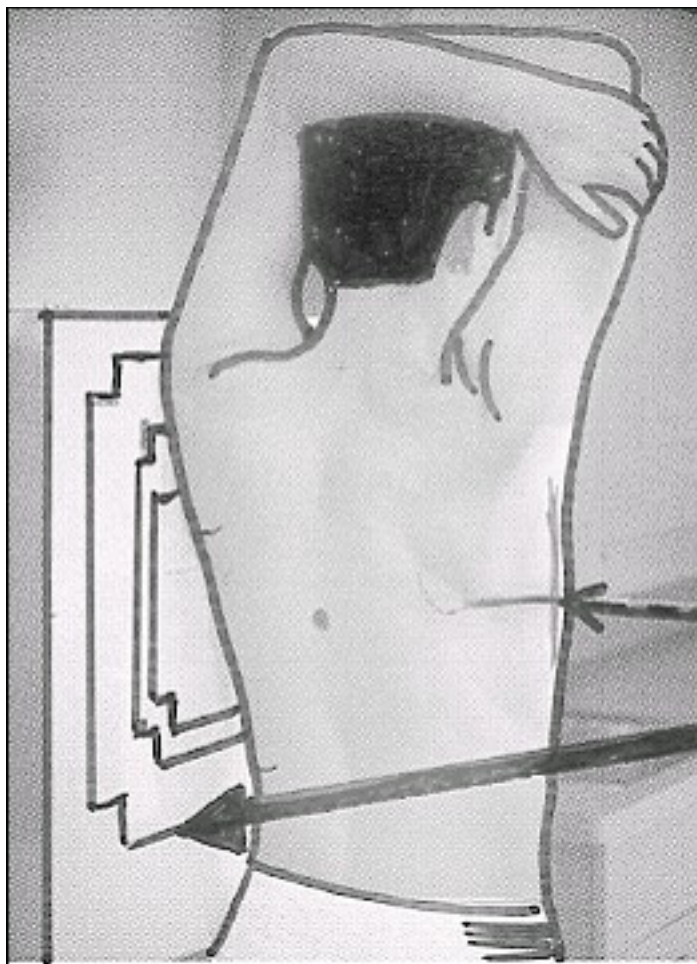
(see Fig. 3, next pg.)



Continued

(Fig. 3)

Patient position



Left lateral chest position. Image courtesy of Dr. Naveed Ahmad.

- Instruct the patient to sit erect or stand upright with their left side against the film cassette or image receptor (IR). A left lateral projection should be performed unless a right lateral projection is specifically requested by the physician. (The left lateral position is preferred because it permits better anatomical detail of the heart.)
- Make sure the patient is upright, with weight distributed evenly on both feet.
- Ask the patient to raise both arms above the head to prevent their superimposition on the chest field.
- Place a lead shield between the x-ray tube and the patient's pelvis for gonadal protection.



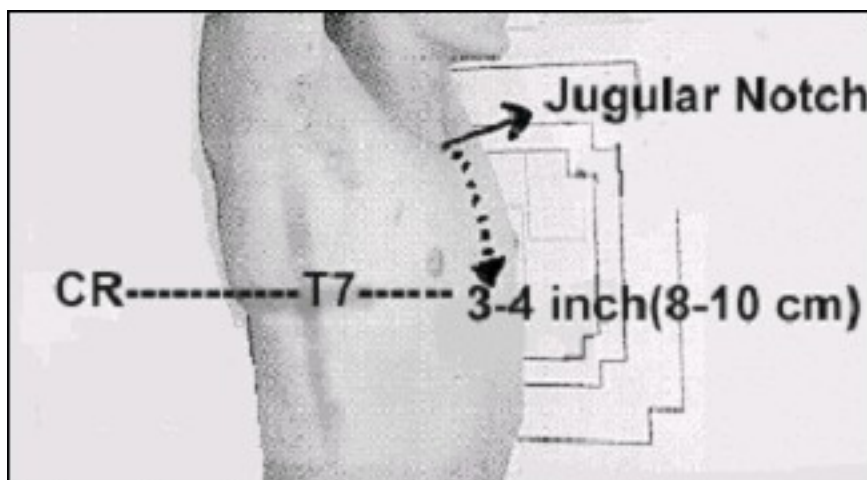
Continued

Chest position

- Adjust the patient so that the left shoulder is firmly against the film cassette, and the lower-left chest wall is no more than 1-2 inches away from the cassette. The goal is to have the midsagittal plane of the body vertical and parallel with the cassette.
- Make sure the patient is not leaning forward, backward, or sideways against the grid.
- Ask the patient to extend the neck, chin, and head upward and vertical.
- Ensure that there will be no rotation in the image by viewing the patient from the tube position.
- When you are ready for exposure, ask the patient to take a deep breath. The patient should then take a second deep breath. (This allows for a deeper inspiration, as more air is inhaled during the second breath than during the first breath.) The exposure is made at the end of the second full inspiration to ensure maximum expansion of lungs.

Central ray

(Fig. 4)



For a lateral projection chest radiograph, the landmark used for locating the center of lung fields is at T7 (mid-thorax). The level of T7 on an average adult is 3-4 inches (8-10 cm) below the jugular notch. Image courtesy of Dr. Naveed Ahmad.



Continued

For a lateral projection, the chest landmark used for locating the center of the lung fields is at the T7 level (mid-thorax). The T7 level on an average adult is 3-4 inches (8-10 cm) below the jugular notch. For patients with an athletic physique, T7 can be as much as 5 inches below the jugular notch. The chest landmark corresponds to the inferior angle of the scapula. The CR should be positioned perpendicular and midline to the film cassette.

Film holder placement

Place the film cassette holder (or IR) crosswise or lengthwise depending on the patient's physique, using a 14 x 17-inch (35 x 43-cm) IR. Place the IR against the left side of the patient. Adjust the height of the cassette so the upper border is 1 1/2 to 2-inches above the shoulder.

Collimation

The upper border of the illuminated field should be above the shoulders and on each side. It should correspond to the outer skin margins.

Imaging technique

- Film size: 14 x 17 inches (30 x 40 cm) crosswise or lengthwise, depending on the patient's physique
- Exposure: 110-125 kVp
- mAs: 6
- ML: 35
- cm: 30

Variations


- If the patient is in a wheelchair or cart, ask him or her to sit completely erect, if possible. Otherwise, raise the head end of the cart as much as patient's condition allows, and then place a pillow support behind patient's back.
- If the patient is unsteady, place an IV stand in front of them and ask them to grasp the stand as high as possible with both arms. This serves as not only support, but also helps to raise the arms.

(see Fig. 5, next pg.)



Continued

(Fig. 5)



In a lateral dorsal decubitus projection, the patient is adjusted in a true supine position with their arms above their head. If the side of pathology is specified, that side should be against the grid. Image courtesy of Dr. Naveed Ahmad.

Reprinted from *Merrill's Atlas of Radiographic Positions and Radiologic Procedures*, 9th edition, Ballinger and Frank, page 550 (figure 10-72), copyright 1999 Mosby, with permission from Elsevier Science.

Lateral Decubitus position (ventral or dorsal)

This position is also called cross-table lateral chest. It is usually requested for patients who are unable to sit or stand upright, and is also helpful to demonstrate air-fluid levels in case of pathology. The patient is adjusted in the true prone or supine position with arms extended above the head. If the side of the pathology is specified, then the affected side should be against the grid.

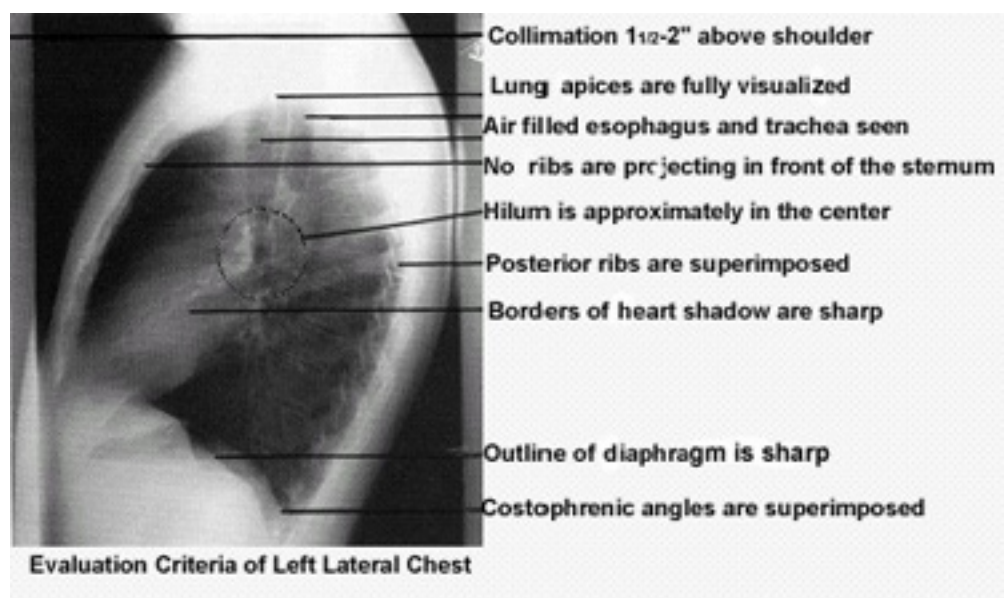
Evaluation criteria for a good lateral chest projection

(see Fig. 6, next pg.)



Continued

(Fig. 6)



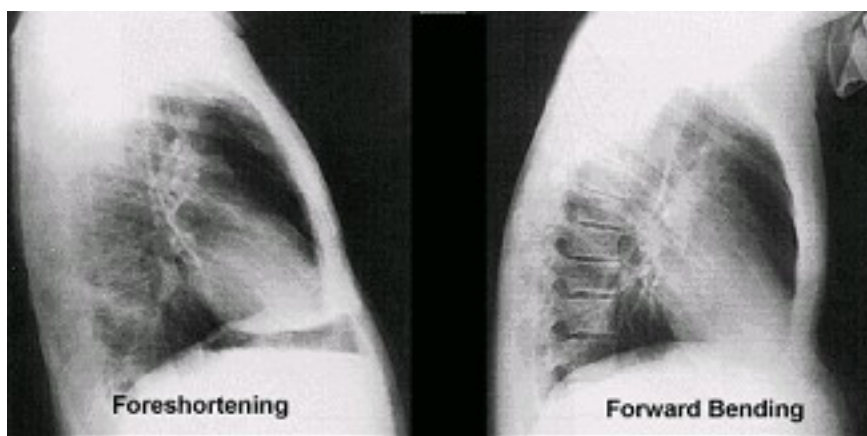
1. All of the lung fields, from apices to the costophrenic angles, should be fully visualized.
2. The arms should not be superimposed over portions of the lung fields.
3. Sharp radiographic outline -- the outline of the diaphragm and lung markings -- should be sharp. This can be accomplished by ensuring no motion or breathing is taking place at the time of exposure.
4. No rotation (true lateral projection). The ribs should be superimposed posterior to the vertebral column without any separation of the right and left posterior ribs and both costophrenic angles. However, in broad-shouldered patients, separation of the posterior ribs by 1 cm, because of the divergence of the x-ray beam, is unavoidable. Moreover, the lateral aspect of the sternum forms the anterior border, and no ribs should be projecting in front of the sternum.

(see Fig. 7, next pg.)



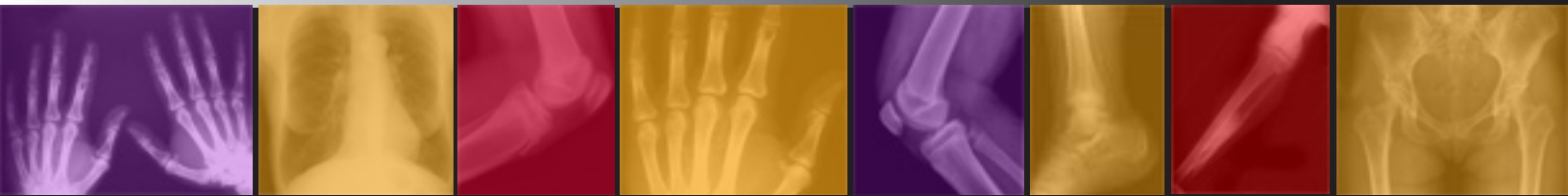Continued

(Fig. 7)



If the patient is leaning against the grid device (foreshortening) or forward bending, there is distortion of all thoracic structures. Image courtesy of Dr. Naveed Ahmad.

5. No tilt -- thoracic intervertebral spaces and intervertebral foramina should be open, except in patients with thoracic deformities. Tilt, if present, may be evident of closed disk spaces of the thoracic vertebra.
6. Hilum should be approximately in the center of the radiograph.



Good positioning is key to PA chest x-ray exams

Good positioning is key to PA chest x-ray exams

By Dr. Naveed Ahmad

October 19, 2001

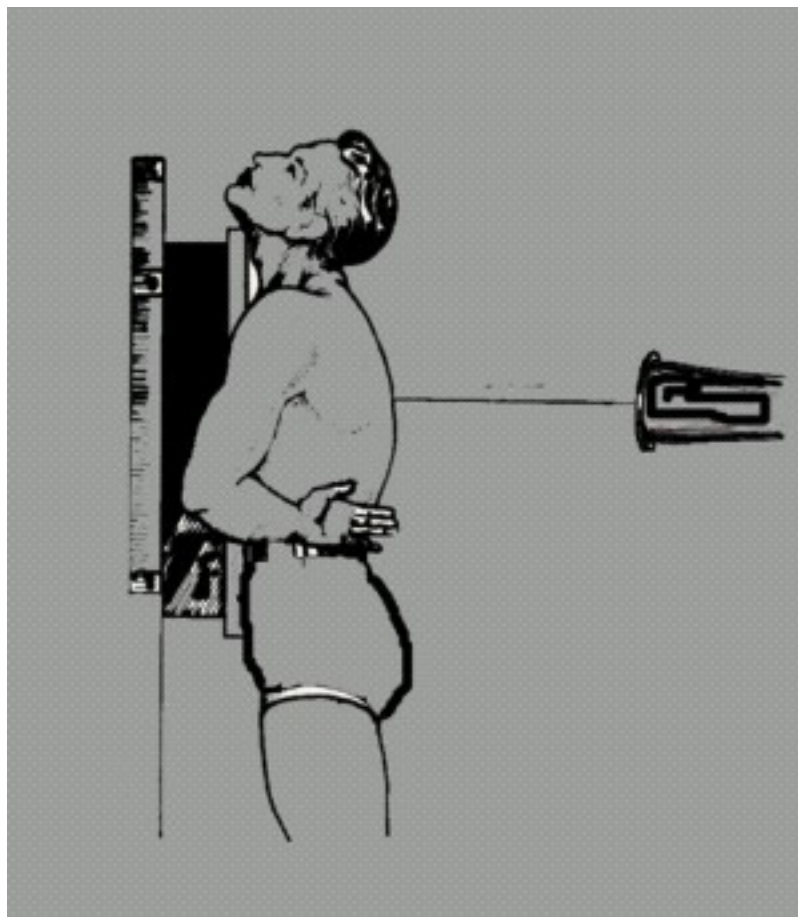
This article inaugurates a series of white papers on radiologic patient positioning techniques that will appear each month on AuntMinnie.com. The series will explore each of the major modalities. If you'd like to offer your comments or contribute an article, please e-mail editorial@auntminnie.com with your thoughts and suggestions.

Patient preparation

Ask the patient to remove clothes from the waist up, put on a hospital gown, remove any jewelry (necklace, earrings), and, if necessary, tie hair up on top of the head.

For posteroanterior (PA) projections, instruct the patient to sit or stand upright. Patients are positioned to face the film-screen cassette in order to minimize magnification of the anteriorly positioned heart and consequent obscuration of the lungs. Make sure the patient is standing straight and is equally distributing the weight of the body on both feet.

(Fig. 1)



(Fig. 1)

Postero anterior (PA) chest projection position, patient against chest board. Image courtesy of Dr. Naveed Ahmad.



Continued

The upright position is preferred for the following reasons:

1. It prevents engorgement (an excess of blood) of pulmonary vessels, whereas supine or recumbent positioning tends to increase engorgement of pulmonary vessels, which can change the radiographic appearance of these vessels and the lungs.
2. It allows full expansion of the lungs. In the recumbent position, full expansion of the lungs is prevented.
3. The upright position is very important in order to visualize possible air and fluid levels in the chest. In the upright position, fluid will locate near the base of the lung while the air will rise. In the recumbent position, fluid will spread out over the posterior surface of the lung, resulting in a hazy appearance of the entire lung.
4. An upright chest film is preferred over an upright abdominal film for the diagnosis of pneumoperitoneum (free air in the abdominal cavity).

Ask the patient to move the shoulders forward and downward, so that the chest wall and both shoulders are in contact with the cassette. This helps to carry the clavicles below the lung apices.

Adjust the height of the cassette so that its upper border is about 2 inches above the shoulders so that the lung apices are not cut off.

Ask the patient to extend the neck, chin, and head upward and vertical. The neck and chin otherwise tend to superimpose the trachea and uppermost lung regions.

The patient's arms are placed overhead or on their hips with elbows angled anteriorly. This will rotate the scapulae off the chest, thereby preventing their superimposition over the lungs.

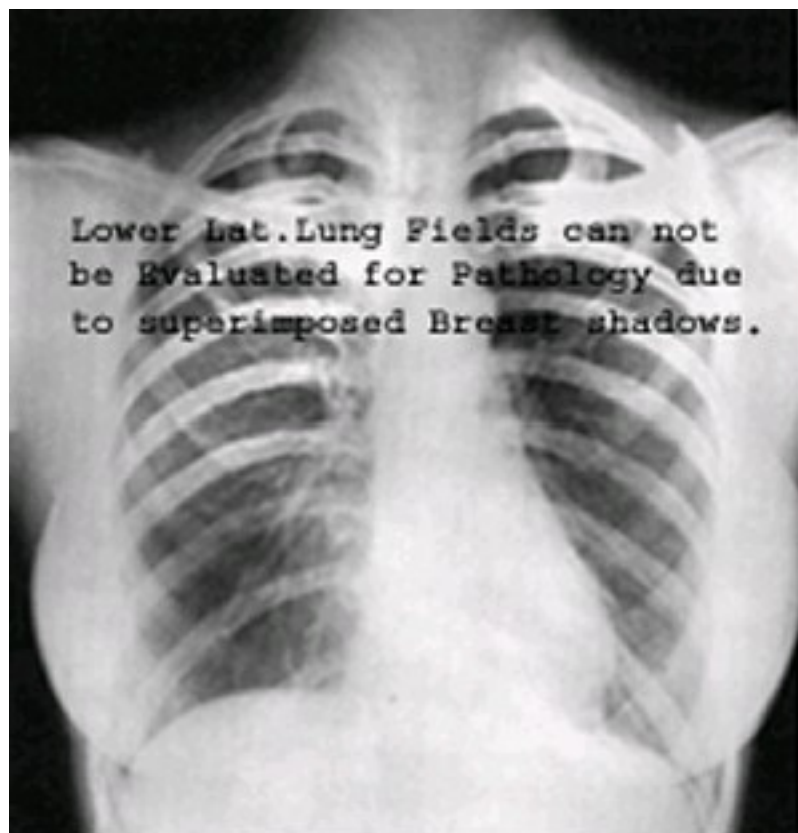
In female patients with large pendulous breasts, it is very important to minimize breast shadows. In some patients, depending on the density and size of breasts, breast shadows cannot be totally eliminated. Breast shadows render the examination suboptimal by superimposing over the lower part of the lung fields and obscuring any pathology. Ask the patient to pull the breasts upward and laterally (outwards), then remove her hands as she leans against the cassette holder to keep them in position.

(see Fig. 2, next pg.)



Continued

(Fig. 2)



Breast shadows over lower lung fields. Image courtesy of Dr. Naveed Ahmad.

Place a lead shield between the x-ray tube and the patient's pelvis. Gonadal shielding from the level of the iliac crests, or slightly higher, to the mid-thigh area should be used on all patients of reproductive age.

Rotation

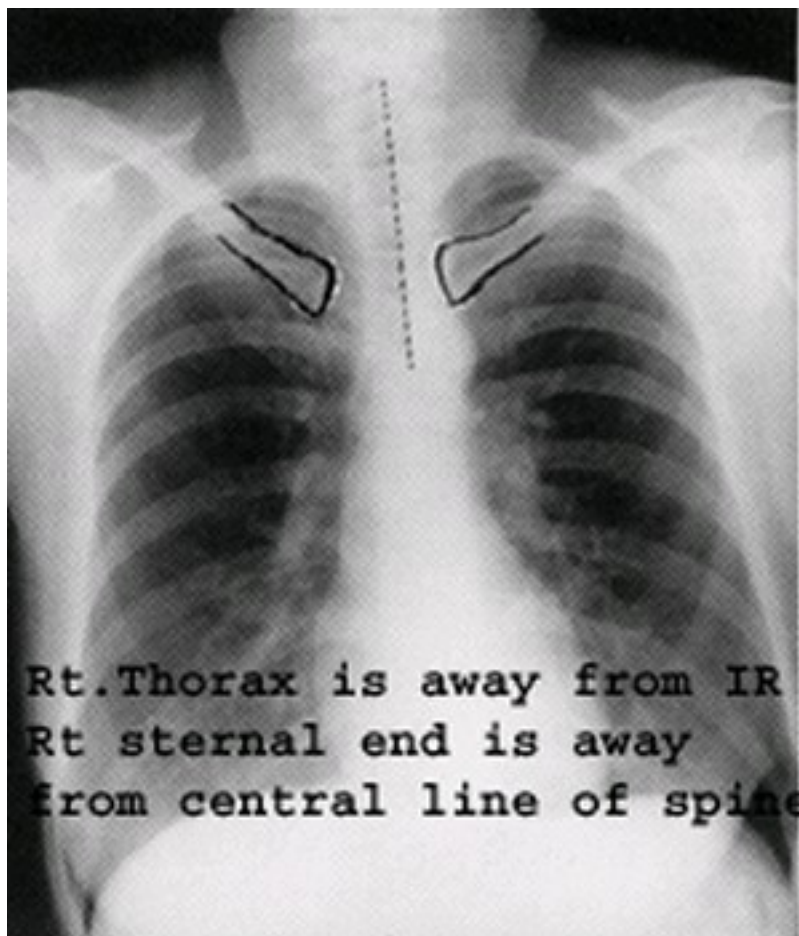
Even a small degree of rotation distorts the mediastinal borders, and the lung nearest the film will appear less translucent. The following points should be stressed to obtain a true PA view (without rotation):

(see Fig. 3, next pg.)



Continued

(Fig. 3)



PA view with rotation. Image courtesy of Dr. Naveed Ahmad.

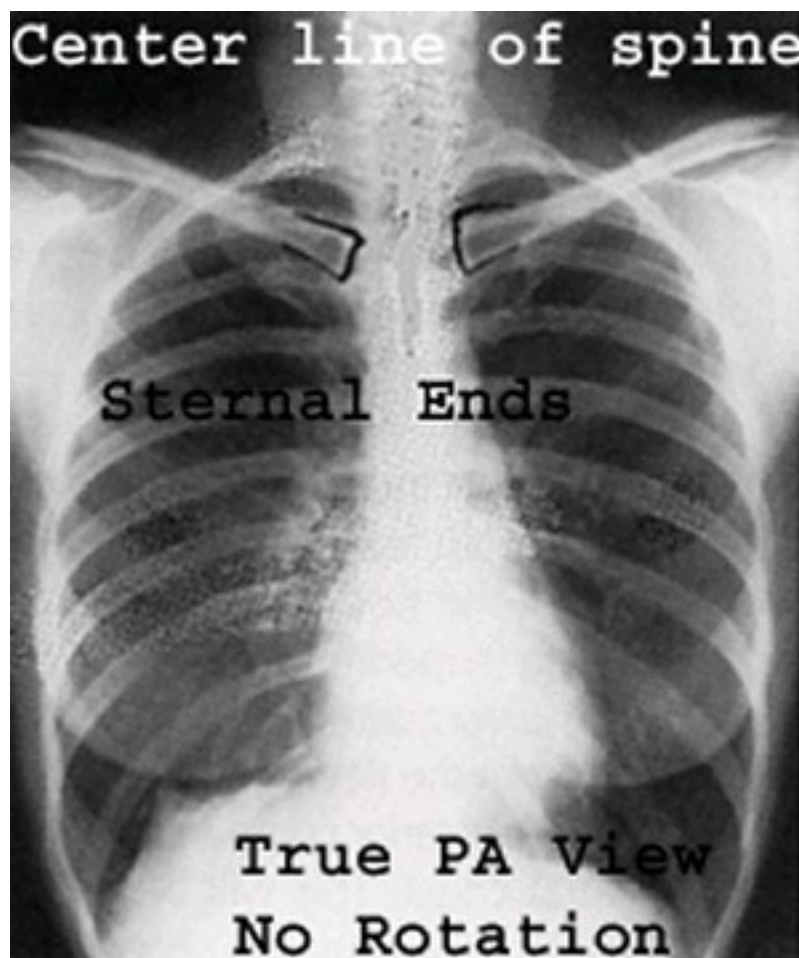
1. Ensure that the patient is standing evenly on both feet.
2. Both shoulders should be rolled forward and downward.
3. The chest radiograph should be well centered so that the medial ends of the clavicle are equidistant from the vertebral spinous processes at T4/5 . However, scoliosis and other thoracic deformities negate the value of conventional centering.

(see Fig. 4, next pg.)



Continued

(Fig. 4)



PA view without rotation. Image courtesy of Dr. Naveed Ahmad.

Central ray

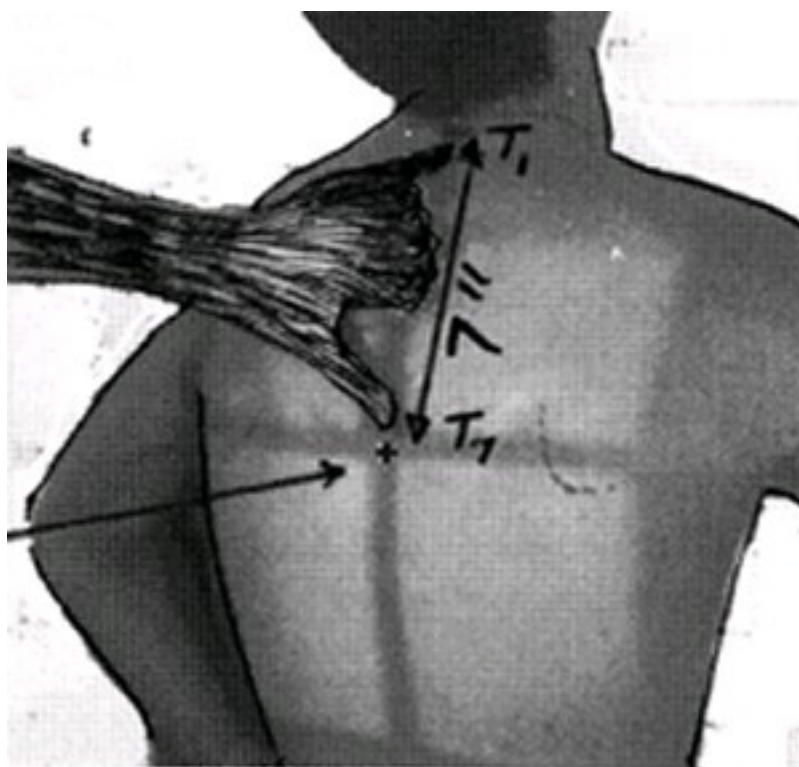
For PA, the chest landmark that is used for locating the center of the lung fields is the vertebra prominans (T1). It corresponds to the apical regions of both lungs. The vertebra prominans can be palpated at the base of the neck. The hand-spread method can be used to locate the central ray. To use this method, the technologist should know his or her own hand-spread width (most hands can reach 7 inches).

(see Fig. 5, next pg.)



Continued

(Fig. 5)



Hand-spread method for central ray positioning utilizing the vertebra prominans. Image courtesy Dr. Naveed Ahmad.

For the average adult, the central ray should be directed to the spinal column (mid-sagittal plane) approximately 7 inches (18 cm) for a female and 8 inches (20 cm) for a male down from the vertebra prominans. This corresponds to the level of T7 and the inferior angle of scapula, a source to image receptor (SID) distance of 72 inches (180 cm). Hypersthenic body types require only 7 inches down from the vertebra prominans, whereas athletic sthenic/hyposthenic types will require 9 inches down from the vertebra prominans.

Film holder (image receptor) placement

The horizontal dimension of an average chest is greater than the vertical dimension. This requires that a 14 x 17-inch film holder or image receptor (IR) be placed crosswise. However, depending on the body type, the most common practice is placing the film holder or IR lengthwise. Either lengthwise or crosswise, the goal is to adequately include the lateral lung margins.



Continued

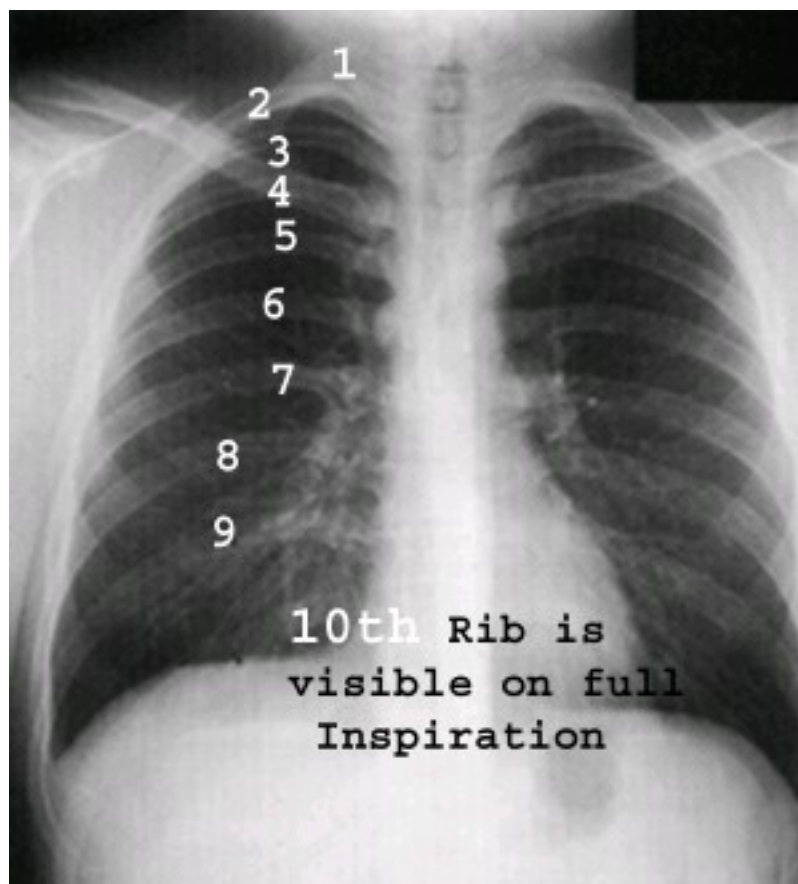
Collimation

Collimation should be adequate to allow for some margin of error in central ray placement and lung expansion during deep inspiration. On each side of the posterior chest the illuminated field margins should correspond to the outer skin margins. The upper border of the illuminated field should be at the level of vertebra prominans (4 cm above the apex of lungs). This will result in a lower collimation border of 1-2 inches below the costophrenic angle, if the central ray was correctly centered.

Respiration

Be sure to make the exposure upon a second full inspiration by the patient. The patient should take as deep a breath as possible, and then hold it to fully aerate the lungs. Taking a second deep breath before holding it allows for a deeper inspiration, as more air is inhaled during the second breath than during the first breath.

(Fig. 6)



PA view on full inspiration. Image courtesy of Dr. Naveed Ahmad.



Continued

The best way to determine the degree of inspiration is to start at the top of the patient's rib cage, with rib number one, and count down to the tenth or eleventh rib posteriorly. A general rule for average adult patients is to show a minimum of 10 ribs on a good PA chest radiograph. Older patients have less inhalation capability, with a resulting low lung volume, which requires a higher central ray location.

Evaluation criteria for a good PA projection

1. Entire lung fields from apices to costophrenic angles should be clearly demonstrated.
2. No rotation. Rotation on a PA chest radiograph can be determined by examining both sternal ends of the clavicles for a symmetric appearance in relationship to the spine. On a true PA chest without any rotation, both the right and left sternal ends of the clavicle will be the same distance from the center line of the spine. The direction of rotation can be determined by which sternal end of the clavicle is closest to the spine.
3. Trachea is visible in midline.
4. Scapula projected outside the lung fields.
5. Ten posterior ribs are visible above the diaphragm.
6. There is a sharp outline of the heart and diaphragm.
7. A faint shadow of the ribs and superior thoracic vertebrae is visible through the heart shadow.
8. Lung markings are visible from the hilum to the periphery of the lung.

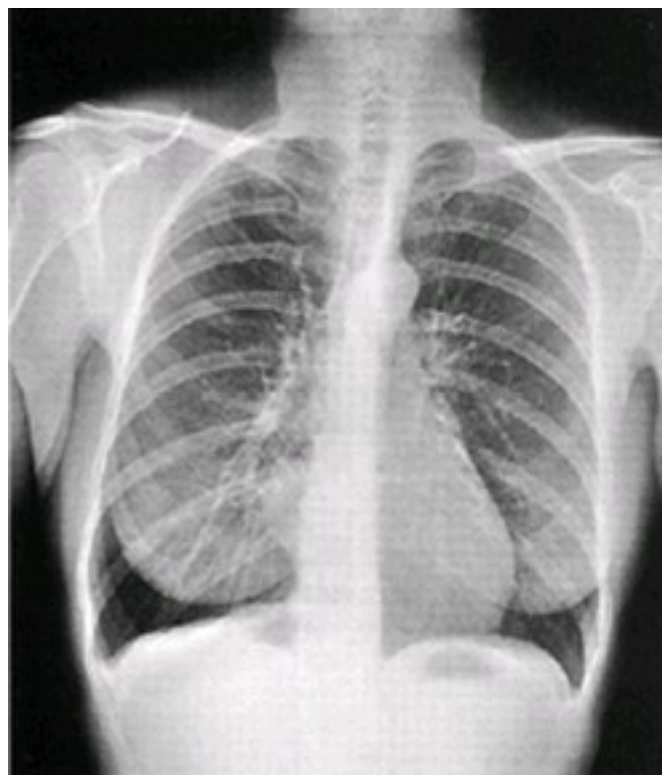
(see Fig. 7, next pg.)



Continued

- Trachea visible in midline
- No rotation -- sternal ends of the clavicles are equidistant from central line
- Scapula projected outside the lung fields
- Entire lung fields from apices to costophrenic angles should be clearly demonstrated
- Faint shadow of the ribs and thoracic vertebrae visible through the heart shadow
- Lung markings visible from the hilum to the periphery of the lung
- Sharp outline of heart and diaphragm
- Ten posterior ribs visible above the diaphragm

(Fig. 7)



Evaluation criteria for a good PA projection. Image courtesy of Dr. Naveed Ahmad.

Variations

An expiratory film may be helpful under some circumstances. A small pneumothorax (air in the pleural cavity) may be difficult to detect on a routine inspiratory PA film. On expiration, the volume of the thorax and lungs is reduced but the amount of air in the pleural space remains essentially unchanged. The pneumothorax then occupies a larger percentage of the area of the thorax and is more easily visible.

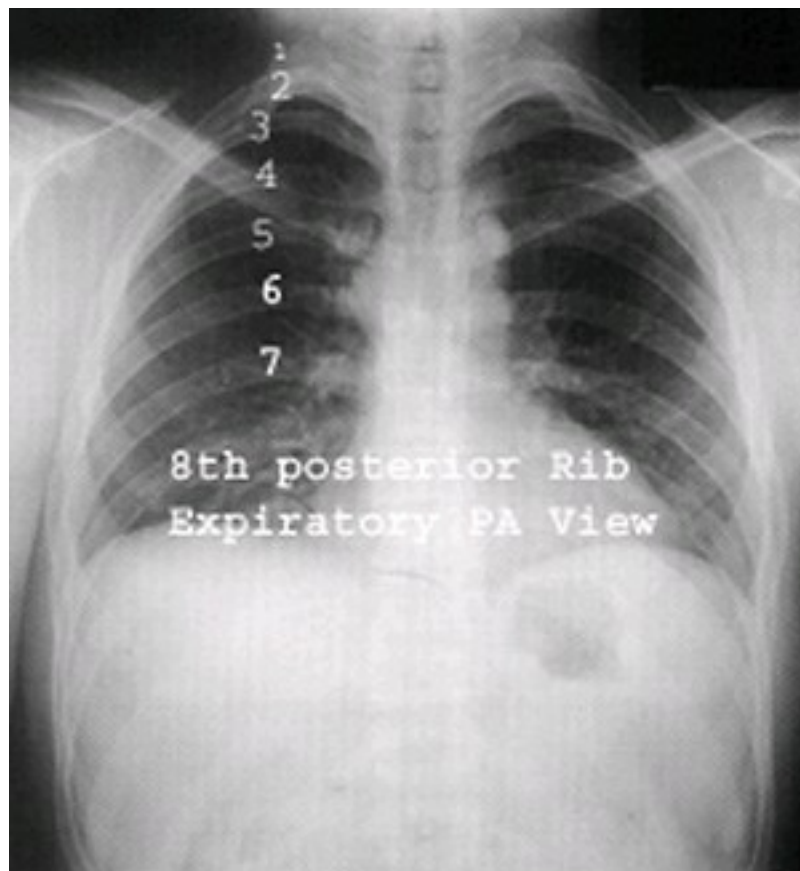
Another indication for an expiratory film is to demonstrate air trapping. The bronchi increase in diameter with inspiration, and decrease with expiration. With a foreign body or tumor in a main bronchus, a valve action may occur, with air bypassing the obstruction on inspiration and becoming trapped on expiration.



Continued

Expiration PA view.
Image courtesy of Dr. Naveed Ahmad.

(Fig. 8)



With expiration, the normal lung is reduced in volume and becomes more radiopaque. The obstructed portion of the lung retains its air, thereby retaining its radiolucency and forcing the mediastinum to shift toward the contralateral side. If a patient has a unilateral respiratory wheeze, air trapping is likely, and an expiratory film may be helpful.

Imaging Technique

- Film size: 14 x 17 inches (35 x 43 cm) lengthwise or crosswise
- Exposure: 110 - 125 kVp range
- mAs: 3
- Sk: 17
- ML: 5
- cm: 22
- Focal Spot: small (large for obese patients)
- Bucky: yes (under the table)
- Film speed: 200