TRY OUT KULIT DAN KELAMIN

dr. Agustina Tri P. Sp.KK

Daftar Pustaka

- Fitzpatrick's Dermatology, Ninth Edition
- Panduan Praktik Klinik PERDOSKI thn 2017
- Holmes’s Sexually Transmitted Disease, Fourth Edition

1. Seorang laki-laki 22 tahun datang ke puskesmas dengan keluhan kulit berwarna kemerahan pada tubuhnya disertai gatal-gatal pada pemeriksaan dermatologik ditemukan herald patch. Diagnosa penyakit ini adalah

A. Lepra TB

B. Dermatitis seboroik

C. Kusta

D. Pitiriasis rosea

E. Pitiriasis versikolor

Pitiriasis Rosea

- Pitiriasis rosea adalah suatu kelainan kulit akut yang diawali dengan timbulnya makula/plak soliter berwarna merah muda dengan skuama halus (*"herald patch"),* kemudian dalam beberapa hari sampai beberapa minggu timbul lesi serupa dengan ukuran lebih kecil di badan dan ekstremitas proksimal yang tersusun sesuai lipatan kulit (*christmas tree pattern).*

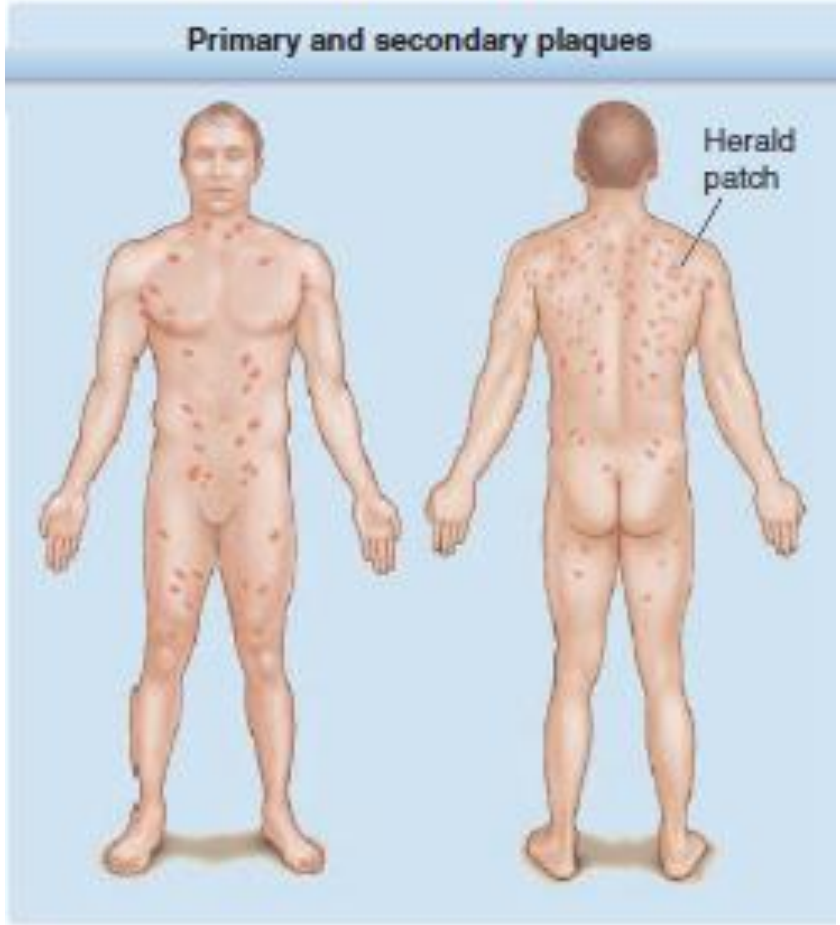
Primary and secondary plaques
Herald patch

Klinis

Anamnesis

- Terutama timbul pada remaja dan dewasa muda yang sehat, kelompok usia 10-35 tahun
- Lebih banyak dialami oleh perempuan
- Gejala subjektif biasanya tidak ditemukan, tetapi dapat disertai gatal ringan maupun sedang
- Kelainan kulit diawali dengan lesi primer yang diikuti lesi sekunder
- Timbul lesi sekunder bervariasi antara 2 hari sampai 2 bulan setelah lesi primer, tetapi umumnya dalam waktu 2 minggu
- Kadang-kadang lesi primer dan sekunder timbul secara bersamaan
- Dapat pula ditemukan demam yang tidak terlalu tinggi atau lemah badan

- Makula/plak sewama kulit/merah muda/*salmon-colored*/hiperpigmentasi yang berbatas tegas, umumnya berdiameter 2-4 cm, berbentuk lonjong atau bulat di bagian badan yang tertutup baju (lesi primer).
- Lesi sekunder berupa makula/plak merah muda, multipel, berukuran lebih kecil dari lesi primer, berbentuk bulat atau lonjong, yang mengikuti *Langer lines* sehingga pada punggung membentuk gambaran *Christmas-tree pattern*.
- Bagian tengah lesi memiliki karakteristik skuama halus membentuk gambaran skuama kolaret.

↓

Singkirkan diagnosis banding dengan:
- Anamnesis
- Pemeriksaan fisik
- Bila meragukan: pemeriksaan laboratorium sesuai diagnosis banding dan histopatologis

↓

Diagnosis:
PITIRISIS ROSEA

↓

1. Prinsip:
   Tidak diperlukan terapi spesifik karena penyakit dapat sembuh spontan.

2. Topikal
   Bila gatal sangat mengganggu:
   - Larutan anti pruritus
   - Kortikosteroid topikal potensi sedang

3. Sistemik:
   - Apabila gatal sangat mengganggu: Antihistamin
   - Eritromisin per oral
   - Asiklovir per oral bila disertai *flu-like symptoms* atau keterlibatan kulit yang luas.
   - Dapat pula dilakukan fototerapi: *narrowband ultraviolet* B (NB-UVB)

↓

Edukasi:
- Kelainan kulit dapat sembuh sendiri.
- Pengobatan bertujuan untuk mengurangi gejala.

2. Seorang perempuan 30 tahun datang dengan keluhan kulit bersisik disertai rasa gatal di daerah alis, sekitar mulut dan liang telinga sudah 5 hari. Pasien juga mengeluhkan sering berketombe. Pada pemeriksaan tampak skuama kuning berminyak dengan dasar kulit eritem. Pengobatan simtomatik topikal untuk pasien tersebut berupa imunosupresan adalah:

a. Kalsipotriol

b. Metronidazol

c. Pimekrolimus

d. Litium suksinat

e. Benzoil peroksida

Dermatitis Seboroik

- Dermatitis seboroik (DS) adalah kelainan kulit papuloskuamosa kronis yang umum dijumpai pada anak dan dewasa
- Penyakit ini ditemukan pada area kulit yang memiliki banyak kelenjar sebasea seperti wajah, kulit kepala, telinga, tubuh bagian atas dan fleksura (inguinal, inframammae, dan aksila

Klinis

Anamnesis

- Pada bayi biasanya terjadi pada 3 bulan pertama kehidupan
- Sering disebut *cradle cap*
- Keluhan utama biasanya berupa sisik kekuningan yang berminyak dan umumnya tidak gatal
- Pada anak dan dewasa, biasanya yang menjadi keluhan utama adalah kemerahan dan sisik di kulit kepala, lipatan nasolabial, alis mata, area post aurikula, dahi dan dada
- Lesi lebih jarang ditemukan di area umbilikus, interskapula, perineum dan anogenital
- Area kulit yang kemerahan biasanya gatal
- Pasien juga dapat mengeluhkan ketombe (Pitiriasis sika)
- Keluhan dapat memburuk jika terdapat stressor atau cuaca dingin
- Pada bayi umumnya bersifat swasirna sementara cenderung menjadi kronis pada dewasa

Pemeriksaan Fisik

- Pada bayi, dapat ditemukan skuama kekuningan atau putih yang berminyak dan tidak gatal
- Skuama biasanya terbatas pada batas kulit kepala (skalp) dan dapat pula ditemukan di belakang telinga dan area alis mata
- Lesi lebih jarang ditemukan di lipatan fleksura, area popok dan wajah
- Pada anak dan dewasa dapat bervariasi mulai dari:
- Ketombe dengan skuama halus atau difus, tebal dan menempel pada kulit kepala
- Lesi eksematoid berupa plak eritematosa superfisial dengan skuama terutama di kulit kepala, wajah dan tubuh
- Di dada dapat pula menunjukkan lesi petaloid atau pitiriasiformis
- Apabila terdapat di kelopak mata, dapat disertai dengan blefaritis
- Dapat meluas hingga menjadi eritroderma

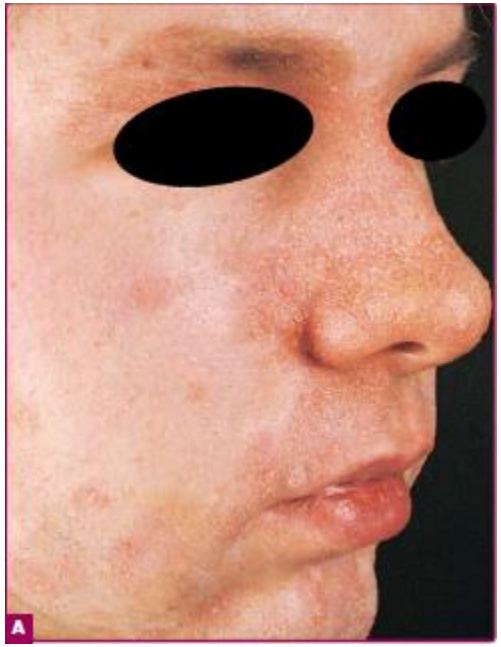
A

PENATALAKSANAAN

1. Daerah non skalp

- Ringan

o Antijamur topikal: krim ciclopirox 1%, krim ketokonazol 2% 2 kali sehari selama 4 minggu

o AIAFp: krim piroctone olamine/alglycera/bisabolol 2 kali sehari selama 4 minggu

o Kortikosteroid topikal kelas I: krim atau salep hidrokortison 1% 2 kali sehari selama 4 minggu

o Inhibitor kalsineurin topikal: krim pimekrolimus 1%5-6,10-11 (A,1), salep takrolimus 0,1% 2 kali sehari selama 4 minggu

- Sedang/berat

o Kortikosteroid topikal kelas II: krim desonide 0,05%, salep aclometasone 0,05% 2 kali sehari selama 4 minggu

o Antijamur sistemik:

- Itrakonazol 200 mg/hari selama 1 minggu kemudian 200 mg/hari selama 2 hari/bulan selama 11 bulan

- Terbinafin 250 mg/hari selama 4-6 minggu (regimen kontinu) atau 250 mg/hari selama 12 hari/bulan untuk 3 bulan (regimen intermiten)

Urutan pilihan terapi

o Lini pertama

- Ketokonazol topikal
- Kortikosteroid topikal potensi ringan-sedang
- AIAFp topikal

o Lini kedua

- Lithium succinate/lithium gluconate topikal
- Krim ciclopirox
- Inhibitor kalsineurin topikaL

o Lini ketiga

- Terbinafin oral
- Itrakonazol oral
- Gel metronidazol
- Krim non steroid
- Terbinafin topikal
- Benzoil peroksida
- Fototerapi

MANAGEMENT

Basically, using emollients (eg, mineral oil, vegetable oil, or petroleum jelly) can help improve symptoms such as scales. Soft rubbing with a brush or comb aids removing thick, adherent scales, but aggressive scraping should be avoided because it can induce further inflammation. The main recommendations for the first-line treatment of SD are topical medications, including corticosteroids, calcineurin inhibitors, antifungal drugs, and keratolytics. In the case of topical corticosteroids, mild-potency formulations are recommended to be used first because of their cutaneous adverse effects and frequent rebound phenomena. Treatment with corticosteroids is highly effective for reducing erythema, scaling, and pruritus rapidly, resulting in total clearance more often than placebo.[40] Topical calcineurin inhibitors (tacrolimus and pimecrolimus) manifest good effects on SD by blocking calcineurin, thus preventing both inflammatory cytokines and a signaling pathway in T-lymphocyte cells. No difference between topical calcineurin inhibitors and topical corticosteroids in total clearance was identified in short-term trials.[40] There is no risk of telangiectasia and skin atrophy, so topical calcineurin inhibitors are recommended

3. Laki-laki 33 tahun datang ke poli kulit dengan keluhan muncul bercak-bercakmerah pada lutut, siku, kepala, punggung sejak 4 bulan yang lalu. Pada pemeriksaan dermatologis didapatkan plakat eritematosa diskret berukuran lentikuler sampai plakat ditutup oleh skuama tebal dan berlapis-lapis. Diagnosis?

A. Dermatitis atopik
B. Psoriasis vulgaris
C. Pityriasis rosea
D. Tinea korporis
E. Liken planus

PSORIASIS VULGARIS

- Penyakit keradangan kulit yang kronik dan residif, mempunyai dasar genetik, dengan karakteristik gangguan pertumbuhan dan diferensiasi epidermis
- Keluhan biasanya berupa bercak merah bersisik mengenai bagian tubuh terutama daerah ekstensor dan kulit kepala
- Dapat pula dijumpai keluhan berupa nyeri sendi, bercak merah disertai dengan nanah, dan bercak merah bersisik seluruh tubuh
- Infeksi, obat-obatan, stres, dan merokok dapat mencetuskan kekambuhan atau memperburuk penyakit. Sering disertai sindrom metabolik
- Bisa ditemukan riwayat fenomena Koebner

Psoriasis Tipe Plak

- Bentuk psoriasis yang paling banyak
- Plak eritematosa berbatas tegas dengan skuama berwarna keperakan adalah karakteristik tetapi tidak harus ada
- Daerah yang terkena biasanya: siku, lutut, kepala, celah intergluteal, palmar dan plantar
- Kadang-kadang genitalia juga terkena

4. Seorang wanita usia 25 tahun datang mengeluh bercak hitam di wajahnya sejak 2 bulan yang lalu dan dirasakan semakin lebar. Bercak awalnya berwarna coklat muda semakin hari menjadi lebih gelap. Pekerjaan sebagai sales yang sering menawarkan jualan saat siang hari. Tidak pernah memakai sunblok. Pada pemeriksaan fisik tampak single makula hiperpigmentasi batas tegas et regio facialis. Apakah diagnosis yang paling tepat?

A. Lentigo

B. Keratosis seboroik

C. Melanoma maligna

D. Hiperpigmentasi pasca inflamasi

E. Karsinoma sel skuamosa

SOLAR LENTIGO

AT-A-GLANCE

- Solar lentigines are hyperpigmented macules that occur on photodamaged skin, singly or as multiple lesions.
- They predominantly develop in older individuals. Children with xeroderma pigmentosum develop solar lentigines during the first year of life because of increased susceptibility to UV radiation.
- Histology shows elongation of rete ridges with budlike processes, hyperpigmentation, normal or slightly increased melanocytes, and dermal solar elastosis.

- Solar lentigines are benign. Development is associated with increased risk of UV-related cutaneous malignancies, including squamous cell carcinoma, basal cell carcinoma, and melanoma.
- Synonyms: actinic lentigo, sun-induced freckle, liver spot, lentigo senilis, senile lentigo

TREATMENT

Solar lentigines are benign lesions that do not require therapy. If desired, cosmetic removal may be completed with cryotherapy or other techniques, including Q-switched laser.

The prevalence of solar lentigines is strongly associated with older age and photodamage. They mainly arise on sun-exposed skin of those with white skin and Asians. More than 90% of those with white skin develop a solar lentigo by the age of 50 years.[87] Multiple lentigines on the face appear to be associated with dark skin (types III and IV).[88,89] In addition to age and sun exposure, they are associated with history of facial ephelides (freckles), tanning capacity, and concurrent use of oral contraceptive therapy.[88]

Solar lentigines arise on skin exposed to natural sunlight or artificial sources of UV radiation. They have well-defined, irregular borders, with a tendency to coalesce at sites of severe sun damage where multiple lesions may be present (Fig. 115-19). They range in size from less than 1 mm to several centimeters in greatest dimension. Lesions are light to dark brown in color. Ink spot lentigo (reticulated black solar lentigo) is a variant with black pigmentation.

5. Seorang wanita berumur 42 tahun PNS datang berobat dengan keluhan bercak menebal yang lunak memanjang bewarna kekuningan tidak terasa gatal dan tidak sakit, simetris pada kelopak mata kanan dan kiri, pada pemeriksaan dijumpai plak yang lunak memanjang bewarna kekuningan, simetris pada regio medial canthus dekstra dan sinistra. Pada pemeriksaan histopatologi akan dijumpai:

A. Sel dendritik
B. Sel melanosit
C. Horn cyst
D. Sel mast
E. Foam cell

XANTHELASMA

Planar xanthomas are yellow macules, soft papules, or plaques found commonly on the upper eyelids near the inner canthus (xanthelasma palpebrarum or xanthelasma), the wrists and palms (xanthoma striatum palmare), and in intertriginous areas (Fig. 126-7 and 126-8).[22] Xanthelasmas may be found in patients with elevated LDL-C levels, but most often occur in patients with relatively normal lipid levels and the occurrence of these lesions on the eyelids is usually not associated with coronary heart disease.[23] A variation of this disorder, known as giant xanthelasma palpebrarum, may involve all 4 eyelids.

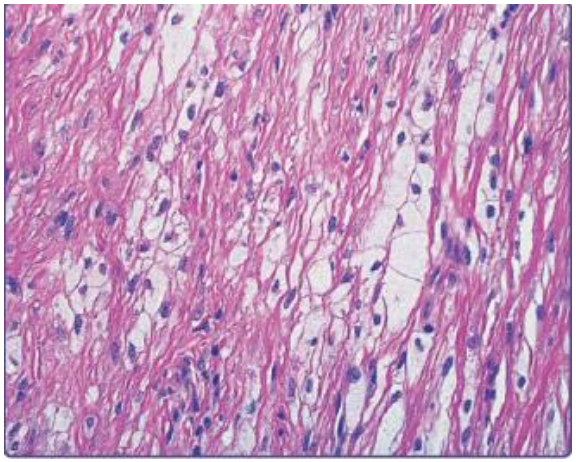

tuberous xanthomas; however, xanthelasmas can be differentiated by their superficial location.[31,32] Along with the foam cells, xanthelasmas may reveal striated muscle, vellus hair, and/or a thinned epidermis, indicative of the superficial location.[7] Both tuberous and tendinous xanthomas may have associated fibrosis, with greater degrees of fibrosis indicating older lesions.

dyslipidemia. Surgery also may be pursued for mainly cosmetic reasons, especially with xanthelasmas. Other treatment options for xanthelasmas include ablative laser therapy or cryotherapy. Lesions may improve with lipid-lowering therapy. However, lesions will usually recur if the underlying dyslipidemia is not treated. In patients with homozygous familial hyper-

6. Seorang laki laki berumur 57 tahun petani datang berobat dengan keluhan bintil-bintil dan penebalan kulit bewarna coklat kehitaman tidak gatal dan tidak sakit di daerah wajah, punggung dan dada sejak lebih dari 10 tahun yang lalu yang semakin lama semakin banyak. Pada pemeriksaan dermatologi dijumpai papul-papul dan plak yang melekat (stuck on) pada regio fasialis, thoracalis dan vertebralis dengan ukuran bervariasi antara 1 cm hingga 4 cm. Pada perabaan terasa verucous dan tampak berminyak (greasy feel). Pada pemeriksaan histopatologi akan dijumpai:

A. Pembentukan “horn cyst”
B. Palisade
C. Rete ridge memanjang
D. Foam cell
E. Sel mast

Keratosis Seboroik

- Merupakan tumor jinak epidermal yang paling sering terjadi
- Lesi umumnya terjadi pada usia pertengahan, namun dapat muncul pada awal masa remaja

- Terdapat banyak varian klinis
- Pada lesi awal terdapat batas yang tegas, permukaan rata, kusam, dan berwarna kecoklatan
- Seiring perkembangannya, lesi menjadi berbentuk papul, permukaannya verukosa, *stuck-on,* mengkilat, dan terdapat kista *pseudohorn*

- Jenis varian:

1. *Stucco keratosis*
2. *Dermatosis papulosa nigra*
3. *Inverted follicular keratosis*
4. *Lichenoid keratosis*
5. *Large cell acanthoma*
6. *Flat seborrheic keratosis*

Pemeriksaan Penunjang

1. Dermoskopi : *Milia-like cysts, comedo-like openings, light-brown fingerprint-like structures, cerebriform pattern(gyrus & sulci)*
2. Histopatologi : tampak akantosis, papillomatosis, kista *pseudohorn,* dan *hiperkeratosis*

Penatalaksanaan

1. Kuretase, krioterapi
2. Bedah listrik (elektrodesikasi) : memiliki efektivitas yang sama dibanding laser CO2 dengan biaya yang lebih murah
3. Laser CO2 ablatif : memiliki efikasi yang hampir sama seperti tindakan bedah listrik (elektrodesikasi) dan memiliki *outcome* yang memuaskan
4. *Potassium-titanyl-phosphate (KTP) laser* memperlihatkan perbaikan yang serupa dalam tatalaksana dermatosis papulosa nigra pada 14 subjek
5. QS Nd: YAG 1064 mm *(long pulsed) :* untuk keratosis seboroik mencapai resolusi sebesar 70- 90% pada dua orang pasien

7. Keganasan pada kulit yang bersifat destruksi lokal dan jarang metastase adalah

A. Karsinoma Sel Skuamosa
B. Karsinoma Sel Basal
C. Melanoma Maligna
D. Keratosis Seboroik
E. Lentigo Solaris

Karsinoma Sel Basal

- Tumor ganas yang berasal dari lapisan epidermis**, tumbuh secara lambat, dan lokal** invasif
- Merupakan kanker kulit tipe non-melanoma yang paling sering terjadi
- Penyakit ini berhubungan dengan pajanan sinar matahari dan jarang terjadi metastasis

TABLE 111-2
Common Basal Cell Carcinoma Subtypes with Corresponding Kodachrome

TYPE OF BASAL CELL CARCINOMA (BCC)	CLINICAL DESCRIPTION	CLINICAL PHOTOGRAPHS	HISTOLOGIC DESCRIPTION	HISTOLOGY
Nodular BCC	Translucent papule or nodule, with telangiectasis and rolled border; may ulcerate		Nodules of basophilic nests with stromal retraction	
Pigmented BCC	Hyperpigmented translucent papule		Nodules of basophilic nests with melanocytes interspersed between tumor cells; melanophages within stroma	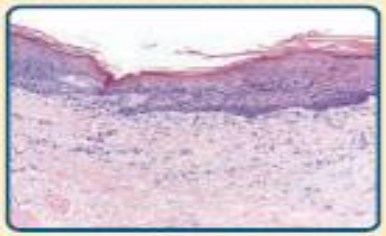
Superficial BCC	Well-demarcated, erythematous patch	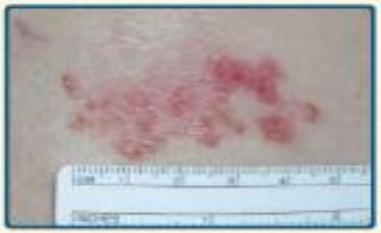	Buds of malignant cells extending into the dermis from the basal layer of the epidermis. Minimal dermal involvement.	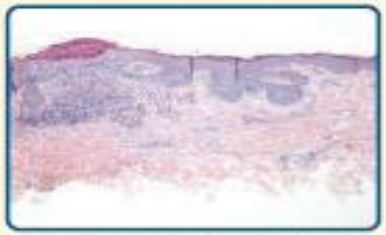
Morpheaform (sclerosing, infiltrative) BCC	Scarlike in appearance; ivory-white		Strands of tumor cells within a dense fibrous stroma	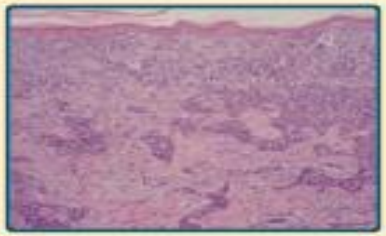

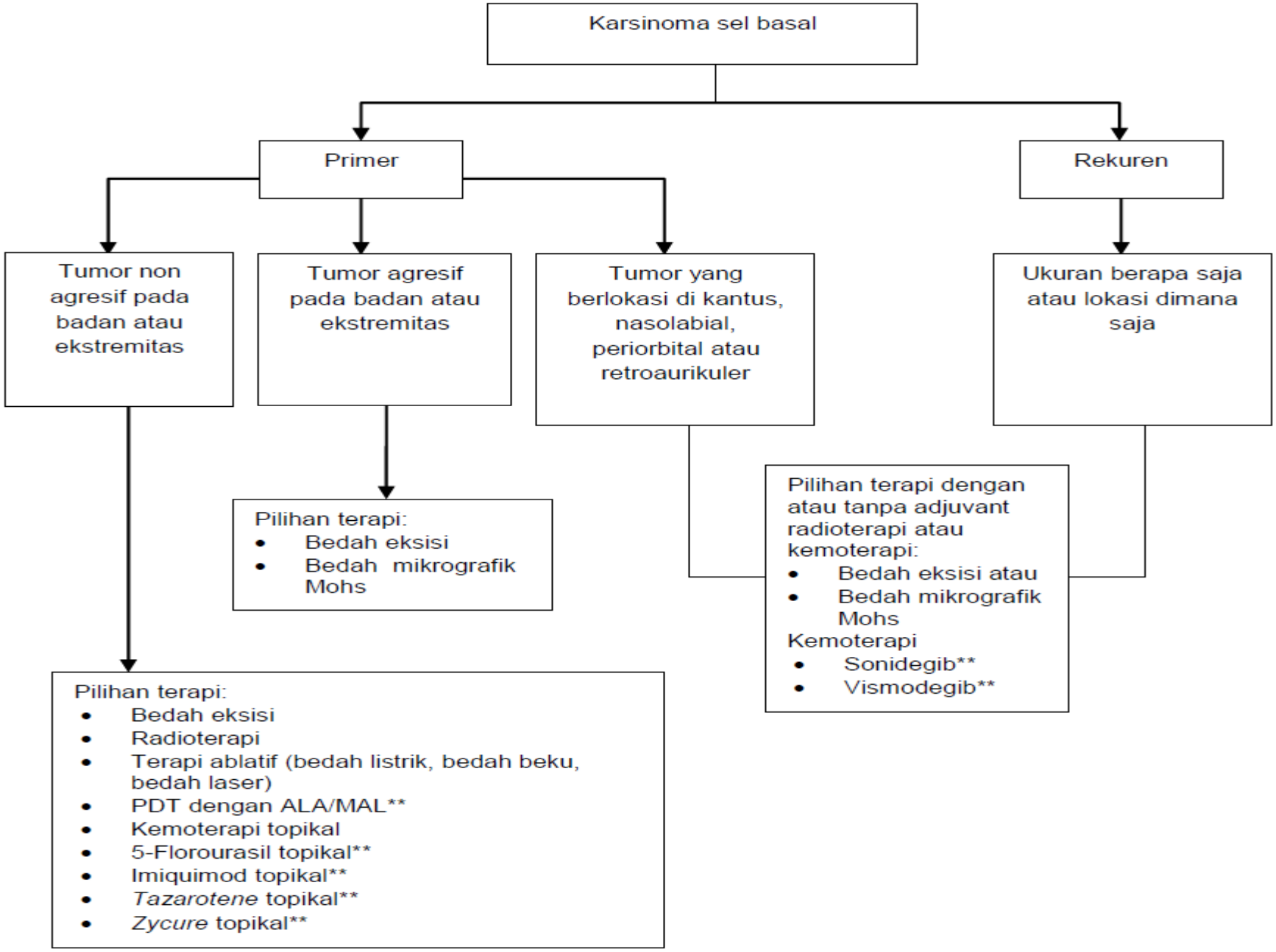

Keterangan:
**Obat menunggu persetujuan BPOM

8. CDC menetapkan 3 jenis keganasan yang sering berkaitan dengan HIV serta membantu penegakan diagnosis AIDS. Salah satu di antara ketiga keganasan tersebut adalah:

A. Kanker anus

B. Seminoma testis

C. Karsinoma prostat

D. Limfoma non-Hodgkin

E. Karsinoma sel skuamosa

MUCOCUTANEOUS MANIFESTATIONS OF HIV

AT-A-GLANCE

- HIV is a retrovirus that causes immune suppression and dysregulation primarily via depletion of CD4+ lymphocytes and CD4+ cells of monocytic lineage.
- In spite of better screening programs, availability of antiretroviral therapy (ART), and improved side-effect profiles, new infections continue to be documented.
- The range of dermatologic complications seen in HIV/AIDS relates to the evolving immunologic state of the patient, specific viral characteristics of the serotype causing infection, the period of time from infection to dermatologic complication, and the length of antiretroviral treatment.
- Acute HIV infection presents as a mononucleosis-like syndrome that can include a morbilliform exanthem 3 to 6 weeks after infection with HIV.
- In resource-limited areas, untreated infection may lead to progressive dermatologic disease.
- In reconstituted individuals and long-term viral suppression, sun-induced neoplasia and viral-induced neoplasia are significant burdens.

CUTANEOUS MALIGNANCY IN HIV

AT-A-GLANCE

- Kaposi sarcoma remains one of the most common HIV-associated malignancies worldwide, even with reduction in incidence because of ART. Recently, a novel group of HIV-infected patients has been identified that develop new-onset Kaposi sarcoma while already virologically suppressed on ART.
- HPV-induced dysplasia and squamous cell carcinoma are more common in HIV-infected men and women than in the general population, with a high burden in men who have sex with men. Screening for anal and cervical dysplasia is particularly important for HIV-positive patients.
- Cutaneous lymphomas and other nonkeratinocyte cancers are also more prevalent in HIV-positive patients. Primary cutaneous lymphomas in HIV patients tend to be aggressive rather than indolent, with survival often less than 1 year.

CUTANEOUS LYMPHOMAS IN HIV

Epidemiology: In the ART era, the risk of lymphoma in HIV patients is at least 11 to 15 times that of the general population[23,188]; pre-ART it may have been as high as 352-fold.[189] Incidence of HIV-associated lymphomas is generally correlated with the degree of immunosuppression, however, with increasingly widespread and early initiation of ART, the incidence of non-Hodgkin lymphoma is declining and is increasingly noted at higher CD4+ counts.[190]

Cutaneous lymphomas, in particular, differ in their epidemiology in HIV-infected individuals as compared to uninfected individuals.[189,191,192] Infected individuals are at increased risk of developing CD30+ anaplastic large-cell lymphoma, diffuse B-cell lymphoma, and plasmablastic lymphoma, a malignancy that is virtually unseen outside of AIDS. Mycosis fungoides, however, has a similar presentation, clinical course, and management paradigm to that for uninfected individuals.[193]

Clinical Features: Cutaneous manifestations can vary widely. Primary cutaneous lymphomas have been described as singular nodules or tumors that can have ulceration.[38,189] Plasmablastic lymphomas may present in the oral mucosa.[194]

Clinical Course, Prognosis, and Management: In HIV-negative individuals, primary cutaneous lymphomas typically have a more indolent course and better prognosis when compared to systemic lymphomas. In contrast, primary cutaneous lymphomas in HIV patients tend to be aggressive, with survival often less than 1 year.[189,192,194,195] Patients often die because of complications of immunosuppression, such as sepsis, rather than the lymphoma itself, although metastasis has been noted, especially with CD30+ anaplastic large-cell lymphoma.[189,192,196]

No guidelines exist for management of cutaneous lymphomas and other nonkeratinocytic malignancies in the setting of HIV. If amenable, lesions of some subtypes may be managed with excision and local radiotherapy.[38,195] Because of the high risk of sepsis and complications of immunosuppression, the literature suggests that chemotherapy is used best when in combination with ART and adequate HIV control. This is true in both resource-abundant as well as resource-poor settings.[196,197] Cyclophosphamide, hydroxydaunorubicin, vincristine, and prednisone (CHOP), and Adriamycin and vincristine monotherapy have been tried.[194] Reports of spontaneous clearance of lymphoma following HIV control exist.[195]

9. Berikut yang termasuk tipe virus papilloma humanus yang dapat menyebabkan karsinoma sel skuamosa:

A. 2
B. 6
C. 10
D. 16
E. 27

Karsinoma Sel Skuamosa

- Tumor ganas non-melanoma yang berasal dari keratosit epidermis supra-basal
- Umumnya timbul pada bagian tubuh yang terpajan matahari dan sebagian besar timbul dari lesi prekursor seperti keratosis aktinik, penyakit Bowen, luka bakar dan penyakit kulit kronis lain

Faktor Predisposisi

1. Lesi prekursor (keratosis aktinik, penyakit Bowen)
2. Pajanan ultraviolet
3. Pajanan radiasi ionisasi
4. Pajanan terhadap karsinogen lingkungan
5. Imunosupresi
6. Skar
7. Luka bakar atau pajanan panas yang lama
8. Ulkus kronik atau dermatosis inflamasi
9. Infeksi *human papilloma virus*
10. Genodermatosis (albinism, xeroderma pigmentosum, porokeratosis, epidermolisis bulosa)
11. Mutasi P53, Bcl2, dll

Gambaran Klinis

- Pada populasi kulit putih lesi kulit biasanya ditemukan pada daerah yang terpajan sinar matahari seperti kepala, leher, dan punggung tangan
- Pada populasi kulit berwarna terdapat distribusi yang sama baik ditempat yang sering terpajan matahari maupun tidak.
- Tumor biasanya soliter, merupakan kelanjutan dari lesi prekursor

Even though the exact role for HPVs in SCC pathogenesis remains poorly defined, HPVs have proposed to be a possible cocarcinogen in the development of SCC with environmental factors such as UVR. Epidemiologic studies suggest a link between these 2 factors in skin carcinogenesis[51,52] as a high prevalence of HPV DNA has been reported in sun-exposed skin in immunocompetent individuals.[51] Also, HPV prevalence and viral load are reportedly higher in AK compared to invasive SCC and normal-appearing skin, and HPVs, particularly of genus type beta, are believed to play a role in the initiation of SCC but may not be necessary for tumor maintenance.[53,54]

SQUAMOUS CELL CARCINOMA AND HUMAN PAPILLOMAVIRUS

Common warts in immunocompetent individuals are not forerunners of skin cancer. However, there are a very few reports, usually in the setting of immunosuppression, of long-standing periungual warts progressing into Bowen disease (full-thickness dysplasia) or invasive SCC.[51] In such cases, the high-risk anogenital HPV type, HPV-16, is usually present. Long-standing and slowly enlarging warty areas on the soles, fingers, or anogenital skin can be a feature of carcinoma cuniculatum or verrucous carcinoma (Buschke-Löwenstein tumour), in which the HPV types usually associated with anogenital warts, HPV-6 or -11, are occasionally detected.[52,53]

TABLE 167-1
Diseases Caused by or Associated with Human Papillomavirus Infection

DISEASE	CLINICAL	MOST COMMONLY ASSOCIATED HPV TYPES[a]	PV GENUS
Cutaneous warts	Common warts, filiform warts, mosaic warts	2, 27, 57 (7) 4, (60) (48)	Alpha Mu Gamma
	Palmar and plantar warts	1, (63)	Nu
	Butchers' warts	2, 7	Alpha
	Plane warts	3, 10 (28)	Alpha
Anogenital warts	Vulval warts, vaginal warts, penile warts, perianal warts	6, 11 (and others)	Alpha
Oral warts		6, 11 (and others)	Alpha
EV and EV-like syndromes	Benign scaly or flaky lesions;	9, 12, 15, 19, 22-25, 36-38, 80	Beta
	Plane warts	3, 10	Alpha
	Skin SCC	5, 8, 14, 17, 20, 21, 47, 93, 96	Beta
Skin SCC	Periungual SCC	16	Alpha
	Carcinoma cuniculatum or verrucous carcinoma	(11, 6)	Alpha
AGIN	VIN, VaIN, CIN, PIN, AIN	16, (18, 31, 33, 35, 45, 52, 58 and others)	Alpha
Anogenital SCC	SCC of vulva, vagina, cervix, penis, anal area	16, 18, 31, 33, 35, 42 (and others)	Alpha
Oropharyngeal SCC	SCC of mouth, pharynx	16 (18, 31, 33, 35 and others)	Alpha

Pemeriksaan Penunjang

1. Dermoskopi
- Struktur vaskular polimorfik berupa linear ireguler/*serpentine, hairpin/looped, glomerular/coiled* dan *dotted.* Sedangkan struktur keratin berupa *white circle, white pearl/clod central keratin,* dan *central keratin with blood spot*

2. Biopsi
- Spesimen diambil pada bagian lesi yang dicurigai infiltrasi lebih dari superfisial (NCCN kategori 2A)

3. Histopatologi
- Pada pemeriksaan harus mencantumkan subtipe perubahan morfologi pada sel, derajat diferensiasi, dalamnya tumor dalam millimeter, kedalaman invasi, dan pemeriksaan keterlibatan saraf, vaskular, dan kelenjar getah bening (NCCN kategori 2A)

4. *Computed tomography (CT)* dan *magnetic resonance imaging (MRI)*
- Dilakukan bila terdapat kecurigaan perluasan penyakit pada tulang, saraf maupun jaringan lunak lain (NCCN kategori 2A)
- Pemeriksaan kelenjar getah bening (NCCN kategori2A)

Karsinoma sel skuamosa

Anamnesis
- Keluhan sesuai KSS
- Faktor predisposisi

Pemeriksaan klinis
Lesi sesuai gambaran KSS

Histopatologi

Tidak sesuai KSS

Tatalaksana sesuai diagnosis

Sesuai KSS

- Staging sesuai kriteria NCCN
- Edukasi penyakit, cara pencegahan, dan deteksi dini

KSS insitu/*non high risk*

1. Eksisi luas
2. Terapi ablatif (non bedah)
3. Topikal, misal: 5FU, imiquimod

High risk/metastasis

1. Eksisi luas
2. Kemoterapi
3. Radiasi
4. Bedah Mohs

Pertemuan dan konsultasi ke bidang terkait:
1. Dept. Radioterapi
2. Dept. Bedah Onkologi
3. Dept. IPD (HOM)
4. Dept. Bedah Plastik Rekonstruksi
5. Dept. Rehabilitasi Medik

10. Whiff test positif pada vaginosis bakterial disebabkan karena:

A. Adanya asam laktat
B. Pelepasan kadaverin pada kondisi asam
C. Pelepasan amin pada pada kondisi basa
D. Pelepasan laktoferin pada kondisi basa
E. Adanya H2O2

Vaginosis Bakterial

- Sindrom klinis yang disebabkan oleh pergantian *Lactobaccillus sp penghasil H2O2* yang normal di dalam vagina dengan sekelompok bakteri anaerob batang gram negatif (*Prevotella sp, Mobiluncus sp), Gardnerella vaginalis dan Mycoplasma horminis*
- Anamnesis:
- 50% perempuan asimtomatik
- Keputihan berbau amis, terutama setelah selesai senggama

Pemeriksaan klinis:

- Duh tubuh vagina warna putih homogen, melekat, berbau amis pada dinding vagina dan vestibulum, kadang-kadang disertai rasa gatal
- Vagina dan serviks tidak ada kelainan

Memenuhi kriteria Amsel yaitu (3 dari 4 gejala):

1. Duh vagina sesuai klinis
2. Tes amin/*Whiff test, hasil positif (tercium bau amis seperti ikan pada duh tubuh* vagina yang ditetesi dengan larutan KOH 10%)
3. pH cairan vagina >4,5
4. Sediaan basah dengan larutan NaCl fisiologis atau sediaan apus dengan pewarnaan Gram ditemukan *clue cells*

Penatalaksanaan

- Obat pilihan:

1. Metronidazol 2x500 mg/hari selama 7 hari atau
2. Metronidazol 2 gram per oral dosis tunggal atau

- Obat alternatif:

1. Klindamisin 2x300 mg/hari per oral selama 7 hari

Catatan:

- Pasien dianjurkan untuk tidak mengkonsumsi alkohol selama pengobatan dengan metronidazol berlangsung sampai 48 jam sesudahnya untuk menghindari *disulfiram-like reaction*

It is thought that amines produced by the microbial flora, perhaps via the action of microbial decarboxylases, account for the characteristic abnormal fishy odor that is produced when vaginal fluid is mixed with 10% KOH. This so-called "whiff test" is thought to be due to volatilization of aromatic amines including putrescine, cadaverine,[124,125] and trimethylamine[125] at alkaline pH. *Mobiluncus* is known to produce trimethylamine,[125] but the other microbial sources of the amines are still unknown. However, it is still unknown which, if any, organisms produce these amines. Trimethylamine can be detected at relatively high concentrations in the vaginal fluid of VB, with a median concentration of 5 mM.[126] The presence of trimethylamine in the vaginal fluid is thought to be largely responsible for symptoms of malodor experienced by women with BV.

11. Produksi lactobasilus yang dapat menghasilkan potent oxidant dan mempunyai efek microbisidal adalah:

A. H2O2

B. Defensin

C. Laktoferin

D. Bakteriosin

E. Asam laktat

ROLE AND SPECIES OF *LACTOBACILLUS* IN THE VAGINA

ROLE OF H_2O_2

In addition to producing acid, some species of lactobacilli produce hydrogen peroxide (H_2O_2).[42] H_2O_2 is toxic to a wide variety of microorganisms, and H_2O_2 of microbial origin interacts with peroxidases produced by the host along with halide (chloride) ion to generate a potent oxidant which is toxic to many bacteria. Over the past several years a number of studies have been published on the prevalence of H_2O_2-producing *Lactobacillus* in the vaginal flora of women. H_2O_2 production is detected by an agar plate method as shown in Fig. 18-1. H_2O_2-producing stains of lactobacilli reduce tetramethylbenzidine, causing colonies to turn blue. In studies of women between the ages of 16 and 45, the prevalence of H_2O_2-producing *Lactobacillus* has varied from 42% to 74%.[36,42–49] Comparatively, premenarchal girls are unlikely to be colonized with H_2O_2-producing lactobacilli,[37] while postmenopausal women have an intermediate prevalence of H_2O_2-producing lactobacilli.[38]

12. Uji serologis sifilis yang memiliki korelasi erat dengan aktivitas penyakit dan dipakai sebagai indikator keberhasilan terapi adalah:

A. Treponema pallidum immobilization
B. Fluorescent treponemal antibody absorption
C. Venereal diseases research laboratory
D. Treponema pallidum haemagglutination assay
E. Enzyme linked immune sorbent assay

Sifilis

- Penyakit infeksi menular seksual yang disebabkan oleh *Treponema pallidum,* bersifat kronis, sejak awal merupakan infeksi sistemik, dalam perjalanan penyakitnya dapat mengenai hampir seluruh struktur tubuh, dengan manifestasi klinis yang jelas namun terdapat masa laten yang sepenuhnya asimtomatik, mampu menyerupai berbagai macam penyakit, dapat ditularkan kepada janin dalam kandungan, dan dapat disembuhkan

Stadium Klinis

Stadium I (Sifilis primer)

- Ulkus tunggal, tepi teratur, dasar bersih, terdapat indurasi, tidak nyeri; terdapat pembesaran kelenjar getah bening regional.
- Lokasi: di tempat kontak dengan lesi infeksius pasangan seksual. Pada laki-laki sering didapatkan di penis (terutama di glans penis atau sekitar sulkus koronarius) dan skrotum; pada perempuan didapatkan di vulva, serviks, *fourchette,* atau perineum. Namun dapat pula ulkus tidak tampak dan tidak disadari oleh pasien.

Figure 170-3 Chancre on the penile shaft, demonstrating a clean base and elevated borders

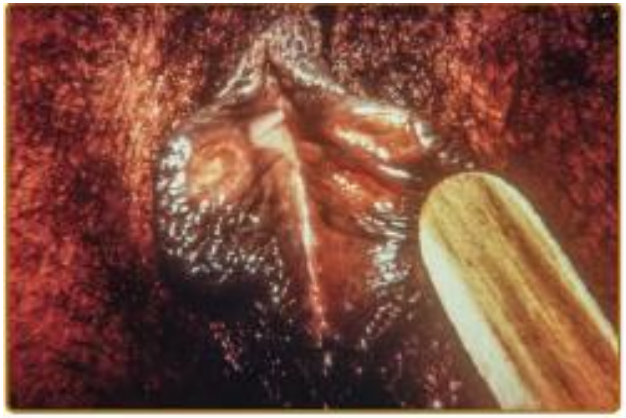

Figure 170-4 Chancres on the labia in a female.

Stadium II (Sifilis sekunder)

- Terdapat lesi kulit yang polimorfik, tidak gatal dan lesi di mukosa, sering disertai pembesaran kelenjar getah bening generalisata yang tidak nyeri (limfadenopati)

Stadium Laten

- Tidak ditemukan gejala klinis pada pasien, namun tes serologi sifilis (TSS) reaktif, baik serologi treponema maupun nontreponema

Stadium III (Sifilis tersier)

- Didapatkan gumma, yaitu infiltrat sirkumskrip kronis yang cenderung mengalami perlunakan dan bersifat destruktif. Dapat mengenai kulit, mukosa dan tulang

PEMERIKSAAN PENUNJANG

Tabel 1. Pemeriksaan penunjang sifilis

	Sifilis primer	Sifilis sekunder	Sifilis laten
RPR atau VDRL	Dapat reaktif atau non reaktif	Reaktif, titer tinggi	Reaktif
TPHA	Reaktif	Reaktif	Reaktif

NONTREPONEMAL SEROLOGIC TESTS

The 2 most widely used nontreponemal tests are the VDRL and rapid plasma reagin (RPR) tests. These tests are used both to diagnose syphilis, and to monitor response to treatment. The VDRL and RPR begin to become reactive 4 to 5 weeks after infection, with 100% sensitivity by approximately 12 weeks, and revert to nonreactive in 25% to 30% of cases during late latent syphilis (Fig. 170-38).[140] Cases of seronega-

Clinical and serologic followup is important to monitor response to treatment (see Table 170-5). Treatment success is generally defined as a fourfold decline in serologic nontreponemal titer (or reversion to nonreactive result) following appropriate treatment, in the absence of persistent signs or symptoms of syphilis, and within a specified time frame depending on stage of infection and HIV infection status of the infected person.[35] An example of a fourfold decline in titer is a 1:64 titer declining to 1:16, or a 1:16 titer declining to 1:4. The CDC recommends followup at 6-month intervals until a fourfold decline is documented, except for HIV-infected persons with

13. Seorang wanita 40 tahun mengeluhkan keputihan berulang. Dalam 1 tahun keluhan keputihan sampai dengan 6x. Keputihan terasa gatal, seperti susu pecah. Riwayat DM (+). Pada pemeriksaan Gram didapatkan blastospora. Apa organisme penyebab kondisi ini?

A. Candida tropicalis

B. Candida glabrata

C. Candida albicans

D. Candida pseudotropicalis

E. Candida krusei

DIABETES MELLITUS

Vaginal colonization with *Candida* is more frequent in diabetic women. Women with NIDDM are more prone to colonization with *C. glabrata*.[57] Although uncontrolled diabetes undoubtedly predisposes to symptomatic vaginitis, well-controlled diabetics do not suffer from an increased prevalence of VVC.[1,58] It has become traditional to perform glucose

KANDIDIASIS VULVOVAGINALIS

- Infeksi pada vulva dan vagina yang disebabkan oleh *Candida albicans* atau kadang oleh *Candida sp, Torulopsis sp* atau ragi lainnya

- **Anamnesis**

1. Gatal pada vulva
2. Vulva lecet, dapat timbul fisura
3. Dapat terjadi dispareunia

Pemeriksaan klinis

- Pada vulva dan vagina tampak:

1. Hiperemis
2. Dapat timbul fisura
3. Edema jika berat
4. Duh tubuh vagina, putih seperti susu, bergumpal, tidak berbau
5. Jika mengenai genitalia luar dapat dijumpai bercak/plak eritema dengan lesi satelit

Pemeriksaan Penunjang

- Bahan dari duh tubuh vagina yang berasal dari dinding lateral vagina, dilakukan pemeriksaan:

1. Sediaan apus dengan pewarnaan Gram ditemukan blastospora dan atau pseudohifa
2. Sediaan basah dengan larutan KOH 10% ditemukan blastospora dan atau pseudohifa
3. Kultur jamur dengan media Saboraud

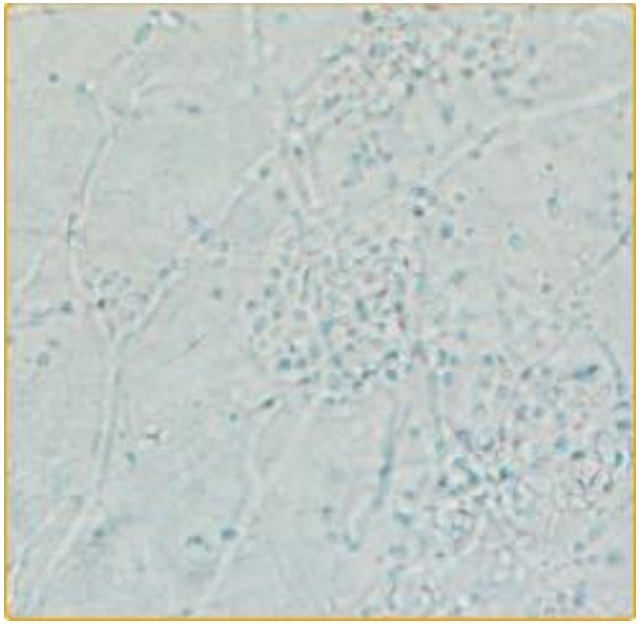

Penatalaksanaan

Obat pilihan :

1. Klotrimazol 500 mg, intravagina dosis tunggal atau
2. Klotrimazol 200 mg, intravagina selama 3 hari atau
3. Nistatin 100.000 IU intravagina selama 7 hari
4. Flukonazol*** 150 mg, per oral, dosis tunggal atau
5. Itrakonazol*** 2x200 mg per oral selama 1 hari atau
6. Itrakonazol*** 1x200 mg/hari per oral selama 3 hari atau
7. Ketokonazol# kapsul 2x200 mg/hari per oral selama 5 hari

- Untuk kandidiasis vulvovaginal rekuren (kambuh ≥4x/tahun):
  - Agen topikal atau flukonazol oral selama 10-14 hari dilanjutkan dengan flukonazol 150 mg/minggu selama 6 bulan

Catatan:

1. Wanita hamil sebaiknya tidak diberikan obat sistemik
2. ***Tidak boleh diberikan pada ibu hamil, menyusui, atau anak di bawah 12 tahun
3. Pada penderita dengan imunokompeten jarang terjadi komplikasi, sedangkan penderita dengan status imun rendah infeksi jamur dapat bersifat sistemik
4. #Ketokonazol tidak dianjurkan untuk pemakaian jangka panjang

14. Keparahan infeksi herpes genital dipengaruhi oleh :

A. Stress

B. Hormon

C. Jumlah virus

D. Reaktivasi virus

E. Keparahan infeksi awal

Herpes Simpleks Genital

- Infeksi menular seksual yang disebabkan oleh virus *Herpes simplex (VHS)* tipe 2 atau tipe 1, dan bersifat rekuren
- Infeksi akibat kedua tipe VHS bersifat seumur hidup; virus berdiam di jaringan saraf, yaitu di ganglia dorsalis
- Perjalanan infeksi:

1. HG episode pertama lesi primer
2. HG episode pertama lesi non-primer
3. HG rekuren
4. HG asimtomatik
5. HG atipikal

Pemeriksaan Penunjang

1. Kultur virus

- Sensitivitas kultur sebesar 67-70% bila sediaan diambil dari vesikel, 32% bila sediaan pustul, dan hanya positif sebesar 17% bila sediaan diambil dari krusta

2. Deteksi antigen (dengan *enzyme immunoassay atau fluorescent antibody), atau* PCR DNA HSV

3. Serologi IgM dan IgG anti-HSV 1 dan 2

The risk of severe HSV disease and the recurrence rate correlate with the level of cellular immune competence of the host. Patients with mild decreases in cellular immunity may experience only an increased number of recurrences and a slower resolution of lesions, while severely compromised patients are more likely to develop disseminated, chronic, or drug-resistant infections. CD8+ and CD4+ T-lymphocyte subsets, natural killer cells, and inflammatory cytokines like interferon-γ are important in mediating protection against HSV. Innate immunity is also important and polymorphisms in TLR2 are associated with increased rates of genital lesions in seropositive persons.[16] Mutations in proteins important

with primary genital HSV-2 infection who have a more prolonged initial episode develop high titers of HSV-2 complement-independent neutralizing antibody in convalescent sera and are more likely to develop recurrences than those who do not develop anti-HSV neutralizing antibody.[130,193]

15. Peningkatan transmisi virus HIV pada pasien dengan trikomoniasis disebabkan oleh:

A. Komponen makromolekul pejamu yang menyelubungi trikomoniasis
B. Fagositosis trikomoniasis terhadap virus
C. Atrofi serviks permanen
D. Respon inflamasi pada epitel vagina dan ektoserviks
E. Sekresi enzim proteinase oleh trikomonas

Trikomoniasis :

Penyakit infeksi menular seksual yang disebabkan oleh parasit berflagel *Trichomonas vaginalis*

- Perempuan:
- 10-50% asimtomatik
- Keputihan berbau busuk, warna kuning kehijauan, kadang-kadang berbusa.
- Jumlah keputihan yang banyak mengiritasi kulit sekitar vulva menimbulkan keluhan gatal dan perih pada vulva dan kulit sekitarnya

- Laki-laki:
- 15–50% asimtomatik, biasanya sebagai pasangan seksual perempuan yang terinfeksi
- Duh tubuh uretra sedikit atau sedang, dan atau nyeri saat kencing, dapat juga iritasi uretra dan sering miksi
- Pada keduanya didapatkan adanya riwayat kontak seksual sebelumnya (*coitus suspectus)*

Pemeriksaan Klinis

- Perempuan:
- Pada daerah forniks posterior, tampak duh tubuh vagina seropurulen, berbau busuk, jumlahnya sedikit sampai banyak, berwarna kuning kehijauan, berbusa, dapat terjadi pada 10-30% wanita, dapat disertai gatal pada vulva
- Kadang terdapat rasa tidak enak di perut bagian bawah
- Vulvitis dan vaginitis
- Gambaran *strawberry cervix dapat ditemukan pada 2% pasien*

- Laki-laki:
- Duh tubuh uretra sedikit atau sedang, dan/atau disuria, dapat juga iritasi uretra dan sering miksi
- Jarang: duh tubuh uretra purulen

Penatalaksanaan

- Obat pilihan:

1. Metronidazol 2 gram per oral dosis tunggal atau
2. Metronidazol 2x500 mg/hari per oral selama 7 hari

Catatan:

- Pasien dianjurkan untuk tidak mengkonsumsi alkohol selama pengobatan hingga 48 jam sesudahnya untuk menghindari *disulfiram-like reaction*

TRICHOMONIASIS AND HIV

T. vaginalis is epidemiologically associated with HIV, and can facilitate the transmission and acquisition of the virus due to inflammatory responses in the vaginal epithelium and ectocervix in women and the urethra in men. Cross-sectional studies demonstrating an association between trichomoniasis and HIV in women suggested two- to threefold increases in HIV transmission.[34,35] These findings were supported by a prospective study conducted among HIV-negative female sex workers that also showed a twofold increased rate of HIV seroconversion among women with prior *T. vaginalis* infection.[13] In men, urethritis associated with *T. vaginalis* has been reported to increase HIV shedding in semen eightfold.[36] Assuming that *T. vaginalis* increases the risk of HIV transmission by 90% (less than twofold) in a population with a 25% prevalence of trichomoniasis, one estimate indicates that approximately 20% of prevalent HIV cases could be attributable to *T. vaginalis.*[37] Another suggests that 6.2% of incident HIV infections among women in the United States may be attributable to trichomoniasis.[38]

Concomitant infection with other STIs occurs commonly in persons with trichomoniasis.[3,39] Mixed infections with *T. vaginalis* and *Neisseria gonorrhoeae* and/or *Chlamydia trachomatis* occurred in 1.4% of 504 East African transport workers, while 61.5% of 91 men with trichomoniasis in West Africa also had a gonococcal infection.[40]

16. Faktor kegagalan terapi pada infeksi trichomoniasis?

A. Peningkatan piruvat reductase

B. Ferrooxidase

C. Tidak reduksinya H2O2

D. Tioreduksi

E. Inaktivasi metronidazole oleh bakteri

In principle, there are two types of metronidazole resistance (aerobic and anaerobic).[287] Aerobic resistance is manifested only if some oxygen is present.[294,295] The MLCs of metronidazole determined in vitro under aerobic conditions for resistant clinical isolates range between 25 and 1000 μg/mL.[142,294,295] Although the exact mechanisms are not known, it has been suggested that impaired oxygen scavenging system is responsible for aerobic resistance.[142,296]

All strains responsible for clinical metronidazole resistance that have been examined so far display anaerobic resistance. Anaerobic metronidazole resistance depends on inactivation of the key components of drug-activating (electron-generating) pathways.[297] However, inactivation of a known *T. vaginalis* ferredoxin gene by genetic manipulation does not lead to aerobic or anaerobic resistance in vitro,[121] suggesting there may be additional mechanisms of drug activation. Anaerobically resistant strains developed in vitro display high MLC values in anaerobic assays (metronidazole up to 1425 μg/mL).[296]

17. Perempuan 28 tahun, hamil 28 minggu, mengeluh duh tubuh vagina berbau amis sejak 3 minggu lalu. Pemeriksaan fisik ditemukan duh tubuh vagina putih abu-abu, homogen, encer, malodorous. Pemeriksaan pH vagina 5,5 (N: 3,8-4,5). Pulasan gram ditemukan clue cell. Pemeriksaan duh tubuh vagina menggunakan KOH 10% ditemukan fishy odor. Pengobatan yang direkomendasikan pada kasus diatas adalah

A. Klindamisin 2 x 200 mg, 7 hari
B. Flukonazol 2 x 150 mg, 7 hari
C. Metronidazole 2 x 500 mg, 7 hari
D. Tinidazol 2 x 500 mg, 7 hari
E. Doksisiklin 2 x 50 mg, 7 hari

TREATMENT

Treatment of patients with BV is summarized in Table 175-8. Treatment in asymptomatic BV is not necessary in women who are not pregnant. The established benefits of therapy for BV in symptomatic nonpregnant women are to (1) relieve vaginal symptoms and signs of infection and (2) reduce the risk for infectious complications after a variety of gynecologic procedures (endometrial biopsy, hysterectomy, hysterosalpingography, placement of an IUD, cesarean section, uterine curettage, and abortion). In pregnant women, treatment of BV also reduces the risk of postpartum

TABLE 175-8
Treatment of Bacterial Vaginosis

- Metronidazole 500 mg PO twice daily for 7 days
  Or
- Tinidazole 2 g PO once daily for 3 days
  Or
- Metronidazole gel, 075%, 5 g intravaginally once daily for 5 days
  Or
- Clindamycin cream, 5%, 5 g intravaginally once a day for 7 days

In pregnant women:

- Metronidazole 250 mg PO three times daily for 7 days
  Or
- Metronidazole 500 mg PO twice daily for 7 days
  Or
- Clindamycin 300 mg twice daily for 7 days

Alternative regimen:

- Tinidazole 1 g PO once daily for 5 days
  Or
- Metronidazole 2 g PO in a single dose
  Or
- Clindamycin ovules 100 g intravaginally once a day for 3 days

PO, oral.

18. Perempuan 32 tahun dengan duh tubuh warna kehijauan dan berbusa, kadang disertai perdarahan pasca coitus. Pemeriksaan sediaan langsung dengan larutan Nacl 0,9% ditemukan organisme dengan pergerakan yang terhentak-hentak. Pemeriksaan serologis HIV non-reaktif. Pengobatan yang direkomendasikan adalah

A. Metronidazole 2 x 500 mg, oral selama 7 hari
B. Tinidazole 2 x 500 mg oral selama 3 hari
C. Metronidazole 2 g, oral, dosis tunggal
D. Itrakonazole 2 g, oral,dosis tunggal
E. Tinidazole 1 g, oral dosis tunggal

TREATMENT

Treatment reduces both symptoms and transmission.[34]

Systemic treatment consists of metronidazole, 2 g orally in a single dose, or tinidazole 2 g can be given in a single dose. The cure rates after metronidazole regimens were 84% to 98%, those after tinidazole 92% to 100%. An alternative regimen, metronidazole 500 mg orally twice a day for 7 days, can be administered. The response rate is considered to be 90% to 95%. One study showed that topical metronidazole 750 mg combined with 200 mg miconazole twice daily for 7 days was as effective as systemic treatment with metronidazole alone.

Long-term treatment with metronidazole should be avoided. During pregnancy, treatment options are limited. Topical metronidazole can be considered.

19. Laki-laki, 29 tahun, supir bus antar kota, mengeluh timbul luka lecet di kelamin sejak 1 minggu lalu. Pemeriksaan venerologikus di batang penis ditemukan ulkus, soliter, diameter 1,5 cm, bulat, kemerahan batas tegas, berindurasi tebal, kenyal, tidak nyeri, dasar bersih tanpa eksudat. Kelenjar getah bening inguinal medial membesar. Diagnosis yang paling mungkin pada kasus di atas adalah

A. Ulkus mole
B. Sifilis primer
C. Sifilis sekunder
D. Herpes genitalis
E. Limfogranuloma venereum

20. Seorang perempuan berusia 30 tahun, dengan keputihan yang berbau amis dan gatal. Pasien baru saja melahirkan dan dilakukan histerektomi. Pada pemeriksaan venereologis didapatkan duh tubuh homogen, keabu-abuan, whiff test positif. Pewarnaan Gram dari duh tubuh didapatkan clue cells. Komplikasi apakah yang dapat terjadi pada pasien ini apabila tidak diobati secara adekuat?

A. Penyakit radang panggul

B. Vaginal cuff cellulitis

C. Endometritis

D. Salfingitis

E. Servisitis

VAGINAL CUFF CELLULITIS

Vaginal cuff cellulitis occurs when vaginal bacteria contaminate the operative field during a hysterectomy. Women with more virulent bacteria in the vaginal flora, present in the increased concentrations characteristic of BV, would be expected to have increased risk of vaginal cuff cellulitis following hysterectomy.

POSTABORTION PID

PID is frequently caused by *Neisseria gonorrhoeae* and *C. trachomatis*. Many investigators have found PID following induced abortion related to *C. trachomatis*. Postabortal endometritis following induced first trimester abortion has also been related to BV. Postabortion PID occurred more commonly among patients with BV than among those with a *Lactobacillus*-dominant flora (OR = 2.4, 95% CI 1.1, 5.3).[231]

The mechanism by which BV might cause cervicitis is not clear, and it could be multifactorial. Cervical shedding of HIV is increased in the setting of BV, suggesting that BV itself may have direct effects at the endocervical mucosa.[247,248] Factors that help regulate the normal function of mucosal defense systems include SLPI, which helps to maintain healthy vaginal mucosa and is decreased in the presence of several STD;[131] IL-10;[249] IL-1β; and TNF,[132] which may increase susceptibility to HIV-1 infection. IL-1β has been associated with a higher number of vaginal neutrophils among women with BV.[250] Even when vaginal flora is normal, the balance of pro- versus anti-inflammatory cervical cytokines may play a key role in modulating visible signs of cervical inflammation and in permitting ascension of STI pathogens or other potential pathogens to the upper genital tract. Decreased cervical proinflam-

cessful treatment of BV.[131] Cervical inflammation may be linked to the degradation of mucins, which protect the cervix as well.[130]

21. Terapi trikomoniasis pada ibu hamil adalah

A. Tinidazol 1 gram peroral dosis tunggal
B. Metronidazole 2 gram peroral dosis tunggal
C. Metronidazole 2x500mg selama 5 hari
D. Metronidazole 1 gram peroral dosis tunggal
E. Metronidazole 3x500mg selama 7 hari

Table 43-3. Treatment Recommendations for *Trichomonas vaginalis* Infections

Treatment Regimen	Reference
Vaginal infections	
Recommended regimens	
Metronidazole 2 g orally in a single dose	30, 69
Tinidazole 2 g orally in a single dose	69
Metronidazole 400–500 mg orally twice a day for 5–7 days	297
Alternative regimens	
Metronidazole 500 mg orally twice a day for 7 days	30
Metronidazole 400–500 mg orally twice a day for 7 days	69
Tinidazole 500 mg orally twice daily for 5 days	297
Pregnancy	
Metronidazole 2 g orally in a single dose	30, 69

22. Seorang perempuan datang dengan keluhan keluar keputihan berwarna putih kehijauan dan berbau serta berbusa sejak seminggu yang lalu. Keluhan dirasakan sangat mengganggu. Keluhan ini tanpa disertai demam. Terkadang pasien merasa nyeri di bagian perut bawah. Pemeriksaan ginekologi didapatkan gambaran "kolpitis makularis". Diagnosis yg mungkin pada pasien?

A. Bacterial Vaginosis

B. Trichomoniasis

C. Ghonorre

D. Kandidiasis vulvovaginal

E. Herpes simpleX

Cervical pathology may be seen with *T. vaginalis* infections. Colpitis macularis, or "strawberry cervix" (Fig. 43-4), is a result of microscopic, punctate hemorrhages on the cervix. Colpitis macularis may be observed in fewer than 5% of women with trichomoniasis; however, a proportion of trichomoniasis cases with colpitis macularis can be identified using colposcopy.[162,232,233] Although uncommon, this finding is highly specific for trichomoniasis; rarely, there are other etiologies.[234] The resulting cervicitis may lead to postcoital

23. Seorang laki-laki usia 30 tahun belum menikah datang ke poliklinik spesialis kulit dan kelamin dengan keluhan luka di kemaluan sejak 2 minggu yang lalu. Hubungan seksual dengan PSK 10 hari sebelum timbul luka tanpa menggunakan pengaman. Pada pemeriksaan fisik di frenulum didapatkan ulkus dangkal, disertai indurasi dan nyeri. Terdapat pembesaran kelenjar limfe perirectal gerotha disertai gejala proktitis dan periproktitis seperti nyeri abdomen, nyeri saat defekasi dan diare. Apakah Diagnosis kasus di atas?

A. Sifilis

B. Chancroid

C. Herpes genital

D. Granuloma inguinale

E. Limfogranuloma venerum

AT-A-GLANCE

- Lymphogranuloma venereum is a sexually transmitted infection caused by L serovars (serologic variants) of *Chlamydia trachomatis*.
- Endemic in Africa, Southeast Asia, and South and Central America, and rare in developed countries.
- Outbreaks have occurred among men who have sex with men in Europe, Australia, and North America.
- Clinically manifests as inguinal and anorectal syndromes, in 3 stages.
- Hematogenous spread with manifestations of systemic infection.
- Diagnosis is by identification of organism and by serology or genotyping.
- Doxycycline or azithromycin (second-line) treatment is curative if given early in the infection course.

PRIMARY STAGE

Three to 30 days after infection, 5- to 8-mm painless erythematous papule(s) or small herpetiform ulcers appear at the site of inoculation (Fig. 173-2). Painful ulcerations[30] and nonspecific urethritis are less common. Thus, the initial lesions may be differentiated from the more common herpetic lesions by the lack of pain associated with the lesions. In males, the lesion is usually found on the coronal sulcus, prepuce, or glans penis, and in females, on the posterior wall of the vagina, vulva, or, occasionally, the cervix. Inoculation also may be rectal, at the lip, or pharyngeal.[15,31] The primary lesion is transient, often heals within a few days, and may go unnoticed.[26]

SECONDARY STAGE

A few weeks after the primary lesion appears, marked lymph node involvement and hematogenous dissemination occur, manifested by variable signs and symptoms, including fever, myalgia, decreased appetite, and vomiting. Photosensitivity may develop in up to 35% of the patients, often 1 to 2 months after bubo formation (painful inflammation of lymph node, characterized by a unilateral enlargement, suppuration, and abscesses, also firm and tender immovable mass).[32] Less commonly, patients may develop meningoencephalitis, hepatosplenomegaly, arthralgia, and iritis.[33,34] The lymphadenitis episodes often resolve spontaneously in 8 to 12 weeks. Depending on the mode of transmission, 2 major syndromes are seen.

The acute genital syndrome or inguinal syndrome is characterized by inguinal and/or femoral lymph node involvement and is the major presentation in men in developing countries. Initially, the skin overlying the affected lymph node is erythematous and indurated (Fig. 173-3). Over the subsequent 1 to 2 weeks, the lymph node enlarges and coalesces to form a firm and tender immovable mass (bubo; Fig. 173-4), which may rupture and drain through the skin, forming sinus tracts. Bilateral involvement occurs in one-third of the cases (Fig. 173-5). Nodal enlargement on either side of the inguinal ligament, the "groove sign," is pathognomonic of LGV, but only presents in 10% to 20% of cases[35] and is rarely bilateral.[15] In women, ingui-

Figure 173-3 Lymphogranuloma venereum: lymph node involvement. Initially, the overlying skin is erythematous and indurated.

Figure 173-5 Lymphogranuloma venereum: bilateral, firm, immovable masses above the Poupart ligament.

The acute anorectal syndrome is characteriz
perirectal nodal involvement, acute hemorrhagic
titis, and pronounced systemic symptoms. It i
most common presentation in women and in h
sexual men who practice anal sex. The major sou
rectal spread in women is the internal lymphatic c
age of the lower two-thirds of the vagina. Patients
complain of anal pruritus, bloody and/or pur
rectal discharge, tenesmus, diarrhea, constipatior
lower abdominal pain.[36] In a recent outbreak of L

TERTIARY STAGE

This stage is seen more often in women with untreated anorectal syndrome than in men, although it is also seen in homosexual men, because of the location of the involved lymphatics. It includes rectal strictures (most common) and abscesses, perineal sinuses, rectovaginal fistulae (leading to "watering can perineum"), and "lymphorrhoids" (perianal outgrowths of lymphatic tissue). Esthiomene (Greek for "eating away") is a rare primary infection of the external genitalia (mostly in women), leading to progressive lymphangitis and genital destruction. Infertility and "frozen pelvis" are potential sequelae of ruptured deep pelvic nodes in women. Late sequelae of the genital syndrome are less common and include urethral strictures and genital elephantiasis with ulcers and fistulas (in 4% of patients).[40] Penile deformities, such as the saxophone penis, may also occur.[41]

TABLE 173-2
Treatment of Lymphogranuloma Venereum

	DRUG	DOSE	LENGTH OF TREATMENT
First-line	Oral doxycycline	100 mg twice daily	3 weeks
Second-line	Oral azithromycin	1 to 1.5 g once weekly	3 weeks
Third-line	Oral erythromycin	500 mg 4 times daily	3 weeks

24. Seorang perempuan berusia 28 tahun G2P1A0 usia kehamilan 28 minggu berobat ke poliklinik kulit dan kelamin dengan keluhan muncul benjolan pada kemaluan sejak 2 minggu yang lalu. Pasien bekerja sebagai seorang PSK. Pada pemeriksaan fisik ditemukan papul multiple dengan permukaan licin yang tersebar diskret pada regio vulva. Pada pemeriksaan histopatologis ditemukan akantosis, parakeratosis dan rete ridges yang memanjang serta ditemukan gambaran koilosis. Apakah terapi yang tepat pada kasus di atas?

A. Bedah beku

B. Podofilin 25%

C. Interferon-alfa

D. 5- Fluorourasil

E. Imidazoquilinamine

KUTIL ANOGENITAL

- Infeksi menular seksual yang disebabkan oleh *virus papilloma humanus (VPH) tipe* tertentu dengan kelainan pada kulit dan mukosa anogenital
- Sebanyak 90% disebabkan HPV tipe 6 dan tipe 11, masa inkubasi 3 minggu sampai dengan 8 bulan, bahkan sampai dengan 18 bulan

1. Anamnesis

- Benjolan di daerah genital yang tidak nyeri
- Adanya riwayat kontak seksual sebelumnya

2. Pemeriksaan klinis

- Vegetasi atau papul soliter dapat juga multipel
- Terdapat empat morfologi

o Akuminata

o Papul dengan permukaan menyerupai kubah

o Papul keratotik dengan permukaan kasar

o Papul datar

Bentuk lain:

o *Bowenoid papullosis yang merupakan varian lesi papula berbentuk* kubah atau datar, berwarna hitam, dan ditemukan tipe HPV risiko tinggi yaitu tipe 16.

o *Giant condyloma atau Buscke-Lowenstein tumor* yaitu lesi yang berukuran lebih besar, bersifat invasif dan destruktif secara lokal, namun tidak bermetastasis, serta ditemukan HPV tipe 6 dan tipe 11.

- Lesi di perianal dapat ditemukan pada laki-laki dan perempuan tetapi lebih umum ditemukan pada laki-laki yang berhubungan seks dengan laki-laki (LSL)

as bone marrow depression. Podophyllin is not used in pregnancy. Trichloroacetic or bichloroacetic acid in 80–90% solu-

patient in proper use. Imiquimod and podofilox have not been approved for treatment of perianal, rectal, urethral, vaginal, or cervical warts. Safety for use in pregnant patients has not been established for either agent.

Cryotherapy, which destroys the wart and a small area of surrounding tissue through freezing, is recommended for small warts that are not extensive. One to six freeze–thaw cycles per wart per treatment session may be required. Most patients will require one to two treatment sessions per week for an average of 4–6 weeks. A cryoprobe, modified Q-tip, or fine spray is used to apply liquid nitrogen to each wart. Cryotherapy may be painful, and a local anesthetic is recommended unless only one or two small warts are being treated. Safety and efficacy are highly dependent on clinician's skills and training. Podophyllin

Other treatments, including intralesion injection of interferon and 5-fluorouracil/epinephrine gel implants, have been shown to be as effective as the modalities discussed above in clearing warts that are small in number and size. Side-effect profiles and expense have limited the use of these alternative treatment modalities.[322–324]

25. Virus HSV akan terperangkap pd batas membrane basalis dan tidak dapat menyebar masuk ke dermis. Hal tersebut karena pada membrane basalis terdapat:

A. Dermo-epidermal tight junction

B. Heparan sulfat proteoglikan

C. Antigen desmoglein

D. Glikosaminoglikan

E. Aminoglikan

Despite the ability of HSV to infect many cell types, HSV disease is usually localized to the body surface at the site of inoculation and to the sensory and autonomic ganglia of nerves communicating with this site. Undoubtedly, an effective immune response is responsible in part for limiting the spread of infection. The possibility exists, however, that there are nonimmunologic barriers to the spread of infection in the normal adult. For example, certain cell types in fully differentiated tissues may not be able to support HSV replication, due either to inaccessibility or lack of required cell-surface receptors or to lack of other factors needed for biosynthesis of viral components. In addition, the basement membrane underlying epithelial surfaces contains high concentrations of heparan sulfate proteoglycans, which could trap virus and impede its spread to the dermis.[66]

TERIMA KASIH