

# The acute scrotum

**Dr Sanjeev Bandi MBBS.,FRCSI, FRACS(Urology)**  
**Consultant Urologist**  
**Mackay Urology**

# ***Introduction***

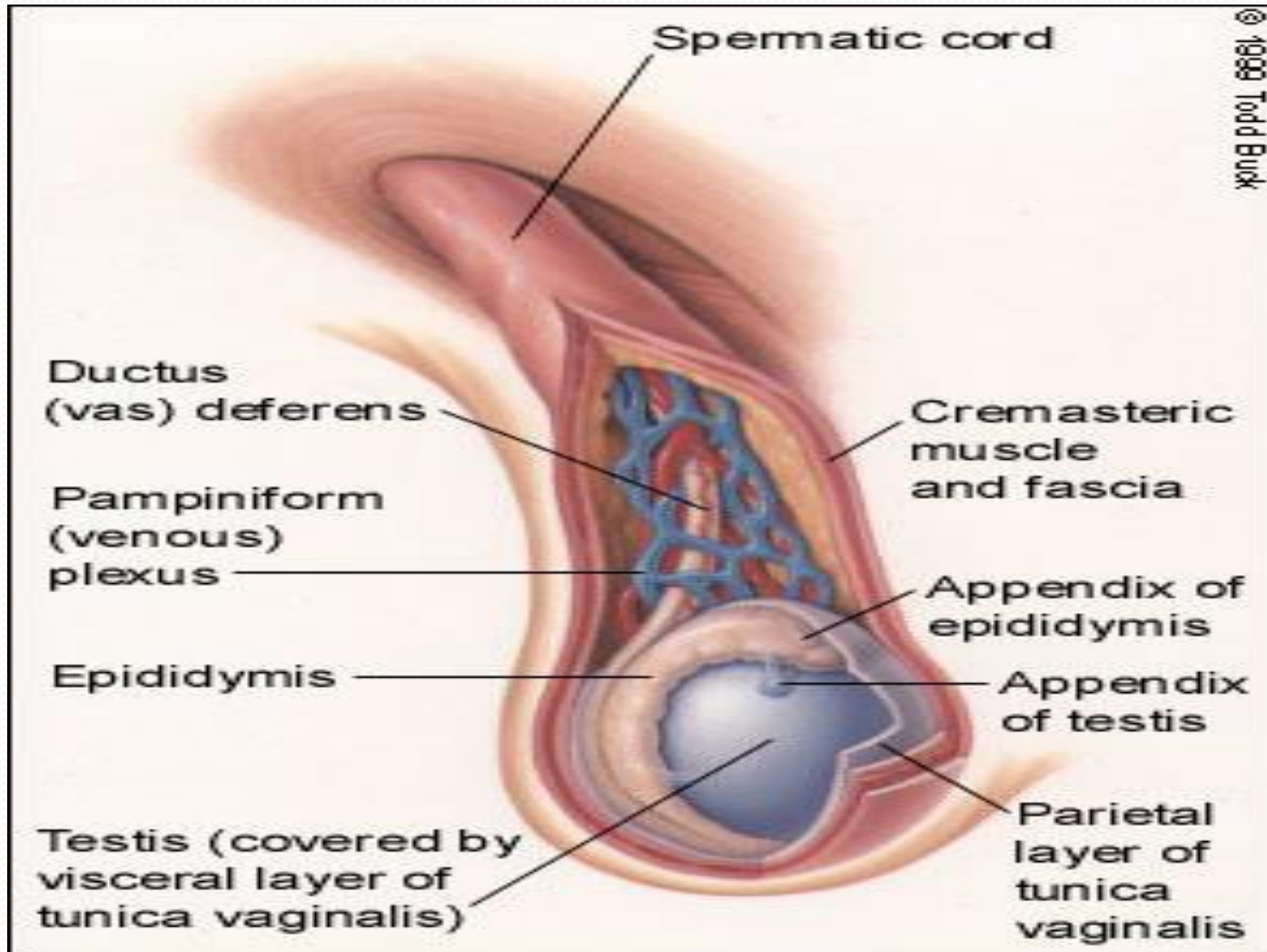
*The spectrum of conditions that affect the scrotum and its contents ranges from incidental findings that may require patient reassurance only OR acute events that may require immediate surgical intervention.*

## ***Normal anatomy***

*The normal testis is oriented in the vertical axis and the epididymis is above the superior pole in the posterolateral position.*

*Cremasteric reflex: Stroking/pinching the inner thigh should result in elevation of  $> 0.5$  cm of the ipsilateral testicle.*

# Normal Anatomy:



# **DIFFERENTIAL DIAGNOSIS**

- *The most common causes of acute scrotal pain in adults are **testicular torsion and epididymitis**.*
- *Other conditions that may result in acute scrotal pathology include Fournier's gangrene, torsion of the appendix testis, trauma/surgery, testicular cancer, strangulated inguinal hernia, Henoch-Schönlein purpura, mumps, and referred pain.*

# Testicular torsion

- Testicular torsion is a **urologic emergency** that is more common in neonates and postpubertal boys, although it can occur at any age [2].
- The prevalence of testicular torsion in adult patients hospitalized with acute scrotal pain is approximately **25 to 50** percent [2,4-7].

# Testicular Torsion

- *Testicular torsion results from inadequate fixation of the testis to the tunica vaginalis producing ischemia from reduced arterial inflow and venous outflow obstruction.*
- *Testicular torsion may occur after an incidental event (eg, trauma) or spontaneously [[10](#)].*

# Testicular Torsion

- *It is generally felt that the testis suffers irreversible damage after 12 hours of ischemia due to testicular torsion [8,9].*
- *Infertility may result, even with a normal contralateral testis, because the disruption of the immunologic "blood-testis" barrier may expose antigens from germ cells and sperm to the general circulation and lead to the development of anti-sperm antibodies.*

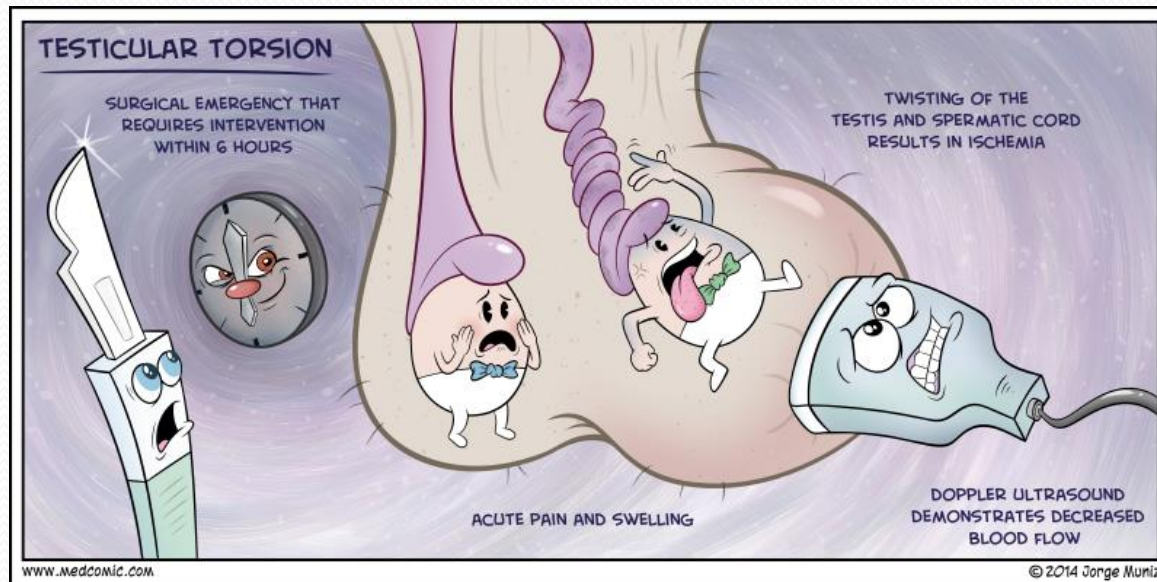


# *Clinical features and diagnosis*

- *The diagnosis of testicular torsion is usually determined by **acute onset** of severe symptoms and characteristic physical findings, although ultrasound may be needed in equivocal cases.*
- *The onset of **pain** in testicular torsion is usually **sudden** and often occurs several hours after vigorous physical activity or minor trauma to the testicles [11].*
- *There may be **associated nausea and vomiting**.*

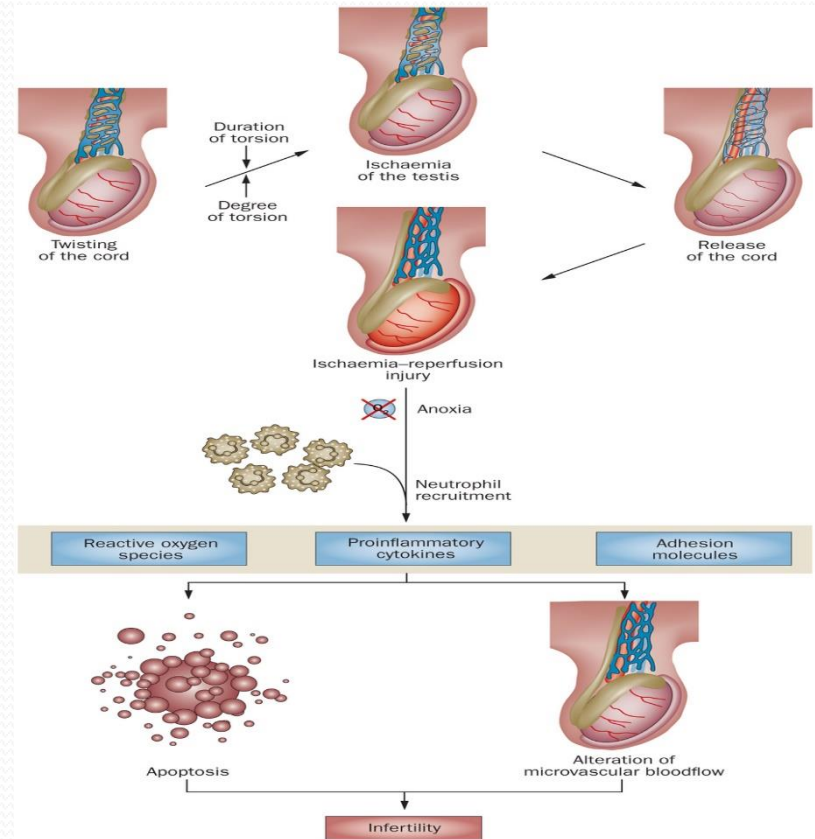
# Testicular Torsion

- Another typical presentation, particularly in **children**, is **awakening with scrotal pain** in the middle of the night or in the morning



# Testicular Torsion

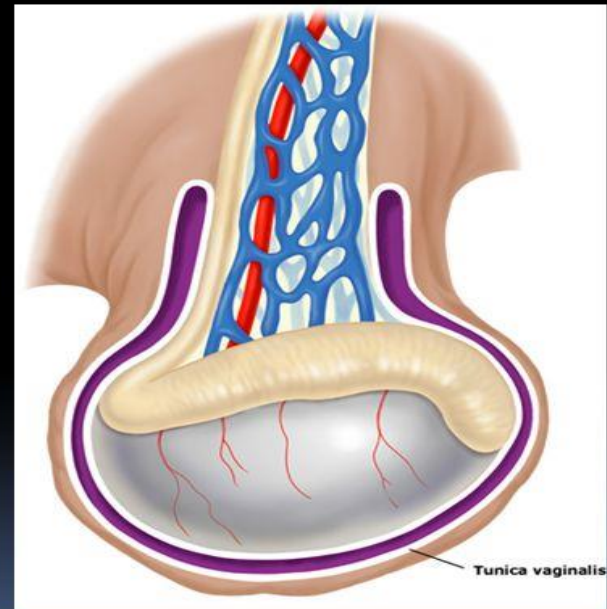
- The classic finding on physical examination is an **asymmetrically high-riding testis** on the affected side with the long axis of the testis oriented transversely instead of longitudinally secondary to shortening of the spermatic cord from the torsion, also called the **“bell clapper deformity”**



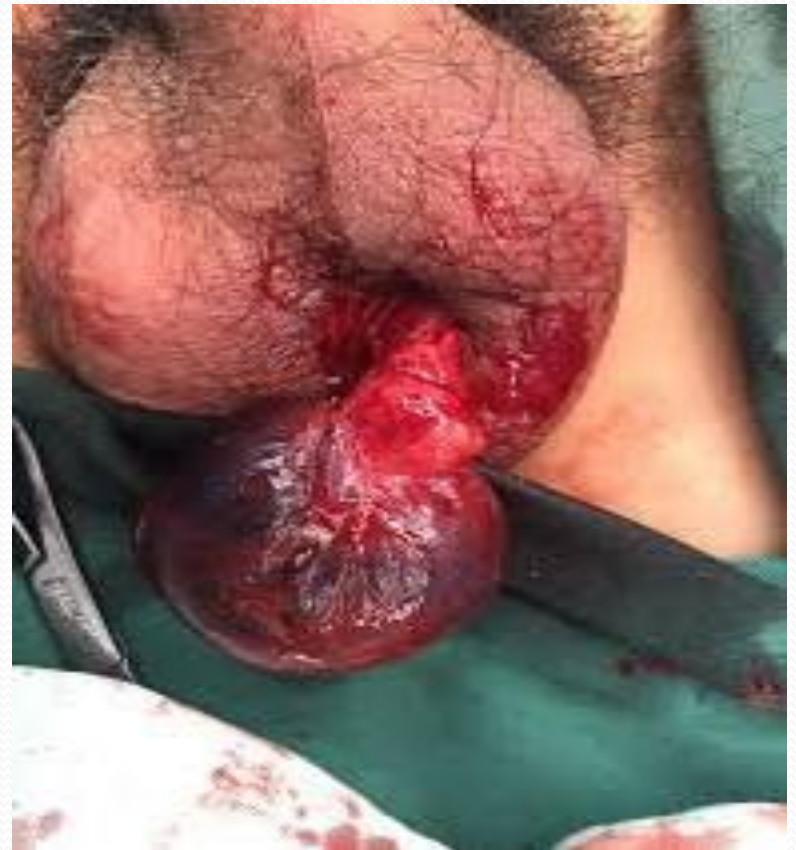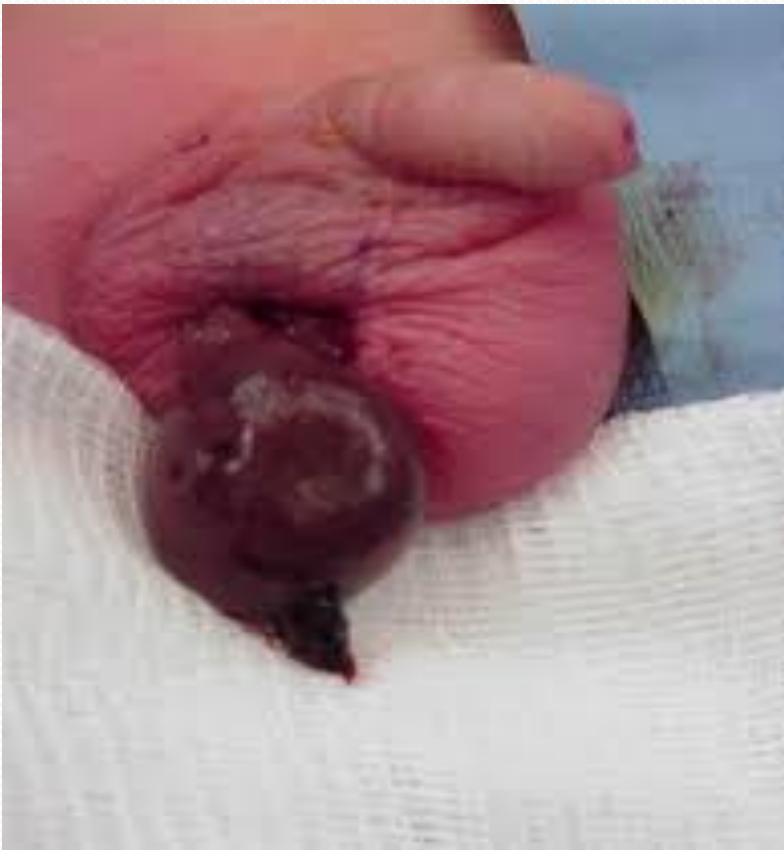# Testicular Torsion

## Predisposing Anatomy

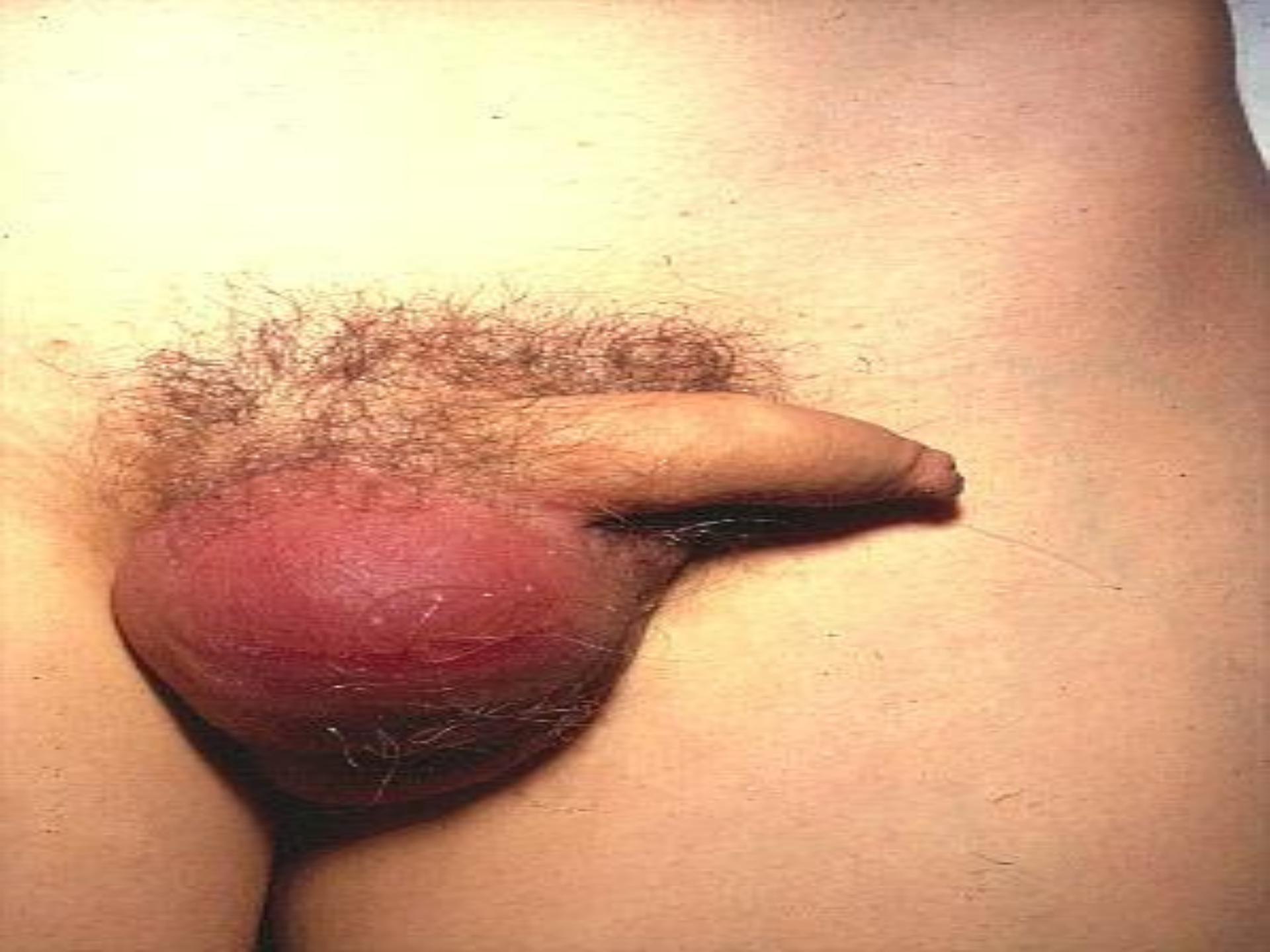- Bell-clapper deformity
  - Testicle lacks normal attachment at vaginalis
  - Increased mobility
  - Transverse lie of testes
  - Typically bilateral
  - Prevalence 1/125



# Testicular Torsion







# *The cremasteric reflex*

- *A normal response is cremasteric contraction with elevation of the testis.*
- *The reflex is usually absent in patients with testicular torsion .*
- *This helps **distinguish testicular torsion from epididymitis and other causes of scrotal pain**, in which the reflex is typically intact [[1](#)].*

# Testicular Torsion

- **Prehn's sign:** *Relief of scrotal pain by elevating testicle. NOT a reliable way to distinguish epididymitis from torsion*



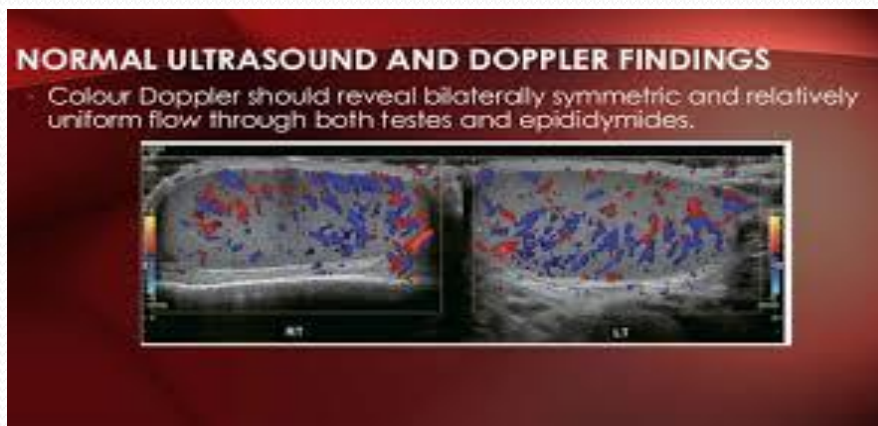
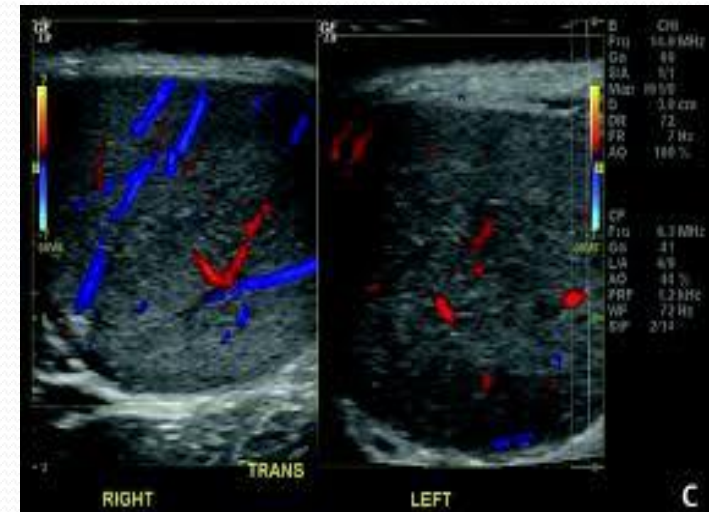
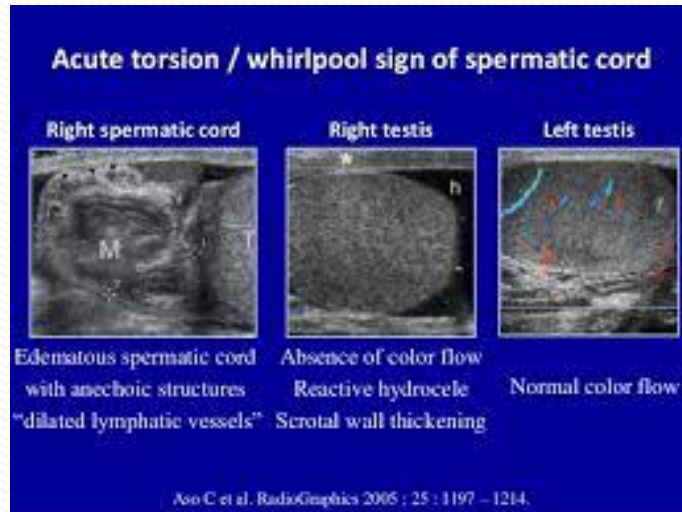
# Imaging

- *If the etiology of an acute scrotal process is equivocal after history and physical examination, **color Doppler ultrasonography** is the diagnostic test of choice to differentiate testicular torsion from other causes, including epididymitis.*
- *lack of immediate access to scrotal ultrasound **should not delay surgical exploration.***

# Testicular Torsion

- *In a study of 56 patients who underwent surgical exploration for acute scrotal pain and had Doppler ultrasound examinations performed preoperatively [4] (sensitivity 100 percent and specificity 97 percent).*

# Testicular Torsion - Imaging



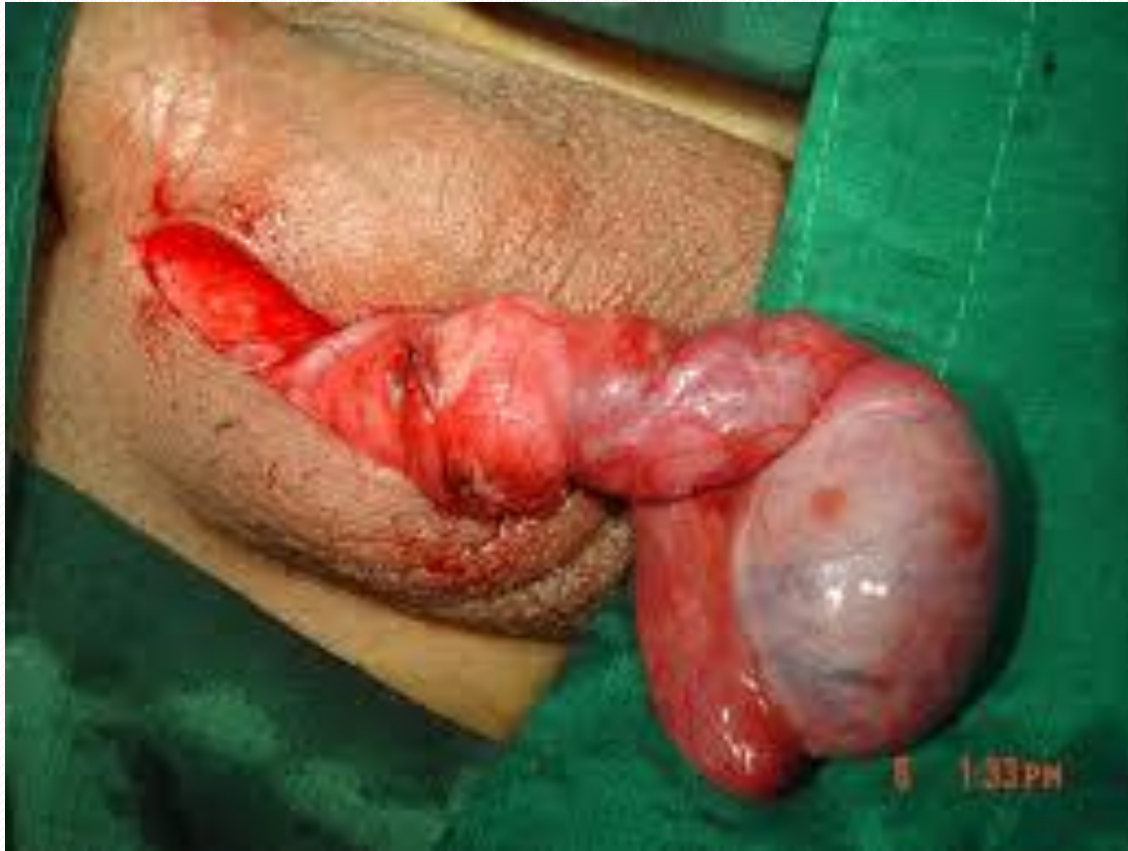# Treatment

- Treatment for suspected testicular torsion is **immediate surgical exploration with intraoperative detorsion and fixation of the testes.**
- Delay in **detorsion** of a few hours may lead to progressively higher rates of **nonviability** of the testis.
- Manual **detorsion** is performed if surgical intervention is not immediately available.

# Surgery

- *Detorsion and fixation of both the involved testis and the contralateral uninvolved testis should be done since inadequate gubernacular fixation is usually a bilateral defect.*
- *Longer periods of ischemia (>12 hours) may cause infarction of the testis with liquefaction requiring **orchietomy**.*

# Testicular Torsion



# *Manual detorsion*

- *If surgery is not immediately available (within two hours), it is reasonable to attempt to manually detorse the testicle [16].*
- *The classic teaching is that the testis usually rotates medially during torsion and can be **detorted** by rotating it outward toward the thigh.*

# Testicular Torsion

- *However, in a retrospective analysis of 200 consecutive males age 18 months to 20 years who underwent surgical exploration for testicular torsion, lateral rotation was present in one-third of cases [17].*



**successful detorsion is suggested by [18]:**

- *Relief of pain*
- *Resolution of the transverse lie of the testis to a longitudinal orientation*
- *Lower position of the testis in the scrotum*
- *Return of normal arterial pulsations detected with a color Doppler study*

# Testicular Torsion

- *Surgical exploration is necessary even after clinically successful manual detorsion because orchiopexy (securing the testicle to the scrotal wall) must be performed to prevent recurrence, and residual torsion may be present that can be further relieved [17].*

# Testicular Torsion

Timely torsion diagnosis, orchidopexy could have saved testicle, medical expert argues

October 01, 2016

By Dawn Collins, JD



Dawn Collins,  
JD

A 16-year-old Massachusetts boy presented to the hospital emergency room with complaints of intense right-sided testicular pain for over 2 hours. He was diagnosed with testicular torsion by an attending nurse practitioner.

**Related - [Offensive disclosure and defensive medicine: What you need to know](#)**

The on-call urologist was informed of the diagnosis, but declined to come to the ER and consult with the patient because the ultrasound was not available after 11 p.m. The urologist suggested the boy be transferred to another hospital.

The teen was then transferred to a second hospital, where an evaluation revealed right scrotal erythema and swelling. The testicular lie felt transverse and tender to palpation. No right cremasteric reflex was observed, and the left scrotal sac appeared normal and non-tender.

A testicular ultrasound revealed diffuse diminished flow throughout the right testis, highly suggestive of testicular torsion. A left-side varicocele was also noted. The on-call urologist was consulted by phone and exploratory surgery was ordered. The patient underwent surgery, but the right testicle could not be saved. A right orchiectomy and a left orchidopexy were performed. A \$750,000 settlement was reached.

# Epididymitis

- *Epididymitis is the **most common cause** of scrotal pain in adults in the outpatient setting [[19](#)].*
- *Epididymitis is most commonly infectious in etiology, but can also be due to noninfectious causes (eg, trauma, autoimmune disease) [[22](#)].*

# ***Clinical features and diagnosis***

- *In acute infectious epididymitis, palpation reveals induration and swelling of the involved epididymis with tenderness.*
- *More advanced cases often present with testicular swelling and pain (epididymo-orchitis) with scrotal wall erythema and a reactive hydrocele.*

# Investigations

- *A **urinalysis and urine culture** should be performed in all patients suspected of epididymitis, although urine studies are often negative in patients without urinary complaints [8].*
- *A **urethral swab** should be obtained in patients with urethral discharge and sent for culture*
- ***Ultrasound** should be performed in patients with acute onset of testicular pain to assess for testicular torsion.*

# *Treatment*

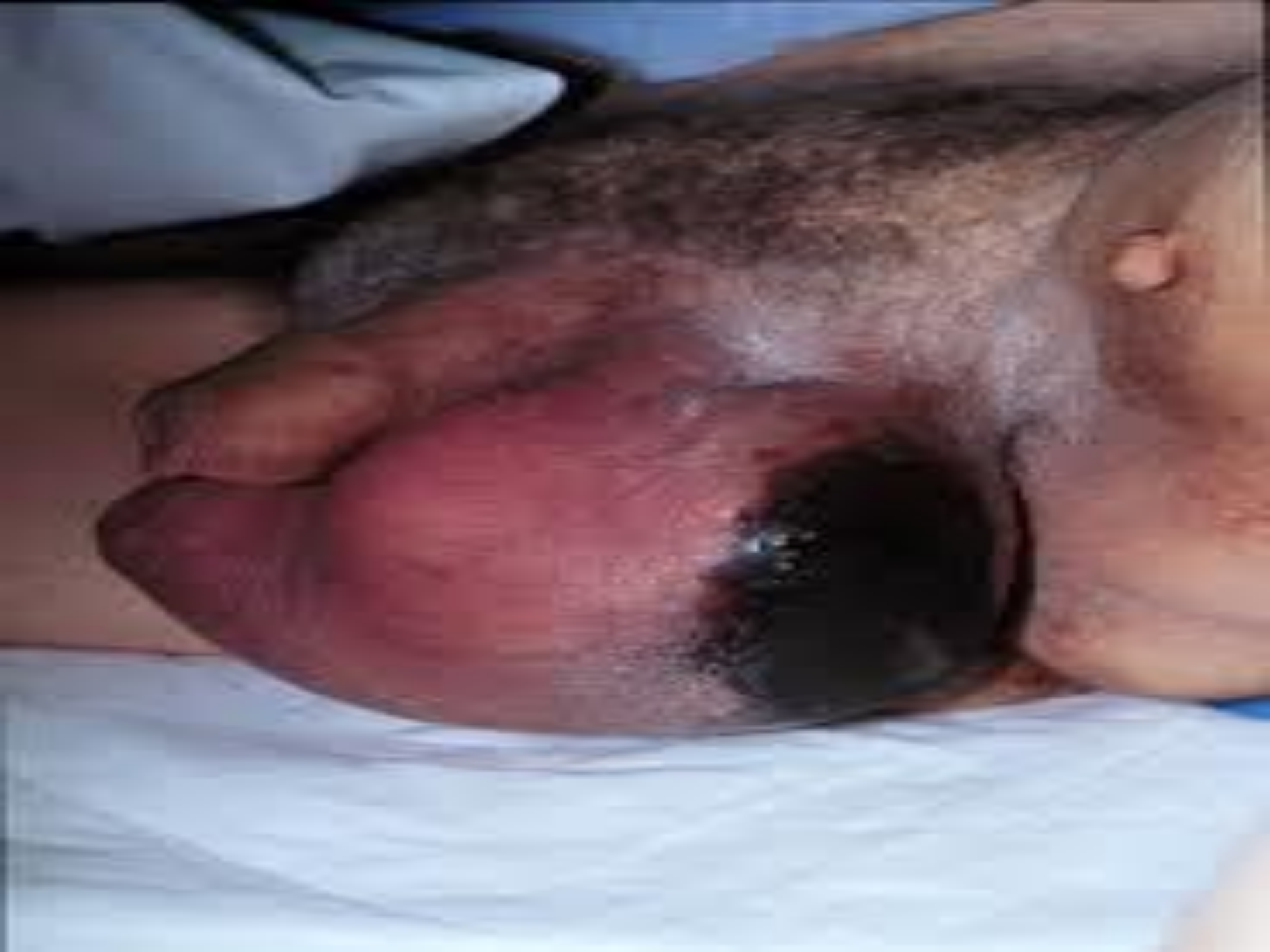- *Acutely febrile patients with sepsis often require hospitalization for intravenous hydration and parenteral antibiotics. Ice, scrotal elevation, and nonsteroidal antiinflammatory drugs (NSAIDs) are helpful adjuncts.*
- *Less severe cases can be treated on an outpatient basis with oral antibiotics, ice, and scrotal elevation).*

- *Regimens that cover C. trachomatis and N. gonorrhoeae. The first-line treatment regimen includes ceftriaxone (250 mg intramuscular injection in one dose) plus doxycycline (100 mg by mouth twice a day for ten days).*
- *Quinolones alone are no longer recommended for the treatment of epididymitis if N. gonorrhoeae is suspected (eg, in patients with acute urethritis or proctitis, high risk for sexually transmitted disease),*

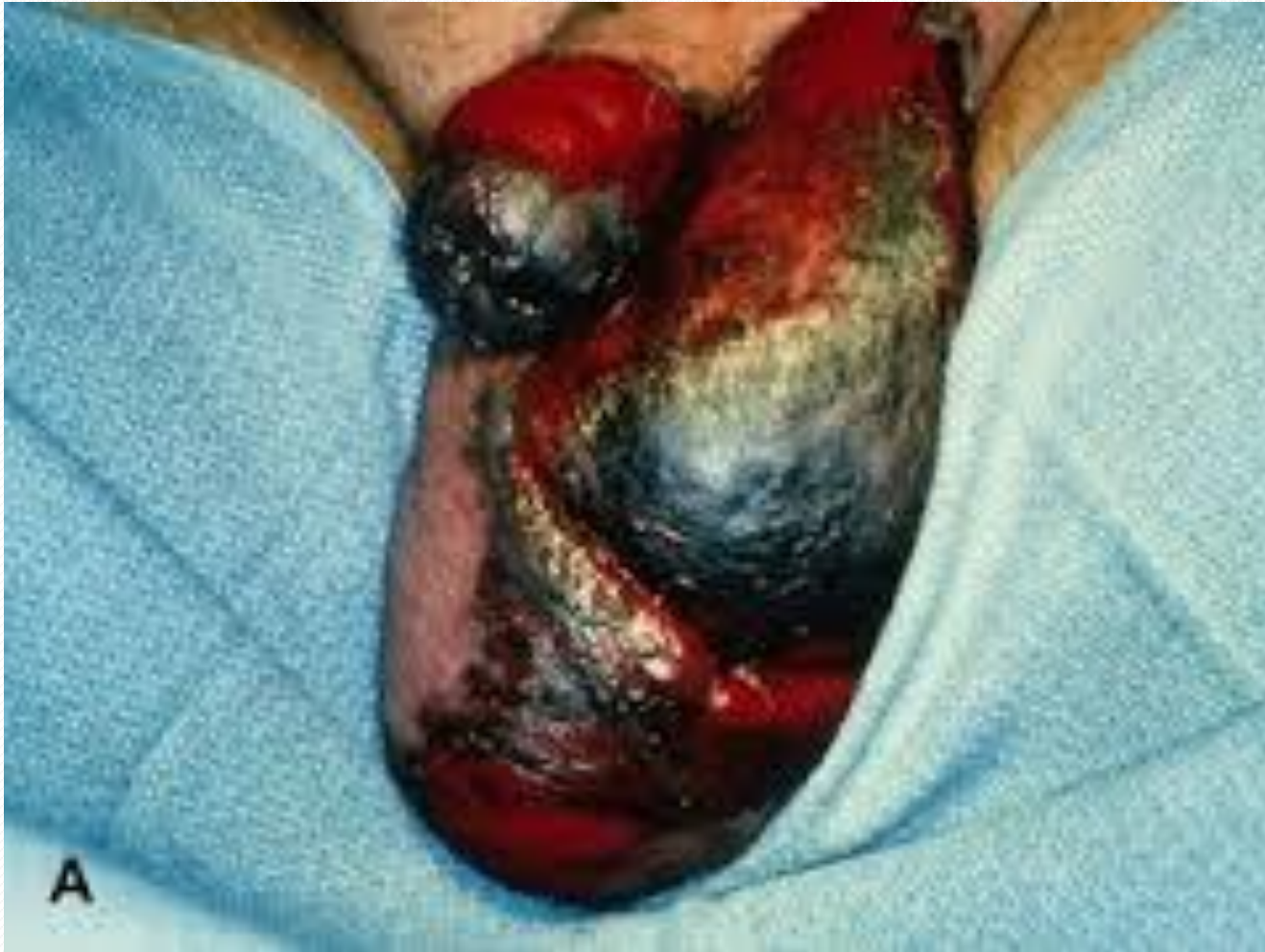

# ***Fournier's gangrene***

- *Fournier's gangrene is a **necrotizing fasciitis of the perineum** caused by a mixed infection with aerobic/anaerobic bacteria, which often involves the scrotum.*
- *Characterized by severe pain that generally starts on the anterior abdominal wall, migrates into the gluteal muscles and onto the scrotum and penis*



# Fournier's gangrene sec to LGV



# *Treatment*

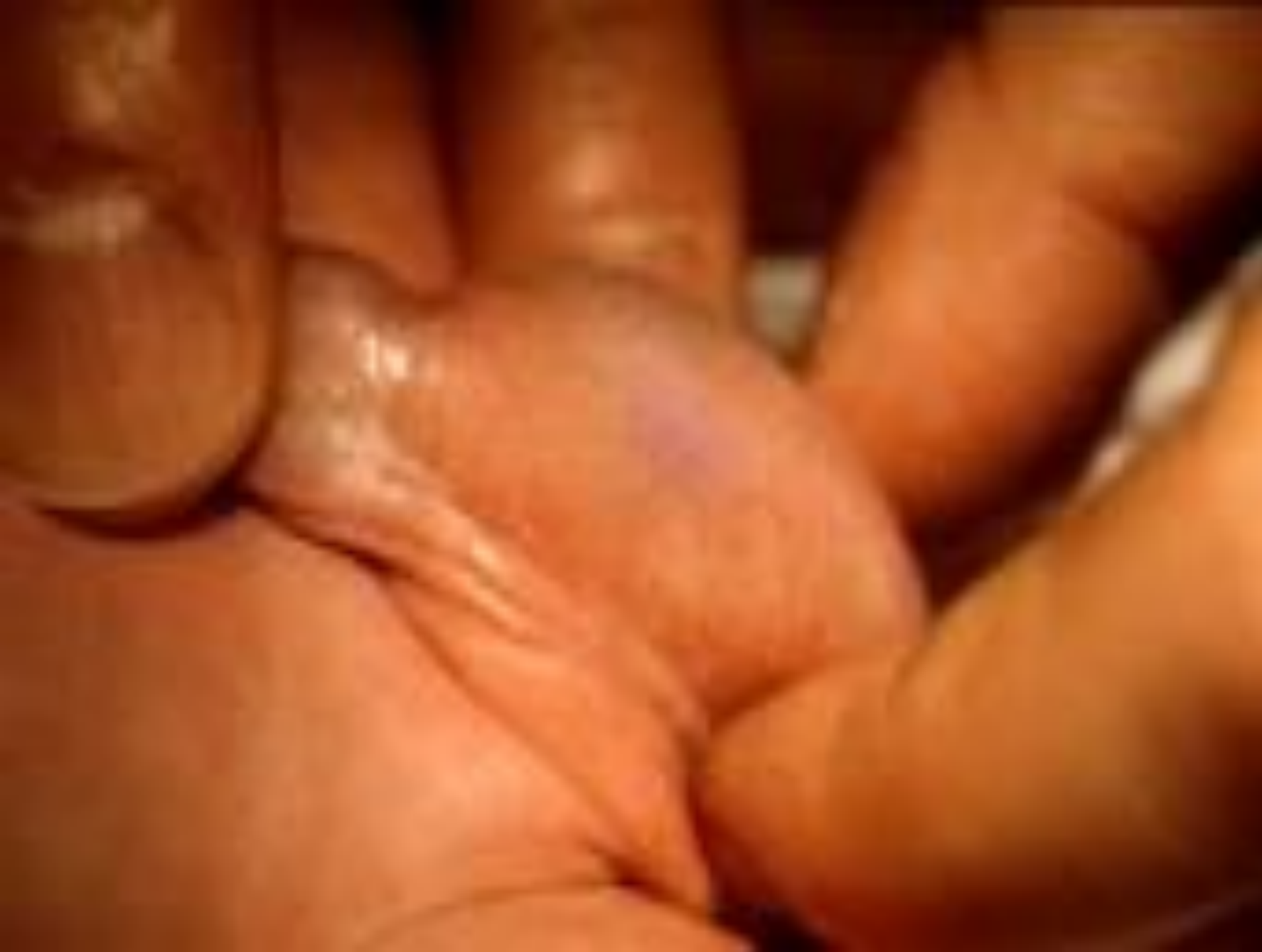- *Treatment of necrotizing fasciitis consists of early and aggressive surgical exploration and debridement of necrotic tissue, antibiotic therapy, and hemodynamic support as needed.*
- *Antibiotic therapy alone is usually associated with a 100 percent mortality rate, highlighting the need for surgical debridement.*

*Other causes*

# ***Torsion of the appendix testis***

- *Testicular pain from torsion of the appendix testis is usually more gradual than with testicular torsion. It is the leading cause of acute scrotal pathology in childhood. Torsion of the appendix testis rarely occurs in adults [29].*
- *It is not uncommon for patients to have several days of scrotal discomfort before they present for evaluation. Pain ranges widely from mild to severe.*
- *Careful inspection of the scrotal wall at this location may detect the classic "blue dot" sign caused by infarction and necrosis of the appendix testis .*





# *management*

- *Management of acute torsion of the appendix testis usually includes conservative treatment, which includes rest, ice, and NSAIDs.*
- *Recovery is generally slow with this approach, and pain may last for several weeks to months.*
- *Surgical excision of the appendix testis is reserved for patients who have persistent pain.*



# Trauma

- *only rarely does trauma result in severe testicular injury, usually due to compression of the testis against the pubic bones from a direct blow or straddle injury.*
- *The spectrum of traumatic complications can range from a hematocele to infection with pyocele to testicular rupture..*
- *Testicular rupture requires surgical repair. Lesser injuries are managed according to the clinical severity and often can be treated conservatively.*



# *Testicular cancer*

- *While most testicular tumors present as painless nodules or masses, rapidly growing germ cell tumors may cause acute scrotal pain secondary to hemorrhage and infarction.*
- *A mass is generally palpable, and ultrasound is usually sufficient to make a diagnosis of testicular cancer.*

# Referred pain

- *Men who have the acute onset of scrotal pain without local inflammatory signs or a scrotal mass on examination may be suffering from referred pain to the scrotum.*
- *The diseases that may cause referred scrotal pain are diverse, reflecting the anatomy of the three somatic nerves that travel to the scrotum: the genitofemoral, ilioinguinal, and posterior scrotal nerves [[31](#)].*

# *Referred pain*

## **Causes of referred pain include :**

- *abdominal aortic aneurysm*
- *urolithiasis*
- *lower lumbar or sacral nerve root compression*
- *retrocecal appendicitis*
- *retroperitoneal tumor*
- *Post herniorrhaphy pain.*

# Summary

## Distinguishing conditions responsible for acute scrotal pain in adults

	Symptom onset	Pain location	Cremasteric reflex	Other clinical findings
Testicular torsion	Acute	Testis	Negative	High riding testis, bell-clapper deformity, profound testicular swelling
Epididymitis	Acute or chronic	Epididymis	Positive	Epididymal induration and tenderness, positive urinalysis or culture
Fournier's gangrene	Acute	Diffuse	Positive	Tense edema outside of involved skin, blisters/bullae, crepitus, fever, rigors, hypotension
Appendiceal torsion	Subacute	Upper pole of testis	Positive	Blue dot sign, tenderness over anterosuperior testis

# References

- 1-Rabinowitz R. The importance of the cremasteric reflex in acute scrotal swelling in children. J Urol 1984; 132:89.
- 2-Molokwu CN, Somani BK, Goodman CM. Outcomes of scrotal exploration for acute scrotal pain suspicious of testicular torsion: a consecutive case series of 173 patients. BJU Int 2011; 107:990.
- 3-Cummings JM, Boullier JA, Sekhon D, Bose K. Adult testicular torsion. J Urol 2002; 167:2109.
- 4-al Mufti RA, Ogedegbe AK, Lafferty K. The use of Doppler ultrasound in the clinical management of acute testicular pain. Br J Urol 1995; 76:625.
- 5-Watkin NA, Reiger NA, Moisey CU. Is the conservative management of the acute scrotum justified on clinical grounds? Br J Urol 1996; 78:623.

# References

- 6- Tajchner L, Larkin JO, Bourke MG, et al. Management of the acute scrotum in a district general hospital: 10-year experience. ScientificWorldJournal 2009; 9:281.
- 7- Hegarty PK, Walsh E, Corcoran MO. Exploration of the acute scrotum: a retrospective analysis of 100 consecutive cases. Ir J Med Sci 2001; 170:181.
- 8- Wampler SM, Llanes M. Common scrotal and testicular problems. Prim Care 2010; 37:613.
- 9- Dunne PJ, O'Loughlin BS. Testicular torsion: time is the enemy. Aust N Z J Surg 2000; 70:441.
- 10- Jarow JP, Sanzone JJ. Risk factors for male partner antisperm antibodies. J Urol 1992; 148:1805.
- 11- Schmitz D, Safranek S. Clinical inquiries. How useful is a physical exam in diagnosing testicular torsion? J Fam Pract 2009; 58:433.

# References

- 12- Wilbert DM, Schaerfe CW, Stern WD, et al. Evaluation of the acute scrotum by color-coded Doppler ultrasonography. J Urol 1993; 149:1475.
- 13- Kapasi Z, Halliday S. Best evidence topic report. Ultrasound in the diagnosis of testicular torsion. Emerg Med J 2005; 22:559.
- 14- Pepe P, Panella P, Pennisi M, Aragona F. Does color Doppler sonography improve the clinical assessment of patients with acute scrotum? Eur J Radiol 2006; 60:120.
- 15- Liguori G, Bucci S, Zordani A, et al. Role of US in acute scrotal pain. World J Urol 2011; 29:639.
- 16- Cornel EB, Karthaus HF. Manual derotation of the twisted spermatic cord. BJU Int 1999; 83:672.
- 17- Sessions AE, Rabinowitz R, Hulbert WC, et al. Testicular torsion: direction, degree, duration and disinformation. J Urol 2003; 169:663.



# References

- 18- Perron, CE. Pain--Scrotal. In: Textbook of Pediatric Emergency Medicine, 4th ed, Fleisher, GR, Ludwig, S (Eds), Lippincott, Williams & Wilkins, Philadelphia 2000. p.473.
- 19- Trojian TH, Lishnak TS, Heiman D. Epididymitis and orchitis: an overview. Am Fam Physician 2009; 79:583.
- 20- Workowski KA, Berman S, Centers for Disease Control and Prevention (CDC). Sexually transmitted diseases treatment guidelines, 2010. MMWR Recomm Rep 2010; 59:1.
- 21- Tracy CR, Steers WD, Costabile R. Diagnosis and management of epididymitis. Urol Clin North Am 2008; 35:101.
- 22- Lewis AG, Bukowski TP, Jarvis PD, et al. Evaluation of acute scrotum in the emergency department. J Pediatr Surg 1995; 30:277.
- 23- Siegel A, Snyder H, Duckett JW. Epididymitis in infants and boys: underlying urogenital anomalies and efficacy of imaging modalities. J Urol 1987; 138:1100.

# References

- 24- Doble A, Taylor-Robinson D, Thomas BJ, et al. Acute epididymitis: a microbiological and ultrasonographic study. Br J Urol 1989; 63:90.
- 25- Hawkins DA, Taylor-Robinson D, Thomas BJ, Harris JR. Microbiological survey of acute epididymitis. Genitourin Med 1986; 62:342.
- 26- Updated recommended treatment regimens for gonococcal infections and associated conditions -- United States, April 2007. (<file:///www.cdc.gov/std/treatment/2010/epididymitis.htm>). Accessed on June 6, 2011.
- 27- Fisher R, Walker J. The acute paediatric scrotum. Br J Hosp Med 1994; 51:290.
- 28- Palestro CJ, Manor EP, Kim CK, Goldsmith SJ. Torsion of a testicular appendage in an adult male. Clin Nucl Med 1990; 15:515.