

Brachial Plexus

"You Young Mermaids LINE UP in front of Poseidon's U L T R A TRIDENT."

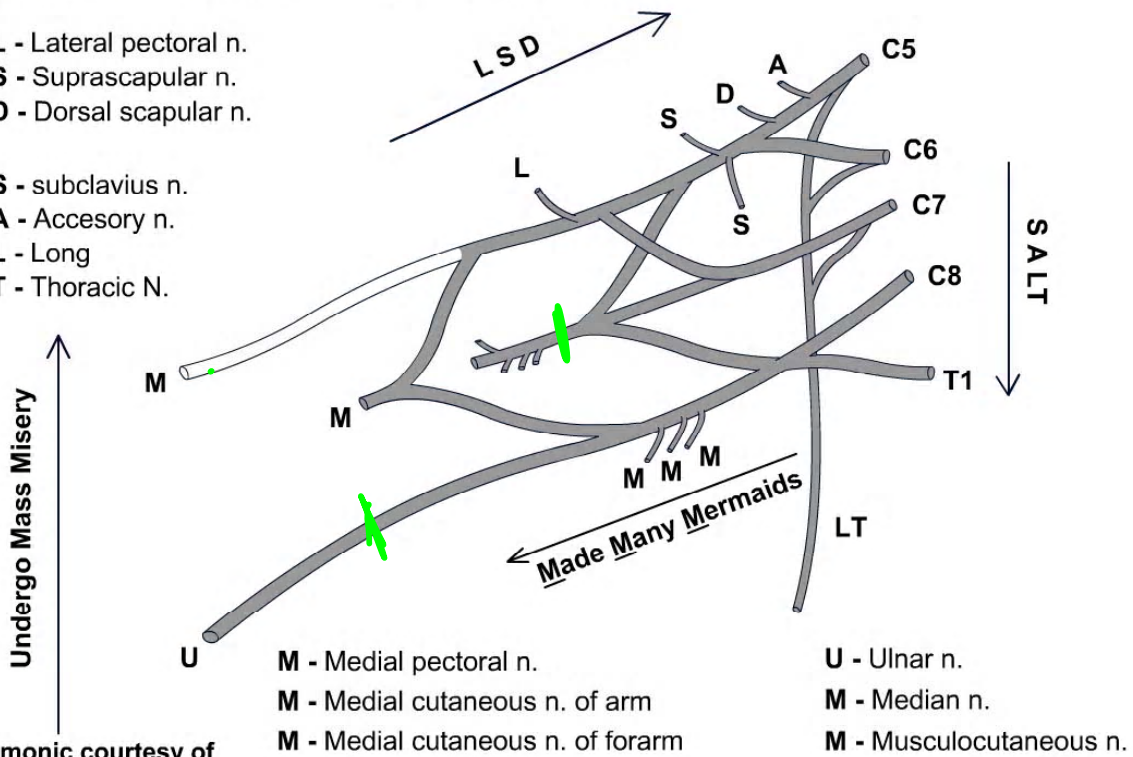
"LSD SALT Made Many Mermaids Undergo Mass Misery!"

"You Young Mermaids LINE UP in front of Poseidon's U L T R A TRIDENT."

"LSD SALT Made Many Mermaids Undergo Mass Misery!"

- L - Lateral pectoral n.
- S - Suprascapular n.
- D - Dorsal scapular n.

- S - subclavius n.
- A - Accessory n.
- L - Long
- T - Thoracic N.

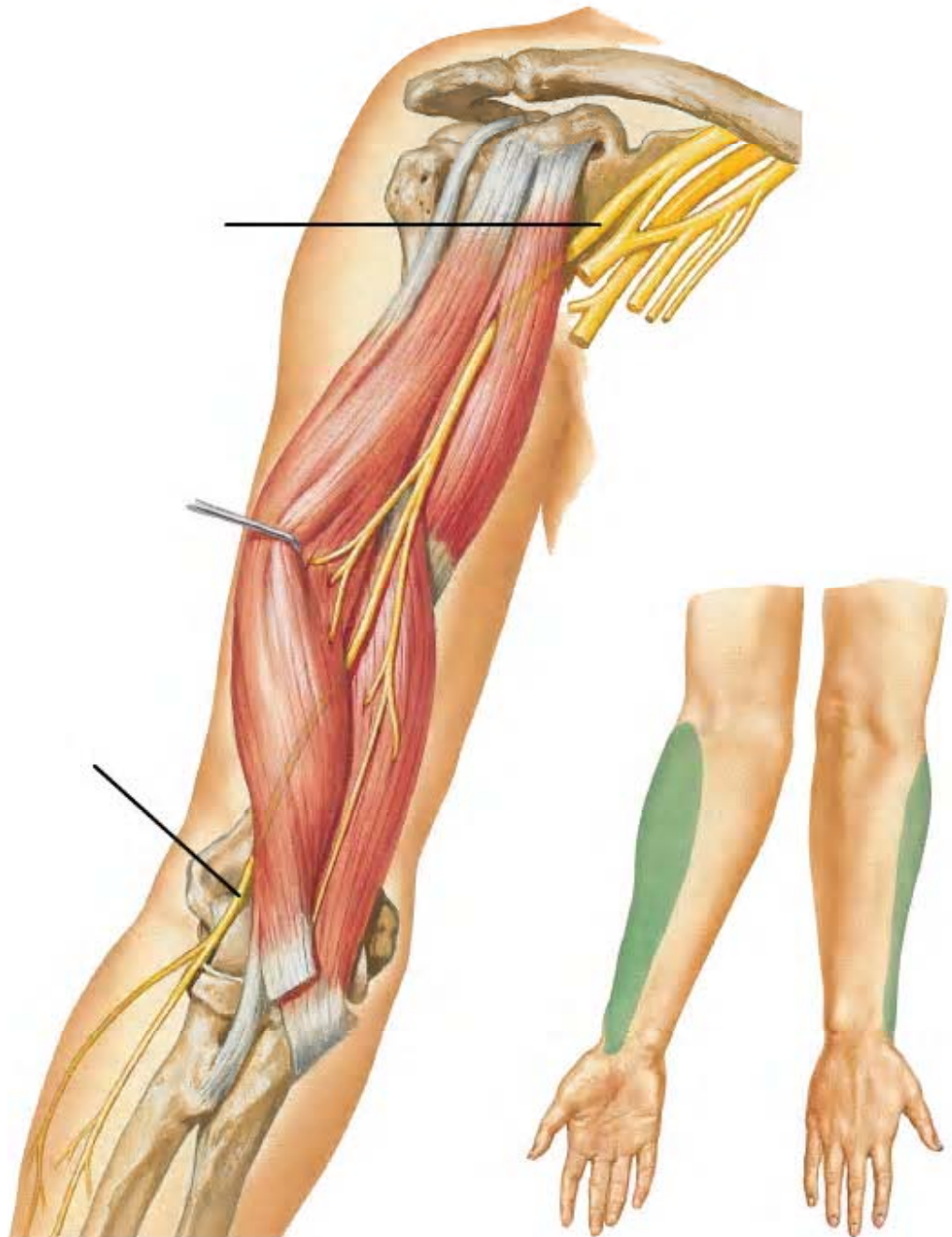


- M - Medial pectoral n.
- M - Medial cutaneous n. of arm
- M - Medial cutaneous n. of forearm

- U - Ulnar n.
- M - Median n.
- M - Musculocutaneous n.

M mnemonic courtesy of
Mark Nielsen
Gross Anatomy

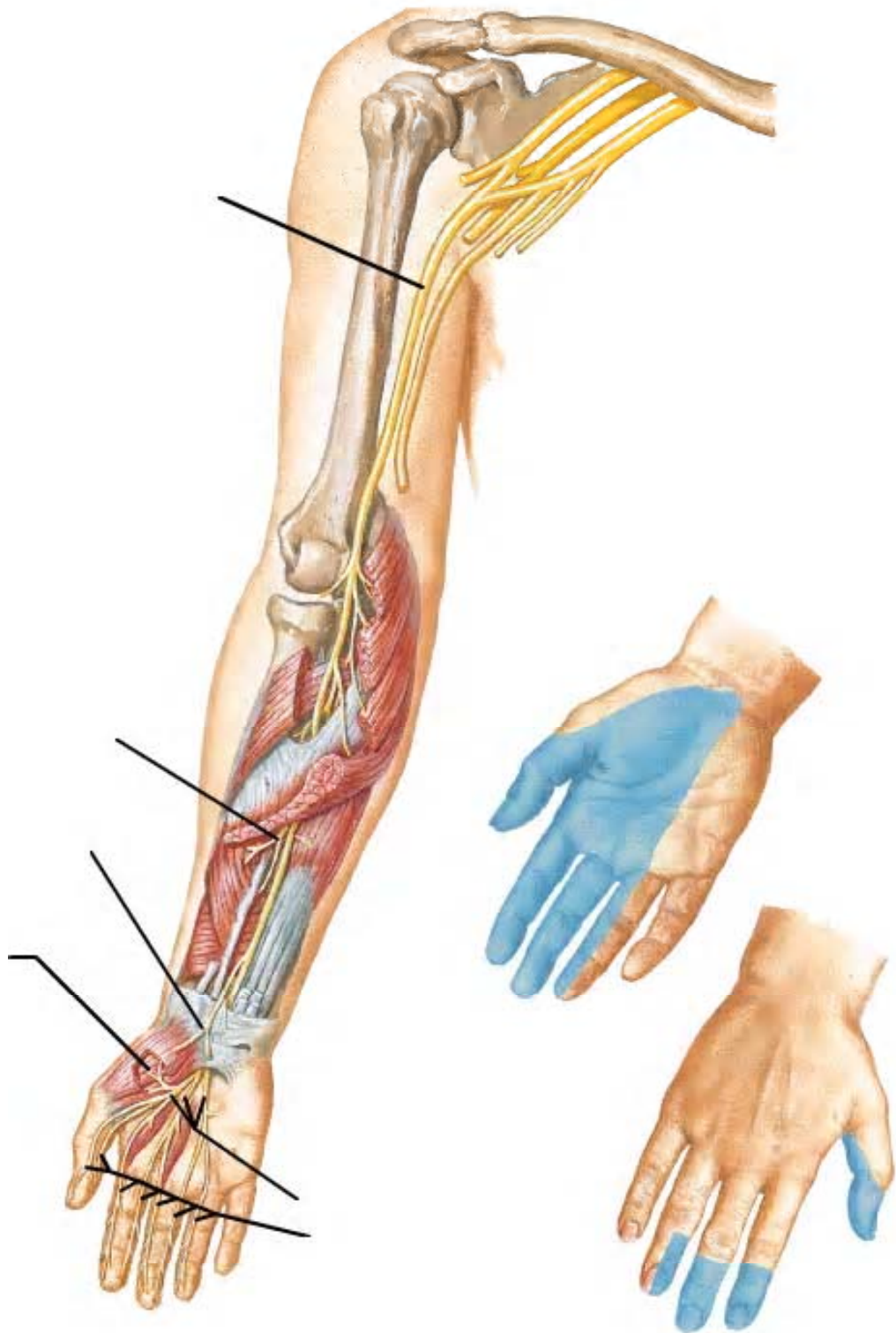
Musculocutaneous Nerve



Netter Presenter Image Copyright
2005, Icon Learning Systems. All

Gross Anatomy

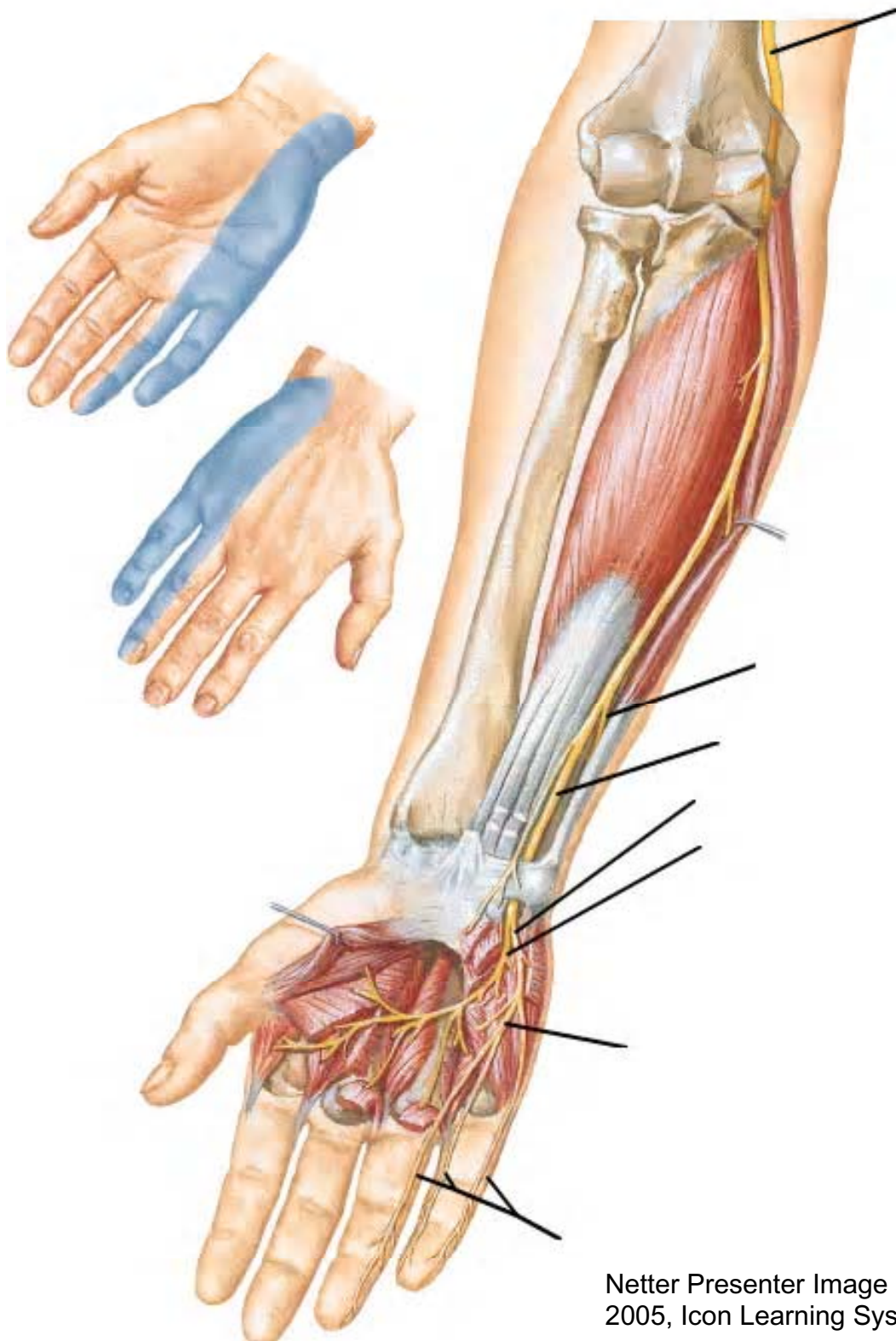
Median Nerve



Netter Presenter Image Copyright
2005, Icon Learning Systems. All

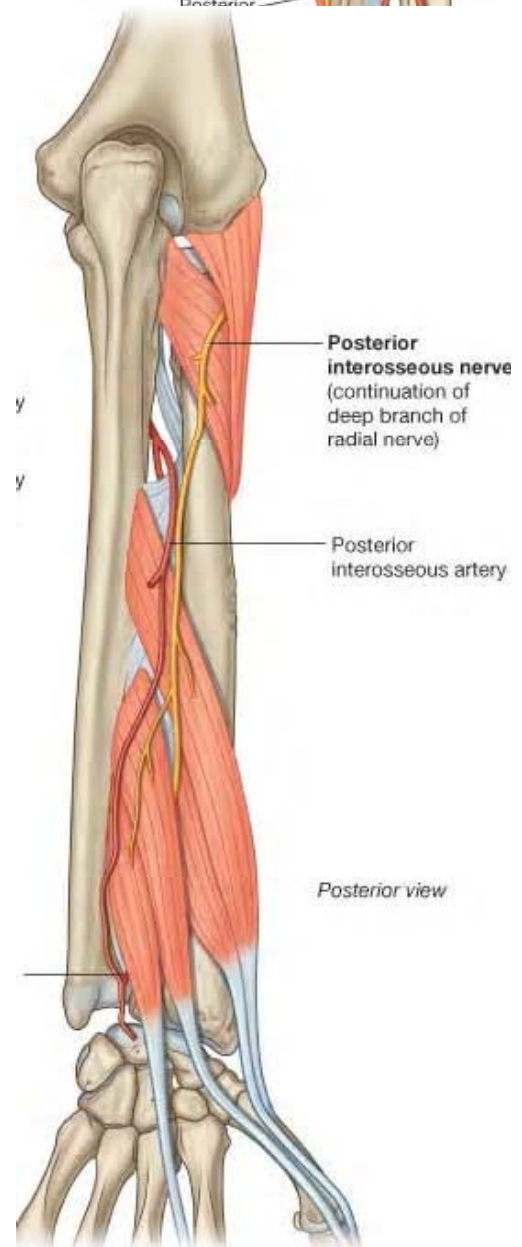
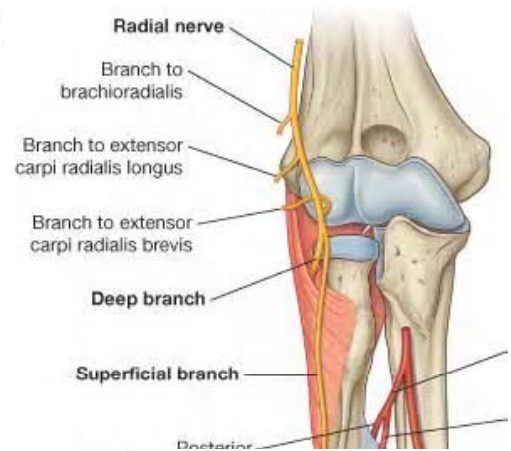
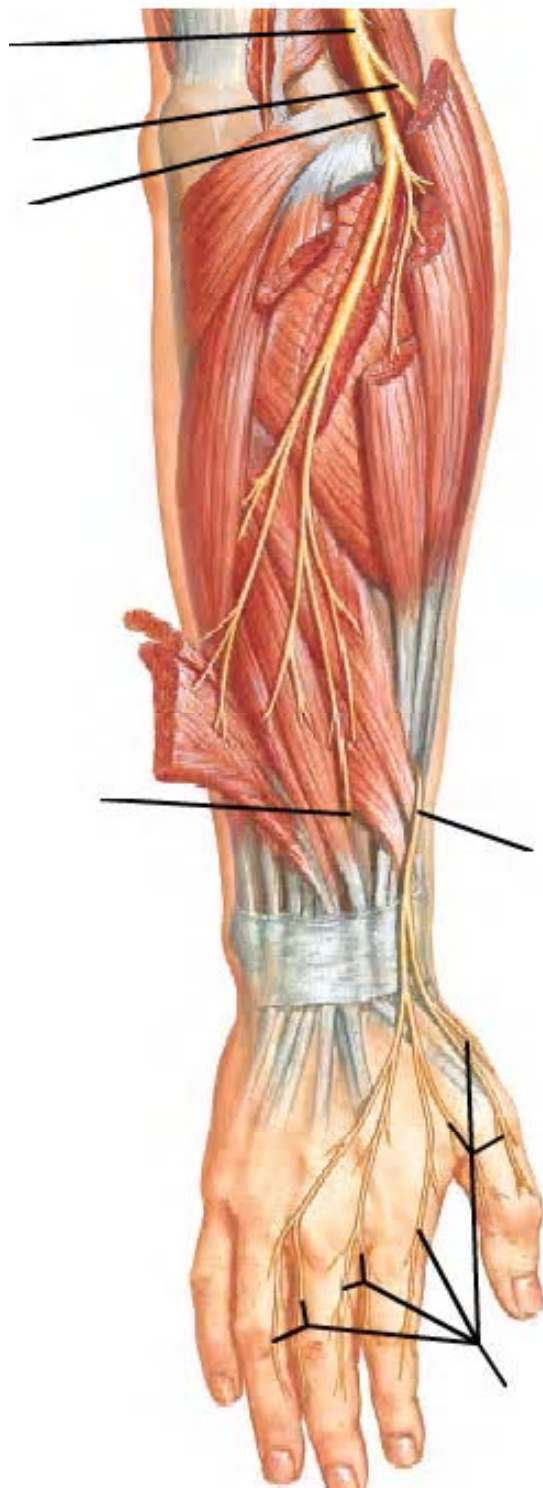
Gross Anatomy

Ulnar Nerve



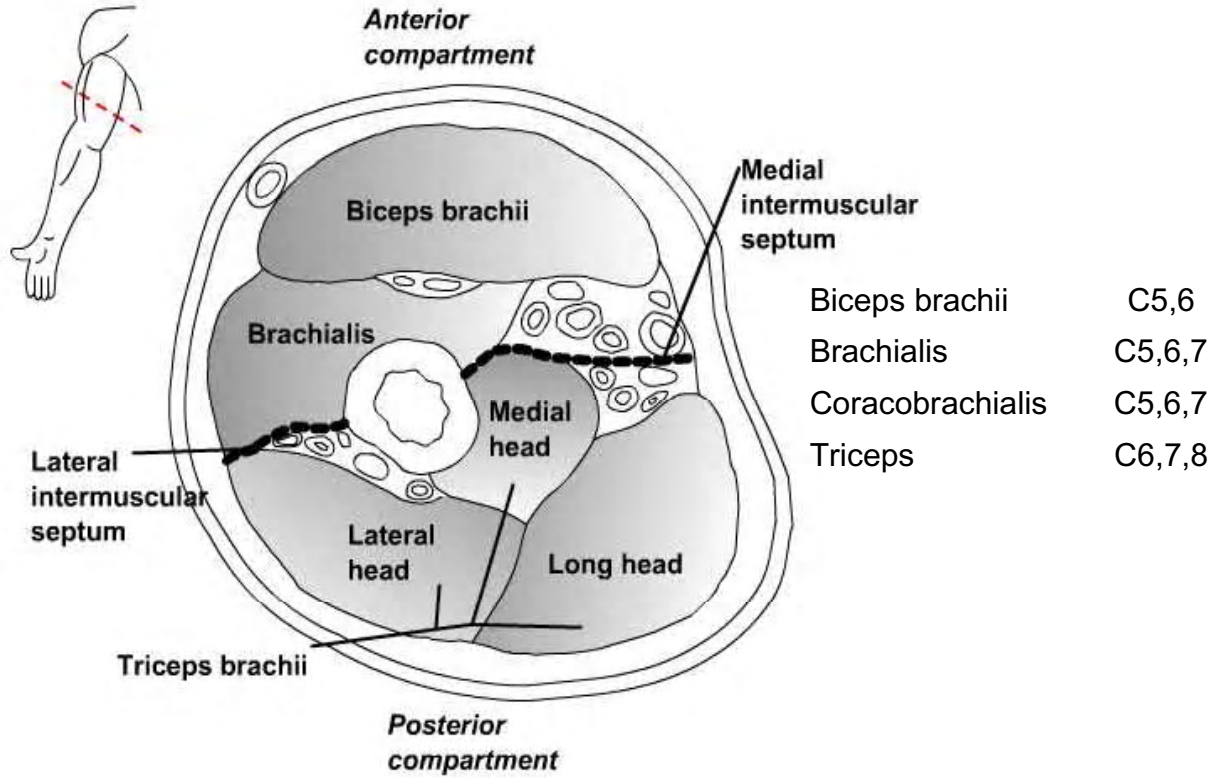
Netter Presenter Image Copyright 2005, Icon Learning Systems. All

Radial Nerve in the Forearm

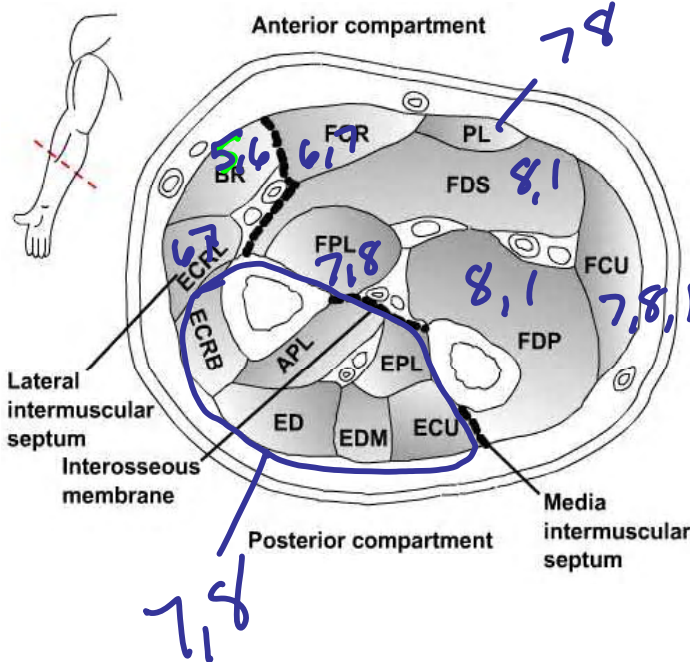


Netter Presenter Image Copyright 2005, Icon Learning Systems. All

Gross Anatomy



Compartments of the forearm

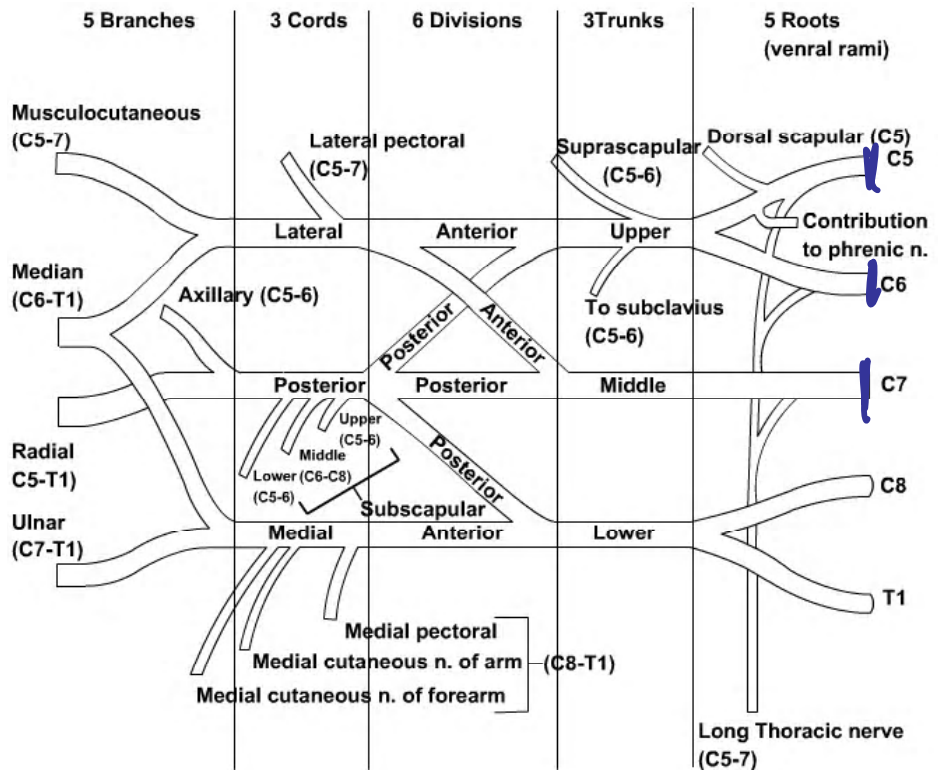


BR	Brachioradialis	C5,6
FCR	Flexor carpi radialis	C6,7
PL	Palmaris longus	C7,8
FDS	Flexor digitorum superficialis	C8,T1
FPL	Flexor pollicis longus	C7,8
FCU	Flexor carpi ulnaris	C7,8,T1
FDP	Flexor digitorum profundus	C8,T1
ECU	Extensor carpi ulnaris	C7,8
EDM	Extensor digiti minimi	C7,8
ED	Extensor digitorum	C7,8
EPL	Extensor pollicis longus	C7,8
APL	Abductor pollicis longus	C7,8
ECRB	Extensor carpi radialis brevis	C7,8
ECRL	Extensor carpi radialis longus	C6,7

Pronator Teres	C6,7
Pronator Quadratus	C7,8
Supinator	C6,7
Extensor pollicis brevis	C7,8
Extensor indicis	C7,8
Anconeus	C6,7,8

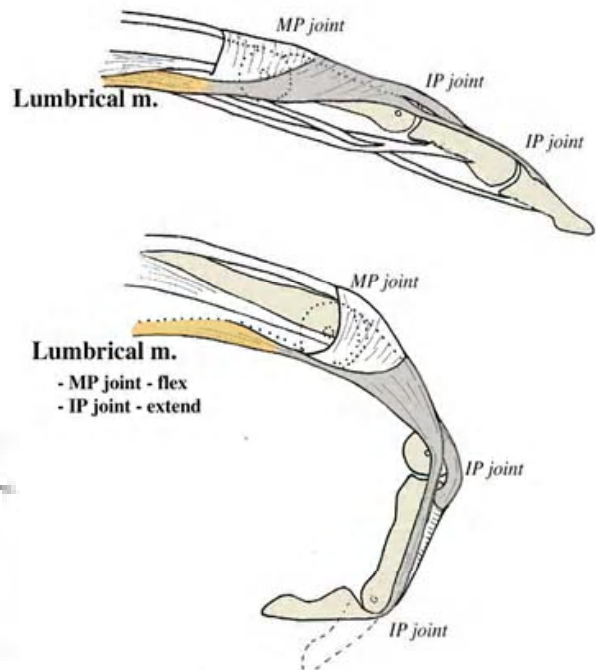
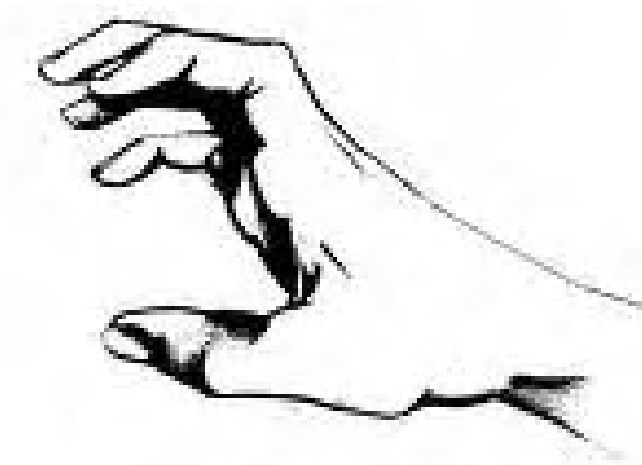
Waiter's tip (Erb's Palsy) Usually involves C5,6 and sometimes 7

- Etiology:
 - Birth (traction on the arm)
 - Falling on the shoulder (head shoulder space increased)
- Result
 - Loss of supraspinatus, infraspinatus, deltoid, brachialis, subscapularis
- Posture



Claw Hand

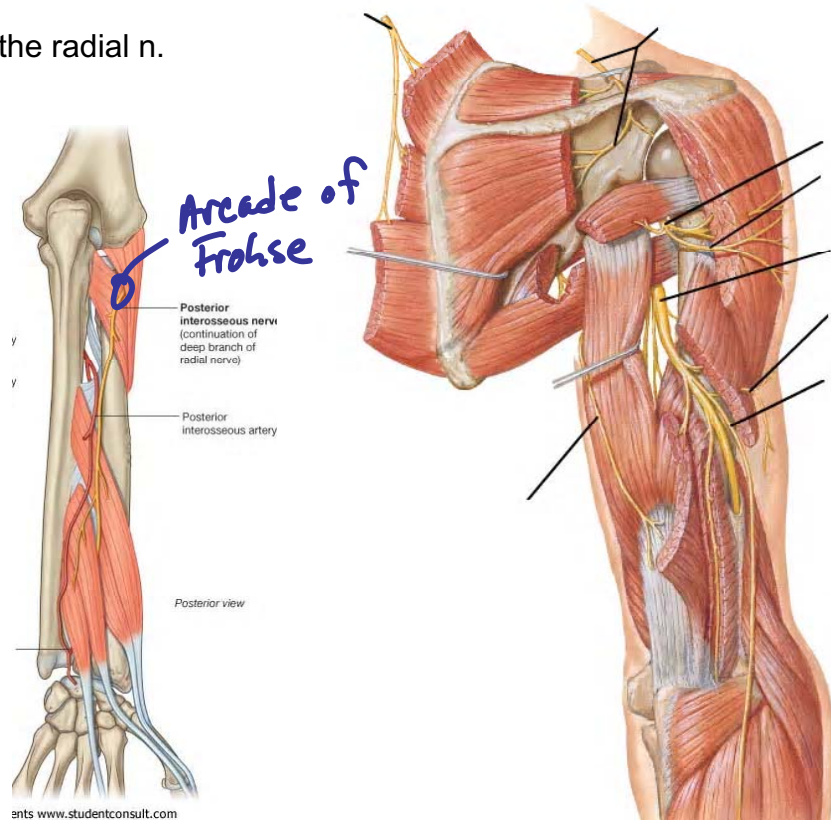
- Etiology
 - Excessive shoulder ABD/Flexion
- Result
 - Inferior trunk injury (C8-T1)



Scapular, Axillary, and Radial Nerves Above t

Wrist drop (Saturday Night Palsy)

- Etiology:
 - Compression of the radial n.
- Result
 - Wrist drop
- Posture



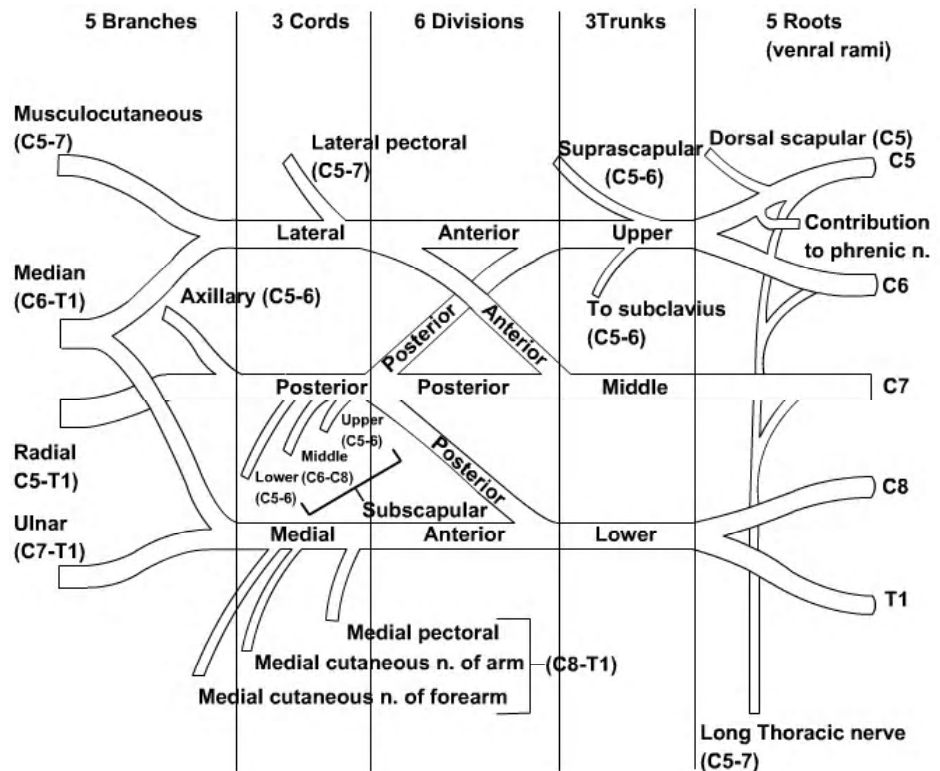
Scapular Winging

- Etiology
 - Entrapment of C5,6
 - Tract erve
 - Traur
 - Weal
- Result
 - Winging Scapul:

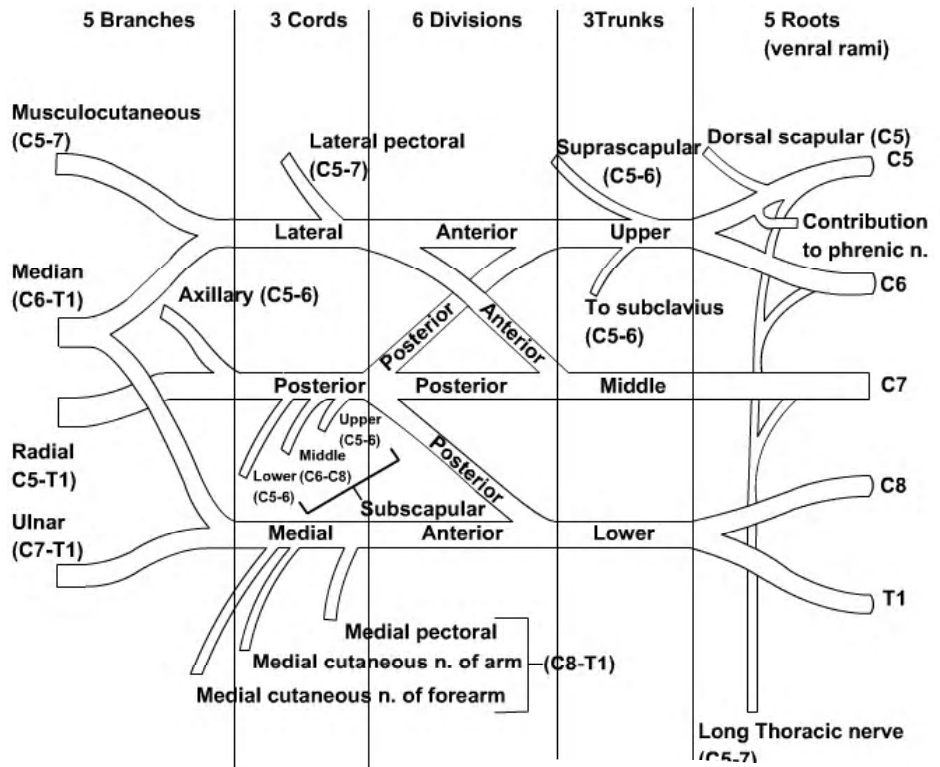
Deltoid paralysis

- Etiology
 - Entrapment of C5,6
 - trauma
- Result
 - Atrophy of the deltoid and teres minor muscles
 - AROM?

Difficulty flexing elbow, variable sensory loss



Benediction Sign



Nerve Compression Sites of the Upper Limb

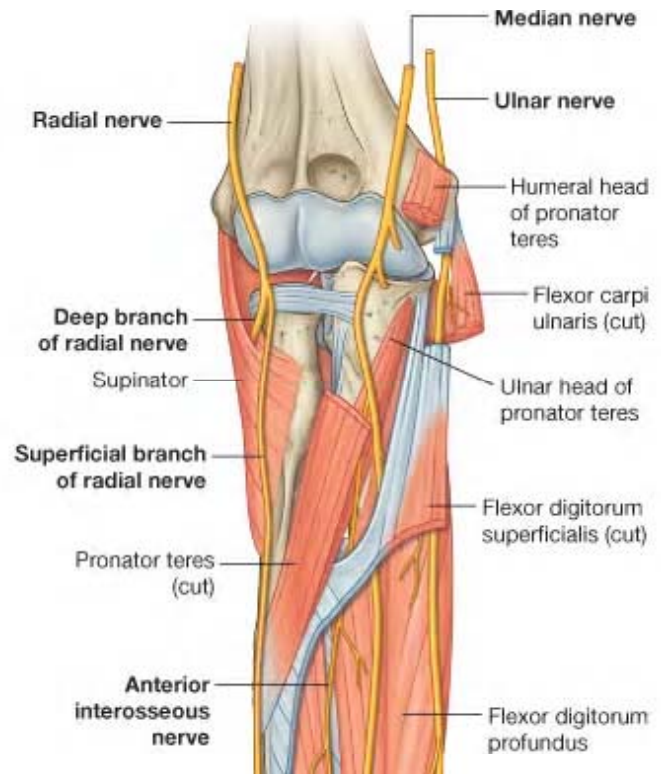
MEDIAN NERVE ENTRAPMENT SYNDROMES

Pronator syndrome

- Etiology:
 - Lacertus fibrosus (bicipital aponeurosis)
 - Pronator teres (musculofascial band or compression between 2 muscular heads)

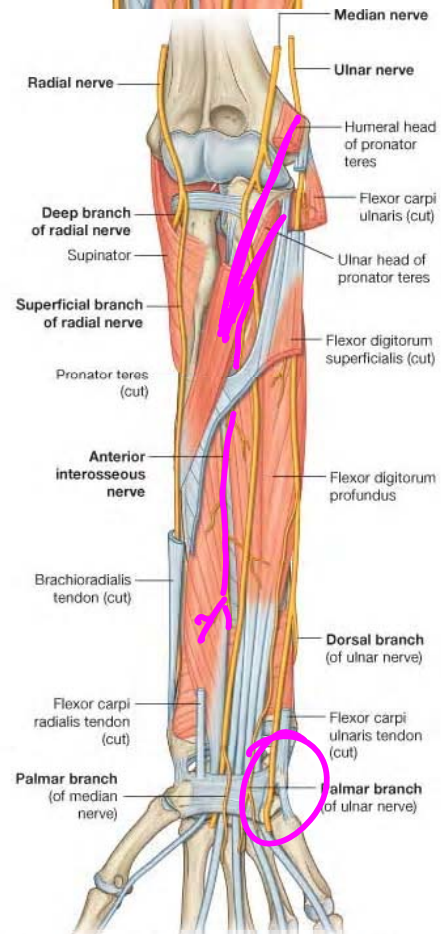
- Ligament of Struthers (thickened or aberrant origin of pronator teres and/or attachment of the fascia of the coracobrachialis)

- FDS (proximal arch or the flexor digitorum superficialis)



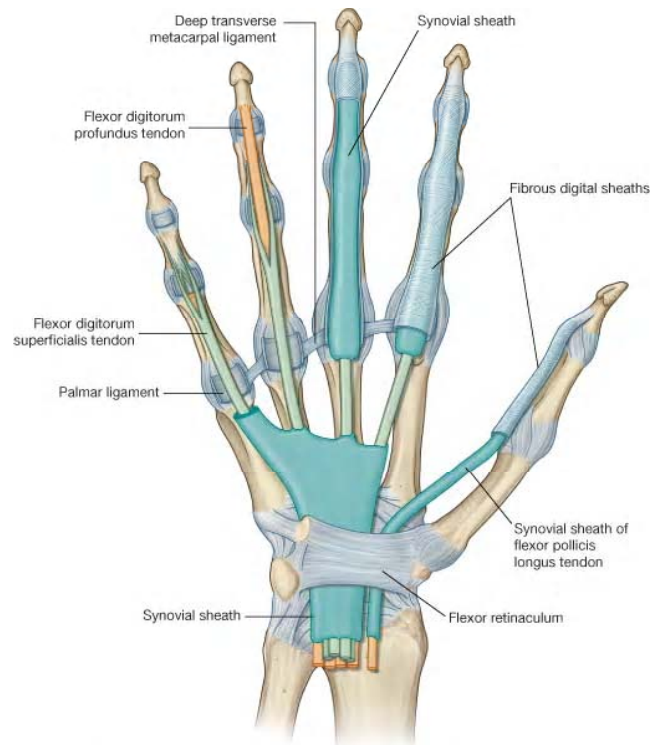
Anterior interosseous syndrome

- Etiology:
 - Tendinous bands
 - Deep head of the pronator teres
 - Accessory muscles
 - Fractures



Carpal tunnel syndrome

- Etiology:
 - Accessory muscles
 - Tenosynovitis
 - Ganglion, foreign or loose bodies
 - Repetitive motion
 - Vibration
 - Carpal fractures or dislocations

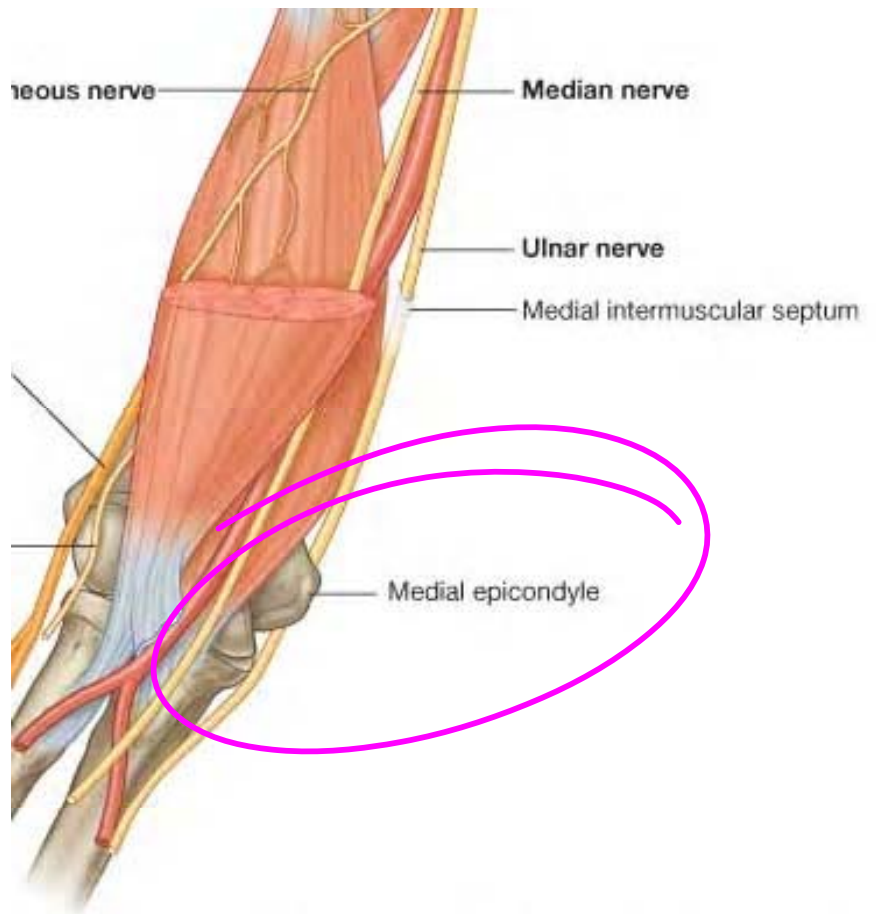


© Elsevier Ltd. Drake et al: Gray's Anatomy for Students www.studentconsult.com

ULNAR NERVE ENTRAPMENT SYNDROMES

Cubital tunnel syndrome

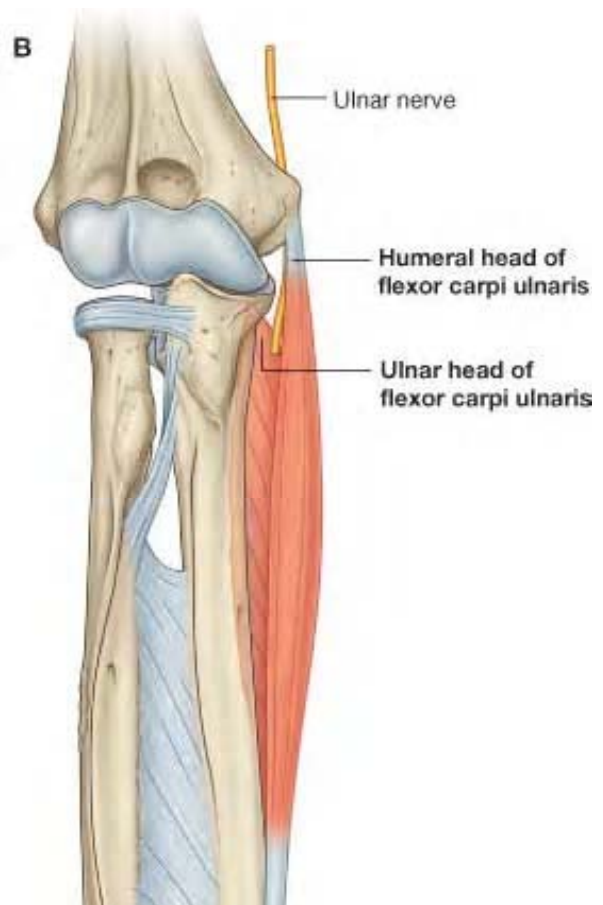- Etiology:
 - Struthers arcade - Thin aponeurotic band extending from the medial head of the triceps to the medial intermuscular septum (8cm prox to the medial epicondyle)
 - Intermuscular septum



© 2012 Elsevier Ltd. Drake et al: Gray's Anatomy for Students www.studentcons

- Anconeus epitrochlearis - Anomalous muscle which arises from medial border of olecranon & adjacent triceps & inserts into the medial epicondyle

- Intermuscular septum
- Osborne band - arching band of aponeurosis between the two heads of the FCU



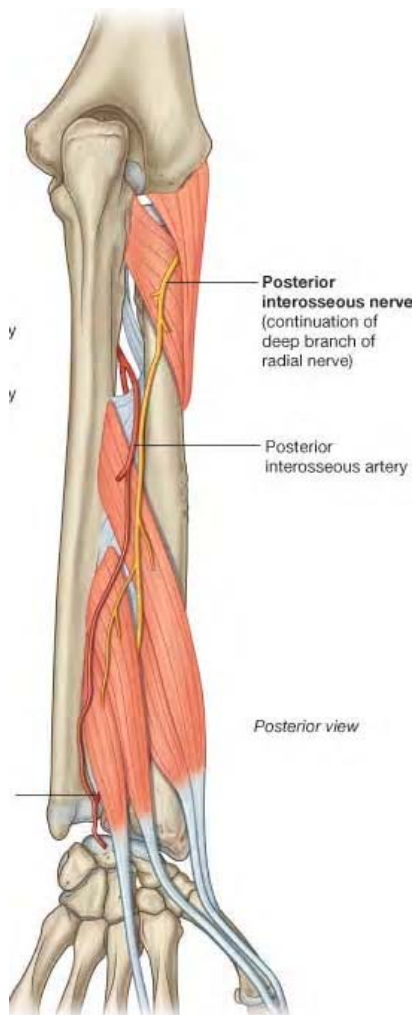
Ulnar tunnel syndrome (Guyon's canal)

- Etiology:
 - Blunt trauma from power tools and gripping or hammering with the palm of the hand
 - Fractures of the hook of the hamate can impinge on the nerve
 - Tumors such as ganglia or lipomas

RADIAL NERVE ENTRAPMENT SYNDROMES

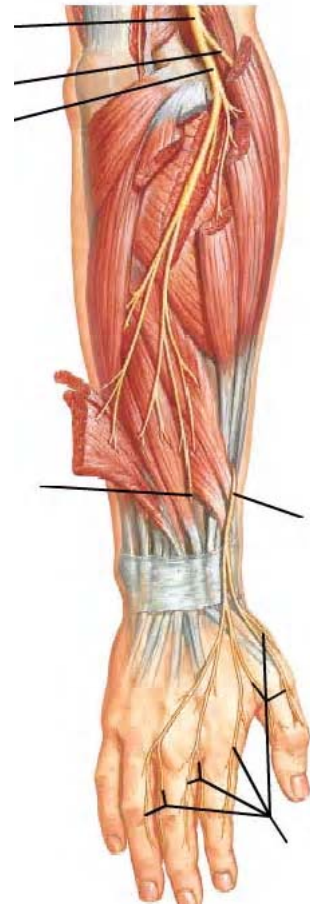
Radial tunnel and posterior interosseous syndrome

- Etiology:
 - Proximal fibrous edge of the supinator muscle, known as the arcade of Frohse
 - Fibrous fascia over the radio-capitellar joint
 - Distal edge of the supinator muscle
 - Fracture or dislocation of the radial head, tumors (eg, ganglion, lipoma), and
 - Resulting from open reduction/internal fixation of proximal radius fractures.



Superficial radial nerve syndrome (Wartenberg syndrome)

- Etiology:
 - Fascial bands in the subcutaneous plane
 - Tendon of brachioradialis
 - Tendon of extensor carpi radialis longus tendon



Upper limb nervesTerminal branches of the brachial plexus

- **Musculocutaneous n.**
 - Motor to anterior compartment of arm
 - Coracobrachialis m.
 - Biceps brachii m.
 - Brachialis m.
 - Sensory to forearm
 - Lateral cutaneous nerve of the forearm
- **Median n.**
 - Motor to superficial anterior compartment of the forearm
 - Pronator teres m.
 - Flexor carpi radialis m.
 - Palmaris longus m.
 - Flexor digitorum superficialis m.
 - Motor to deep anterior compartment of the forearm via anterior interosseous n.
 - Radial ½ of flexor digitorum profundus m.
 - Flexor pollicis longus m.
 - Pronator quadratus m.
 - Motor to the hand via recurrent median n.
 - Abductor pollicis brevis m.
 - Opponens pollicis m.
 - Superficial head of the flexor pollicis brevis m.
 - Motor to the hand via common palmar digital nn.
 - 1st and 2nd lumbrical mm.
 - Sensory to hand
 - Palmar branch of median n.
 - Common palmar digital nn.
 - Proper palmar digital nn.
- **Ulnar n.**
 - Motor to anterior compartment of the forearm
 - Ulnar ½ of flexor digitorum profundus m.
 - Flexor carpi ulnaris m.
 - Motor to hand via superficial branch of the ulnar n.
 - Palmaris brevis m.
 - Motor to hand via deep branch of the ulnar n.
 - Abductor digiti minimi m.
 - Flexor digiti minimi (brevis) m.
 - Opponens digiti minimi m.
 - Palmar interosseous mm.
 - Dorsal interosseous mm.
 - 3rd and 4th lumbrical mm.
 - Adductor pollicis m.
 - Deep head of the flexor pollicis brevis m.

- **Ulnar n. continued**
 - Sensory to hand
 - Dorsal branch of the ulnar n.
 - Dorsal digital nn.
 - Palmar branch of the ulnar n.
 - Superficial branch of the ulnar n.
 - Common palmar digital nn.
 - Proper palmar digital nn.
- **Axillary n.**
 - Motor to posterior shoulder
 - Deltoid m.
 - Teres minor m.
 - Sensory to posterior shoulder
 - Superior lateral cutaneous nerve of the arm
- **Radial n.**
 - Motor to posterior compartment of the arm
 - Triceps brachii m.
 - Motor to posterior compartment of the forearm
 - Anconeus m.
 - Brachioradialis m.
 - Extensor carpi radialis longus m.
 - Motor to posterior compartment of the forearm via the deep radial n.
 - Extensor carpi radialis brevis m.
 - Motor to the posterior compartment of the forearm via the posterior interosseous n.
 - Supinator m.
 - Extensor carpi ulnaris m.
 - Extensor digitorum m.
 - Extensor digiti minimi m.
 - Extensor indicis m.
 - Extensor pollicis longus m.
 - Abductor pollicis longus m.
 - Extensor pollicis brevis m.
 - Sensory to arm
 - Posterior cutaneous nerve of the arm
 - Inferior lateral cutaneous nerve of the arm
 - Sensory to forearm
 - Posterior cutaneous nerve of the forearm
 - Sensory to hand
 - Superficial branch of the radial n.
 - Dorsal digital nn.