



UPPSALA
UNIVERSITET

*Digital Comprehensive Summaries of Uppsala Dissertations
from the Faculty of Medicine 1402*

Endovascular aortic aneurysm repair: Aspects of follow-up and complications

BADERKHAN HASSAN



ACTA
UNIVERSITATIS
UPSALIENSIS
UPPSALA
2018

ISSN 1651-6206
ISBN 978-91-513-0167-9
urn:nbn:se:uu:diva-334369

Dissertation presented at Uppsala University to be publicly examined in Gustavianum, Akademigatan 3, 753 10 Uppsala, Sverige, Uppsala, Friday, 19 January 2018 at 13:15 for the degree of Doctor of Philosophy (Faculty of Medicine). The examination will be conducted in English. Faculty examiner: Clinical Senior Lecturer Colin Bicknell (Imperial College London).

Abstract

Hassan, B. 2018. Endovascular aortic aneurysm repair: Aspects of follow-up and complications. *Digital Comprehensive Summaries of Uppsala Dissertations from the Faculty of Medicine* 1402. 89 pp. Uppsala: Acta Universitatis Upsaliensis. ISBN 978-91-513-0167-9.

Endovascular aortic aneurysm repair (EVAR) is the procedure of choice in most patients with abdominal aortic aneurysm. The drawbacks of EVAR are a higher rate of complications and frequent need for reinterventions, requiring regular postoperative follow-up. Non-stratified follow-up may have a deleterious effect on patients and the health care system. The aim of this thesis is to develop strategies that can stratify the EVAR follow-up programme according to an individual patient's risk profile.

Study I, an international multicentre study of all abdominal aortic aneurysm (AAA) patients with EVAR in three centres (2000 to 2011) demonstrated a lower rate of late complications and reinterventions in patients with sac shrinkage during the first postoperative year, compared to the non-shrinkage group.

Study II, an international multicentre study of patients treated for a ruptured aortic aneurysm with EVAR in three centres (2000 to 2012) demonstrated that ruptured EVAR (rEVAR) in patients with hostile anatomy is associated with a high rate of graft-related complications, reinterventions and increased overall mortality.

Study III, a two-centre cohort study of 326 patients with EVAR (2001 to 2012), with first postoperative computerised tomographic angiography (CTA) within one year of the operation. Patients with adequate proximal and distal sealing zones and no endoleak in the first postoperative CTA had significantly lower risk for AAA-related complications and reinterventions up to five years postoperatively.

Study IV, studied all complications and reinterventions in a two-centre cohort study of all EVAR patients (1998 to 2012). One-fourth of the patients in the study developed complications during a mean follow-up of five years. Most complications were asymptomatic imaging-detected. Ultrasound could detect most of the clinically significant complications.

Keywords: abdominal aortic aneurysm, EVAR, rEVAR surveillance

Baderkhan Hassan, Department of Surgical Sciences, Vascular Surgery, Akademiska sjukhuset ing 70 1 tr, Uppsala University, SE-751 85 Uppsala, Sweden.

© Baderkhan Hassan 2018

ISSN 1651-6206

ISBN 978-91-513-0167-9

urn:nbn:se:uu:diva-334369 (<http://urn.kb.se/resolve?urn=urn:nbn:se:uu:diva-334369>)

To my Beloved family

Harman, Miro, Meivi and Sharo

List of studies

This thesis is based on the following papers, which are referred to in the text by their Roman numerals.

- I Frederico Bastos Gonçalves, Hassan Baderkhan, Hence J. M. Verhagen, Anders Wanhainen, Martin Björck, Robert J. Stolker, Sanne E. Hoeks, Kevin Mani. Early sac shrinkage predicts low-risk of late complications after endovascular aneurysm repair.

British Journal of Surgery. 2014 Jun;101 (7):802-10

- II Hassan Baderkhan, Frederico Bastos Gonçalves, Nelson Gomes Oliviera, Hence J. M. Verhagen, Anders Wanhainen, Martin Björck, Kevin Mani. Challenging anatomy predicts mortality and complications after endovascular treatment of ruptured abdominal aortic aneurysm.

Journal of Endovascular Therapy. 2016 Dec;23 (6):919-927

- III Hassan Baderkhan, Olov Haller, Anders Wanhainen, Martin Björck, Kevin Mani. Follow-up after endovascular aortic aneurysm repair can be stratified based on first postoperative imaging.

In press, British Journal of Surgery

- IV Hassan Baderkhan, Olov Haller, Anders Wanhainen, Martin Björck, Kevin Mani. Detection of late complications after endovascular abdominal aortic aneurysm repair and implications for follow-up.

Manuscript

Reprints were made with permission from the respective publishers.

Cover Picture:

Illustration of the endovascular aortic aneurysm repair (EVAR), with some of the most common complications, provided by the brilliant illustrator and researcher *Fuad Bahram*.

Contents

Abbreviations	9
Introduction	11
Historical aspects.....	12
Definition and prevalence	14
Natural course and rupture	15
Management of abdominal aortic aneurysm	17
Open repair	17
Endovascular repair	18
EVAR in ruptured cases	20
Suitability for EVAR and technical success	21
Instructions for use for EVAR.....	21
Technical success	22
EVAR complications.....	23
Graft-related complications	24
Endoleaks	24
Migration.....	30
Component separation	30
Limb kinking and occlusion.....	31
Post-implantation rupture.....	31
Other EVAR complications.....	32
Risk factors for post-EVAR complications	32
Surveillance after EVAR.....	34
Imaging modalities for EVAR surveillance	34
Computerised Tomographic Angiography	35
Duplex Ultrasonography	35
Contrast-Enhanced Duplex Ultrasound	35
Magnetic Resonance Imaging.....	36
Plain Abdominal X-ray	36
Other modalities.....	36
Surveillance protocols	36
Compliance with EVAR surveillance and loss to follow-up.....	38

Aims of this thesis	39
Specific aims.....	39
Materials and methods	40
Study I.....	40
Study II	40
Study III.....	41
Study IV.....	41
Statistical analysis	43
Results	44
Study I.....	44
Study II	47
Study III.....	49
Study IV.....	53
General Discussion.....	57
Post-implantation rupture and the benefit of EVAR surveillance.....	57
EVAR follow-up - an increasing burden	61
Type II endoleak and surveillance.....	62
EVAR for ruptured AAA	63
Can the current studies change EVAR follow-up?.....	64
Low-risk.....	65
High-risk.....	65
Follow-up after five years from EVAR.....	66
Future perspectives.....	67
Conclusion.....	68
Sammanfattning på svenska (Summary in Swedish)	69
Delarbete I	70
Delarbete II.....	70
Delarbete III.....	71
Delarbete IV	71
Acknowledgement.....	73
References	75

Abbreviations

<i>AAA</i>	<i>Abdominal aortic aneurysm</i>
<i>AJAX trial</i>	<i>The Amsterdam Acute Aneurysm trial</i>
<i>CEDU</i>	<i>Contrast-enhanced duplex ultrasound</i>
<i>CI</i>	<i>confidence interval</i>
<i>CTA</i>	<i>Computerised tomographic angiography</i>
<i>DREAM trial</i>	<i>The Dutch Randomized Endovascular Aneurysm Management trial</i>
<i>DSA</i>	<i>Digital subtraction angiography</i>
<i>DUS</i>	<i>Duplex ultrasonography</i>
<i>ECAR</i>	<i>Endovasculaire ou Chirurgie dans les Anévrysmes aorto-iliaques Rompus</i>
<i>ESVS</i>	<i>The European Society for Vascular Surgery</i>
<i>EVAR</i>	<i>Endovascular aortic aneurysm repair</i>
<i>EVAR trials</i>	<i>UK Endovascular versus Open Repair of Abdominal Aortic Aneurysm Trials 1 and 2</i>
<i>GFR</i>	<i>Glomerular filtration rate</i>
<i>HR</i>	<i>Hazard ratio</i>
<i>ICU</i>	<i>Intensive care unit</i>
<i>IFU</i>	<i>Instruction of use</i>

<i>IMPROVE trial</i>	<i>The Immediate Management of the Patient with Rupture: Open Versus Endovascular strategies trial</i>
<i>MAIFU</i>	<i>Minimum appropriate imaging follow-up</i>
<i>MRI</i>	<i>Magnetic resonance imaging</i>
<i>NCT</i>	<i>Non-contrast Computerised tomographic angiography</i>
<i>OSR</i>	<i>Open surgical repair</i>
<i>OVER trial</i>	<i>The Open versus Endovascular Repair Veterans Affairs trial</i>
<i>PAX</i>	<i>Plain Abdominal X-ray</i>
<i>PTFE</i>	<i>Polytetrafluoroethylene</i>
<i>rAAA</i>	<i>Ruptured abdominal aortic aneurysm</i>
<i>RCT</i>	<i>Randomised controlled trial</i>
<i>rEVAR</i>	<i>Ruptured endovascular aortic aneurysm repair</i>
<i>SVS</i>	<i>Society for vascular surgery</i>

Introduction

Abdominal aortic aneurysm (AAA) is a pathological widening of the abdominal aorta, which untreated expands and ends in rupture with fatal consequence. Conventionally the AAA operation has been performed by the open approach through a long laparotomy incision, a technique associated with risk for morbidity and mortality. A new catheter-based technique, endovascular aortic aneurysm repair (EVAR), was introduced in 1985 by Volodos and further developed by Parodi (Veith, 2005; Volodos, 2015; Volodos, 1986). EVAR resulted in a paradigm shift and changed AAA management dramatically, introducing the possibility to treat new patient cohorts who were previously deemed too high risk for open aortic surgery. Standard EVAR requires certain anatomical criteria to be fulfilled to achieve long-lasting results. Juxta – and suprarenal aneurysms require more complex endovascular procedures with fenestrations, chimneys or branches. EVAR has a superior short-term outcome compared to open aortic repair, but unlike open repair, there is a risk of late complications related to incomplete exclusion of the aneurysm sac, repressurisation and, ultimately, rupture. Therefore, EVAR patients should be followed regularly according to all current guidelines to detect and manage complications timely. However, EVAR follow-up is an increasing burden for the health care system. This thesis aims to determine whether all EVAR patients have the same risk of repressurisation of the aneurysm sac with risk of rupture or whether follow-up can be stratified, based on an individual patient's risk profile.

Historical aspects

The word *aneurysm* is derived from the Greek *aneurysma*, which means 'widening'. The first written record of an aneurysm is in the Book of Hearts, from the Eber Scolls papyrus of ancient Egypt, dating back to 1550 BC. In that text, an aneurysm was called a 'tumour of the arteries'. Even India's Sushruta (800–600 BC) and Galen (126–c216 AD), a surgeon in ancient Rome, mentioned aneurysm in their works.

In the 2nd century AD, the Greek surgeon Antyllus (Friedman and Friedman, 1989) tried to treat an aneurysm with a proximal and a distal ligature, central incision and removal of thrombotic material from the aneurysm.

In 1554, Vesalius (1514–564) produced the first true anatomical plates based on cadaveric dissection, in "De Humani Corporis Fabrica". A year later, he provided the first accurate diagnosis and illustrations of AAA (Van Hee, 1993).

In 1923, Matas (Livesay, 2005) performed the first successful complete ligation of the aorta for an aneurysm. The patient survived for 17 months before dying of pulmonary tuberculosis. Matas also developed the technique of endoaneurysmorrhaphy. This method involved tying the aneurysmal sac upon itself to restore normal blood flow to the lower limbs; this was the first recorded technique to allow blood flow and was the basis for the development of homografts, synthetic grafts and endovascular techniques.

Arthur Voorhees is credited with the invention of synthetic arterial prosthetics. He tested a wide variety of materials for synthetic tube grafts and settled upon vinyon-N, which proved to be robust. In 1952, Voorhees (Voorhees, 1952) inserted the first synthetic graft into a ruptured abdominal aortic aneurysm. By 1954, he had successfully implanted 17 such grafts. Similar materials with improved tensile strength are still used in open aneurysm repair, including Teflon, Dacron and expanded Polytetrafluoroethylene (PTFE).

The development of ultrasound in the 1940s and 1950s was a major milestone in the management of AAA and reduction of ruptures. In 1958, Ian Donald (Donald, 1958) published "Investigation of abdominal masses by pulsed ultrasound", which is regarded as a major work in diagnostic imaging. Computerised axial tomography scans became available in the early 1970s and rapidly became the gold standard to define aneurysm morphology and planning before surgical intervention.

In the 1980s, Volodos (Volodos, 1991) and his team experimented intensively with different catheter-based approaches to treat aortic aneurysms. In 1986 he could use a hybrid approach to AAA for the first time. In this procedure, an endoprosthesis was deployed following laparotomy to achieve proximal anastomosis in a rapid fashion without aortic clamping. Volodos continued to develop stent grafts for treatment of thoracic and abdominal aortic disease (Diethrich, 2013; Volodos, 2015).

In 1991, Parodi (Parodi, 1991) operated on five patients with elective AAA, using a custom-made Dacron tube endoprosthesis inserted transfemorally and fixed with balloon expandable stents. In 1994, endovascular repair of a ruptured aneurysm was first performed in Nottingham, UK (Yusuf, 1994).

Definition and prevalence

AAA is defined in various ways. The most frequently used definition is the infrarenal aortic diameter of 30mm or larger as cutoff for definition of AAA (McGregor, 1975). Another definition is an infrarenal to suprarenal ratio of 1.5 or more (Sterpetti, 1987). Collin defined AAA as an infrarenal diameter of 40 mm or more, or an infrarenal diameter larger than the suprarenal diameter by at least 5 mm (Collin, 1988). The International Society of Cardiovascular Surgery defines AAA as a 50 % permanent dilatation of the normal artery, adjusted to gender and radiological modality (Johnston, 1991).

AAA is more common in men than in women. In population-based screening studies, the prevalence was 4–7.6 % in men, compared to 1.3 % in women (Ashton, 2002; Lindholt, 2003; Norman, 2004; Scott, 2002). Screening data from Sweden from 2011 to 2014, reported a much lower prevalence than in the studies mentioned above: 1.3–2.2 % in men and 0.3 % in women (Linne, 2014; Svensjo, 2013; Wanhainen and Bjorck, 2011). The aetiology and pathogenesis of AAA are complex, characterised by the interaction of hereditary and environmental factors (Bjorck and Wanhainen, 2013). The reduction in prevalence is mainly explained by a reduction in smoking (Svensjo, 2011).

Natural course and rupture

An AAA expands at a rate of 2–3 mm per year. Larger aneurysms grow faster (Brady, 2004; Thompson, 2010). Smoking cessation and presence of diabetes are associated with a lower growth rate (Lindblad, 2005; Tornwall, 2001), while the associations between AAA growth and hypertension, obstructive pulmonary diseases and medications are unclear (Prisant and Mondy, 2004). Currently there is no drug therapy for small AAA. Several commonly used cardiovascular drugs have been associated with reduced AAA growth in observational studies. However, a number of clinical trials have so far not been able to verify these findings. Beta-blockers, Macrolide/Doxycycline, mast cell inhibition, and ACE inhibition have been evaluated in several RCTs, with no effect. Early observational studies suggested a possible growth reduction effect of Statins, while more recent and larger association studies found no such effect (Golledge, 2017).

Initial aneurysm diameter is an independent risk factor for rupture (Conway, 2001; Lederle, 2002). Several studies have demonstrated an increased risk of rupture in female patients (Brown, 2003; Norman and Powell, 2007), smokers and patients with hypertension (Brown and Powell, 1999; Cronenwett, 1985). Table 1 shows the estimated annual rupture risk based on initial aneurysm size.

Table 1.

The estimated rupture rate per 100 person-years, based on aneurysm diameter.

Diameter, mm	Rupture rate per 100 person-years	Data source
30-55	1.6	(Powell, 2011)
55-59	9.4	(Lederle et al., 2002)
60-70	10-20	(Lederle et al., 2002)
70-80	30-40	(Lederle et al., 2002)
>80	30-50	(Lederle et al., 2002)

Management of abdominal aortic aneurysm

Surgical management should be considered for all AAA larger than 55 mm in men and 52 mm in women to avoid a rupture, according to the current guidelines of the European Society for Vascular Surgery (Moll, ESVS guidelines, 2011). Once the AAA reaches these thresholds, a choice must be made between open and endovascular repair.

Open repair

The conventional surgical method is usually performed with transperitoneal (or less commonly retroperitoneal) laparotomy through a long midline incision from the Xyphoid process to the symphysis pubis. The aneurysm is resected and replaced by a straight or Y-shaped graft (Figure 1).

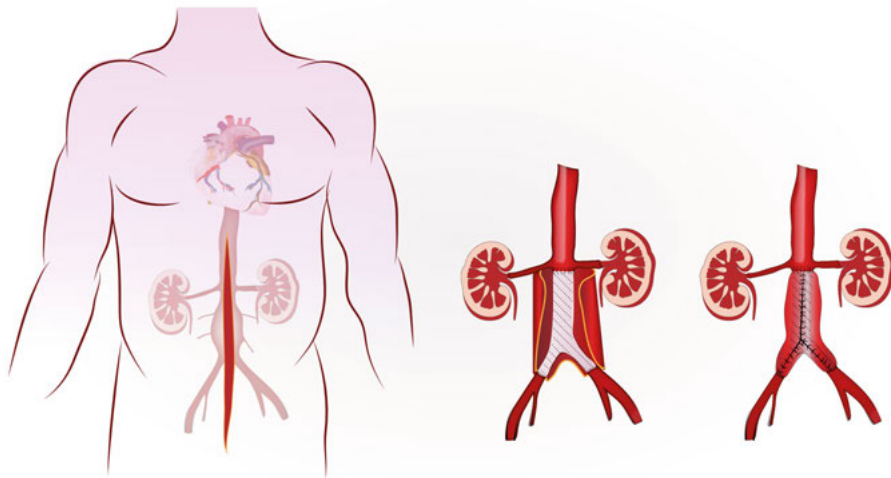


Figure 1. Conventional open surgical infrarenal aortic aneurysm procedure.

Open surgery provides a durable and successful treatment of an aneurysm. The perioperative mortality rate is approximately 3 % in the Swedish vascular registry (Swedvasc), and ranging from 1 to 8 % in other cohorts, in

elective cases (EVAR trial 1 investigators, 2005; Hertzner, 2002; Huber, 2001), and 30% to 82 % in ruptured cases (Bown, 2002; Noel, 2001; Prance, 1999). These are higher than the perioperative mortality rates after EVAR, as verified in existing randomised controlled trials and populations-based registries (Lilja, 2017; Mani, 2015).

After open repair, 15% to 30% of patient’s experience complications (Lee, 2004; Nowygrod, 2006). Open repair is also associated with more blood loss and longer intensive care unit and hospital stays (Brewster, 1998).

Endovascular repair

EVAR is now the standard procedure used to treat aortoiliac aneurysms and is the most often used technique for AAA repair in many Western countries, including Sweden (Beck, 2016; Budtz-Lilly, 2017; Lilja et al., 2017; Mani, 2011). Since 2000, there has been a more than 600% increase in EVAR procedures performed in the USA (Nowygrod et al., 2006). In Sweden, the number of EVAR procedures grows each year; in 2013, more than 600 procedures were performed (Figure 2).

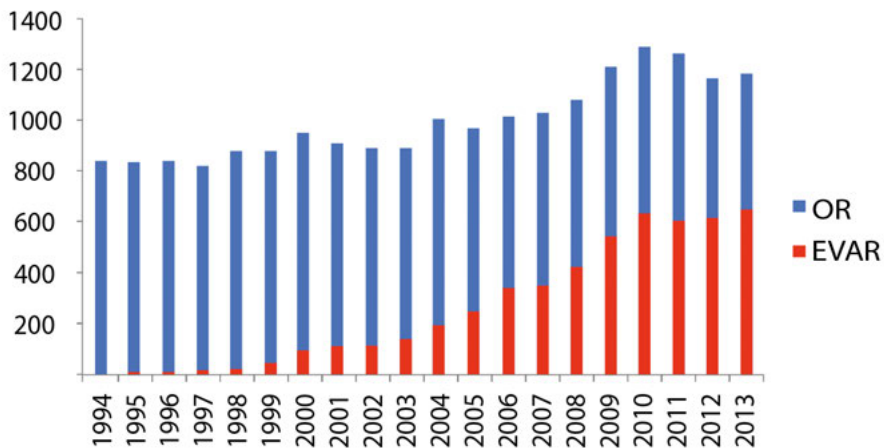


Figure 2. The number of procedures for AAA in Sweden (1994-2013), from the Swedvasc database.

EVAR is a minimally invasive operation. A stent graft is implanted in the aorta through femoral access, to exclude the aneurysm from the circulation. The femoral access is closed through a vascular cut down, fascia sutures or closure devices placed percutaneously. The contemporary stent grafts have barbs and hooks for supra- or infrarenal fixation to the aortic wall (Figure 2).

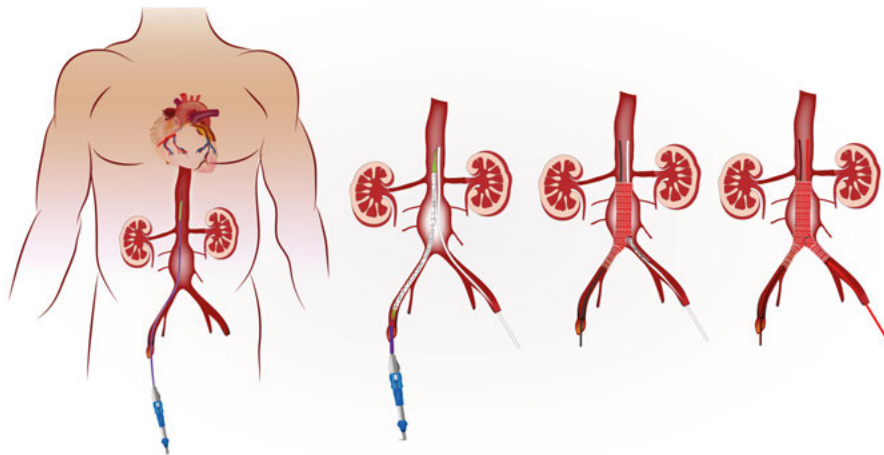


Figure 3. Aortic aneurysm repair with the EVAR procedure.

Giles et al. analysed the USA inpatient database from 1993 to 2005 and found that, since the introduction of EVAR, the annual number of deaths from AAA has significantly decreased. This trend coincided with an increase in the number of EVAR procedures performed for intact AAA (Giles, 2009).

EVAR is associated with shorter operating time, decreased blood loss, decreased postoperative pain and need for intensive care, as well as shorter hospital stays (Brewster et al., 1998). In addition, it can be performed under local anaesthesia and has a better early outcome regarding perioperative mortality. Disadvantages of EVAR include the potential risk of incomplete sealing, endoleak and repressurization, which may lead to sac enlargement and rupture. Thus, regular follow-up for many years after the operation has been regarded as mandatory.

UK Endovascular versus Open Repair of Abdominal Aortic Aneurysm Trial (EVAR Trial 1) reported a perioperative mortality rate of 1.7 % for EVAR compared to 4.7 % for open surgical repair (OSR), $p=0.009$ (Greenhalgh, 2004). Similar results have been reported by the Dutch Randomized Endovascular Aneurysm Management (DREAM) trial, with 1.2 % EVAR vs 4.6 % for OSR, $p=0.1$ (Prinssen, 2004), and the Open versus Endovascular Repair (OVER) Veterans Affairs Study, with 0.5 % vs 3.0 %, $p=0.004$ (Lederle, 2009), as well as in several non-randomised reports (Budtz-Lilly et al., 2017; Giles, 2009; Greenberg, 2004; Lilja et al., 2017; Matsumura, 2003).

However, the early survival benefit after EVAR is not durable, and long-term survival after EVAR for intact AAA using earlier generation's devices is less favourable. In both the EVAR 1 and DREAM trials (De Bruin, 2010; Greenhalgh, 2010), the EVAR groups had a lower aneurysm-related mortality rate during the first postoperative year, but a comparable overall mortality with the convergence of survival curves during the second

postoperative year. In both trials, the EVAR group had more late complications and reinterventions. An analysis of Medicare beneficiaries who had surgery for AAA between 2001 and 2004 reported a higher rate of rupture (1.8 % vs. 0.5 %, $p < 0.001$) and a higher rate of minor and major AAA-related reinterventions (9.0 % versus 1.7 %, $p < 0.001$) by four years post-surgery in the EVAR group compared to the OSR group (Schermerhorn, 2008). EVAR I trial investigators published newly 15 years follow-up data. Eight years after operation and onward had open group better survival compared with EVAR group. The endovascular group had higher risk of aneurysm sac rupture and cancer, resulting in higher rate of aneurysm-related, as well as total mortality (Patel, EVAR 1 trial, 2016).

The endografts used in these RCTs were of older generations, and there are some reports that newer endografts have a lower rate of complications (Verzini, 2014).

EVAR in ruptured cases

Wide adoption of EVAR in elective cases with superior short-term outcomes has encouraged vascular surgeons to use this minimally invasive technique in ruptured cases. Observational trials reported lower mortality for EVAR for ruptured aneurysms (rEVAR) compared to OSR (Dillon, 2007; Noorani, 2012; Ten Bosch, 2012), but this could not be verified in the earlier reports of the three randomised trials, the Immediate Management of the Patient with Rupture: Open versus Endovascular strategies (IMPROVE) trial, the Amsterdam Acute Aneurysm (AJAX) trial, Endovasculaire ou Chirurgie dans les Anévrismes aorto-iliaques (ECAR) Rompus, comparing the two techniques (Desgranges, 2015; Powell, 2014; Reimerink, AJAX trial, 2013; Sweeting, 2015). However, patients undergoing rEVAR are more likely to be discharged from hospital faster, and women may benefit more from an endovascular strategy (Sweeting et al., 2015). IMPROVE trial newly published the three years result. In the mid-term (three months to three years), EVAR group had a better survival (hazard ratio [HR] 0.57, 95 % confidence interval [CI] 0.36 to 0.90), leading to lower mortality (48 % v 56 %). Lower mortality together with better quality of life resulted in higher cost effectiveness for the EVAR group. Both groups had similar levels of reintervention (IMPROVE trial investigators, 2017).

Suitability for EVAR and technical success

Instructions for use for EVAR

As mentioned previously, EVAR requires certain anatomical criteria to be fulfilled (Figure 4). These are summarised in the manufacturer's instructions for use (IFU) for each specific device and include aneurysm characteristics of the neck and iliac criteria.

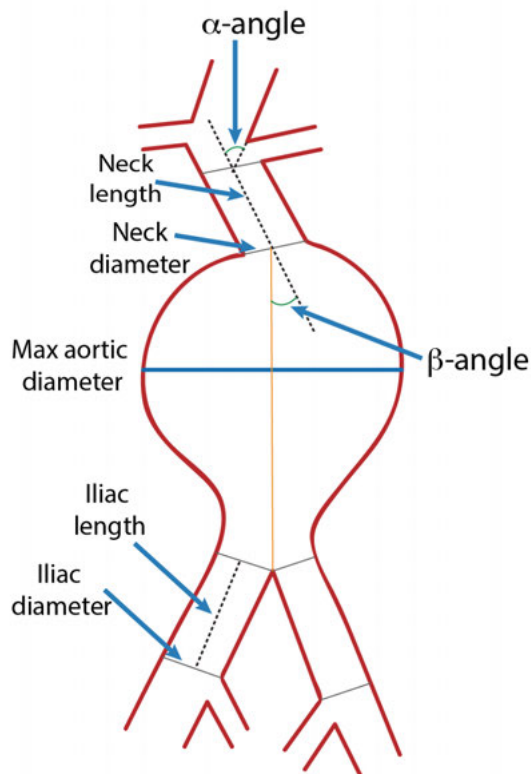


Figure 4. Schematic illustration of anatomic criteria included in device-specific IFU.

IFU for most contemporary devices are quite similar; Table 2 shows the IFU of the most commonly used stent grafts: Endurant[®] (Medtronic, Santa Rosa,

CA, USA), Excluder[®] (W.L. Gore and Associates, Flagstaff, AZ, USA) and Zenith[®] (Cook Medical INC., Bloomington, IN, USA).

Table 2.

Instructions for use for the most commonly used endografts

Anatomical parameter	Endurant [®]	Excluder [®]	Zenith [®]
Neck length, mm	≥10*	≥ 15	≥ 15
Neck diameter, mm	19-32	19-29	18-32
Suprarenal neck angulation (α)	≤ 45°	---	< 45°
Infrarenal neck angulation (β)	≤ 60°	≤60°	< 60°
Distal fixation site length, mm	≥ 15	≥10	> 10
Distal fixation site diameter, mm	8-25	8-25	7.5-20

* ≥15mm with ≤ 75° infrarenal and ≤ 60° suprarenal neck angulation.

In addition to the criteria mentioned above, there should be adequate femoral access. Additional anatomical elements may affect successful endovascular repair:

- Significant or circumferential calcification or thrombosis in the proximal and distal landing zones
- Conic neck (greater than 10 mm increase in diameter over intended landing zone length)

Technical success

Primary technical success has been defined by reporting standards of Society for Vascular Surgery, SVS (Chaikof, 2002) as successful introduction and deployment of the endograft without conversion or mortality, type I and III endoleak and graft limb obstructions. Technical failure relates to occurrence of any of these events from the initiation of the procedure through the first 24 hours after the operation. The terms assisted primary or secondary technical success are used when an unplanned endovascular or surgical procedure has been necessary in addition to the planned procedure.

EVAR complications

EVAR is a minimally invasive procedure and is associated with reduced systemic complications (i.e. cardiac, pulmonary and renal disorders) when compared to OSR (Anderson, 2004; Becquemin, 2008; Feringa, 2007; Wald, 2006) (Table 3).

Table 3

Perioperative outcome EVAR vs OSR, based on Marc L. Schermerhorn et al., New England Journal of Medicine 2008; 358:464-474 (Schermerhorn et al., 2008)

Outcome	EVAR	OSR	p-value
Mortality, %	1.2	4.8	<0.001
Myocardial Infarction, %	7.0	9.4	<0.001
Pneumonia, %	9.3	17.4	<0.001
Acute renal failure, %	5.5	10.9	<0.001
Dialysis, %	0.4	0.5	0.047
Colonic ischaemia, %	1.0	2.1	<0.001

There is, however, a set of EVAR-specific complications. The **graft-related complications** (Herman, 2017), refers to complications related to the stent graft and sac repressurisation such as type I and III endoleaks, expansion more than 5 mm, migration, graft limb occlusion and rupture. **Clinically significant complications**, based on Chaikof's definition of clinical failure (Chaikof, 2002), refers to all complications that follow EVAR and have significant clinical impact. These include direct endoleaks, type II endoleak with expansion, any significant expansion, migration, graft infection, graft limb thrombosis and post-implantation ruptures.

Graft-related complications

Technical failure is uncommon with currently available EVAR devices and experience. However, EVAR still results in graft-related complications and reinterventions over time. The thirty-day reintervention rate was 9.8 % in the EVAR trial 1 and 18 % in EVAR trial 2 (EVAR trial 2 investigators, 2005; EVAR trial 1 investigators, 2005). Most reinterventions were performed to repair endoleaks. The rate of graft-related complications that required reinterventions was 19 % over a three year mean follow-up in a large study by Mehta et al. (Mehta, 2010), and about 20 % over 6.4 years median follow-up in the DREAM trial (De Bruin et al., 2010).

Endoleaks

Endoleak is defined as a persistent flow outside the stent graft but within the aneurysm sac. Endoleaks are the most common complication after EVAR and occur in 5 % to 25 % of cases (Hobo and Buth, 2006; Hoornweg, 2007; Ouriel, 2003; Sheehan, 2006). Computerised tomographic angiography (CTA) is the standard method used to detect endoleaks. Other diagnostic methods include duplex ultrasonography (DUS), contrast-enhanced duplex ultrasound (CEDU), magnetic resonance imaging (MRI) and digital subtraction angiography (DSA). White and May have classified endoleaks into four types, as described below (White, 1998):

Endoleak type I

Endoleak type I occurs because of incomplete sealing of the proximal (type Ia) or the distal (type Ib) end of the endograft with the aorta or iliac arteries (Figure 5). Hostile anatomy, such as short, conical or angulated neck or iliac landing zones, are predisposing factors for type I endoleaks. Type I endoleaks occur at a rate of 3-4 % over 6 years follow up (Conrad, 2009; Lal, OVER trial, 2015). Type I endoleaks are associated with significant risk for rupture and should be managed promptly (Buth and Laheij, 2000; Harris, 2000; Schurink, 1998).

Most of the proximal type I endoleaks can be treated by balloon dilatation or balloon expandable stents or cuffs, with or without fenestrations for visceral arteries, as shown in Figure 6 (Faries, 2003). Distal type I endoleaks are managed by a graft leg extension (Figure 7). Use of embolic agents and coils may be another way to treat type I endoleaks (Maldonado, 2003; Sheehan, 2004), but sometimes a conversion to open operation is the only option to treat type I endoleaks (Kelso, 2009).

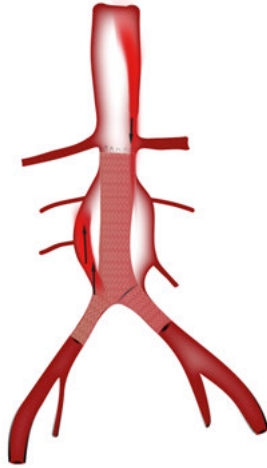


Figure 5. Schematic illustration of type Ia and Ib endoleaks.

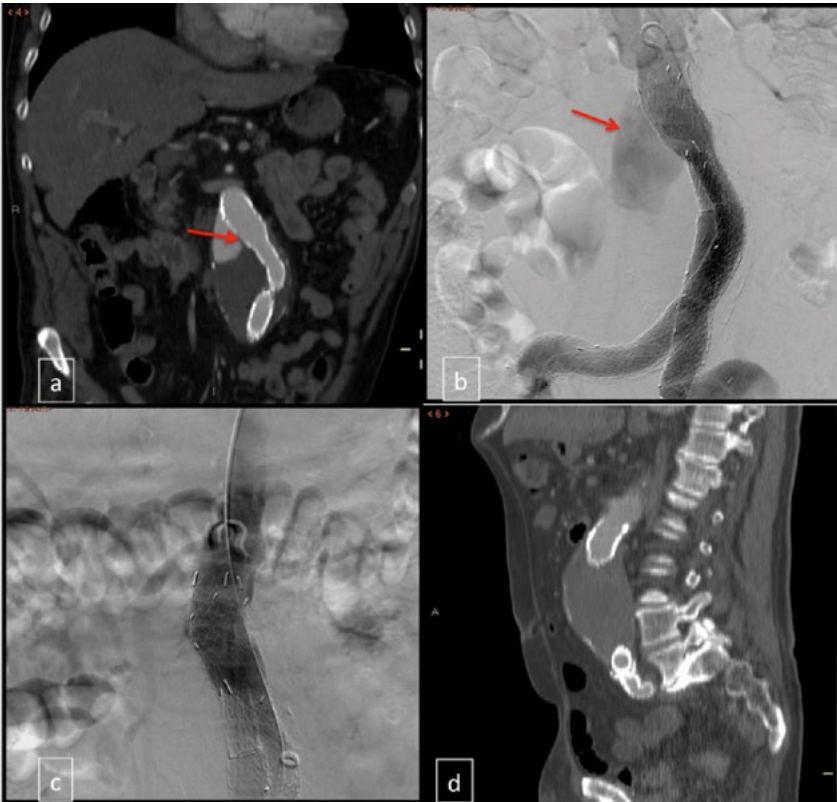


Figure 6. Endoleak type Ia on CTA (a) and DSA (b), management with proximal cuff extension (c) and disappearance of endoleak on control CTA (d).

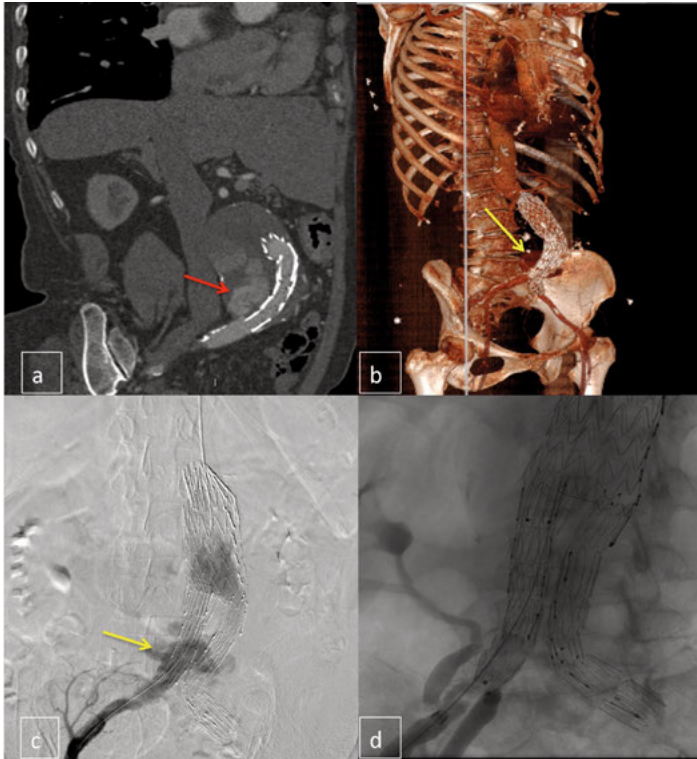


Figure 7. Right side Endoleak Type Ib on CTA (a and b) and DSA (c), management with limb extension (d).

Endoleak type II

Endoleak type II occurs because of backflow from the inferior mesenteric artery (IIa) or lumbar arteries (IIb) into the aneurysm sac (Figure 8). Other sources of type II endoleaks may be an accessory renal artery, sacral artery or leak from iliac occluders. Type II endoleak is the most common endoleak and is observed in 10 to 20 % of patients (Veith, 2002). Most type II endoleaks resolve spontaneously within a few months postoperatively (Higashiura, 2007; Jones, 2007; Silverberg, 2006). Type II endoleaks associated with sac expansion should be treated to avoid post-implantation rupture (Moll, 2011; van Marrewijk, 2004)

The most common way to treat type II endoleaks is to stop the side branch's flow through embolisation with coils or other embolic agents (Figure 9). The approach could be transarterial catheterisation of the branches (Kasirajan, 2003) or translumbar with direct puncture of the aneurysm sac (Binkert, 2006). If these methods fail, other alternatives include laparoscopy or laparotomy and ligation of the side branches (Kolvenbach, 2002; Yamada, 2015) or conversion to open repair (van Marrewijk et al., 2004). Patients who have a type II endoleak that is associated with expansion and, in particular, those who experience

expansion after treatment of the endoleak, should be examined to exclude type I or III endoleaks (Hajibandeh, 2015).

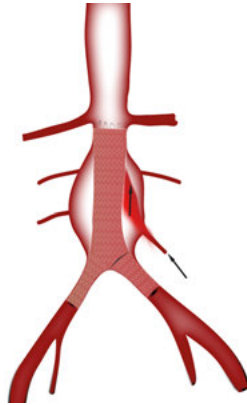


Figure 8. Schematic illustration of type II endoleak.

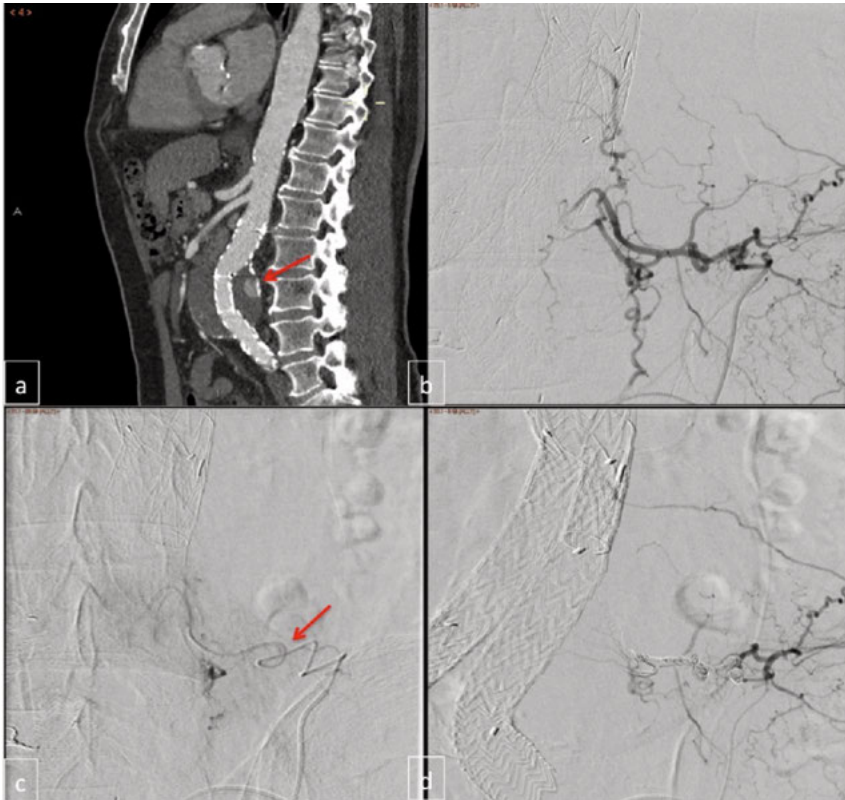


Figure 9. Endoleak type II on CTA (a) and DSA (b), catheterisation of the lumbar artery through the left internal iliac artery all the way to the aneurysm sac (c), disappearance of the endoleak after coiling (d).

Endoleak type III

Endoleak type III is caused by endograft disintegration and component separation, mostly due to migration or angulation of the stent graft (Figure 10). Less commonly, endoleak type III occurs as a result of fabric disruption. The published rate for this type of endoleak is 0 % to 1.5 % (Brewster, 2006; Wang and Carpenter, 2008). This type of endoleak should be treated promptly due to repressurisation of the aneurysm sac with the systemic blood pressure and a high risk of rupture. The standard treatment is endovascular, by bridging the gap between the two separated components with a stent graft limb, relining (Figure 11).

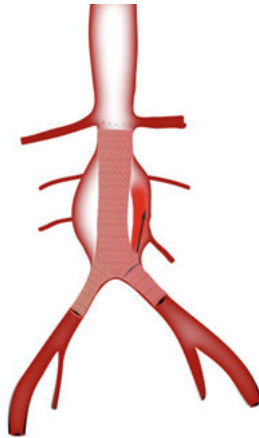


Figure 10. Schematic illustration of type III endoleak.

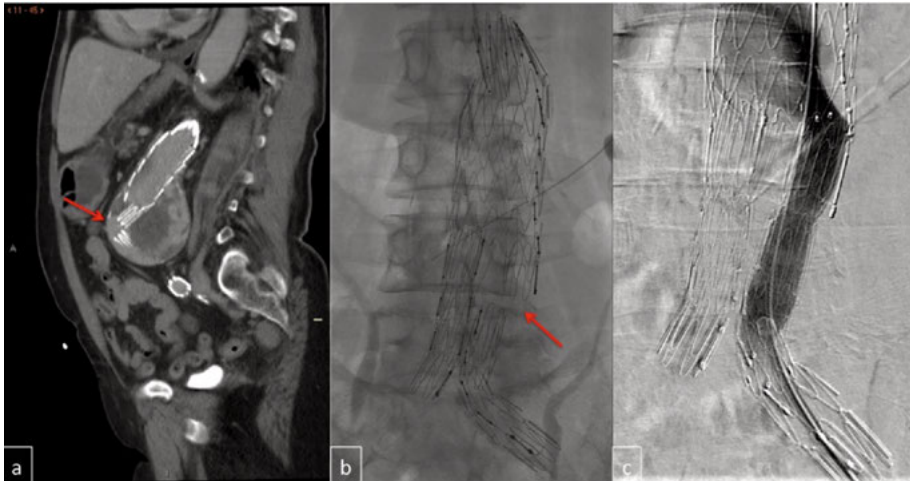

Figure 11. Endoleak type III due to component separation on CTA (a) and DSA (b), management with by bridging the gap between the two components (c).

Endoleak type IV

Endoleak type IV is seepage through porous fabric, usually seen in the control angiography (Figure 12). It is uncommon with today's devices and it is usually self-limiting (Becquemin, 2005).

Seepage through fabric observed after the first postoperative month should not be considered as a type IV endoleak (Chaikof et al., 2002).

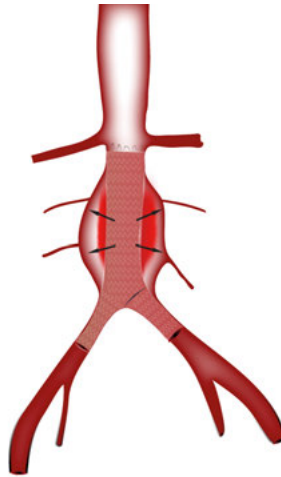


Figure 12. Schematic illustration of type IV endoleak.

Undefined endoleaks

Undefined endoleaks are flows outside the graft that are observed in imaging studies, but of which the exact origin cannot be determined. These endoleaks can be managed by active follow-up if not associated with sac expansion. When direct endoleak is suspected, or sac expansion occurs, treatment should be preceded by advanced imaging to define the type of endoleak and identify the best management strategy.

Endotension

Endotension (endoleak type V) is defined as continuous sac enlargement without any detectable endoleak. The cause of endotension is unclear; it could be due to a low-flow endoleak, an endoleak that cannot be detected by current imaging modalities or pressure transmission through the endograft fabric or the thrombus mass (Figure 13). Continuous sac expansion without a clear leak is usually managed by realignment of the endograft or by conversion to open operation (van Sambeek, 2004).

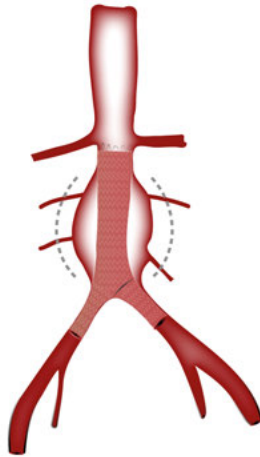


Figure 13. Schematic illustration of type V endoleak or endotension

Migration

Migration is defined as stent graft movement by >10mm by SVS reporting standards and in other reports (Cao, 2002; Chaikof et al., 2002; Herman et al., 2017), or any movement leading to complications, usually type I endoleak (Tonnessen, 2004). There are some controversies regarding this definition and some authors using 5 mm as a migration limit (Sternbergh, 2004). The rate of migration varies widely from 0 % to 45 % (Becquemin et al., 2005). Migration has been observed with all commercially available devices but was more common with older devices without active fixation. Most migrations have been reported after 24 months of follow-up (Tonnessen, 2005).

The migration is most often caudal, but sometimes a cranial migration of the iliac attachment site may occur. Neck anatomy (Cao et al., 2002; Rodway, 2008; Tonnessen et al., 2005), degree of oversizing (Sternbergh et al., 2004; van Prehn, 2009) disease progression and different device designs (Malina, 1998; Resch, 2000) may influence the risk of downward migration. A proximal cuff, deployed as close as possible to the lowest renal artery, usually manages caudal migration. Cranial migration is managed by distal extension of the iliac limb.

Component separation

Component separation is defined as an insufficient overlap between components of the stent graft that may lead to type III endoleak and rupture (Figure 11). Component separation was common with older devices. Most of the current commercially available stent grafts have not demonstrated any significant rate of integrity problems (Greenberg, 2008).

Limb kinking and occlusion

Kinking, twisting and stenosis of the stent graft limb may lead to thrombosis and occlusion of the graft limb (Figure 14). The causes of kinking and stenosis may be narrow aortic bifurcation, severely angulated iliac artery or upward migration of the graft limb. Severely atherosclerotic iliac or femoral artery may cause stenosis and decreased outflow and thrombosis of the graft limb as well. The EVAR trials reported 2.3 % limb thrombosis (Wyss, EVAR trials, 2010), while the Eurostar registry reports 3.7 % (Fransen, 2003). Graft limb thrombosis is usually managed with thrombolysis and ballooning or stenting of the stenosis, or sometimes with an extra anatomical femorofemoral bypass. Graft limb thrombosis without or with little symptom can be left untreated.

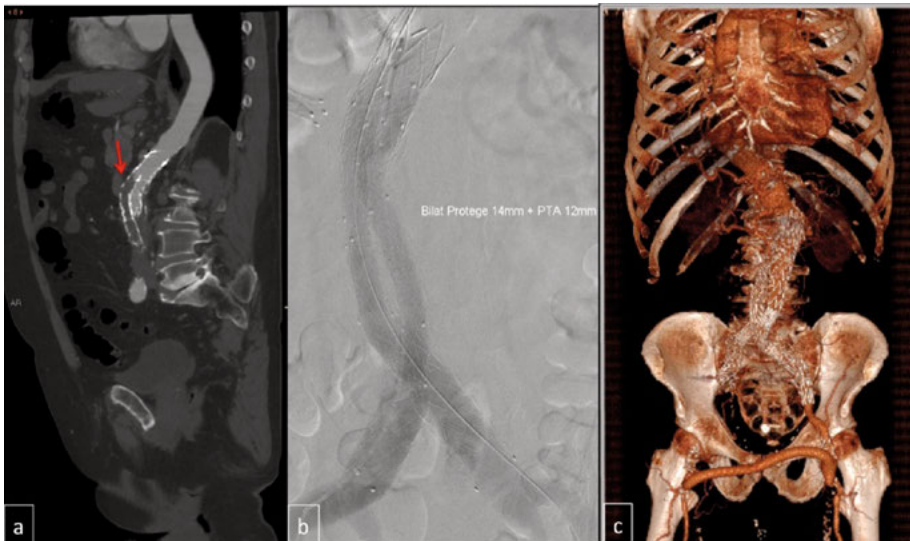


Figure 14. Graft limb thrombosis (a), management with thrombolysis and restenting (b). Another patient with right side graft limb thrombosis, managed with femorofemoral crossover (c).

Post-implantation rupture

Post-implantation rupture is regarded as a major failure of EVAR implantation and is often a lethal complication. Regular post-EVAR follow-up aims to prevent this complication. The rate of post-implantation rupture in the existing RCTs and registry reports is approximately 1 % to 4 % at a mean follow-up time of 5 years (Stather, 2013). The median time to rupture was 18 months in the Eurostar registry (Fransen, 2003), while in EVAR trials there were few ruptures within 30 days from the primary operation and late ruptures occurred in a mean time of 44 months (Wyss et al., EVAR

trials, 2010). The EVAR 1 trial 15 years results reported the increased aneurysm-related mortality in the EVAR group after 8 years, mainly as a result of aneurysm rupture, 13 deaths (7 %) in the EVAR group vs two (1 %) in the open repair group (Patel et al., EVAR 1 trial, 2016).

Other EVAR complications

There are several other complications that may occur after EVAR (Maleux, 2009). These include local wound complications, access artery injury, contrast-induced nephropathy, colonic ischaemia, spinal cord ischaemia, renal artery occlusion and graft infection, In general prevention of these complications is not the primary aim of post-EVAR follow-up programme.

Risk factors for post-EVAR complications

Not all patients have the same risk of post-EVAR complication. In the current literature different pre-, per- and postoperative risk factors have been identified for post-EVAR complications and reinterventions.

- **IFU and preoperative aortoiliac anatomy**

Compliance with IFU when performing EVAR has been studied extensively. Most authors agree that non-adherence to device-specific IFU is associated with increased postoperative risk for complications and reinterventions (Abbruzzese, 2008; AbuRahma, 2016; Herman et al., 2017; Nakai, 2013), while others reported no significant differences in the outcome (Beckerman, 2016; Igari, 2014; Lee, 2013; Walker, 2015). Most reports recommend a more careful and long-term follow-up when EVAR is used outside IFU.

- **Preoperative aortic aneurysm diameter**

Several studies reported that maximum preoperative aortic aneurysm diameter is an independent predictor for EVAR outcome; larger aneurysms have a higher risk for late complications and reinterventions (Karthikesalingam, 2013; Patel, 2017; Schuurmann, 2017).

- **Anatomical factors associated with increased risk for type II endoleak**

In a single center series of 189 patients, Piazza et al. defined several criteria for increased risk of type II endoleak, such as patent inferior mesenteric artery >3mm in diameter, patency of at least three pairs of lumbar arteries or patency of at least two pairs of lumbar arteries with a patent sacral, accessory renal or any diameter inferior mesenteric artery (Piazza, 2017). Other studies have reported similar results (Marchiori, 2011).

- **Intraoperative adjunct procedures**

Byrne et al. demonstrated a higher rate of type I endoleak and secondary reinterventions in patients who required a Palmaz stent in the primary operation (Byrne, 2013). Karthikesalingam et al. showed that intraoperative adjuncts are an independent risk factor for future reintervention (Hazard ratio [HR] 2.62, p= 0.012) (Karthikesalingam, 2010).

- **Sealing zones**

Short sealing or presence of endoleak in early post-EVAR imaging is significant risk factors for aneurysm-related complications (Bastos Goncalves, 2013).

- **Aneurysm sac shrinkage**

Patients with aneurysm sac regression have significantly lower rate of endoleaks, ruptures, or reinterventions and better survival (Cieri, 2013; Houballah, 2010).

- **Symptomatic or ruptured initial indication for EVAR**

A study identified symptomatic or ruptured AAA as a significant predictor for late rupture after EVAR, (HR 7.4; 95 % confidence interval [CI] 2.2-24.8; P <.01) (Candell, 2014).

Surveillance after EVAR

As described in the previous chapter, EVAR is associated with a significant risk of postoperative complications and reinterventions (Powell, 2017; Stather et al., 2013). Different types of endoleaks, device migration and structural failure may lead to aneurysm expansion and rupture. Hence, continued surveillance after EVAR is currently regarded as mandatory for all patients, and is recommended in current vascular surgical guidelines. Presently, the optimal modality and timing for EVAR surveillance is a topic of debate.

Imaging modalities for EVAR surveillance

Finding a proper imaging modality that is safe, repeatable, non-invasive, cost-effective, reliable and able to detect all complications before rupture is not easy (Table 4).

Table 4

Detecting various complications with different imaging modalities for surveillance after EVAR

Complications	NCT	CTA	DUS	CEDU	PAX	MRI
Endoleak	No	Yes	Yes	Yes	No	Yes
Sac diameter	Yes	Yes	Yes	Yes	No	Yes
Migration	Yes	Yes	No	No	Yes	Y/N
Component separation	Yes	Yes	No	No	Yes	Y/N
Limb kinking	Yes	Yes	Yes	Yes	Yes	Yes
Limb occlusion	Yes	Yes	Yes	Yes	No	Yes
Sealing	Yes	Yes	No	No	No	Y/N

NCT, non-contrast computerised tomographic angiography; CTA, computerised tomographic angiography; DUS, duplex ultrasonography; CEDU, contrast-enhanced duplex ultrasound; PAX, plain abdominal X-ray; MRI, magnetic resonance imaging.

Computerised Tomographic Angiography

Computerised tomographic angiography (CTA) is a known standard and is the most commonly used modality for follow-up after EVAR, both to detect endoleaks and to measure aneurysm diameter. Early and delayed phase CTA is used for diagnosis of endoleaks (Buth, 2002). The major issues with CTA are contrast-induced nephrotoxicity and the potential cancer risk of ionising radiation. Non-contrast-enhanced CTA can be used in patients with impaired renal function to measure aneurysm diameter, but will not provide any information about the presence of endoleaks. CTA can also detect component separation and kinking of the graft limbs.

Duplex Ultrasonography

Duplex ultrasonography (DUS) is a safe, non-invasive, repeatable method for EVAR surveillance. Several studies have demonstrated a sensitivity of DUS comparable to CTA in detecting clinically significant endoleaks (Bargellini, 2009; Chaer, 2009; Collins, 2007; Sandford, 2006), while Mirza et al. reported an inferior sensitivity of DUS for endoleak detection compared to CEDU and CTA. DUS lacks the ability to give information regarding endograft integrity, sealing and migration (Mirza, 2010). Additionally, it is operator-dependent and is limited by body habitus and bowel gas. Manning et al. concluded that, despite low positive predictive value, DUS is a sensitive test for detecting clinically significant endoleaks (Manning, 2009), a finding that was supported by Karthikesalingam et al. in a systemic review (Karthikesalingam, 2012). It is still a matter of debate whether DUS can be used as a stand-alone modality for EVAR follow-up.

Contrast-Enhanced Duplex Ultrasound

In the systemic review by Karthikesalingam et al. the pooled sensitivity of contrast-enhanced duplex ultrasound (CEDU) was 0.96, and 0.99, and pooled specificity was 0.85 and 1.00 for detection of all types of endoleaks and direct endoleaks respectively, compared to CTA (Karthikesalingam et al., 2012). The advantages of CEDU include that it is safe, uses a non-toxic contrast agent, and it has the ability to detect late and low flow endoleaks. Additionally, it results in the possibility to achieve a dynamic analysis of the flow. Disadvantages are that it is operator-dependent and it needs special equipment and good expertise. CEDU also has the traditional limitations of ultrasound, such as bowel gas and obesity (Corriere, 2004).

Magnetic Resonance Imaging

Magnetic resonance imaging (MRI) with a blood pool contrast agent is effective for endoleak detection and measurement of AAA diameter (Cornelissen, 2008) and is comparable to CTA (Ayuso, 2004). MRI lacks the CTA's risks of radiation and contrast-induced nephrotoxicity. Disadvantages of the MRI include difficulties in assessing device integrity, artefacts from some endografts containing stainless steel, the fact that MRI is not suitable for pacemaker patients and that it is not as widely available as CTA. In addition, the gadolinium contrast agent has been identified as the cause of nephrogenic systemic fibrosis in patients with low glomerular filtration rate (GFR).

Plain Abdominal X-ray

Plain abdominal X-ray (PAX) using anteroposterior and lateral projections gives accurate information on structural disruption, stent fractures and migration, but no information about endoleak and sac diameter (Fearn, 2003). PAX is not a stand-alone imaging modality for the follow-up.

Other modalities

Intra-aneurysm sac pressure measurement, three-dimensional contrast-enhanced ultrasound and digital tomosynthesis are also modalities that have been discussed for EVAR surveillance. However, they are beyond the scope of this thesis.

Surveillance protocols

The Society for Vascular Surgery (SVS) practice guidelines recommend the following protocol for surveillance after EVAR (Chaikof, SVS guidelines, 2009), (Figure 15):

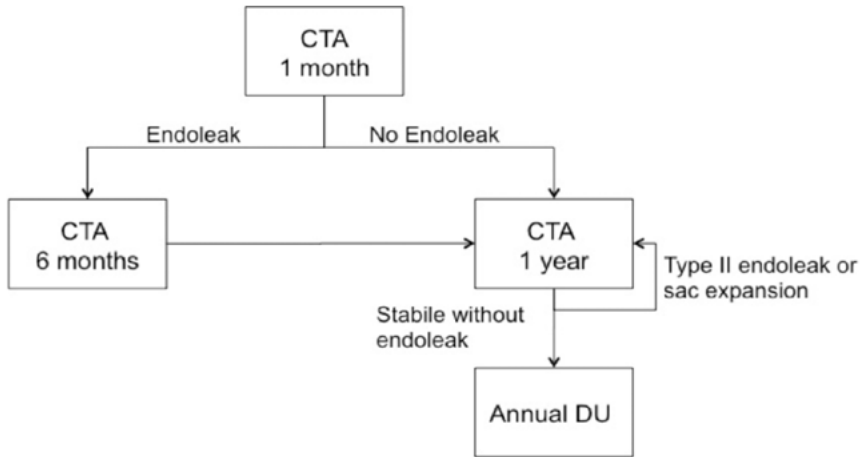


Figure 15. Based on Chaikof EL, Brewster DC, Dalman RL, Makaroun MS, Illig KA, Sicard GA, et al. The care of patients with an abdominal aortic aneurysm: The Society for Vascular Surgery practice guidelines. *J Vasc Surg* 2009; 50 (4 Suppl): S2-49.

The European Society of Vascular Surgery (ESVS) presented another protocol (Moll et al., ESVS guidelines, 2011) (Figure 16):

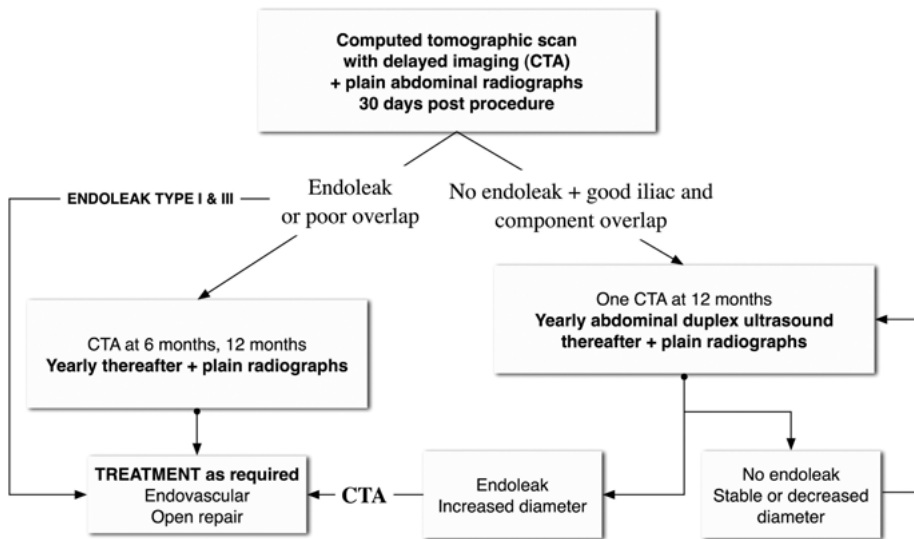


Figure 16. Moll FL, Powell JT, Fraedrich G, et al. Management of abdominal aortic aneurysms clinical practice guidelines of the European Society for Vascular Surgery. *Eur J Vasc Endovasc Surg* 2011 (Reprinted with the permission from EJVES/Elsevier).

Both guidelines recommend a CTA at 30 days postoperatively and, if there is no endoleak, the next surveillance will be a CTA at one year. If there is endoleak (or poor overlap, in the ESVS guidelines), another CTA should be done at six months. Normal CTA at one year will be followed by annual DUS. New or persistent endoleaks or increased sac diameter should be controlled by a CTA at any time. ESVS recommends lateral and anteroposterior projection PAX in every phase of the surveillance to check for metallic frame failure or inadequate component overlap.

Divergence from these guidelines is very common, and almost all vascular units have developed local routines for the EVAR follow-up (Garg, 2015). Most follow-up protocols now include one or two CTA imagings in the first postoperative year, followed by annual DUS, if there are no endoleaks or sealing problems; this is a change from previous recommendations for yearly CTA (Hirsch, 2006; Sapirstein, 2001).

The follow-up programmes varied in the centres involved in the studies described in this thesis. In Uppsala, the follow-up comprised ultrasound at 30 days, CTA at six months, ultrasound at one year, and then ultrasound every two years and CTA every two years. In Rotterdam and Gävle, the follow-up was CTA at one, six and 12 months, then yearly. In both centres, yearly CTA was replaced by ultrasound when no significant abnormalities could be detected.

Compliance with EVAR surveillance and loss to follow-up

Compliance with surveillance and lack to follow-up has been defined differently in different reports. De Mestral et al. define minimum appropriate imaging follow-up (MAIFU) as a CTA or ultrasound of the abdomen within 90 days of EVAR as well as every 15 months after that (de Mestral, 2017). Garg et al. defined complete surveillance as one imaging event within 15 months from EVAR and at least one imaging event every 15 months after that (Garg et al., 2015). AbuRahma et al. considered patients non-compliant if they missed their first follow-up imaging over 6 months or if they did not have any imaging for two years (AbuRahma, 2016). Adherence to surveillance is heterogeneous, and its impact on outcome is unclear.

Aims of this thesis

The aims of this thesis is to identify patients with low versus high risk for complications after EVAR in order to enable tailored post-EVAR surveillance depending on the patient's risk profile.

Specific aims

- To assess the role of early aneurysm sac dynamics after EVAR in determining the long-term outcome (Study I)
- To analyse the impact of the aortic-iliac anatomy of ruptured AAA on outcome after rEVAR (Study II)
- To assess the possibility to predict risk for late complications and reinterventions after EVAR based on evaluation of sealing zone and endoleak on the first postoperative CTA (Study III)
- To study the frequency and methods of detection of post-EVAR complications (Study IV)
- To compare the efficacy of DUS in detecting clinically significant complications to CTA (Study IV)

Materials and methods

Study I and II were based on a multicentre international collaboration between Uppsala university hospital and Gävle district hospital in Sweden and Erasmus university hospital in Rotterdam, Netherlands. Approximately 400 EVAR procedures performed during the period 2000-2011 in Rotterdam were included in these studies. Uppsala and Gävle had performed approximately 500 EVAR procedures during the period 1998-2012. Study III and IV comprised patients from Uppsala and Gävle.

Study I

All patients treated with standard EVAR in the three centres from January 2000 to December 2011 were included. Clinical, procedural and follow-up data were collected in a study-specific database. The inclusion criteria were patients with infrarenal aortic/aortoiliac aneurysm treated with standard EVAR, who had two consecutive postoperative image examinations with the same technique (CTA or DUS): the first within one month of the operation and the second after approximately one year (range 6–18 months). The second of the two scans was considered to be the index examination. The sac dynamic between the two examinations was analysed. Patients with a mycotic aneurysm or previous aortic surgery were excluded. Patients with examinations with two different modalities were also excluded owing to measurement variability between the modalities.

Study II

All patients treated with rEVAR from January 2000 to December 2012, at the three centres were assessed. Only patients with a ruptured infrarenal aortic/aortoiliac aneurysm evident on the preoperative CT, with contrast extravasation or retroperitoneal hematoma, and who were treated with standard EVAR (no procedures including chimneys, fenestrations or branches) were included. Symptomatic aneurysms, isolated iliac aneurysms or previous abdominal aortic surgeries were excluded. Clinical and anatomical baseline characteristics, procedural details and follow-up data were collected in a study-specific database in each centre. Anatomical

measurements were performed with a central lumen line of flow reconstruction using dedicated software (3mensio Vascular™, Pie medical imaging B.V., Bilthoven, the Netherlands). Follow-up information included all registered complications, secondary interventions and mortality.

Study III

All EVAR patients from Uppsala and Gävle who were treated between 2001 and 2012 with a first postoperative CTA within one year from the operation were included in the study. Patients with isolated iliac aneurysm and patients with complex endovascular reconstruction were excluded. The study database comprised baseline characteristics, operative and follow-up data. Anatomical measurements were performed with central luminal line reconstructions using dedicated software (3mensio Vascular™, Pie medical imaging B.V., Bilthoven, the Netherlands and Acquarius iNtuition™, Terarecon, Foster city, CA, USA). Figure 17 demonstrates the method of measuring sealing zone on the CTA.

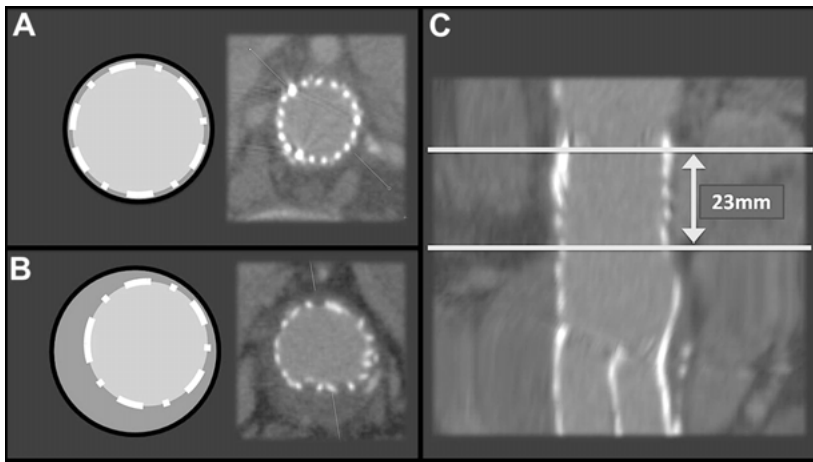


Figure 17. The method of measuring sealing zone on the CTA. **A**, Reconstructed axial slice shows adequate seal, 2 mm below the renal arteries, with good wall-graft apposition in the entire vessel circumference. **B**, Same patient, 30 mm below the renal arteries, shows inadequate seal. **C**, Length of adequate proximal seal, measured in stretched view. (Reprinted with permission from journal of vascular surgery/Elsevier) (Bastos Goncalves et al., 2013).

Study IV

All EVAR patients from the two centres (Uppsala and Gävle) who were treated from 1998 to 2012 were studied. The study database included

preoperative patients' demographic, procedural and postoperative data. All clinically significant complications and reinterventions as well as follow-up modalities, were studied. All paired images (CTA and DUS) within three months of each other were studied to analyse the efficacy of DUS compared to CTA in detecting clinically significant complications. Non-compliance was defined as no follow-up imaging for two years during follow-up or in the first six months after the operation.

Statistical analysis

The data analyses were performed using IBM SPSS Statistics 21-23 (IBM Inc., Chicago, IL, USA).

Categorical variables were presented as count and percentage and compared with Chi-square or Fisher's exact test tests. Continuous variables were presented as mean and standard deviation if normally distributed and as median and range when the distribution was skewed, and compared using one-way Anova test in study I and Student t-tests or Mann-Whitney U-test in study II-IV.

Study I: The Kaplan-Meier method was used to estimate freedom from complications and secondary interventions. A multivariable Cox-regression model was created to assess the independent influence of early sac dynamics on late complication rates. Selection bias was explored by comparing baseline characteristics, survival, follow-up duration, complication and secondary intervention rates in patients included in and excluded from this study.

Study II: The effect of potential predictors on overall mortality and late complications were assessed by Cox hazard regression. The Kaplan-Meier method was used to estimate survival, late complications and reinterventions distribution for the groups, and were compared with log-rank test.

Study III: The effect of potential predictors on primary and secondary endpoints was analysed by logistic regression. Selection bias was assessed by comparing baseline characteristics, follow-up time, mortality, AAA-related complications and reintervention rates between patients included in and excluded from the study. Estimates for the freedom from AAA-related complications and reinterventions for each group were obtained using the Kaplan-Meier method and compared using the log-rank test. The kappa coefficient was used to evaluate interobserver agreement in classifying patients to each group.

Study IV: The kappa coefficient was used to evaluate agreement between the two imaging modalities used during follow-up.

Results

Study I

From 2000 to 2011, 840 patients were treated with EVAR in the three participating institutions. Of these, 45 died within six months, and 198 were excluded. 597 (71 %) were included in the study (Figure 18). In 284 patients (48 %), no shrinkage was observed. Among these, a growth of 5 mm or more was noted in 14 patients (2 %). Moderate shrinkage (5 to 9 mm) was registered in 142 patients (24 %) and major shrinkage (at least 10 mm) in the remaining 171 (29 %).

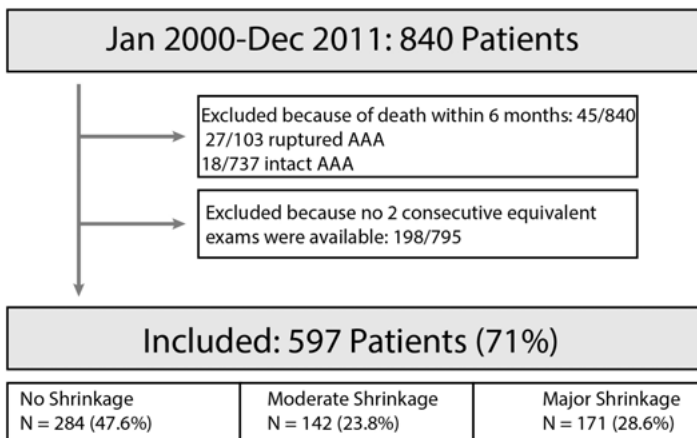


Figure 18. Flow chart for patient selection.

After the index imaging, freedom from complications was 84 % (95% CI: 79-90), 88 % (81-95) and 94 % (90-99) for no shrinkage versus moderate and major shrinkage. Figure 19 shows a Kaplan-Meier analysis of freedom from complications and secondary interventions for all three groups.

No shrinkage compared to major shrinkage was an independent risk factor for late complications (HR 3.37, $p=0.003$) and moderate compared to major shrinkage (HR=2.49, $P=0.045$), as shown in Table 5.

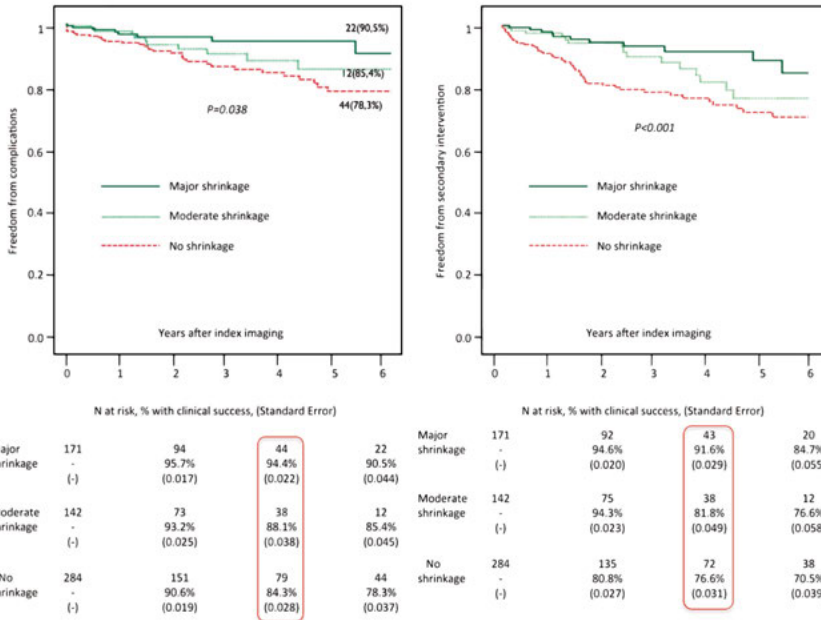


Figure 19. Five years' freedom from late complications and reinterventions, according to early sac dynamics (Bastos Goncalves, 2014).

Table 5

Risk factors for late complications (Cox-regression)

	Hazard Ratio	95% CI	P-value
Moderate shrinkage (compared to major shrinkage)	2.489	1.022-6.057	0.045
No shrinkage (compared to major shrinkage)	3.371	1.512-7.513	0.003
AAA diameter (per mm increase)	1.035	1.017-1.053	<0.001
Treatment of intact (vs. ruptured) AAA	1.675	0.465-6.034	0.430
Aorto-monoiliac design	3.829	1.280-11.45	0.016
Occurrence of intraoperative complications	2.039	1.170-3.552	0.012
Occurrence of complications before index examination	1.070	0.331-3.461	0.910

Freedom from secondary interventions and direct endoleaks were greater for patients with major shrinkage. Table 6 shows late outcome in all three groups according to sac dynamics.

Table 6

Late outcome according to early AAA sac dynamics

	No shrinkage	Moderate shrinkage	Major shrinkage	P-value
	N=284	N=142	N=171	
Total follow-up, years – median (range)	3.1 (11.4)	3.2 (11.8)	3.2 (12.2)	0.35
Follow-up after index exam, years – median (range)	2.2 (11.3)	2.2 (11.2)	2.2 (11.9)	0.31
Complications – N (%)	36 (13)	14 (10)	8 (5)	0.038
Secondary interventions – N (%)	59 (20)	17 (12)	11 (6)	<0.001
Proximal extension cuff or stent – N events	20	7	2	
Limb component extensions – N events	21	9	3	
Coil/glue embolisation – N events	18	1	4	
Open/laparoscopic collateral ligation – N events	9	0	0	
Conversion to open repair – N events	9	2	3	
Post-implantation rupture – N (%)	3 (1)	1 (1)	2 (1)	0.90
Direct endoleak – N (%)	20 (7)	11 (8)	3 (2)	0.040
Type 1a – N events	10	7	1	-
Type 1b – N events	8	4	2	-
Type III – N events	3	1	1	-
Undetermined type – N events	2	1	0	-
Persistent or late-onset type II endoleak – N (%)	55 (19)	9 (6)	9 (5)	<0.001
Endograft occlusion – N (%)	5 (2)	3 (2)	3 (2)	0.95
Endograft infection – N (%)	2 (1)	1 (1)	1 (0)	0.92

Study II

From 2000 to 2012, a total of 112 patients were treated with rEVAR in the three participating institutions. Sixty-one (55 %) of the rEVAR patients were treated inside IFU, and 43 patients (38 %) were treated outside IFU. Eight patients (7 %) lacked preoperative CT of adequate quality for anatomical assessment and were excluded from the analysis. The mean patient age was 73 years. Patients treated outside IFU had larger aneurysms and a higher frequency of peripheral arterial diseases. Of patients outside IFU, 19 (44 %) had neck length <15 mm, 11 (26 %) had neck diameter outside IFU (29mm for excluder, 32mm for others) and 18 (42 %) had an infrarenal angulation > 60 degrees (Table 7).

Table 7

Anatomical characteristics of patients inside vs outside IFU

	Inside IFU	Outside IFU	p-value
Mean neck diameter, mm	25.1	27.1	0.017
Mean neck length, mm	25.1	18.6	0.008
Mean suprarenal angulation, degrees	20.3	37.3	<0.001
Mean infrarenal angulation, degrees	34.3	56.8	<0.001
Neck calcification > 50%, n (%)	2 (3.3)	4 (9.8)	0.216
Neck thrombosis > 50%, n (%)	7 (11.7)	10 (24.4)	0.110
Any iliac stenosis, n (%)	5 (8.9)	7 (16.7)	0.352
Severe iliac tortuosity (> 90°), n (%)	3 (5.4)	4 (10.0)	0.446
Mean right iliac diameter, mm	14.6	16.9	0.104
Mean left iliac diameter, mm	14.4	17.2	0.023

Patients treated outside IFU had a higher 90-day mortality (inside IFU 15 %; outside IFU 37 %; p=0.011).

The mean follow-up for patients surviving the first 30 days was 2.9 years (range 0-11.5 years). Eight out of 30 patients (27 %) surviving the 30-day period and treated outside IFU had graft-related complications, compared to three of the 52 (6 %) patients treated inside IFU (p=0.015). At three years, the Kaplan-Meier estimate of graft-related complications was 44 % for

patients treated outside IFU versus 9 % of patients treated inside IFU ($p=0.001$), as shown in Figure 20.

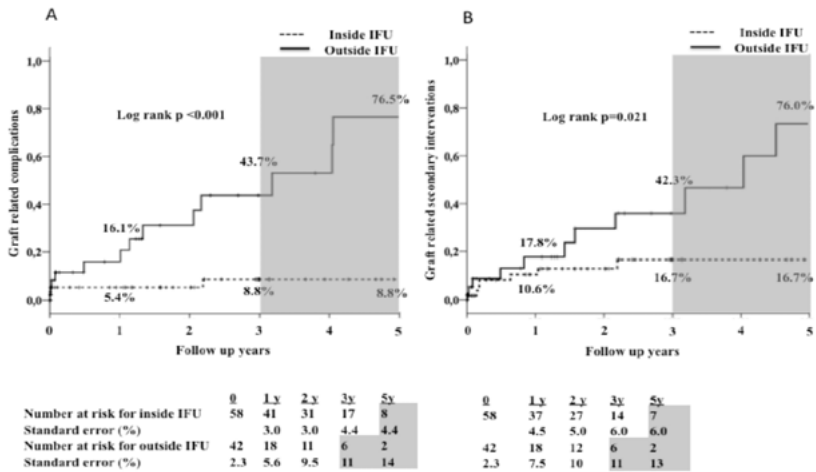


Figure 20. Kaplan-Meier plot for graft-related complications and reintervention for inside versus outside IFU groups.

The outside IFU group had a higher rate of graft-related reinterventions at three years, 42 % outside IFU versus 17 % inside IFU ($p=0.060$). Overall mortality was 56 % for outside IFU, 34 % for inside IFU ($p=0.016$), as shown in Figure 21.

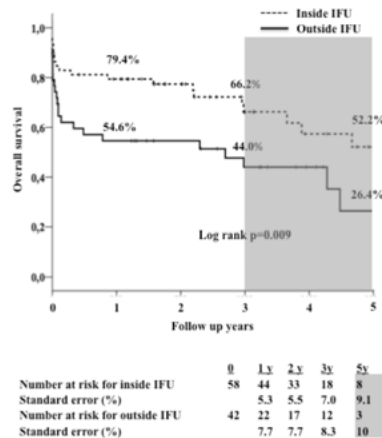


Figure 21. Overall mortality for inside vs outside IFU groups.

Age, surgery under local anaesthesia and neck diameter were predictors of overall survival. Neck length and infrarenal angulation were predictors of late graft-related complications (Table 8).

Table 8

Risk factors for overall mortality and graft-related complications

Univariable analysis	Overall mortality			Graft-related complication		
	HR	95% CI	p-value	HR	95% CI	p-value
Age, per year	1.068	1.032-1.105	<0.001	0.975	0.922-1.031	0.376
Local anaesthesia	0.681	0.386-1.202	0.185	0.756	0.283-2.021	0.577
Outside IFU, Device	2.117	1.167-3.842	0.014	7.066	2.288-21.824	0.001
Neck length <15mm	1.252	0.617-2.540	0.533	7.504	2.830-19.896	<0.001
Neck diameter >29mm	2.993	1.522-5.885	0.001	0.946	0.211-4.240	0.943
Beta angle >60 degrees	1.494	0.732-3.049	0.270	2.514	0.873-7.237	0.087
Multivariable analysis						
Age, per year	1.086	1.032-1.142	0.002	-	-	-
Local anaesthesia	0.404	0.188-0.865	0.020	-	-	-
Neck length <15mm	-	-	-	8.149	3.026-21.944	<0.001
Neck diameter >29mm	2.513	1.065-5.932	0.035	-	-	-
Beta angle >60 degrees	-	-	-	3.094	1.026-9.328	0.045

Study III

Three hundred twenty six patients treated with EVAR at Uppsala and Gävle hospitals during the time period 2001-2012 were included in the study. Patients were classified based on the presence of endoleak and measurement of sealing zone length on first postoperative CTA into a high-risk or low-risk cohort. 35 % of the patients were classified as high-risk, as they had endoleak and/or short sealing (<10 mm seal zone) proximal in the aneurysm neck or distal in the common or external iliac arteries, (Figure 22).

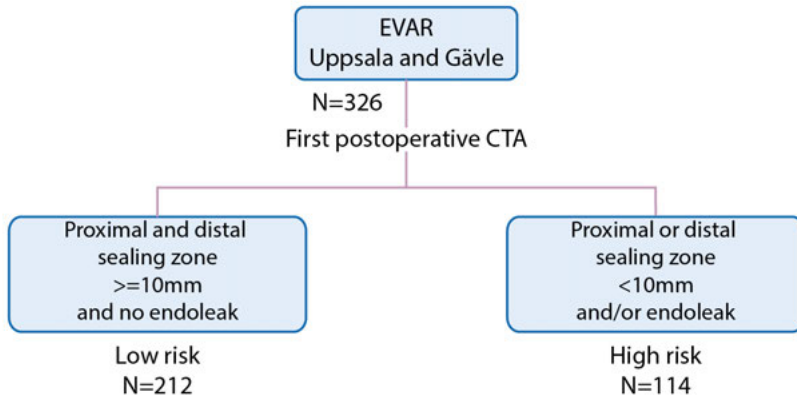


Figure 22. Flow chart for patient selection in the study III.

Within five years of the operation, 3 % AAA-related complications occurred in the low-risk group compared to 47 % in the high-risk group ($p < 0.001$). Reinterventions occurred in 2 % of the low-risk group compared to 39 % of the high-risk group ($p < 0.001$), as shown in Table 9.

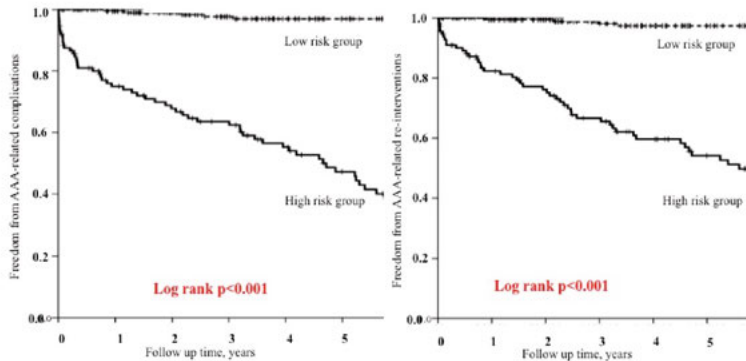
Table 9

Five years frequency of AAA-related complications and reinterventions after EVAR categorised to low or high-risk based on first postoperative CTA

	Low-risk N=212	High-risk N=114	p-value
Overall outcome			
AAA-related complications, n (%)	7 (3.3)	53 (46.5)	<0.001
AAA-related reinterventions, n (%)	4 (1.9)	44 (38.6)	<0.001
Any endoleak, n (%)	4 (1.9)	48 (42.1)	<0.001
Rupture, n (%)	1 (0.5)	3 (2.6)	0.125
Detailed outcome*			
Type Ia endoleak, n (%)	0 (0)	24 (21.1)	<0.001
Type Ib endoleak, n (%)	0 (0)	13 (11.4)	<0.001
Type III endoleak, n (%)	0 (0)	5 (4.4)	0.005
Undefined endoleak, n (%)	1 (0.5)	2 (1.8)	0.281
Type II with expansion	3 (1.4)	13 (11.4)	<0.001
Expansion without clear endoleak, n (%)	2 (0.9)	4 (3.5)	0.189
Graft migration, n (%)	0 (0)	2 (1.8)	0.122
Graft limb thrombosis, n (%)**	12 (5.7)	4 (3.5)	0.391
Proximal cuff/Palmaz [®] stent, n (%)	1 (4.2)	23 (20.2)	<0.001
Relining, n (%)	0 (0)	4 (3.5)	0.014
Limb extension, n (%)	0 (0)	11 (9.6)	<0.001
Coil or glue embolisation, n (%)	3 (1.4)	9 (7.9)	0.005
Conversion to open surgery, n (%)	1 (0.5)	4 (3.5)	0.052
Conversion to AUI, n (%)	0 (0)	1 (0.9)	0.350
Thrombolysis, n (%)**	6 (2.8)	1 (0.9)	0.428

AUI=Aorto-uni-iliac. *Some patients had more than one adverse event and reintervention. ** Graft limb thrombosis and thrombolysis were not regarded as AAA-related complications and reinterventions in the analysis.

In the low-risk group, 97 % patients had five years of freedom from AAA-related complications vs 47 % in the high-risk group, (log rank $p < 0.001$). In the low-risk group, five years freedom from AAA-related reinterventions was 97 % compared to 54 % in the high-risk group (log rank $p < 0.00$), as shown in Figure 23.



	0	1	3	5
Number at risk, low risk group	212	188	138	98
Standard error (%)	0	0	1	1
Number at risk, high risk group	114	75	57	33
Standard error (%)	0	4	4	5

	0	1	3	5
Number at risk, low risk group	212	190	138	98
Standard error (%)	0	0	1	1
Number at risk, high risk group	114	83	61	38
Standard error (%)	0	3	4	5

Figure 23. Kaplan-Meier plot of 5-years freedom from AAA-related complications and reinterventions

During follow-up, there were 1343 surveillance imaging examinations in the low-risk group and 652 in the high-risk group. This results in 168 imaging examinations per AAA-complications in the low-risk group and 11 imaging examinations per complication in the high-risk group (Table 10).

Table 10

Details of imaging of post-EVAR surveillance categorised to low or high-risk based on first postoperative CTA.

	Low-risk	High-risk
Total number of examinations performed to the first complication or the end of the follow-up	1343	652
CTA	533	265
DUS	632	345
Non-contrast-enhanced computerised tomography	79	30
Plain abdominal X-ray	87	4
Others (15 CEDU, 4 DSA, 1 IVUS)	12	8
AAA-related complications during total follow-up time	8	59
<u>Examinations needed for one AAA-related complications</u>	<u>168</u>	<u>11</u>

CTA, computerised tomographic angiography. DUS, duplex ultrasonography. CEDU, Contrast-enhanced duplex ultrasonography. DSA, digital subtraction angiography. IVUS, intravenous ultrasound.

Study IV

Some 454 patients were included in the study from Uppsala and Gävle. Fifteen patients died within 30 days of the operation, and they were excluded from the analysis. Of the remaining 439 patients, 118 (27 %) developed 176 complications (Figure 24).

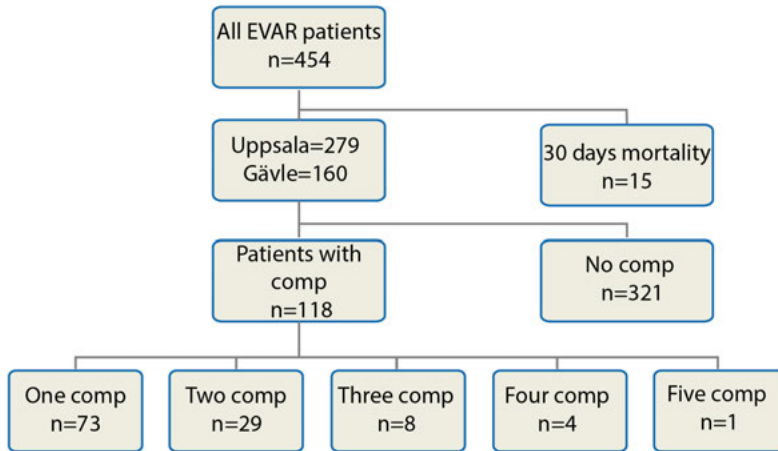


Figure 24. Flow chart of all patients in the study IV.

Table 11 shows baseline characteristics for patients with and without complications after EVAR. Image-detection identified complications in 62 % of the patients. Graft limb thrombosis, graft infection and post-implantation ruptures were mainly symptomatic complications, while sac expansion and endoleaks were mainly asymptomatic imaging-detected.

Table 11

Baseline characteristics of patients with and without post-EVAR complications

	No complication group, N=321	Complication group, N=118	P-Value
Male patients, n (%)	268 (83.5)	99 (83.9)	0.918
Mean follow-up time, years	4.9 (3.2)	5.6 (3.1)	0.345
Maximum aortic diameter, mm (SD)	62.8 (11.9)	64.9 (14.8)	0.116
Age, years (SD)	75.1 (7.0)	74.9 (6.7)	0.715
Rupture, n (%)	19 (6.0)	12 (9.8)	0.157
Cardiac disease, n (%)	156 (49.8)	57 (48.7)	0.836
Pulmonary disease, n (%)	59 (18.8)	23 (20.0)	0.783
Renal disease, n (%)	31 (9.9)	14 (11.9)	0.546
Outside IFU	89 (32.6)	43 (41.3)	0.112
Type of stentgraft used			
Endurant [®] , n (%)	72.0 (23.1)	27 (22.5)	0.898
Zenith [®] , n (%)	132 (42.3)	53 (44.2)	0.727
Excluder [®] , n (%)	83 (26.6)	33 (27.5)	0.850
Talent [®] , n (%)	17 (5.4)	4 (3.3)	0.360
Other endografts, n (%)	8 (2.6)	3 (2.5)	1.000

Endurant[®] and Talent[®] (Medtronic, Santa Rosa, CA, USA), Excluder[®] (W.L. Gore and Associates, Flagstaff, AZ, USA) and Zenith[®] (Cook Medical INC., Bloomington, IN, USA).

Over 80 % of complications occurred within 5 years from the operation and mainly in the first postoperative year (Figure 25).

Fifty-five clinically significant complications had dual imaging (a CTA and a DUS within three months from each other). Additionally, there were 194 paired negative or false positive images during the follow-up period. The kappa coefficient between CTA and DUS for detecting clinically

significant complications was 0.91. The DUS had a sensitivity of 88.8 %, specificity of 99.4 % and negative predictive value of 97 % for clinically significant complications. The compliance with follow-up in the cohort was 59 %.

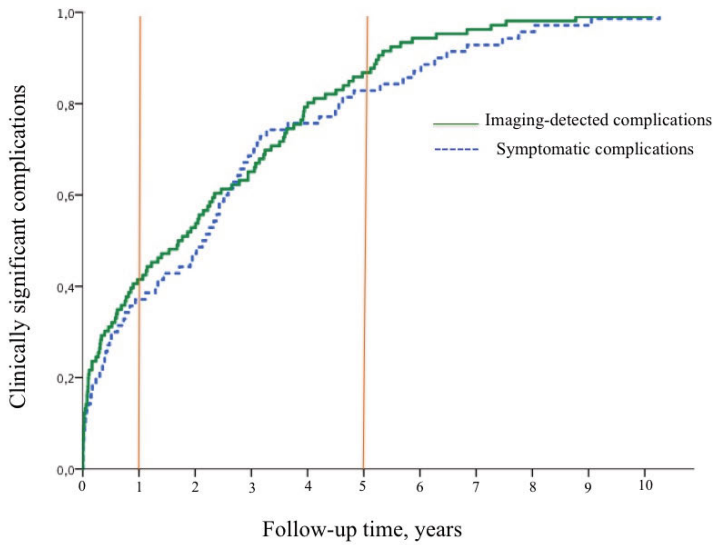


Figure 25. Most of the post-EVAR complications occurred within five years of the operation.

General Discussion

Although EVAR is now the primary treatment modality for AAA in most countries, unfortunately, EVAR's path is not always strewn with roses. A successful EVAR requires some predefined anatomical criteria to be fulfilled, based on the device's IFU. Additionally, the procedure is not infrequently complicated by early or late graft-related complications including the different type of endoleaks and expansion that may lead to post-implantation rupture. Therefore, surveillance after EVAR is regarded as mandatory, and annual imaging is recommended in current guidelines. With increasing number of EVARs, this results in an increasing burden of post-EVAR surveillance examinations.

Post-implantation rupture and the benefit of EVAR surveillance

Post-implantation rupture is regarded as a major failure of EVAR and aims to be prevented by the surveillance programme. Figure 26 clarifies the idea behind the EVAR surveillance programme.

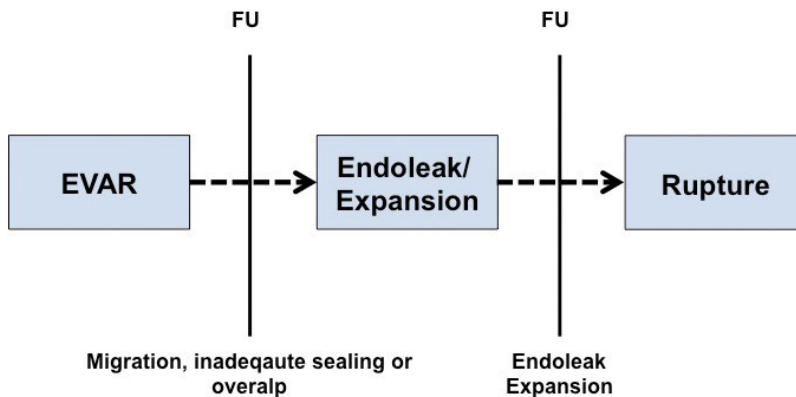


Figure 26. Schematic view of the idea of EVAR follow-up: to detect abnormalities that lead to endoleak and expansion, which may result in rupture.

Post-implantation rupture is a devastating complication. The 30-day mortality rate varies from 44 % in the study IV to 63 % in the Eurostar registry and 66 % in the EVAR trials. Table 12 illustrates a comparison of post-implantation ruptures between the study IV and the EVAR trials.

Table 12

Analysis of post-implantation ruptures between the study IV and EVAR trials

	Study IV, n=454	EVAR trials, n= 848
Post-implantation ruptures, n	16	27
Time to rupture, months	60	58
Ruptures within 30 days from EVAR, n	0	5
No intervention, n	4	15
Successful Endovascular approach, n	8	5
30-days mortality, %	44	66
Survival after reintervention, %	75	75

Cho JS et al. analysed mortality rate of ruptures with and without prior EVAR, He concluded that an existing endograft did not provide any survival benefit in the rupture setting (Cho, 2010). Table 13 demonstrates post-implantation rupture frequency in different trials.

Table 13

Frequency of post-implantation rupture in different trials

Trials	Design	Indication	No. of patients	Rupture frequency, n	Study period, year	Mean follow-up, months
ACE (Becquemin, 2011)	RCT	Elective	150	3	2003-2008	36
(Antoniou, 2015)	Meta	-----	16974	150	1992-2013	---
DREAM (De Bruin et al., 2010)	RCT	Elective	173	2	2000-2003	24
EVAR 1 & 2 (Wyss et al., EVAR trials, 2010)	RCT	Elective	848	27	2000-2003	58
Medicare (Schermerhorn et al., 2008)	Obs	Elective	22830	441	2001-2004	61
OVER (Lederle, 2012)	RCT	Elective	444	6	2000-2005	62
Study IV	Obs	Mixed	454	16	1998-2012	60

Predicting post-implantation rupture is not always easy, and spontaneous ruptures occur despite objection-free follow-up (Dellagrammaticas, 2015; Fransen, 2003; Karthikesalingam et al., 2010; Wyss et al., EVAR trials, 2010). In the study IV, 11 patients had imaging follow-up within 12 months before rupture, but only four ruptures were preceded by complications visible on the follow-up. In EVAR trials, there were no signs of any abnormality in five of 22 late ruptures. In the Eurostar registry, 12 of 34 ruptures were preceded by an unremarkable follow-up (Fransen et al., 2003).

Surveillance after EVAR is highly variable and divergence from existing guidelines is quite common (Garg et al., 2015). In addition, studies report incomplete adherence to EVAR surveillance without a clear effect on the outcome (AbuRahma et al., 2016; Leurs, 2005). Kret et al. reported no survival benefit for patients with complete surveillance and Garg et al. reported a lower rate of total complications, late ruptures and reinterventions in patients with incomplete surveillance (Garg, 2015; Kret, 2013). Five of 10 studies in a systemic review by Spanos et al. suggested that complete surveillance has no impact on survival. Only one study in this review

showed that incomplete surveillance was associated with higher rate of complications (Spanos, 2016).

Other reports underline the role of complete surveillance and compliance to prevent aneurysm expansion and rupture (de Mestral et al., 2017; Hicks, 2017; Jones, 2007). Table 14 shows the rate of compliance in different trials. Study IV and other studies reported fewer adherences to compliance as more time passes from the primary operation (Godfrey, 2015).

Table 14

Compliance rate in different reports

Reports	N of patients	Compliance rate, %	Follow-up time, months
(Schanzer, 2015)	19962	50	60
(AbuRahma, 2016)	565	43	25
(Garg et al., 2015)	9695	43	72
(Godfrey et al., 2015)	50	13	48
(Cohen, 2017)	517	82	30
(Chang, 2013)	1736	92	36
(Wu, 2015)	188	59	40
(Spanos et al., 2016)	36119	50	25-73
(Antoniou et al., 2015)	16974	37	---
(de Mestral et al., 2017)	4988	58	41
Study IV	454	59	59

Early graft limb occlusion and graft thrombosis are usually the result of a technical issues and are detectable on the early perioperative imaging. Late occlusions are usually not detectable with prior imaging (van Zeggeren, 2013). Late occlusions occurred in approximately 2 % of the patients in studies I and II and presented with symptoms. Graft infection is usually a fatal complication but is rarely detectable or preventable with surveillance.

The proportion of complications detected with surveillance imaging varies among studies. While some studies reported that most of the post-EVAR complications are symptomatic (Karthikesalingam et al., 2010; Nordon, 2010), 60 % of complications in study IV were imaging-detected.

Norden et al. reported that no more than 9 % of reinterventions are imaging-initiated (Norden et al., 2010). Newer EVAR devices perform better than older devices regarding late complications and post-implantation ruptures (Al-Jubouri, 2013; Verzini et al., 2014).

All these aspects question the value of the EVAR surveillance programme in its current form with annual imaging.

EVAR follow-up - an increasing burden

The burden of repeated imaging grows larger every year. In Sweden, the number of EVAR operations has exceeded 600 operations per year since 2010 (Figure 27).

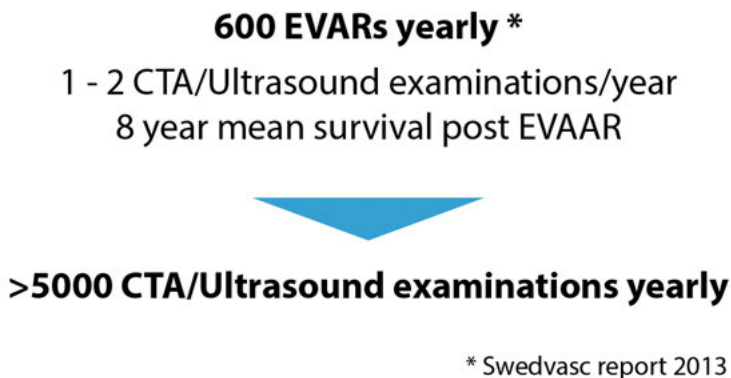

Figure 27. Imaging examinations needed yearly to follow-up EVAR cases in Sweden.

A CTA imaging requires approximately 90 ml of contrast agent and results in 10 mSv of ionising radiation exposure to the patient. The cost of a CTA is approximately 6000 Swedish crowns. The cost for DUS imaging is approximately 4600 Swedish crowns. Repeated annual imaging represents about one-third the total cost of EVAR (Mani, 2008; Sternbergh, 2008). A simple health cost calculation of the follow-up for the cohort in the study III results in a total cost of about 70000 euro to detect one aneurysm-related complication in the low-risk group compared to approximately 4500 euro in the high-risk group.

In addition to the cost and resources used, follow-up may affect the patient's wellbeing (Figure 28). Additionally, reinterventions are not risk free.

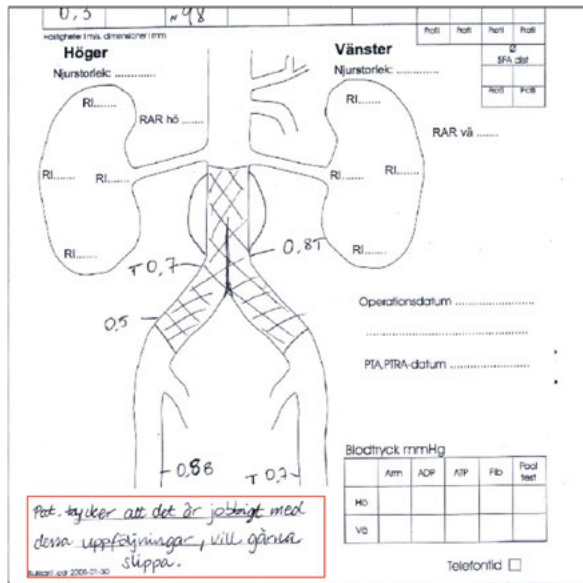


Figure 28. Note in Swedish on the lower left corner of a post-EVAR follow-up scan: “The patient feels the follow-up scans are inconvenient and would like to quit surveillance”.

Type II endoleak and surveillance

The risk associated with presence of type II endoleak is a matter of debate. In the study III, most of the type II endoleaks could be detected on the first postoperative CTA. During follow-up time, 3 (1.4 %) in the low-risk vs 15 (13.2 %) in the high-risk group developed sac growth, $p < 0.001$. In Study IV, there were 78 type II endoleaks, including 28 patients with type II with expansion. Two ruptures in this cohort could be related to type II endoleak by finding bleeding from lumbar arteries during open conversion. As most type II endoleaks are detected on the first postoperative CTA, and a very low percentage of the sac expansions are due to type II endoleak in the patients with adequate seal, is promising and supports that risk stratification based on first CTA is applicable even for this subgroup of patients. The significantly low percentage of sac expansion due to type II endoleaks in the low-risk group is also an interesting finding. Studies report that most causes of rupture were due to direct endoleaks and not type II (Antoniou et al., 2015). Study IV shows a similar trend (Table 15).

Table 15

Post-implantation ruptures in Study IV

Patients	Time to rupture, months	Cause of rupture	Reinterventions	Survival time after rupture, months
1	6	Unknown	No reintervention	0
2	16	Type III	Extension inside the components	68
3	18	Type Ia	Proximal cuff	63
4	22	Type Ib	Limb extension	54
5	26	Type Ia	Proximal cuff	64
6	33	Unknown	Conversion to open repair	68
7	34	Unknown	No reintervention	0
8	38	Type Ia	Proximal cuff	27
9	53	Unknown	No reintervention	0
10	55	Type Ib	Limb extension	17 (Still alive)
11	69	Type II with expansion	Conversion to open repair	0
12	77	Type Ib	Conversion to open repair	0
13	86	Type Ib	Limb extension	10
14	92	Type II with expansion	Open ligation of collaterals	32
15	117	Type Ib	Limb extension	0
16	128	Unknown	No reintervention	0

EVAR for ruptured AAA

Standard EVAR in elective cases with hostile anatomy has resulted in an acceptable outcome in some retrospective analyses (Lee et al., 2013). Ruptured AAAs are, in general, larger in diameter and often have more hostile anatomical characteristics. As an example, 36% of ruptured AAAs were outside IFU for EVAR in the IMPROVE trial (IMPROVE trial

investigators, 2015) and 61 % were regarded as outside IFU in the AJAX trial (Reimerink et al., AJAX trail, 2013). Study II assessed outcomes after a ruptured EVAR, based on the aneurysm anatomy. Patients treated with rEVAR outside IFU had a higher rate of mortality, graft-related complications and reinterventions. Of the patients in the study, 40 % treated outside IFU. Neck diameter > 29mm was the strongest predictor of overall mortality, while short neck length was the main predictor of graft-related complications. Ruptured AAA with hostile anatomy may have better results when treated with more complex endovascular techniques, e.g. chimneys, branched or fenestrated grafts. However, using standard EVAR in these cases should be regarded as high-risk and should be followed by a vigilant surveillance programme.

Can the current studies change EVAR follow-up?

EVAR patients have different risks for post-implantation rupture, depending on several risk factors that have been described in the literature. Study I confirms that early sac dynamics predict EVAR outcome, showing that different degrees of sac shrinkage have different prognostic impacts. Eight of 149 patients in the major shrinkage group developed postoperative complications, of which only three were predictable with follow-up imaging: two type I and one type III endoleak. All three patients had postoperative characteristics that could predict increased risk (inadequate sealing zone and overlaps).

Many studies report the impact of aortic anatomy on the EVAR outcome, but almost all focus on elective cases (Leurs, 2006; Waasdorp, 2005). Study II includes an analysis of EVAR outcome in ruptured cases based on the preoperative aortic anatomy. This study clarifies that expanding EVAR beyond IFU results in increased risk for graft-related complications and overall mortality. However, EVAR outside IFU can be used as a damage control strategy in emergency cases with a more intensive follow-up programme.

Study III stratifies the follow-up based on the results of the first postoperative CTA. Two-thirds of all EVAR patients had adequate sealing proximally and distally and no endoleak in the first postoperative CTA. These patients developed very few complications in the first five years post-EVAR. Delaying subsequent imaging follow-up in this group would reduce surveillance workload remarkably.

Study IV demonstrates that the majority of the complications after EVAR is imaging-detected and occurs within the first five years post-EVAR. DUS has a high negative predictive value and can be used for EVAR follow-up.

Based on the current studies and the existing literature, a risk classification algorithm for EVAR follow-up is suggested below.

Low-risk

- Friendly anatomy (Study II)
- No endoleak and adequate sealing at first postoperative CTA (Study III)
- Major shrinkage at one year (Study I)

These patients have a low risk for complications in the first five years postoperatively, and may not require annual imaging during this period.

High-risk

- Hostile anatomy (Study II)
- Endoleak or inadequate sealing at first postoperative CTA (Study III)
- Increased or unchanged sac diameter at one year (Study I)

These patients are at high-risk for complications and need regular annual imaging (DUS, to be completed with CTA if needed) according to guidelines. Patients with direct endoleaks and sac expansion need further investigation and reintervention.

The role of other risk factors such as intraoperative adjunct procedures, initial aneurysm diameter and patent collateral is less clear. Ruptured AAA by itself is not a risk factor for post-EVAR complications, as shown in Study II.

Figure 29 shows a simplified illustration of a surveillance protocol suggestion, based mainly on first postoperative CTA results and sac dynamic.

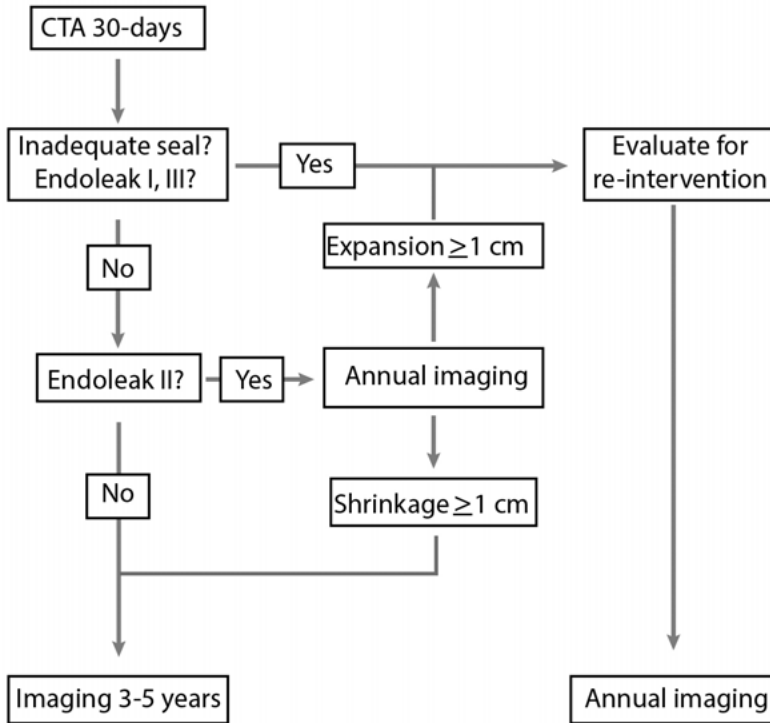


Figure 29. Suggestion for risk-stratified post-EVAR surveillance protocol

Follow-up after five years from EVAR

Corriere et al. reported the occurrence of endoleaks as late as seven years post-EVAR (Corriere et al., 2004). The EVAR 1 trial's 15-year follow-up report stated that increased aneurysm-related mortality after eight years from EVAR was mainly attributable to aneurysm sac rupture (Patel, EVAR trial 1, 2016). Hence, patients at low-risk for complications in the first five years post-EVAR would require imaging and reevaluation after five years. It is unclear if imaging and re-evaluation after five years should be performed yearly or with less intensity. However, it is important to bear in mind that mean survival after elective AAA repair is approximately 8 years (Mani, 2009), and many of the patients have reached an age at which it is not reasonable to continue follow up.

Future perspectives

Most of the studies done on risk stratification of EVAR follow-up are retrospective studies, which restrict generalisability. A prospective and preferably randomised study between the classic follow-up protocol and a risk-stratified protocol is recommended. However, initial attempts on the design of such study indicate that it would require a very large number of cases, and may be difficult to perform practically.

Most of the reports on post-implantation rupture comprise very small cohorts. To better understand different mechanisms behind post-implantation rupture, a national or international analysis of all ruptured cases in an accident-investigation manner may be of interest. The Swedish vascular registry, Swedvasc, is an excellent tool for finding ruptures cases for such a study.

One limitation of almost all randomised trials on elective EVAR includes that the devices they were used were of the older generation. Newer devices and better experiences in endovascular and imaging technology are expected to result in better outcome. Further studies to compare the outcome of EVAR with newer devices and open repair will be of interest, especially when the vascular surgeon's experience in the open repair diminishes.

In addition to risk stratification to reduce the burden of follow-up, preventive measurements to reduce the risk of complications, have been discussed. One option is collateral arteries embolisation to reduce the risk of type II endoleak. Another one is total coverage of aneurysm neck and iliac landing zones to obtain as long sealing as possible and to reduce the risk for future disease progression. Studying long-term effects of these measurements may be beneficial to ensure more durable EVAR results.

Endograft devices are constantly being improved. Distal sealing is a subject of special importance as it is a usual cause of the failure. Developing graft limbs with distal hooks, equivalent to TEVAR grafts with distal component, may have an impact on reducing this kind of complications.

Non-invasive sac pressure monitoring using implantable sensors was a hot subject for several years ago. Unfortunately, the method had many limitations. Newer sensors, preferably integrated with EVAR devices may be a future solution to surveillance issues.

Type II endoleak, as a potential cause of secondary sac rupture is a matter of continual debate. Further studies needed to clarify the nature of type II endoleaks and their role in EVAR failure.

Conclusion

- Sac shrinkage early after EVAR is associated with low risk for late complications and reinterventions.
- Patients with hostile anatomy have less favourable outcomes after ruptured EVAR.
- No endoleak and adequate sealing in the first postoperative CTA is a predictor for a low rate of late complications and reinterventions post-EVAR.
- Most post-EVAR complications are imaging-detected and occur in the early years after surgery.
- DUS is as good as CTA in detecting clinically significant complications after EVAR.

Sammanfattning på svenska (Summary in Swedish)

Bukaortaaneurysm är en vidgning av stora kroppspulsådern, som normalt har en diameter under 30mm. Aneurysmet ökar successivt i storlek för att till slut spricka (rupturera). För att förbygga det dödliga ödet som en ruptur innebär, brukar man operera patienter med en förebyggande operation då aortadiameter överstiger 55mm hos män och 52mm hos kvinnor.

Traditionellt har man opererat bukaortaaneurysm med öppen teknik. Man öppnar buken, tar bort aneurysmet och bytt ut den mot ett konstgjort rör, ett så kallad graft. Operationen är komplex och förenad med risker för organsvikt och 4-7 % risk för död i elektiva fall och över 40 % i akuta fall. Sedan början av 90-talet har man utvecklat en operationsmetod som är minimalinvasiv och baserad på kateterteknik, Endovascular aneurysm reparation, eller EVAR. Istället för att patienten är sövd och hela buken öppnas, så gör man i lokalbedövning små snitt i ljumskarna och placerar ett syntetiskt stentgraft som förstärkning på insidan av stora kroppspulsådern och aneurysmet exkluderas från cirkulationen. Metoden har mindre behov av intensivvård, mindre blodförlust och kortare vårdtid. Flera randomiserade studier har visat minskad dödlighet vid minimalinvasiv kirurgi jämfört med öppen operation.

I de flesta länder har EVAR blivit standard metod för behandling av aortaaneurysm. I Sverige görs ca 600 EVAR årligen. För att EVAR skall lyckas måste vissa anatomiska förutsättningar uppfyllas.

Komplikationer med EVAR är bl.a. att aneurysmet inte alltid helt lyckas isoleras från cirkulationen. I vissa fall kan man hitta fortsatt eller nyttillkommet flöde till aneurysmsäcken, så kallad endoläckage. Endoläckage kan leda till fortsatt vidgning av aneurysmsäcken vilket till slut kan leda till ruptur med ofta hög dödlighet. Andra komplikationer som kan uppstå är migration av stentgraftet, säcktillväxt, trombotisering av graft skänklarna och graft infektion.

För att upptäcka komplikationer i tid och förebygga ruptur, rekommenderas regelbunden uppföljning av alla EVAR patienter, vanligtvis med ultraljud eller datortomografi. Det brukar vara kontroller efter 1, 6, 12 månader och sen årligen eller vartannat år om allt ser bra ut.

Problemet med uppföljningen att den är kostsam, den innebär stor arbetsbelastningen för sjukvården och kan orsaka ångest och oro hos

patienterna. Det vore önskvärt att i framtiden kunna skräddarsy uppföljningen efter EVAR baserad på patienternas risk för att utveckla komplikationer.

Delarbete I

Tidig krympning av aneurysmsäcken efter EVAR operation är associerad med lägre risk för sena komplikationer.

Krympning av aneurysmsäcken har alltid ansetts som ett tecken på en lyckad EVAR operation. I delarbete I har vi undersökt om tidig krympning av säcken har någon effekt på framtida komplikationer. Patienter som behandlats med EVAR mellan 2000- 2011, på 3 sjukhus, två i Sverige (Uppsala och Gävle) och ett i Holland (Erasmus sjukhuset i Rotterdam) undersöktes. Studien inkluderade 597 patienter.

I 284 fall (48 %) hade aneurysmsäcken blivit större eller var oförändrad, vid kontrollundersökning i medel 1 år efter operation. I 142 fall (24 %) hade aneurysmsäcken krympt 5-9mm, och i 171 fall (29 %) hade den krympt 10mm eller mer.

Patienter där aneurysmsäcken hade krympt 10mm eller mer på ett år efter EVAR hade en mycket liten risk för komplikationer upp till fem år efter ingreppet (6 %). Hos patienter där aneurysmsäcken hade krympt 5-9mm var risken för komplikation 12 % och hos patienter med ingen krympning eller tillväxt av aneurysmsäcken var risken 16 %. Slutsatsen av studien var att patienter där aneurysmsäcken krymper redan vid ett års kontroll efter EVAR löper mycket mindre risk för sena komplikationer, och därmed inte behöver lika tät uppföljning.

Delarbete II

Komplex aortaanatomi indikerar högre risk för mortalitet och komplikationer efter EVAR vid rupturerat bukaortaaneurysm.

I andra delarbetet, studerades om det finns skillnad i utfallet efter EVAR operation för rupturerat aneurysm hos patienter som behandlas inom anatomiska riktlinjer för stentgraft behandling (s.k. instructions for use eller IFU), eller utanför IFU.

Hundratolv patienter opererades med EVAR på grund av ruptur 2000-2012 på de tre sjukhus som ingick i det första arbetet. Åtta patienter saknade adekvat preoperativ datortomografi och exkluderades från analyserna då kroppspulsåderns anatomi inte kunde utvärderas. Sextioen patienter (55 %) opererades inom IFU och 43 (38 %) utanför IFU.

Medel uppföljningstiden var 2,9 år. Tre år efter operationen var komplikationsfrekvensen 44 % för gruppen som behandlats utanför IFU och

9 % inom IFU, $p=0,003$. Totalmortaliteten var 56 % utanför IFU och 34 % inom IFU, ($p=0,016$).

Studien visar att EVAR utanför IFU vid rupturerat AAA är associerad med större risk för komplikationer, reinterventioner och högre mortalitet.

Delarbete III

Uppföljning efter endovaskulär aneurysmoperation kan stratifieras baserat på resultatet av första postoperativa datortomografin.

I den här studien undersöktes om patienter som har bra tätningszon mellan stentgraftet och aorta (minst 10 mm) och saknar endoläckage vid första postoperativa datortomografin har mindre risk för sena komplikationer.

Alla EVAR patienter från Uppsala och Gävle (326 patienter) som hade genomgått en första postoperativ datortomografi inom 1 år från EVAR, inkluderades i studien. 35 % klassades som hög risk, dvs de hade ett endoläckage vid första kontrollen eller en tätningszon <10 mm i aneurysmhalsens eller distalt i iliaca. Resten klassades som låg risk.

Fem år efter operation hade 3 % i låg risk gruppen och 47 % i hög risk gruppen drabbats av någon komplikation relaterad till aneurysmet, $p<0,001$. Under samma tidsperiod hade 2 % i låg risk gruppen och 39 % i hög risk gruppen genomgått aneurysmrelaterade reinterventioner, $p<0,001$.

Studien visar att tillräckligt lång tätningszon och inget endoläckage vid första postoperativa datortomografin är associerad med mycket liten risk för aneurysmrelaterade komplikationer upp till 5 år efter EVAR.

Delarbete IV

Upptäckten av sena komplikationer efter endovaskulär aneurysmoperation och betydelsen för uppföljning.

I den här studien analyserades hur sena komplikationer efter EVAR upptäcktes. Hypotesen var att de flesta komplikationer resulterar i symptom och således upptäcks oavsett uppföljningsrutiner. I studien analyserade också om ultraljud kunde upptäcka komplikationer lika bra som datortomografi.

Fyrahundrafemtiofyra patienter som opererades med standard EVAR i Uppsala och Gävle från 1998 till 2012 inkluderades i studien. Femton patienter dog inom 30 dagar och uteslöts från analyserna. Hundraarten (27 %) av patienterna fick 176 komplikationer. Sextiotvå procent av komplikationerna upptäcktes tack vare uppföljningsundersökningar och var asymtomatiska. Åttiofem procent av komplikationerna skedde inom första fem åren efter EVAR, framförallt under första året. Överenskommelsen mellan ultraljud och datortomografi för att upptäcka komplikationer var mycket bra i den här kohorten, med ett kappavärde på 0,91.

Studien visar att de flesta komplikationerna efter EVAR upptäcks tack vare uppföljningsundersökningar, och därför är fortsatt uppföljning nödvändig. Ultraljud är tillräcklig som uppföljningsmetod för att upptäcka kliniskt signifikanta komplikationer.

Acknowledgement

I wish to express my sincere gratitude to all those who have supported me during the process of working on and writing this thesis. I especially want to thank:

My main supervisor, Associate Professor **Kevin Mani**, for your friendship, unfailing support and encouragement, for being available for silly questions at any time!

My co-supervisor and head of the section of vascular surgery, Professor **Anders Wanhainen**, for your never-ending support and enthusiasm, for your brilliant mind and your extraordinary way to find solutions to every problem.

My co-supervisor, Professor **Martin Björck** for introducing me to the world of scientific research, for being such a great scientist, for suggesting Kevin as the main supervisor when he was still in London, for always sharing your knowledge so generously and for all your stories and histories at the dinner tables.

For my co-authors **Frederico Bastos Gonçalves, Professor Hence J. M. Verhagen, Nelson Gomes Oliviera** and all other co-authors of the research team in Rotterdam for excellent and fruitful collaboration.

For my co-author **Olov Haller** for your unconditional and always very prompt response every time I needed your help.

Claes Juhlin, former head of the Department of Surgery at Uppsala University Hospital, **Kristiina Kask**, present head of the department, and **Per Hellman**, head of the Department of Surgical Sciences, for providing me with the resources and conditions to make this work possible.

As my first mentor in vascular surgery, **Torbjörn Tuve**sson, for your professional clinical guidance and encouraging mentorship, for everything I have learned from you, for being such a great person. **Lars Strindberg**, my first endovascular mentor, I am still missing working with you.

Lars Karlsson, my clinical supervisor at Gävle Hospital, for always being patient and supportive. **Khatereh Djavani, Kerry Filler, Knut Torbjörnsson, Kim Gunnarsson and Samuel Ersryd**, former vascular colleagues at Gävle Hospital for great support.

Christer Ljungman, Björn Kragsterman, Gustaf Tegler, Nakisa Esfahani, Achilleas Karkamanis, Demos Dellagrammaticas, Marek Kuzniar, Kalle Sörelius, Jacob Eriksson, Jon Unosson, Olivia Grip and

Tina Hellgren, for all your help, support, joyful moments and making vascular surgery such an amazing job.

My friend **Fuad Bahram**, director of the research centre at Södersjukhuset, Stockholm and excellent graphic designer, for providing me with the cover picture and illustrations of different kinds of endoleaks.

My **former colleagues and the staff** at the Department of Surgery at Gävle Hospital, for all years we have worked together.

My **colleagues and the staff** at the Department of Surgery at Uppsala University Hospital and vascular unit for support and encouragement.

For my colleagues and friends **Mahmud, Zakaria, Ismail, Zirek, Karim, Kajal and Shahban** for being such wonderful friends.

My best friend **Muhamad Ali** for being a very dear friend, always able to cheer me up.

In heaven, **my father**, who was always proud of me. **My mother**, for everything she has done for me. It is difficult to thank her enough. For all my **sisters and brothers** for their unrestricted support.

My family: **Harman, Miro, Meivi and Sharo**, for all love and patience all those times I have been busy working on this thesis. For giving me endless love and hope whenever I needed them.

References

- Abbruzzese, T.A., Kwolek, C.J., Brewster, D.C., Chung, T.K., Kang, J., Conrad, M.F., et al. (2008) Outcomes following endovascular abdominal aortic aneurysm repair (EVAR): an anatomic and device-specific analysis. *J Vasc Surg* 48, 19-28.
- AbuRahma, A.F., Yacoub, M., Hass, S.M., AbuRahma, J., Mousa, A.Y., Dean, L.S., et al. (2016) Compliance of postendovascular aortic aneurysm repair imaging surveillance. *J Vasc Surg* 63, 589-595.
- AbuRahma, A.F., Yacoub, M., Hass, S.M., AbuRahma, J., Mousa, A.Y., Dean, L.S., et al. (2016) Compliance of postendovascular aortic aneurysm repair imaging surveillance. *J Vasc Surg* 63, 589-595.
- AbuRahma, A.F., Yacoub, M., Mousa, A.Y., Abu-Halimah, S., Hass, S.M., Kazil, J., et al. (2016) Aortic Neck Anatomic Features and Predictors of Outcomes in Endovascular Repair of Abdominal Aortic Aneurysms Following vs Not Following Instructions for Use. *J Am Coll Surg* 222, 579-589.
- Al-Jubouri, M., Comerota, A.J., Thakur, S., Aziz, F., Wanjiku, S., Paolini, D., et al. (2013) Reintervention after EVAR and open surgical repair of AAA: a 15-year experience. *Ann Surg* 258, 652-657; discussion 657-658.
- Anderson, P.L., Arons, R.R., Moskowitz, A.J., Gelijns, A., Magnell, C., Faries, P.L., et al. (2004) A statewide experience with endovascular abdominal aortic aneurysm repair: rapid diffusion with excellent early results. *J Vasc Surg* 39, 10-19.
- Antoniou, G.A., Georgiadis, G.S., Antoniou, S.A., Neequaye, S., Brennan, J.A., Torella, F., et al. (2015) Late Rupture of Abdominal Aortic Aneurysm After Previous Endovascular Repair: A Systematic Review and Meta-analysis. *J Endovasc Ther* 22, 734-744.
- Ashton, H.A., Buxton, M.J., Day, N.E., Kim, L.G., Marteau, T.M., Scott, R.A., et al. (2002) The Multicentre Aneurysm Screening Study (MASS) into the effect of abdominal aortic aneurysm screening on mortality in men: a randomised controlled trial. *Lancet* 360, 1531-1539.
- Ayuso, J.R., de Caralt, T.M., Pages, M., Riambau, V., Ayuso, C., Sanchez, M., et al. (2004) MRA is useful as a follow-up technique after endovascular repair of aortic aneurysms with nitinol endoprostheses. *J Magn Reson Imaging* 20, 803-810.
- Bargellini, I., Cioni, R., Napoli, V., Petrucci, P., Vignali, C., Cicorelli, A., et al. (2009) Ultrasonographic surveillance with selective CTA after endovascular repair of abdominal aortic aneurysm. *J Endovasc Ther* 16, 93-104.

- Bastos Goncalves, F., Baderkhan, H., Verhagen, H.J., Wanhainen, A., Bjorck, M., Stolker, R.J., et al. (2014) Early sac shrinkage predicts a low risk of late complications after endovascular aortic aneurysm repair. *Br J Surg* 101, 802-810.
- Bastos Goncalves, F., van de Luijngaarden, K.M., Hoeks, S.E., Hendriks, J.M., ten Raa, S., Rouwet, E.V., et al. (2013) Adequate seal and no endoleak on the first postoperative computed tomography angiography as criteria for no additional imaging up to 5 years after endovascular aneurysm repair. *J Vasc Surg* 57, 1503-1511.
- Beck, A.W., Sedrakyan, A., Mao, J., Venermo, M., Faizer, R., Debus, S., et al. (2016) Variations in Abdominal Aortic Aneurysm Care: A Report From the International Consortium of Vascular Registries. *Circulation* 134, 1948-1958.
- Beckerman, W.E., Tadros, R.O., Faries, P.L., Torres, M., Wengerter, S.P., Vouyouka, A.G., et al. (2016) No major difference in outcomes for endovascular aneurysm repair stent grafts placed outside of instructions for use. *J Vasc Surg* 64, 63-74.e62.
- Becquemin, J.-P., Allaire, E., Desgranges, P., Kobeiter, H. (2005) Delayed Complications Following EVAR. *Techniques in Vascular and Interventional Radiology* 8, 30-40.
- Becquemin, J.P., Majewski, M., Fermani, N., Marzelle, J., Desgrandes, P., Allaire, E., et al. (2008) Colon ischemia following abdominal aortic aneurysm repair in the era of endovascular abdominal aortic repair. *J Vasc Surg* 47, 258-263; discussion 263.
- Becquemin, J.P., Pillet, J.C., Lescalie, F., Sapoval, M., Goueffic, Y., Lermusiaux, P., et al. (2011) A randomized controlled trial of endovascular aneurysm repair versus open surgery for abdominal aortic aneurysms in low- to moderate-risk patients. *J Vasc Surg* 53, 1167-1173.e1161.
- Binkert, C.A., Alencar, H., Singh, J., Baum, R.A. (2006) Translumbar type II endoleak repair using angiographic CT. *J Vasc Interv Radiol* 17, 1349-1353.
- Bjorck, M., Wanhainen, A. (2013) Pathophysiology of AAA: heredity vs environment. *Prog Cardiovasc Dis* 56, 2-6.
- Bown, M.J., Sutton, A.J., Bell, P.R., Sayers, R.D. (2002) A meta-analysis of 50 years of ruptured abdominal aortic aneurysm repair. *Br J Surg* 89, 714-730.
- Brady, A.R., Thompson, S.G., Fowkes, F.G., Greenhalgh, R.M., Powell, J.T. (2004) Abdominal aortic aneurysm expansion: risk factors and time intervals for surveillance. *Circulation* 110, 16-21.
- Brewster, D.C., Geller, S.C., Kaufman, J.A., Cambria, R.P., Gertler, J.P., LaMuraglia, G.M., et al. (1998) Initial experience with endovascular aneurysm repair: comparison of early results with outcome of conventional open repair. *J Vasc Surg* 27, 992-1003; discussion 1004-1005.
- Brewster, D.C., Jones, J.E., Chung, T.K., Lamuraglia, G.M., Kwolek, C.J., Watkins, M.T., et al. (2006) Long-term outcomes after endovascular abdominal aortic aneurysm repair: the first decade. *Ann Surg* 244, 426-438.

- Brown, L.C., Powell, J.T. (1999) Risk factors for aneurysm rupture in patients kept under ultrasound surveillance. UK Small Aneurysm Trial Participants. *Ann Surg* 230, 289-296; discussion 296-287.
- Brown, P.M., Zelt, D.T., Sobolev, B. (2003) The risk of rupture in untreated aneurysms: the impact of size, gender, and expansion rate. *J Vasc Surg* 37, 280-284.
- Budtz-Lilly, J., Venermo, M., Debus, S., Behrendt, C.A., Altreuther, M., Beiles, B., et al. (2017) Editor's Choice - Assessment of International Outcomes of Intact Abdominal Aortic Aneurysm Repair over 9 Years. *Eur J Vasc Endovasc Surg* 54, 13-20.
- Buth, J., Harris, P.L., van Marrewijk, C. (2002) Causes and outcomes of open conversion and aneurysm rupture after endovascular abdominal aortic aneurysm repair: can type II endoleaks be dangerous? *J Am Coll Surg* 194, S98-102.
- Buth, J., Laheij, R.J. (2000) Early complications and endoleaks after endovascular abdominal aortic aneurysm repair: report of a multicenter study. *J Vasc Surg* 31, 134-146.
- Byrne, J., Mehta, M., Dominguez, I., Paty, P.S., Roddy, S.P., Feustel, P., et al. (2013) Does Palmaz XL stent deployment for type 1 endoleak during elective or emergency endovascular aneurysm repair predict poor outcome? A multivariate analysis of 1470 patients. *Ann Vasc Surg* 27, 401-411.
- Candell, L., Tucker, L.Y., Goodney, P., Walker, J., Okuhn, S., Hill, B., et al. (2014) Early and delayed rupture after endovascular abdominal aortic aneurysm repair in a 10-year multicenter registry. *J Vasc Surg* 60, 1146-1152.
- Cao, P., Verzini, F., Zannetti, S., De Rango, P., Parlani, G., Lupattelli, L., et al. (2002) Device migration after endoluminal abdominal aortic aneurysm repair: analysis of 113 cases with a minimum follow-up period of 2 years. *J Vasc Surg* 35, 229-235.
- Chaer, R.A., Gushchin, A., Rhee, R., Marone, L., Cho, J.S., Leers, S., et al. (2009) Duplex ultrasound as the sole long-term surveillance method post-endovascular aneurysm repair: A safe alternative for stable aneurysms. *J Vasc Surg* 49, 845-849.
- Chaikof, E.L., Blankensteijn, J.D., Harris, P.L., White, G.H., Zarins, C.K., Bernhard, V.M., et al. (2002) Reporting standards for endovascular aortic aneurysm repair. *J Vasc Surg* 35, 1048-1060.
- Chaikof, E.L., Blankensteijn, J.D., Harris, P.L., White, G.H., Zarins, C.K., Bernhard, V.M., et al. (2002) Reporting standards for endovascular aortic aneurysm repair. *J Vasc Surg* 35, 1048-1060.
- Chaikof, E.L., Brewster, D.C., Dalman, R.L., Makaroun, M.S., Illig, K.A., Sicard, G.A., et al. (SVS guidelines, 2009) The care of patients with an abdominal aortic aneurysm: The Society for Vascular Surgery practice guidelines. *J Vasc Surg* 50, S2-S49.
- Chang, R.W., Goodney, P., Tucker, L.-Y., Okuhn, S., Hua, H., Rhoades, A., et al. (2013) Ten-year results of endovascular abdominal aortic aneurysm repair from a large multicenter registry. *J Vasc Surg* 58, 324-332.

- Cho, J.S., Park, T., Kim, J.Y., Chaer, R.A., Rhee, R.Y., Makaroun, M.S. (2010) Prior endovascular abdominal aortic aneurysm repair provides no survival benefits when the aneurysm ruptures. *J Vasc Surg* 52, 1127-1134.
- Cieri, E., De Rango, P., Isernia, G., Simonte, G., Verzini, F., Parlani, G., et al. (2013) Effect of stentgraft model on aneurysm shrinkage in 1,450 endovascular aortic repairs. *Eur J Vasc Endovasc Surg* 46, 192-200.
- Cohen, J., Pai, A., Sullivan, T.M., Alden, P., Alexander, J.Q., Cragg, A., et al. (2017) A Dedicated Surveillance Program Improves Compliance with Endovascular Aortic Aneurysm Repair Follow-up. *Ann Vasc Surg* 44, 59-66.
- Collin, J., Araujo, L., Walton, J., Lindsell, D. (1988) Oxford screening programme for abdominal aortic aneurysm in men aged 65 to 74 years. *Lancet* 2, 613-615.
- Collins, J.T., Boros, M.J., Combs, K. (2007) Ultrasound surveillance of endovascular aneurysm repair: a safe modality versus computed tomography. *Ann Vasc Surg* 21, 671-675.
- Comparative clinical effectiveness and cost effectiveness of endovascular strategy v open repair for ruptured abdominal aortic aneurysm: three year results of the IMPROVE randomised trial. (2017) *Bmj* 359, j4859.
- Conrad, M.F., Adams, A.B., Guest, J.M., Paruchuri, V., Brewster, D.C., LaMuraglia, G.M., et al. (2009) Secondary intervention after endovascular abdominal aortic aneurysm repair. *Ann Surg* 250, 383-389.
- Conway, K.P., Byrne, J., Townsend, M., Lane, I.F. (2001) Prognosis of patients turned down for conventional abdominal aortic aneurysm repair in the endovascular and sonographic era: Szilagyi revisited? *J Vasc Surg* 33, 752-757.
- Cornelissen, S.A., Verhagen, H.J., Prokop, M., Moll, F.L., Bartels, L.W. (2008) Visualizing type IV endoleak using magnetic resonance imaging with a blood pool contrast agent. *J Vasc Surg* 47, 861-864.
- Corriere, M.A., Feurer, I.D., Becker, S.Y., Dattilo, J.B., Passman, M.A., Guzman, R.J., et al. (2004) Endoleak following endovascular abdominal aortic aneurysm repair: implications for duration of screening. *Ann Surg* 239, 800-805; discussion 805-807.
- Cronenwett, J.L., Murphy, T.F., Zelenock, G.B., Whitehouse, W.M., Jr., Lindenauer, S.M., Graham, L.M., et al. (1985) Actuarial analysis of variables associated with rupture of small abdominal aortic aneurysms. *Surgery* 98, 472-483.
- De Bruin, J.L., Baas, A.F., Buth, J., Prinssen, M., Verhoeven, E.L., Cuypers, P.W., et al. (2010) Long-term outcome of open or endovascular repair of abdominal aortic aneurysm. *N Engl J Med* 362, 1881-1889.
- de Mestral, C., Croxford, R., Eisenberg, N., Roche-Nagle, G. (2017) The Impact of Compliance with Imaging Follow-up on Mortality After Endovascular Abdominal Aortic Aneurysm Repair: A Population Based Cohort Study. *Eur J Vasc Endovasc Surg* 54, 315-323.
- Dellagrammaticas, D., Baderkhan, H., Mani, K. (2015) Management of Aortic Sac Enlargement Following Successful EVAR in a Frail Patient. *Eur J Vasc Endovasc Surg*.

Desgranges, P., Kobeiter, H., Katsahian, S., Bouffi, M., Gouny, P., Favre, J.P., et al. (2015) Editor's Choice - ECAR (Endovasculaire ou Chirurgie dans les Aneurysmes aorto-iliaques Rompus): A French Randomized Controlled Trial of Endovascular Versus Open Surgical Repair of Ruptured Aorto-iliac Aneurysms. *Eur J Vasc Endovasc Surg* 50, 303-310.

Diethrich, E.B. (2013) Introduction: Behind the iron curtain. *J Endovasc Ther* 20 Suppl 1, 11-2.

Dillon, M., Cardwell, C., Blair, P.H., Ellis, P., Kee, F., Harkin, D.W. (2007) Endovascular treatment for ruptured abdominal aortic aneurysm. *Cochrane Database Syst Rev*, CD005261.

Donald, I., Macvicar, J., Brown, T.G. (1958) Investigation of abdominal masses by pulsed ultrasound. *Lancet* 1, 1188-1195.

The effect of aortic morphology on peri-operative mortality of ruptured abdominal aortic aneurysm. (2015) *Eur Heart J* 36, 1328-1334.

Endovascular aneurysm repair and outcome in patients unfit for open repair of abdominal aortic aneurysm (EVAR trial 2): randomised controlled trial. (2005) *Lancet* 365, 2187-2192.

Endovascular aneurysm repair versus open repair in patients with abdominal aortic aneurysm [EVAR trial 1]: randomised controlled trial. (2005) *Lancet* 365, 2179-2186.

Faries, P.L., Cadot, H., Agarwal, G., Kent, K.C., Hollier, L.H., Marin, M.L. (2003) Management of endoleak after endovascular aneurysm repair: cuffs, coils, and conversion. *J Vasc Surg* 37, 1155-1161.

Fearn, S., Lawrence-Brown, M.M., Semmens, J.B., Hartley, D. (2003) Follow-up after endovascular aortic aneurysm repair: the plain radiograph has an essential role in surveillance. *J Endovasc Ther* 10, 894-901.

Feringa, H.H., Karagiannis, S., Vidakovic, R., Noordzij, P.G., Brugts, J.J., Schouten, O., et al. (2007) Comparison of the incidences of cardiac arrhythmias, myocardial ischemia, and cardiac events in patients treated with endovascular versus open surgical repair of abdominal aortic aneurysms. *Am J Cardiol* 100, 1479-1484.

Fransen, G.A., Desgranges, P., Laheij, R.J., Harris, P.L., Becquemin, J.P. (2003) Frequency, predictive factors, and consequences of stent-graft kink following endovascular AAA repair. *J Endovasc Ther* 10, 913-918.

Fransen, G.A., Vallabhaneni, S.R., Sr., van Marrewijk, C.J., Laheij, R.J., Harris, P.L., Buth, J. (2003) Rupture of infra-renal aortic aneurysm after endovascular repair: a series from EUROSTAR registry. *Eur J Vasc Endovasc Surg* 26, 487-493.

Fransen, G.A.J., Vallabhaneni, S.R., van Marrewijk, C.J., Laheij, R.J.F., Harris, P.L., Buth, J. (2003) Rupture of Infra-renal Aortic Aneurysm after Endovascular Repair: A Series from EUROSTAR Registry. *European Journal of Vascular and Endovascular Surgery* 26, 487-493.

Friedman, S.G. (1988) Alexis Carrel: Jules Verne of cardiovascular surgery. *Am J Surg* 155, 420-424.

- Friedman, S.G., Friedman, M.S. (1989) Matas, Antyllus, and endoaneurysmorrhaphy. *Surgery* 105, 761-763.
- Garg, T., Baker, L.C., Mell, M.W. (2015) Adherence to postoperative surveillance guidelines after endovascular aortic aneurysm repair among Medicare beneficiaries. *J Vasc Surg* 61, 23-27.
- Garg, T., Baker, L.C., Mell, M.W. (2015) Postoperative Surveillance and Long-term Outcomes After Endovascular Aneurysm Repair Among Medicare Beneficiaries. *JAMA Surg* 150, 957-963.
- Giles, K.A., Pomposelli, F., Hamdan, A., Wyers, M., Jhaveri, A., Schermerhorn, M.L. (2009) Decrease in total aneurysm-related deaths in the era of endovascular aneurysm repair. *J Vasc Surg* 49, 543-550; discussion 550-541.
- Giles, K.A., Schermerhorn, M.L., O'Malley, A.J., Cotterill, P., Jhaveri, A., Pomposelli, F.B., et al. (2009) Risk prediction for perioperative mortality of endovascular vs open repair of abdominal aortic aneurysms using the Medicare population. *J Vasc Surg* 50, 256-262.
- Godfrey, A.D., Morbi, A.H., Nordon, I.M. (2015) Patient Compliance with Surveillance Following Elective Endovascular Aneurysm Repair. *Cardiovasc Intervent Radiol* 38, 1130-1136.
- Golledge, J., Norman, P.E., Murphy, M.P., Dalman, R.L. (2017) Challenges and opportunities in limiting abdominal aortic aneurysm growth. *J Vasc Surg* 65, 225-233.
- Greenberg, R.K., Chuter, T.A., Cambria, R.P., Sternbergh, W.C., 3rd, Fearnot, N.E. (2008) Zenith abdominal aortic aneurysm endovascular graft. *J Vasc Surg* 48, 1-9.
- Greenberg, R.K., Chuter, T.A., Sternbergh, W.C., 3rd, Fearnot, N.E. (2004) Zenith AAA endovascular graft: intermediate-term results of the US multicenter trial. *J Vasc Surg* 39, 1209-1218.
- Greenhalgh, R.M., Brown, L.C., Kwong, G.P., Powell, J.T., Thompson, S.G. (2004) Comparison of endovascular aneurysm repair with open repair in patients with abdominal aortic aneurysm (EVAR trial 1), 30-day operative mortality results: randomised controlled trial. *Lancet* 364, 843-848.
- Greenhalgh, R.M., Brown, L.C., Powell, J.T., Thompson, S.G., Epstein, D., Sculpher, M.J. (2010) Endovascular versus open repair of abdominal aortic aneurysm. *N Engl J Med* 362, 1863-1871.
- Hajibandeh, S., Ahmad, N., Antoniou, G.A., Torella, F. (2015) Is intervention better than surveillance in patients with type 2 endoleak post-endovascular abdominal aortic aneurysm repair? *Interact Cardiovasc Thorac Surg* 20, 128-134.
- Harris, P.L., Vallabhaneni, S.R., Desgranges, P., Becquemin, J.P., van Marrewijk, C., Laheij, R.J. (2000) Incidence and risk factors of late rupture, conversion, and death after endovascular repair of infrarenal aortic aneurysms: the EUROSTAR experience. European Collaborators on Stent/graft techniques for aortic aneurysm repair. *J Vasc Surg* 32, 739-749.

- Herman, C.R., Charbonneau, P., Hongku, K., Dubois, L., Hossain, S., Lee, K., et al. (2017) Any nonadherence to instructions for use predicts graft-related adverse events in patients undergoing elective endovascular aneurysm repair. *J Vasc Surg*.
- Hertzer, N.R., Mascha, E.J., Karafa, M.T., O'Hara, P.J., Krajewski, L.P., Beven, E.G. (2002) Open infrarenal abdominal aortic aneurysm repair: the Cleveland Clinic experience from 1989 to 1998. *J Vasc Surg* 35, 1145-1154.
- Hicks, C.W., Zarkowsky, D.S., Bostock, I.C., Stone, D.H., Black, J.H., Eldrup-Jorgensen, J., et al. (2017) Endovascular aneurysm repair patients who are lost to follow-up have worse outcomes. *J Vasc Surg* 65, 1625-1635.
- Higashiura, W., Greenberg, R.K., Katz, E., Geiger, L., Bathurst, S. (2007) Predictive factors, morphologic effects, and proposed treatment paradigm for type II endoleaks after repair of infrarenal abdominal aortic aneurysms. *J Vasc Interv Radiol* 18, 975-981.
- Hirsch, A.T., Haskal, Z.J., Hertzer, N.R., Bakal, C.W., Creager, M.A., Halperin, J.L., et al. (2006) ACC/AHA 2005 Practice Guidelines for the management of patients with peripheral arterial disease (lower extremity, renal, mesenteric, and abdominal aortic). *Circulation* 113, e463-654.
- Hobo, R., Buth, J. (2006) Secondary interventions following endovascular abdominal aortic aneurysm repair using current endografts. A EUROSTAR report. *J Vasc Surg* 43, 896-902.
- Hoornweg, L.L., Wisselink, W., Vahl, A., Balm, R. (2007) The Amsterdam Acute Aneurysm Trial: suitability and application rate for endovascular repair of ruptured abdominal aortic aneurysms. *Eur J Vasc Endovasc Surg* 33, 679-683.
- Houbballah, R., Majewski, M., Becquemin, J.P. (2010) Significant sac retraction after endovascular aneurysm repair is a robust indicator of durable treatment success. *J Vasc Surg* 52, 878-883.
- Huber, T.S., Wang, J.G., Derrow, A.E., Dame, D.A., Ozaki, C.K., Zelenock, G.B., et al. (2001) Experience in the United States with intact abdominal aortic aneurysm repair. *J Vasc Surg* 33, 304-310; discussion 310-301.
- Igari, K., Kudo, T., Toyofuku, T., Jibiki, M., Inoue, Y. (2014) Outcomes following endovascular abdominal aortic aneurysm repair both within and outside of the instructions for use. *Ann Thorac Cardiovasc Surg* 20, 61-66.
- Johnston, K.W., Rutherford, R.B., Tilson, M.D., Shah, D.M., Hollier, L., Stanley, J.C. (1991) Suggested standards for reporting on arterial aneurysms. Subcommittee on Reporting Standards for Arterial Aneurysms, Ad Hoc Committee on Reporting Standards, Society for Vascular Surgery and North American Chapter, International Society for Cardiovascular Surgery. *J Vasc Surg* 13, 452-458.
- Jones, J.E., Atkins, M.D., Brewster, D.C., Chung, T.K., Kwolek, C.J., LaMuraglia, G.M., et al. (2007) Persistent type 2 endoleak after endovascular repair of abdominal aortic aneurysm is associated with adverse late outcomes. *J Vasc Surg* 46, 1-8.
- Jones, W.B., Taylor, S.M., Kalbaugh, C.A., Joels, C.S., Blackhurst, D.W., Langan, E.M., 3rd, et al. (2007) Lost to follow-up: a potential under-appreciated limitation of endovascular aneurysm repair. *J Vasc Surg* 46, 434-440; discussion 440-431.

Karthikesalingam, A., Al-Jundi, W., Jackson, D., Boyle, J.R., Beard, J.D., Holt, P.J., et al. (2012) Systematic review and meta-analysis of duplex ultrasonography, contrast-enhanced ultrasonography or computed tomography for surveillance after endovascular aneurysm repair. *Br J Surg* 99, 1514-1523.

Karthikesalingam, A., Holt, P.J., Hinchliffe, R.J., Nordon, I.M., Loftus, I.M., Thompson, M.M. (2010) Risk of reintervention after endovascular aortic aneurysm repair. *Br J Surg* 97, 657-663.

Karthikesalingam, A., Holt, P.J., Vidal-Diez, A., Choke, E.C., Patterson, B.O., Thompson, L.J., et al. (2013) Predicting aortic complications after endovascular aneurysm repair. *Br J Surg* 100, 1302-1311.

Kasirajan, K., Matteson, B., Marek, J.M., Langsfeld, M. (2003) Technique and results of transfemoral superselective coil embolization of type II lumbar endoleak. *J Vasc Surg* 38, 61-66.

Kelso, R.L., Lyden, S.P., Butler, B., Greenberg, R.K., Eagleton, M.J., Clair, D.G. (2009) Late conversion of aortic stent grafts. *J Vasc Surg* 49, 589-595.

Kolvenbach, R., Pinter, L., Raghunandan, M., Cheshire, N., Ramadan, H., Dion, Y.M. (2002) Laparoscopic remodeling of abdominal aortic aneurysms after endovascular exclusion: a technical description. *J Vasc Surg* 36, 1267-1270.

Kret, M.R., Azarbal, A.F., Mitchell, E.L., Liem, T.K., Landry, G.J., Moneta, G.L. (2013) Compliance with long-term surveillance recommendations following endovascular aneurysm repair or type B aortic dissection. *J Vasc Surg* 58, 25-31.

Lal, B.K., Zhou, W., Li, Z., Kyriakides, T., Matsumura, J., Lederle, F.A., et al. (OVER trial, 2015) Predictors and outcomes of endoleaks in the Veterans Affairs Open Versus Endovascular Repair (OVER) Trial of Abdominal Aortic Aneurysms. *J Vasc Surg* 62, 1394-1404.

Lederle, F.A., Freischlag, J.A., Kyriakides, T.C., Matsumura, J.S., Padberg, F.T., Jr., Kohler, T.R., et al. (2012) Long-term comparison of endovascular and open repair of abdominal aortic aneurysm. *N Engl J Med* 367, 1988-1997.

Lederle, F.A., Freischlag, J.A., Kyriakides, T.C., Padberg, F.T., Jr., Matsumura, J.S., Kohler, T.R., et al. (2009) Outcomes following endovascular vs open repair of abdominal aortic aneurysm: a randomized trial. *Jama* 302, 1535-1542.

Lederle, F.A., Johnson, G.R., Wilson, S.E., Ballard, D.J., Jordan, W.D., Jr., Blebea, J., et al. (2002) Rupture rate of large abdominal aortic aneurysms in patients refusing or unfit for elective repair. *JAMA* 287, 2968-2972.

Lee, J.T., Ullery, B.W., Zarins, C.K., Olcott, C.t., Harris, E.J., Jr., Dalman, R.L. (2013) EVAR deployment in anatomically challenging necks outside the IFU. *Eur J Vasc Endovasc Surg* 46, 65-73.

Lee, W.A., Carter, J.W., Upchurch, G., Seeger, J.M., Huber, T.S. (2004) Perioperative outcomes after open and endovascular repair of intact abdominal aortic aneurysms in the United States during 2001. *J Vasc Surg* 39, 491-496.

Leurs, L.J., Kievit, J., Dagnelie, P.C., Nelemans, P.J., Buth, J. (2006) Influence of infrarenal neck length on outcome of endovascular abdominal aortic aneurysm repair. *J Endovasc Ther* 13, 640-648.

- Leurs, L.J., Laheij, R.J., Buth, J. (2005) What determines and are the consequences of surveillance intensity after endovascular abdominal aortic aneurysm repair? *Ann Vasc Surg* 19, 868-875.
- Lilja, F., Mani, K., Wanhainen, A. (2017) Editor's Choice - Trend-break in Abdominal Aortic Aneurysm Repair With Decreasing Surgical Workload. *Eur J Vasc Endovasc Surg* 53, 811-819.
- Lindblad, B., Borner, G., Gottsater, A. (2005) Factors associated with development of large abdominal aortic aneurysm in middle-aged men. *Eur J Vasc Endovasc Surg* 30, 346-352.
- Lindholt, J.S., Juul, S., Fasting, H., Vammen, S., Henneberg, E.W. (2003) [Hospital costs and benefits of screening for abdominal aortic aneurysm. Results from a randomized screening trial]. *Ugeskr Laeger* 165, 579-583.
- Linne, A., Leander, K., Lindstrom, D., Tornberg, S., Hultgren, R. (2014) Reasons for non-participation in population-based abdominal aortic aneurysm screening. *Br J Surg* 101, 481-487.
- Livesay, J.J., Messner, G.N., Vaughn, W.K. (2005) Milestones in the treatment of aortic aneurysm: Denton A. Cooley, MD, and the Texas Heart Institute. *Tex Heart Inst J* 32, 130-134.
- Maldonado, T.S., Rosen, R.J., Rockman, C.B., Adelman, M.A., Bajakian, D., Jacobowitz, G.R., et al. (2003) Initial successful management of type I endoleak after endovascular aortic aneurysm repair with n-butyl cyanoacrylate adhesive. *J Vasc Surg* 38, 664-670.
- Maleux, G., Koolen, M., Heye, S. (2009) Complications after endovascular aneurysm repair. *Semin Intervent Radiol* 26, 3-9.
- Malina, M., Lindblad, B., Ivancev, K., Lindh, M., Malina, J., Brunkwall, J. (1998) Endovascular AAA exclusion: will stents with hooks and barbs prevent stent-graft migration? *J Endovasc Surg* 5, 310-317.
- Mani, K., Bjorck, M., Lundkvist, J., Wanhainen, A. (2008) Similar cost for elective open and endovascular AAA repair in a population-based setting. *J Endovasc Ther* 15, 1-11.
- Mani, K., Bjorck, M., Lundkvist, J., Wanhainen, A. (2009) Improved long-term survival after abdominal aortic aneurysm repair. *Circulation* 120, 201-211.
- Mani, K., Lees, T., Beiles, B., Jensen, L.P., Venermo, M., Simo, G., et al. (2011) Treatment of abdominal aortic aneurysm in nine countries 2005-2009: a vascunet report. *Eur J Vasc Endovasc Surg* 42, 598-607.
- Mani, K., Venermo, M., Beiles, B., Menyhei, G., Altreuther, M., Loftus, I., et al. (2015) Regional Differences in Case Mix and Peri-operative Outcome After Elective Abdominal Aortic Aneurysm Repair in the Vascunet Database. *Eur J Vasc Endovasc Surg* 49, 646-652.
- Manning, B.J., O'Neill, S.M., Haider, S.N., Colgan, M.P., Madhavan, P., Moore, D.J. (2009) Duplex ultrasound in aneurysm surveillance following endovascular aneurysm repair: a comparison with computed tomography aortography. *J Vasc Surg* 49, 60-65.

- Marchiori, A., von Ristow, A., Guimaraes, M., Schonholz, C., Uflacker, R. (2011) Predictive factors for the development of type II endoleaks. *J Endovasc Ther* 18, 299-305.
- Matsumura, J.S., Brewster, D.C., Makaroun, M.S., Naftel, D.C. (2003) A multicenter controlled clinical trial of open versus endovascular treatment of abdominal aortic aneurysm. *J Vasc Surg* 37, 262-271.
- McGregor, J.C., Pollock, J.G., Anton, H.C. (1975) The value of ultrasonography in the diagnosis of abdominal aortic aneurysm. *Scott Med J* 20, 133-137.
- Mehta, M., Sternbach, Y., Taggart, J.B., Kreienberg, P.B., Roddy, S.P., Paty, P.S.K., et al. (2010) Long-term outcomes of secondary procedures after endovascular aneurysm repair. *J Vasc Surg* 52, 1442-1449.
- Mirza, T.A., Karthikesalingam, A., Jackson, D., Walsh, S.R., Holt, P.J., Hayes, P.D., et al. (2010) Duplex ultrasound and contrast-enhanced ultrasound versus computed tomography for the detection of endoleak after EVAR: systematic review and bivariate meta-analysis. *Eur J Vasc Endovasc Surg* 39, 418-428.
- Moll, F.L., Powell, J.T., Fraedrich, G., Verzini, F., Haulon, S., Waltham, M., et al. (2011) Management of abdominal aortic aneurysms clinical practice guidelines of the European society for vascular surgery. *Eur J Vasc Endovasc Surg* 41 Suppl 1, S1-S58.
- Moll, F.L., Powell, J.T., Fraedrich, G., Verzini, F., Haulon, S., Waltham, M., et al. (ESVS guidelines, 2011) Management of abdominal aortic aneurysms clinical practice guidelines of the European society for vascular surgery. *Eur J Vasc Endovasc Surg* 41 Suppl 1, S1-s58.
- Nakai, M., Sato, M., Sato, H., Sakaguchi, H., Tanaka, F., Ikoma, A., et al. (2013) Midterm results of endovascular abdominal aortic aneurysm repair: comparison of instruction-for-use (IFU) cases and non-IFU cases. *Jpn J Radiol* 31, 585-592.
- Noel, A.A., Gloviczki, P., Cherry, K.J., Jr., Bower, T.C., Panneton, J.M., Mozes, G.I., et al. (2001) Ruptured abdominal aortic aneurysms: the excessive mortality rate of conventional repair. *J Vasc Surg* 34, 41-46.
- Noorani, A., Page, A., Walsh, S.R., Varty, K., Hayes, P.D., Boyle, J.R. (2012) Mid-term outcomes following emergency endovascular aortic aneurysm repair for ruptured abdominal aortic aneurysms. *Eur J Vasc Endovasc Surg* 43, 382-385.
- Nordon, I.M., Karthikesalingam, A., Hinchliffe, R.J., Holt, P.J., Loftus, I.M., Thompson, M.M. (2010) Secondary interventions following endovascular aneurysm repair (EVAR) and the enduring value of graft surveillance. *Eur J Vasc Endovasc Surg* 39, 547-554.
- Norman, P.E., Jamrozik, K., Lawrence-Brown, M.M., Le, M.T., Spencer, C.A., Tuohy, R.J., et al. (2004) Population based randomised controlled trial on impact of screening on mortality from abdominal aortic aneurysm. *BMJ* 329, 1259.
- Norman, P.E., Powell, J.T. (2007) Abdominal aortic aneurysm: the prognosis in women is worse than in men. *Circulation* 115, 2865-2869.

- Nowygrod, R., Egorova, N., Greco, G., Anderson, P., Gelijns, A., Moskowitz, A., et al. (2006) Trends, complications, and mortality in peripheral vascular surgery. *J Vasc Surg* 43, 205-216.
- Ouriel, K., Clair, D.G., Greenberg, R.K., Lyden, S.P., O'Hara, P.J., Sarac, T.P., et al. (2003) Endovascular repair of abdominal aortic aneurysms: device-specific outcome. *J Vasc Surg* 37, 991-998.
- Parodi, J.C., Palmaz, J.C., Barone, H.D. (1991) Transfemoral intraluminal graft implantation for abdominal aortic aneurysms. *Ann Vasc Surg* 5, 491-499.
- Patel, R., Sweeting, M.J., Powell, J.T., Greenhalgh, R.M. (EVAR 1 trial, 2016) Endovascular versus open repair of abdominal aortic aneurysm in 15-years' follow-up of the UK endovascular aneurysm repair trial 1 (EVAR trial 1): a randomised controlled trial. *The Lancet* 388, 2366-2374.
- Patel, R., Sweeting, M.J., Powell, J.T., Greenhalgh, R.M. (EVAR trial 1, 2016) Endovascular versus open repair of abdominal aortic aneurysm in 15-years' follow-up of the UK endovascular aneurysm repair trial 1 (EVAR trial 1): a randomised controlled trial. *Lancet* 388, 2366-2374.
- Patel, S.R., Allen, C., Grima, M.J., Brownrigg, J.R.W., Patterson, B.O., Holt, P.J.E., et al. (2017) A Systematic Review of Predictors of Reintervention After EVAR: Guidance for Risk-Stratified Surveillance. *Vasc Endovascular Surg* 51, 417-428.
- Piazza, M., Squizzato, F., Miccoli, T., Lepidi, S., Menegolo, M., Grego, F., et al. (2017) Definition of Type II Endoleak Risk Based on Preoperative Anatomical Characteristics. *J Endovasc Ther* 24, 566-572.
- Powell, J.T., Gotensparre, S.M., Sweeting, M.J., Brown, L.C., Fowkes, F.G., Thompson, S.G. (2011) Rupture rates of small abdominal aortic aneurysms: a systematic review of the literature. *Eur J Vasc Endovasc Surg* 41, 2-10.
- Powell, J.T., Sweeting, M.J., Thompson, M.M., Ashleigh, R., Bell, R., Gomes, M., et al. (2014) Endovascular or open repair strategy for ruptured abdominal aortic aneurysm: 30 day outcomes from IMPROVE randomised trial. *Bmj* 348, f7661.
- Powell, J.T., Sweeting, M.J., Ulug, P., Blankensteijn, J.D., Lederle, F.A., Becquemin, J.P., et al. (2017) Meta-analysis of individual-patient data from EVAR-1, DREAM, OVER and ACE trials comparing outcomes of endovascular or open repair for abdominal aortic aneurysm over 5 years. *Br J Surg* 104, 166-178.
- Prance, S.E., Wilson, Y.G., Cosgrove, C.M., Walker, A.J., Wilkins, D.C., Ashley, S. (1999) Ruptured abdominal aortic aneurysms: selecting patients for surgery. *Eur J Vasc Endovasc Surg* 17, 129-132.
- Prinssen, M., Verhoeven, E.L., Buth, J., Cuypers, P.W., van Sambeek, M.R., Balm, R., et al. (2004) A randomized trial comparing conventional and endovascular repair of abdominal aortic aneurysms. *N Engl J Med* 351, 1607-1618.
- Prisant, L.M., Mondy, J.S., 3rd (2004) Abdominal aortic aneurysm. *J Clin Hypertens (Greenwich)* 6, 85-89.
- Reimerink, J.J., Hoornweg, L.L., Vahl, A.C., Wisselink, W., van den Broek, T.A., Legemate, D.A., et al. (AJAX trail, 2013) Endovascular repair versus open repair of

- ruptured abdominal aortic aneurysms: a multicenter randomized controlled trial. *Ann Surg* 258, 248-256.
- Resch, T., Malina, M., Lindblad, B., Malina, J., Brunkwall, J., Ivancev, K. (2000) The impact of stent design on proximal stent-graft fixation in the abdominal aorta: an experimental study. *Eur J Vasc Endovasc Surg* 20, 190-195.
- Rodway, A.D., Powell, J.T., Brown, L.C., Greenhalgh, R.M. (2008) Do abdominal aortic aneurysm necks increase in size faster after endovascular than open repair? *Eur J Vasc Endovasc Surg* 35, 685-693.
- Sandford, R.M., Bown, M.J., Fishwick, G., Murphy, F., Naylor, M., Sensier, Y., et al. (2006) Duplex ultrasound scanning is reliable in the detection of endoleak following endovascular aneurysm repair. *Eur J Vasc Endovasc Surg* 32, 537-541.
- Sapirstein, W., Chandeysson, P., Wentz, C. (2001) The Food and Drug Administration approval of endovascular grafts for abdominal aortic aneurysm: an 18-month retrospective. *J Vasc Surg* 34, 180-183.
- Schanzer, A., Messina, L.M., Ghosh, K., Simons, J.P., Robinson, W.P., 3rd, Aiello, F.A., et al. (2015) Follow-up compliance after endovascular abdominal aortic aneurysm repair in Medicare beneficiaries. *J Vasc Surg* 61, 16-22.e11.
- Schermerhorn, M.L., O'Malley, A.J., Jhaveri, A., Cotterill, P., Pomposelli, F., Landon, B.E. (2008) Endovascular vs. open repair of abdominal aortic aneurysms in the Medicare population. *N Engl J Med* 358, 464-474.
- Schurink, G.W., Aarts, N.J., Wilde, J., van Baalen, J.M., Chuter, T.A., Schultze Kool, L.J., et al. (1998) Endoleakage after stent-graft treatment of abdominal aneurysm: implications on pressure and imaging--an in vitro study. *J Vasc Surg* 28, 234-241.
- Schuermann, R.C.L., van Noort, K., Overeem, S.P., Ouriel, K., Jordan, W.D., Jr., Muhs, B.E., et al. (2017) Aortic Curvature Is a Predictor of Late Type Ia Endoleak and Migration After Endovascular Aneurysm Repair. *J Endovasc Ther* 24, 411-417.
- Scott, R.A., Bridgewater, S.G., Ashton, H.A. (2002) Randomized clinical trial of screening for abdominal aortic aneurysm in women. *Br J Surg* 89, 283-285.
- Sheehan, M.K., Barbato, J., Compton, C.N., Zajko, A., Rhee, R., Makaroun, M.S. (2004) Effectiveness of coiling in the treatment of endoleaks after endovascular repair. *J Vasc Surg* 40, 430-434.
- Sheehan, M.K., Ouriel, K., Greenberg, R., McCann, R., Murphy, M., Fillinger, M., et al. (2006) Are type II endoleaks after endovascular aneurysm repair endograft dependent? *J Vasc Surg* 43, 657-661.
- Silverberg, D., Baril, D.T., Ellozy, S.H., Carroccio, A., Greyrose, S.E., Lookstein, R.A., et al. (2006) An 8-year experience with type II endoleaks: natural history suggests selective intervention is a safe approach. *J Vasc Surg* 44, 453-459.
- Spanos, K., Karathanos, C., Athanasoulas, A., Sapelstis, V., Giannoukas, A.D. (2016) Systematic review of follow up compliance after endovascular abdominal aortic aneurysm repair. *J Cardiovasc Surg (Torino)*.

- Stather, P.W., Sidloff, D., Dattani, N., Choke, E., Bown, M.J., Sayers, R.D. (2013) Systematic review and meta-analysis of the early and late outcomes of open and endovascular repair of abdominal aortic aneurysm. *Br J Surg* 100, 863-872.
- Sternbergh, W.C., 3rd, Greenberg, R.K., Chuter, T.A., Tonnessen, B.H. (2008) Redefining postoperative surveillance after endovascular aneurysm repair: recommendations based on 5-year follow-up in the US Zenith multicenter trial. *J Vasc Surg* 48, 278-284; discussion 284-275.
- Sternbergh, W.C., 3rd, Money, S.R., Greenberg, R.K., Chuter, T.A. (2004) Influence of endograft oversizing on device migration, endoleak, aneurysm shrinkage, and aortic neck dilation: results from the Zenith Multicenter Trial. *J Vasc Surg* 39, 20-26.
- Sterpetti, A.V., Schultz, R.D., Feldhaus, R.J., Cheng, S.E., Peetz, D.J., Jr. (1987) Factors influencing enlargement rate of small abdominal aortic aneurysms. *J Surg Res* 43, 211-219.
- Svensjo, S., Bjorck, M., Gurtelschmid, M., Djavani Gidlund, K., Hellberg, A., Wanhainen, A. (2011) Low prevalence of abdominal aortic aneurysm among 65-year-old Swedish men indicates a change in the epidemiology of the disease. *Circulation* 124, 1118-1123.
- Svensjo, S., Bjorck, M., Wanhainen, A. (2013) Current prevalence of abdominal aortic aneurysm in 70-year-old women. *Br J Surg* 100, 367-372.
- Sweeting, M.J., Balm, R., Desgranges, P., Ulug, P., Powell, J.T. (2015) Individual-patient meta-analysis of three randomized trials comparing endovascular versus open repair for ruptured abdominal aortic aneurysm. *Br J Surg* 102, 1229-1239.
- Ten Bosch, J.A., Willigendael, E.M., Kruidenier, L.M., de Loos, E.R., Prins, M.H., Teijink, J.A. (2012) Early and mid-term results of a prospective observational study comparing emergency endovascular aneurysm repair with open surgery in both ruptured and unruptured acute abdominal aortic aneurysms. *Vascular* 20, 72-80.
- Thompson, A.R., Cooper, J.A., Ashton, H.A., Hafez, H. (2010) Growth rates of small abdominal aortic aneurysms correlate with clinical events. *Br J Surg* 97, 37-44.
- Tonnessen, B.H., Sternbergh, W.C., 3rd, Money, S.R. (2004) Late problems at the proximal aortic neck: migration and dilation. *Semin Vasc Surg* 17, 288-293.
- Tonnessen, B.H., Sternbergh, W.C., 3rd, Money, S.R. (2005) Mid- and long-term device migration after endovascular abdominal aortic aneurysm repair: a comparison of AneuRx and Zenith endografts. *J Vasc Surg* 42, 392-400; discussion 400-391.
- Tornwall, M.E., Virtamo, J., Haukka, J.K., Albanes, D., Huttunen, J.K. (2001) Lifestyle factors and risk for abdominal aortic aneurysm in a cohort of Finnish male smokers. *Epidemiology* 12, 94-100.
- Van Hee, R. (1993) [Andreas Vesalius and surgery]. *Verh K Acad Geneeskdg Belg* 55, 515-532.
- van Marrewijk, C.J., Fransen, G., Laheij, R.J., Harris, P.L., Buth, J. (2004) Is a type II endoleak after EVAR a harbinger of risk? Causes and outcome of open conversion and aneurysm rupture during follow-up. *Eur J Vasc Endovasc Surg* 27, 128-137.

- van Prehn, J., Schlosser, F.J., Muhs, B.E., Verhagen, H.J., Moll, F.L., van Herwaarden, J.A. (2009) Oversizing of aortic stent grafts for abdominal aneurysm repair: a systematic review of the benefits and risks. *Eur J Vasc Endovasc Surg* 38, 42-53.
- van Sambeek, M.R., Hendriks, J.M., Tseng, L., van Dijk, L.C., van Urk, H. (2004) Sac enlargement without endoleak: when and how to convert and technical considerations. *Semin Vasc Surg* 17, 284-287.
- van Zeggeren, L., Bastos Goncalves, F., van Herwaarden, J.A., Zandvoort, H.J., Werson, D.A., Vos, J.A., et al. (2013) Incidence and treatment results of Endurant endograft occlusion. *J Vasc Surg* 57, 1246-1254; discussion 1254.
- Veith, F.J., Baum, R.A., Ohki, T., Amor, M., Adiseshiah, M., Blankensteijn, J.D., et al. (2002) Nature and significance of endoleaks and endotension: summary of opinions expressed at an international conference. *J Vasc Surg* 35, 1029-1035.
- Veith, F.J., Marin, M.L., Cynamon, J., Schonholz, C., Parodi, J. (2005) 1992: Parodi, Montefiore, and the first abdominal aortic aneurysm stent graft in the United States. *Ann Vasc Surg* 19, 749-751.
- Verzini, F., Isernia, G., De Rango, P., Simonte, G., Parlani, G., Loschi, D., et al. (2014) Abdominal aortic endografting beyond the trials: a 15-year single-center experience comparing newer to older generation stent-grafts. *J Endovasc Ther* 21, 439-447.
- Volodos, N.L. (2015) The 30th Anniversary of the First Clinical Application of Endovascular Stent-grafting. *Eur J Vasc Endovasc Surg* 49, 495-497.
- Volodos, N.L., Karpovich, I.P., Troyan, V.I., Kalashnikova Yu, V., Shekhanin, V.E., Ternyuk, N.E., et al. (1991) Clinical experience of the use of self-fixing synthetic prostheses for remote endoprosthetics of the thoracic and the abdominal aorta and iliac arteries through the femoral artery and as intraoperative endoprosthesis for aorta reconstruction. *Vasa Suppl* 33, 93-95.
- Volodos, N.L., Shekhanin, V.E., Karpovich, I.P., Troian, V.I., Gur'ev Iu, A. (1986) [A self-fixing synthetic blood vessel endoprosthesis]. *Vestn Khir Im I I Grek* 137, 123-125.
- Voorhees, A.B., Jr., Jaretzki, A., 3rd, Blakemore, A.H. (1952) The use of tubes constructed from vinyon "N" cloth in bridging arterial defects. *Ann Surg* 135, 332-336.
- Waasdorp, E.J., de Vries, J.P., Hobo, R., Leurs, L.J., Buth, J., Moll, F.L. (2005) Aneurysm diameter and proximal aortic neck diameter influence clinical outcome of endovascular abdominal aortic repair: a 4-year EUROSTAR experience. *Ann Vasc Surg* 19, 755-761.
- Wald, R., Waikar, S.S., Liangos, O., Pereira, B.J., Chertow, G.M., Jaber, B.L. (2006) Acute renal failure after endovascular vs open repair of abdominal aortic aneurysm. *J Vasc Surg* 43, 460-466; discussion 466.
- Walker, J., Tucker, L.Y., Goodney, P., Candell, L., Hua, H., Okuhn, S., et al. (2015) Adherence to endovascular aortic aneurysm repair device instructions for use guidelines has no impact on outcomes. *J Vasc Surg* 61, 1151-1159.

- Wang, G.J., Carpenter, J.P. (2008) The Powerlink system for endovascular abdominal aortic aneurysm repair: six-year results. *J Vasc Surg* 48, 535-545.
- Wanhainen, A., Bjorck, M. (2011) The Swedish experience of screening for abdominal aortic aneurysm. *J Vasc Surg* 53, 1164-1165.
- White, G.H., May, J., Waugh, R.C., Chaufour, X., Yu, W. (1998) Type III and type IV endoleak: toward a complete definition of blood flow in the sac after endoluminal AAA repair. *J Endovasc Surg* 5, 305-309.
- Wu, C.Y., Chen, H., Gallagher, K.A., Eliason, J.L., Rectenwald, J.E., Coleman, D.M. (2015) Predictors of compliance with surveillance after endovascular aneurysm repair and comparative survival outcomes. *J Vasc Surg* 62, 27-35.
- Wyss, T.R., Brown, L.C., Powell, J.T., Greenhalgh, R.M. (EVAR trials, 2010) Rate and predictability of graft rupture after endovascular and open abdominal aortic aneurysm repair: data from the EVAR Trials. *Ann Surg* 252, 805-812.
- Yamada, M., Takahashi, H., Tauchi, Y., Satoh, H., Matsuda, H. (2015) Open Surgical Repair Can Be One Option for the Treatment of Persistent Type II Endoleak after EVAR. *Ann Vasc Dis* 8, 210-214.
- Yusuf, S.W., Whitaker, S.C., Chuter, T.A., Wenham, P.W., Hopkinson, B.R. (1994) Emergency endovascular repair of leaking aortic aneurysm. *Lancet* 344, 1645.

Acta Universitatis Upsaliensis

*Digital Comprehensive Summaries of Uppsala Dissertations
from the Faculty of Medicine 1402*

Editor: The Dean of the Faculty of Medicine

A doctoral dissertation from the Faculty of Medicine, Uppsala University, is usually a summary of a number of papers. A few copies of the complete dissertation are kept at major Swedish research libraries, while the summary alone is distributed internationally through the series Digital Comprehensive Summaries of Uppsala Dissertations from the Faculty of Medicine. (Prior to January, 2005, the series was published under the title "Comprehensive Summaries of Uppsala Dissertations from the Faculty of Medicine".)

Distribution: publications.uu.se
urn:nbn:se:uu:diva-334369



ACTA
UNIVERSITATIS
UPSALIENSIS
UPPSALA
2018