This article was first published by Lerner H. Palti A in Praktische Implantologie und Implantatprothetik ("pip"), 4 (2009), pg. 46–50.

One-year prospective study of patient cases

Success factors for treatment with mini-implants and their relevance for the practice

by Dr. medic. Stom. Henriette Lerner, Prof. A. Palti, Baden-Baden, Germany

The clinical success of mini-implants depends on various parameters, which are also interrelated. The following study examines whether there is a correlation between the diameter of the placed implants and primary stability. The examination took into account the different bone thicknesses specified in the respective patient case. There was also documentation of the osseointegration and depth of any peri-implant pockets over a period of one year post implant placement. The influence of the implant diameter and type of implant abutment on the success rate was also determined.

Introduction

If a tooth is lost, the bone also undergoes resorption. According to Christensen [1] bone loss is generally 20 to 30%. Already in the first six months it is approximately 15%, after which it is about 1 % per year [2] (Fig. 1 to 3).

This has consequences in particular for the treatment of patients with an edentulous mandible. In 80% of cases long-term edentulous patients (more than 10 years) have an alveolar ridge width of 5 millimetres or less [3]. Compromised oral conditions of this kind often exclude standard implant placement. A tissue-borne denture therefore remains the standard treatment in the edentulous jaw, especially for many older patients. A bar-supported denture with conventional implants is often not feasible for reasons of cost, due to advanced atrophy of the jaw or for other medical reasons. Mini-implants for stabilisation have proved to be an interesting alternative; in many cases dentures can be supported in the maxilla in this way and can even be fabricated using a palate-free design. The following applies as a rule of thumb: mini-implants are the first choice where the alveolar ridge is 3.5 mm wide and with patients who suffer from general medical impairment.

In terms of price these types of restoration lie between a tissue-borne denture and a bar-supported restoration. Due to the advantages mentioned above mini-implants are experiencing something of a boom. Since their introduction over 1,000,000 have been sold in the United States of America alone.

Materials and methods

Patient population and type of implants placed

In this study a total of 187 mini-implants (3M ESPE MDI and MDI Hybrid, 3M ESPE, Seefeld, Germany) were placed in 42 patients. The patients were between 20 and 92 years of age, with 8 under 60 years. The average age was 68 years. Sixteen patients were male and 26 female.

One-piece implants with different diameters (3M ESPE MDI: 1.8 to 2.4 mm; MDI Hybrid: 2.9 mm) and different types of abutments (conical, ball, square) were used (Tab. 1 and Tab. 2). The ball abutment version was the most frequently used as standard for the stabilisation of a denture.

Patients were followed up over a minimum period of 12 months with a three-month gap between each appointment, i.e. 3, 6, 9, 12 months after implant placement. During the follow-up appointment a check X-ray was taken, the occlusion checked and the degree of osseointegration determined. The periotest used was applied analogous to the procedure with standard implants (whereby the results are interpreted slightly differently due to the different scale). The pocket depth on all four sides was measured using a periodontal probe. Conventional curettage was performed as a prophylactic measure and the mini-implants were also thoroughly cleaned using a specially designed brush for the purpose (Access, 3M ESPE, Seefeld). This brush was also recommended to the patient for oral care at home.

Espertise™

Fig. 1: Mini-implants in different diameters and alternatively in a ball ("O-ball") or square ("square head") design.

Fig. 2: 2.1 mm mini dental implant from 3M ESPE, with ball abutment for easy placement, even in very dense bone. Top in the photograph: metal sleeve and retention insert. Possible indication: Stabilisation of upper/lower dentures and cemented single restorations. Small photograph: An innovative microthread supports the healing and stability of the soft tissue as well as the cortical bone during the healing process.

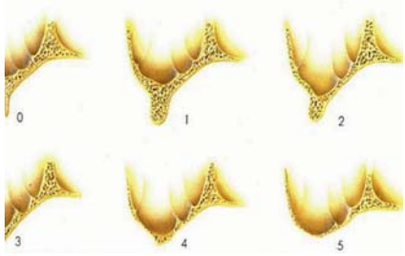

Fig. 3: Classification of the atrophied jaw according to Cawood and Howell [see: Cawood JI and Howell RA: A classification of the edentulous jaws, International Journal of Oral and Maxillofacial Surgery 17(4): 232-236 (1988)].

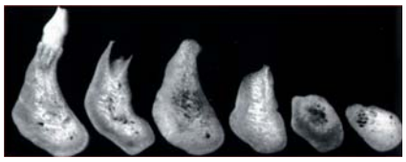

Fig. 4: Resorption Classes (RCL) of the mandible (from left to right): RCL 1 = dentate mandible, no resorption; RCL 2 = alveolus after extraction; RCL 3 = high alveolar ridge (healed alveolar process); RCL 4 = high and narrow alveolar ridge; RCL 5 = rounded and flat alveolar ridge (vertically resorbed); RCL 6 = concave and severely atrophied alveolar ridge [cf.: Atwood, DA: Reduction of residual ridges: A major oral disease entity. J Prosthe Dent 26, 266-279 (1971)].

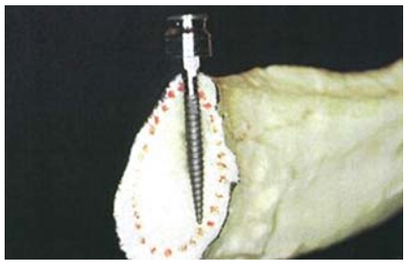

Fig. 5: The bone height is used to maximum effect during insertion of the implant in the direction of the opposite cortex.

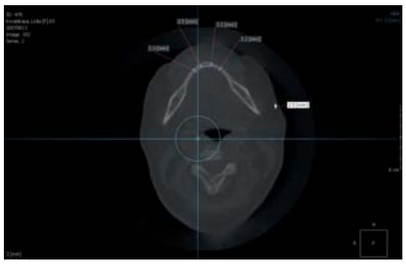

Fig. 6: The width of the alveolar ridge is measured with the aid of computed tomography (Iluma, 3M ESPE, Seefeld, Germany).

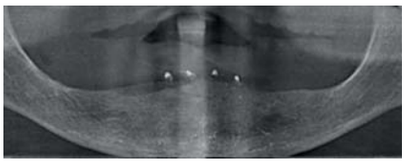

Fig. 7: Planning of further implantological procedures is completed using radiopaque reference points.

Fig. 8: Clinical situation immediately after transgingival placement of four mini-implants in the mandible.

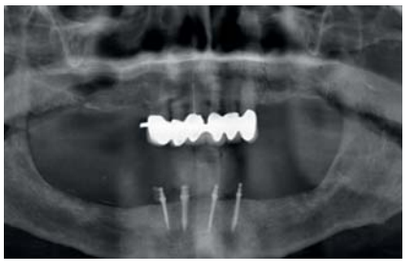

Fig. 9: The orthopantomogram shows the situation immediately after placement of the mini-implants with a diameter of 1.8 mm and a length of 13 mm.

Fig. 10: The metal housings are positioned at the correct level on the implants by covering the cervical sections using approx. 2 mm high spacers.

Fig. 11: The denture is specifically hollowed out for integration of the housings.

Fig. 12: The bite is checked before and after final polymerisation of the housings, ensuring that the contact points match.

Fig. 13: The integrated housings after direct polymerisation.

Fig. 14: Design of the mini-implant with 2.9 mm diameter (MDI Hybrid, 3M ESPE – Implantology, Seefeld, Germany): it can also be used for single restorations.

3M ESPE

Fig. 15: Initial situation in the mandible: Teeth 32 to 42 exhibit degree 2 mobility and are non-retainable.

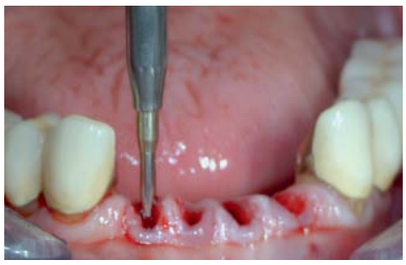

Fig. 16: The pilot drill hole is in the alveolus in the region of tooth 32 at the beginning of the minimally invasive surgical procedure.

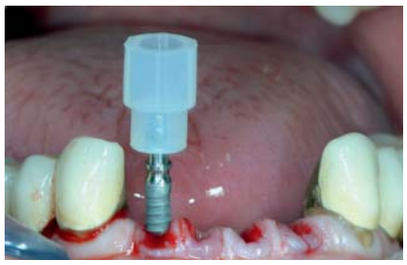

Fig. 17: The mini-implant is gripped by its plastic handle, removed from the sterile packaging and placed in the extraction alveolus with several turns.

Fig. 18: The final stage of placement is completed using a torque ratchet. In the case shown here a good primary stability of approx. 50 Ncm was achieved (minimum stability for immediate loading: 35 Ncm).

Fig. 19: After placement, the mini-implants in the region 42, 32 were fitted with Snap-on caps.

Fig. 20: A vacuum formed foil was fabricated over a mock-up for the temporary restoration.

Fig. 21: Fabrication of the temporary restoration.

Fig. 22 – 24: The finished temporary bridge on Snap-on caps for the uncemented temporary restoration.

Fig. 24

Fig. 25: The temporary restoration in situ in nonocclusion.

Placement protocol

The mini-implants used in this study have a much smaller diameter (1.8 – 2.9 mm) than standard implants and incorporate a one-piece, conical-cylindrical compression screw with self-tapping thread. (Fig. 2) Due to this special design the 3M ESPE MDI implants can be easily placed transgingivally into the bone following perforation of the cortical bone using a 1.1 mm pilot cutter and drilling the bone to one third the length of the implant thread. The procedure is slightly different for the larger MDI Hybrid mini-implant with a 2.9 mm diameter: a 1.8 mm pilot cutter is used; in the case of a bone quality of D3 a pilot hole one third the length of the implant thread is drilled, however, with D1 or D2 bone a pilot hole of two-thirds the length of the implant thread is drilled.

3M ESPE

Generally, the patient's existing dentures can continue to be used. Metal housings with a semi-elastic rubber ring are inserted into the existing dentures. They are then supported on the mini-implants wound into the jaw with a certain degree of flexibility, so that the masticatory forces applied are optimally transmitted ("soft loading"). This avoids overloading the implants and bone site immediately after placement and cushions the loading in the long term, i.e. over the entire time in situ. The bony site is simultaneously protected against further resorption.

The implant can be loaded immediately with a full denture provided primary stability in excess of 35 Newton centimetres (Ncm) is achieved after placement. Otherwise the denture should be relined using a soft reline material.

The author followed this protocol exactly during treatment within the framework of this study. The following should be noted (Tab. 3): a vertical relief incision was made in 80 cases (about 43 %) and in 85 cases (about 45 %) augmentation using a collagen membrane of equine origin was carried out (Tissue Fleece, Baxter, Heidelberg, Germany). This involved patients with severely atrophied bone and low availability of keratinised gingiva. The membrane also had a haemostatic effect. This achieved a better quality of peri-implant tissue which, according to bibliographical references, is attributed to stimulation of the production of growth hormones (4). The implants were immediately loaded in 24 cases (about 13%) and dentures were relined with a soft relining material in 163 cases (about 87%).

A new denture was also fabricated in 90% of cases in this study. This was based on aesthetic reasons and/or a crown height ("crown height space", i.e. the distance between the bone level and incisal and occlusal level) of less than 15 mm. It is not unusual that old, heavily abraded full dentures fall well below this value intended by nature. Aesthetic rehabilitation can only be achieved by remaking the denture in this case. Occasionally full dentures also do not have sufficient space for the metal housing after a longer time in situ. This is another possible reason for the fabrication of a new denture.

In addition to the standard indication and after thorough consideration of the risk-benefit ratio as well as comprehensive patient consultation, mini-implants are also placed for subsequent treatment with single crowns or bridges in individual cases.

Results

Primary stability with different implant diameters

Implants that had been placed in the same thickness of bone and in the same site were each compared to determine whether the implant diameter had an effect on the primary stability. Smaller and next higher implant diameters were compared respectively, e.g. 1.8 mm versus 2.1 mm and 2.1 mm versus 2.4 mm.

The primary stability was determined using a torque ratchet. Significant differences were established for the pairs "1.8 vs. 2.1" and "2.4 vs. 2.9". The 2.1 mm mini-implants exhibited an average higher primary stability of approximately 10 Newton centimetres (Ncm) than the 1.8 mm mini-implants, while the respective value for the "2.4 vs. 2.9" comparison was 15 Ncm.

Clinical success parameters

No bone loss was detected over the entire study period. The mini-implants healed in the jaw over the entire observation period, whereby osseointegration greatly improved between the 6th and 12th month. During the entire period no regeneration or deepening of periodontal pockets took place, particularly in the peri-implant region of the newly placed mini-implants.

Success rates

The overall success rates were in a comparable range to those of the high success rates produced by the standard implants (Tab. 4). The rates were well over 90 percent for the "larger" diameters (2.1 to 2.9 mm); only the rates for the 1.8 mm diameter mini-implants were below 90%.

This produced the following correlation: high primary stability also resulted in high success rates. Classification according to "fixed" or "removable" as well as implant diameter produced virtually no evidence of any differences (Table 5). The fixed restorations had slightly higher success rates with the standard 3M ESPE MDI implants (1.8 to 2.4 mm).

Number of mini-implants placed according to abutmen

Diameter [mm]	Abutment	Number	Abutment	Totals for the individual types of abutment
1.8	Ball	36		
2.1	Ball	24		
2.4	Ball	68		
2.9	Ball	37	Ball	165
2.9	Conical	15	Conical	15
1.8	Square	3		
2.4	Square	1		
2.9	Square	3	Square	7

Tab. 1

Number of mini-implants placed according to diameter

Diameter [mm]	Total number	Type of abutment	Number
1.8	39	Ball	36
		Square	3
2.1	24	Ball	24
2.4	69	Ball	68
		Square	1
2.9	55	Ball	37
		Square	3
		Conical	15

Tab. 2

Characteristics of procedures performed in the frame of this study

Characteristic	Number of implants (in 187 altogether)	Number of patients
Placement with vertical relief incisions	80	
Placement after augmentation	85	
Immediate load after placement	24	12
Initially soft relining	163	30

Tab. 3

Success rates itemized by implant diameter

Implant diameter	Successes	Number of placements performed with it	Success rate (by percent)
1,8	32	39	82.05 %
2,1	24	24	100.00 %
2,4	67	69	97.10 %
2,9	52	55	94.55 %

Tab. 4

Success rates itemized by fixed resp. removable

Type of restoration	Implant diameter [mm]	Successes	Total number of treatments	Success rate
fixed	1.8 – 2.4	21	22	95.45 %
removable	1.8 – 2.4	154	165	93.33 %
fixed	2.9	17	18	94.44 %
removable	2.9	35	37	94.59 %

Tab. 5

Conclusion

Based on the results of the present study, a similar success rate to standard implants may be expected when using mini-implants for stabilising dentures. As there is a correlation between success and primary stability, success can already be easily assessed after determining the primary stability using the torque ratchet immediately after placement. If the figures obtained are borderline (≈ 35 Ncm), a soft relining should be completed in case of doubt. Depending on the individual case, it should also be checked whether another mini-implant can be placed to improve stabilisation. Given the choice, it is preferable to select a slightly larger diameter, i.e. instead of the 1.8 mm implant place the 2.1 mm implant and place the MDI Hybrid implant with a 2.9 mm diameter instead of the 2.4 mm implant.

It is obviously advisable to arrange recall appointments in close succession, particularly in order to be able to monitor regularly that osseointegration is progressing according to plan. Osseointegration is not fully complete after six months, but there is generally further significant improvement during the following six months.

References

1. Christensen GJ: Ridge Preservation: Why not? J Am Dent Assoc 127 (1996), 669-670
2. Misch C: Contemporary Implant Dentistry. Second edition (1999), 225
3. Meskin LH, Brown LG: Prevalence and patterns of tooth loss in the U. S employed adult and senior population, J Dent Educ 52 (1988), 686-691.
4. Sendic, M: Wachstumsverhalten und gegenseitige Beeinflussung von Gingivakeratinozyten und Osteoblasten auf Kollagen, Inauguraldissertation zur Erlangung des Zahnmedizinischen Doktorgrades der Medizinischen Fakultät der Albert-Ludwigs-Universität Freiburg i. Br., 2005

3M ESPE

3M Deutschland GmbH · Location Seefeld · 3M ESPE · ESPE Platz · 82229 Seefeld · Germany · info3mespe@mmm.com · www.3MESPE.com