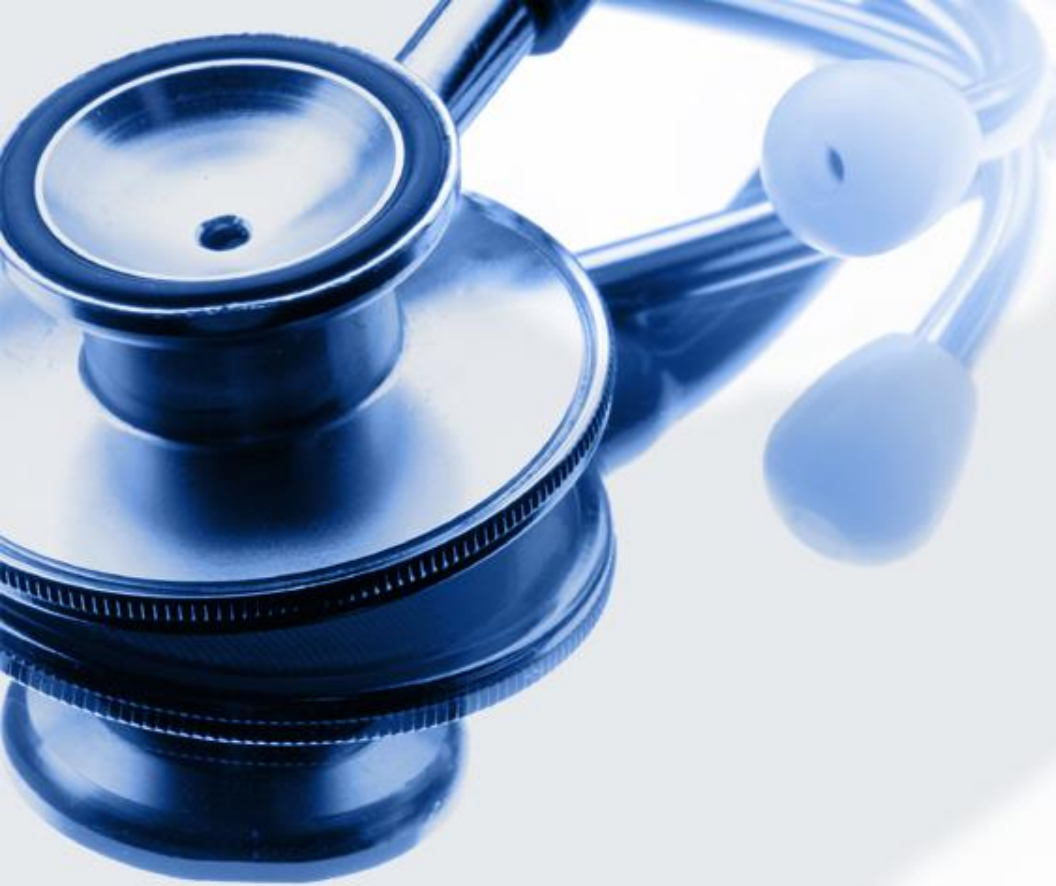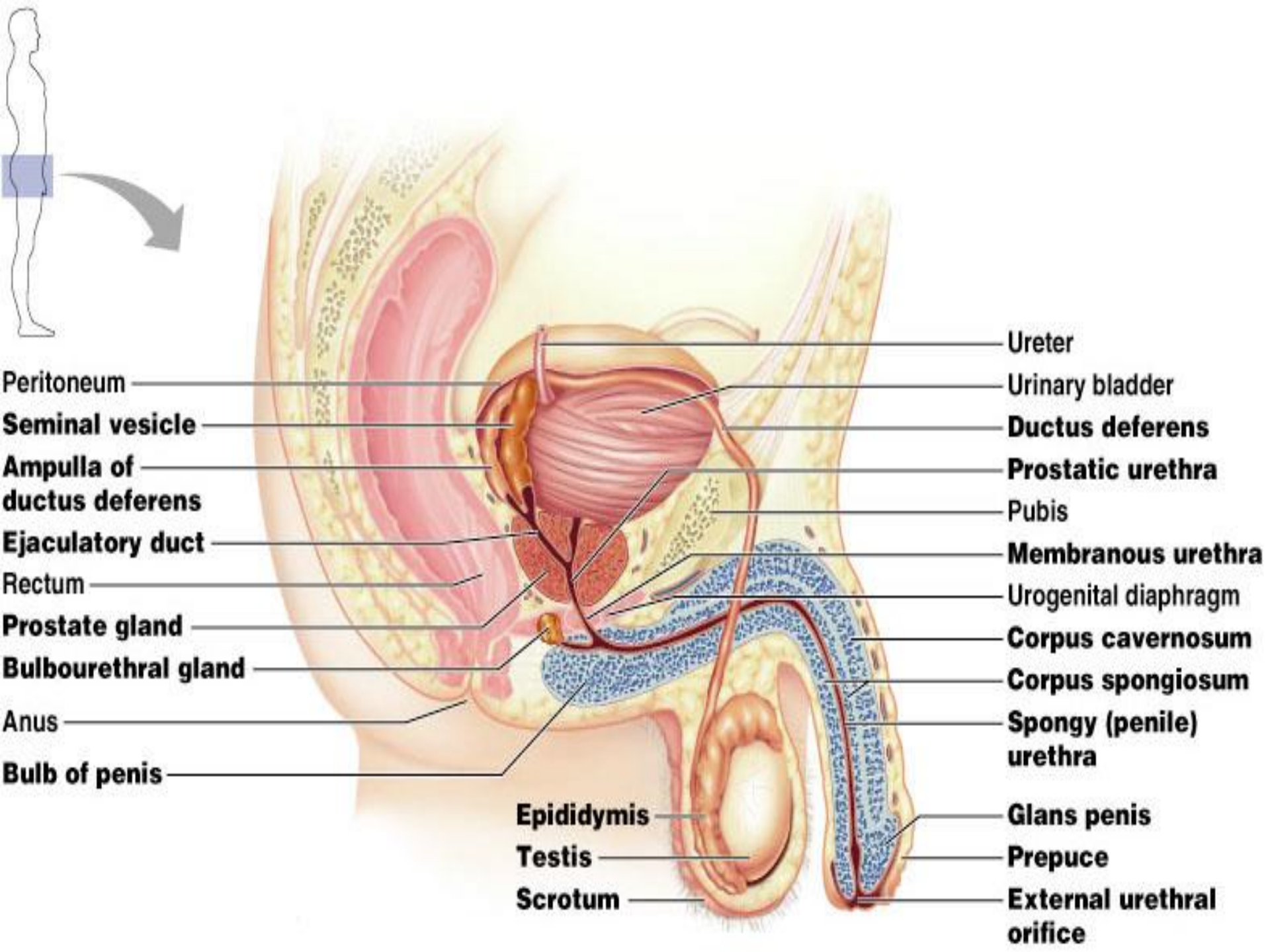
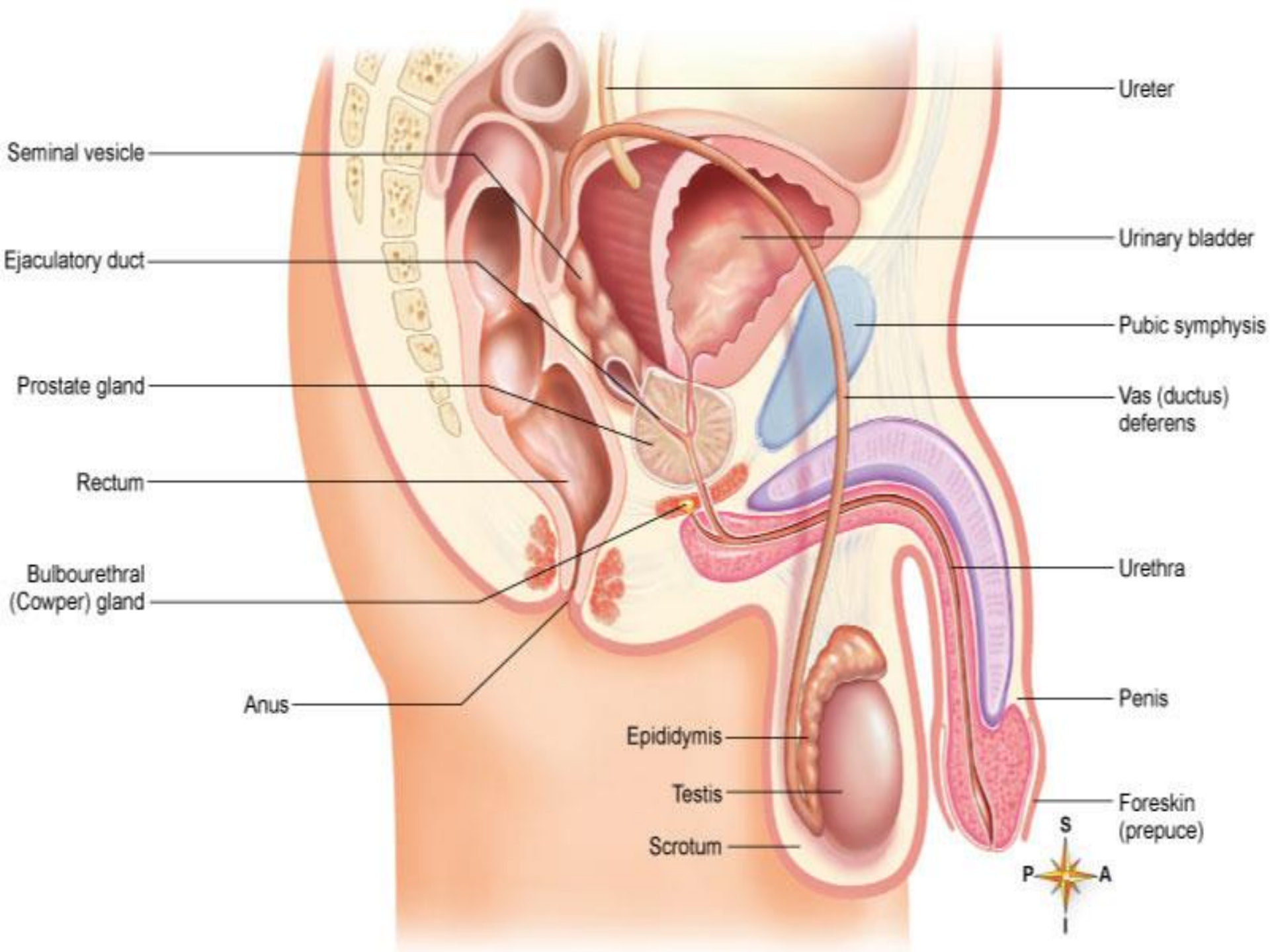




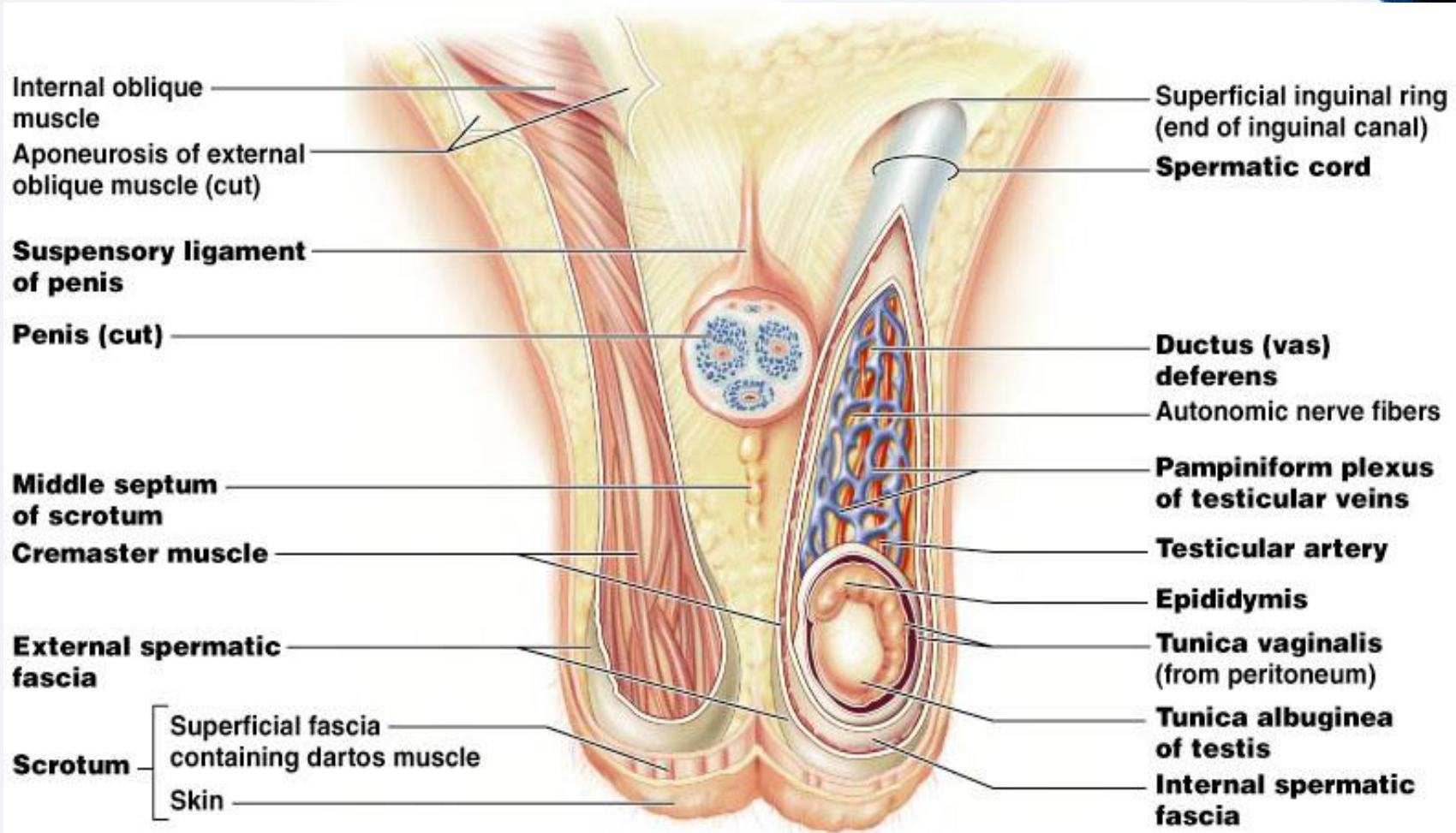
Examination of Male Genitalia & Hernia

Dr. Gary Mumaugh – Western Physical Assessment





The Scrotum



Anatomy Review



- The penis
 - The shaft of the penis is formed by three columns of vascular erectile tissue
 - The corpora spongiosum contains the urethra
 - The two corpora cavernosa
 - The corpora spongiosum forms the bulb of the penis, ending in the glans
 - In uncircumcised men, the glans is covered by a loose, hood-like fold of skin, prepuce or foreskin, where smegma (secretions of glans) may collect

Anatomy Review



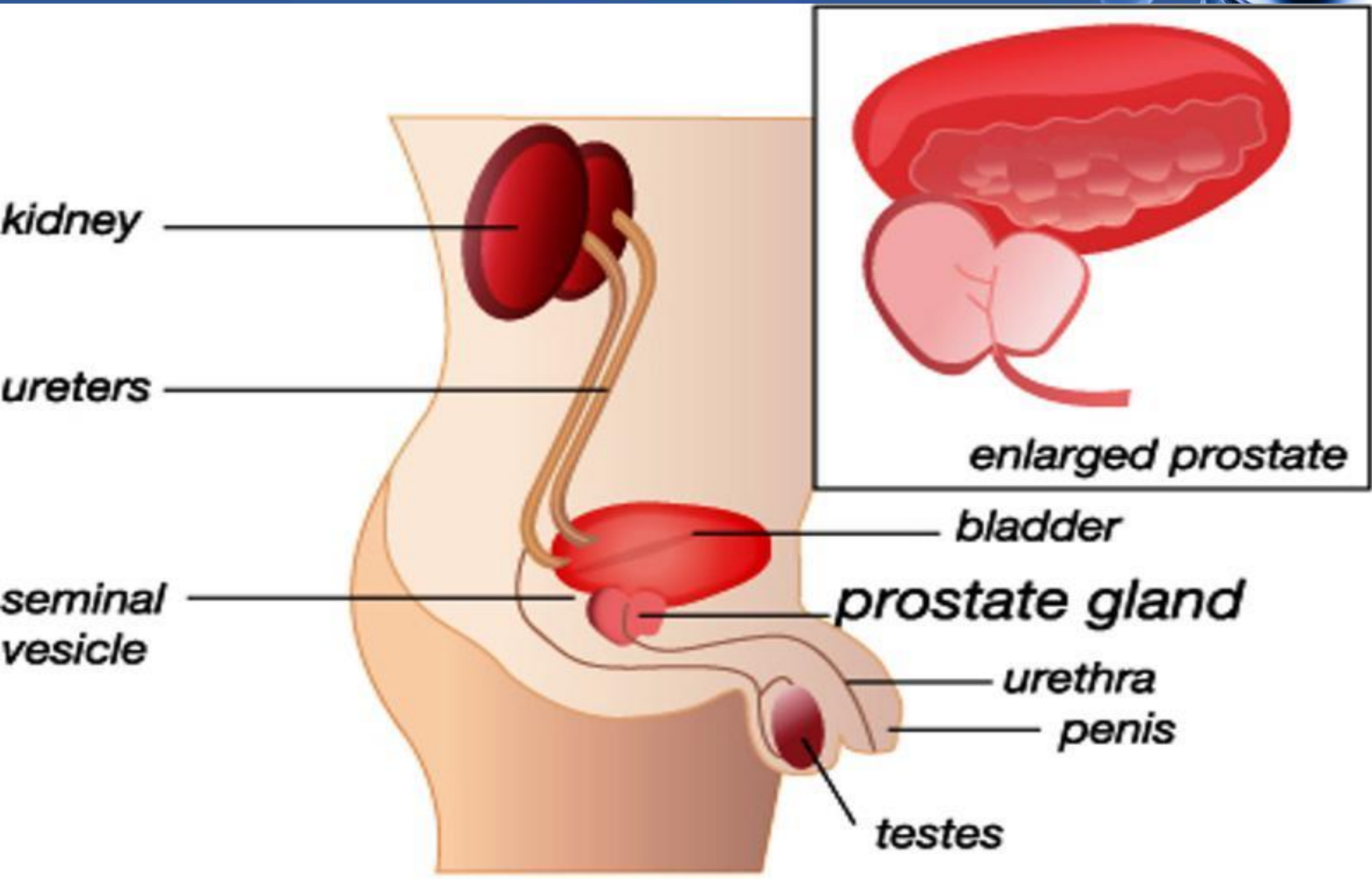
- The testes
 - Produce spermatozoa and testosterone
 - The left testes usually lies somewhat lower than the right
 - The scrotum is a loose, wrinkled pouch divided into two compartments, each containing a testis
 - On the posterolateral surface of each testis is the comma-shaped epididymus, which is a reservoir for storage, maturation and transport of spermatozoa

Anatomy Review



- The lower genitourinary tract
 - The vas deferens, a cord-like structure, begins at the tail of the epididymus
 - It ascends within the scrotal sac (as the spermatic cord) and passes through the inguinal ring on it's way to the abdomen and pelvis
 - Behind the bladder, it is joined by the duct from the seminal vesicle and enters the urethra with the prostate gland

Anatomy Review



Anatomy Review



- The groin
 - The basic landmarks of the groin are the anterior superior iliac spine , the pubic tubercle and the inguinal ligament
 - The inguinal canal, which lies above and parallel to the inguinal ligament, forms a tunnel for the vas deferens
 - The external opening of the tunnel is the external inguinal ring, the internal opening is the internal inguinal ring

Anatomy of the Groin Area

Superficial Muscles

Deep Muscles

Rectus abdominis

External oblique

Inguinal ligament

Tensor fascia latae

Gracilis

Sartorius

Rectus femoris

Iliotibial band

Transversus abdominis

Iliopsoas

Gluteus medius

Pectineus

Adductor longus

Adductor brevis

Adductor magnus

Vastus lateralis

Vastus medialis

Inferuior epigastric artery

Deep inguinal ring

Rectus abdominis muscle

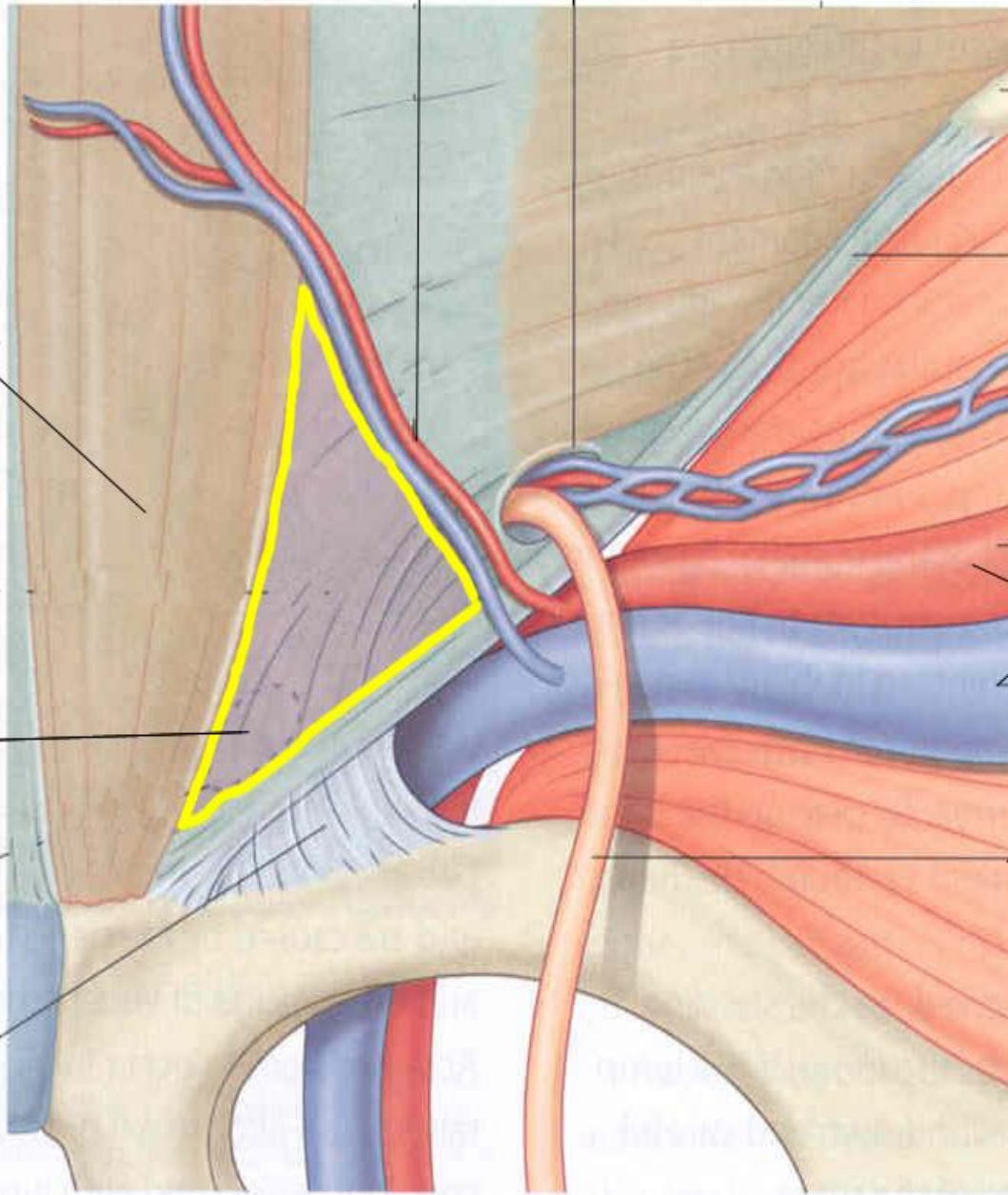
Inguinal ligament

Superfical inguinal ring

External iliac vessels

Ductus deferens

Lacunar ligament



Anterior superior
iliac spine

Site of femoral
canal

Femoral artery

Femoral vein

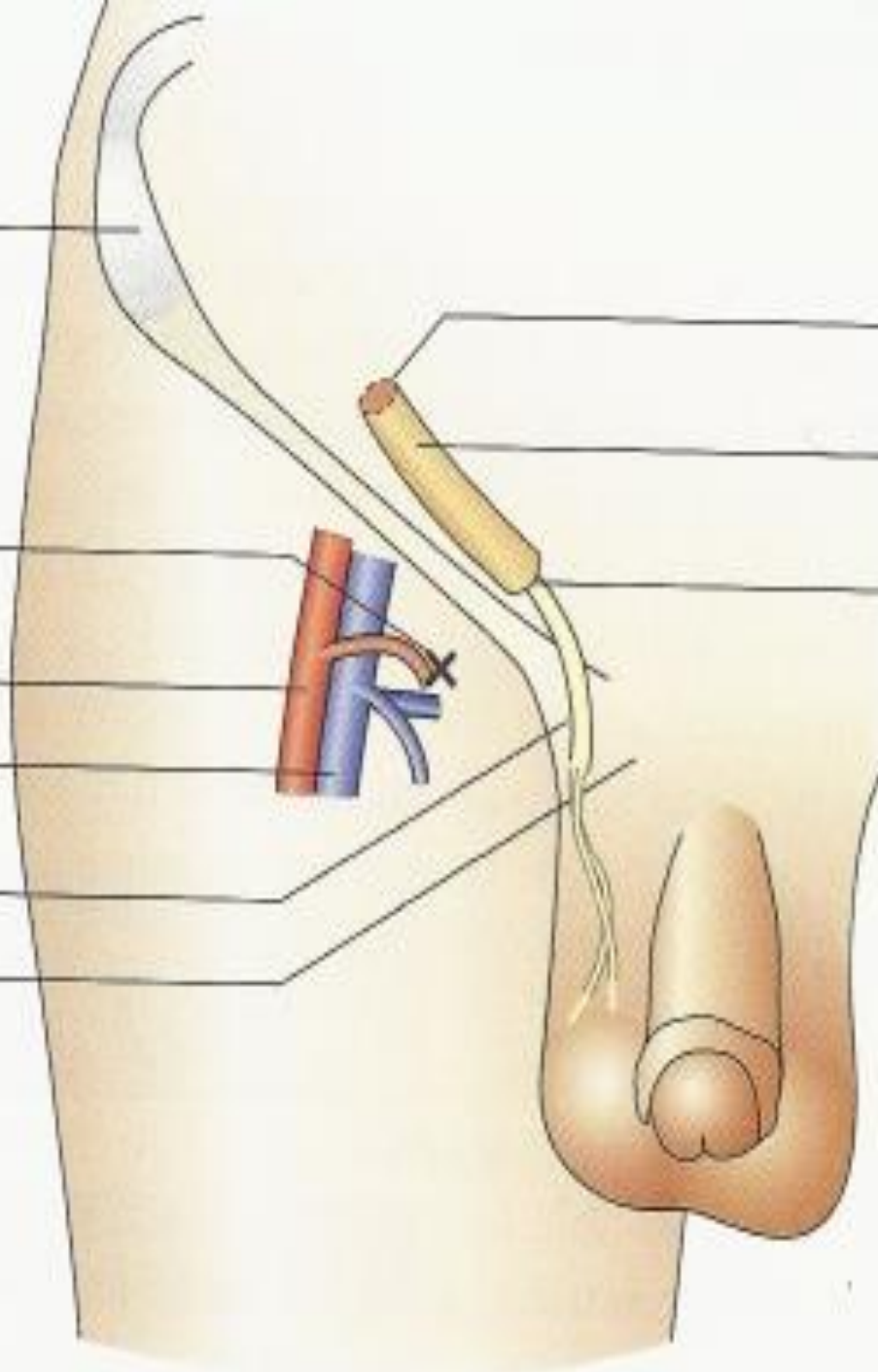
Spermatic cord

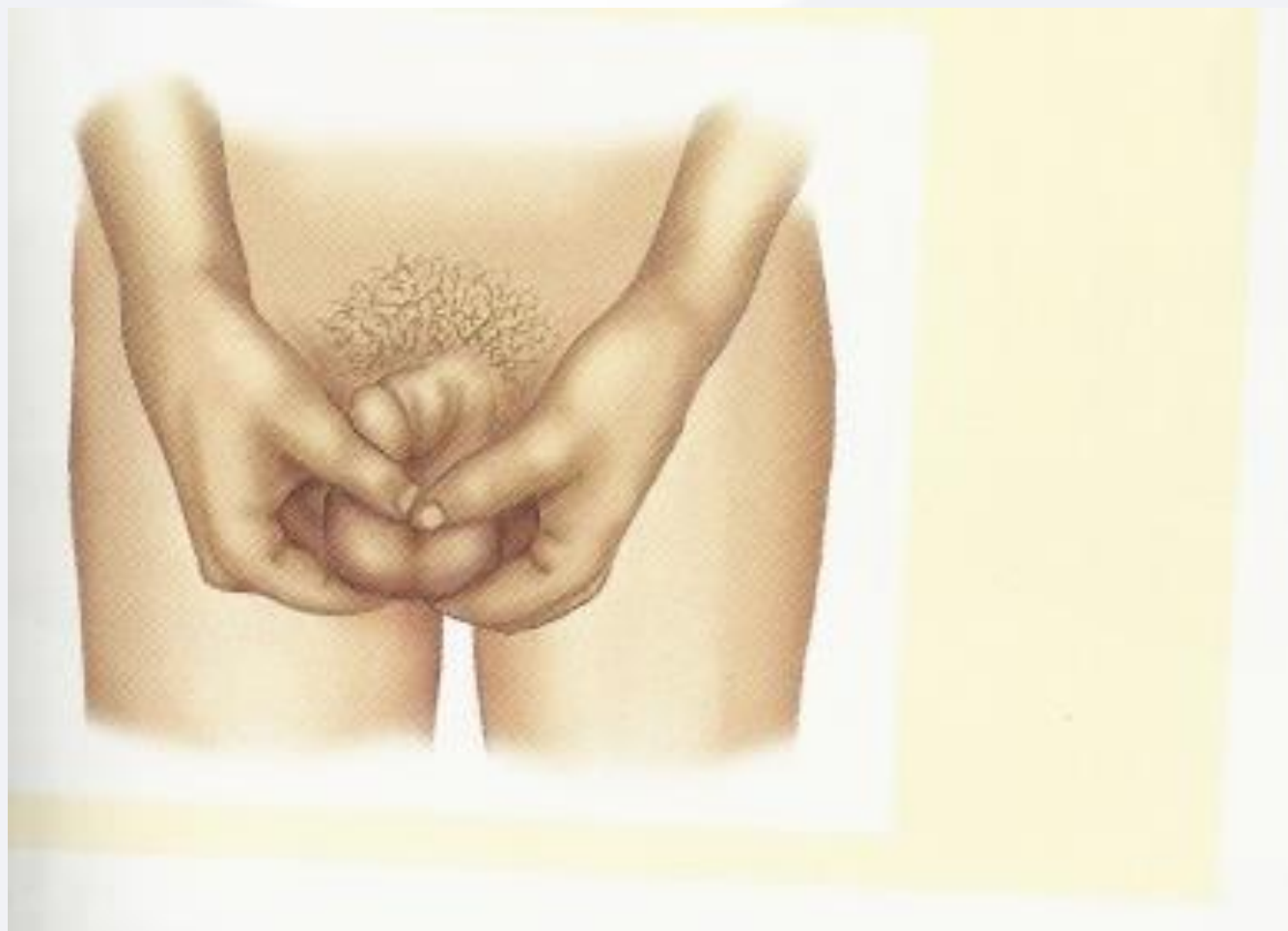Pubic tubercle

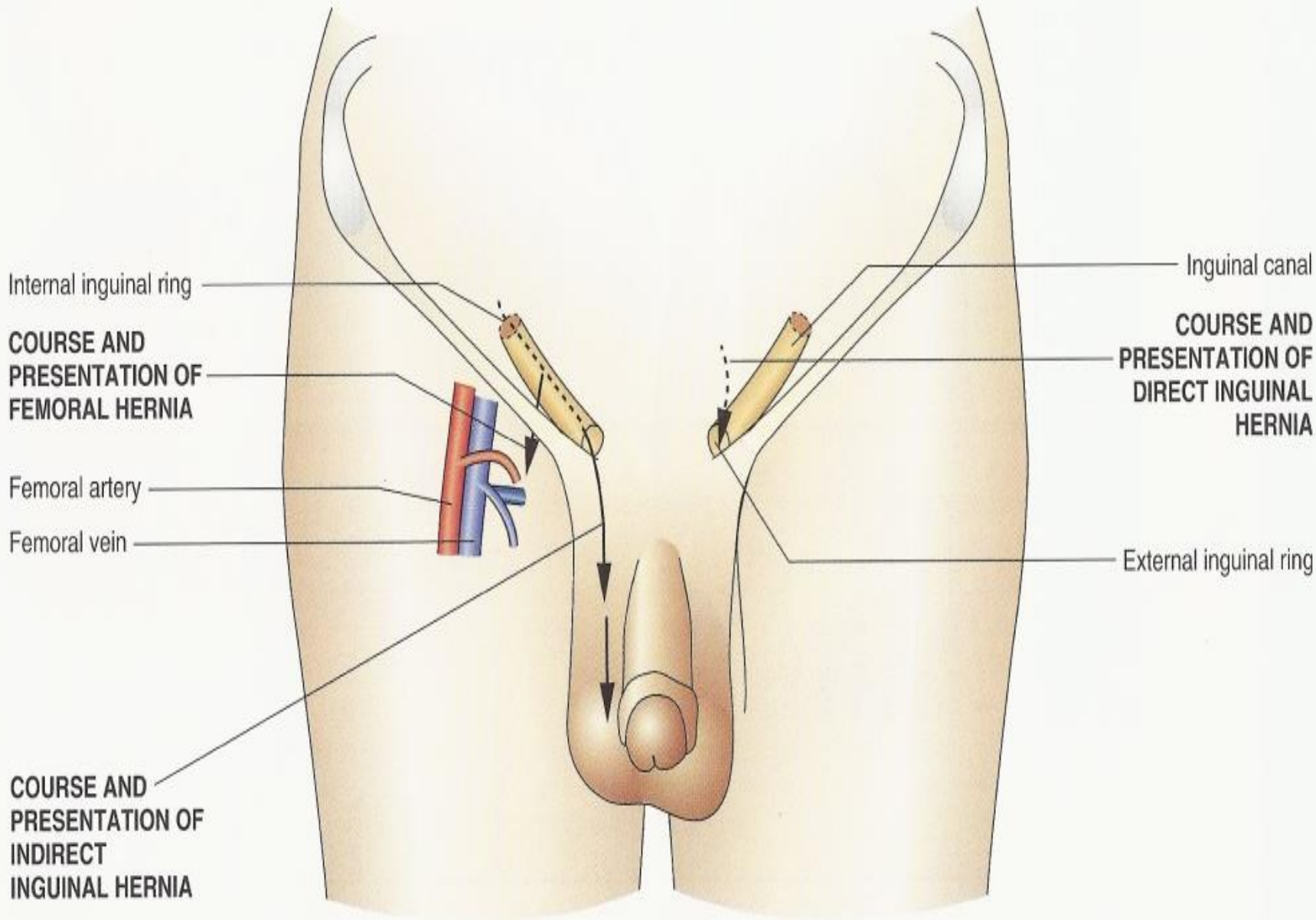
Internal inguinal
ring

Inguinal canal

External inguinal
ring



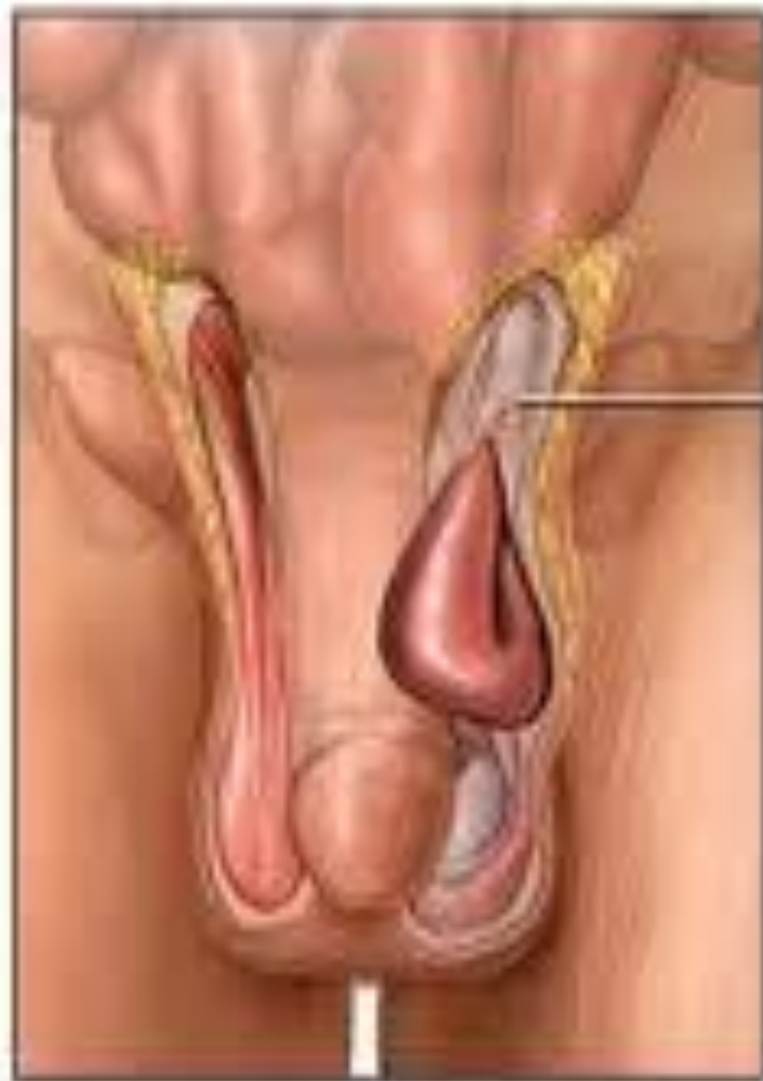



Anatomy Review



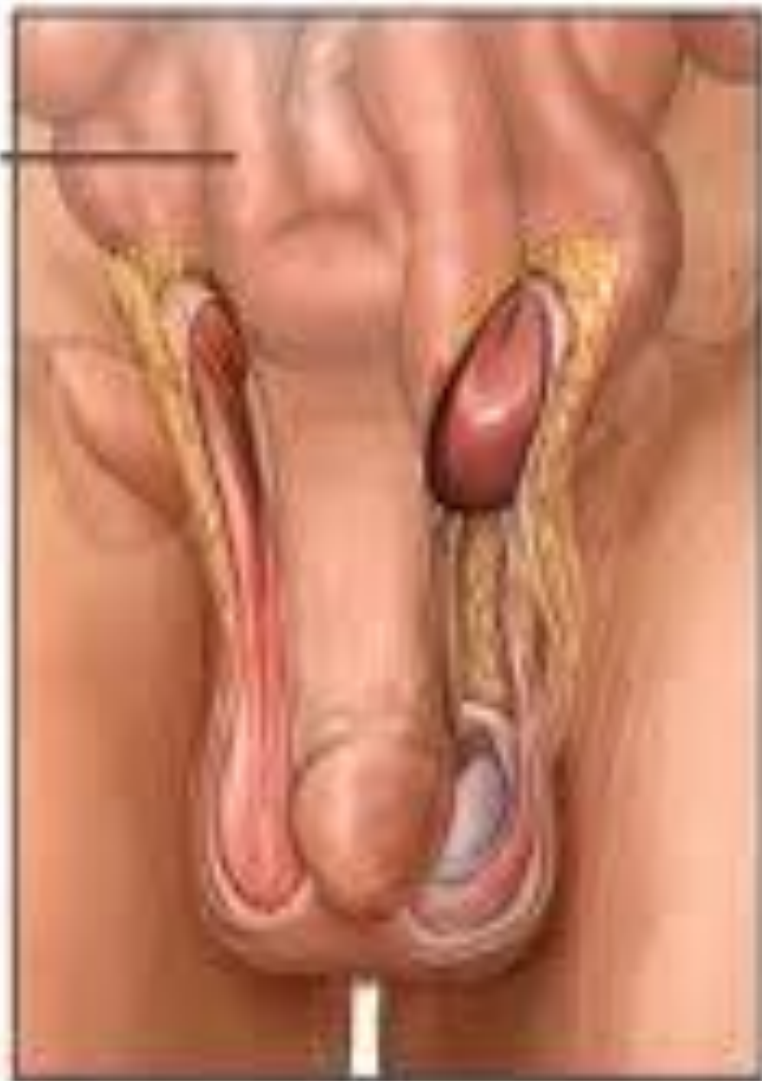- The groin
 - When loops of bowel force their way through the weak areas of the inguinal canal, they produce inguinal hernias
 - Another potential route for a herniating mass is the femoral canal where femoral hernias protrude here.



Indirect inguinal hernia

Small intestine

Inguinal canal



Direct inguinal hernia

Tips for Taking the Sexual History



- Explain why you are taking the sexual history
- This information is highly personal, so encourage the patient to be open and direct
- Assure the patient that you gather a sexual history on all patients
- Affirm that your conversation is confidential

Tips for Taking the Sexual History



- Sexual preference and sexual response questions
 - Start with a general question, such as “How is sexual function for you?”
 - If there is a problem, direct questions help to access each phrase of the sexual response
 - “Have you maintained interest in sex?” (desire)
 - “Can you achieve and maintain an erection?” (arousal)
 - “About how long does intercourse last?” (orgasm and ejaculation)

Symptoms of Infection Questions



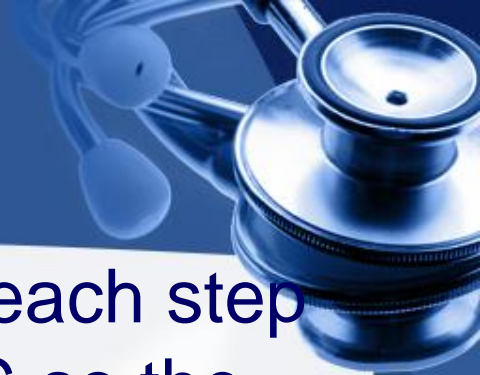- Is there any penis discharge, dripping or staining if underwear? If so, how much and what is the color and consistency?
- Any associated fever, chills or rash?
- Any sores or growths on the penis?
- Any pain or swelling in the scrotum?
- Any history of risk factors for STD?
 - Promiscuity, homosexuality, illicit drug use

Health Promotion and Counseling



- Prevention of STD's and HIV
- Testicular self-examination

Techniques of Examination



- It is reassuring to the patient to explain each step of the examination **BEFORE STARTING** so the patient knows what to expect.
- Occasionally, male patients will have erections during the examination. If this happens, explain this is a normal response.
- Many will feel uneasy about examining genitals.
- A thorough genital examination can be performed with the patient standing or supine.
- When checking for hernias, the patient should stand and the examiner should sit on a chair or stool.

Techniques of Examination



- Skin
 - Check the skin around the base of the penis for excoriations and inflammation.
- Prepuce
 - Smegma, a cheesy, whitish material may accumulate under the foreskin.

Techniques of Examination



- Glans
 - Check for ulcers, scars, nodules, or signs of inflammation
 - Gently compress the glands between your index finger above and thumb below to open the urethral meatus and allow inspection for discharge (normally there is none)

Techniques of Examination



- Penis palpation
 - If the patient reports a discharge that you are unable to see, ask him to milk the shaft of the penis from the base to the glands.
 - This maneuver may bring the discharge to the urethral meatus for examination.
 - Palpate any abnormality of the penis, noting any induration
 - Palpate any abnormality
 - Not any tenderness or indurations

Techniques of Examination



- Examination of Scrotum, Testis, Epididymis and Spermatic Cord
 - Inspection
 - Skin – lift the scrotum to view the posterior surface
 - Scrotal contours – note swelling, lumps, veins

Techniques of Examination



- Examination of Scrotum, Testis, Epididymis and Spermatic Cord
 - Palpation
 - Each testis and epididymis – note size, shape, consistency and tenderness
 - Feel for nodules
 - Epididymis palpates as a soft, nodular, cordlike structure in the back of the testis
 - Each spermatic cord – note nodules or swelling

Techniques of Examination

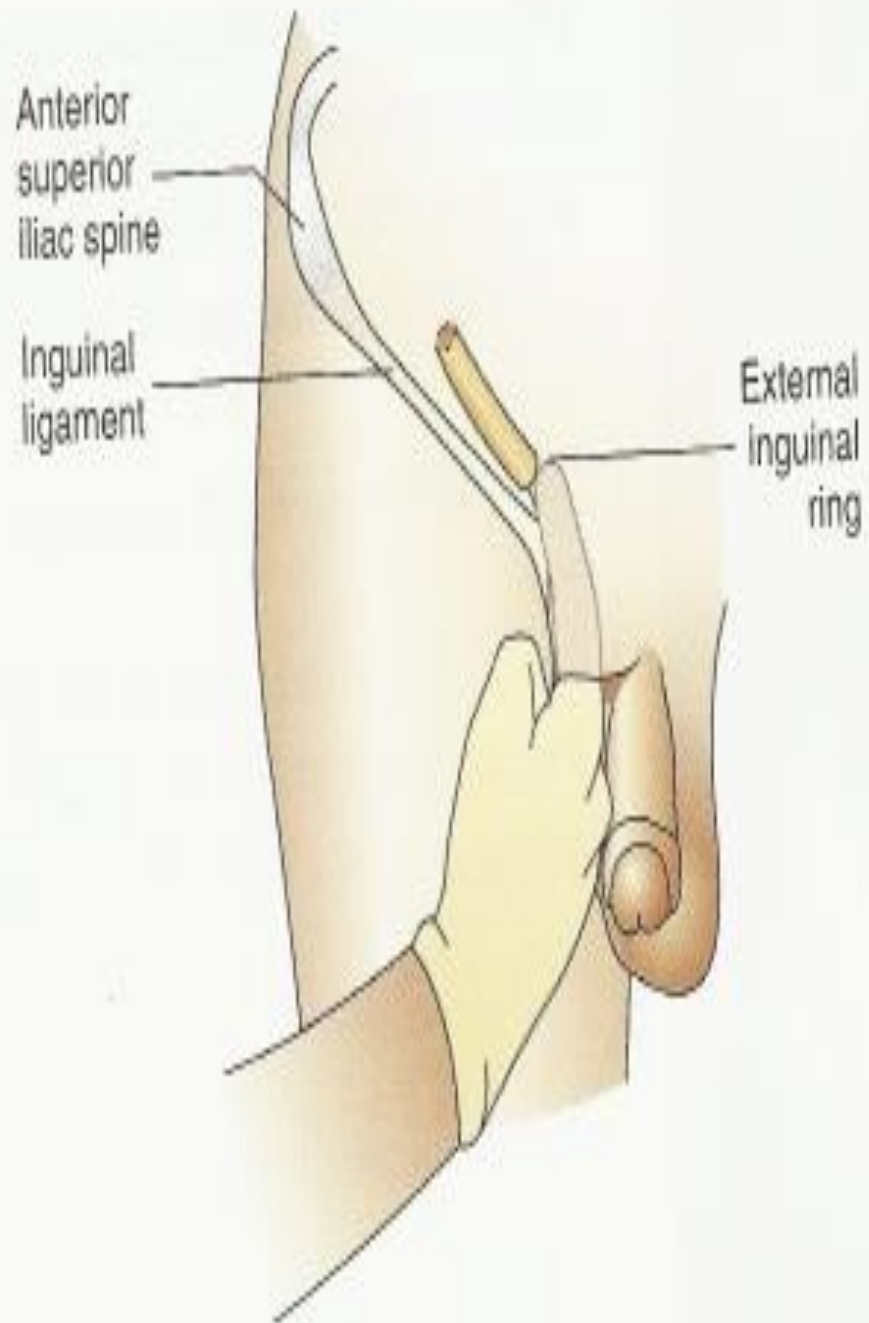
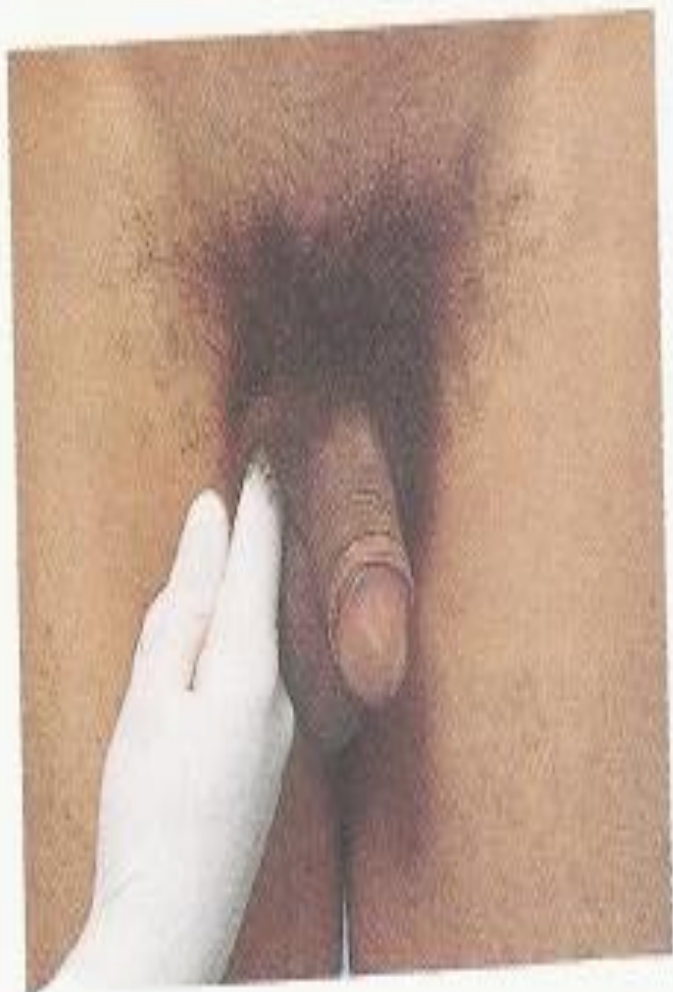

- Hernias
 - Inspection
 - Sit comfortably in front of standing patient
 - Note any areas of bulging or symmetry
 - Ask the patient to strain or bear down, making it easier to detect any hernias
 - Palpation
 - Inguinal and femoral hernias

Techniques of Examination



- Evaluating a possible scrotal hernia
 - If a large scrotal mass is found, ask the patient to lie down. If the mass disappears, it is a hernia.
 - If the mass remains
 - Listen to the mass with a stethoscope. If bowel sounds are heard, it is a hernia.
 - Shine a strong light from behind the scrotum through the mass (transillumination). If a red glow is observed, it is probably not a hernia.

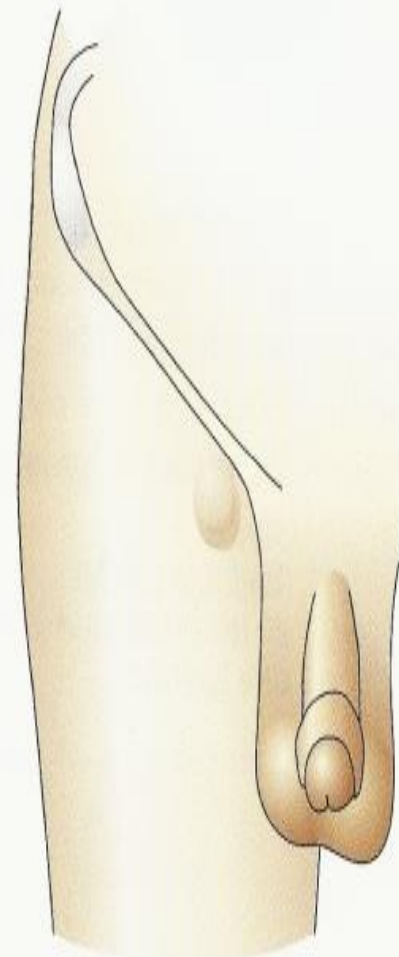
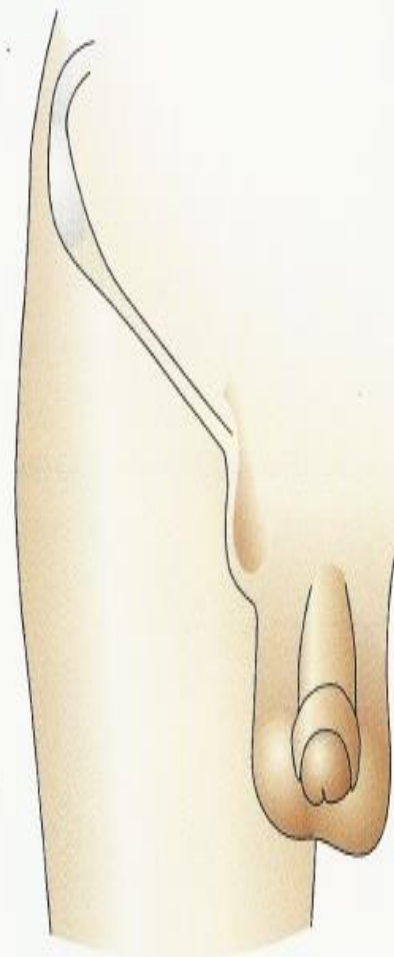
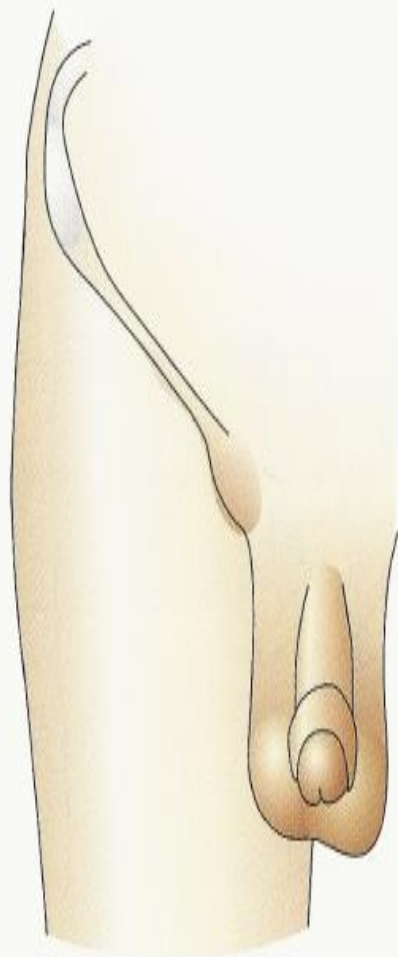


Inguinal

Indirect

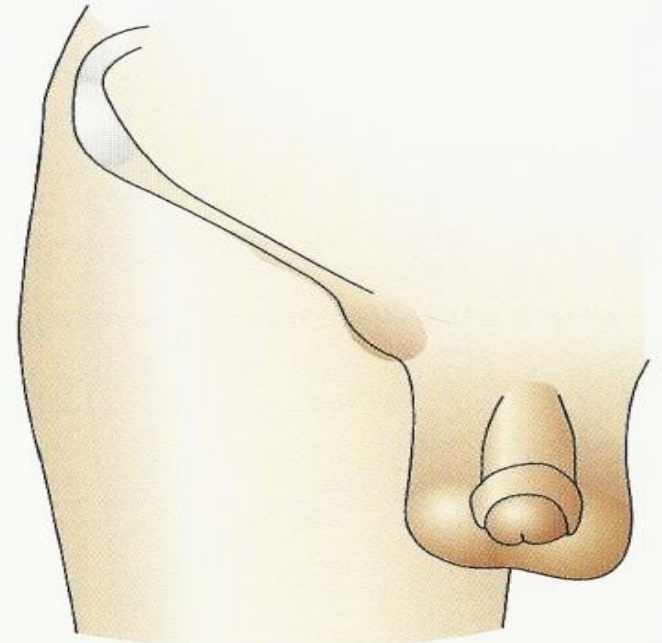
Direct

Femoral



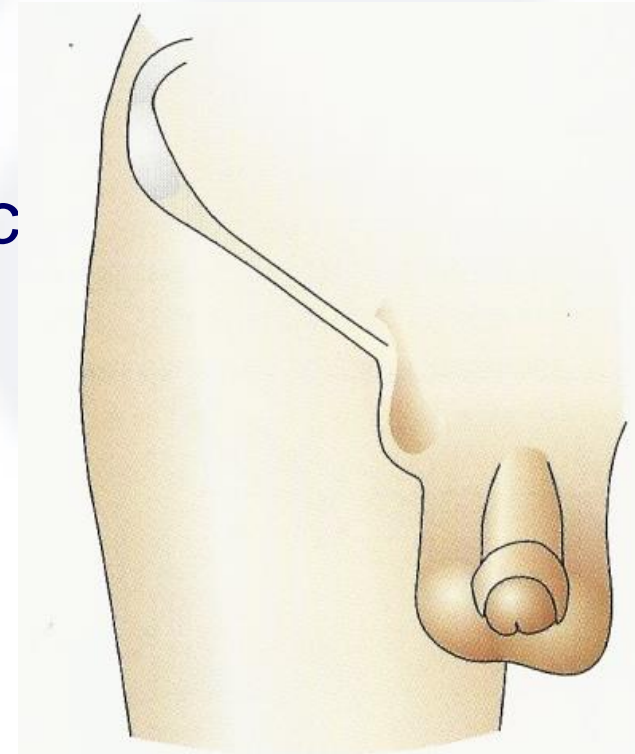
Groin Hernias

- Indirect Inguinal
 - Frequency - Common all ages, both male and female
 - Age & Sex - Seen more in children, but may be in adults
 - Point of Origin – Found above inguinal ligament near the midpoint by internal inguinal ring



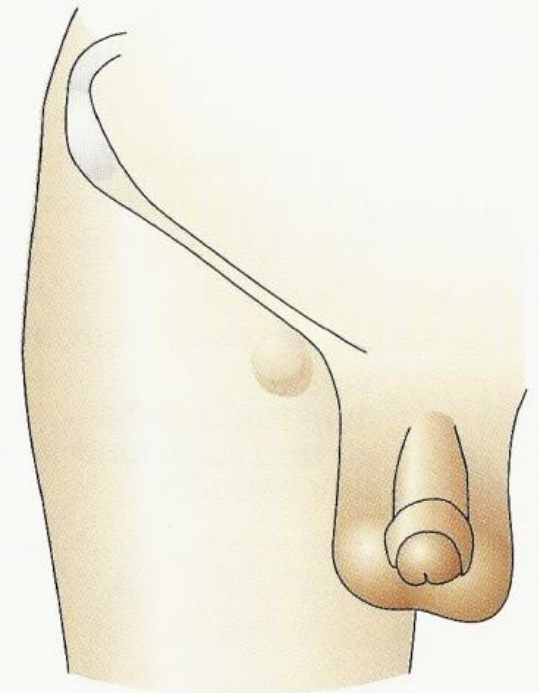
Groin Hernias

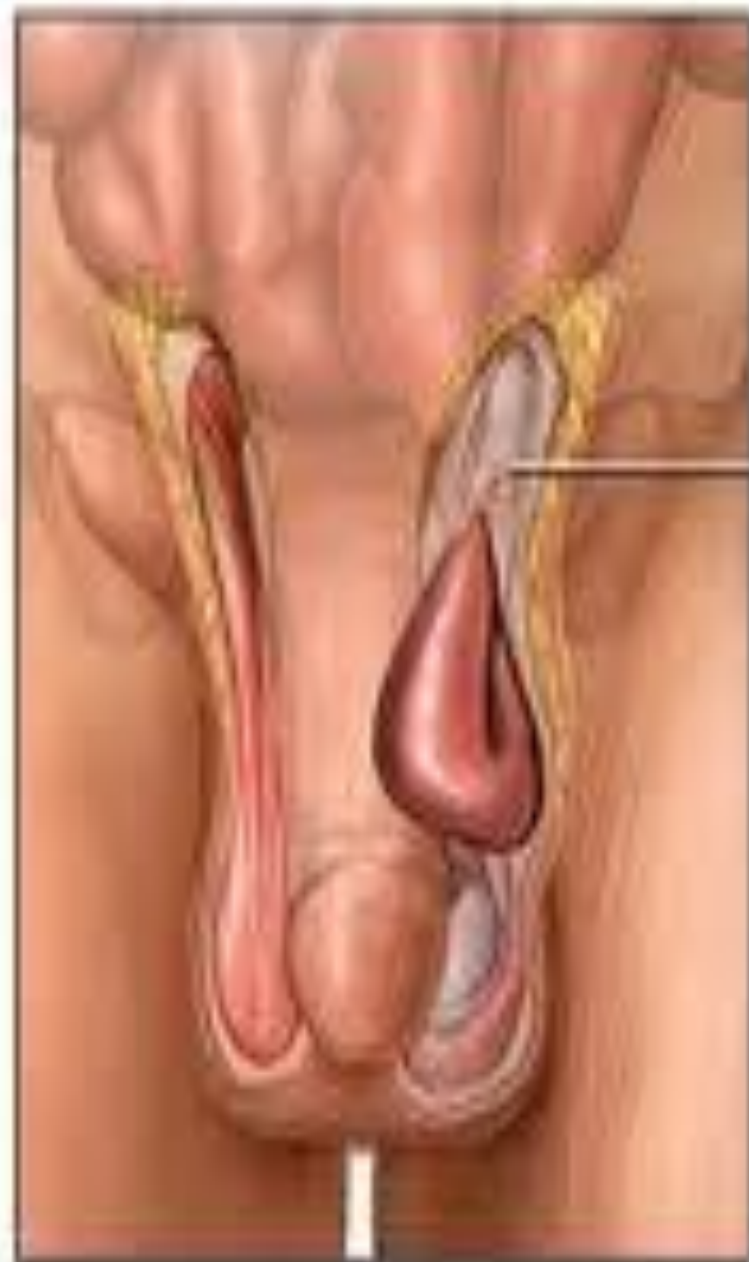- Direct Inguinal
 - Frequency - Much less common
 - Age & Sex - Usually in men over 40, rare in women
 - Point of Origin - Above inguinal ligament close to pubic tubercle
(near external inguinal ring)



Groin Hernia

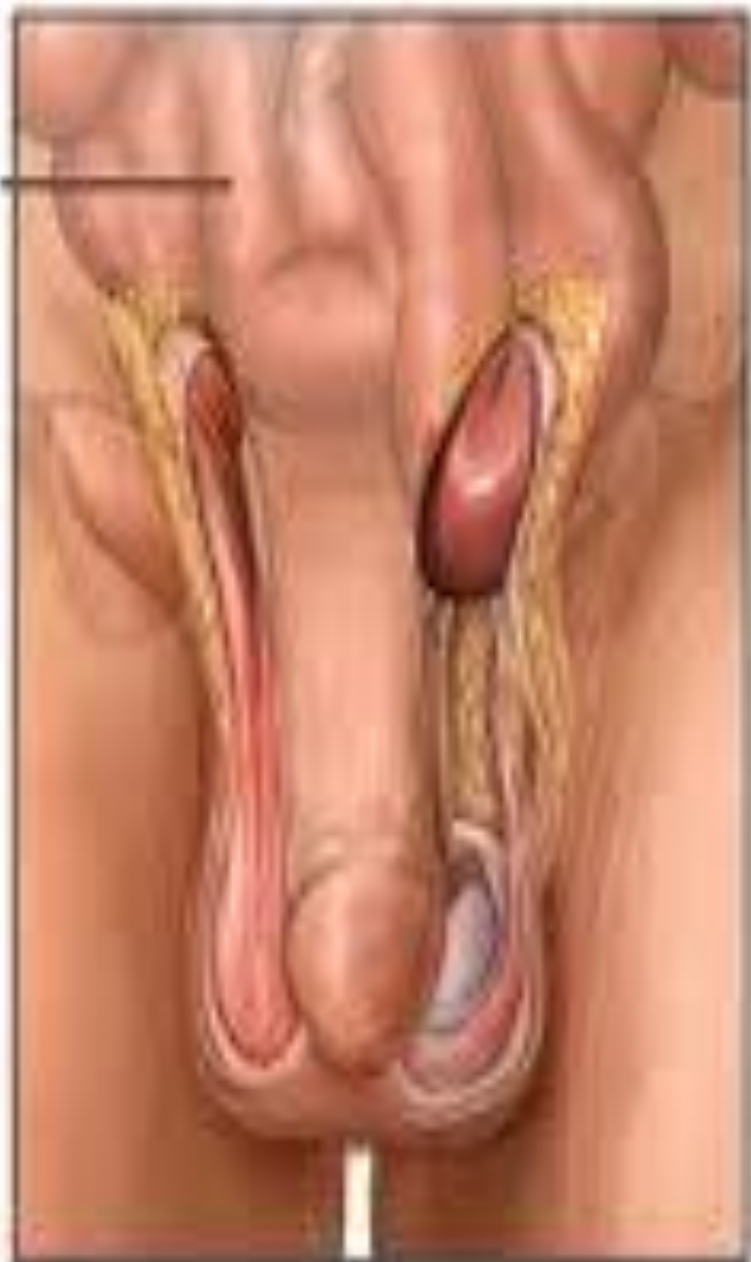- Femoral Hernia
 - Frequency – Least common
 - Age & Sex – More common in women than men
 - Point of Origin – Below the inguinal ligament. Appears more lateral than an inguinal hernia. May be hard to differentiate from lymph nodes.





Small intestine

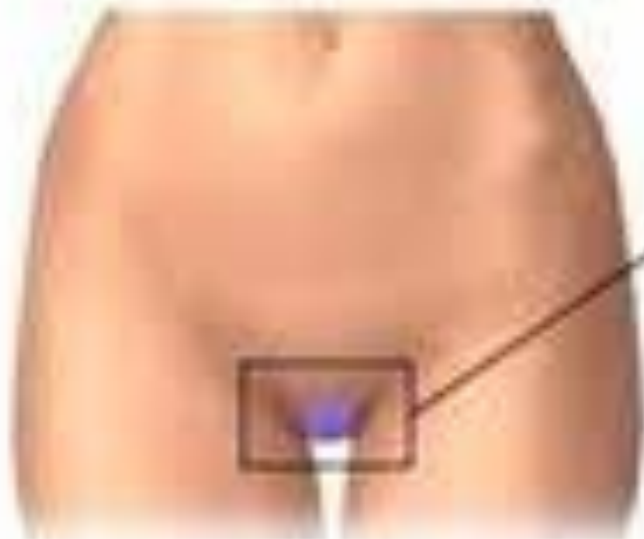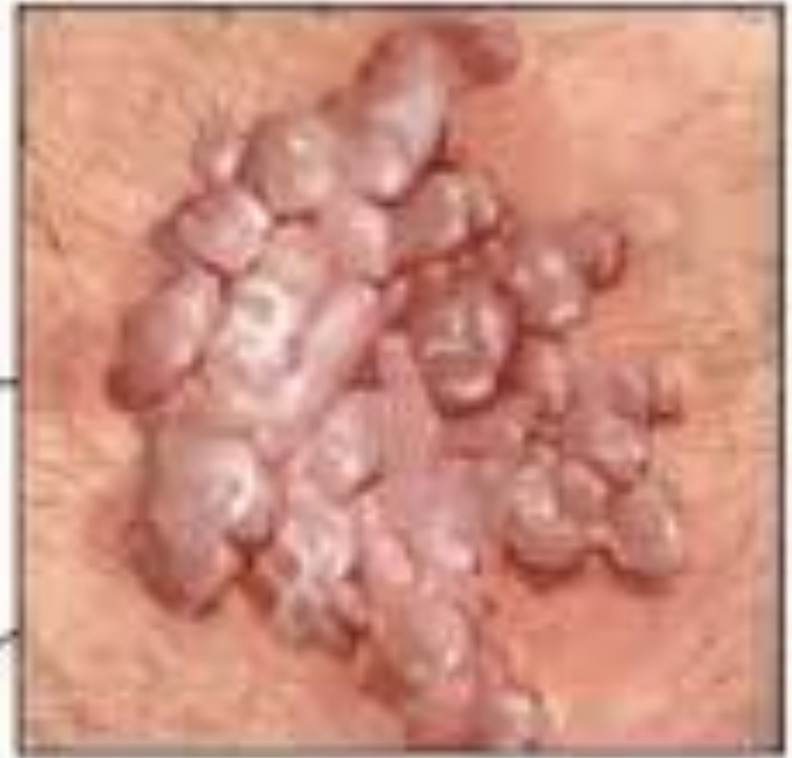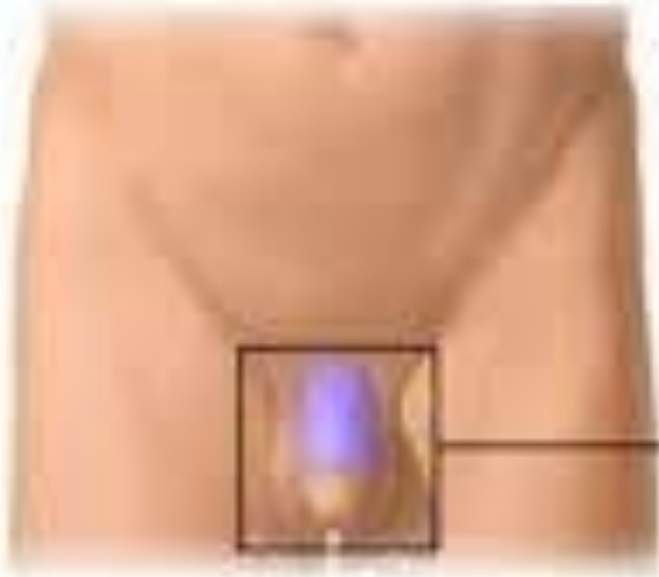
Inguinal canal



Indirect inguinal hernia

Direct inguinal hernia

Male Genital Pathology



Genital warts:
Found on shaft of penis (male),
vagina, vulva, cervix (female)
and around anus

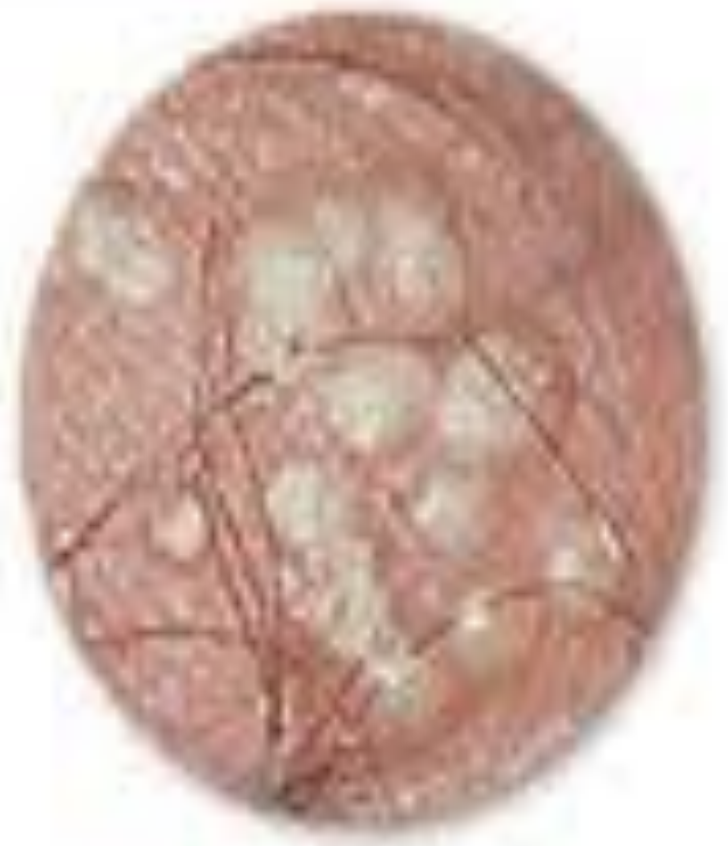Male Genital Pathology



Herpes Blisters

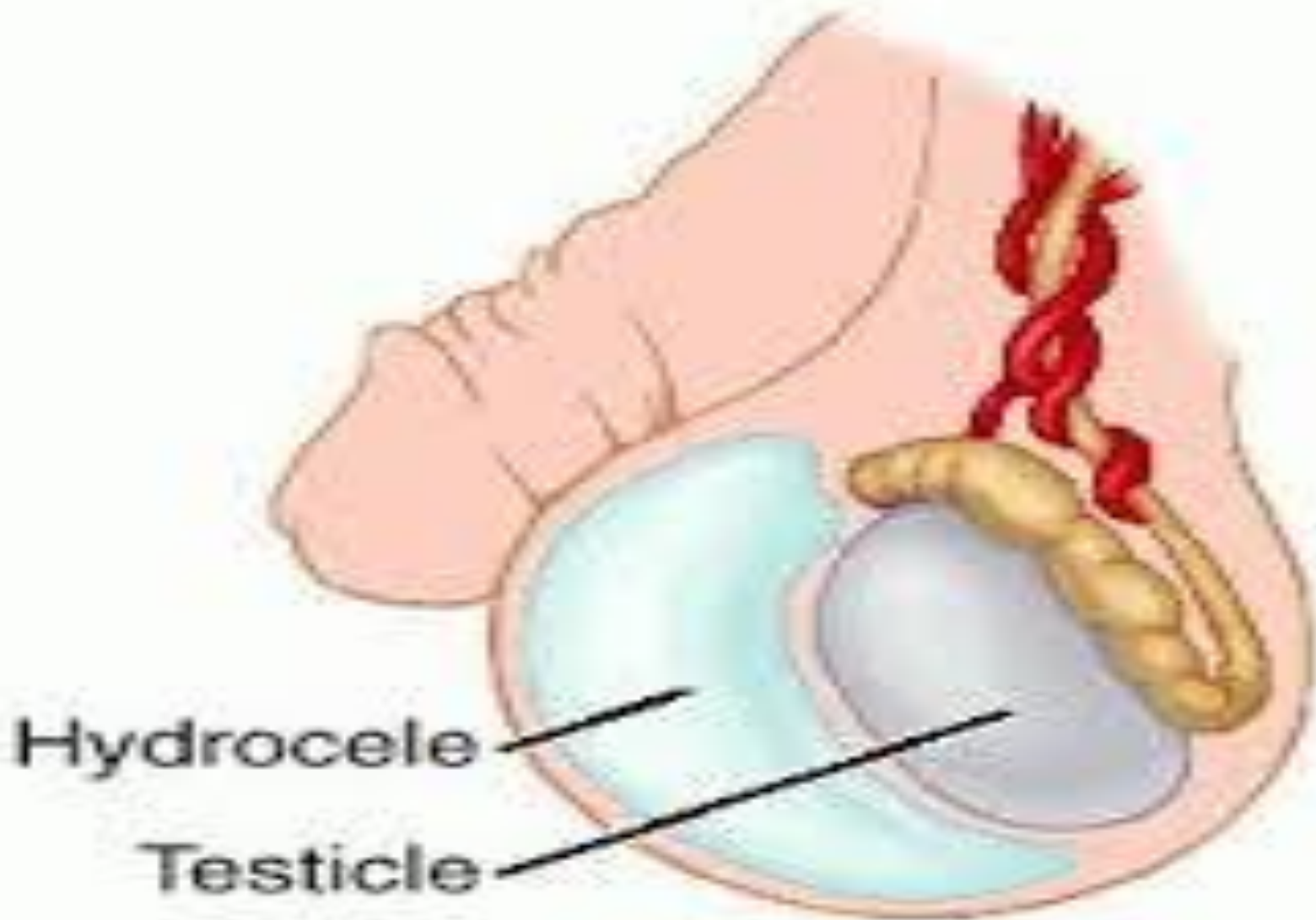


Early Stage



Later Stage

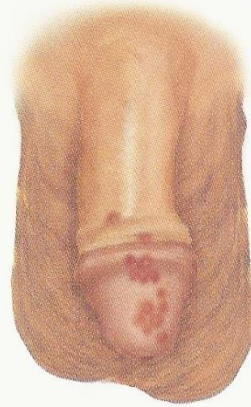Male Genital Pathology





Venereal Wart (*Condyloma acuminatum*)

Venereal warts are rapidly growing excrescences that are moist and often malodorous. They result from infection by human papillomavirus.



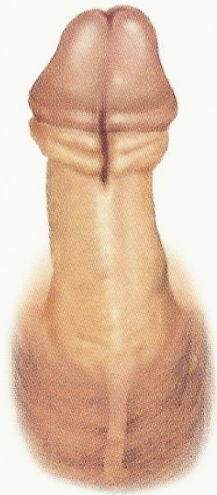Genital Herpes

A cluster of small vesicles, followed by shallow, painful, nonindurated ulcers on red bases, suggests a herpes simplex infection. The lesions may occur anywhere on the penis. Usually there are fewer lesions when the infection recurs.



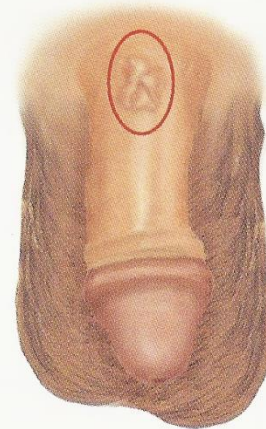
Syphilitic Chancre

A syphilitic chancre usually appears as an oval or round, dark red, painless erosion or ulcer with an indurated base. Nontender enlarged inguinal lymph nodes are typically associated. Chancres may be multiple, and when secondarily infected may be painful. They may then be mistaken for the lesions of herpes. Chancres are infectious.



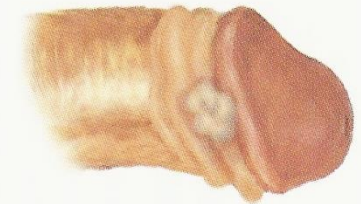
Hypospadias

Hypospadias is a congenital displacement of the urethral meatus to the inferior surface of the penis. A groove extends from the actual urethral meatus to its normal location on the tip of the glans.



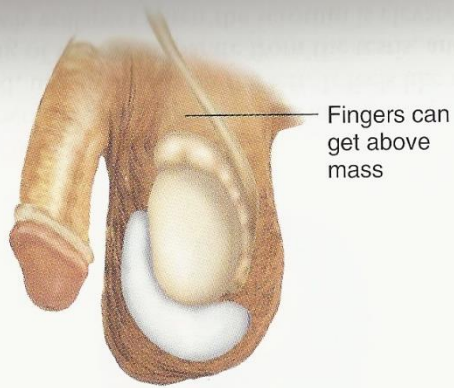
Peyronie's Disease

In Peyronie's disease, there are palpable nontender hard plaques just beneath the skin, usually along the dorsum of the penis. The patient complains of crooked, painful erections.



Carcinoma of the Penis

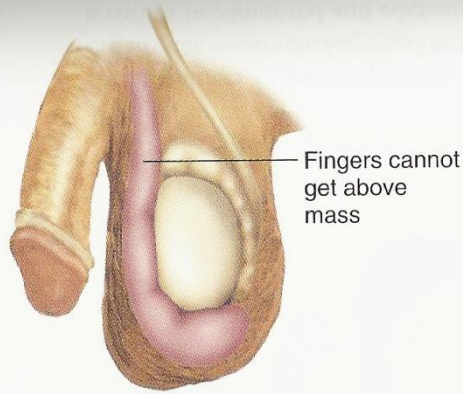
Carcinoma may appear as an indurated nodule or ulcer that is usually nontender. Limited almost completely to men who are not circumcised in childhood, it may be masked by the prepuce. Any persistent penile sore must be considered suspicious.



Fingers can get above mass

Hydrocele


A hydrocele is a nontender, fluid-filled mass within the tunica vaginalis. It transilluminates and the examining fingers can get above the mass within the scrotum.



Fingers cannot get above mass

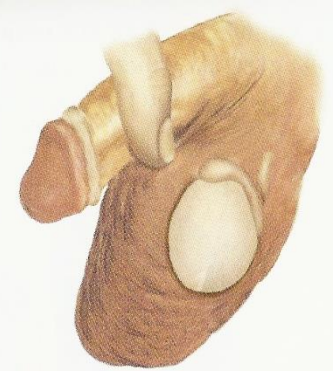Scrotal Hernia

A hernia within the scrotum is usually an *indirect inguinal hernia*. It comes through the external inguinal ring, so the examining fingers cannot get above it in the scrotum.



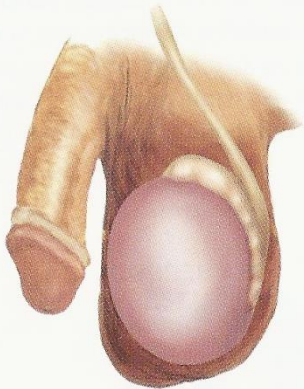Scrotal Edema

Pitting edema may make the scrotal skin taut. This may accompany the generalized edema of congestive heart failure or nephrotic syndrome.



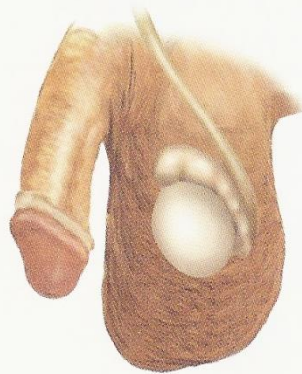Cryptorchidism

In cryptorchidism, the testis is atrophied and may lie in the inguinal canal or the abdomen, resulting in an undeveloped scrotum as above. There is no palpable left testis or epididymis. Cryptorchidism markedly raises the risk of testicular cancer.



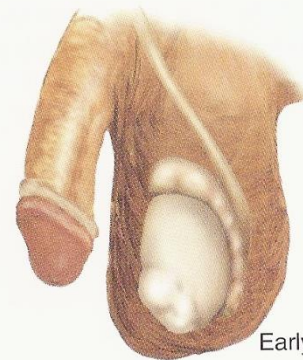Acute Orchitis

The testis is acutely inflamed, painful, tender, and swollen. It may be difficult to distinguish from the epididymis. The scrotum may be reddened. Seen in mumps and other viral infections; usually unilateral.



Small Testis

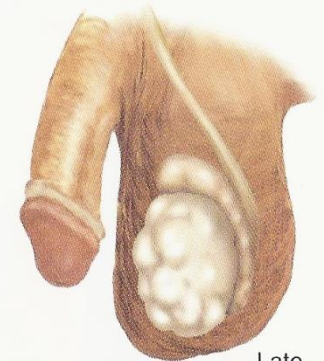
In adults, the length is usually ≤ 3.5 cm. Small firm testes in *Klinefelter's syndrome*, usually ≤ 2 cm. Small soft testes suggesting atrophy seen in cirrhosis, myotonic dystrophy, use of estrogens, hypopituitarism; may also follow orchitis.



Early

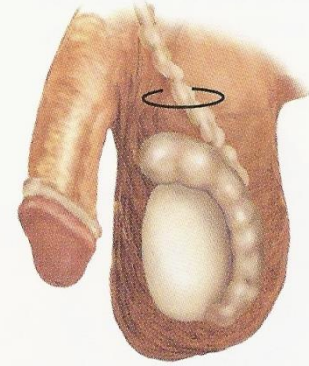
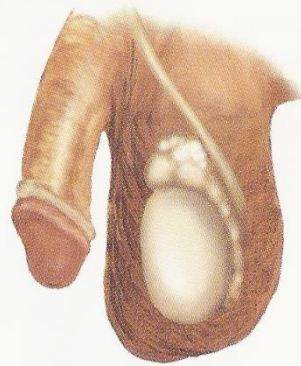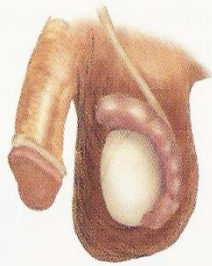Tumor of the Testis

Usually appears as a painless nodule. Any nodule within the testis warrants investigation for malignancy.



Late

As a testicular neoplasm grows and spreads, it may seem to replace the entire organ. The testicle characteristically feels heavier than normal.



Acute Epididymitis

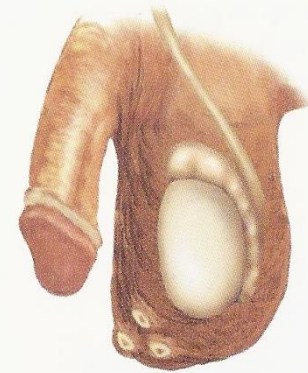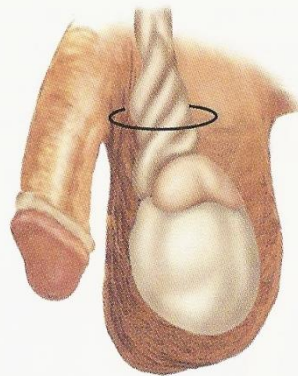
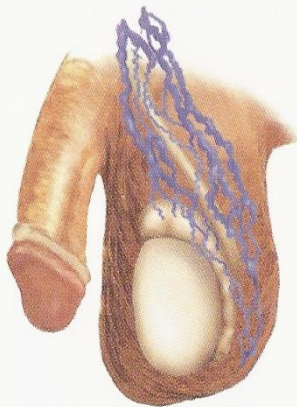
An acutely inflamed epididymis is tender and swollen and may be difficult to distinguish from the testis. The scrotum may be reddened, and the vas deferens inflamed. It occurs chiefly in adults. Coexisting urinary tract infection or prostatitis supports the diagnosis.

Spermatocele and Cyst of the Epididymis

A painless, movable cystic mass just above the testis suggests a spermatocele or an epididymal cyst. Both transilluminate. The former contains sperm and the latter does not, but they are clinically indistinguishable.

Tuberculous Epididymitis

The chronic inflammation of tuberculosis produces a firm enlargement of the epididymis, which is sometimes tender, with thickening or beading of the vas deferens.



Varicocele

Varicocele refers to varicose veins of the spermatic cord, usually found on the left. It feels like a soft "bag of worms" separate from the testis, and slowly collapses when the scrotum is elevated in the supine patient. Infertility may be associated.

Torsion of the Spermatic Cord

Torsion, or twisting, of the testicle on its spermatic cord produces an acutely painful, tender, and swollen organ that is retracted upward in the scrotum. The scrotum becomes red and edematous. There is no associated urinary infection. Torsion, most common in adolescents, is a surgical emergency because of obstructed circulation.

Epidermoid Cysts

These are firm, yellowish, nontender, cutaneous cysts up to about 1 cm in diameter. They are common and frequently multiple.

Examination Video



- [Male Genital Examination](#)
- [Testicular Self Examination](#)