

INSIDE

- Uses of autofluorescence in clinical practice: p. 3
- The Vision Therapy Service has been remodeled: p. 4
- Don't ignore decreased best corrected visual acuity: p. 4

pacificu.edu



Pacific University College of Optometry

EYE ON PACIFIC

News for local referring providers

Fall | 2014

Corneal Topography in Optometric Practice

As vision subspecialties continue to grow, we can ensure that patients continue to get the care they deserve.

MATT LAMPA, OD, FAAO | CONTACT LENS SERVICE CHIEF

Corneal topography has revolutionized our understanding of corneal disease diagnosis and progression. Corneal topography has numerous applications in refractive surgery, and the implications for contact lens design and management continue to evolve as information is gleaned from the modern corneal topographer.

The modern corneal topographer has the ability to interpret the videokeratoscopic image in several ways. In optometric practice, three display modes rise to the forefront: axial, tangential, and elevation displays.

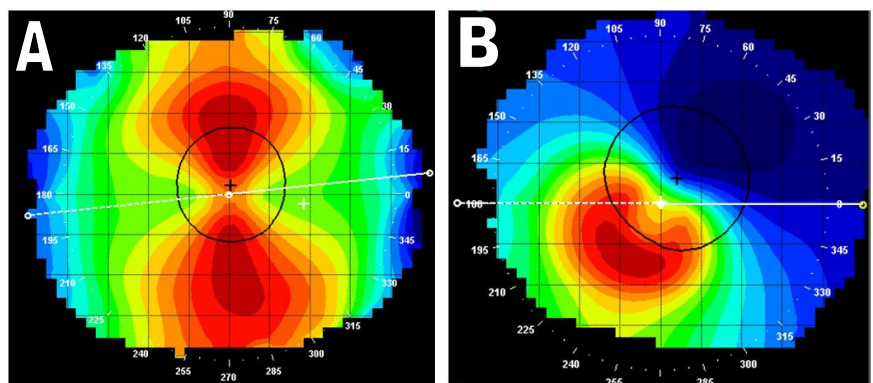


Figure 1: Axial corneal topography demonstrating a regular (A) and irregular (B) corneal astigmatism.

The axial power display is a dioptric power display of the cornea. As the cornea steepens (keratoscopic mires become closer together), the corneal dioptric power increases. The axial power display is a direct representation to how the cornea behaves refractively.

Corneal Topography (continued)

The axial display is useful in monitoring changes in corneal power following refractive surgery or orthokeratology, as well as determining the amount and type (regular or irregular) of astigmatism over the pupil (See Figure 1). This allows us to predict how a patient may see optimally with spectacles after careful manifest refraction and when a non-flexing rigid contact lens may be indicated to improve the final visual outcome for the patient (See Figure 1).

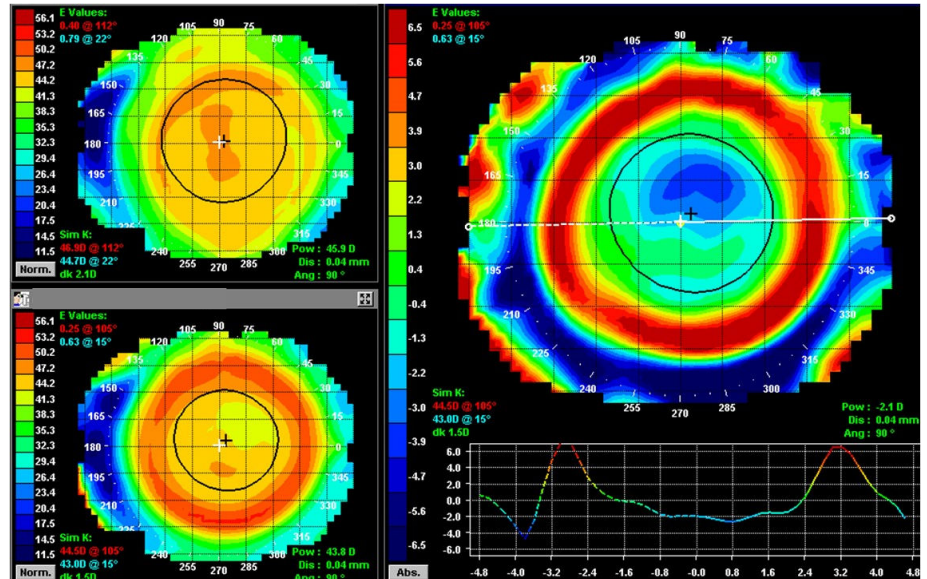


Figure 2: Tangential corneal topography demonstrating areas of corneal topography change following orthokeratology. Baseline cornea top left, post-orthokeratology cornea bottom left.

A tangential display is more of a smoothing of the corneal profile and attempts to compare how one point on the cornea relates to another, i.e., how the slope or shape changes with distance across the cornea. The tangential display gives us an understanding of position of corneal change. This is particularly important to the contact lens practice when analyzing the position of the contact lens with orthokeratology (See Figure 2).

The elevation display attempts to describe the cornea in terms of height rather than curvature. This has direct implications as it relates to contact lenses. The corneal topographer assumes a reference surface and theoretically overlies this on the cornea. From this reference surface the

topographer measures up or down to the corneal surface. If the measurement needed is from the reference surface down toward the cornea the topographer identifies this as blue (depressed), and if it needs to measure up it will identify this area as red within the color display (elevated). It is through the elevation display that corneal topographers are able to simulate a rigid contact lens sodium fluorescein pattern (See Figure 3).

The simulated fluorescein pattern can be extremely helpful in clinical practice when troubleshooting corneal rigid contact lenses for regular and irregular astigmatism or for

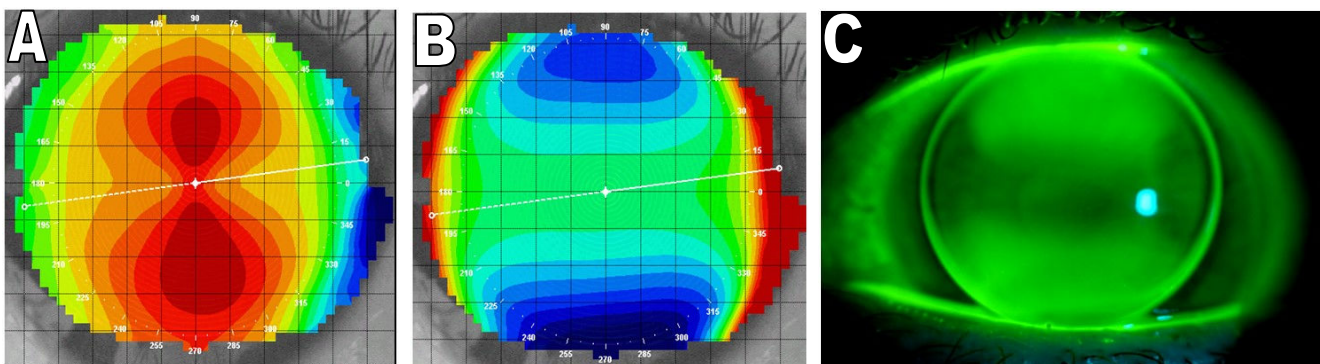


Figure 3: These axial (A) and elevation (B) corneal topography maps correlate with the actual rigid contact lens sodium fluorescein pattern (C).

Corneal Topography (continued)

orthokeratology. Some corneal topographers even attempt to simulate scleral lens designs within their topography software.

By taking advantage of the elevation display and its corneal height data we recently completed a retrospective analysis attempting to determine the corneal elevation difference when rigid corneal contact lenses become challenging to design. In looking at 72 cases of individuals who had struggled or failed in custom rigid corneal contact lenses and were ultimately successful in scleral contact lenses, the elevation difference between the maximum and minimum corneal elevation was at least 400 microns (See Figure 4). This rule has aided us immensely in quickly analyzing whether a patient with irregular astigmatism should be initially fit in rigid corneal or scleral lenses.

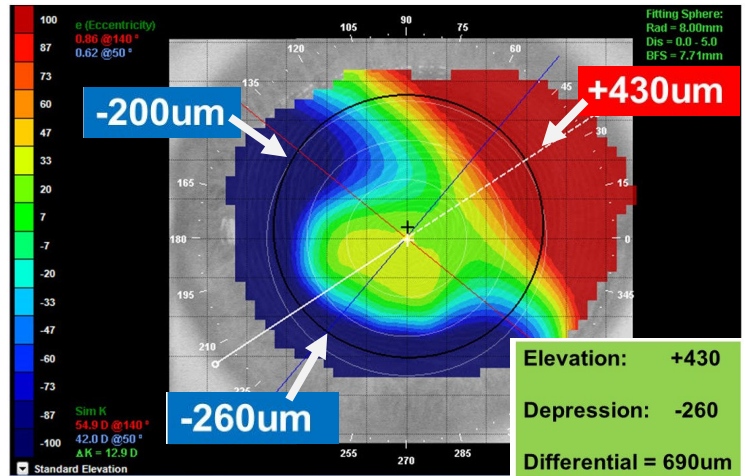


Figure 4: Elevation map demonstrating a greater than 400 micron difference in corneal elevation.

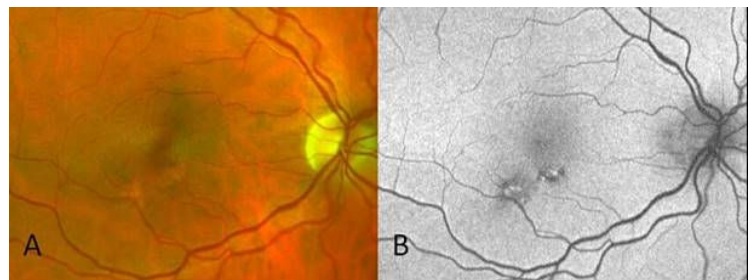
As we continue to progress in our understanding of corneal anatomy and shape we aim to better serve patients with contact lenses and manage their corneal conditions.

Advances in Medical Eye Care

LORNE YUDCOVITCH, OD, MS, FAAO | MEDICAL EYE CARE SERVICE CHIEF

Optometrists are experiencing a renaissance of new technologies to assist with diagnosing conditions and treating patients. Ironically, fundus autofluorescence (FAF), present since at least 1959 when fluorescein angiography first came into routine use, has gained renewed utility in ocular disease management. The Pacific University Forest Grove Eye Clinic currently uses FAF in the Medical Eye Care/Ocular Disease and Special Testing Service.

How does autofluorescence work? A molecule class called 'fluorophores' is stimulated by short wavelength light and subsequently naturally emits longer wavelength light back to the instrument sensor. Fluorophores are in retinal pigment epithelial (RPE) lipofuscin, as well as optic disc drusen, and to a lesser extent other ocular tissues. Hyperfluorescence may indicate RPE metabolic stress, while hypofluorescence may indicate RPE death.



Autofluorescence patterns may differ significantly from what is seen with conventional fundus photography. For example, this patient (See Figure) showed no obvious pathology on conventional fundus photography (A). FAF revealed hyper and hypo-fluorescent defects below his macula (B). The patient admitted working with various lasers as an engineer for years, sighting only with his right eye.

We are happy to consult with you and/or accept referrals for FAF testing for your patients.

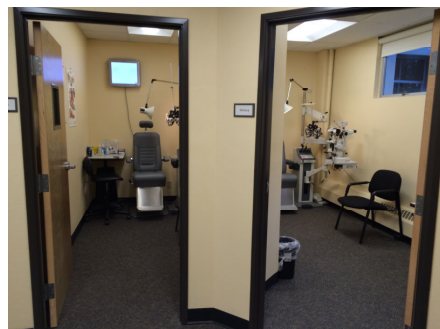Advances in Binocular Vision

HANNU LAUKKANEN, OD, MED, FAAO, FCOVD-A | VISION THERAPY SERVICE CHIEF

Our Forest Grove Vision Therapy Service has been remodeled! New walls, new carpets, new window coverings, new lighting, new ceiling tile, and spanking new paint with modern wall coverings. Our service is still on the bottom floor of the Jefferson Hall, but the old institution look is gone. We now have new diagnostic and therapeutic rooms with color accents plus HIPAA compliant privacy. Fully adjustable modern LED lighting completely transforms the environment. Equipment has been parsed and redistributed to optimize the new lighting. Now our Neuro-Vision Rehabilitator, which requires projection on a large screen, has found a better home in a room with exquisitely adjustable illumination.



Our vision therapy staff and faculty are thankful for the generous bequest and equally thankful to our Dean Coyle for directing resources our way. Thanks also to Drs. Timpone and Eakland for their assistance in transforming our hoped-for remodel into reality. Please come by and see for yourself.



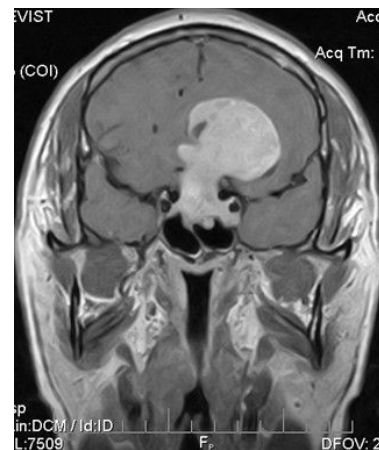Advances in Neuro-Ophthalmic Disease

DENISE GOODWIN, OD, FAAO | COORDINATOR, NEURO-OPHTHALMIC DISEASE SERVICE

A number of the referrals that we see in the Neuro-ophthalmic Disease Clinic involve decreased best corrected visual acuity of unknown origin. Congratulations to those who don't just ignore this potentially devastating sign. Even if the vision loss is subtle, there must be a cause. Be careful to not attribute vision loss to cataracts or dry eye if the signs are not consistent with the vision loss.

This is a patient who came in just because he was experiencing dry eyes. However, when we did visual acuities, we found that he was 20/15 in the right eye and 20/30 in the left eye. Pupils and extraocular muscle movements were normal. He did have bilateral pterygia. Otherwise, anterior and posterior ocular health was unremarkable. Past records indicated that he was seeing 20/15 in both eyes a year previous. Because of the unexplained vision loss, we performed numerous tests looking for a cause. Topography and macular

OCT were normal. However, visual fields showed a complete bitemporal visual field loss. Based on this, we ordered neuroimaging. The cause of vision loss ultimately turned out to be a very large pituitary adenoma.



The take home message: Don't just ignore decreased best visual acuity. There must be a cause. If your view of the retina is obscured, then the cause may be attributed to cataracts or dry eye. Otherwise, visual field, OCT, or neuroimaging may be necessary. We have also found the ERG and VEP to be very helpful with these cases.

CE Opportunities

January:

- PUCO Glaucoma Symposium; Willows Lodge, Woodinville, WA; Jan. 10
- Island Eyes Conference, Hilton Waikoloa, HI; Jan. 24-31

February:

- Columbia Optometry Conference; Vancouver Hilton Hotel, Vancouver, WA; Feb. 27-28

March:

- PMOS Annual Spring Event; Oregon Zoo; Mar. 14

April:

- PUCO Coeur d'Alene CE; Coeur d'Alene Golf and Spa Resort; April 24-25

July:

- Victoria Conference; Inn at Laurel Point, British Columbia, Canada; July 16-19

Research Opportunities

We are recruiting patients for two National Eye Institute sponsored studies. The Convergence Insufficiency Treatment Study is evaluating the effectiveness of home-based therapy for symptomatic convergence insufficiency. Children should be 9 to <18 years of age with symptomatic convergence insufficiency. The Hyperopic Treatment Study is evaluating when to prescribe for hyperopia in very young children. We are recruiting hyperopes +3.00 to +6.00. There are 2 Cohorts: children 12 months to <36 months of age and 36 to <72 months of age. For recruitment criteria or to refer a candidate, please contact study coordinator, Jayne Silver, at jaynesilver@comcast.net or 503-804-8241.

Practice Management Tips

BARBARA COLTER | DIRECTOR OF CLINICAL OPERATIONS

When it comes to providing a diagnosis code that speaks to the medical necessity of punctal plug insertion, what code should be used after September 30, 2015? Currently, ICD-9 code 375.15 describes the dry eye diagnosis that necessitates the insertion of a punctal plug. It is accepted by most carriers (including most Medicare carriers).

Looking ahead to 2015, note that this diagnosis has been expanded to 4 possible codes, eliminating the need for some modifiers currently used with ICD-9:

- H04 Disorders of lacrimal system
- H04.1 Other disorders of lacrimal gland
- H04.12 Dry eye syndrome (Tear film insufficiency, NOS)
- H04.121 Dry eye syndrome of right lacrimal gland
- H04.122 Dry eye syndrome of left lacrimal gland

- H04.123 Dry eye syndrome of bilateral lacrimal glands
- H04.129 Dry eye syndrome of unspecified lacrimal gland

As with ICD-9, CPT code 68761 will be used for insertion of a plug with the HCPCS code A4262 (temporary duct). The patient should be scheduled back in clinic after 14 days (remember there is a global period of 10 days for this CPT code). If they have been successful with the temporary plug, bill again using CPT code 68761 with the HCPCS code A4263 (permanent duct). If multiple punctal plugs are to be inserted, report each code on a separate line.

Medicare considers the plug supplies (HCPCS codes) non-billable, but some non-Medicare carriers may reimburse for them. As always, check with the carrier.

Referral Service Contact Numbers

Pacific EyeClinic Forest Grove

2043 College Way, Forest Grove, OR 97116

Phone: 503-352-2020

Fax: 503-352-2261

Vision Therapy: Scott Cooper, OD; Graham Erickson, OD; Hannu Laukkanen, OD; JP Lowery, OD

Pediatrics: Scott Cooper, OD; Graham Erickson, OD; Hannu Laukkanen, OD; JP Lowery, OD

Medical Eye Care: Ryan Bulson, OD; Tracy Doll, OD; Lorne Yudcovitch, OD

Low Vision: Karl Citek, OD; JP Lowery, OD

Contact Lens: Mark Andre; Patrick Caroline; Beth Kinoshita, OD; Scott Pike, OD

Pacific EyeClinic Cornelius

1151 N. Adair, Suite 104 Cornelius, OR 97113

Phone: 503-352-8543

Fax: 503-352-8535

Pediatrics: JP Lowery, OD

Medical Eye Care: Tad Buckingham, OD; Len Koh, OD; Sarah Martin, OD; Lorne Yudcovitch, OD

Pacific EyeClinic Hillsboro

222 SE 8th Avenue, Hillsboro, OR 97123

Phone: 503-352-7300

Fax: 503-352-7220

Pediatrics: Ryan Bulson, OD

Medical Eye Care: Tracy Doll, OD; Dina Erickson, OD; Len Koh, OD; Caroline Ooley, OD

Neuro-ophthalmic Disease: Denise Goodwin, OD

Pacific EyeClinic Beaverton

12600 SW Crescent St, Suite 130, Beaverton, OR 97005

Phone: 503-352-1699

Fax: 503-352-1690

3D Vision: James Kundart, OD

Pediatrics: Alan Love, OD

Medical Eye Care: Drew Aldrich, OD; Susan Littlefield, OD

Contact Lens: Matt Lampa, OD

Pacific EyeClinic Portland

511 SW 10th Ave., Suite 500, Portland, OR 97205

Phone: 503-352-2500

Fax: 503-352-2523

Vision Therapy: Bradley Coffey, OD; Ben Conway, OD; Scott Cooper, OD; James Kundart, OD

Pediatrics: Bradley Coffey, OD; Ben Conway, OD; Scott Cooper, OD; James Kundart, OD

Medical Eye Care: Ryan Bulson, OD; Candace Hamel, OD; Scott Overton, OD; Carole Timpone, OD

Contact Lens: Mark Andre; Candace Hamel, OD; Matt Lampa, OD; Scott Overton, OD; Sarah Pajot, OD

Neuro-ophthalmic Disease/Strabismus: Rick London, OD

Low Vision: Scott Overton, OD

When scheduling an appointment for your patient, please have the patient's name, address, phone number, date of birth, and name of insurance, as well as the type of service you would like Pacific University eye clinics to provide.