

February 2013

TEXAS DENTAL Journal

Inside:

Page 127:

Missed Canal Systems
are the Most Likely
Basis for Endodontic
Retreatment of
Molars

Page 141:

CAD/CAM and
Lithium Disilicate:
An Anterior
Esthetic
Case Study

Missed Canal Systems are the Most Likely Basis for Endodontic Retreatment of Molars

David E. Witherspoon, BDS_c, MS

Joel C. Small, DDS, MBA

John D. Regan, DDS, MSc, MS

Introduction

The goal of endodontic treatment is to preserve healthy and functional teeth. Classic studies report a success rate of approximately 95% in all treated endodontic cases (1-3). The small percentage of endodontic failures are characterized by persistent or reoccurring apical periodontitis. Typically, the lack of healing is a result of persistent intraradicular infection residing in previously uninstrumented canals or in the complex irregularities of the root canal system (4). In a smaller percentage of cases, persistent apical periodontitis is due to extraradicular causes including periapical actinomyces, a foreign body reaction or an unresolved cystic lesion (5-9).

An examination of failed cases showed that more than two-thirds of these failures were related to incomplete cleaning and obturation of the root canal system (1). The quality of previous endodontic treatment has been found to be a major factor in the success of retreatment procedures, with previous poor quality endodontic treatment having a great-



Witherspoon



Small



Regan

David E. Witherspoon, BDS_c, MS, private practice limited to endodontics, Plano, Texas.

Joel C. Small, DDS, MBA, private practice limited to endodontics, Plano, Texas.

John D. Regan, DDS, MSc, MS, private practice limited to endodontics, Plano, Texas.

Corresponding address and print requests: David E. Witherspoon, BDS_c, MS, 5800 Coit Rd Ste 200, Plano, TX 75023; Email: dewspoon@ntendo.com.

The authors have declared no conflicts of interest, relationships and/or affiliations relevant to the subject matter or materials discussed in the manuscript.

This manuscript has been peer reviewed.

Abstract

Unfortunately, a small percentage of endodontically treated teeth do not respond favorably to non-surgical root canal treatment. Failure to locate and treat an additional canal system is cited as the principle basis for endodontic retreatment. The aim of this retrospective clinical study was to identify the incidence of additional or missed canal systems in molar retreatment cases in a private practice setting. Missed canals were identified in 64 of the 133 previously treated teeth (48%). Of the total missed canals, 11% involved a maxillary second molar and 44% involved a maxillary first molar. For the maxillary first molars, 93% of all missed canal were identified in the mesiobuccal root. In the mandibular second molars, 29% of missed canals were identified in the distal and 71% were identified in the mesial root. In the mandibular first molars, 86% of missed canals were identified in the distal and 14% were identified in the mesial root. The results of the current study support the findings of previous studies and confirm the importance of locating, instrumenting and obturating the additional canal systems in molar endodontic treatment. Given that failure to locate all canal systems of a tooth contributes significantly to unsuccessful endodontic treatment, all measures available to the clinician to maximize canal identification should be used.

KEY WORDS: missed root canal, endodontic retreatment, tooth anatomy

Tex Dent J 2013;130(2): 127-139.

er chance of being successfully retreated (12). The treatment of the disease consists of eradicating the root canal microbes or substantially reducing the

microbial load and preventing reinfection by placing a well compacted root canal filling to the ideal working length and a well formed coronal restoration

(Figure 1) (13). Clinically, this involves the chemo-mechanical removal of microorganisms and their substrate followed by obturation of the canal space.

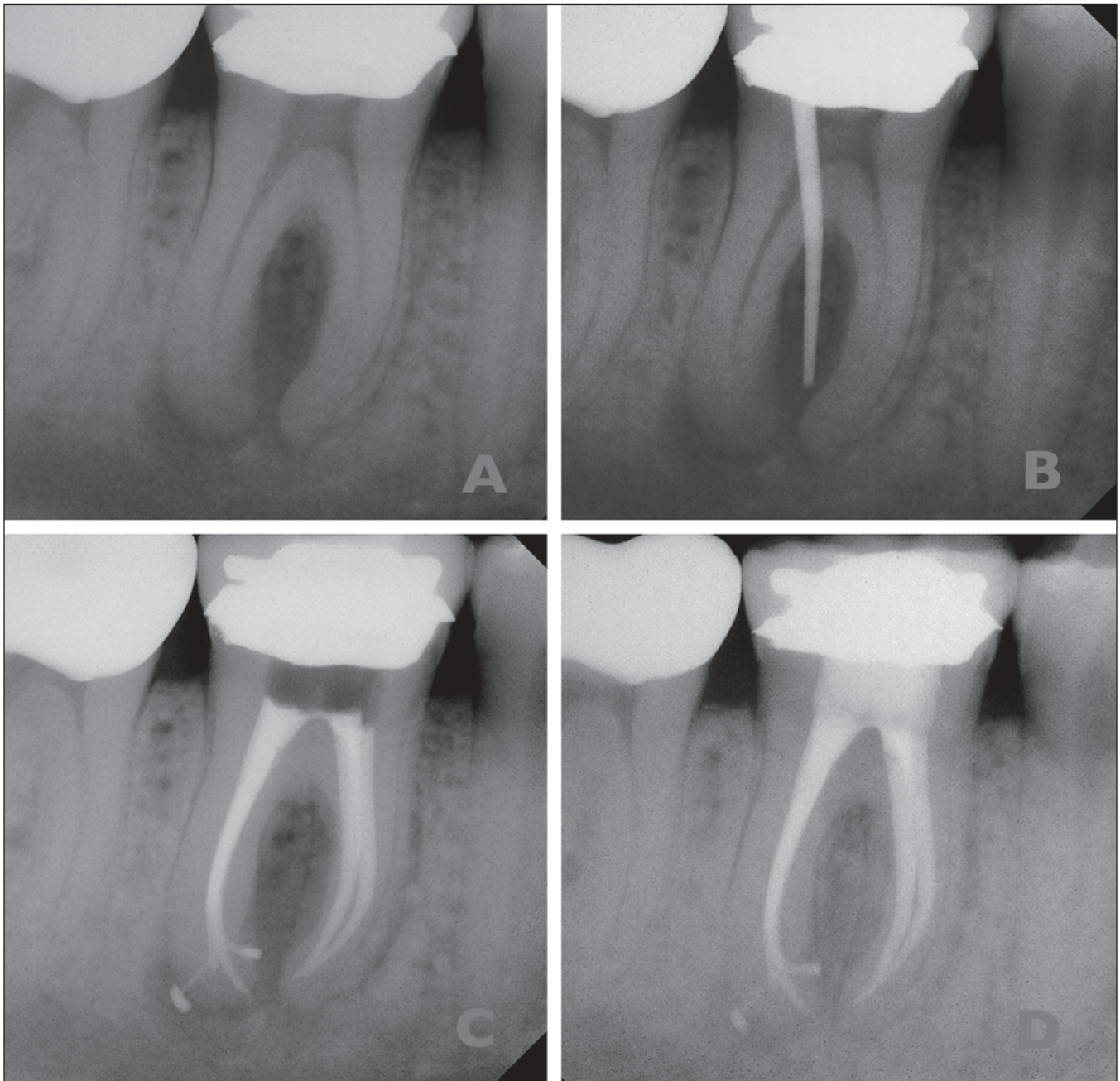


Figure 1. *A: preoperative radiograph; B: preoperative radiograph with sinus trace in place; C: postoperative radiograph; D: 1-year recall radiograph.*

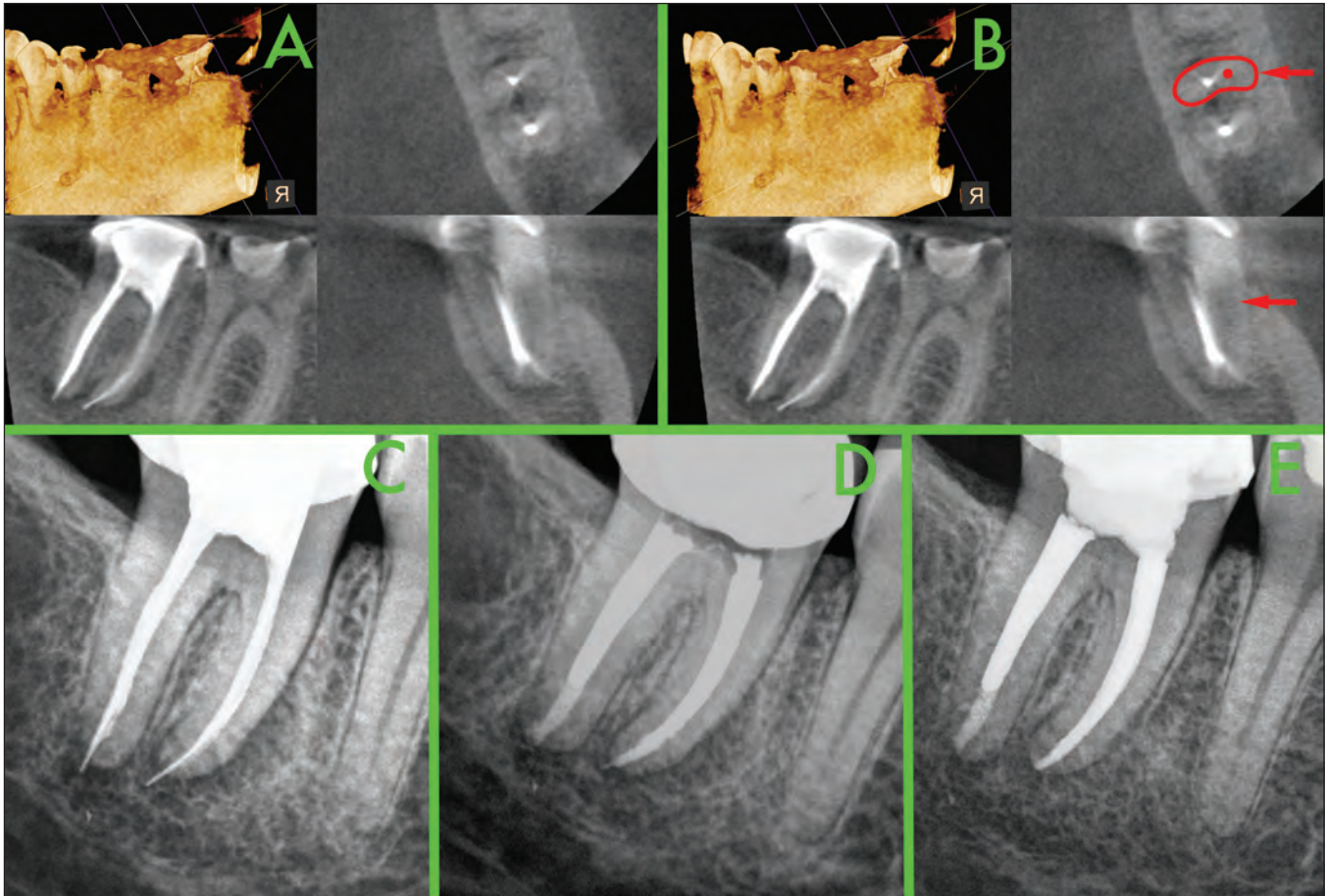


Figure 2. A: cone-beam computed tomography (CBCT) image of an endodontically treated mandibular second molar; B: CBCT image of an endodontically-treated mandibular second molar with the likely position of the missed mesiolingual canal indicated (red dot and red arrows); C: preoperative radiograph; D: postoperative radiograph (note the presence of a cleaned and shaped canal in the mesiobuccal root); E: 1-year recall radiograph.

Complex tooth anatomy can prove to be a considerable challenge for the clinician during cleaning, shaping, and obturation of the root canal system. It is not surprising then that one of the most likely causes of persistence or development of periradicular disease following endodontic therapy is a failure to locate, clean, shape, and obturate all canal systems within a tooth (Figures 2 and 3)

(11,14,15). Nonsurgical retreatment has been shown to be associated with a high degree of success (Figure 4) (12,16-22). In vitro studies have contributed significantly to the understanding of root canal morphology. They demonstrate the complexities that the clinician faces when undertaking endodontic treatment (Table 1). Several clinically based studies, focusing mainly on the mesio-

buccal root (MB) of the maxillary molars, have investigated the presence of additional canal systems in failing root canal treated teeth (15,23,24). In 2 separate studies of the presence of additional canal system in the MB root of the maxillary molars, Wolcott et al found that the incidence of an additional canal system in the MB root in first molar non-surgical retreatments was 66-67% and 40-44%

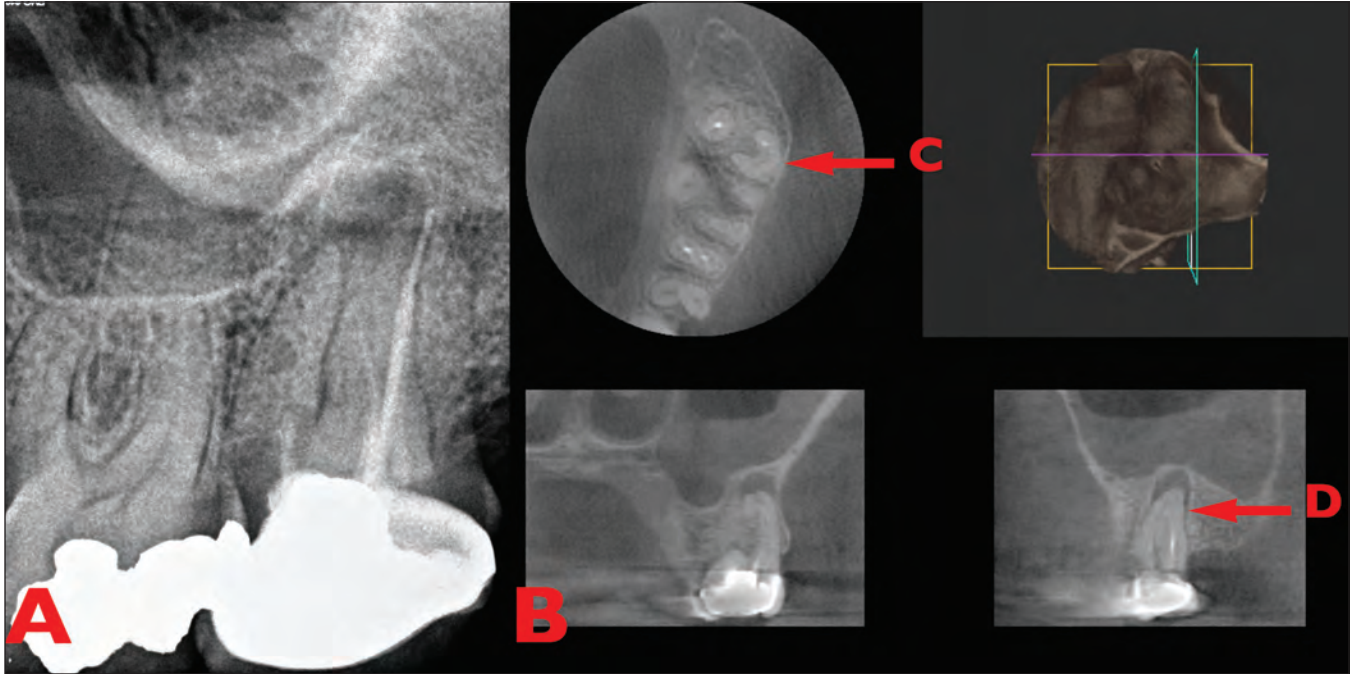


Figure 3. A: preoperative radiograph of an endodontically treated maxillary second molar; B: CBCT image of the same endodontically-treated maxillary second molar; C: axial view demonstrating a C-shaped buccal root system; D: missed canal space.

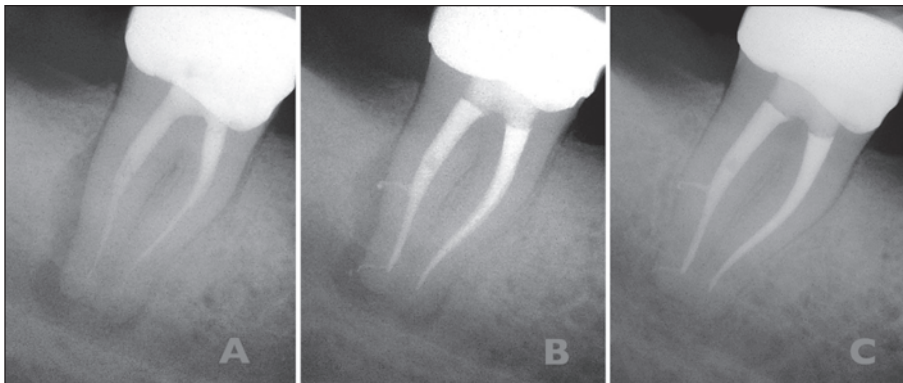


Figure 4. A: preoperative radiograph; B: postoperative radiograph; C: 1-year recall radiograph.




Figure 5. A: Initial access, red arrow indicating the presence of a missed second mesiobuccal canal; B: green arrow indicating the shaped second mesiobuccal canal; C: final obturation.

Table 1. Tooth Anatomy: Number of Canals per Tooth

Tooth	Maxillary Second Molar	Maxillary First Molar	Maxillary Second Premolar	Maxillary First Premolar	Mandibular Second Molar	Mandibular First Molar	Mandibular Second Premolar	Mandibular First Premolar	Mandibular Canine	Mandibular Lateral Incisor	Mandibular Central Incisor
1 canal	3%		54%	10%			90%	75%	80%	60%	65%
2 canal	7%		45%	85%	5%	5%	10%	25%	20%	40%	35%
3 canal	55%	25%	1%	5%	55%	55%					
4 canal	35%	75%			40%	40%					
					C-Shaped*						

* C-shaped canal systems occur in the mandibular second molar tooth in ~10% of a mixed population and ~30% of an Asian population.

in second molar non-surgical retreatments (23,24). Hoen and Pink reported 42% of nonsurgical retreatment cases had missed canals. Furthermore, additional canal space was located and treated in 89% of nonsurgical retreatments (15). The aim of this clinical study was to identify the incidence of missed canal systems in molar retreatment cases in a private practice setting and discuss contemporary measures to facilitate successful treatment.

Materials and Methods

The data was retrospectively collected from patients referred to 2 endodontists for the management of failing endodontically-treated teeth. Consecutive nonsurgical retreatments of all molar teeth for a period of 1 year were included in this study. The teeth were examined

and a diagnosis and treatment plan was established. Informed consent was routinely obtained from each patient before examination and treatment, and there were no contraindications to nonsurgical endodontic treatment. Standard straight-on and distal angle periapical radiographs were taken of each tooth. A second canal was suspected if multiple periodontal ligament spaces or apices were noted radiographically or if an instrument appeared to be off center in the root. During the treatment, the tooth number and the presence of an additional canal system was recorded in the practice management software (TDO; The Digital Office, Santa Barbara, California, USA).

All treatments were completed using a Zeiss (Carl Zeiss Meditec, Dublin, California, USA) dental operating microscope at a magnification of at least 7.5 power. In maxillary molar

teeth, access preparations were routinely modified to a rhomboidal shape and troughing of the fissure or groove between the MB and palatal canals was routinely performed (25-26). Troughing was continued until the presence or absence of a second mesiobuccal (MB2) canal was established (Figure 5). The depth of the trough was not recorded. To be included and recorded as a second canal, the canal had to be negotiable and obturated to its own apex or within 5 mm of the apex when contiguous with an adjacent canal system.

Results

A total of 133 molars were examined. Missed canals were identified in 64 of the 133 previously treated teeth (48%). Of the total missed canals, 11% (n = 7) involved a maxillary second molar (Figure 7), and 44% (n = 28) involved a maxillary

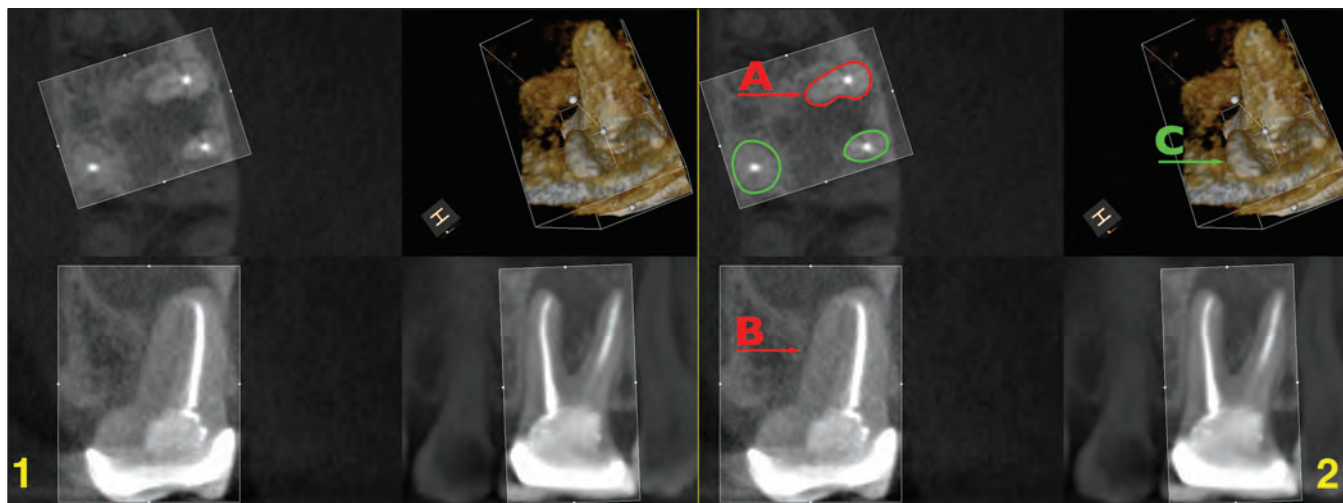


Figure 6. 1: CBCT image of an endodontically-treated maxillary first molar; 2: CBCT image of an endodontically treated maxillary first molar with A and B the offset center position of the MB canal (indicating the likely presence of the missed MB2 canal). C notes the broadness of the mesiobuccal root in the 3D reconstruction.

first molar. For the mandibular teeth, 11% (n = 7) involved a second molar, and 34% (n = 22) involved a first molar. With respect to the missed canal system in the maxillary second molars, 71% (n = 5) were located within the MB root. For the maxillary first molars, 93% (n=26) of all missed canals within this tooth group were identified in the MB root. For the mandibular second molars, 29% (n = 2) were identified in the distal and 71% (n = 5) were identified in the mesial root. For the mandibular first molars, 86% (n = 19) were identified in the distal, and 14% (n = 3) were identified in the mesial root. A summary of the results is presented in Table 2. Figures 6–8 are examples of cases of previous endodontically-treated

teeth where canal systems remain unidentified and untreated.

Discussion

Diagnosis is undoubtedly the most important part of clinical endodontics, especially in retreatment cases. Teeth are frequently relegated to the “failure” category without adequate assessment of the etiology for the failure. “Failure” is frequently a direct result of the presence of uninstrumented and inadequately debrided canal space such as extra canals, anastomoses, or unusual anatomical morphology. Canals may be left untreated if their presence is not recognized by the dentist (27). It is

incumbent on the clinician to do a thorough and exhaustive assessment, using all available technologies and techniques, before determining the appropriate treatment for the tooth, be it retreatment or extraction.

Failure to locate and treat a second canal system contributes importantly to unsuccessful root canal treatments. This has widespread implications for patient morbidity and additional financial consequences and inconvenience for patients. The majority of studies that examine the impact of missed canal systems during root canal treatment focus on the MB roots of maxillary molars, which has been recognized for decades and demonstrated in both in-vitro and in vivo stud-

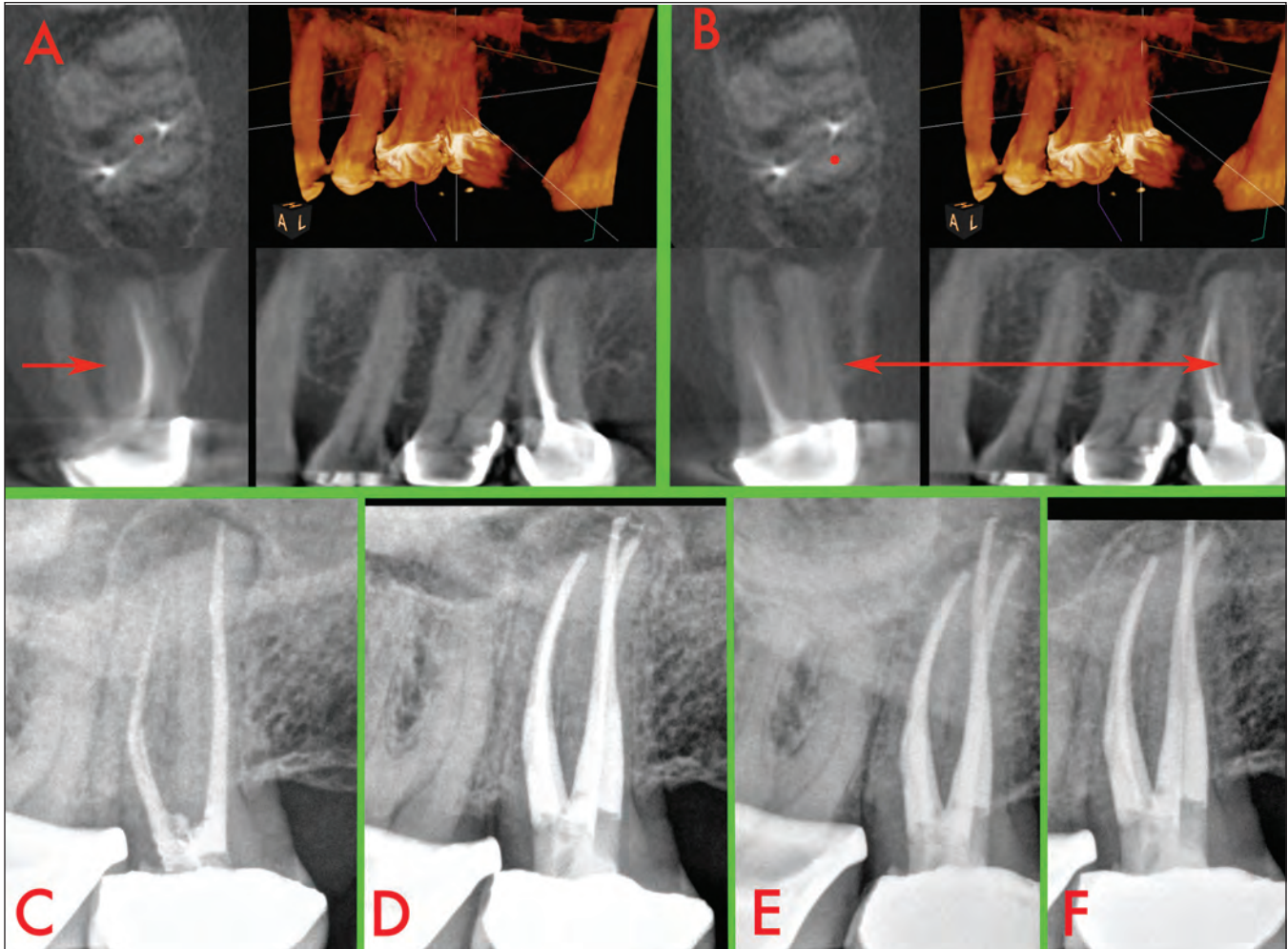


Figure 7. A: CBCT image of an endodontically-treated maxillary second molar (red dot and red arrow indicating the position of a missed MB2 canal); B: CBCT image of an endodontically-treated maxillary second molar (red dot and red arrow indicating the position of a missed distobuccal canal); C: preoperative radiograph; D: postoperative radiograph (note the presence of cleaned and shaped MB2 and distobuccal canal systems); E: 12-month recall radiograph; F: 12-month recall radiograph.

Table 2. Summary Data

Tooth No.	No. of teeth treated	No. of teeth with missed canals	% of teeth with missed canals
Tooth 15	8	6	75%
Tooth 14	27	14	52%
Tooth 2	4	1	25%
Tooth 3	19	14	74%
Tooth 19	30	10	33%
Tooth 18	4	3	75%
Tooth 30	27	12	44%
Tooth 31	14	4	29%
Totals	133	64	48%

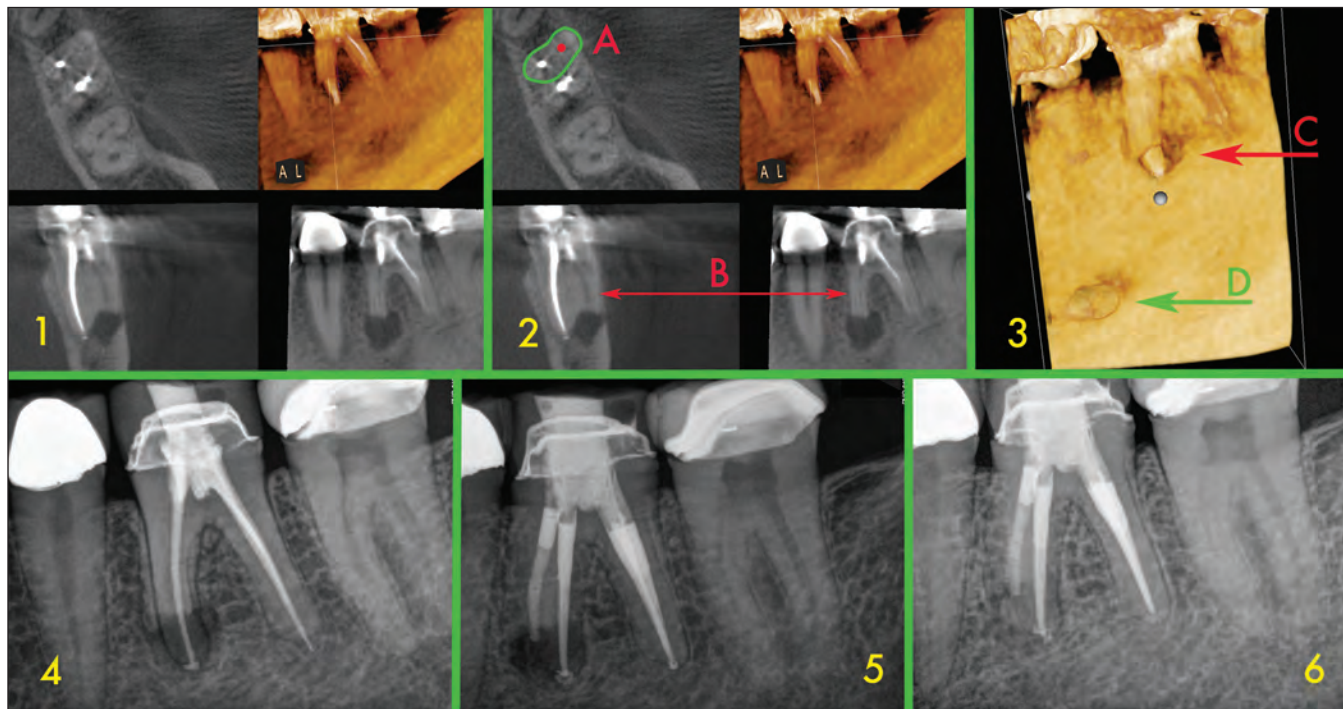


Figure 8. 1: CBCT image of an endodontically-treated mandibular first molar; 2: CBCT image of an endodontically-treated mandibular first molar with the likely position of the missed MB canal indicated (A&B); 3: 3D reconstruction demonstrating (C) root resorption of the MB root and (D) the mental nerve foramen; 4: preoperative radiograph; 5: postoperative radiograph (note the presence of a cleaned and shaped canal in the MB root); 6: 9-month recall radiograph.

ies (23,24,28-42). Historically, in vitro studies have contributed significantly to the understanding of root canal morphology. Results from these studies have highlighted the prevalence of MB2 canals in extracted maxillary molar teeth. A 2005 in vivo examination of 5,616 maxillary molars revealed that MB2 canals were present in 60% of first and 35% of second molars (23). The definition of what constitutes a “missed” canal has major impact on the results of individual studies. In 2005 Wolcott stipulated that to be included in the study, the

MB2 canal had to be negotiated and obturated either separate from the MB or within 5mm of the apex when it joined the MB canal (23). These ‘stringent’ criteria account for the slightly lower incidence of negotiable MB2 canals compared to other in vivo studies (33,43-45). The present study adopted similar criteria. In the Kulid and Peters study, 2 canals were identified in 95.2% of the MB roots in the first and second maxillary molars examined (40). In a review of laboratory versus clinical studies, Pomeranz and Fishelberg documented significant

variability in the frequency with which an MB2 canal is located (41).

Several studies have highlighted the importance of using a dental operating microscope especially when treating maxillary molar teeth. Using an dental operating microscope MB2 canal systems were located and negotiated in 80% of cases which was significantly higher than when a microscope was not used (47). Additionally, using the dental operating microscope, significantly improved access cavity preparation and

accuracy in identifying canals (48). It has been demonstrated that the use of a dental operating microscope by experienced endodontists enhances the chance of identifying additional canal systems. Buhley et al showed that the use of magnification increases the chance of locating the additional canal systems by 3x in general and by 4x in the first maxillary molar tooth (49). The inherent variability in the anatomy of teeth and in the practical difficulties encountered in treating molar teeth in patients dictate that the clinician should employ all the available resources including enhanced illumination, magnification and CBCT to insure the most predictable outcome of treatment.

Recently, the use of small field of view CBCT in endodontic practice has allowed the clinician to directly visualize the canal system morphology before and during treatment thereby facilitating the location of additional canal systems. (Figures 6–8) (46). (The Food and Drug Administration approved the first CBCT machines for use in dentistry in the year 2000). This technological leap allows visualization of the tooth canal morphology in genuine 3D while exposing the patient to low levels of radiation. It is well recognized that diagnostic acuity increases with the number of different radiological views available and so 2 or

more periapical films have been recommended (50). With CBCT, hundreds of different views are available with a single scan. Each of these images can then be further manipulated and enhanced using a number of software programs thereby maximizing the information available to the clinician (46).

As interest in CBCT in endodontics increases, a growing body of evidence underlines the accuracy of the technology to identify the existence of periradicular lesions or resorptive defects not normally identifiable on periapical films (51-55). This allows for earlier and more accurate diagnosis of disease entities. When assessing a tooth for retreatment, CBCT axial views are especially valuable in locating potential etiological factors in the failure of the previous non successful root canal therapy (Figure 7). The presence of extra canals or overlooked canal system space is rapidly and clearly identified (Figure 8) and aberrant root morphology can be identified and treated accordingly. The detection rate of MB2 canals in maxillary molars in vivo has been consistently lower than that of laboratory-based reports (56). The use of CBCTs in endodontic diagnosis can be justified while concurrently satisfying the goals of ALARA (as low as reasonably achievable). This has been confirmed in recent reports, which in turn

have been referenced in the American Association of Endodontists *Colleague for Excellence* Summer 2011 newsletter (58-60). It is stated in this newsletter the effective dose for an anterior focused field CBCT scan is less than that (0.7 times) of a single digital periapical radiograph. The effective dose for a maxillary posterior focused field CBCT scan is approximately 1.4 times higher than that of a digital periapical radiograph while that of a mandibular posterior focused field CBCT scan is 5.4 times that of a single digital periapical radiograph. In addition, CBCT studies frequently allow the clinician to eliminate multiple standard periapical radiographs, which are sometimes necessary for adequate preoperative evaluation of the tooth anatomy.

The results of the current study support the findings of previous studies and confirm the importance of locating, instrumenting, and obturating the additional canal systems in molar endodontic treatment. The study underlines the need for the operator to be cognizant of the anatomical anomalies existing in molar canal systems and the clinician should be technically competent to address these issues.

References

1. Ingle JI, Bakland LK. Endodontics. 5th ed. Hamilton, Ontario: BC: Decker; 2002.
2. Salehrabi R, Rotstein I. Endodontic treatment outcomes in a large patient population in the USA: an epidemiological study. *Journal of Endodontics*. Dec 2004;30(12):846-850.
3. de Chevigny C, Dao TT, Basrani BR, et al. Treatment outcome in endodontics: the Toronto study--phase 4: initial treatment. *Journal of Endodontics*. Mar 2008;34(3):258-263.
4. Nair PN, Sjogren U, Krey G, Kahnberg KE, Sundqvist G. Intraradicular bacteria and fungi in root-filled, asymptomatic human teeth with therapy-resistant periapical lesions: a long-term light and electron microscopic follow-up study. *Journal of Endodontics*. 1990;16(12):580-588.
5. Tronstad L, Barnett F, Cervone F. Periapical bacterial plaque in teeth refractory to endodontic treatment. *Endod Dent Traumatol*. 1990;6(2):73-77.
6. Koppang HS, Koppang R, Solheim T, Aarnes H, Stolen SO. Cellulose fibers from endodontic paper points as an etiological factor in postendodontic periapical granulomas and cysts. *Journal of Endodontics*. 1989;15(8):369-372.
7. Nair PN, Sjogren U, Krey G, Sundqvist G. Therapy-resistant foreign body giant cell granuloma at the periapex of a root-filled human tooth. *Journal of Endodontics*. 1990;16(12):589-595.
8. Nair PN, Pajarola G, Schroeder HE. Types and incidence of human periapical lesions obtained with extracted teeth. *Oral Surgery, Oral Medicine, Oral Pathology, Oral Radiology, & Endodontics*. 1996;81(1):93-102.
9. Nair PN, Sjogren U, Figdor D, Sundqvist G. Persistent periapical radiolucencies of root-filled human teeth, failed endodontic treatments, and periapical scars. *Oral Surgery Oral Medicine Oral Pathology Oral Radiology & Endodontics*. May 1999;87(5):617-627.
10. Kakehashi S, Stanley HR, Fitzgerald RJ. The Effects of Surgical Exposures of Dental Pulps in Germ-Free and Conventional Laboratory Rats. *Oral Surg Oral Med Oral Pathol*. 1965;20:340-349.
11. Sundqvist G, Figdor D. Endodontic treatment of apical periodontitis. In: Orstavik D, Pitt Ford T, eds. *Essential Endodontology*. Oxford, UK: Blackwell; 1998:242-277.
12. de Chevigny C, Dao TT, Basrani BR, et al. Treatment outcome in endodontics: the Toronto study--phases 3 and 4: orthograde retreatment. *Journal of Endodontics*. Feb 2008;34(2):131-137.
13. Nair PN, Henry S, Cano V, Vera J. Microbial status of apical root canal system of human mandibular first molars with primary apical periodontitis after "one-visit" endodontic treatment. *Oral Surgery Oral Medicine Oral Pathology Oral Radiology & Endodontics*. Feb 2005;99(2):231-252.
14. Sundqvist G, Figdor D, Persson S, Sjogren U. Microbiologic analysis of teeth with failed endodontic treatment and the outcome of conservative re-treatment. *Oral Surgery, Oral Medicine, Oral Pathology, Oral Radiology, & Endodontics*. 1998;85(1):86-93.
15. Hoen MM, Pink FE. Contemporary endodontic retreatments: an analysis based on clinical treatment findings. *Journal of Endodontics*. 2002;28(12):834-836.
16. Bergenholtz G, Lekholm U, Milthorpe R, Heden G, Odesjo B, Engstrom B. Retreatment of endodontic fillings. *Scand J Dent Res*. 1979;87(3):217-224.

17. Molven O, Halse A. Success rates for gutta-percha and Kloroperka N-0 root fillings made by undergraduate students: radiographic findings after 10-17 years. *International Endodontic Journal*. 1988;21(4):243-250.
18. Allen RK, Newton CW, Brown CE, Jr. A statistical analysis of surgical and nonsurgical endodontic retreatment cases. *Journal of Endodontics*. 1989;15(6):261-266.
19. Sjogren U, Hagglund B, Sundqvist G, Wing K. Factors affecting the long-term results of endodontic treatment. *Journal of Endodontics*. 1990;16(10):498-504.
20. Friedman S, Mor C. The success of endodontic therapy--healing and functionality. *J Calif Dent Assoc*. Jun 2004;32(6):493-503.
21. Torabinejad M, Corr R, Handysides R, Shabahang S. Outcomes of nonsurgical retreatment and endodontic surgery: a systematic review. *Journal of Endodontics*. Jul 2009;35(7):930-937.
22. Salehrabi R, Rotstein I. Epidemiologic evaluation of the outcomes of orthograde endodontic retreatment. *Journal of Endodontics*. May 2010;36(5):790-792.
23. Wolcott J, Ishley D, Kennedy W, Johnson S, Minnich S, Meyers J. A 5 yr clinical investigation of second mesiobuccal canals in endodontically treated and retreated maxillary molars. *Journal of Endodontics*. 2005;31(4):262-264.
24. Wolcott J, Ishley D, Kennedy W, Johnson S, Minnich S. Clinical investigation of second mesiobuccal canals in endodontically treated and retreated maxillary molars. *Journal of Endodontics*. 2002;28(6):477-479.
25. Hartwell G, Bellizzi R. Clinical investigation of in vivo endodontically treated mandibular and maxillary molars. *Journal of Endodontics*. 1982;8(12):555-557.
26. Weller RN, Hartwell GR. The impact of improved access and searching techniques on detection of the mesiolingual canal in maxillary molars. *Journal of Endodontics*. 1989;15(2):82-83.
27. Zhang R, Yang H, Yu X, Wang H, Hu T, Dummer PM. Use of CBCT to identify the morphology of maxillary permanent molar teeth in a Chinese subpopulation. *International Endodontic Journal*. Feb 2011;44(2):162-169.
28. Tam A, Yu DC. Location of canal isthmus and accessory canals in the mesiobuccal root of maxillary first permanent molars. *J Can Dent Assoc*. 2002;68(1):28-33.
29. Ferguson DB, Kjar KS, Hartwell GR. Three canals in the mesiobuccal root of a maxillary first molar: a case report. *Journal of Endodontics*. 2005;31(5):400-402.
30. Teixeira FB, Sano CL, Gomes BP, Zaia AA, Ferraz CC, Souza-Filho FJ. A preliminary in vitro study of the incidence and position of the root canal isthmus in maxillary and mandibular first molars. *International Endodontic Journal*. 2003;36(4):276-280.
31. Weine FS, Healey HJ, Gerstein H, Evanson L. Canal configuration in the mesiobuccal root of the maxillary first molar and its endodontic significance. *Oral Surg Oral Med Oral Pathol*. 1969;28(3):419-425.
32. Vertucci FJ. The endodontic significance of the mesiobuccal root of the maxillary first molar. *US Navy Medicine*. 1974;63(5):29-31.
33. Fogel HM, Peikoff MD, Christie WH. Canal configuration in the mesiobuccal root of the maxillary first molar: a clinical study. *Journal of Endodontics*. 1994;20(3):135-137.

34. Pecora JD, Woelfel JB, Sousa Neto MD, Issa EP. Morphologic study of the maxillary molars. Part II: Internal anatomy. *Braz Dent J.* 1992;3(1):53-57.
35. Ricucci D. Three independent canals in the mesial root of a mandibular first molar. *Endod Dent Traumatol.* 1997;13(1):47-49.
36. Seidberg BH, Altman M, Guttuso J, Suson M. Frequency of two mesiobuccal root canals in maxillary permanent first molars. *J Am Dent Assoc.* 1973;87(4):852-856.
37. Sempira HN, Hartwell GR. Frequency of second mesiobuccal canals in maxillary molars as determined by use of an operating microscope: a clinical study. *Journal of Endodontics.* 2000;26(11):673-674.
38. Schwarze T, Baethge C, Stecher T, Geurtsen W. Identification of second canals in the mesiobuccal root of maxillary first and second molars using magnifying loupes or an operating microscope. *Aust Endod J.* 2002;28(2):57-60.
39. al Shalabi RM, Omer OE, Glennon J, Jennings M, Claffey NM. Root canal anatomy of maxillary first and second permanent molars. *International Endodontic Journal.* 2000;33(5):405-414.
40. Kulid JC, Peters DD. Incidence and configuration of canal systems in the mesiobuccal root of Maxillary first and second molars. *Journal of Endodontics.* 1990;16(7):311-317.
41. Pomeranz HH, Fishelberg G. The secondary mesiobuccal canal of maxillary molars. *J Am Dent Assoc.* 1974;88(1):119-124.
42. Peikoff MD, Christie WH, Fogel HM. The maxillary second molar: variations in the number of roots and canals. *International Endodontic Journal.* 1996;29(6):365-369.
43. Stropko JJ. Canal morphology of maxillary molars: clinical observations of canal configurations. *Journal of Endodontics.* 1999;25(6):446-450.
44. Neaverth EJ, Kotler LM, Kaltenbach RF. Clinical investigation (in vivo) of endodontically treated maxillary first molars. *Journal of Endodontics.* 1987;13(10):506-512.
45. Henry BM. The fourth canal: its incidence in maxillary first molars. *J Can Dent Assoc.* 1993;59(12):995-996.
46. Cotton TP, Geisler TM, Holden DT, Schwartz SA, Schindler WG. Endodontic applications of cone-beam volumetric tomography. *Journal of Endodontics.* Sep 2007;33(9):1121-1132.
47. Gorduysus MO, Gorduysus M, Friedman S. Operating microscope improves negotiation of second mesiobuccal canals in maxillary molars. *Journal of Endodontics.* 2001;27(11):683-686.
48. Rampado ME, Tjaderhane L, Friedman S, Hamstra SJ. The benefit of the operating microscope for access cavity preparation by undergraduate students. *Journal of Endodontics.* Dec 2004;30(12):863-867.
49. Buhrley LJ, Barrows MJ, BeGole EA, Wenckus CS. Effect of magnification on locating the MB2 canal in maxillary molars. *Journal of Endodontics.* 2002;28(4):324-327.
50. Brynolf I. Histological and roentgenological study of periapical region of upper human incisors. *Odontologisk Revy.* 1967;18 Suppl. 11.
51. Patel S, Kanagasingam S, Pitt Ford T. External cervical resorption: a review. *Journal of Endodontics.* May 2009;35(5):616-625.
52. Patel S. New dimensions in endodontic imaging: Part 2. Cone beam computed tomography. *International Endodontic Journal.* Jun 2009;42(6):463-475.

53. Durack C, Patel S, Davies J, Wilson R, Mannocci F. Diagnostic accuracy of small volume cone beam computed tomography and intraoral periapical radiography for the detection of simulated external inflammatory root resorption. *International Endodontic Journal*. Feb 2011;44(2):136-147.
54. Lofthag-Hansen S. Cone beam computed tomography radiation dose and image quality assessments. *Swedish Dental Journal - Supplement*. 2009(209):4-55.
55. Estrela C, Bueno MR, Leles CR, Azevedo B, Azevedo JR. Accuracy of cone beam computed tomography and panoramic and periapical radiography for detection of apical periodontitis. *Journal of Endodontics*. Mar 2008;34(3):273-279.
56. Imura N, Hata GI, Toda T, Otani SM, Fagundes MI. Two canals in mesiobuccal roots of maxillary molars. *International Endodontic Journal*. Nov 1998;31(6):410-414.
57. Bauman R, Scarfe W, Clark S, Morelli J, Scheetz J, Farman A. Ex vivo detection of mesiobuccal canals in maxillary molars using CBCT at four different isotropic voxel dimensions. *International Endodontic Journal*. Aug 2011;44(8):752-758.
58. Ludlow JB, Davies-Ludlow LE, Brooks SL, Howerton WB. Dosimetry of 3 CBCT devices for oral and maxillofacial radiology: CB Mercuray, NewTom 3G and i-CAT. *Dentomaxillofac Radiol*. Jul 2006;35(4):219-226.
59. White SC, Pharoah MJ. *Oral Radiology: Principles and Interpretation*. St. Louis, Missouri: Mosby Elsevier; 2009.
60. Barnett F. Cone Beam-Computed Tomography in Endodontics. *Endodontics: Colleagues for Excellence*. Chicago: American Association of Endodontists; 2011:1-7.

PLACE YOUR NEXT ADVERTISEMENT HERE!

Display advertising in the Texas Dental Journal is one of the best ways to reach the majority of Texas dentists. Published monthly, the Journal's circulation exceeds 9,000, its readership exceeds 50,000, and it's the only statewide publication of its kind to reach the majority of Texas dentists. Provide promo code **TDJ78704** to receive a 10% discount on display advertising! TDA PERKS Partners, allied groups, and non profits receive additional discounts. For more information, contact TDA Publications Coordinator Lauren Oakley lauren@tda.org, 512-443-3675 ext 150.



DENTAL CHAIR UPHOLSTERY KITS

If your dental chair upholstery snaps, bolts or Velcros to a chair frame, you have a 'kit' style chair. These cushions remove easily and the new upholstery goes on just as easily. If you are not sure if your chair is a 'kit' style, give us a call, or e-mail us a picture. Kit style chairs include, Adec, Pelton Crane, Belmont, Healthco, and others We have specialized in upholstering dental chairs since 1985, shown at the Chicago Midwinter for 23 years, and are experienced in all makes and models. Our shippable, kit style chairs can be half the cost of on-site upholstery, or new upholstery from the manufacturer. We also replace broken plastic original parts, with sturdier plastic or plywood parts, where needed. Call us today to discuss your upholstery needs!

MILLER DENTAL UPHOLSTERY
STEVE MILLER
630-761-1450
E-DENTALUPHOLSTERY.COM
S.MILLER8@COMCAST.NET